COUNTWAY LIBRARY
HC 4ZGT R

28.D.288.

A TREATISE

ON

DISEASES OF THE EYE

BY

JOHN ELMER WEEKS, M.D.

PROFESSOR OF OPHTHALMOLOGY IN THE UNIVERSITY AND BELLEVUE HOSPITAL MEDICAL COLLEGE (MEDICAL DEPARTMENT OF NEW YORK UNIVERSITY); SURGEON TO THE NEW YORK EYE AND EAR INFIRMARY; MEMBER OF THE AMERICAN OPHTHALMOLOGICAL SOCIETY; HONORARY MEMBER OF THE ROYAL HUNGARIAN MEDICAL SOCIETY OF BUDAPEST, ETC.

WITH 528 ENGRAVINGS AND 25 FULL-PAGE PLATES IN COLORS

LEA & FEBIGER
NEW YORK AND PHILADELPHIA
1910

11811

Entered according to Act of Congress, in the year 1910, by

LEA & FEBIGER,

in the Office of the Librarian of Congress. All rights reserved.

THESE PAGES ARE

AFFECTIONATELY DEDICATED TO MY WIFE.

THE AUTHOR.

PREFACE.

In preparing this volume it has been the design of the author to produce a treatise on ophthalmology that will enable the undergraduate in medicine to obtain a sufficiently comprehensive and trustworthy knowledge of the subject, a book to which the practitioner of medicine may refer for information regarding questions concerning the eye, and also a book which may be of use to the specialist in ophthalmology.

The work includes a description of the embryology and anatomy of the eye and the principles of optics, as well as the clinical aspects of the subject, as, in the opinion of the author, a knowledge of these is necessary to a full understanding of the pathological processes discussed, and it is convenient to have them embodied in one volume. As little theory as possible has been given, and this only when facts were not sufficient to explain the phenomena described. The endeavor has been made to present the subject in as direct a manner as possible, describing conditions and accepted methods of treatment as briefly as is compatible with a full exposition of each topic. Due weight has been given to recent developments in ophthalmology, including the role of microörganisms. The application of modern methods of treatment in affections of the eye has been fully considered.

The author gratefully acknowledges his indebtedness and tenders his thanks to the gentlemen who have aided him in the preparation of this volume, particularly to Dr. William Norwood Souter, who has contributed the chapter on the General Principles of Optics; to Dr. Alexander Duane, for the chapter on Movements of the Eyeballs and Their Anomalies; to Dr. George S. Dixon, for a description of his method of localizing foreign bodies in the eye, and for numerous excellent photographs used for illustration; to Dr. Robert G. Reese and Dr. S. Lewis Ziegler, each for descriptions of operations and for illustrative drawings; to Dr. A. Maitland Ramsay, of Glasgow, Scotland, for colored drawings depicting pathological conditions; to Dr. R. Linder, of Vienna, Austria, for a colored drawing of the chlamydozoan of Halberstädter and Prowazek; also to Messrs. G. B. Meyrowitz and George Tiemann & Co. for cuts of instruments.

The author also desires to express his thanks to Messrs. Lea & Febiger for their courteous treatment in the publication of this work.

John E. Weeks.

New York, 1910.

CONTENTS

CHAPTER I

Development 17

CHAPTER II

Anatomy 29

CHAPTER III

General Principles of Optics 88

CHAPTER IV

Examination 110

CHAPTER V

The Eyelids 155

CHAPTER VI

The Lachrymal Apparatus 195

CHAPTER VII

The Conjunctiva 211

CHAPTER VIII

The Cornea 262

CHAPTER IX

The Sclera 312

CHAPTER X

The Iris 320

CHAPTER XI

The Ciliary Body 349

CHAPTER XII

The Chorioid 359

CHAPTER XIII

Uveitis 384

CHAPTER XIV

Sympathetic Ocular Manifestations 388

CHAPTER XV

Glaucoma 397

CHAPTER XVI

The Retina 423

CHAPTER XVII

The Optic Nerve and Optic Chiasm 491

CHAPTER XVIII

Amblyopia, Amaurosis, and Hemianopsia without Intra-ocular Inflammatory Manifestations 527

CHAPTER XIX

Toxic Amblyopia and Amaurosis 544

CHAPTER XX

Asthenopia and Hysteria 562

CHAPTER XXI

Diseases of the Crystalline Lens 571

CHAPTER XXII

The Vitreous 596

CHAPTER XXIII

The Eyeball 607

CHAPTER XXIV

The Orbit 618

CHAPTER XXV

Relation of Diseases of the Throat, the Nose, and the Accessory Sinuses to the Eye 641

CHAPTER XXVI

Refraction 646

CHAPTER XXVII

Movements of the Eyeballs and their Anomalies 709

CHAPTER XXVIII

Ocular Conditions Connected with General Disease 759

CHAPTER XXIX

Operations 774

CHAPTER XXX

Special Remedies 895

CHAPTER XXXI

Preparation of Specimens for Diagnosis in the Search for Micro-organisms 907

DISEASES OF THE EYE.

CHAPTER I.

DEVELOPMENT.

In the development of the mammalian embryo the ovum, which is the primitive cell, divides by indirect cell division (karyokinesis) into two cells; these again divide and subdivide until a more or less globular cell mass is developed. A cavity soon forms within this mass of cells known as the *blastocele*. The cells are arranged in an even layer around the central spherical cavity, forming the *blastodermic vesicle*. Soon, by a multiplication of cells, a thickened oval area is formed at some part of the wall of the blastodermic vesicle, which is known as the *germinal area*, from which the embryo develops.

Fig. 1

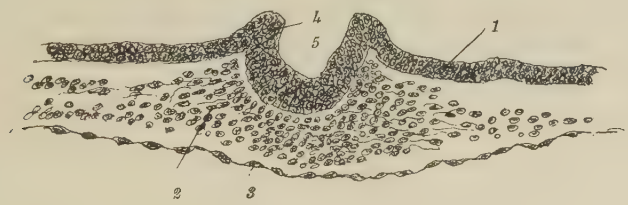

Embryo of chick: 1, ectoderm; 2, mesoderm; 3, entoderm; 4, dorsal plate; 5, medullary groove.

The germinal area, by a multiplication of its cells, becomes differentiated into three layers, the outer of which is known as the *ectoderm* or epiblast; the inner, the *entoderm* or hypoblast; the third, lying between the other two, the *mesoderm* or mesoblast. The eye is developed from the ectoderm and mesoderm. From the ectoderm are developed the lens, retina, optic nerve, inner layers of ciliary body and iris, epithelium of the cornea, epithelium of the conjunctiva, of the lids and nasal duct, the Meibomian glands, the cilia, and the ocular nerves. From the mesoderm are developed the chorioid, outer layers of ciliary body and iris, deeper layers of the cornea, blood-vessels, humors of the eye, muscles and tissues of the orbit. Soon, by a thickening of the ectoderm, parallel ridges appear, which develop into the *dorsal plates;* between these ridges a groove, known as the *medullary groove*, is formed (Fig. 1).

The ridges of the dorsal plates grow higher, approach each other, and become united, forming a canal known as the *medullary canal* or tube. This tube gradually becomes detached from the external layer of ectoderm, and surrounded by mesodermic tissue. From one end of the medullary tube the *encephalon* is developed, the remaining portion forming the spinal cord. The closure of the tube and the detachment proceed from the cephalic end. At the extremity destined to develop the encephalon the tube grows larger and becomes flexed upon itself ventrally. This bend is termed *the cranial flexure.* The medullary tube at this stage of development consists of a wall of epiblastic cells enclosing a space which is filled with fluid; it is, in fact, an elongated vesicle. Three enlargements are soon recognizable at the cephalic extremity. These are known as the *cerebral vesicles.*

Fig. 2

Chick embryo of thirty-three hours' incubation, viewed from the dorsal aspect. × 30. (From Duval's Atlas d'Embryologie.)

Primary Eye Vesicle.—The development of the eye is from the lateral portion of the anterior cerebral vesicle. It is first manifest by a slight bulging of the lateral wall of the anterior cerebral vesicle; soon distinct processes, lying laterally, are apparent. The apices of these processes are in close relation to the external layer of ectoderm; the cavity is continuous with the cavity of the cerebral vesicle. At this stage of development the rudimentary eye is known as the *primary eye vesicle.*

Traces of the primary eye vesicle are observable at a very early stage in the development of the embryo; in the chick, at the end of twenty-five hours; in the human embryo, on the eighteenth to twenty-first day.[1] The lateral position which the eye obtains in the early development of the embryo is permanent in many of the lower vertebrates, but in man, because of the lengthening of the optic nerve and the shifting of the adjacent organs, the eyes are gradually brought to an anterior position.

[1] Coste, Histoire du Développement, Paris, 1847, 1860.

Secondary Eye Vesicle.—The external layer of ectoderm, with which the primary eye vesicle is almost in contact, now consists of two layers of cells—a large columnar basement layer and a layer of equally large cuboidal surface cells. This layer becomes thickened immediately over the apex of the primary eye vesicle, forming a diverticulum which develops into the rudimentary lens. The cells forming the apex of the primary eye vesicle take on a more rapid development than the cells of other parts; the apex broadens and tends to fold upon itself. A depression is formed, converting the projecting stem into a cup-shaped process—the *secondary eye vesicle*[1] or optic cup (Foster and Balfour). The depression thus formed is filled by the developing lens.

Fig. 3

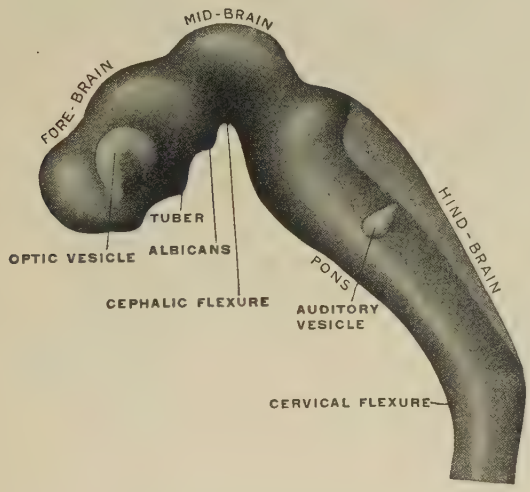

Profile view of the brain of a human embryo of about fifteen days, reconstructed from sections (After His.)

The secondary eye vesicle now consists of a depressed inner or anterior wall, from which the retina proper is developed, an outer wall, from which the pigment layer of the retina is formed, and a now narrow stem or stile, which connects it with the anterior cerebral vesicle. The cavity of the cerebral vesicle is continuous through the stile with the space between the inner and outer walls of the optic cup. The optic cup forms the foundation for the globe, and on its perfect development depends the perfect formation of the eyeball. At this stage the optic cup is not perfect; a narrow defect, the *retinal fissure*, exists in the lower inner portion, which extends from the margin of the cup into the stem or pedicle. It was formerly described as the chorioidal fissure, as it was thought that the chorioid was responsible for its presence. The retinal fissure gives entrance to mesodermic tissue into the space between the rudimentary lens and the inner or retinal wall of the optic cup.

[1] Kölliker, Entwickelungsgeschichte des Menschen, etc., 1861.

From this tissue the vessels which traverse the vitreous chamber and the vitreous body are formed.

One large arterial vessel, the *hyaloid artery,* extends from the optic stem to the posterior pole of the lens, giving off branches which spread out over the inner aspect of the inner or retinal wall of the optic cup, and branches that extend into the vitreous chamber. Smaller vessels pass up through the fissure into the vitreous chamber and are concerned in the development of the vitreous body. The formation of the mesodermic tissue into vitreous body does not begin until about the fourth week in the human embryo, and is not complete until much later.

Fig. 4

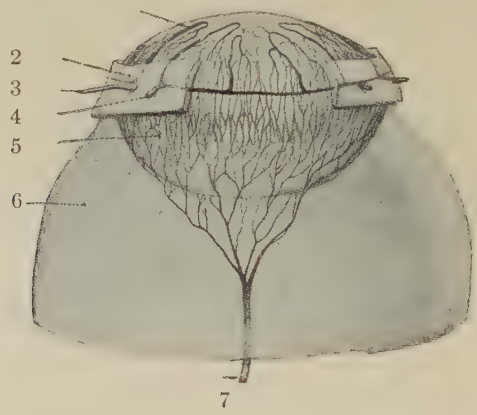

Vascular tunic of lens from a human embryo of eight months. A portion of the uvea is excised: 1, membrana pupillaris; 2, iris; 3, arteria ciliaris longa; 4, arteria ciliaris brevis; 5, membrana capsularis; 6, corpus vitreum; 7, arteria hyaloidea. (Kollmann.)

In the human embryo the retinal fissure closes early, ordinarily, leaving no trace of its existence. In rare cases partial closure only occurs when the congenital defects known as coloboma of the nerve, of the chorioid, and of the iris, and very rarely cyst of the sclera and microphthalmos occur. The groove in the optic stem gradually closes by approximation of its margins, including the mesoderm and the blood-vessels, the latter forming the arteria and vena retinæ centralis.

Development of the Lens.—By an increase in the cells of the ectoderm forming the walls of the lens pit the pit deepens, its borders approach and coalesce, converting it into a sac, the *lens vesicle.* The lens vesicle soon becomes detached from the outer layer of ectoderm and lies in the opening of the optic cup. At this stage the walls of the lens vesicle are of almost uniform thickness, and consist of two or three layers of elongated epithelial cells, which are placed with their long axes perpendicular to the surface of the vesicle and are interlaced. The outer cells lie on a delicate homogeneous membrane, the rudiment of the lens capsule. The cells of the inner or posterior wall of the lens capsule become elongated and rapidly form primitive lens fibers; they

PLATE I

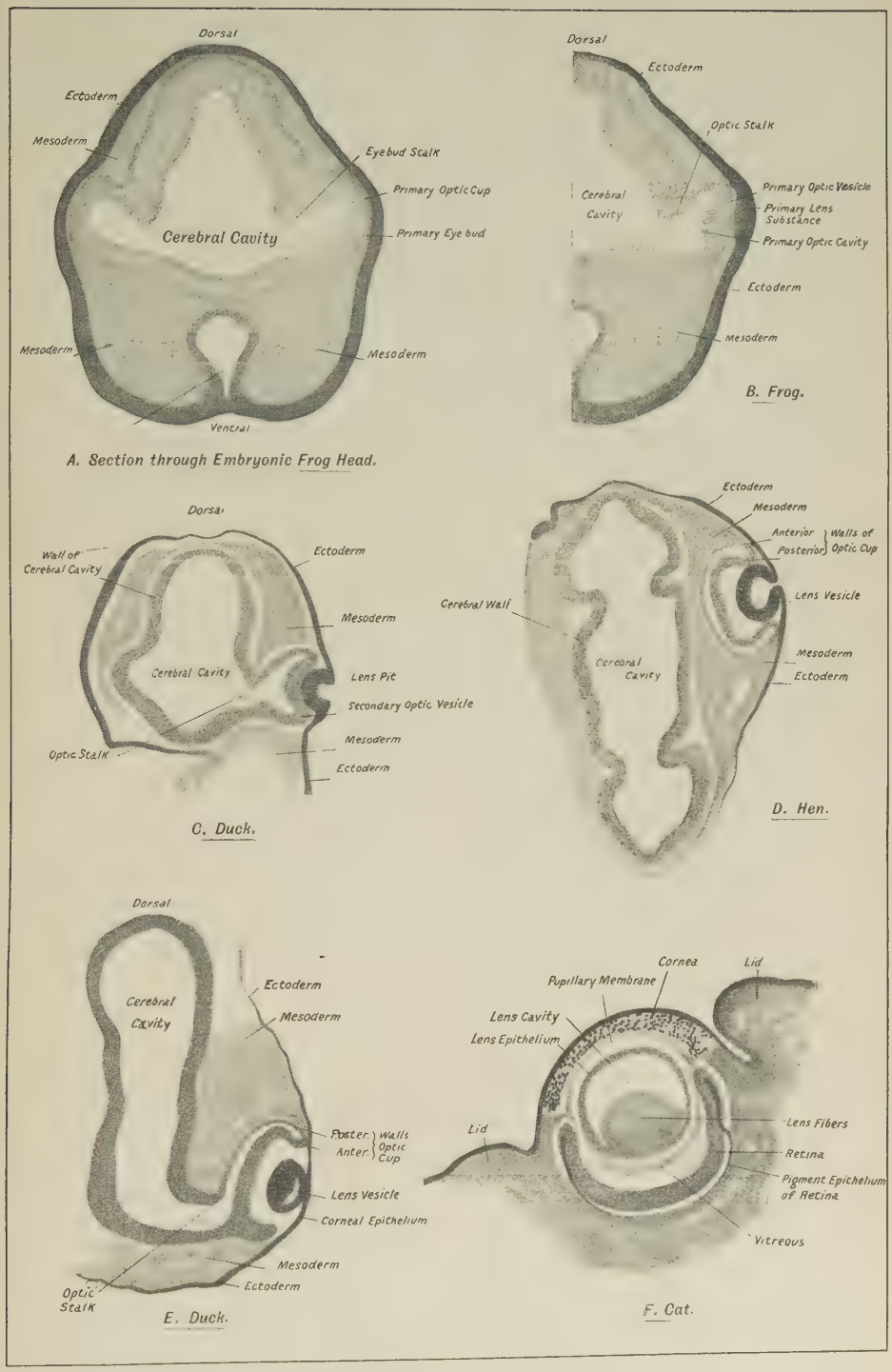

Development of the Eye. (Fick.)

PLATE II

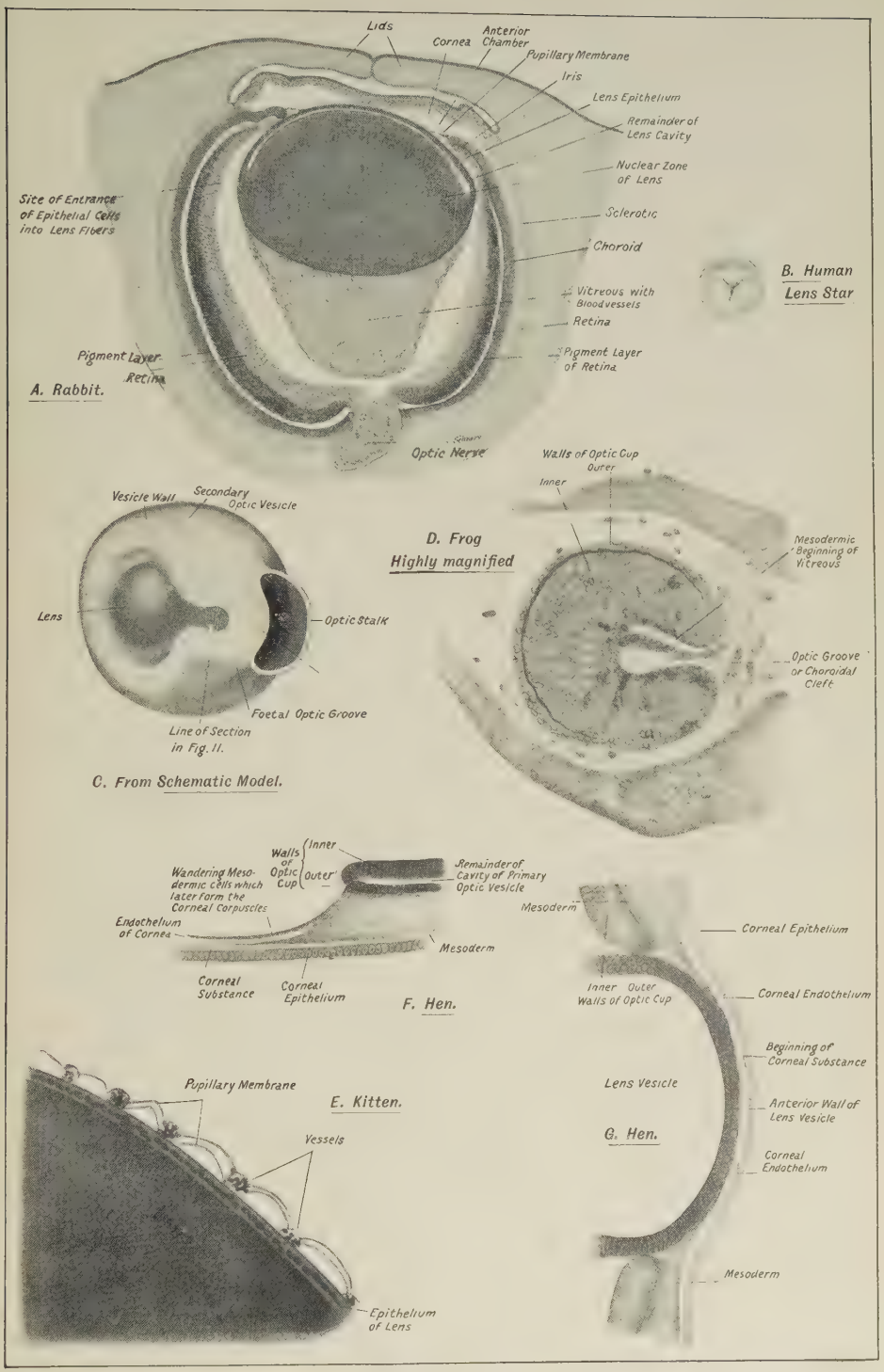

Development of the Eye. (Fick.)

extend forward uniformly from the posterior wall into the cavity of the lens capsule and eventually completely fill it, obliterating the cavity and impinging upon the cells lining the anterior wall of the vesicle. These fibers form the nucleus proper of the lens. (See Plates I and II.) The cells of the anterior half of the lens wall lose their columnar shape and assume the cuboidal form, which they retain. The cells lining the anterior portion of the lens capsule increase in number and crowd toward the equator of the lens. At the equator of the lens these cells become elongated and form new lens fibers, which are added to the primary fibers in superimposed layers. The place at the equator of the lens where the epithelium of the anterior portion of the capsule elongates to form lens fibers is known as the *lens whorl* (Fig. 5). The individual fibers abut upon each other in regular order, forming rays, or lines of contact, "*lens figures*," where their extremities join. The *lens figures* are geometrical and, primarily, consist of three lines anteriorly and three posteriorly. The lines unite at the poles of the lens and diverge

Fig. 5

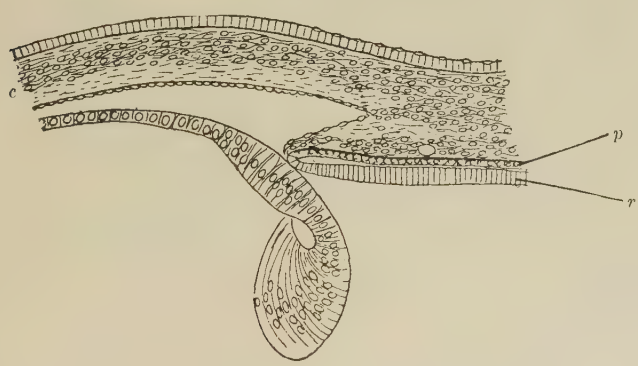

Lens whorl. Meridional section of the embryo of a chick at eight days: *c*, cornea; *l*, lens; *r*, retina; *p*, pigment layer of retina. (After Kessler.)

at an angle of 120 degrees. The form of the anterior figure is approximately that of an inverted Y, the upper limb being in the vertical meridian. The posterior figure is approximately that of an upright Y. These figures lose their simplicity, as the growth of the lens advances, by the appearance of secondary rays, which branch from the primary ones.

The weight of the lens in the newborn is, according to Hasche, 0.123 gram; of the adult, 0.19 gram.

Lens Capsule.—A thin, delicate, homogeneous membrane, the beginning lens capsule, can be seen even before the lens vesicle has become detached from the ectoderm overlying it (Figs. 6, 7, 8). The membrane gradually increases in thickness. There is a difference of opinion regarding the origin of this membrane. Because of the fact that the lens capsule begins to develop before vascular mesoblastic tissue is

present, Kölliker, Kesler, and H. Müller believe it to be a cuticular formation springing from the cells of the ectoderm that form the lens; this view is also held by Collins and Hess, and is in all probability the correct one. Zemof and Waldeyer believe it to be of mesodermic origin, and Manz and Schwalbe have entertained the opinion that it may have a twofold source of origin. Its chemistry would seem to indicate that it is not of mesodermic origin.

Fig. 6

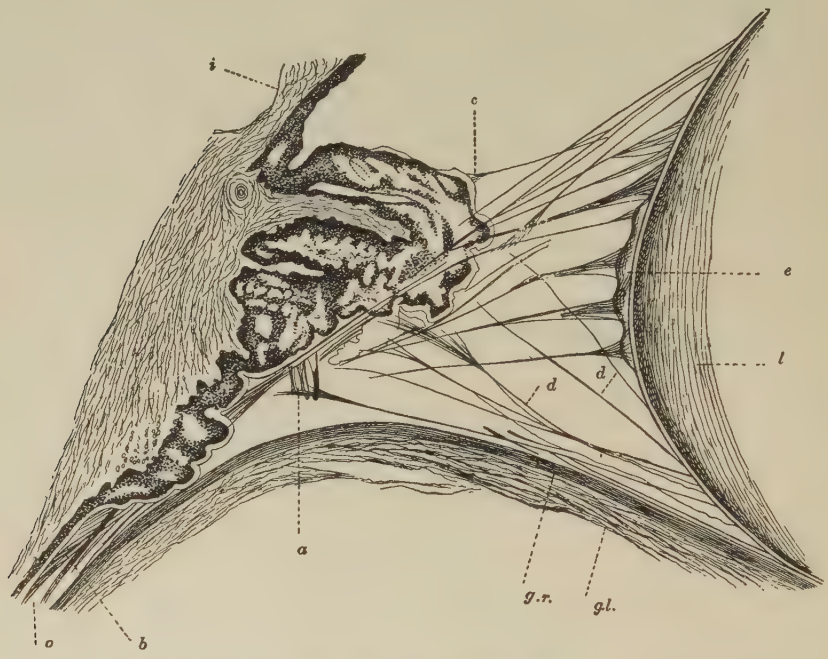

Meridional section through the ciliary region of an adult human eye: *l*, equatorial periphery of lens; *g.l.*, vitreous substance; *g.r.*, anterior boundary of same; *e*, orbicular space; *i*, root of iris; *a*, short, robust attachment fibers of the posterior zonular trabeculæ; *b*, posterior fibers related to vitreus; *c*, anterior fibers from ciliary processes; *d*, ciliary fibers crossing and adhering to the zonular trabeculæ; *e*, clefts between the pericapsular membrane and the lens capsule. Low amplification. (Retzius.)

Vascular Membrane.—Nutrition for the development of the lens is provided by the development of a vascular membrane, which entirely surrounds it from the second month until near the end of gestation, and is known as the *tunica vasculosa lentis*. This membrane is apparently developed from two sources, namely, as an extension of the vessels which form in the vitreous humor, the principal one of which is the hyaloid artery, and from the vessels that form in the tissue of the iris, the anterior ciliary vessels. The vessels from these two sources break up into a fine capillary network just outside of the capsule of the lens and completely surround the lens.

Where this vascular membrane occupies the pupillary area it is

known as the *fetal pupillary membrane,* remnants of which sometimes persist throughout adult life. In rare cases remnants of the tunica vasculosa lentis remain attached to the posterior capsule of the lens, forming very small, white, fibrous deposits near, or at, the posterior pole of the lens. Examination with high powers of the microscope fails to reveal any blending of the mesoblastic tissue of the tunica vasculosa lentis with the lens capsule.

Suspensory Ligament.—The lens is held in position between the aqueous and vitreous chambers of the eye by a ligament which is composed of numerous very thin bands or ribbons. These minute bands are attached to the lens capsule and intimately incorporated with it. They extend outward and backward, and are continuous with cells (ectodermic) that form the inner layer of the ciliary body, the *pars ciliaris retinæ.*

Mr. Treacher Collins[1] discusses the development as follows: "Gradually the ingrowing process (lens vesicle) gets cut off from the surface epiblast, forming thus the primitive lens, which next becomes separated from the inner layer of the secondary optic vesicle at the posterior part, by the formation of the vitreous. It remains, however, for a long time in contact with it at its sides; that is, at that part in which, subsequently, the ciliary body becomes developed. The lens becomes encircled by what is termed its fibrovascular sheath, derived in part from the central artery of the vitreous, and in part from vessels growing in between the lens and the cornea. The portion of the inner layer of the secondary optic vesicle still in contact with the lens—that is, the pars ciliaris retinæ—acquires adhesions to this sheath. Then, as the eyeball enlarges, it does so at a greater rate than the lens, so that a portion of the ciliary body, which was in contact with the lens, grows away from it, and the adhesions which have formed between them become stretched, and the cells forming them much elongated, until only fibers with nuclei lying on them can be distinguished, and ultimately the nuclei also go, leaving only the delicate fibers of the suspensory ligament as we see them in the adult eye. The lens is at first sight of a globular shape, measuring almost as much anteroposteriorly as laterally. From the drag exerted on its capsule at its peripheral parts, by the growing away from it of the ciliary body, which has acquired adhesions to it, it tends to increase in size laterally more than anteroposteriorly, and hence assumes the lenticular form of the adult lens."

The adhesions between the lens and secondary eye vesicle extend as far backward as the *ora serrata retinæ,* to which some of the fibers of the suspensory ligament are attached; to the traction of these fibers the serrations at the margin of the layer of nervous tissue (ora serrata) are due. Collins further states that: "I have been unable to determine definitely whether the cells from which these fibers develop are derived from the fibrovascular sheath of the lens, or from the cells of the inner layer of the secondary optic vesicle which form the pars

[1] Royal London Ophthalmological Hospital Reports, December, 1890, vol. xiii, p. 83.

ciliaris retinæ, or in part from one and in part from the other. The fact that they belong to the connective tissue class would lead one to expect that they are more likely mesoblastic in origin, and therefore derived from the fibrovascular sheath, than epiblastic, and derived from the pars ciliaris retinæ."

Retina.—As the invagination of the *anterior* portion of the eye vesicle proceeds, this portion increases in thickness, and by the time that it comes into contact with the posterior part it is many times thicker. The portion destined to become retina, by rapid proliferation of its cells, continues to increase in thickness and become differentiated, forming two kinds of tissue—the nervous elements proper and the sustentacular (supporting) tissue from which the fibers of Müller are derived. An outer, richly nucleated zone appears early—the rudiment of the two nuclear layers. This zone soon divides, a narrow non-nucleated zone appearing, which becomes the *external reticular* layer. The *outer nuclear* layer is that from which the rods and cones, until now absent, are to develop, forming the *visual cells* of the retina. The inner nuclear layer represents the *bipolar cells.* The inner zone soon becomes differentiated into a layer of large cells—the *ganglion cells*, and into the *inner reticular layer.* This process of differentiation does not extend to the margin of the optic cup, but stops abruptly at an irregular line—*ora serrata.*

The anterior wall of the optic cup that extends forward from the ora serrata is composed of a number of layers of non-pigmented columnar cells, which lie in contact with the posterior wall of the optic cup. The posterior wall has resolved itself into a single layer of cells in which fine pigment granules have been deposited, forming the *pigment layer of the retina.* The pigment layer extends to the free margin of the optic cup (secondary eye vesicle) and is, at this period, accompanied beyond the ora serrata by the non-pigmented cells of the inner wall. The cells of the pigment layer increase rapidly and apparently cause a reduplication at the margin of the optic cup. In the adult eye this reduplication extends from the anterior border of the ciliary body to the free margin of the iris. It forms the posterior pigmented layer of the iris, and is termed *pars iridis retinæ.* The double layer of cells which extends from the ora serrata to the root of the iris and is derived from the optic cup is termed *pars ciliaris retinæ.*

An ingrowth of mesodermic tissue (connective tissue) accompanies the blood-vessels, and fine fibrillæ of the same tissue extend into the layer of vessels and nerve fibers through the interspaces between the heads of the sustentacular fibers of Müller.

The line of demarcation (ora serrata) between the portion of the anterior wall of the optic cup that contains the nervous elements and the portion that extends forward to the anterior margin of the cup is not distinctly marked, even at the end of fetal life, but many minute tufts appear, six to eight hundred[1] in number, which mark the attach-

[1] Schoen. Anatom. Anzeiger, 1894–95, Band x.

ment of fibers of the suspensory ligament. Subsequent traction serves to make this annular line of tufts (the extreme posterior limit of the attachment of fibers of the suspensory ligament) more prominent, and the serrations in this line become more marked. Eventually about forty rather pronounced serrations are formed between which there are many smaller ones.

Fig. 7

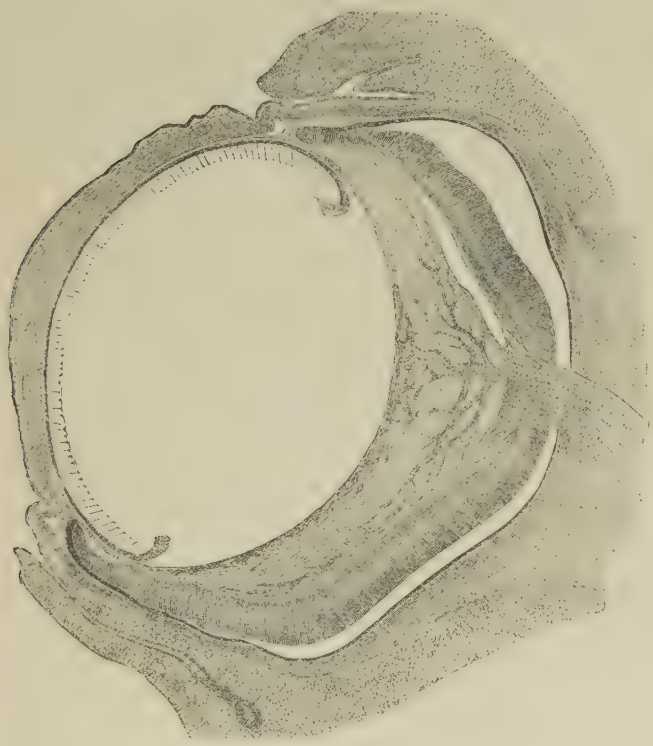

Further development of the eye as shown by a section through an eye of a pig embryo. (Kölliker.)

According to Schultze, the retina in the fetus is nourished by the posterior ciliary arteries. In regard to the origin of the retinal vessels, the view generally held is that they are derived from the vessels of the mesoderm that enter the eye through the groove in the optic stem. The lymphatics of the retina develop with the blood-vessels and accompany them as perivascular spaces.

Optic Nerve.—The fibers of the optic nerve that first appear are those that develop from the ganglion cells of the retina—centripetal fibers. Investigations by Froriel, Cajal, Assheton, and others have determined the fact that the centripetal optic nerve fibers converge and pass over the ventral wall of the optic cup at the apex of the retinal fissure, in the form of axis cylinders. On reaching the optic stem they grow in the groove on the lower aspect of the stem, and are apparently

thus conducted to the brain. While the nerve fibers from the neurons of the retina are the first to develop, and form the greater number of nerve fibers in the optic nerve, other axis cylinders grow from the neurons in the brain (centrifugal fibers), and advance into the optic nerve. The optic stalk does not take part in the formation of the nervous tissue of the optic nerve. By invagination of the stalk and proliferation of the cells of the walls of the stalk, its lumen becomes obliterated. The optic stem gradually disappears, giving place to the solid bundle of nerve fibers, its cells developing into supporting (neuroglia) tissue. The medullary envelope of the nerve fibers begins to form about the end of the sixth month of fetal life, first appearing in the optic tracts and advancing slowly toward the lamina cribrosa. The medullary substance has not reached the eyeball at the birth of the child; it is fully developed only some months afterward.

Fibrous and Vascular Coats.—The primary eye vesicle is everywhere surrounded by formative mesodermic cells except where it lies in contact with the ectoderm, the eye vesicle apparently serving as a form over which the fibrous and vascular coats develop. Soon after the lens capsule becomes detached from the parent ectoderm, a layer of mesoderm develops between the lens and the ectoderm. Preceding this a thin homogeneous layer appears lying immediately below the cells of the ectoderm, apparently developing from them. This is the *membrane of Bowman,* the so-called anterior elastic lamina, or basement membrane.

The mesoderm lies in contact with the anterior capsule of the lens primarily. Minute blood-vessels, extending from the mesoderm that surrounds the optic cup, form in the portion which lies next to the capsule of the lens, becoming continuous with the blood-vessels which are derived from the mesodermic tissue behind the lens. A cleft in the mesodermic tissue immediately in front of the lens soon appears (the primitive aqueous chamber), leaving a very thin vascularized layer (the fetal pupillary membrane) next to the lens, and a relatively thick layer over the surface of the anterior portion of the optic cup. This subsequently becomes iris. The portion of mesodermic tissue that lies immediately behind the ectoderm in front of the crystalline lens subsequently becomes the *substantia propria* of the *cornea.* The cells lining the space between the two layers become flattened, and form the *endothelium* of the cornea and of the iris. The formation of the *ligamentum pectinatum* and of *Descemet's* membrane are closely associated with the differentiation of the anterior part of the vascular tunic, and have been termed the *pars uvealis corneæ.*

Early in the third month an annular proliferation of cells, occurring in the anterior portion of the optic cup just back of its free margin, throws it into meridional folds, between which the tissue of the mesoderm dips externally. These delicate processes, which project from a thickened ring of mesodermic tissue, the future *ciliary body,* become highly vascular, forming the *ciliary processes.* A little farther back on the optic cup, lying close to the pigment layer, numerous capillary blood-

vessels develop which form the *choriocapillaris* of the chorioid. Larger vessels appear in the tissue just outside of the choriocapillaris, which eventually form the layer of large vessels of the chorioid. A condensation and proliferation of the cells of the mesoderm, continuous with the substantia propria of the cornea, takes place and is differentiated into *sclera.* A space develops between the embryonic chorioid and *sclera,* the *perichorioidal lymph space.* This is in connection—by means of lymph spaces which surround the vessels that pierce the sclera—with a lymph space outside the sclera, which passes forward almost to the margin of the cornea and backward to the sheath of the optic nerve, the *lymph space of Tenon.*

Fig. 8

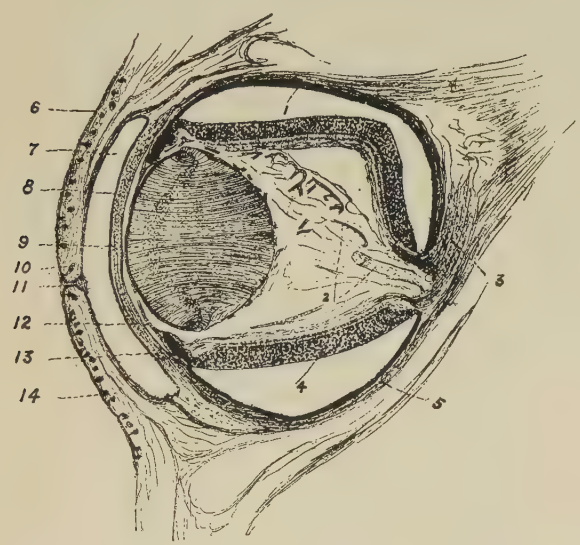

1, posterior layer of wall of secondary eye vesicle (pigment layer of retina); 2, hyaloid artery and vessels in vitreous body; 3, optic nerve; 4, anterior layer of wall of secondary eye vesicle; 5, chorioid and sclera; 6, epithelium of lid; 7, conjunctival pouch; 8, epithelium of cornea; 9, cornea; 10, eyelid; 11, prenatal union of eye lids; 12, fetal pupillary membrane; 13, rudiment of ciliary body and iris; 14, glands of skin of lid.

Vitreous Body.—Coincident with the filling of the lens capsule, the mesoderm finds its way through the retinal fissure into the narrow space between the lens and the anterior wall of the optic cup. This space grows larger, developing into the vitreous chamber. Numerous thin-walled blood-vessels appear which ramify in the mesodermic tissue that fills this chamber (Fig. 8). The principal vessel thus formed is the arteria hyaloidea (Fig. 8). A few delicate formative cells are present. A glassy substance, the *vitreous body,* is developed from the mesodermic tissue which eventually fills the space between the lens and retina. About the sixth or seventh month the blood-vessels and the greater part of the cellular elements in the vitreous chamber disappear

and the transparent vitreous body alone is left; the blood-vessels in the centre of the vitreous are the last to go.

Eyelids.—Early in fetal life a fold of the ectoderm, nearly circular in form, appears around the cornea. This increases, developing much more rapidly from above and below than from the sides, soon converting what was at first approximately a circular area between the margin of the folds into a narrow slit. The margins of the folds approach each other and become united by the adhesion of the ectodermic (epithelial) cells. Closure of the slit (palpebral fissure) takes place during the third month of fetal life. Separation of the lids by disintegration of the uniting cells takes place in man during the last month of fetal life. The tissue of the mesoderm, which occupies the space between the layers of ectoderm forming the inner and outer layers of the lids, becomes differentiated into the muscles, subcutaneous tissue, and tarsus.

The *lachrymal, Meibomian, sebaceous,* and *sweat glands* and hair bulbs are developed from solid ingrowths of the surface or ectodermic cells. These are well advanced long before the birth of the child, and the functions of all except the lachrymal glands and sweat glands are established at or before birth. The function of the lachrymal and sweat glands is established from one to six weeks after birth.

Fig. 9

Human embryo of thirty-one days. Magnified 5 diameters. (After His.)

Lachrymal Canals.—The sphenonasal process and the maxillary process approach each other in the development of the head of the fetus, separating the eye from the nasal cavity. The fissure between these processes marks the course of the nasolachrymal groove. The margins of the groove coalesce, converting the floor of the groove into a canal filled with ectodermic cells. With the development of the nose the median end of the tube becomes more deeply seated. The upper end broadens and becomes bifurcated by an ingrowth of mesodermic tissue, forming the *lachrymal canaliculi* and ending on the margin of the lids to form the *puncta lachrymalia.*

Shortly before the birth of the child the cells occupying the centre of the cylinder disintegrate and disappear, establishing the lumen of the lachrymal canaliculi, lachrymal sac, and lachrymal canal. Failure or arrest of the development at any stage may occur.

CHAPTER II.

ANATOMY.

Orbits.—The orbits are two pyramidal cavities in the anterior portion of the skull, which lodge the eyes. They are symmetrically placed, and are separated by a distance of approximately 22 mm. The inner walls of the orbits are placed in the vertical plane, and are almost parallel to each other, being, however, very slightly convex. The roof of the orbit is placed approximately in the horizontal plane. The surface of the roof is not a plane, but is irregularly concave, the concavity being more acute near the margin of the orbit. The angle between the inner

Fig. 10

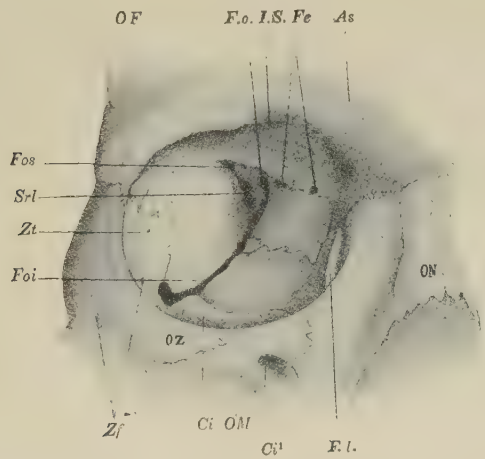

Right orbit: *OF*, frontal bone; *OZ*, malar bone; *OM*, superior maxillary; *ON*, nasal bone; *F.o.*, optic foramen; *Fos*, sphenoidal fissure; *Foi*, sphenomaxillary fissure; *Fe*, ethmoidal foraminæ; *F.l.*, lachrymal fossa; *Ci*, inferior orbital canal; *Ci*¹, anterior opening of the same; *Zt*, zygomatico-temporal canal; *Zf*, zygomatico-facial canal; *Srl*, spine of the external rectus muscle; *I. S.*, supra-orbital fissure; *As*, superciliary arch. (Merkel and Kallius.)

wall and the roof of the orbit is quite acute. The outer wall diverges sharply from the median plane of the head; it inclines slightly inward below, the angles of union with the roof and floor of the orbit are well rounded. The floor of the orbit slopes outward and downward, and joins the inner wall by a rounded obtuse angle.

The *axes* of the orbits, if continued backward, would cross each other just back of the sella turcica at an angle of 42 to 46 degrees. The *plane* of the axes of the orbits projects forward at an angle of 15 to 20 degrees below the horizon. The openings of the orbits are irregularly

quadrilateral; their planes slant backward from their inner margins, forming an angle of 11 degrees with the plane of the face. They measure approximately 40 mm. in the horizontal and 35 mm. in the vertical meridians. The width between the external borders is approximately 98 mm. The depth of the orbit is approximately 43 mm. in men, 40 mm. in women. According to Merkel, the opening of the orbits in the child of five years is only 2 or 3 mm. less than in the adult. The measurements given are average measurements only.

The bones that enter into the formation of the orbit are the frontal, lachrymal, superior maxillary, malar, sphenoid, ethmoid, and palate bones.

Frontal Bone.—The frontal bone forms about two-fifths of the margin of the orbit at its upper portion. At the inner half of the margin of the orbit it is prominent, forming the *superciliary ridge* where it covers the frontal sinus. At one-third of the distance from the mesial wall the margin of the orbit is pierced or grooved, forming the *supra-orbital foramen* or notch for the passage of the supra-orbital nerve. On the roof of the orbit, about four millimeters back of and to the mesial side of the supra-orbital notch, is a small elevation of bone, *the trochlear spine*, to which the pulley of the superior oblique muscle is attached. The frontal bone at the outer margin of the orbit is prominent and strong; immediately beneath the outer third is a depression, the *lachrymal fossa*, in which the lachrymal gland is lodged. The horizontal plate of the frontal bone forms at least four-fifths of the roof of the orbit. It is a thin, hard shell of bone, concave on its lower surface. The inner wall of the orbit is formed by the nasal process of the superior maxilla, the lachrymal bone, and the orbital plate (os planum) of the ethmoid. The superior maxilla, by means of the nasal process, forms about one-fifth of the margin of the orbit at its inner lower part. It is thick and strong.

The orbital surface of the nasal process is grooved, forming with the lachrymal bone, with which it articulates, the lachrymal groove. This groove is continuous with the lachrymal canal, which passes through the superior maxilla and opens into the inferior nasal meatus.

Superior Maxilla.—The orbital plate of the superior maxilla forms the greater part of the floor of the orbit. It articulates on its mesial border with the lachrymal bone, the orbital plate (os planum) of the ethmoid, and the orbital process of the palate bone. The outer margin of the orbital plate articulates with the malar bone. It is separated from the greater wing of the sphenoid by the *sphenomaxillary fissure*, which extends backward to the lesser wing of the sphenoid. The orbital plate of the superior maxilla is grooved from the middle of the sphenomaxillary fissure one-half the distance to the margin of the orbit, the groove being then converted into a canal which terminates on the front aspect of the superior maxilla. This groove and canal are known as the *infra-orbital groove* and *infra-orbital canal*. They give lodgment to the infra-orbital nerve and vessels.

Malar Bone.—The malar bone forms the outer lower two-fifths of the orbital margin. It is a thick, strong mass, and affords good protection

to the contents of the orbit. Its frontal process forms the outer margin of the orbit. It is broad and thick, particularly at its base where it passes over into the *zygomatic process.* Its orbital plate forms about one-third of the outer wall of the orbit. It becomes quite thin before the articulation with the greater wing of the sphenoid is reached.

Sphenoid Bone.—The sphenoid bone, by the orbital surface of its greater wing, forms the posterior half of the outer wall of the orbit. In front it articulates with the malar bone; above with the orbital plate of the frontal bone. It barely touches the orbital plate of the superior maxilla at the anterior end of the sphenomaxillary fissure.

Between the greater and lesser wings of the sphenoid is the *sphenoidal fissure,* which gives passage to the third, fourth, superior branch of the fifth, and the sixth cranial nerves, and to the superior orbital vein. The lesser wing of the sphenoid forms a very small part of the roof of the orbit at its apex, and the lower border of its orbital surface forms the upper margin of the sphenoidal fissure. Between the roots of the lesser wing of the sphenoid is the *optic foramen* or *canal,* which gives passage to the optic nerve and ophthalmic artery. Fracture through this portion of the sphenoid is not very infrequent, producing blindness by pressure on the optic nerve.

Palate Bone.—The *orbital process* of the palate bone forms a very small part of the floor at the apex of the orbit.

Lachrymal Bone.—The lachrymal bone, a small, thin plate of bone situated immediately back of the nasal process of the superior maxilla, presents a vertical ridge in the centre of its orbital surface, the *crista lachrymalis.* The concave anterior half of the lachrymal bone forms, with the nasal process of the superior maxilla, the lachrymal groove which lodges the lachrymal sac. The *crista lachrymalis* affords attachment to the posterior lamella of the inner canthal ligament. The mesial surface of the lachrymal bone is covered by the soft tissues of the nasal cavity. Emphysema of the orbital tissue results most frequently from the fracture of the posterior half of this bone. In the aged, absorption of parts of this bone sometimes occurs, leaving only a membranous septum between orbital and nasal cavities.

Ethmoid Bone.—The *os planum* (lamina papyracea) of the *ethmoid* bone completes the inner wall of the orbit. It is a very thin, hard plate, and separates the orbits from the pneumatic cavities, the ethmoid cells. Portions of this plate not infrequently become absorbed, particularly in the aged. In the suture between the os planum and the orbital plate of the frontal bone are two foramina. The posterior one, situated about 8 mm. anterior to the optic canal, gives passage to the *posterior ethmoid artery* and *vein.* The anterior foramen, situated 17 mm. back of the upper extremity of the crista lachrymalis, gives passage to the *anterior ethmoid artery* and *nasal nerve.*

Eyeball and Contents of Orbit.—The eyeball is a globular mass which is lodged in the orbit, supported on a cushion of fat, and held in position by connective-tissue aponeuroses, ocular muscles, and the eyelids.

Normally the eyeball protrudes beyond the margin of the orbit. At the nasal side the projection is approximately 5 mm.; at the temporal side, 11 to 12 mm. The globe is covered by the eyelids. The mass of fat contained in the orbit is lobulated; it serves to fill all the space in the orbit not occupied by the eyeball and the structures to be described. Its extent anteriorly is limited by the septum orbitale; normally the orbital fat does not pass beyond the membranous aponeurosis which springs from the portion of Tenon's capsule at the equator of the globe, where Tenon's capsule is adherent to the recti muscles.

Fig. 11

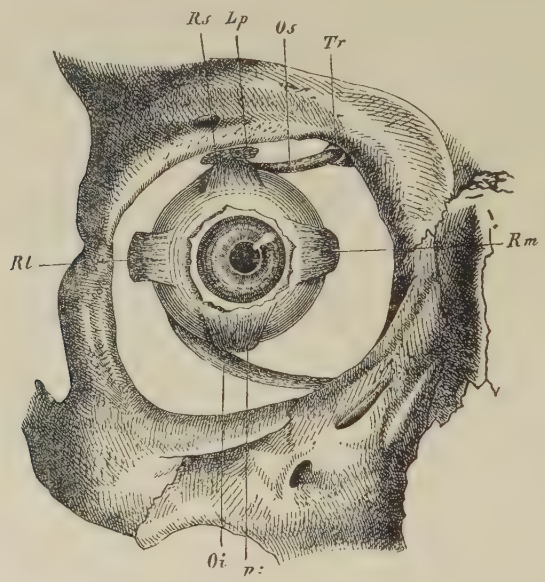

Position of eyeball in the orbit: *Rl*, external rectus; *Rs*, superior rectus; *Lp*, levator palpebræ; *Os*, *Tr*, superior oblique, with its pulley; *Rm*, internal rectus; *Oi*, inferior oblique; *Pi*, inferior rectus. (Merkel.)

The eyeball may be said to be formed of segments of two globes, one having a radius of curvature of 12 mm. (sclera), the other a radius of curvature of 7.8 mm. (cornea). The membranes of the eyeball are three in number: (1) Fibrous (outer); (2) vascular (middle); (3) nervous (inner). The fibrous membrane consists of two parts—the *cornea*, situated in the anterior portion of the globe, comprising about one-seventh of the area; the *sclera*, comprising the remaining portion of this membrane. The fibrous membrane is a stiff, highly resisting membrane; it serves to maintain the shape of the eye and to withstand the intraocular tension.

The middle tunic of the eyeball extends from the optic nerve entrance to within about 1 mm. of the sclerocorneal junction, lying immediately beneath the sclera. At the sclerocorneal junction it leaves the fibrous

coat, forming the *iris*, and hangs over the anterior surface of the lens, terminating in a free border enclosing a circular space, *the pupil.*

On account of the many vessels that it contains, the middle tunic of the eye is known as the vascular coat. Divested of the sclera and cornea, the pigmented vascular coat presents a bluish-black color and, to some extent, resembles a grape on the optic stalk. On account of this resemblance it has been termed the uvea (L. uva, grape) or *uveal tract.* The uveal tract is divided into three parts, which are anatomically well defined. The anterior portion is termed the iris, the middle portion the ciliary body, and the posterior portion the chorioid.

Fig. 12

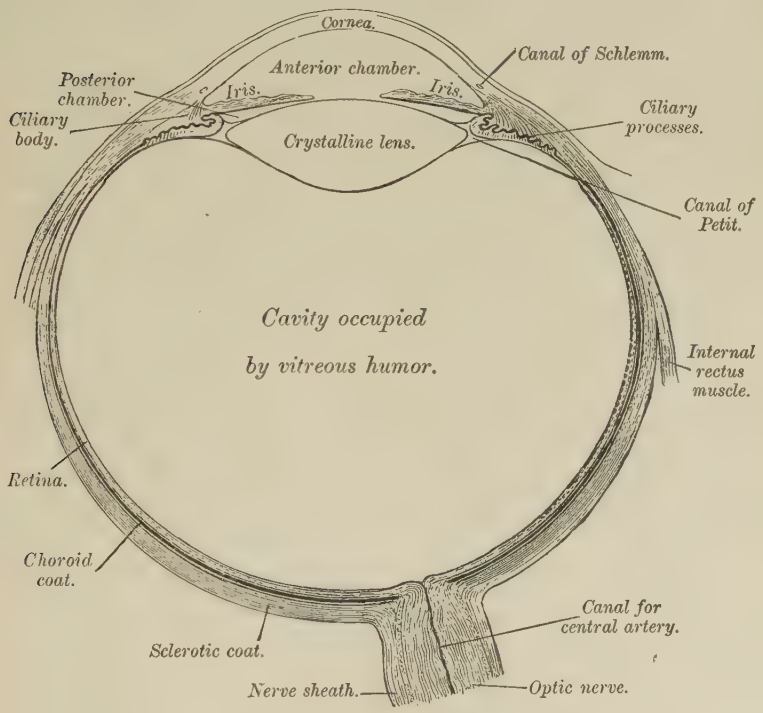

A horizontal section of the eyeball. (Allen.)

The nervous membrane, the *retina,* lines the inner surface of the vascular coat. The eyeball contains the crystalline lens, the suspensory ligament, and the aqueous and vitreous bodies. Its interior is divided into three chambers—the *anterior chamber,* that portion lying anterior to the iris; the *posterior chamber,* that portion lying in front of the crystalline lens and suspensory ligament and posterior to the iris; the *vitreous chamber,* that portion posterior to the crystalline lens and suspensory ligament. The eyeball has six muscles attached to it—the *extrinsic ocular muscles.* Posteriorly the optic nerve connects it with the brain.

The same geometrical terms that are employed in describing other globular bodies are employed in relation to the eyeball.

Tension of the Eyeball.—The fibrous coat of the eyeball is rendered tense by the secretion of fluid into its interior. This condition is known as the *normal intra-ocular pressure.* The secretion of the fluid takes place from the ciliary portion of the vascular membrane. Excess of fluid finds its escape from the eyeball by channels, the greater number of which are located in the anterior margin of the sclera. The normal intra-ocular pressure corresponds very closely to the normal blood pressure, varying only slightly in the same individual, but somewhat more in different individuals.

Tenon's Capsule (*Tunica Vaginalis Bulbi*).—The eyeball is surrounded posteriorly by a fibrous sheath, *Tenon's capsule,* which is separated by a space, *Tenon's lymph space,* into two layers. The visceral layer is closely attached to the sclera. The opposing surfaces of the visceral and the parietal layers of Tenon's capsule are lined with endothelium and sufficiently lubricated by serous fluid to permit of free movement of the eyeball. Tenon's capsule extends forward to about 2.5 mm. from the margin of the cornea; it is most dense at the equator of the globe, where it is pierced by the extrinsic muscles of the eye as they pass to their insertion into the sclera. Tenon's capsule is closely attached to each of the extrinsic ocular muscles about 1 cm. from their insertion, and is continuous with the sheaths of these muscles. By aponeurotic expansions the parietal layer of Tenon's capsule is intimately connected with the septum orbitale, and affords support to the globe.

Lymph Channels.—Either by transudation or by true secretion, the fluid which nourishes the vitreous humor, the lens, and, to some extent, the posterior layers of the cornea passes into the chambers of the eye from the inner surface of the ciliary body. If any of this fluid is derived from the iris, the quantity is extremely small. It is well known that in cases where the iris is entirely absent, the tension of the globe is maintained; also that disease of the ciliary body almost invariably leads to a lowering of the intra-ocular tension. This nutrient fluid, which, when it is present in the anterior or posterior chamber, is known as the aqueous humor, is constantly flowing into and out of the eyeball. The avenues which it traverses are termed lymph channels.

The experiments of Priestley Smith[1] and of Gifford[2] prove conclusively that the lymph channels are the posterior and anterior chambers; Fontana's spaces, which are in close relation to the various channels known as the canal of Schlemm; the perichorioidal space, which communicates to some extent with the anterior chamber by way of the interfibrillar spaces continuous with Fontana's spaces (Kessler); the space between the visceral and parietal layers of Tenon's capsule, Tenon's space, which connects with the perichorioidal space by way of the perivascular lymph sheaths of the vortex veins; perivascular lymph spaces in the optic nerve; the intervaginal lymph space, which at its bulbar end

[1] Glaucoma, 1891, p. 15.

[2] Arch. of Ophth., vol. xxi, p. 171.

PLATE III

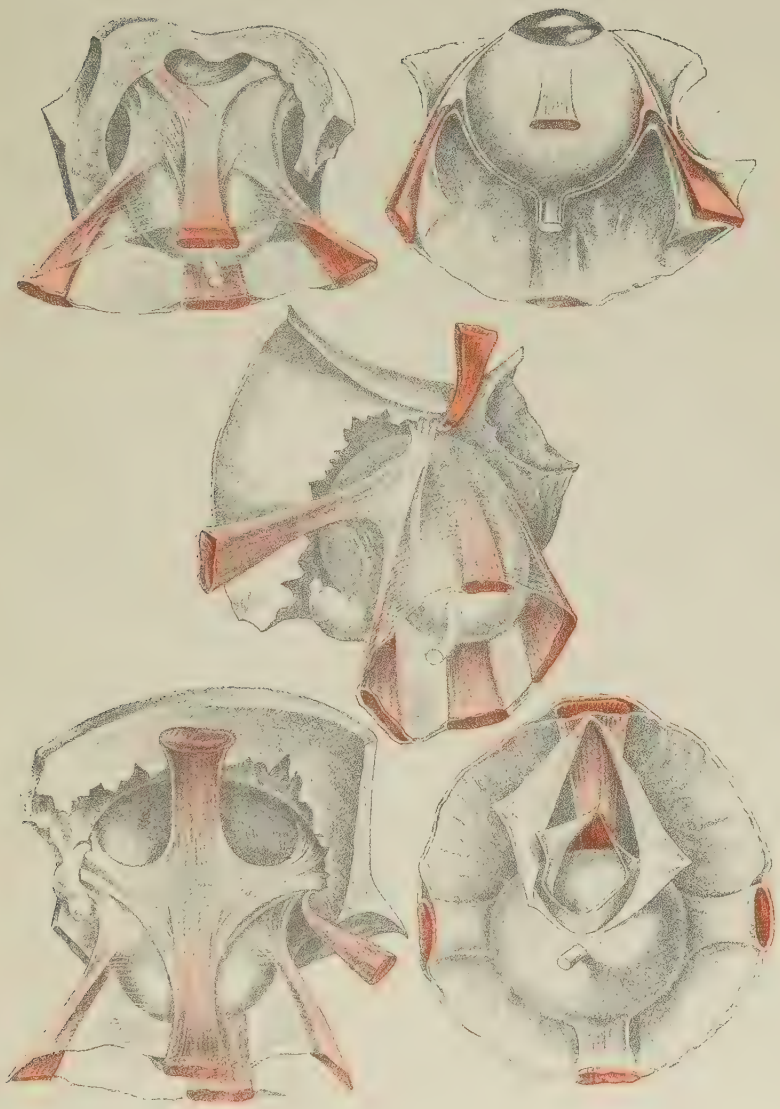

Capsule of Tenon. (Motais.)

may communicate to some extent with the perichorioidal space; and the supravaginal space, a continuation of Tenon's space. A central canal in the vitreous, corresponding with the site of the arteria hyaloidea, exists in some adult eyes, and may be considered a lymph space. The escape of fluids from the interior of the eye is chiefly by way of the anterior chamber and the iris angle, passing through the spaces of Fontana into Schlemm's canal and the veins communicating with it. The amount of fluid that passes through the optic nerve is extremely small.

According to Priestley Smith and Laplat,[1] the ratio of the quantity of fluid passing from the eye through the anterior chamber and the papilla is 50 to 1. It is possible that the iris takes up some of the intra-ocular fluid,[2] but the quantity is small. Obstruction to the passage

Fig. 13

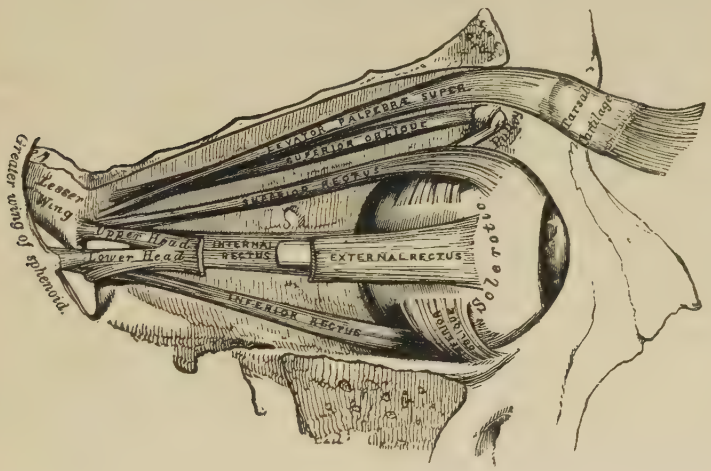

Extrinsic ocular muscles. (Gray.)

of fluid from the anterior chamber leads to increase in the intra-ocular pressure. The fibers of the suspensory ligament of the lens permit of the free passage of liquid from the vitreous to the posterior chamber. In removal of the aqueous the anterior chamber is refilled in large part by fluid which passes from the vitreous humor.

Extrinsic Ocular Muscles.—These are six in number—four recti muscles, the *internal, external, inferior,* and *superior;* and two oblique muscles, the *superior* (trochlearis) and the *inferior.* All of these muscles, except the inferior oblique, take their origin from bone or from strong aponeurotic connective tissue attachments *at the apex* of the orbit.

Internal Rectus.—This is the largest and strongest of the recti muscles; it is 41 mm. long, and weighs about 0.75 gram. It passes forward from

[1] Ann. d'Ocul., vol. ci, p. 123.

[2] Miel and Benoit, Arch. d'opht., vol. xx, 4, p 161.

the apex of the orbit, nearly parallel to the inner wall of the orbit, to the equator of the globe; it is inserted into the sclera 6.5 to 7 mm. from the margin of the cornea. The insertion is in a slightly curved line, convexity toward the cornea. The width of the tendon at the insertion averages 10.5 mm., extending equally above and below the horizontal meridian of the globe.

Fig. 14

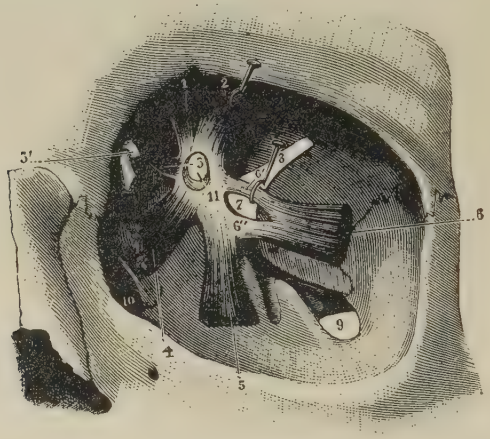

Origin of ocular muscles: 1, levator palpebræ superioris; 2, rectus superioris; 3, superior oblique; 3′, pulley; 4. rectus internus; 5, rectus inferioris; 6, rectus externus; 6′ and 6″, double insertion; 7, circle of Zinn; 8, sphenoidal fissure; 9, sphenomaxillary fissure; 10, nasal canal; 11, optic canal. (Testut.)

External Rectus.—This is the second longest of the recti muscles. Weight, about 0.7 gram; length, 40.6 mm. Arising from two heads, it extends forward to the equator of the globe; it is inserted into the sclera 7 to 7.5 mm. from the corneal margin in a curved line, convexity toward the cornea. The length of the insertion is 10 to 10.2 mm., about equally divided above and below the horizontal meridian of the globe.

Superior Rectus.—It is the weakest of the recti muscles, weight approximately 0.5 gram; length, 41.8 mm.; it takes its origin from the upper part of the circle of Zinn, passes through the tissues of the orbit at its upper part to the equator of the globe, and becomes inserted into the sclera in an irregularly curved line diagonal to the vertical plane of the globe. The inner end of the line of insertion is often not more than 6 to 6.5 mm. from the margin of the cornea, while the outer end may be 10 mm. from the margin of the cornea. About three-fifths of the width of the insertion is to the outer side of the vertical meridian of the globe. The sheath of the superior rectus is quite closely connected with that of the levator palpebræ superioris. The contraction of these two muscles is frequently associated.

Inferior Rectus Muscle.—This weighs about 0.66 gram, and is 40 mm. long; it extends from its point of origin at the apex of the orbit to the lower portion of the circle of Zinn, along the lower part of the orbit, passes between the inferior oblique and the globe, and is inserted into

the sclera about 7 mm. from the margin of the cornea. The nasal extremity of the line of insertion is slightly nearer to the cornea than the temporal, the insertion being diagonal to the vertical plane of the globe, but not to the same extent as obtains in the insertion of the superior rectus; about three-fifths of the insertion is to the *nasal* side of the vertical meridian.

All of the tendons of the recti muscles have delicate lateral connective tissue attachments (alæ) and still more delicate ventral attachments, apparently derived from Tenon's capsule.

Superior Oblique Muscle (*Trochlearis*).—This muscle takes its origin from the circle of Zinn between the heads of the superior and internal recti muscles, extends forward near the roof of the orbit to the trochlear spine, becoming tendinous before it reaches this point, where it passes through a strong connective-tissue loop (the *trochlea* or *pulley*), which is attached to the trochlear spine and is supplied with a synovial membrane; the muscle then passes backward and outward between the superior rectus and globe at an angle of 50 degrees with the first part of the muscle, and is inserted into the sclera, back of the equator, in the posterior superior quadrant of the globe. The insertion is oblique, irregularly curved, its convexity outward. The posterior end of the insertion usually reaches the vertical meridian of the globe. The length of the line of insertion is approximately 7.5 mm. Its anterior extremity is from 1 to 4 mm. posterior to the external extremity of the insertion of the tendon of the superior rectus.

Fig. 15

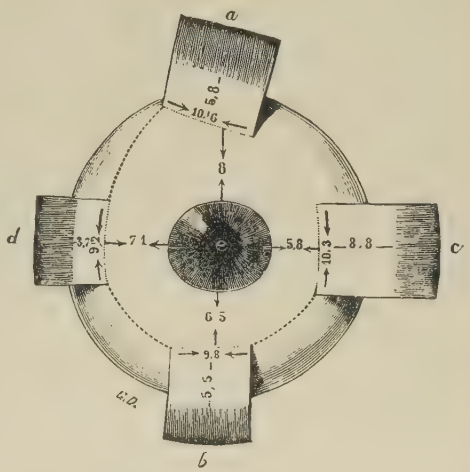

Insertion of recti muscles of right eye: *a*, superior rectus; *b*, inferior rectus; *c*, internal rectus; *d*, external rectus. The figures represent millimeters. (Testut.)

Inferior Oblique.—This muscle has its origin from the orbital plate of the superior maxilla at the lower inner angle of the orbit just within the margin of the orbit; its course is backward and outward, passing between the floor of the orbit and the inferior rectus muscle, between the globe and the external rectus muscle, to its insertion back of the equator of the globe. The line of insertion is about 10.5 mm. in length, is slightly curved, the convexity upward.

The anterior extremity of the line of insertion is approximately 16 mm. from the margin of the cornea, and 3 mm. below the horizontal meridian; it extends upward and backward at an approximate angle of 20 degrees with the horizontal meridian of the globe.

Vascular Supply.—*Arteries.*—The arteries are derived from the *ophthalmic artery,* a branch of the internal carotid, which enters the orbit through the optic foramen to the outer side and slightly below the horizontal plane of the optic nerve; it then curves over (sometimes under) the optic nerve and passes to the inner wall of the orbit, dividing into two principal branches—the *nasal* and *frontal* arteries. As the artery curves to cross the optic nerve it gives off a number of branches—the *lachrymal,* which passes to the lachrymal gland, *retinal* and *ciliary* arteries, *nutrient* branches to the tissues of the orbit, and *muscular* branches to the levator palpebræ superioris muscle and to the six extrinsic muscles of the eye. The arteries enter the muscles on the ventral surface and near their places of origin. A partial arterial supply is derived from the infra-orbital artery, a branch of the internal maxillary, which passes through the infra-orbital canal. Branches are given off from this vessel which pass to the inferior oblique and internal rectus muscles.

Veins.—There are two principal venous trunks in the orbit—the *superior* and *inferior* ophthalmic veins. The superior is the larger; it collects blood from all the tissues of the upper part of the orbit. It anastomoses freely with the frontal and nasal veins at the upper inner angle of the eye. The inferior ophthalmic vein anastomoses with the veins of the face, lids, and nose. The venous anastomosis within the orbit is free, collecting blood from the lachrymal gland, eyeball and other tissues of the orbit. The two principal venous trunks pass out of the orbit by way of the sphenoidal fissure, between the heads of the external rectus muscle, and enter the cavernous veins. Not infrequently they unite just before leaving the orbit. A free anastomosis takes place between the veins of the orbit and those of the maxillary fossa, connecting with the external jugular vein.

Nerve Supply.—The muscles of the orbit, with the exception of Müller's muscle (see Lids, p. 47), are innervated by three cranial nerves; the *third,* or motor oculi, the *fourth,* or trochlearis, and the *sixth,* or abducens. The third nerve supplies the superior, internal, and inferior recti, the inferior oblique and the levator palpebræ superioris muscles; the fourth nerve supplies the superior oblique, the sixth nerve the external rectus muscle.

Third Nerve.—This nerve takes its origin from a collection of ganglion nerve cells in the tissue in the floor of the third ventricle. The nucleus of the nerve extends from a point corresponding to the anterior border of the posterior commissure into the floor of the aqueduct of Sylvius, and is about 1 cm. long. The nucleus is made up of a number of groups of cells, from which nerve fibers supplying the various muscles proceed. The destination of the fibers arising from the various groups has been quite satisfactorily determined by experimentation and by clinical observation, with subsequent histological examination. Perlia has plotted the several groups of the nucleus of the third, as in Fig. 16. It is now generally conceded that a crossing of nerve fibers between the individual groups of cells in the nucleus, particularly those innervating the sphincter of the iris and those in which symmetrical action

PLATE IV

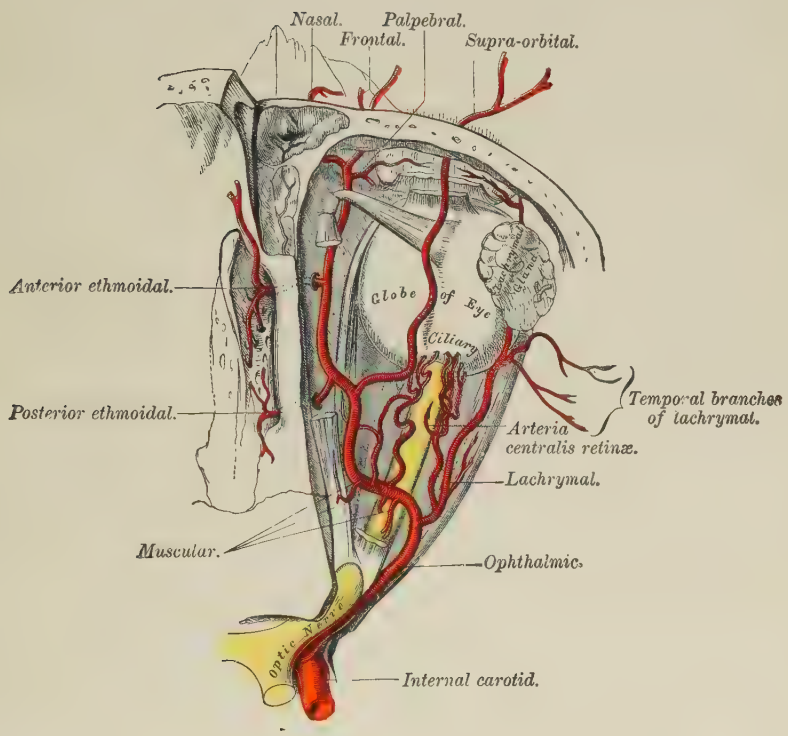

The Ophthalmic Artery and its Branches, the Roof of the Orbit having been Removed. (Gray.)

of the eye muscles is required, takes place. The nerve fibers in small bundles pass through the tegmentum of the cerebral peduncle, converging, to emerge in eight to twelve separate bundles close together at the inner lower margin of the peduncle (between the crura cerebri). The separate bundles unite to form a single cord at a distance of 3 to 5 mm. from the point of emergence. The nerve trunk passes forward and outward between the superior cerebellar and the posterior cerebral arteries, piercing the dura mater at the posterior end of the cavernous

Fig. 16

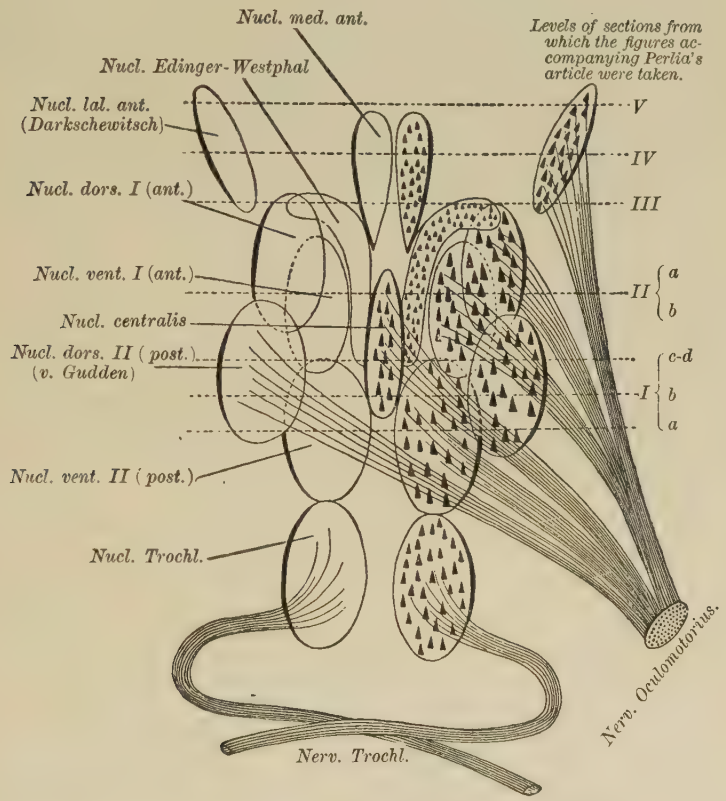

Scheme of the nuclei of the oculomotor nerve. (After Perlia, Arch. f. Ophth., Leipzig, Bd. xxv., Abth. iv., S. 297.)

sinus, passing along its outer wall just above and to the inner side of the sixth nerve, close to the wall of the internal carotid; it is virtually encased in a sheath of dura mater. It enters the orbit through the sphenoidal fissure, near its inner angle, through an opening in the dense aponeurosis. This opening has been termed the *foramen oculomotorii.*

In the cavernous sinus the third nerve anastomoses with the sympathetic and with the supra-orbital branch of the fifth. Soon after entering the orbit the nerve divides into branches, which are distributed to the levator palpebræ superioris, entering on the under surface. To

the superior, internal, and inferior recti, entering on their inner or ventrical surfaces, and to the inferior oblique by a branch which runs along the outer margin of the inferior rectus muscle and enters the inferior oblique on its upper surface. A branch of the third nerve passes to the ciliary ganglion, being given off from the branch to the inferior oblique.

Fourth Nerve (*Trochlearis*).—A group of ganglion cells which forms the principal part of the nucleus of this nerve (the anterior trochlear nucleus) is found in the floor of the aqueduct of Sylvius, appearing as an extension of the nucleus of the third nerve and continuous with it. A second smaller group of cells, the posterior trochlear nucleus, lies somewhat farther back, in close relation with the posterior longitudinal fasciculus on its upper aspect. The nerve fibers pass downward and

Fig. 17

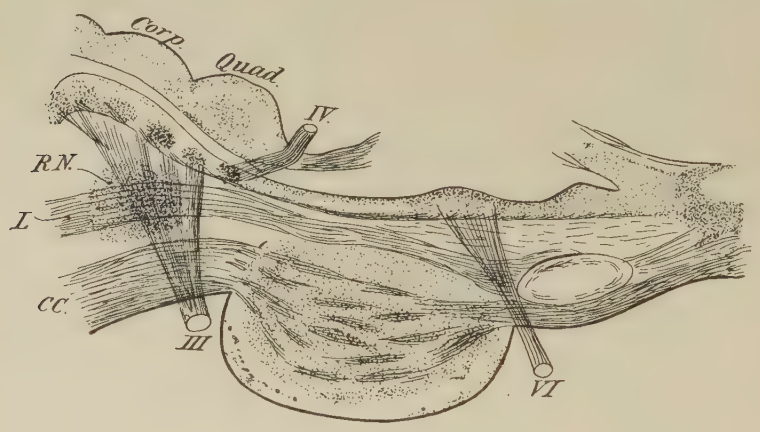

Sagittal section through the cerebral axis, to show the nuclei of the ocular nerves in the floor of the aqueduct of Sylvius and the fourth ventricle, and the course of the nerves to their exit. The various groups of cells from which the third nerve arises are seen. *RN*, red nucleus of tegmentum; *L*, lemniscus (sensory tract); *CC*, motor tract in the crus cerebri seen to traverse the pons and enter the anterior pyramid of the medulla. (Starr.)

backward from the two divisions of the nucleus and curve over the aqueduct, decussating in the anterior medullary velum. They then pursue a downward and outward course and emerge from the brain at the outer side of the crura cerebri, close to the upper margin of the pons. The nerve passes forward, crossing the crura cerebri, passing between the posterior cerebral and superior cerebellar arteries, over the internal carotid, piercing the dura at the base of the tentorium cerebelli laterally and on a level with the lower border of the third nerve. Entering the cavernous sinus, it passes along the outer wall, lying close to the outer side of the internal carotid artery, entering the orbit through the sphenoidal fissure slightly above and to the temporal side of the third nerve. In its passage along the wall of the cavernous sinus it is enveloped in a duplicature of the dura mater. After

PLATE V

FIG. 1

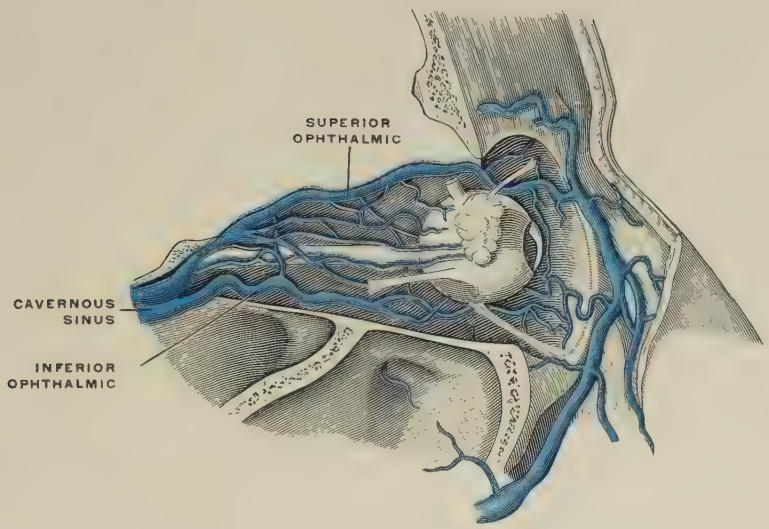

Veins of the Orbit. (Poirier and Charpy.)

FIG. 2

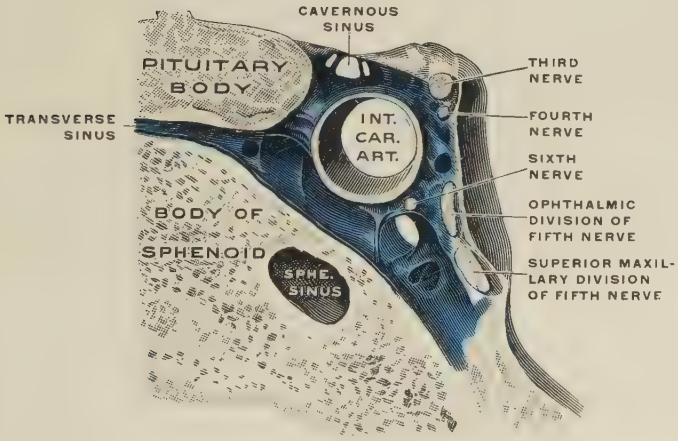

Frontal Section through the Right Cavernous Sinus. (Spalteholz.)

entering the orbit, it passes above the optic nerve and enters the superior oblique muscle from above.

Sixth Nerve (Abducens).—The nucleus of this nerve is located in the tissue of the floor of the fourth ventricle, near the median line, lying under the "knee" of the fibers of the seventh nerve, formed as they pass from the nucleus to the point of exit from the brain. The nucleus of the sixth nerve is well defined and is almost spherical; the fibers pass slightly spinalward and emerge at the lower margin of the pons, near the median line. It is generally believed that a small number of fibers pass to the nucleus of the opposite side. The nucleus of the abducens is believed to be in connection with the acoustic nerve through the superior olive, from which it receives fibers. It is also in connection with the nuclear centre for the internal rectus muscle of the opposite side by means of the posterior longitudinal fasciculus. After emerging from the brain the nerve passes forward across the pons, pierces the dura mater, and enters the cavernous sinus at the outer lower angle. It passes along the outer wall of the sinus, separated from the internal carotid artery by a thin septum of connective tissue, and enters the orbit through the sphenoidal fissure a little to the outer side and slightly below the entrance of the other nerves. It then passes between the heads of the external rectus and enters the muscle on its ventral surface. During its course through the cavernous sinus, the sixth nerve receives a filament from the carotid plexus of the sympathetic and a small branch from the ophthalmic branch of the fifth nerve. On account of its long extracerebral course, the sixth nerve is very liable to become involved in disease processes affecting the base of the brain.

Fifth or Trigeminal Nerve.—We have chiefly to do with the sensory portion of the fifth, although in certain associated movements of the muscles of mastication and the muscles of the eye, especially the levator palpebræ superioris, the motor portion of the fifth is involved. The sensory nucleus of the fifth nerve is quite widely distributed. It lies beneath the floor of the fourth ventricle, below and lateral to the nuclei of the third, fourth, and sixth nerves, and lateral to the motor portion of the nucleus of the fifth. According to Spiller,[1] the sensory fibers arise in the Gasserian ganglion, and after entering the pons, terminate only partially in the sensory nucleus, the larger number of them bending downward at the level of the sensory nucleus, to form the descending or spinal root, which may be traced as far as the second cervical segment of the spinal cord. Within the spinal cord it occupies a position behind the posterior horn. The motor nucleus is well defined; it lies slightly in advance of the nucleus of the sixth nerve, between it and the middle portion of the sensory nucleus of the fifth. The motor root of the fifth remains distinct until it joins the third division of the trigeminus at the distal end of the Gasserian ganglion. The trunk of the fifth nerve pierces the pons about midway on its lateral aspect. From the Gasserian ganglion, which lies

[1] Posey and Spiller, p. 16.

on the apex of the petrous portion of the temporal bone, the three branches of the fifth nerve proceed. The superior or ophthalmic branch passes into the orbit through the sphenoidal fissure; it divides, on or before entering the orbit, into three branches—the *supra-orbital, lachrymal,* and *nasociliary.* The supra-orbital nerve gives off the *supratrochlear* and the *frontal* branches as it passes through the orbit just under the orbital roof. The lachrymal branch passes directly to the lachrymal gland, from which it sends branches to the conjunctiva and skin of the lid. The nasociliary nerve gives off the *long root* (sensory) to the ciliary ganglion, one to three long *ciliary* nerves[1] to the globe, the *ethmoidal* nerve and the *infratrochlearis* (Fig. 22).

The Ciliary Ganglion (Ophthalmic Ganglion, Lenticular Ganglion).—This is a flat, irregularly quadrilateral mass measuring about 2 mm. long by 0.75 mm. thick, located between the optic nerve and the external rectus muscle at about the junction of the posterior third with the anterior two-thirds of the orbital portion of the optic nerve, separated from the optic nerve by a thin layer of fat. The ganglion has a smooth surface, is pink in color, and is firm in consistence.

It receives branches from the fifth nerve, radix longa (sensory), from the plexus of the internal carotid (sympathetic), and from the third nerve, radix brevis (motor). The conclusion reached by various investigators[2] is that the ciliary ganglion is more closely related to the sympathetic than to the cerebrospinal nervous system. It is a ganglion cell "station" where the axis cylinders from the three nerve roots are interrupted, and new axis cylinders from the ganglion cells there located proceed by way of the ciliary nerves to the eyeball. The ciliary ganglion gives off from its anterior end three to six nerve bundles, *short ciliary nerves,* which subdivide into twelve to eighteen bundles, proceed to the posterior part of the globe, and, in company with the *long* ciliary nerves, pierce the sclera around the optic nerve diagonally and pass to the outer layer of the chorioid. A few nerve fibers have been traced to the optic nerve sheath from the inner surface of the ganglion, and a very few fibers pass to the fatty tissue of the orbit. The bundles of nerve fibers pass forward in the external layer of the chorioid, supply the chorioid, ciliary body, and iris. (See Plate VI.)

Eyelids.—The eyelids are membranous structures which serve to protect the eye from injury, to shut out light when required, and to prevent desiccation of the eye. They also serve to distribute evenly the fluids that are poured into the pouches (conjunctival sacs) between the eyelids and eyeball, and to aid in carrying away excessive fluid by wafting it toward the lachrymal passages.

The eyelids are limited above by the brow. Below they pass imperceptibly into the tissues of the cheek. They are separated from each other in man by the *palpebral fissure,* which, in the adult, is 28 to 30 mm. in length, but varies largely in width, measuring, when the eye is ordi-

[1] These nerves contain sympathetic fibers principally, and pass to the iris, innervating the dilatator pupillæ.

[2] See Wilbrand and Saenger, vol. ii, p. 47.

PLATE VI

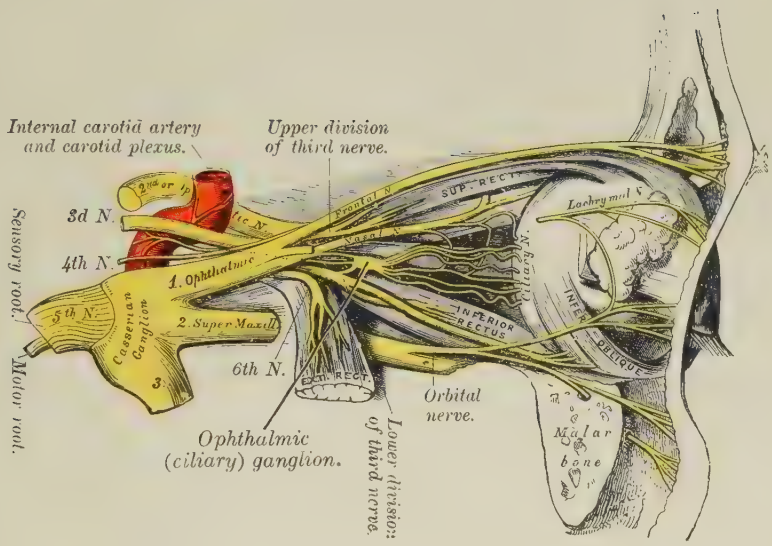

Nerves of the Orbit and Ophthalmic Ganglion, side view. (Gray.)

narily wide open, from 8 to 14 mm; it frequently varies in width in the two eyes. Temporally the lids approach each other at a sharp angle, forming the *external canthus*. When the lids are separated, a delicate, thin membrane stretches across this angle, forming the *external commissure*. At the inner angle of the lids, *internal canthus*, the palpebral fissure is horseshoe in shape, the ends of the shoe corresponding to the puncta lachrymalia.

Puncta Lachrymalia.—The *puncta lachrymalia* are situated about five millimeters from the mesial end of the palpebral fissure. The area included between a line uniting the puncta, and the mesial end of the palpebral fissure is termed the *tear lake* (*lacus lachrymalis*). It contains a fleshy mass, the *caruncle*.

Integument.—The *integument* of the eyelids is very thin. It is loosely attached to the deeper structures by areolar connective tissue, which

Fig. 19

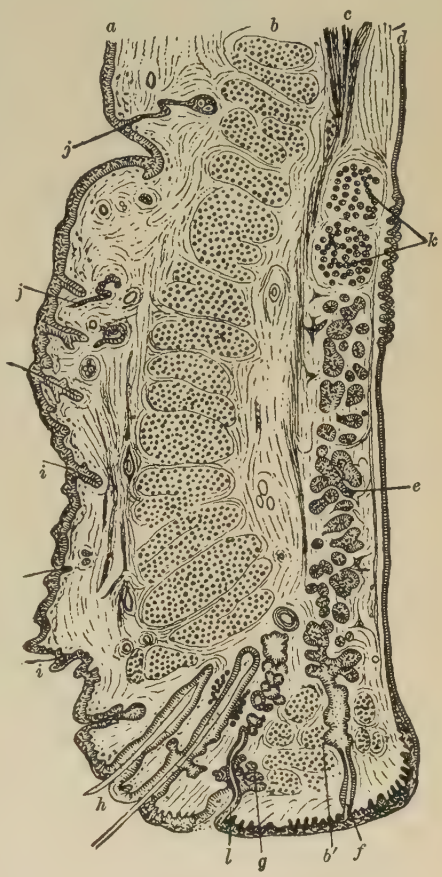

Vertical section through the upper eyelid: *a*, skin; *b*, orbicularis palpebrarum; *b′*, marginal fasciculus of orbicularis (ciliary bundle or muscle of Riolani); *c*, levator palpebræ; *d*, conjunctiva; *e*, tarsal plate; *f*, Meibomian gland; *g*, sebaceous gland; *h*, eyelashes; *i*, small hairs of skin; *j*, sweat glands; *k*, posterior tarsal glands (Krause's glands); *l*, gland of Moll. (After Waldeyer.)

Fig. 18

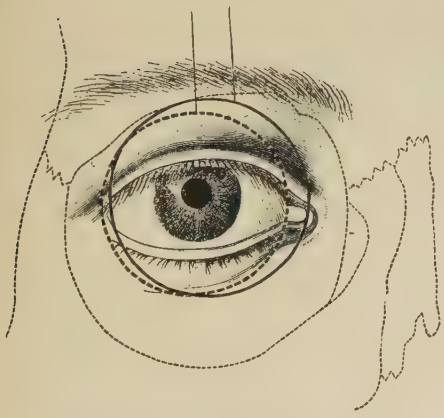

The relation of the eyelids to the eyeball, conjunctiva, and orbit. (Graefe and Saemisch.)

permits it to move readily over the underlying tissue. It is firmly attached to the margins of the lids, and is only slightly movable where it passes on to the nose. On opening the eye the skin of the lids is thrown into folds above, particularly in adults and in the aged. A fold that is almost constant is one that corresponds closely to the upper margin of the tarsus of the upper lid.

Surface.—The *surface* of the lids is sparsely studded with minute hairs (lanugo). Some sweat glands and sebaceous glands attached to the hair follicles are present. The epithelium of the lid is stratified and resembles that of the skin in other parts of the body. Much adipose tissue is found in the lids of infants, but it soon disappears, little being present after the age of three years.

Margins.—The margins of the eyelids are about two millimeters in width. They present an outer and an inner angle.

The *outer angle* is rounded and bears the *eyelashes* or *cilia.* These are stout hairs—120 to 150 in number in the upper lid, and 70 to 80 in number in the lower lid. They measure 7 to 12 mm. in length, being longer and thicker above than below, are medullated and pigmented, the color usually corresponding to the color of the brows. The *follicles* of the cilia are 1½ to 2 mm. in length, extending diagonally into the substance of the lids, often slightly embedded in the tarsus. They are supplied with the usual sebaceous glands (Zeiss glands), and are arranged irregularly in two or three rows. The life of an eyelash is about four months, the old ones dropping out and their places being supplied by slender new ones. The *inner angle* of the lid is quite acute. The integument, which has assumed a delicate pink color on the margin of the lid, here passes over into mucous membrane. The space between the outer and inner angle of the lids is termed the *intermarginal* space. Near the inner angle of the lid, arranged in an even row, are the openings of the ducts of the *Meibomian glands.* Between the openings of these ducts and the cilia are the openings of the ducts of the *glands of Moll.* These are modified sweat glands, and are not so numerous as the Meibomian glands. They extend deep into the tissue of the lids, reaching almost to the base of the hair follicles.

Muscles.—*Orbicularis Palpebrarum Muscle* (Sphincter of the Eyelids).—This is a thin circular plate of striated muscle fibers, lying almost directly beneath the skin, and extending from the margin of the lids well over the margin of the orbit. It is divided into *palpebral, orbital,* and *malar portions.* The palpebral portion arises from a fibrous band, which is attached to the frontal process of the superior maxilla at the margin of the orbit. The muscle fibers spread out in a thin layer arching over the tarsal plates. Reaching the outer portion of the lids, they are inserted into a band of connective tissue, the *external palpebral ligament* (*raphæ palp. lateralis*), which extends from the external canthus to the periosteum a little beyond the margin of the orbit, and slightly below the external canthus—a portion of the external canthal ligament. The fibers of the orbital portion arise, some from the inner canthal ligament, some from the contiguous margin of the orbit above and below. These fibers arch more than the inner fibers. Some are inserted in the raphé at the outer angle of the lids. A few of the outer bundles describe a complete circle; some of the outer bundles above are lost in the tissues of the brow. A few fasciculi below, internally and externally, pass to the tissues of the cheek, forming the *malar division* of the orbicularis palpebrarum muscle.

Muscle of Riolani.—This is a well-pronounced bundle of muscle fibers which passes between the hair bulbs at the margin of the lids.

Tensor Tarsi Muscle (Horner's Muscle).—A band of fibers arises from the lachrymal bone just back of the lachrymal sac, some of the fibers being attached to the inner ends of the tarsi, some encircling the tear ducts, and some mingling with the more superficial fibers. This fasciculus is the *tensor tarsi* muscle (*Horner's* muscle); it is a deep head of the orbicularis palpebrarum muscle. This fasciculus serves to draw the lids inward and to slightly compress the lachrymal sac and canaliculi. It is called into action to a slight degree in connection with the palpebral portion of the orbicularis palpebrarum, in gentle movements of the lids, as in winking. In forcible closure of the lids all of the fibers of the orbicularis palpebrarum participate.

Fig. 20

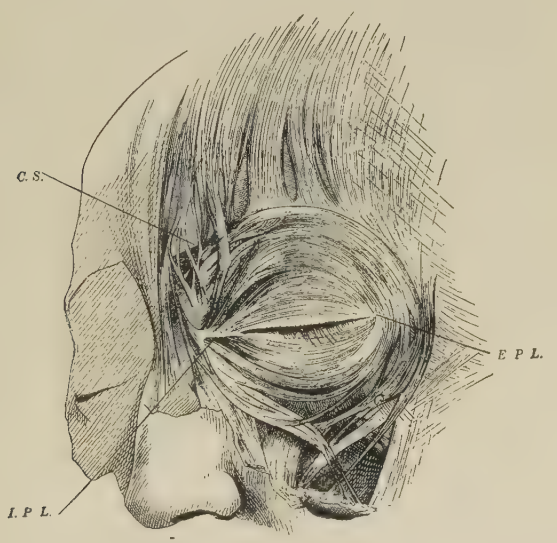

Orbicularis palpebrarum. The palpebral and orbital portions are easily recognized, though the line of separation is not always to be seen: *C. S.*, points to the corrugator supercilii; *I. P. L.*, internal palpebral ligament; *E. P. L.*, position of external palpebral ligament. (After Henle.)

Corrugator Supercilii.—A small muscle known as the corrugator supercilii arises from the superciliary ridge near the median line. Its fibers run between those of the frontalis and orbicularis, and are inserted into the skin near the middle of the upper margin of the orbit. The contraction of this muscle serves to throw the skin of the brow into vertical folds, and is called into action in the act of frowning. These muscles are innervated by the facial nerves.

Tarsal Plates.—Lying beneath the orbicularis palpebrarum muscle are the tarsal plates, which measure about 20 mm. in length. The upper plate measures 9 mm. in width and 0.8 to 1 mm. in thickness; the lower plate is 4 mm. wide and 0.8 mm. thick. They are plates of dense connective tissue. The *tarsal plates* are the skeleton of the lids.

They are convex on their posterior surface, corresponding to the curvature of the eyeball. They impart rigidity and maintain the shape of the lids. The posterior surface of the lids is covered by mucous membrane, the *conjunctiva.*

Meibomian Glands.—These number thirty to forty in the upper, and twenty to thirty in the lower lid, and are located in the substance of the tarsal plates. They are simple acinous glands, being composed of numerous minute lobules arranged along a common duct. Beginning at the opening of the duct on the margin of the lid, the gland extends in nearly a straight line to within a short distance of the attached margin of the tarsus. The lobules do not approach the margin of the lids nearer than the ends of the bulbs of the eyelashes. They are sebaceous glands, supplying the oily substance necessary to lubricate the margin of the lids.

Fig. 21

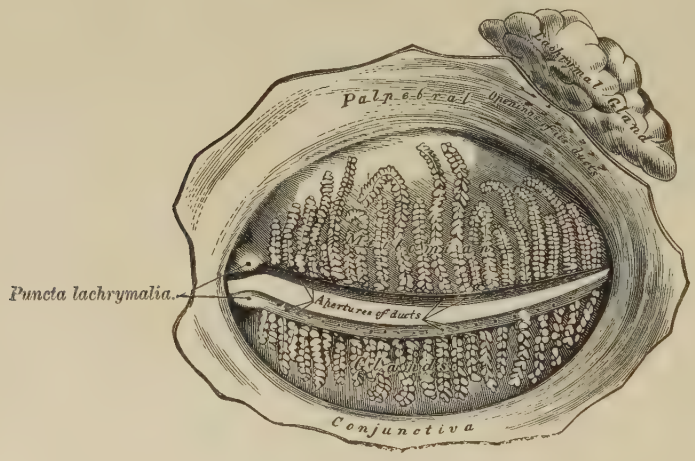

The Meibomian glands, etc., seen from the inner surface of the eyelids. (Gray.)

When the lids are closed the sebum serves to render them water tight, so that the tears are confined to the conjunctival sacs. The presence of an oily substance on the margin of the lids prevents maceration from the tears.

Krause's Glands.—Near the attached margin of the tarsus, embedded in the tarsal plates, a number of acinous or acinotubular glands (Krause's glands, Fig. 19), which excrete a fluid resembling the lachrymal fluid, are found. They discharge into the conjunctival sac from the tarsal surface.

Septum Orbitale.—Beneath the orbicularis palpebrarum muscle and attached to the curved margin of the tarsal plates is a firm, thin, loosely placed aponeurosis, which is attached to the margin of the orbit throughout its entire extent. The attachment is flush with the surface of the cranium, except at the inner margin of the orbit, where it encroaches on the orbital wall, passing along the crista lachrymalis in intimate connection with the posterior root of the internal canthal ligament. At

PLATE VII

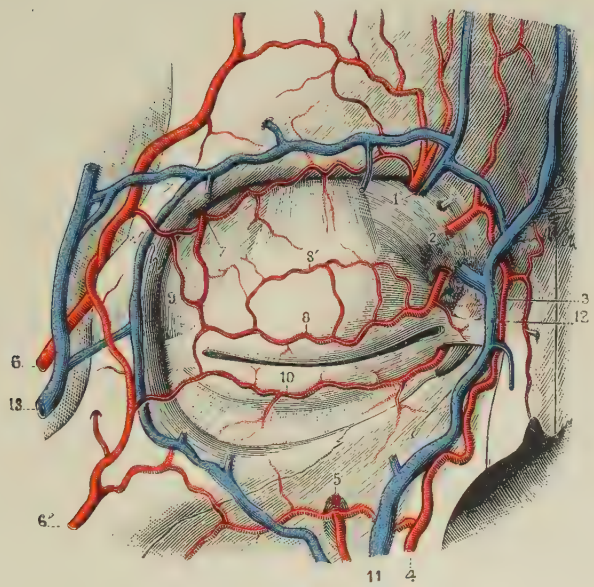

Bloodvessels of the Eyelids, front view.

1. Suborbital artery and vein. 2. Nasal artery. 3. Angular artery, the terminal branch of 4, the facial artery. 5. Suborbital artery. 6. Anterior branch of the superficial temporal artery. 6′. Malar branch of the transverse artery of the face. 7. Lachrymal artery. 8. Superior palpebral artery, with 8′, its external arch. 9. Anastomoses of the superior palpebral with the superficial temporal and lachrymal. 10. Inferior palpebral artery. 11. Facial vein. 12. Angular vein. 13. Branch of the superficial temporal vein. (Testut.)

the outer margin of the orbit it is continuous with the outer canthal ligament; in fact, these structures appear as thickened bands of the aponeurosis. It is also connected with the fibrous structure in the orbit, a part of which is known as *Tenon's capsule.* By means of this aponeurosis the tissues of the lids proper and the tissues that fill the orbits are separated one from the other so that hemorrhages, effusions, and, in many cases, newgrowths that occur in the tissues on one side do not invade the tissues on the other side—a fact that is of much clincial importance. This aponeurosis is known as the *septum orbitale,* also as *fascia tarsoörbitalis.* Three principal openings exist in this septum, two at the upper margin of the orbit for the passage of the supra-orbital nerve and artery, and one at the superior inner margin of the orbit for the passage of the branch of the ophthalmic vein, which unites with the vena angularis.

Levator Palpebræ Superioris.—The palpebral fissure is widened principally by elevation of the upper lid by contraction of the *levator palpebræ superioris* muscle, although a relaxation of the fibers of the orbicularis palpebrarum permits the margin of the lower lid to drop a very little. The levator palpebræ superioris muscle has its origin at the apex of the orbit from the sphenoid bone, just above and to the median side of the optic foramen (Figs. 13 and 14), by a thin tendinous band. The muscle extends forward just below the roof of the orbit, expands into a flattened belly of striated muscle fibers, and terminates in a broad, thin, tendon, which is inserted into the upper margin of the upper tarsal plate. Anterior fibers of the tendon extend between the fibers of the orbicularis palpebrarum and are inserted into the integument of the lid on a line closely corresponding to the upper border of the tarsus. The striated muscle fibers terminate as the muscle passes the orbital wall, where it is surrounded by a delicate supporting structure of connective tissue. The muscle is innervated by the third (motor oculi) nerve.

Müller's Muscle.—Closely associated with the connective-tissue fibers of the tendon of the levator palpebræ superioris are numerous non-striated muscle fibers, which lie just beneath the tendon, pass backward, and are lost in the tissues of the orbit. A corresponding band of fibers, but much smaller, which bear the same name, is found in the lower lid also. The upper muscle is sometimes influenced by pathological conditions producing retraction of the upper lid, which is of much diagnostic importance (see Graves' disease). The position of the lower lid is influenced to some extent by fibers from the sheath of the inferior rectus muscle, which extend forward and are inserted into the tarsus of the lower lid.

Vascular Supply.—*Arteries.*—The arterial blood supply to the lids is derived from the *ophthalmic, infra-orbital, angular, transverse,* and *anterior temporal* arteries. The ophthalmic artery gives rise to the *supra-orbital,* the *palpebral,* and the *lachrymal* arteries. The supra-orbital sends a branch to the inner canthus, which supplies the tissues in this vicinity. The palpebral arteries (two in number) arise from the ophthalmic in a single trunk. The superior palpebral artery emerges

from the orbit above the inner canthal ligament, and passes along the upper margin of the tarsus, anastomosing with the lachrymal and the orbital branch of the temporal, forming the *upper tarsal arch.* The inferior palpebral branch emerges from the orbit below the inner canthal ligament, and passes along the lower margin of the tarsus, forming the *lower tarsal arch.* This vessel anastomoses with the lachrymal and malar branch of the transverse facial artery at the outer angle of the lids. A secondary arch, usually quite well marked in the upper lid, is formed by a branch given off from the superior palpebral artery. It passes along the upper margin of the tarsus between the lamellæ of the tendon of the levator palpebræ superioris muscle. Numerous anastomoses occur between the vessels which form the arches and

Fig. 22

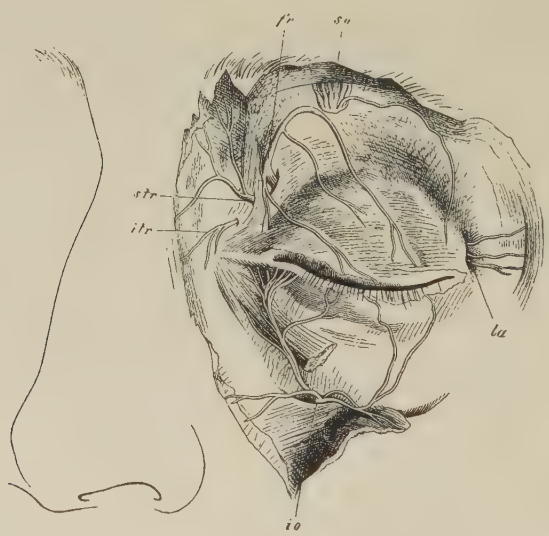

Nerves of eyelids: *str* and *itr*, branches from the superior and inferior trochlear nerves; *fr*, branches from the frontal nerve; *so*, supra-orbital; *la*, lachrymal; *io*, infra-orbital. (Merkel.)

branches from the anterior temporal, supra-orbital, and angular arteries above and the infra-orbital and transverse facial below. Small twigs supply the integument and orbicularis palpebrarum muscle. So-called perforating arteries pass into the tarsi, supplying the tissue of the tarsi and the Meibomian glands, reaching as far as the tarsal conjunctiva. From the infrapalpebral artery a branch passes to the nasal duct.

Veins.—The veins do not follow the arteries, but are larger and form a rich network, particularly above and below the tarsi. Much of the venous blood flows into the veins of the face, but a portion flows into the ophthalmic vein. The veins tributary to the ophthalmic must pass between the fibers of the orbicularis palpebrarum muscle, and, on forcible contraction of that muscle, may become engorged. This occurs

in patients who are the subjects of tonic or clonic blepharospasm, venous congestion and edema being produced.

Lymphatics.—The lymphatics of the eyelids are numerous. They form a network above and in the tarsi. About the acini of the Meibomian glands rather large lymph spaces may be found. The lymphatics of the lid are continuous with lymph channels which pass to the preauricular and submaxillary lymph glands.

Nerve Supply.—The sensory nerve supply to the upper lid is derived from the *supra-orbital* and the *frontal branches* of the first division of the trifacial. They anastomose freely and form the *superior marginal plexus,* which is disposed along the margin of the upper lid. A similar plexus, the *inferior marginal plexus,* is formed by branches from the infra-orbital branch of the trifacial. The supratrochlear and infratrochlear branch of the trifacial supply accessory twigs, which are distributed to the integument at the inner angle of the lids. The lachrymal branch of the trifacial becomes subcutaneous to the outer side and above the outer canthus. It sends a few branches to the lids, but is chiefly distributed to the integument at the temporal side of the orbit.

Conjunctiva.—The conjunctiva is a delicate mucous membrane which covers the posterior surface of the eyelids and is reflected onto the anterior half of the eyeball. At the margin of the lids the conjunctiva joins the integument; it does not pass beyond either canthus. Where the conjunctiva covers the tarsal plates it is closely adherent to these plates. Beyond the tarsi the membrane is attached, subconjunctivally, to areolar connective tissue to within a few millimeters of the margin of the cornea, which renders the conjunctiva freely movable over the underlying tissue. At the inner canthus the conjunctiva extends over the fleshy glandular mass known as the caruncle.

The conjunctiva is thrown into a crescentic fold—*plica semilunaris,* just beneath and to the temporal side of the caruncle. This fold is drawn outward on movements of the cornea toward the temporal side. By its reflection from the lids to the eyeball the conjunctiva forms pouches above and below—the *conjunctival sacs* (culs-de-sac). These vary in depth at different distances from the canthi and in different individuals. The depth of the upper sac at the middle of the lids is approximately 18 mm.; of the lower sac, 8 mm.

Divisions.—The conjunctiva is divided into various parts, as follows: Palpebral, that covering the posterior portion of the lids; fornix, the transition fold; ocular, that covering the globe.

The part of the palpebral portion that covers the tarsus is known as tarsal conjunctiva. The surface of the conjunctiva is smooth near the margin of the lid, but at the orbital margins of the tarsi there are numerous minute papillæ. (These papillæ form an ill-defined zone.) The fornix is composed of a number of folds of conjunctiva, the surface of which is uneven and presents a number of small, shallow depressions, which have been termed follicles by some writers. These follicles are said to possess the properties of secreting glands. The ocular conjunctiva ends at the margin of the cornea, where it is termed *limbus*

conjunctivæ, and where it is continuous with the conjunctival portion of the cornea. At about three millimeters from the margin of the cornea the conjunctiva becomes united with the anterior reflection of Tenon's capsule.

Structure.—The epithelial layer is stratified. The superficial cells of the tarsal and ocular conjunctiva are of the flat or tesselated variety; of the fornix, irregularly cuboidal. The middle layer of epithelial cells is cuboidal, and the basement layer cylindrical. The tunica propria is very thin.

Vascular Supply.—The conjunctiva possesses no large vessels, but it has a very rich network of small vessels, which become prominent on irritation of the conjunctiva. In the retrotarsal and ocular portions of the conjunctiva the vessels are freely movable over the underlying tissue.

A rich plexus of lymphatic vessels exists in the conjunctiva; those of the upper conjunctiva near the outer canthus communicate with the chain of lymphatic vessels which pass to the pre-auricular region, those of the lower lid communicate with the submaxillary lymphatics.

Nerve Supply.—The nerve supply is from the lachrymal and from the supratrochlear and infratrochlear branches of the fifth nerve.

Lachrymal Apparatus.—The lachrymal apparatus comprises a secreting and a conducting portion. The secreting portion consists of the lachrymal glands and their ducts; the conducting portion of the puncta lachrymalia, canaliculæ, lachrymal sac, and lachrymal canal.

Secreting Portion.—*Lachrymal Glands.*—This part of the lachrymal apparatus includes (*a*) a large mass of glandular tissue, the principal lachrymal gland; (*b*) a number of small lachrymal glands, whose ducts open into the fornix conjunctivæ above; (*c*) Krause's glands (Fig. 19). The principal lachrymal gland consists of two portions—the orbital, which is the principal part, and the palpebral, often designated the accessory lachrymal gland (Fig. 23). The orbital portion is a flattened mass of gland tissue which measures about 1.8 cm. in its longest, transverse diameter, 1.5 cm. in its anteroposterior diameter, and is approximately 5 mm. thick. These dimensions vary greatly. The orbital portion of the lachrymal gland is enclosed in a delicate connective-tissue capsule, and is lodged in the upper outer angle of the orbit, just within the margin of the orbit, in a depression in the frontal bone—the lachrymal fossa. The gland lies immediately beneath the periosteum, to which it is connected by a few delicate connective-tissue fibers; a thin cushion of orbital fat separates it from the fibrous capsule of Tenon and from the eyeball. The gland is composed of numerous acini associated in lobules, which are held together by connective-tissue fibers. The acini open into small channels, which converge to form from five to seven common ducts, measuring about 0.5 mm. in diameter. The ducts open on the conjunctival surface of the upper fornix, which at this point approaches very closely to the gland (Fig. 23). The openings form an irregular line. According to Hyrtl, Luschka, and Henle, one or two of these ducts pass to the lower fornix, where they discharge the lachry-

mal fluid that passes through them. The common ducts are surrounded by lobules of glandular tissue of the same character as the principal gland, which discharge their secretion in part into the common duct, in part by independent ducts into the upper fornix. This cluster of glandular tissue is the palpebral portion of the lachrymal gland, also known as the *accessory lachrymal gland.* The expansion of the tendon of the levator palpebræ superioris partly separates the lower or accessory portion of the lachrymal gland from the orbital portion.

Lying in the upper fornix conjunctivæ, extending forward almost to the inner canthus, are a number of small acinous glands which secrete a small amount of fluid like the lachrymal fluid, which is discharged into the fornix. These may also be termed accessory lachrymal glands.

Fig. 23

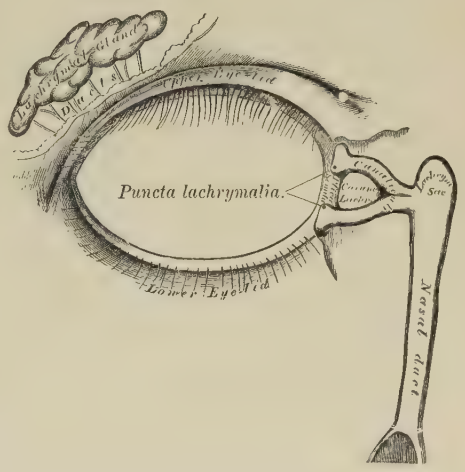

The lachrymal apparatus. Right side. (Gray.)

Vascular Supply. — The lachrymal gland is supplied with blood from the lachrymal artery, usually a branch of the ophthalmic artery (sometimes from the deep temporal artery). It passes along the orbital wall between the outer and superior recti muscles, and enters the gland; the vein has a similar course, emptying into the ophthalmic vein.

Nerve Supply.—The lachrymal gland is innervated by the lachrymal nerve, a branch of the first division of the fifth. In the gland branches are given off which supply the upper outer portion of the conjunctiva. Branches pierce the external palpebral ligament and pass to the integument of the upper eyelid, anastomosing with branches from the facial nerve.

Lachrymal Secretion.—Under ordinary conditions the quantity of lachrymal fluid secreted is dissipated by evaporation, very little passing into the lachrymal canals; but when the flow is excessive, which occurs under the influence of certain stimuli, the fluid is wafted to the lachrymal lake by the motion of the lids, where it passes into the lachrymal canals. If the capacity of these channels is overtaxed, the tears (lachrymal fluid) flow over onto the cheek.

The lachrymal secretion, according to Arlt,[1] is composed as follows:

Water	98.223
Chloride of sodium	1.257
Albumin	0.504
Salts	0.016
Trace of fat	0.000
	100.000

[1] Arch. f. Ophth., 1, 2, p. 137.

Experiments have been made to determine the bactericidal action of the tears, and positive results have been obtained. Hellberg[1] made a series of 22 experiments with the staphylococcus. In 16 cases partial or complete destruction of the germs occurred; in 4 cases the germs multiplied. It was found that boiling destroyed the germicidal constituent, demonstrating the fact that this principle must be a volatile or an albuminous substance.

Conducting Portion.—*Lachrymal Papillæ.*—The conducting portion of the lachrymal apparatus begins at the small perforated elevations or papillæ (lachrymal papillæ) situated 4 to 5 mm. from the mesial end of the internal canthus at the point where the free inner borders of the lids end.

Fig. 24

Outline of cast of tear passages: *C*, canaliculi; *S*, lachrymal sac; *N*, neck of sack; *D*, lachrymal duct. (Dwight, Warren Museum, Harvard Medical School.)

Lachrymal Canaliculi.—These passages (lachrymal canaliculi) extend almost at right angles to the surface at the papillæ, becoming ampulliform immediately beneath the surface, where they measure 1 mm. in diameter. At a depth of 1.5 to 2 mm. the canaliculi bend abruptly toward the median line, become narrower (0.6 mm.) in lumen, and lie a little more superficially. The curve of the canaliculi follows the curve of the border of the lachrymal lake, and either unite before entering the lachrymal sac or enter by separate openings very close together and just behind the outer band of the internal canthal ligament. The perforations at the lachrymal papillæ are known as the *puncta lachrymalia.* The upper punctum is smaller than the lower, which measures 0.5 mm. They are not always placed at the apex of the papilla.

The canaliculi vary in length in different individuals, averaging 8 mm. They are lined with squamous epithelium. Their walls are composed largely of elastic connective-tissue fibers, and they are surrounded by the fibers of Horner's muscle, arranged spirally, which act as sphincters of the canaliculi, contracting and narrowing the lumen of the canaliculi whenever the act of winking takes place.

Lachrymal Sac.—The lachrymal sac (*saccus lachrymalis*) is lodged in the lachrymal groove at the inner margin of the orbit (page 29). Its upper extremity is closed, dome-like (*fundus sacci lachrymalis*). Its lower extremity terminates at what is known as the *neck of the sac* (Fig. 24), in the membranous canal, the *lachrymal canal,* which lies in the bony passage, the *nasal duct.* The lachrymal sac varies in size in different

[1] Hygeia, May, 1900.

individuals; its average measurement is 12 mm. in length, 4 mm. in its transverse, and 5 mm. in its anteroposterior diameter. The sac is firmly attached to the periosteum of the lachrymal groove. It lies between the inner and outer reflection of the septum orbitale, a thickening of the outer portion forming the internal canthal ligament. The canaliculi open into the lateral wall of the sac. On closure of the eyelids the lachrymal sac is slightly compressed by Horner's muscle, forcing the lachrymal fluid there contained into the lachrymal canal, and thus into the nasal cavity.

Lachrymal Canal.—The lachrymal canal is slightly narrower as it unites with the sac, measuring 3 mm. in diameter. It sometimes presents a veritable fold of mucous membrane at this point. The lumen reaches a diameter of 4 mm. in the lower part of the canal. The diameter of the bony canal varies from 2.5 mm. to 7 mm., with an average of 5.5 mm. The length of the canal varies much in different individuals. The average is 14 mm.; extremes, 10 to 23 mm. A system of veins is present in the wall of the canal, forming a cavernous tissue which, when congested, may suffice to close the lumen of the canal. This canal opens into the inferior nasal meatus, terminating differently in different individuals; a vertical or oblique slit, or a prolongation of the membranous canal, may convert it into a valve-like opening. The walls of the sac and of the canal are lined with ciliated epithelium, which wafts the contents of the sac and canal toward the nasal cavity. The stroma is composed of non-elastic and elastic connective-tissue fibers, and is closely attached to the periosteum.

The opening of the lachrymal canal into the lower meatus varies in distance from the border of the posterior nasal meatus from 28 to 35 mm., from the anterior extremity of the inferior turbinate from 8 to 16 mm.

The direction of the lachrymal canal is downward, outward, and slightly backward. The degree of deviation from the perpendicular varies in different individuals. If a straight probe be laid over the middle of the inner canthal ligament and in the groove between the ala of the nose and the cheek, it will lie exactly over the course of the canal. Thus, it will be seen that the course of the canal depends not only on the width of the bridge of the nose, but also on the width of the base of the nose, or the distance of the alæ apart.

Cornea.—The cornea is in form a horizontal ellipse, measuring 10 to 11 mm. in its vertical and 11 to 12 mm. in its horizontal meridians. At the periphery the cornea is 1 mm. thick; at the centre it is slightly thinner. The radius of curvature of the anterior surface of the cornea is: Horizontal meridian, 7.8 mm.; vertical meridian, 7.7 mm. (Donders); of the posterior surface, which is more regular, 6 mm. (Merkel). Since the radius of curvature of the scleral portion of the globe is 12 mm., it will be readily seen that the cornea is more sharply curved than the sclera (Fig. 12). A slight annular depression is found at the union of the cornea with the sclera—the *sulcus scleræ*. Although oval in form anteriorly, posteriorly the cornea is circular. The sclera overlaps the

corneal tissue externally, the overlapping being greatest above and below.

Layers.—The cornea is composed of five layers (Fig. 26, transverse section of the cornea):

1. *Epithelial Layer.*—This layer is stratified. The superficial layer of cells is composed of tessellated or pavement epithelium. The cells of the middle layer are irregularly cuboidal in form, and are supplied with numerous fine processes ("prickle cells"), which interlace with the processes of adjoining cells. The cells of the deep or basement layer are columnar or cylindrical in shape; are somewhat irregular in length, and are placed on a basement membrane (Bowman's membrane). All of the cells of the retina are supplied with nuclei. Regeneration of cells takes place from all the layers.

2. *Bowman's Membrane.*—This forms the second layer, and is a thin, homogeneous membrane.

Fig. 25

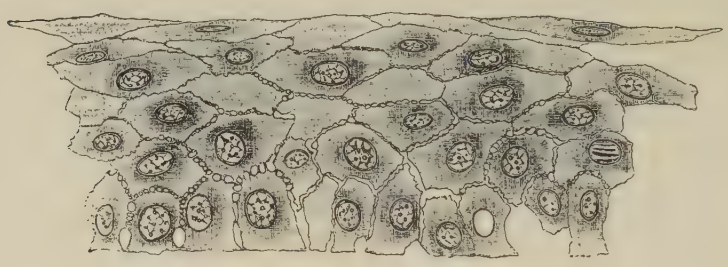

Epithelial layer of cornea. (Quain.)

3. *Substantia Propria.*—The third layer is the thickest layer of the five, and is known as the substantia propria. It consists of numerous bundles of connective-tissue fibers, associated in lamellæ. The lamellæ are arranged parallel to the surface of the cornea. They are connected by connective-tissue fibers, which pass from one lamella to another. These fibers are numerous in the anterior part of the substantia propria, and have been given the name of *fibræ arcuatæ.* Lying between the bundles and lamellæ are small spaces—*lacunæ*—and uniting these, numerous small canals—*canaliculæ.* These lacunæ and canaliculæ together form the *canalicular lymph system of Recklinghausen.* In each lacuna a branching cell is found, whose protoplasmic processes extend along the canaliculæ, anastomosing with those of adjacent cells. These cells are the *fixed cells* of the cornea, in contradistinction to the leukocytes which, by amebic movements, penetrate to every part of the cornea—the *migratory cells* of the cornea.

4. *Descemet's Membrane.*—The fourth layer of the cornea (Descemet's membrane) is a thin homogeneous membrane possessing chemical constitutents which serve to distinguish it from Bowman's membrane. Ranvier is of the opinion that this corneal membrane is the product

of the endothelial cells of the cornea which rest upon it. The membrane of Descemet breaks up into numerous fibers at the periphery of the cornea, forming the *ligamentum pectinatum.*

Fig. 26



Sectional view of cornea: 1, epithelium; 2, Bowman's membrane; 3, substantia propria; 4, Descemet's membrane; 5, endothelium; *a*, fibræ arcuatæ; *b* and *d*, lamellæ; *c*, lacunæ; *e*, sclera; *f*, limbus conjunctivæ. (Schäfer.)

5. *Endothelial Layer.*—The fifth layer of the cornea consists of a single layer of polygonal cells of the endothelial variety, which lose their peculiarities at the ligamentum pectinatum, passing over into cells that are much thinner, that cover the fibers of this ligament.

Vascular Supply.—Blood-vessels do not occur in the cornea.

Nerves.—These are derived from the ciliary plexus formed by the long and short ciliary nerves. They pass through the sclera on the outer side

of Schlemm's canal, and form a network, the *plexus annularis*, in the vicinity of the margin of the cornea. (See Plate VIII.) From this plexus two sets of twigs are given off: (*a*) One set passes to the conjunctiva, where they join the conjunctival nerves and form a plexus. From this plexus a number of nerve trunks are given off, which enter the cornea and are distributed to the anterior layers of that structure. (*b*) The second set of twigs passes directly to the substantia propria corneæ, entering it near Descemet's membrane. The entire number of nerve trunks that enter the cornea is sixty to eighty, two-thirds of which are concerned in supplying the anterior portion of the cornea. The nerve trunks lose their medullary substance after passing the margin of the cornea, break up into smaller bundles, and form plexuses. Radial fibers, which leave the

Fig. 27



Rabbit's cornea, showing lacunæ and canaliculi. Gold stain. (Dixon.)

Fig. 28

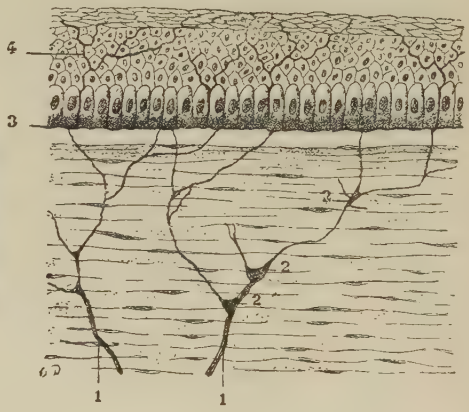

Nerves in corneal tissue: 1, nerve trunks; 2, nodes of Ranvier; 3, terminal nerve fiber entering epithelial layer; 4, nerve ending. (Gutmann.)

nerve trunks at the nodes of Ranvier, pass to Bowman's membrane, which they pierce, and form a plexus, the subepithelial plexus, from which terminal fibrillæ are derived which end in the epithelial layer in nerve plates (Dogiel), peculiar convolutions, bulbs, hooks, and free ends.

Nutrition.—The cornea is nourished by nutrient fluid which enters at Fontana's spaces in part, and in part from the capillary network at the limbus conjunctiva.

Sclera.—The sclera, together with the cornea, forms the fibrous coat of the eye (Fig. 12). It is the segment of a sphere, the radius of curvature of which is about 12 mm. The sclera joins the cornea at the sulcus scleræ. The sclera is thickest at its posterior part, where it measures about 1 mm.; thinnest near the equator, becoming slightly increased in thickness in its anterior portion, where it receives the insertion of the recti muscles.

PLATE VIII

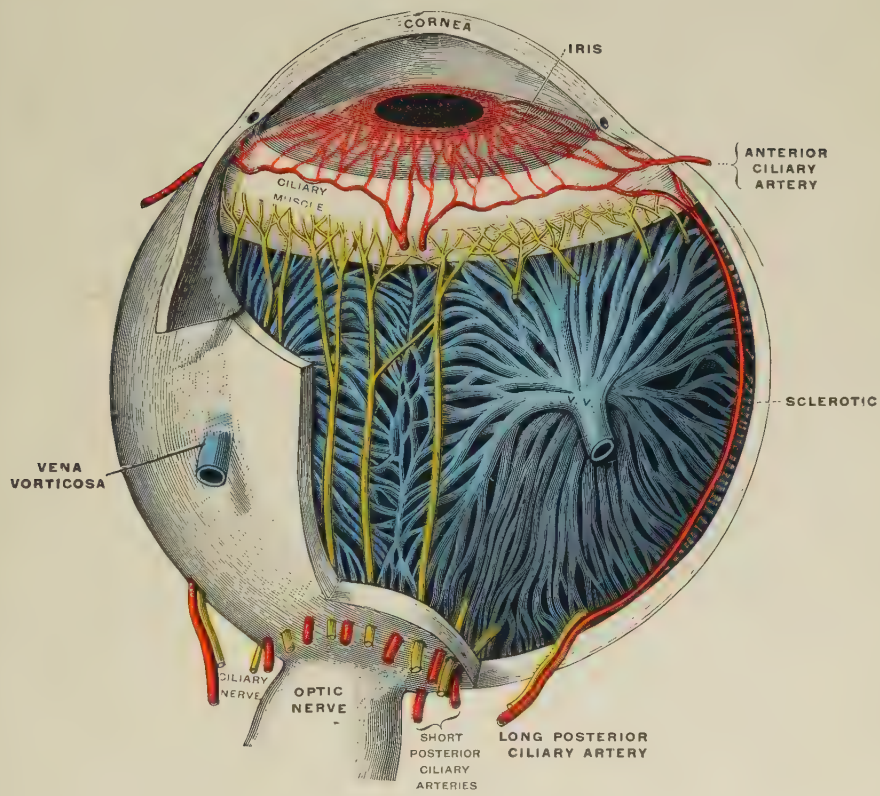

Vessels and Nerves of the Chorioid and Iris, seen from above.

The sclerotic and cornea have been largely removed. (Testut.)

The anterior portion of the sclera is pierced by a number of minute openings through which pass the anterior ciliary arteries and veins. Some small nerve twigs also pass through the sclera a short distance back from the corneal margin. At the equator of the globe the sclera is pierced by four, sometimes five, relatively large openings, which give

Fig. 29

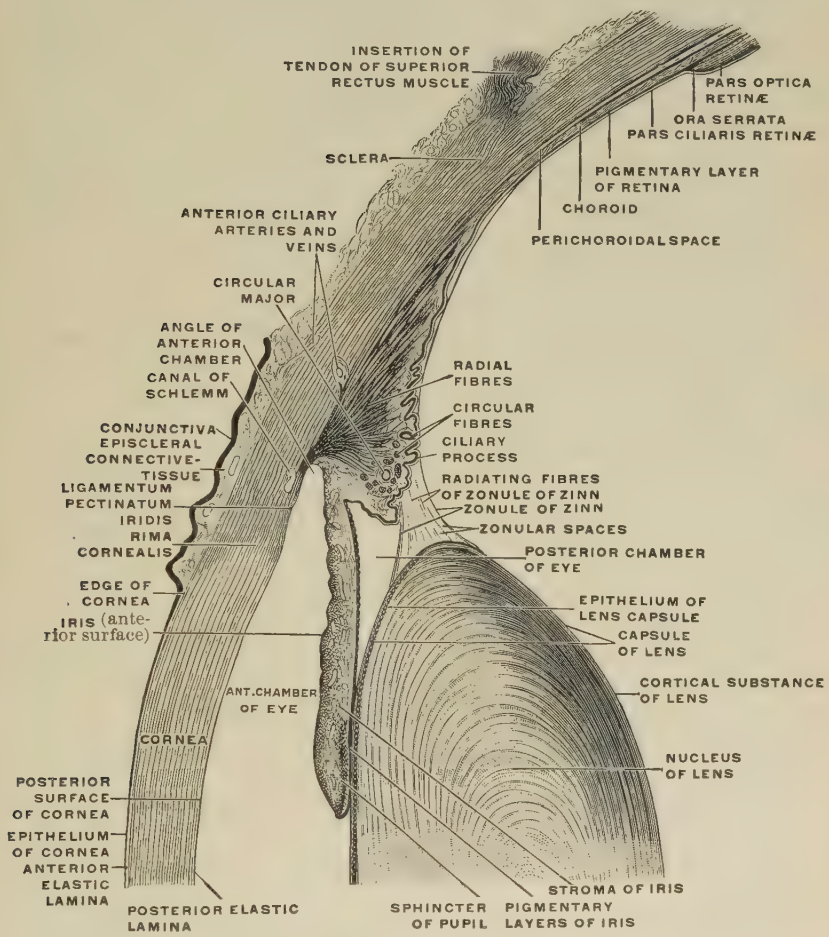

The upper half of a sagittal section through the front of the eyeball. (Toldt.)

passage to the large venæ corticosæ. (See Plate VIII.) Posteriorly a number of openings are found which give passage to the short ciliary arteries and ciliary nerves, and a large opening to permit the passage of the optic nerve fibers. This opening, which measures about 1.5 mm. in diameter, is traversed by connective-tissue bundles which are continuous with the sclera proper, forming the *cribriform plate*. The sclera is made up of connective-tissue fibers which are not disposed in regular lamellæ as

are those of the cornea, and which run in various directions. Between these bundles of connective-tissue fibers spaces are found resembling the lacunæ of the cornea. In the sclera about the optic nerve entrance, and in its anterior portion, branching pigment cells are found; these are most plentiful near the inner surface of the sclera. In certain individuals the openings for the passage of the anterior ciliary veins are pigmented, giving the appearance of a number of black points within the sclera. In certain individuals, particularly those of the colored race, the pigmentation of the sclera anteriorly is very marked.

At its anterior margin the tissue of the sclera is continuous with that of the cornea. Near the anterior margin of the cornea, and separated from its inner surface by a thin layer of connective-tissue bundles, is the venous sinus, known as Schlemm's canal. Externally the sclera is covered by the visceral layer of Tenon's capsule. Internally it affords, at its anterior part, attachment for the ciliary body by means of the ligamentum annularis. Posteriorly the inner surface of the sclera is covered by the lamina fusca of the chorioid, the sclera being separated from the chorioid proper by the suprachorioidal lymph space. But few blood-vessels are found in the substance of the sclera. The episcleral tissue, however, is richly supplied with blood-vessels, particularly in its anterior portion. The nerve supply of the sclera is extremely scanty. Posteriorly the tissue of the sclera is continuous with the sheath of the optic nerve.

Iris.—The iris is the anterior portion of the vascular tunic. Its free border, the pupillary margin, rests on the anterior surface of the capsule of the lens. As this surface occupies a plane anterior to the ciliary border of the iris, the iris forms a shallow cone, the depth of which depends on the position of the crystalline lens. If the lens is absent, the iris hangs in a vertical plane and is tremulous (iridodonesis). The diameter of the iris (in small eyes 9 mm., in large eyes 13 mm.) is approximately 11 mm. The iris is not of uniform thickness, but averages 0.04 mm. when at rest. When widely dilated, it may double in thickness. The pupil varies from 2.5 to 6 mm. in diameter by moderate illumination when the iris is in a state of rest.

At its insertion the posterior two-thirds of the iris passes into the ciliary body; the anterior third is continuous with the ligamentum pectinatum. The iris at its insertion is thin and weak, a very slight injury being sufficient to detach it from the ciliary body. The pupillary margin of the iris is thin and is bordered by a very narrow black line, the slightly extended posterior pigment layer.

The anterior surface of the iris is irregular; delicate, radiating ridges of tissue, in which the larger blood-vessels run, extend from the ciliary border to a short distance from the margin of the pupil, where they become united, forming a wavy or angular line which encircles the pupillary margin. This line marks the site of the *circulus arteriosus iridis minor.* It serves to divide the iris into two zones—the inner, known as the *pupillary* or *minor zone;* the outer, the *ciliary* or *major zone.* Between the ridges of tissue are depressions which, at the cir-

culus minor, form crypts of various sizes; similar, but smaller, crypts are present at the ciliary border.

The posterior surface of the iris is not ridged. When the iris is dilated, equatorial folds become manifest.

Layers.—*Anterior Endothelial Layer.*—The iris is limited anteriorly by a layer of flat, nucleated endothelial cells, which is continuous over the surface of the trabeculæ of the ligamentum pectinatum and the posterior surface of the cornea.

Anterior Boundary Layer.—The anterior boundary layer is not a distinct layer, but is the condensed anterior portion of the stroma of the iris. It is situated immediately beneath the endothelium, and is composed of delicate connective-tissue fibers and irregular and branching connective-tissue cells. Small clefts are present between the elements that compose this layer, which are continuous with the large lymph spaces of the vascular stroma. The deposit of pigment granules takes place in the cells of this layer and in the cells of the pupillary zone to a greater extent than in the cells in other parts of the stroma.

Vascular Stroma Layer.—This is composed of bundles of connective-tissue fibers loosely associated. The connective tissue invests the blood-vessels and nerves, and constitutes the supporting framework of the iris. This layer contains numerous blood-vessels, nerve trunks, and irregular lymph spaces. Round, oval, and branching nucleated cells, the protoplasm of which becomes pigmented in colored irides, are found scattered throughout this layer. The muscles of the iris—the sphincter and dilator pupillæ—are also found in this layer.

Muscles of the Iris.—*Sphincter Pupillæ.*—The sphincter pupillæ muscle lies very near the pupillary margin. It is a flat, circular band measuring 0.04 mm. to 0.08 mm. in width, according to the state of contraction, and is about one-tenth as much in thickness. It is composed of bundles of non-striated muscle fibers, which interlace. The bundles are separated from each other by delicate connective-tissue sheaths. The sphincter pupillæ is separated from the pupillary margin by the posterior pigment layer of the iris, which extends a very little way over the stroma at the pupillary margin, and is seen as a narrow black ring at this point.

Fig. 30



Segment of iris: *a*, sphincter; *b*, dilatator. (Iwanoff and Arnold.)

Dilatator Pupillæ.—The dilatator pupillæ consists of two or three layers of long spindle-shaped cells, possessing elongated nuclei; they are undoubtedly non-striated muscle fibers. These fibers are arranged meridionally and lie on the limiting membrane. They apparently

form a continuous layer, extending from the ciliary margin of the iris to the sphincter pupillæ, with which muscle they blend, entering at the outer border and posterior surface.

Lamina Vitrea (*Posterior Limiting Lamella, Membrane of Bruch*).—This extremely delicate membrane is homogeneous under low magnifying powers, but presents fine striations when examined with high powers of the microscope. It is extremely thin (0.002 mm.), and is closely adherent to the inner layer of cells of the pigment layer. The cells that compose the dilatator pupillæ lie, apparently, immediately upon this layer. The lamina vitrea of the iris is continuous with the lamina vitrea of the chorioid and the membrane of Bruch in the ciliary body, being an extension of the same membrane.

Pigmented Layer (*Uvea of the Iris*).—This represents the extreme anterior portion of the secondary eye vesicle. The cells of both layers in pigmented irides are so closely filled with pigment granules that the individual cells cannot be distinguished. They possess round nuclei, which are also pigmented. In bleached specimens and in the irides of albinos the cellular character of this membrane can be clearly seen. At the ciliary attachment the pigment layer of the iris (pars iridis retinæ) passes over into the inner or pigmented layer of the ciliary body (pars ciliaris retinæ). As the layer passes on to the ciliary body, the pigment granules of the inner layer of cells gradually disappear, the deep or outer layer only remaining pigmented

Vascular Supply.—*Circulus Arteriosus Iridis Major.*—The long posterior ciliary arteries pierce the sclera near the optic nerve entrance and run forward in the vascular tunic, lying in the horizontal meridian of the globe, until within 2 to 5 mm. from the ciliary border of the iris, where they divide into an ascending and a descending branch. These branches run equatorially in the anterior part of the ciliary body, encircling the iris and forming the circulus arteriosus iridis major. They give off anterior radial branches to the iris, and posterior branches to the ciliary body as they proceed. When they reach the vertical meridian of the globe, each branch again divides into two principal branches, which run meridionally and anastomose. The branches of the long ciliary arteries are reinforced by the short ciliary arteries derived from the muscular and lachrymal branches of the ophthalmic artery. These small vessels, six to eight in number, pierce the sclera at the attachment of the annular ligament, about 2 to 3 mm. from the sclerocorneal junction, and anastomose with the branches from the long ciliary artery, sending branches into the iris and ciliary body.

Circulus Arteriosus Iridis Minor.—The branches that pass into the iris proceed radially, giving off small branches, until they reach the outer margin of the sphincter iridis, where they anastomose freely and form the circulus arteriosus iridis minor. From this circle three sets (Piersol) of minute arterioles are given off, which terminate in capillaries. The inner set goes to nourish the muscle-fibers of the sphincter iridis, the middle set to the deep stroma of the iris, and the outer set to the more superficial stroma of the iris. The capillaries terminate in the

venous radicals which proceed radially to the ciliary body, where they empty into the vena vorticosæ. (See Plate VIII.)

The walls of the arteries are thick, due to a preponderance of connective tissue, with some elastic fibers. Muscle fibers are said to be relatively few. The arteries and veins possess thick sheaths of connective tissue, between which and the wall proper is the perivascular lymph space.

Lymphatics of the Iris.—There are no distinct lymph vessels in the iris. The clefts between the tissue elements of the anterior border layer, the irregular spaces between the fibers of the vascular stroma, and the perivascular spaces are the lymph channels of the iris. They communicate with the lymph spaces in the ciliary body, with the lymph spaces at the filtration angle, and through the spaces of Fontana with the anterior chamber.

Nerve Supply.—The bundles of nerve fibers that enter the iris are derived from the *ciliary plexus* that lies in the ciliary muscle. They enter the iris at the ciliary border and unite to form a plexus in the stroma of the iris, which is most dense at the border of the sphincter pupillæ. Three kinds of fibers are given off from this plexus: (1) The sensory; (2) motor; (3) sympathetic. The sensory fibers are medullated; they supply the anterior border layer of the iris. The motor fibers are medullated; they pass to the sphincter, where they terminate in fine fibrillæ upon the muscle fibers. The sympathetic nerve fibers are non-medullated; they pass backward toward the dilatator, and are supposed to supply it (Baker). Retzius has demonstrated motor nerve endings in the dilatator iridis of the rabbit's iris.

Pigmentation of the Iris.—Pigmentation may be deeper in one eye than in the other, *chromatic asymmetry.* It may affect but part of the stroma of an iris, or one iris may be pigmented, the other escaping—heterochromous. As the age increases the stroma of the iris becomes more dense, changing a blue to a gray eye; the brown eye often becomes lighter in tone. The pigmentation of the stroma of the iris usually corresponds to the general pigmentation of the individual; blondes have blue or gray eyes; brunettes, brown eyes.

Ciliary Body.—That portion of the vascular coat of the eye situated between the root of the iris and the free margin of the layer of the chorioid known as the choriocapillaris (which marks the anterior limit of the retina) is known as the *ciliary zone* or *body* (Fig. 29). The zone is about 5.5 mm. wide. It is marked on its inner surface by numerous fine radiations, which are most prominent anteriorly. The radiations resemble to some degree cilia or hairs, and it is because of this resemblance that the region has been known as the ciliary region ever since the writings of Vesalius (1543).

The ciliary body is thickest in its anterior portion. On cross-section it forms a wedge-shaped body, its base lying anteriorly.

The ciliary body is divided into two zones—a posterior portion, which is relatively smooth, termed the *pars non-plicata,* or *orbiculus ciliaris;* and an anterior portion, which bears the ciliary processes, the *pars*

plicata, or *corona ciliaris*. The entire inner surface of the iliary body is covered by a double layer of cuboidal cells, the *pars ciliaris retinæ*. This layer lies on a homogenous basement membrane, the extension of the lamina vitrea of the chorioid.

The pars non-plicata is a continuation of all of the layers of the chorioid except the choriocapillaris.

Ciliary Processes.—The pars plicata bears the ciliary processes. These are folds of tissue, approximately seventy in number, which are arranged like a corona, radiating from the anterior end of the ciliary body. They measure 2.5 to 3 mm. in length, are 0.12 to 0.15 mm. in breadth, and from 0.8 to 1 mm. in height near their anterior extremity. They begin abruptly just posterior to the insertion of the iris and, gradually diminishing in size, pass imperceptibly into the tissues of the pars non-plicata. The ciliary processes are composed of a mass of convoluted vessels held together by a delicate framework of connective tissue. They are undoubtedly concerned in supplying the aqueous humor, and nutrition for the vitreous body, lens, and possibly the cornea. The limiting internal layer, *pars ciliaris retinæ*, is thrown into folds, and in the vicinity of the union of the two zones shallow depressions or follicles are formed, which Treacher Collins[1] has described as *ciliary glands*.

Annular Ligament.—The ciliary body is attached to the sclera by means of the annular ligament. The annular ligament is approximately 0.75 mm. in width; it is not very strong, but little force being required to tear through it and to detach the ciliary body from the sclera.

Muscles.—*Ciliary Muscle.*—The ciliary muscle, first examined microscopically by W. C. Wallace,[2] measures approximately 0.8 mm. in its greatest thickness, is from 3 to 4 mm. long, and is composed of two sets of muscle fibers.

The outer portion of the muscle is composed of fibers that run meridionally—*Brücke's muscle.*[3] The meridional fibers are divided into two portions. The fibers of the outer portion are long and terminate in the tissue of the chorioid in peculiar stellate expansions. This division of the ciliary muscle is frequently termed the *tensor chorioidea*. The inner half of the meridional fibers are known as the *radiating fibers*. They pass toward the inner surface of the ciliary body and before reaching the pigment layer form a network of muscle fibers, from which fine radiations are given off (Iwanoff). The more anterior fibers are said to be converted into circular fibers.

The second division of the ciliary muscle consists of bundles of fibers which are located in the inner anterior portion of the ciliary body and run equatorially. They constitute what is known as *Müller's muscle* or as the *compressor lentis* (Fig. 29). The size of this portion of the muscle varies greatly in different eyes, as pointed out by Iwanoff, being greatest in the hypermetropic eye and least in the highly myopic eye. A con-

[1] Trans. Ophth. Soc. United Kingdom, London, 1890-91.
[2] Amer. Jour. of Sciences and Arts, 1835, xxvii, 219-222.
[3] Med. Zeit., Berlin, 1846, xv, 130.

nective-tissue stroma, which contains some branching pigment cells, serves to support the different parts of the ciliary body.

Vascular Supply.—The ciliary body is richly supplied with blood-vessels and nerves. Posterior to the annular ligament the ciliary body is separated from the sclera by a narrow space, an extension of the perichorioidal lymph space.

Arteries.—The arterial supply to the ciliary body, muscle, and ciliary processes is from the circulus arteriosus irides major by means of posterior radiating branches. (See Plate VIII.)

Veins.—The veins carry the blood to the venæ vorticosæ.

Nerve Supply.—The nerve supply to the ciliary body is from the long and short ciliary nerves. The long ciliary nerves, usually two in number, are from the nasal branch of the trigeminus. They carry sensory and sympathetic fibers. The short ciliary nerves, eight to fourteen in number, are from the ciliary ganglion and are mixed (see page 42). Anterior branches of these nerves pass to the ciliary body, where they form a plexus—the orbicularis gangliosus—within the ciliary muscle. In the ciliary body three sets of nerve fibers are recognized: (1) Sensory fibers; (2) vasomotor (sympathetic) fibers; (3) motor fibers from the motor oculi, distributed to the ciliary muscle. Ganglion cells have been observed in the angles of the plexus (H. Müller).

Fig. 31

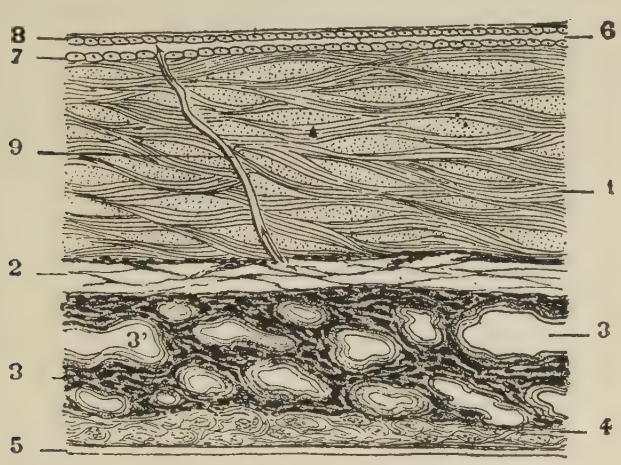

Transverse section of sclera and chorioid: 1, sclera; 2, lamina fusca and suprachorioidal space; 3, chorioid; 4, choriocapillaris; 5, lamina vitrea; 6, lymph space of Tenon; 7 and 8, endothelial layers; 9, lymph canal. (Testut.)

Chorioid.—The chorioid extends throughout the entire posterior part of the globe, its anterior boundary being at the ora serrata. At this point all of its layers except the choriocapillaris are continuous with the orbiculus ciliaris.

Posteriorly the chorioid is perforated by a circular opening through which the tissues of the optic nerve pass to the retina. The chorioid

lies against the sclera, to which it is quite firmly adherent about the optic-nerve entrance. The connective-tissue sheaths which surround the vessels and nerves which enter the chorioid after piercing the sclera, also form points of attachment to the sclera; in other parts the principal layers of the chorioid are separated from the sclera by the *perichorioidal lymph space*, which is traversed by numerous very small bundles of connective-tissue fibers; these loosely connect the two membranes.

The chorioid varies in thickness; in the vicinity of the macular region it measures 0.35 mm. It gradually decreases in thickness toward its anterior limit, where it measures 0.15 mm.

Color.—The color varies from a reddish to a dark brown, according to the amount of pigment that it contains. The stroma of the chorioid is composed of connective tissue which supports the numerous blood-vessels and nerves.

Layers.—The membrane may be divided into four layers:

1. The outer layer, *lamina fusca*, consists of a rather loose pigmented connective-tissue network, which, when the chorioid and sclera are separated, remains attached to the sclera; the rupture of the trabeculæ which unite both layers leaves the surface rough and shaggy. The space between these layers is the perichorioidal lymph space.

2. The *layer of large vessels* containing nerve trunks, veins which anastomose freely, and arteries. The outer portion of this layer contains the larger vessels; the inner portion a network of smaller vessels. The connective-tissue stroma in the outer portion of this layer contains branching pigment cells which are more or less numerous. A few non-striated muscle fibers are found. The inner portion of this layer contains elastic connective-tissue fibers, and the connective tissue here is condensed, forming a stratum easily seen with the microscope, the *elastic lamina of Sattler.*

3. *Choriocapillaris*, a layer of capillaries which anastomose freely, forming a close network. The capillaries are most dense immediately back of the fovea centralis and macula lutea of the retina, the meshes becoming larger as the periphery is approached. The capillaries anastomose with those of the optic nerve, but not with those of the retina. The function of this layer is to supply nourishment to the posterior layers of the retina.

4. *Lamina vitrea*, a thin membrane (0.0006 to 0.0008 mm., Iwanoff), homogeneous under ordinary powers of the microscope, but when macerated and viewed by higher power, finely fibrillar. This layer separates the pigment layer of the retina from the choriocapillaris. It is continuous beneath the pars ciliaris retinæ and in a modified form beneath the pars iridis retinæ.

Vascular Supply.—*Arteries.*—The blood supply to the chorioid is by the short posterior ciliary arteries, twelve to fifteen in number, which pierce the sclera diagonally about the optic nerve. On reaching the chorioid they anastomose rather freely in the layer of large vessels, sending numerous small branches to the choriocapillaris, into which the arterial blood flows. About the optic nerve the arteries form a

vascular circle, the *circle of Haller,* from which some small branches pass to the retina. Anteriorly they anastomose with the anterior ciliary arteries.

Veins.—The blood is returned from the choriocapillaris by numerous small veins which pass to larger venous branches in the layer of large vessels. The veins anastomose very freely and finally converge to form four to six large veins, the *venæ vorticosæ,* which pierce the sclera at the equator of the globe, emptying into the large venous trunks of the orbit. (See plate VIII).

Nerve Supply.—The nerves of the chorioid are derived from the third and fifth cranial and from the sympathetic, the long ciliary nerves (see iris), and the short ciliary nerves which spring from the ciliary ganglion (Plate VI). The former are two or three in number; the latter eight to fourteen. They pierce the sclera in a diagonal course near the optic nerve and enter the outer part of the layer of large vessels. They give off many branches, which anastomose freely and form a plexus in the superficial portion of the layer of large vessels, from the anterior portion of which numerous branches pass to the ciliary body. The plexus contains many ganglion cells which are found at the point of anastomosis and at the crossing of nerve trunks. From this plexus many minute branches are given off which follow the small arterial trunks and terminate in the choriocapillaris. Many branches also pass to the muscular coats of the vessels. The nerve fibers that terminate in the chorioid are almost exclusively from the sympathetic nervous system.

Lens.—The crystalline lens of the eye was first compared to a lens of glass by Maurolyci in 1575. It possesses the property of changing its form for the purpose of greater or less refraction, and because of this was thought to contain muscular fibers, and was termed by Leeuwenhoek, the *musculus crystallinus.*

The lens is circular in shape and is suspended from the ciliary process, its equatorial margin being separated 0.5 to 0.6 mm. from them.

Size.—The size of the lens varies somewhat according to the age of the individual, being larger in advanced adult life and in the very tall. Its anteroposterior diameter varies according to the condition of its refraction. The following table taken from Norris and Oliver gives the approximate dimensions.

	Distant vision. Millimeters.	Near vision. Millimeters.
Thickness	3.7	4.0
Anterior radius	10.0	6.0
Posterior radius	6.0	5.0

The diameters of the lens at different ages, as given by Collins,[1] are:

Age.	Anteroposterior. Millimeters.	Equatorial. Millimeters.
Four months	2.8	3.3
Six months	3.5	4.0
Nine months	4.3	5.75
Adult (Merkel)	3.7	9.0

[1] Lancet, London, December 8 and 22, 1894.

It will be seen by this table that the lens in the fetus and infant is much more nearly spherical in shape than in the adult.

Although the anterior surface approaches that of the segment of a sphere, it corresponds to the segment of an ellipsoid, the posterior surface to the segment of a paraboloid (Brücke). The weight of the lens, determined by the results of many observers, varies from 0.2 to 0.29 gram, being lighter in the very young, heavier in the old. The specific gravity is 1121 (Mumeley). Its volume is approximately 0.25 c.c.

Color.—In youth it is nearly transparent. It may present a bluish tinge when viewed by oblique illumination. In middle-aged adults the lens presents a slight grayish-blue tint by oblique illumination; in the aged, often a yellowish or amber tint.

Substance.—In early life the lens is quite soft and gelatinous, and is nearly uniformly so. In the old the centre of the lens is much harder and denser than the peripheral portions (*substantia corticalis*), the transition being gradual; the central portion (*nucleus lentis*) is said to be sclerosed, and usually presents an amber hue when examined by oblique light. This increase in hardness causes loss of elasticity, and the form of the lens cannot be so easily influenced by the ciliary muscle.[1]

Fig. 32

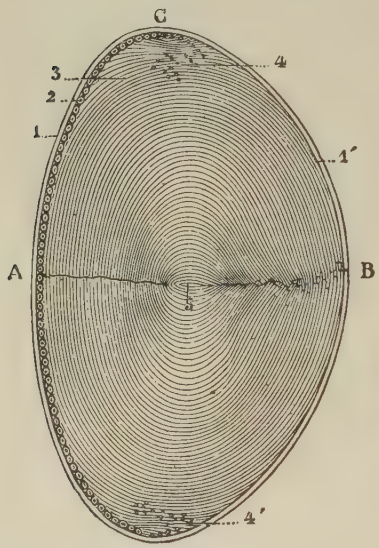

Section of crystalline lens: *A*, anterior surface; *B*, posterior surface; *C*, equator; 1 and 1′, capsule of lens; 2, epithelium; 4, fibers at the equator; 5, nuclear fibers of lens. (Babuchin.)

Fig. 33

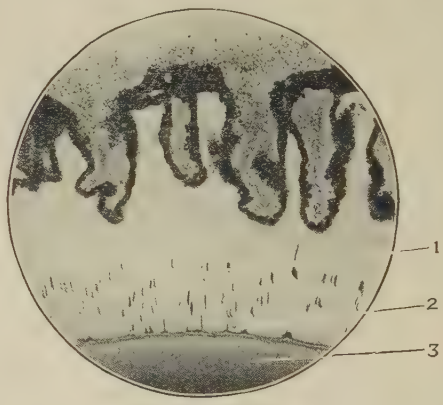

Ciliary processes: 1, cut fibres of the suspensory ligament; 2, insertion of fibers of suspensory ligament into capsule of lens; 3, segment of lens.

The crystalline lens and its containing membrane present three structures for consideration—the lens capsule, the subcapsular epithelium, and the lens substance proper.

[1] For this reason the refraction of the lens can be changed but little in the aged.

Capsule.—The substance of the lens is contained in a delicate, elastic, homogeneous structure, the *capsule.* The capsule is thicker in its anterior than in its posterior portion, measuring 0.01 to 0.015 mm. anteriorly and 0.005 to 0.007 mm. at the posterior pole of the lens. The fibers of the *suspensory ligament* are inserted into the lens capsule at and near the equator of the lens. The portion of the capsule anterior to the equator of the lens is lined with epithelium and has been designated *anterior capsule;* that portion back of the equator, free from epithelium in the normal lens, the *posterior capsule.* The capsule is quite strong and elastic. If cut or torn it rolls outward. It is affected but little by inflammatory processes, and does not become absorbed when torn or injured.

When examined under high magnification, the capsule shows some fine parallel striations near the outer surface; the inner portion does not present striations. It often occurs that a few lamellæ at the equator of the lens are slightly raised by traction of the fibers of the suspensory ligament (Fig. 33).

The tendency to divide into lamellæ is regarded by Schwalbe and others as indicating a double source of origin—the outer portion from mesoderm; the inner portion from epithelial cells.

Subcapsular Epithelium.—The epithelium covers the inner surface of the anterior portion of the lens capsule in a single layer in the adult lens, and extends as far as the equator of the lens; they are polyhedral and possess short processes, but approach the hexagonal shape. They measure 0.019 mm. to 0.021 mm. in diameter, are supplied with a nucleus and often a nucleolus. At the equator of the lens the epithelial cells elongate and assume the columnar type. They elongate at both ends, become somewhat narrowed; the capsular end is crowded on to the posterior portion of the capsule; its anterior end, projecting forward, finds itself in contact with the free surface of the subcapsular epithelium. It has now assumed the shape of a lens fiber, is slightly bent, its concavity looking toward the equator of the lens. The place of transition from epithelial cell to lens fiber, which is exactly at the equator of the lens, is known as the lens whorl (Fig. 5) (O. Becker). The new-formed fibers constitute the outermost layer or lamella of lens fibers; as they elongate and other layers are formed above them, their extremities meet and abut, forming suture lines which appear as faintly marked radiating striæ, constituting the *lens star,* or *lens figure* (Figs. 34 and 35).

In the young lens the fibers retain their nuclei. On examining an anteroposterior section of such a lens, it will be found that the nuclei are included in a zone which describes an arc, the convexity of which is directed forward (toward the anterior part of the lens). This clearly shows that the capsular or posterior end of the lens fiber develops more rapidly than the free or anterior end. As the lens fiber grows older the nucleus gradually disappears. In the adult lens the nucleus is present only in the fibers of the peripheral lamellæ. The lens fibers that compose the superficial lamellæ are larger than the nuclear fibers;

the former, which extend about two-thirds the meridional distance from pole to pole, measure about 8 mm. in length; the latter (nuclear fibers) correspond more nearly to the length of the axis of the lens, about

Fig. 34



Fig. 35



Lens figure in the adult. (Arnold.)

4 mm. The lens fibers are compressed into the shape of ribbons which on cross-section are roughly hexagonal. There is a marked difference in the width and thickness of the fibers in various portions of the lens. At the periphery they measure 0.01 to .012 mm. in width and about 0.005 mm. in thickness. At the nucleus, 0.0075 mm. in width and 0.0025 mm. in thickness (Piersol).

The surfaces of the lens fibers are irregular (serrated); the fibers are held together by means of a cement substance having the same index of refraction. The cement substance is most plentiful in the seams form-

Fig. 36

Isolated lens fibers. (Graefe and Saemisch.)

Fig. 37



Cross-section of lens fibers from a frozen lens. (Graefe and Saemisch.)

ing the lens star, at the apex of the lens anteriorly and posteriorly, and between the lens capsule and the lens proper.

The lens fibers do not run a perfectly meridional course; they resemble an elongated "S," the ends bending slightly to terminate at a radius of

the lens figure. The lens fibers do not abut on the subcapsular epithelium except over a limited area at the lens whorl; beyond this they terminate at the radii of the lens star, as before described (Figs. 34, 35, and 38).

Suspensory Ligament.—The lens is held in position by means of the suspensory ligament (*zonula of Zinn*), which has been quite fully described in the chapter on development (page 22). The general character of the suspensory ligament is depicted in Figs. 5 and 29, which figures also show its attachment to the capsule of the crystalline lens.

Fig. 38

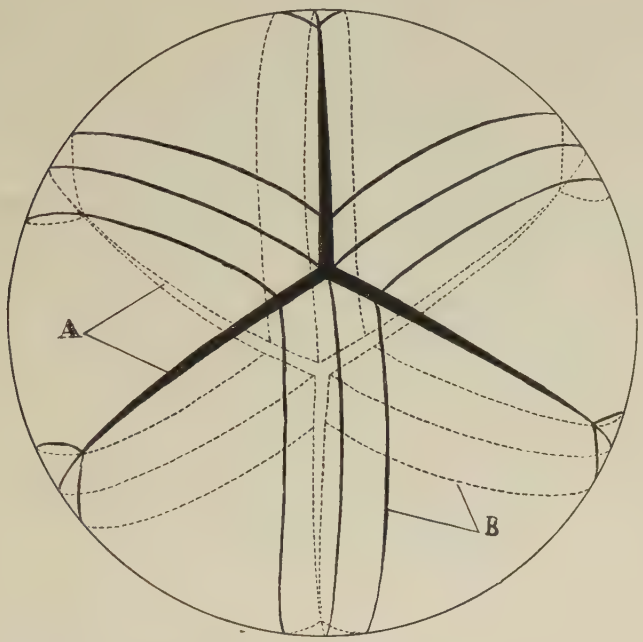

Course of the lens fibers: *A*, primary lens figures; *B*, lens fibers.

Nutrition.—The nutrition of the lens is derived from the ciliary processes. The nutrient fluids enter the lens through the capsule, principally at and near the equator, passing through the interfibrillar spaces.

Vitreous Body.—The vitreous body occupies about four-fifths of the interior of the eyeball, being in apposition anteriorly with the capsule of the crystalline lens and the suspensory ligament, and posteriorly with the membrana limitans interna of the retina and the optic disk. It is a transparent, semifluid or gelatinous mass, resembling a sphere flattened in its anteroposterior axis. At the anterior pole there is a depression, the patellar fossa, in which the posterior half of the crystalline lens is lodged.

The vitreous body, which is derived from the mesoblast (see Embryology), is, according to Virchow, gelatinous or mucoid connective tissue

resembling the jelly of Wharton of the umbilical cord. In the fetus the vitreous body contains a number of stellate connective-tissue cells, the bodies and branches of which form a delicate framework. In the vitreous body of the adult the cell bodies are imperfect, having undergone degeneration, but numerous very delicate fibrillæ, arranged more or less concentrically, apparently not anastomosing, traverse the vitreous body and furnish a very weak and delicate supporting structure, which serves to retain the fluid portions. At the periphery of the vitreous body, particularly in its anterior portion, the fibrillæ become much more numerous and are condensed next to the surface. This condensation

Fig. 39

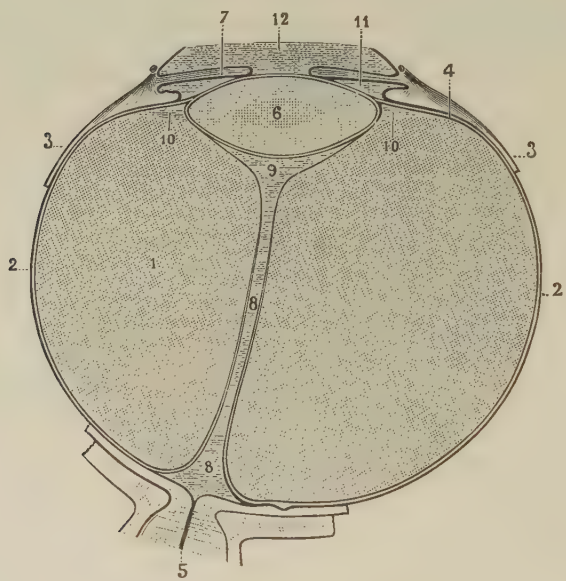

The vitreous body and hyaloid canal. (Schematic.) Horizontal section passing through the optic nerve: 1, vitreous body; 2, hyaloid membrane; 3, region of the ora serrata; 4, zone of Zinn or zonula; 5, optic nerve; 6, crystalline lens; 7, iris; 8, hyaloid canal with (8′) its extended posterior extremity (area Martegiani); 9, postlenticular space; 10, canal of Petit; 11, posterior chamber of the eye; 12, anterior chamber. (Testut.)

of the fibrillæ forms what is known as the limiting membrane of the vitreous body and, although it does not possess a double contour, has been termed the hyaloid membrane. The former site of the hyaloid artery is marked by a lymph channel, the *canal of Cloquet,* of small caliber, considerably broadened at the optic disk. This canal extends from the optic disk well forward into the vitreous, reaching the posterior pole of the lens in some cases. Its walls are formed by a condensation of the fibers of the vitreous body. There are few, if any, cellular elements.

The vitreous body is attached to the retina at the optic disk by the remnants of the hyaloid artery, to the retina by a number of delicate fibrillæ, and to the pars ciliaris retinæ by more numerous delicate fibrillæ.

A few rounded, stellate, and spindle-shaped cells are found in the vitreous body. These are most numerous in the vicinity of the disk and of the ora serrata.

The vitreous body is nourished from the vessels of the ciliary processes and, in less degree, from the vessels of the retina.

Retina.—The retina, the innermost of the three tunics of the eye, contains the light-perceiving elements. The portion bearing perceptive elements, ganglion cells, rods and cones, optic nerve fibers, etc., extends from the posterior pole of the eye forward to an irregular line (*ora serrata*) situated about at the union of the anterior with the middle third of the globe and a little farther anteriorly on the nasal than on the temporal side. The retina forms a complete membrane, except at the optic nerve entrance, where a circular opening, about 1.5 mm. in diameter, permits the passage of the optic nerve fibers. Beyond the ora serrata the non-perceptive elements of the retina continue to the margin of the iris. These parts have been described in the chapters on embryology and anatomy.

The retina measures 0.4 mm. in thickness near the optic nerve, and diminishes in thickness gradually toward the ora serrata, where it measures 0.2 mm. The retina is transparent, except throughout an area near the posterior pole (*macula lutea*), which surrounds the area of most acute perception (*fovea centralis*), where it presents a dull yellow tinge postmortem, and is termed the yellow spot, and, after the retina has been deprived of light, when a purplish tinge may be observed, due to the presence of the visual purple.

Structure.—When properly stained and viewed under the microscope, the retina presents ten distinct layers, and by special staining and bleaching processes the appearance of a fenestrated layer, described by Verhoeff,[1] may be developed. We may also see a thin differentiated layer in the outer part of the external recticular layer—*Henle's layer.*

The layers of the retina from within outward are:

1. Inner limiting membrane (membrana limitans interna).
2. Nerve-fiber layer.
3. Nuclear layer (large retinal neurons).
4. Inner reticular or plexiform layer.
5. Inner nuclear layer (layer of bipolar cells).
6. Outer reticular or plexiform layer.

6*a*. Henle's external fibrous layer.

7. Outer nuclear layer (bodies of the rods and cones.)
8. Outer limiting membrane (membrana limitans externa).
9. Layer of rods and cones.
10. Pigment layer.

10*a*. Fenestrated layer of Verhoeff.

Viewed by the microscope, the retina presents an appearance approximately as in Fig. 40, *A*, but in the light of the observation of Dogiel,[2]

[1] Boston Med. and Surg. Jour., October 22, 1903.

[2] Arch. f. Anat. u. Physiol., Anat. Abth., 1893, p. 426, and other papers.

Retzius, S. Ramón y Cajal,[1] the true composition of the retina may be schematically represented by Fig. 40, *B*.

By a study of these diagrams it will be seen that, according to Cajal, there is not only a path of communication from the rods and cones to the nerve fibers passing to the optic nerve, but fibers of intercommunication between the nervous cellular elements of the retina itself.

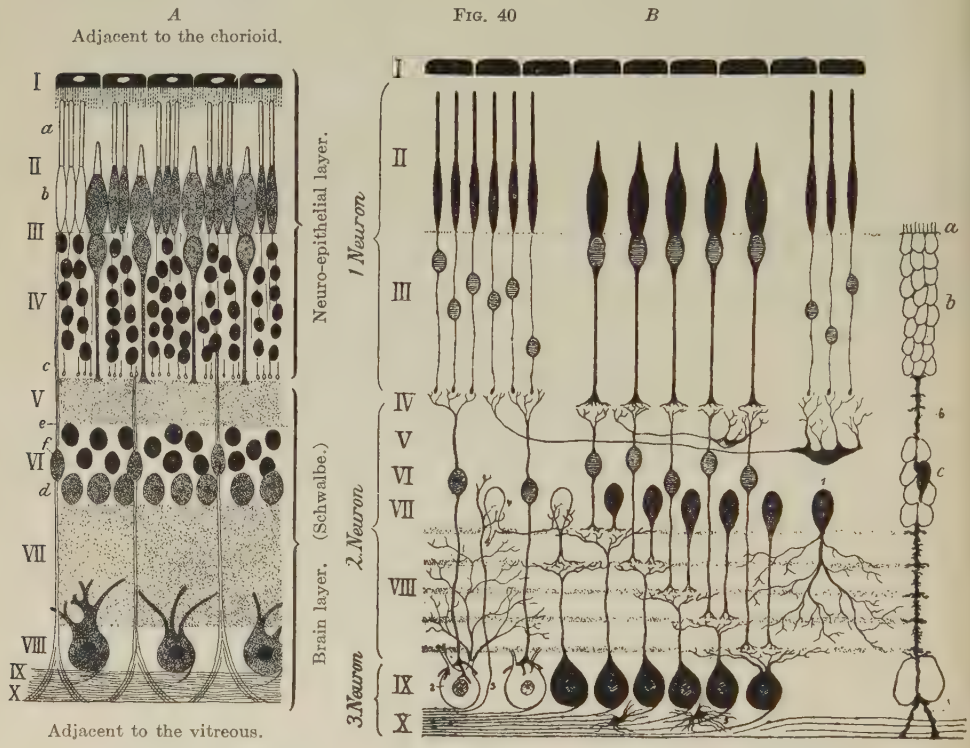

Scheme of the structure of the human retina. *A*. Horizontal section, hematoxylin stain: *I*, pigment epithelial layer; *II*, layer of rods and cones: *a*, external; *b*, internal elements; *III*, external limiting membrane; *IV*, external molecular layer: *c*, fiber layer (Henle's); *V*, external granular layer; *VI*, internal molecular layer: *d*, spongioblasts; *e*, supporting fibers of Müller; *f*, nuclei of the same; *VII*, internal granular layer; *VIII*, layer of ganglion cells; *IX*, nerve fiber layer; *X*, internal limiting membrane. *B*. Demonstration after the method of Golgi: *I*, pigment epithelial layer; *II*, layer of rods and cones; *III*, molecular and visual cells; *IV*, external plexiform layer; *V*, layer of horizontal cells; *VI*, layer of bipolar cells; *VII*, layer of amacrine cells; *VIII*, internal plexiform layer (fiber layers); *IX*, layer of ganglion cells; *X*, nerve fiber layer; 1, diffuse amacrine cells; 2, diffuse ganglion cells; 3, centrifugal nerve fibers; 4, association-amacrine cells; 5, neuroglia cells; 6, supporting fibers of Müller. (Posey and Wright.)

Müller's Fibers.—The framework or supporting structure of the retina is made up of fibers of irregular shape—Müller's fibers (Fig. 40).

Inner Limiting Membrane.—The inner limiting membrane is formed by the broadening out of the inner ends of Müller's fibers, and, when viewed from the surface, presents the appearance of a mosaic.

[1] Arch. f. Anat. u. Physiol., Anat. Abth., 1893, p, 400.

Nerve Fiber Layer.—The nerve fiber layer is composed of afferent and efferent nerve fibers which are not medullated, the fibers passing to the optic nerve being much more numerous than those passing from the optic nerve. This layer also contains a number of neuroglia cells, and in this layer the larger vessels of the retina are lodged.

Ganglion Cell Layer.—The ganglion cell layer is composed of large nerve cells or neurons, which measure 0.03 to 0.01 mm. in diameter. They possess protoplasmic processes, *dendrites*, which are directed

Fig. 41

Radiation of nerve fibers in retina: *N*, nasal; *T*, temporal. (Kölliker.)

outward and terminate in multiple short processes in the external plexiform layer, and a process, the axon, which forms the axis cylinder and passes into the nerve fiber layer and to the optic nerve. The ganglion cells are not connected with each other, but double ganglion cells, the twin ganglion cells of Graef, are met with. The physiological significance of this arrangement is not positively known.

Fig. 42

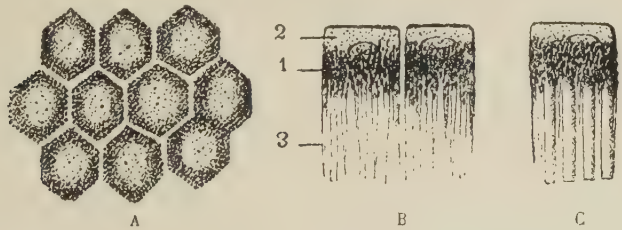

Pigment cells of retina: *A*, outer surface; *B*, profile view; 1, densely pigmented portion; 2, outer non-pigmented portion; 3, prolongations to enclose terminals of visual cells; *C*, a cell enclosing terminals of visual cells. (Testut after Shultze.)

Pigment Layer.—This layer is composed of a single layer of large pigmented cells flat on their outer surface, which is in apposition with the lamina vitrea of the chorioid. The cells measure 0.012 to 0.018 mm. in diameter, are usually hexagonal in outline, but many cells are found with five and some with four sides. One nucleus is

the rule. Some cells have two nuclei; such cells are larger than the mononuclear cells. The nuclei are placed at the centre of the cell near its outer surface. The inner surface of the pigment cells consists of delicate protoplasmic processes which extend along the distal ends

Fig. 43

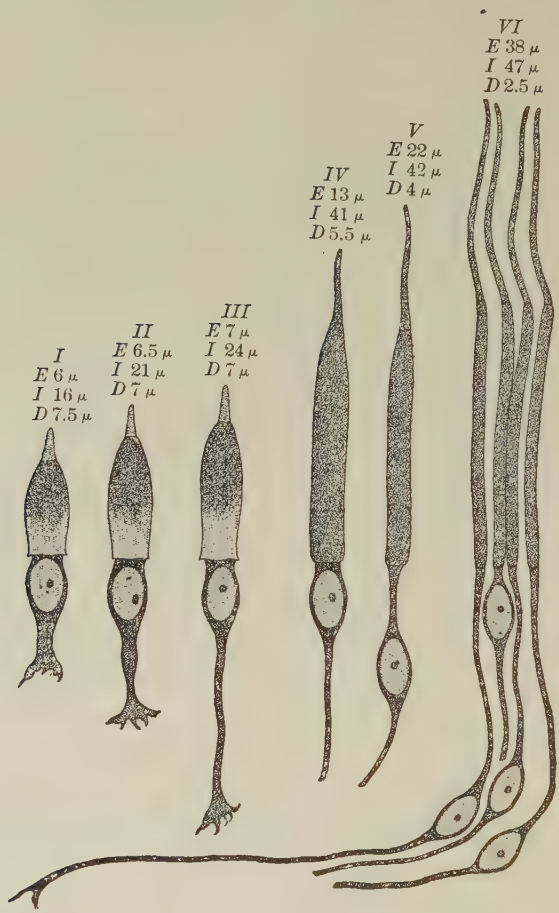

Cones in the different regions of the retina: *I*, near the ora serrata; *II*, at 3 mm. from the ora serrata; *III*, at an equal distance from the ora serrata and the papilla; *IV*, at the periphery of the fovea centralis; *V*, in the fovea centralis; *VI*, at the centre of the fovea centralis; *E*, length of the external segment; *I*, length of internal segment; *D*, diameter of the internal segment. (Poirier and Charpy.)

of the rods and cones (visual cells). In the spaces between these processes the outer ends of the visual cells are lodged, forming a more or less intimate connection between the two.

The pigment in the cells is composed of minute crystals, dark brown in color, termed *fuscin* by Kühne. It is derived from the coloring matter of the blood. If the retina is exposed to bright light, the pig-

ment granules advance along the protoplasmic processes and envelop the outer membranes of the visual cells. If the light is removed and the retina subjected to prolonged darkness, the pigment granules recede to the body of the cell. This displacement of pigment granules is due to the flow of fluids through the protoplasm of the cells and not to migration of the pigment granules themselves.

Fenestrated Layer of Verhoeff.—According to Verhoeff there is a delicate fenestrated membrane extending throughout the layer of pigmented cells. This membrane is identical in chemical reaction with the membrana limitans externa, and appears to be the product of the cells which project through it.

Neuro-epithelium or Visual Cells.—The rods and cones are really the terminal members only of cells whose bodies or nuclei are for the most part found within the fenestrated membrane formed by Müller's fibers and known as the external limiting membrane. Under the microscope the rods and cones, the membrana limitans externa, and the nuclei of the rods and cones form distinctly separate layers.

Rods and Cones.—This layer, which measures 0.06 mm. in thickness, embraces the terminal members of the visual cells, both of which are made up of two segments, an inner segment, larger in diameter than the outer, particularly in the cones, and differing in their chemical and refractive properties. The *rods* are approximately 0.06 mm. in length and 0.002 mm. in diameter. The outer segment is of uniform diameter, and with high power shows very fine longitudinal striations. Schultze is of the opinion that this part of the rod is built up of minute disks superimposed. A delicate investing membrane has been described (Kühne). The external segments of the *rods* contain the visual purple,[1] and are apparently its exclusive seat. The inner segment of the rod is slightly larger in diameter than the outer segment, is faintly striated, and slightly elliptical in shape. The inner portion of this segment of the rod is finely granular and presents the appearance of protoplasm. The rod is continued through the external limiting membrane in the form of a narrow protoplasmic column, the *rod fiber,* to the nucleus, the *rod granule,* lying in the external nuclear layer, and terminates in the outer reticular layer.

The cones consist each of an outer and an inner segment. The inner segment of the cone measures 0.0065 mm. at its greatest diameter. Its length is less than that of the inner segment of the rod. This segment of the cone is ellipsoidal rather than conical. The outer segment is about 0.002 mm. in diameter where it joins the inner segment. It gradually dimishes in size and terminates before reaching the length of the outer rod segment in all parts of the retina except at the fovea centralis.

The body of the cone lies within the external limiting membrane, and consists of the delicate rod of protoplasm, the cone fiber, and the nucleus or cone granule.

The relative proportion between rods and cones varies much in

[1] Boll, Arch. f. Anat. u. Physiol., Physiolog. Abth., 1877, and Kühne, Unterstich. a. d. Physiolog., Institut d. Univ. Heidelberg, 1877, i.

different parts of the retina. At the fovea centralis the entire area is made up of cones which are narrowed at the base and are longer than the cones in other parts. From the fovea centralis toward the ora serrata the cones gradually diminish in number and in length, and the rods increase in number. Near the ora serrata the cones are very few and widely scattered. The number of the cones in the adult human retina have been estimated by Krause[1] at 7,000,000, that of the rods at 130,000,000.

External Limiting Membrane.—Under the microscope this consists of a fine line lying between the layer of rods and cones and the external nuclear layer.

External Nuclear Layer.—The external nuclear layer is composed largely of the bodies of the *rod* and *cone* visual cells, with their contained nuclei. The outer portion of the *rod visual cell* is continuous with the protoplasm of the inner segment of the rod. The inner portion ends in a minute knob expansion which lies in the external reticular layer closely surrounded by the branching terminals of the bipolar nerve cells. The rod fiber presents numerous varicosities. The rod nuclei (granules) are found in all the strata of the external nuclear layer. They are much more numerous than the cone nuclei (granules) and form the greater part of the layer. (A nucleolus is described by some writers.)

The bodies of the *cone* visual cells also consist of cone fiber and nucleus. The cone fiber is broad at the base of the cone and the nucleus is found in the expanded fiber lying very near the membrana limitans externa. At times the nucleus lies outside of this layer. The cone fiber, after it leaves the nucleus, becomes very much attenuated on passing through the external nuclear layer; it ends in the outer stratum of the external reticular layer by an expanded base from which numerous fine processes are given off. These lie in close apposition with the end processes of the bipolar nerve cells. The nuclei of the cone cells contain nucleoli and do not possess the transverse striations which are seen in the rod granules.

Outer Reticular Layer.—This layer, 0.01 mm. in width, consists of a network of delicate fibers and includes the delicate processes from the cone fibers, the knob-like expansion from the rod fibers, the arborizations from the external ends of the bipolar nerve cells, the *horizontal* (basal or stellate) cells, and fine fibrillæ from Müller's fibers. The *horizontal* cells are divided into outer (smaller), and inner (larger) cells. They are regarded as true nerve cells, possessing dendrites and axons, and are concerned in "indirect conduction" in the retina.

Inner Nuclear Layer (layer of bipolar nerve cells).—This layer varies in thickness in different parts of the retina, measuring 0.035 mm. near the optic nerve entrance, and 0.018 mm. near the ora serrata. The layer consists principally of *bipolar nerve cells* of two varieties, one of which is closely related to the terminals of the *rod* visual cells and one to the terminals of the *cone* visual cells. These cells serve to form the connecting link between the rod and cone visual cells and the large ganglion cells of the retina.

[1] Handbuch d. menschlichen Anat., Band ii, 1879.

The cells consist of a central body containing a nucleus. From the body two principal processes are given off, an external axis-cylinder process, axon, and an internal protoplasmic process, a dendrite. The *rod* bipolars vary in size. The outer terminal breaks up into numerous fibrils in the outer plexiform layer, the larger ones embracing the terminals of a number of rods, the smaller ones, a very few rod terminals. The inner process is long, extends well through the inner plexiform layer, and breaks up into fibrils which embrace the ganglion cells. The *cone* bipolars are less numerous. The nuclei are found in all parts of the layer, but are most numerous in the outer stratum. The inner processes of the cone bipolars are not so long as those of the rod bipolars, but meet and interlace with fibrils from processes from the ganglion cells in the middle and outer strata of the internal plexiform layer. The external processes break up into terminal fibrils which interlace with the terminal fibrils of the cone visual cell. The inner nuclear layer also contains the cell bodies of the *spongioblasts* or amacrine cells, whose branches (dendrites) are found in the inner plexiform layer.

Inner Plexiform Layer.—This layer measures about 0.04 mm. in thickness. It is composed of numerous interlacing fibrillæ derived from the bipolar cells, the ganglion, the amacrine cells, and from Müller's fibers. Very small "interstitial" amacrine cells are also found in this layer. This layer can be differentiated into five zones.

Retinal Sustentacular Tissue.—The retinal sustentacular tissue is present in the retina in two forms: (1) as the fibers of Müller, and (2) as the spider cells. These are products of the ectoderm, and may be considered as neuroglia. Müller's fibers pass through the entire thickness of the retina to the layer of rods and cones. The expanded inner extremity of these fibers forms the membrana limitans interna. The trunk of the fiber may divide in the internal plexiform layer and proceed in two or more large branches through the nerve fiber layer to the internal limiting membrane. Many minute fibrillæ are given off in the inner plexiform layer. The nucleus of the fiber is found in the inner nuclear layer. Some fibrillæ are given off in the external plexiform layer, and in the outer nuclear layer plate-like processes closely envelop the bodies of the cone and rod visual cells. Minute processes, extending just beyond the external limiting membrane, are described by a number of observers. It is held by many that the *membrana limitans externa* is formed by the external ends of the fibers of Müller. Verhoeff is of the opinion that this membrane is formed by a cuticular concretion from the rod and cone cells. The fibers of Müller are present throughout the entire retina. They are particularly numerous near the ora serrata and at the macular region.

The spider cells or stellate neuroglia cells are small cells having numerous filiform processes. They are found almost exclusively in the nerve fiber layer and are most numerous where the nerve fiber layer is thickest, that is, at and near the optic nerve entrance. They are larger and more numerous in the optic nerve.

Regions of the retina that deserve special mention are the macula

lutea, containing the fovea centralis, the ora serrata, and the region of the optic nerve.

Macula Lutea (yellow spot).—If the retina is examined shortly after death, a small, almost circular spot will be observed situated to the temporal side and about 3 mm. from the optic nerve entrance (from centre of optic disk to centre of fovea, 3.9 mm., Landolt) and 1 mm. below the horizontal meridian of the optic disk. This spot is of a dusky yellow color, due to postmortem changes affecting the ganglion cell layer. The ganglion cells at this point are greatly augmented in number and are heaped up, forming a layer of 6 to 7 rows deep. During life the yellow tone is not present, but the region often presents a slightly deeper tone than that of the surrounding fundus. It presents a uniform appearance on account of the absence of blood-vessels large enough to be seen with the ophthalmoscope.

Fig. 44



Normal fovea centralis. Specimen prepared by J. E. Weeks. Photographed by George S. Dixon. × 300.

Fovea Centralis.—The fovea centralis occupies the centre of the macula lutea. It consists of a double, cone-like depression affecting the inner (*fovea interna*) surface of the retina and the external limiting membrane (*fovea externa*). The fovea is circular and is about 1.1 mm. in diameter at the upper border of the depression. At the margin of the fovea the retina is about 300 μ in thickness. At the centre of the fovea the retina is 100 μ in thickness. The cones which at the margin of the fovea have attained the length of the rods, 60 to 62 μ, increase to 85 μ at the centre of the fovea (Graefe), necessitating (as the pigment layer of the retina does not undergo a change of plane) a depression of the membrana limitans externa (fovea externa) of 25 μ. The depression of the membrana limitans interna is about 125 μ, which occurs at the expense of the nerve fiber layer (very greatly reduced in thickness), the ganglion cell and internal reticular (almost entirely), and the internal nuclear layers.

Ora Serrata.—The highly complex nervous elements of the retina terminate abruptly at the ora serrata, where the thickness of the retina is suddenly reduced from 0.2 to 0.04 mm. The retina is continued as the pars ciliaris retinæ, as heretofore described. Small cystic spaces are

Fig. 45

Distribution of retinal vessels. (Jaeger.)

Fig. 46

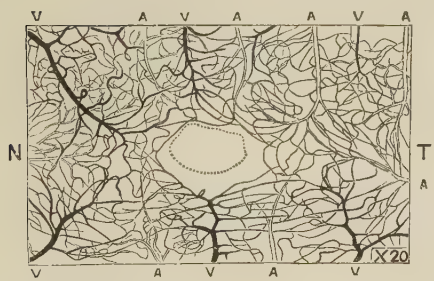

Bloodvessels of human retina at the yellow spot (artificial injection). The central gap corresponds to the fovea centralis: *A*, arteries; *V*, veins; *N*, nasal side (toward disk); T, temporal side. The meshes are many times wider at the periphery of the retina. (Nettleship.)

often observed in the retina near the ora serrata. These are looked upon as atrophic manifestations, and are most frequently seen in the retinæ of adults.

Vascular Supply.—*Arteries.*—The anterior layers of the retina are nourished by the blood supplied to the retina through the branches of

the arteria retinæ centralis (Fig. 45). The artery divides at or near the lamina cribrosa (sometimes a few millimeters back of the lamina cribrosa) into two principal branches, which, on reaching the disk,

Fig. 47

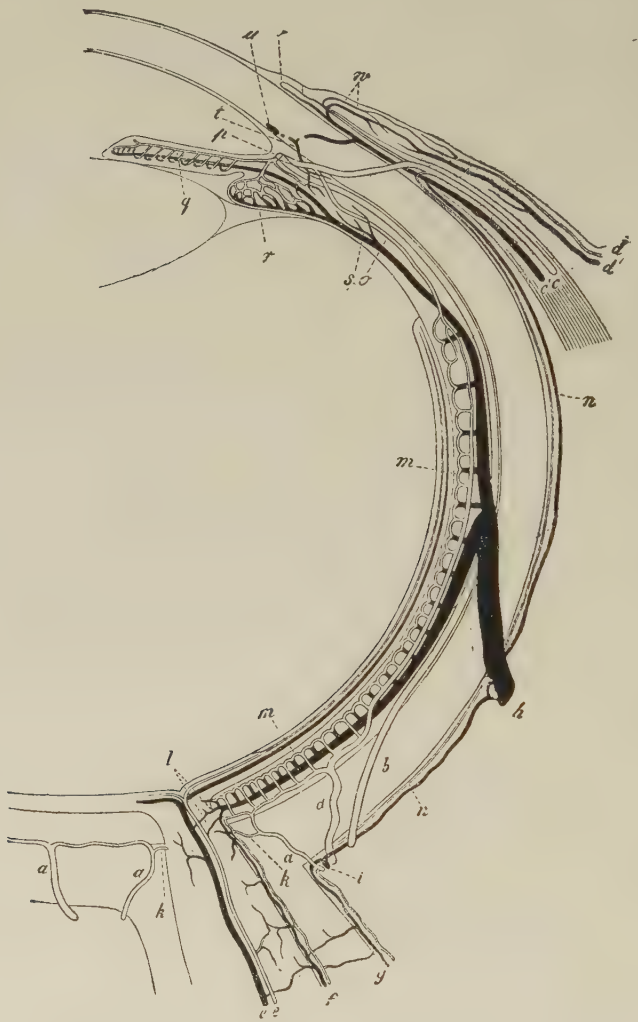

Diagram of a horizontal section of the circulation of the eye. The veins are made black and the arteries clear: *a*, *a*, *a*, *a*, represent the short ciliary arteries; *b*, a long ciliary artery; *c*, *c*, an anterior ciliary artery and vein; *d*, *d*, a posterior conjunctival artery and vein; *e*, *e*, the central retinal artery and vein; *f*, *g*, vessels of the inner and outer optic sheaths respectively; *h*, one of the vortex veins of the chorioid; *i*, a short ciliary vein; *k*, a branch of the vein which passes into the optic nerve; *l*, an anastomosis of the chorioidal veins with the central vein of the retina; *m*, *m*, the chorioidal capillaries; *n*, an episcleral branch; *o*, recurrent chorioidal artery; *p*, major arterial circle of the iris; *q*, vessels of the iris; *r*, vessels of the ciliary processes; *s*, venous branch passing from the ciliary muscle to the vortex vein; *t*, venous branch passing from the ciliary muscle to the anterior ciliary vein; *u*, venous plexus or circle; *v*, venous network at the corneal border. (Leber.)

pass one upward, and one downward, *superior* and *inferior papillary* branches. These subdivide, forming the *superior nasal* and *temporal* and the *inferior nasal* and *temporal* branches. These rapidly subdivide. Direct branches are given off from the papillary branches which pass mesially and temporally. Those which pass temporally are known as the macular arteries. The arteries and veins lie in the nerve fiber layer. The arteries rapidly subdivide and ultimately break up into capillaries through which the blood passes to the veins.

Two plexuses of capillaries are described, one situated in the ganglion cell layer and one in the inner nuclear layer. The capillaries do not pass beyond the internal nuclear layer as a rule; rarely a few are found in the external reticular layer; the author has observed them in a few specimens in the external nuclear layer. The macula is richly supplied with small vessels and capillaries, but at the fovea centralis, over an area of 0.151 sq. mm. (Mayerhausen), the retina is devoid of capillaries, this portion being nourished entirely from the choriocapillaris of the chorioid. Throughout the retina, the pigment layer, the visual cells, and the greater part of the external plexiform layer are nourished from the choriocapillaris. The blood-vessels of the retina are surrounded by delicate adventitious sheaths between which and the walls of the vessels there is a space, the perivascular lymph space.

The blood-vessels of the retina form a closed system. The arteries are "end arteries," not anastomosing with each other except through the capillaries. The veins also do not anastomose. The plugging of a principal arterial branch means atrophy and consequent loss of function to the part of the retina nourished by blood flowing through such branch.

Cilioretinal Branches.—Small arteries arising from the ciliary arteries and passing to the retina at the temporal side of the disk occur in quite a large number of cases. Of those examined by Lacy and Barrett,[1] 16.7 per cent.; by Veasey[2], 14 per cent. The vessels are small and usually extend toward the macula.

Lymphatics.—The lymph spaces of the retina are principally the perivascular lymph spaces which communicate with the extra-ocular lymph spaces by way of the arteria retinæ centralis. Injections beneath the pial sheath of the nerve have caused the injected fluid to pass between the pigment layer and the layer of rods and cones; also between the retina and the vitreous, and these spaces are considered to be lymph spaces.

Nerve Supply.—The *vasomotor nerves* to the retinal vessels are from the cervical sympathetic.

Optic Nerve.—The optic nerve extends from the eyeball to the optic chiasm. It is about 5 cm. in length in the adult. About 3.5 cm. lie within the orbit and 1.5 cm. in the optic canal and cranial cavity. A small portion of the optic nerve, about 1.25 mm., lies within the eyeball and may be termed the intra-ocular portion. The free end of the intra-ocular portion is known as the *papilla* or *disk*.

[1] R. L. O. Hosp. Rep., xii, 1, 59.

[2] Ann. of Ophth. and Otol., July, 1893.

The *nerve fibers* in the *intra-ocular portion* of the optic nerve are non-medullated. At the scleral opening, through which the nerve fibers pass,[1] the nerve measures approximately 1.5 mm. in diameter. The nerve fibers become medullated immediately back of the lamina cribrosa, where the optic nerve has the appearance of a round white cord and measures 5 mm. in diameter. The orbital portion of the optic nerve lies loosely in the orbital tissue, its disposition being such that the movements of the eyeball are unimpeded by it. In the optic foramen the nerve is closely surrounded by the bony wall, the ophthalmic artery (Plate IV), which lies on the ventral and lateral aspect of the nerve, being the only other structure to occupy that canal. The short intra-

Fig. 48

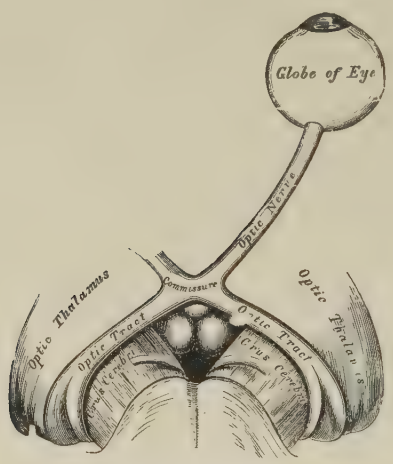

The left optic nerve and optic tracts. (Gray.)

cranial portion of the nerve lies on the body of the sphenoid just above the sphenoidal sinus, from which it is separated by a very thin shell of bone. The nerve fibers of the optic nerve are arranged in bundles, the bundles being held together by septa of connective tissue which proceed from the inner (pial) optic nerve sheath. The fibers of each bundle are supported and presumably partly insulated by neuroglia tissue, the nuclei of whose cells are readily seen with the microscope.

Sheaths.—The optic nerve possesses three sheaths.

Pial Sheath.—The first or inner sheath is closely adherent to the nerve, is thin and vascular. It is continuous with the pia mater of the brain, and is termed the *pial sheath.* From it the septa, which are composed of elastic and non-elastic fibrous tissue, and bear the blood-

[1] The tissue fibers that surround the optic disk have been studied by Nicolai (Annal. d'Ocul., cxxviii, p. 342), who believes that the Van Giesen stain and the trypsin reaction indicate that these fibers are unstriped muscle fibers. He distinguishes circular, longitudinal, and radial fibers, and terms them "musculus papillæ optici."

vessels necessary for the nutrition of the nerve, proceed. The pial sheath terminates at the sclera, some of its minute vessels anastomosing with those of the chorioid.

Dural Sheath.—The *third* or outer sheath is a thick layer of connective tissue, the dural sheath, continuous with the dura mater of the brain. Only a narrow space separates it from the optic nerve in the optic canal. It is here closely united with the periosteum. It loosely encases the optic nerve as far as the sclera, becoming incorporated in the tissue of the sclera, a thin outer layer going to Tenon's capsule. Between the dural and pial sheaths is a space, the *subvaginal space.*

Middle Sheath.—This space is divided by the second or middle sheath of the optic nerve, which is an extension of the arachnoid membrane of the brain. This is a thin, transparent membrane which is quite closely attached to the dural sheath and is loosely attached to the pial sheath by delicate bundles of connective tissue. The space between dura and arachnoid is the *dural space,* that between the arachnoid and pia the *subarachnoid space.* The surfaces of the walls of both of these spaces and the trabeculæ of connective tissue which connect the membranes are covered by endothelium. The spaces are lymph spaces and are in connection with the corresponding spaces in the cranial cavity. The subdural and subarachnoid spaces terminate at the sclera. It is thought that the subarachnoid space[1] is in connection with the lymph spaces in the head of the optic nerve. Distention of the subarachnoid space of the optic nerve sheath takes place in many cases of neuritis, depending on intracranial disease.

The sheath of the optic nerve and the optic nerve to its centre are pierced on the lower inner aspect, at a distance of 7 to 14 mm. back of the sclera, by a canal which gives passage to the arteria centralis retinæ and its accompanying vein. Minute branches are given off from the central artery in its passage through the nerve for the purpose of supplying nutrition to that part of the nerve.

Nerve Fibers.—The *nerve fibers* of the optic nerve vary much in size. The larger medullated nerve fibers vary in diameter from 0.001 to 0.014 mm. (Krause); the finest fibers are 0.0005 mm. The number of larger medullated fibers has been estimated by Salzer at 438,000. It is thought that the smaller fibers are at least as numerous, making approximately 1,000,000 nerve fibers in the optic nerve.

The course of the greater number of nerve fibers is centripetal. This has been definitely ascertained by embryological studies.[2] The location of fibers in the optic nerve which pass to specific parts of the retina may be indicated only in a general way. Except the fibers that proceed from the macular region (papillomacular bundle), whose course is definitely known, Parsons, from his investigations on monkeys, concludes that "the fibers derived from various parts of the retina outside of the macular region retain their relative position in the optic nerve,

[1] Schmidt-Rimpler, Arch. f. Ophth., 1869, p. 193.
[2] Froriep, Anat. Anzeiger, 1891, 6, p. 155.

i. e., temporal fibers remain external, nasal fibers internal. The temporal fibers tend toward the dorsal side as they approach the chiasm, the nasal toward the ventral side." The papillomacular bundle immediately back of the eye is located in the outer part of the nerve. It is wedge-shaped, the apex approaching the centre of the nerve. As it nears the optic foramen, the papillomacular bundle gains the centre of the nerve and becomes cylindrical as it passes from the foramen into the cranial cavity. Partial decussation takes place in the chiasm, where the bundle becomes much flattened. This fasciculus maintains its position in the centre of the tracts until the basal ganglia are reached.

Optic Chiasm. (*Optic Commissure*).—The optic chiasm is formed by the union of the optic tracts and optic nerves. It lies in the optic groove on the body of the sphenoid, separated from the sphenoidal sinus by a very thin plate of bone. The chiasm lies transversely. It is flattened

Fig. 49

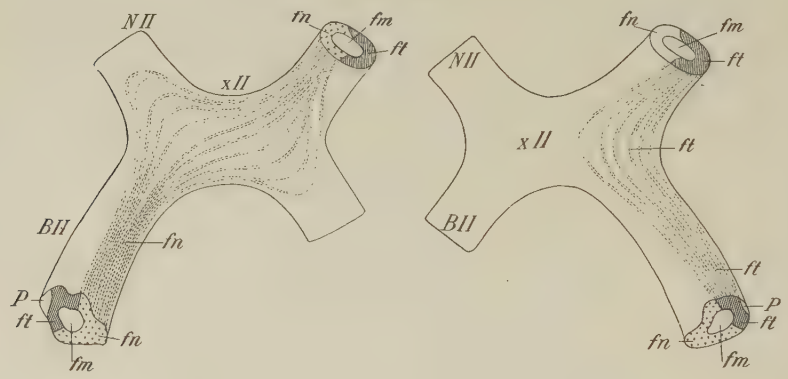

The relation in the optic nerves, optic chasm, and optic tracts of the fibers from the nasal half (*fn*), temporal half (*ft*), and central spot (*fm*) of the retina; *NII*, optic nerve; *BII*, optic tract; *xII*, optic decussation. The left figure shows the fibers which cross; the right figure shows those which do not cross; *P*, pupillary fibers. (Dejerine.)

above and below. Its lower central margin lies almost in contact with the infundibulum, the pituitary body being below and just posterior to it. The floor of the third ventricle lies upon it. Anteriorly it lies against the dura mater. The external angles of the chiasm are in quite close relation to the internal carotid arteries. It is covered by the pia mater and arachnoid, except where it comes in contact with the floor of the third ventricle. The decussating fibers in the chiasm occupy its middle portion; the non-decussating fibers the lateral portions. At the anterior border of the chiasm a small fasciculus of fibers passes from one optic nerve to the other, the inter-retinal fibers. These fibers have no relation to the optic tracts.

At the posterior border of the chiasm a small fasciculus of fibers passes from one side to the other. These are commissural fibers (the commissure of Meynert and Von Gudden) belonging to the brain, and not to the optic apparatus. The theory of crossed and uncrossed fibers

was first formulated by Newton;[1] it presupposed that the images formed on "corresponding retinal points" are elaborated and recognized by a corresponding cortical centre in the brain. In all animals in which the

FIG. 50

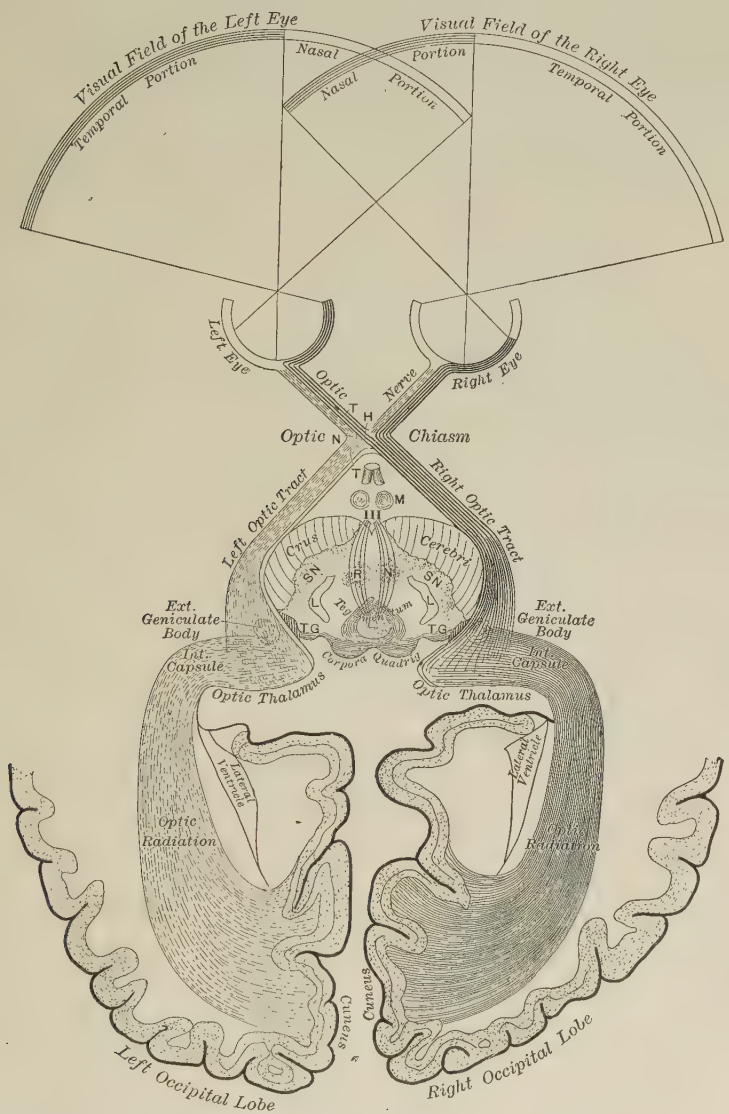

The visual tract. The result of a lesion anywhere between the chiasm and the cuneus is to produce homonymous hemianopsia: *H*, lesion at chiasm causing bilateral temporal hemianopsia; *N*, lesion at chiasm causing unilateral nasal hemianopsia; *T*, lesion at chiasm causing unilateral temporal hemianopsia; *S N*, substantia nigra of crus; *L*, lemniscus in crus; *R N*, red nucleus; *III*, third nerves. Macular bundles not shown. (Starr.)

[1] Newton's Optics, Qu. 15.

fields of vision overlap (a portion of one field common to the other), binocular single vision occurs. In all animals in which the field of vision in one eye is independent of that of the other eye (fishes, birds, etc.), only crossed nerve fibers have been observed. The number of uncrossed optic nerve fibers is in direct proportion to the area of the field of binocular single vision (area of the field of vision common to both eyes). In man the proportion of crossed to uncrossed nerve fibers is as 3 to 2.

Optic Tracts.—The optic nerve fibers, after leaving the chiasm, proceed to the basal ganglia by way of the optic tracts. The optic tracts are somewhat flattened, lie on the under surface of the brain, diverge and bend around the crura cerebri, and pass to the basal ganglia ("primary subcortical optical centres"), the external geniculate bodies, the

Fig. 51

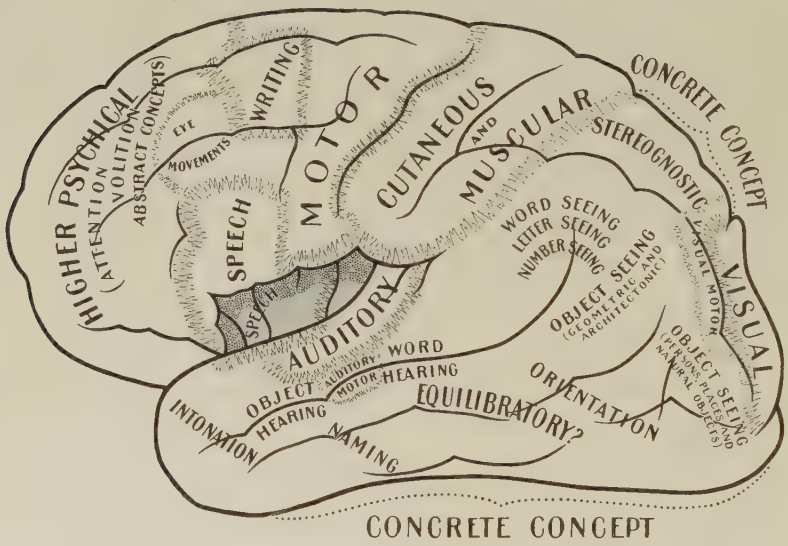

Side view of the human brain, showing localization of functions. (Charles K. Mills.)

anterior corpora quadrigemina, and the posterior portion (pulvinar) of the optic thalami. The external geniculate bodies are the most important visual ganglia. A fasciculus passes to the sphincter and accommodation group of cells of the nucleus of the third (St. Bernheimer) just before the centripetal fibers in the tract reach the external geniculate body. This is the optic-nerve portion of the *pupillary reflex arc.* The ends of the fibers passing to the basal ganglia become arborescent and apparently terminate in close proximity to neurons, whose axions pass into the posterior part of the internal capsule and reach the cortical visual area; there they break up into brush-like terminals, which are closely associated with the ganglion cells of the cortex. Visual impulses, conducted along the tract described, cause excitation of the neurons of the cortex, producing the phenomenon of vision.

Cortical Visual Area.—The observations and investigations of Henschen[1] led him to conclude that the really essential part of the visual area is the region of the calcarine fissure.

This is quite conclusively proved by the case which he has illustrated and described. He has demonstrated the fact that the nerve fibers of the visual tract lie near the posterior margin of the internal capsule and are associated in a more or less compact bundle, which runs nearly horizontally at the level of the second temporal convolution. The upper part of this bundle passes to the cortex at the upper margin of the calcarine fissure, the lower part to the cortex at the lower margin of the calcarine fissure. The fibers of the upper part correspond to the

Fig. 52

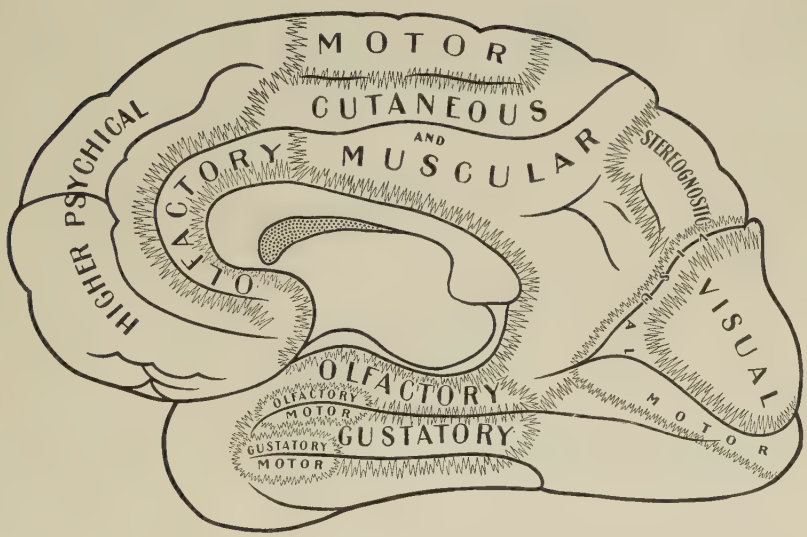

View of the mesial surface of the human brain, showing localization of functions. (Charles K. Mills.)

upper part of the retina, the lower to the lower part of the retina. It is probable that the macular portion of the cortical visual centre lies at the bottom of the calcarine fissure anteriorly, the periphery of the retina more posteriorly. Both cortical centres supply each macula, but with the exception of the maculæ each cortical centre supplies its corresponding half of each retina only. "The elements of the crossed and direct fibers lie close together in the cortex." The convolutions of the outer convex surface of the occipital lobe immediately above the cuneus is the location of the visual memory centre where visual impressions are received and stored up.

[1] Klin. u. Anat. Beiträge z. Path. d. Geh. Upsala, 1892.

CHAPTER III.

GENERAL PRINCIPLES OF OPTICS.

By WILLIAM NORWOOD SOUTER, M.D.

Light is that form of energy which, by its action on the retina, produces the consciousness of vision. The study of the laws of light constitutes the science of optics. The general principles of this science must be briefly considered in order that the ordinary phenomena of vision may be properly understood.

A substance which has the property of originating or emitting light is said to be *luminous*. A body which does not originate light, but which becomes visible only by reflection of light from some other source, is *non-luminous*.

The question as to how light is transmitted from a luminous body to other bodies and to the eye has given rise to much discussion among scientists. The general belief is that it is conveyed by wave motion which travels with great rapidity through a tenuous medium existing throughout space. This supposititious medium is called *ether*.

The various colors of which light is composed—*the colors of the spectrum*—are due to the variation in wave length. *Red* is the color of greatest wave length and least rapidity of vibration, and *violet* is the color of least wave length and greatest rapidity of vibration.

For practical purposes we may assume that light consists of *rays* which are given off from luminous bodies in all directions, and which travel in homogeneous media in straight lines. These rays are the radii of the spherical waves which are set in motion by luminous bodies.

A small sector of a spherical wave is called a *pencil of light*.

When the luminous point is remote the rays of a small pencil are very nearly parallel. Such rays as enter the eye from any point may be regarded as parallel when the point is not less than six meters or twenty feet from the eye.

When rays of light travelling through a medium impinge upon the surface of a second substance, which differs in density from the first, the behavior of the light varies with the nature of the second substance. If this is *transparent* some of the light may enter it, but with a change of direction. Such light is said to be *refracted*. Another portion may be *reflected* or turned back into the first medium. These two portions may make up the whole of the wave, but usually there is a third portion which is *absorbed*, or changed into some other form of energy.

If, on the other hand, the second substance is *opaque*, none of the light passes through it. A portion of the incident wave is reflected, and the remainder is absorbed.

Law of Refraction.—When light, having passed through one medium, enters a second medium whose density is greater than that of the first, any ray which meets the separating surface obliquely is refracted or bent *toward* the normal to this surface, but the ray which meets the surface perpendicularly undergoes no change of direction (Fig. 53). When the second medium is rarer than the first, the opposite condition prevails; that is, the oblique rays are refracted *away* from the normal. Refraction is a consequence of the wave motion of light. The degree of refraction which a ray undergoes depends upon the obliquity of the ray, being greater as the obliquity is greater, and upon the difference in density of the two media.

The relative density—or, to be more exact, the relative power of the substances to retard the progress of light—constitutes the *refractive index.*

Fig. 53

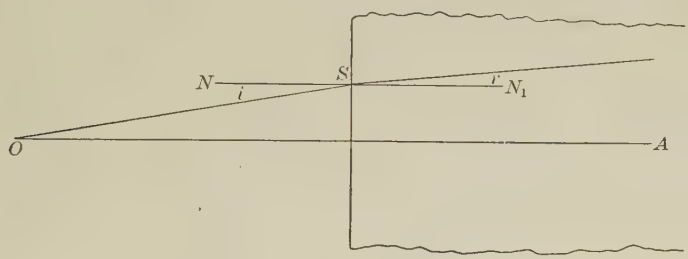

Illustrating the law of refraction.

The angle formed by the incident ray with the normal to the surface is called the *angle of incidence* (i, Fig. 53). The angle formed by the refracted ray with the normal to the surface, is called the *angle of refraction* (r, Fig. 53).

The index of refraction is determined by dividing the sine of the angle of incidence by the sine of the angle of refraction. The index is usually expressed by the letter n. Therefore, $n = \frac{\sin. i}{\sin. r}$.

Passage of Light through a Body with Parallel Plane Surfaces.—When light passes through a medium bounded by parallel plane surfaces, and reënters the original medium, the deviation of any ray which occurs at the first surface is exactly neutralized by that which occurs at the second surface, for the angle of incidence at the first surface is equal to the angle of refraction at the second surface (Fig. 54). Hence the final direction of any ray which passes through such a body is the same as the initial direction; but there is a lateral displacement which varies with the thickness of the plate.

Prisms.—An optical prism is a portion of a medium bounded by two plane faces meeting in an edge or *apex.* The thick side opposite the edge is called the *base* of the prism. Rays of light passing through a prism whose index is greater than that of the surrounding medium are always deflected *away from the apex of the prism.* It can be proved

that the least amount of deviation occurs when the angles of incidence and emergence are equal. The rays which are so situated that these two angles are equal are called rays of *minimum deviati n.*

It is apparent (Fig. 55) that rays which are parallel before their entrance into a prism will also be parallel after their emergence; but

Fig. 54

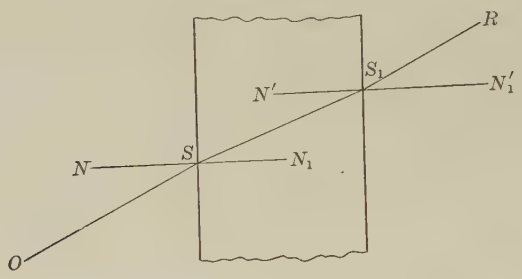

Refraction through a plate with parallel surfaces.

when rays diverge from a point near the prism, the angles of incidence of the various rays will be unequal, and those rays which lie more remote from the position of minimum deviation will be more refracted than those which lie near this position. Hence the relative divergence of rays is altered by the action of a prism.[1]

Fig. 55

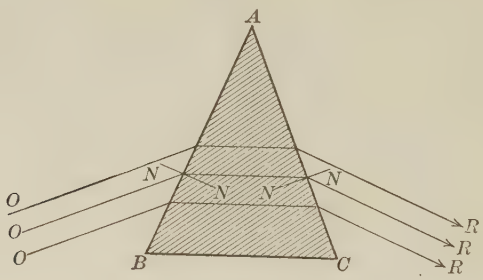

Refraction of parallel rays by a prism.

Numeration of Prisms.—Several methods of numbering prisms are in use. The old method consists in designating the prism according to the *refracting angle*, which is the angle included between the two refracting surfaces. In prisms of glass the minimum deviation for weak

[1] In the direction parallel to the edge of the prism the two faces are parallel, and since the relative direction of rays is unaffected in the passage through a plate with parallel faces, the divergence is unaffected in this direction. Therefore the divergence of rays proceeding from a point is not the same after passing through a prism on section parallel to the edge as on section perpendicular to the edge. The pencil of rays will thus have lost its homocentric character, having been rendered asymmetric by the prism. This effect of prisms is, however, too complicated to be studied in this connection; furthermore, in the weak prisms used in ophthalmology it is not of material moment.

prisms, such as are used in ophthalmology, is about one-half of the refracting angle, so that a prism whose refracting angle is 2 degrees effects a minimum deviation of about 1 degree. In this method the prisms are numbered with the ordinary degree marking: Pr. 1°, 2°, etc.

In the second method of numeration the prisms are numbered according to the minimum deviation which they produce. The number of a prism in this system is therefore about one-half of the number of the same prism in the first system. A small letter *d*, above and to the right of the number, is used to express the deviating power: Pr. 1^d, 2^d, etc.

The prism dioptre denotes the strength of the prism which deviates a standard ray $\frac{1}{100}$ of a meter (tangentially) at a distance of 1 meter, or $\frac{2}{100}$ of a meter at a distance of 2 meters, etc. This system has been adopted by the principal optical manufacturers of America, and it is therefore coming into general use. The Greek letter $\triangle$ is used as the symbol of the prism dioptre: Pr. $1^{\triangle}$, $2^{\triangle}$, etc. When the prisms are made of glass whose index is about 1.52, the number of prism dioptres in any prism is practically the same as the number of degrees in the refracting angle system, so that the units in these two systems differ chiefly in nomenclature.

The *centrad* differs from the prism dioptre in that the former expresses the deviation in hundredths of the radius as measured on an arc, while in the dioptric system the deviation is measured on the tangent of the arc. The difference between the two is very slight in the prisms used in ophthalmology.

The metre angle denotes the angular deviation which the visual line of each eye undergoes in turning from the primary position (straight forward) in order that the eyes may converge to a point in the median line and 1 meter distant. As this angle varies with the interocular distance, it is unsuitable for numbering prisms, though it is very useful in the measurement of convergence.

Fig. 56

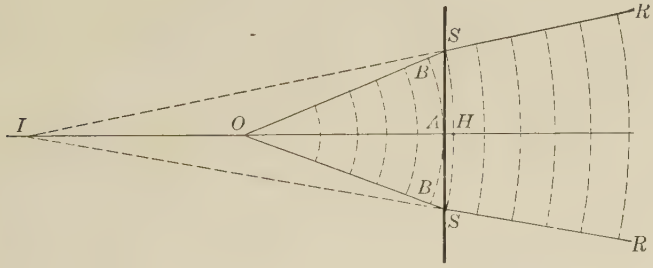

Refraction of Divergent Rays at a Plane Surface.—In Fig. 56, *SOS* represents a section of a spherical pencil of light which enters the dense substance at the plane surface *SS*. That part of the light-wave which travels along *OA* meets the surface sooner than that which travels along *OB*. While the latter is travelling the distance *BS*, the ray *OA* advances to *H* in the dense medium. It is necessary in the explanation

of refraction to assume that the velocity of light is less in dense than in rare media—an assumption which is corroborated by experiment. Since, then, the rate of propagation is less in the dense than in the rare medium, AH is less than BS, so that the wave front after refraction is represented by the curved line SHS. If this line is the arc of a circle its centre does not lie at O, but at some point, I, farther from the surface than O. Mathematical demonstration proves that SHS is not strictly circular, yet it is so nearly so that for small pencils it may be assumed to be the arc of a circle whose centre is at I. Since light appears to advance in the direction of the rays, at right angles to the wave front, it is apparent that the ray OA undergoes no refraction, while any other ray, as OS, is refracted so as to appear as the ray ISR, that is, as we have already learned, the oblique rays are refracted *toward* the normal to the surface.

If the second medium is rarer than the first, we have the opposite condition to that described: the convexity of the wave front, or, the divergence of the rays is increased by the refraction.

Thus, we see that the *divergence* of rays is altered by refraction at a single plane surface. But when the point (O) of origin of the light is very remote in comparison with the size of the pencil, that is, when the rays may be regarded as parallel to OA, there is no refraction.

Fig. 57

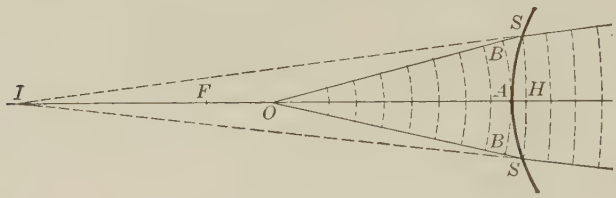

Refraction at a Spherical Surface.—When the divergent rays pass from a rarer to a denser medium at a convex (spherical) surface, the condition is similar to that just described except that the flattening of the wave is greater, and it is greater as the convexity of the surface is greater (Fig. 57).

In refraction at a plane surface, rays diverging from a point always remain divergent, but in refraction at a convex surface, rays which before refraction diverge from a point may be rendered parallel by the refraction (Fig. 58), or they may even be rendered convergent (Fig. 59), so as to be concentrated at a point (I).

Since the path of the rays may be reversed, these diagrams serve also to illustrate the refraction which occurs in the passage of light from a *denser* to a *rarer* medium at a *concave* surface.

On the other hand, in the passage of light from a *rarer* to a *denser* medium at a *concave* surface or from a *denser* to a *rarer* medium at a *convex* surface, the convexity of the wave front, or the divergence of the rays is increased.

Foci.—The point from which the rays proceed before refraction is the *anterior* focus; that at which they meet after refraction is the *posterior* focus. The two foci together are called *conjugate foci.* In Fig. 59 all the rays from O are concentrated at I, which is, therefore, a brightly illuminated point; it constitutes a *real focus.* In Fig. 57 the refracted

Fig. 58

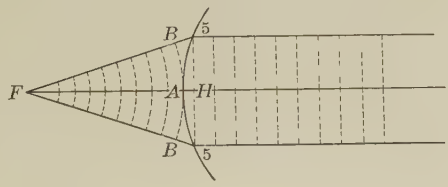

rays do not actually meet at I, but their direction is such that they appear to have passed through this point, which accordingly is called a *virtual* or *imaginary* focus.

The point at which parallel rays are brought to a focus is called the *posterior principal* focus (Fig. 60). The point from which rays

Fig. 59

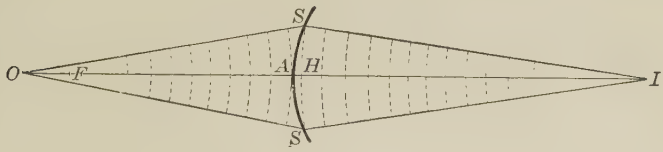

must proceed in order that they may be parallel after refraction is the *anterior principal* focus (F, Fig. 58).

The focus which is conjugate to any point nearer than infinity (that is, the focus for divergent rays) always lies farther from the surface than the principal focus, and it approaches this focus as the point

Fig. 60

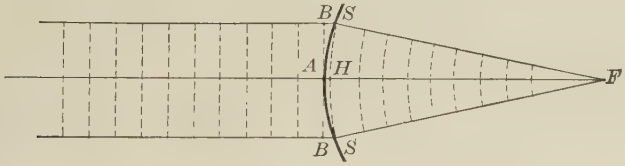

recedes to a greater distance from the surface. On the other hand, when the rays are already converging (the point of origin being, mathematically beyond infinity, or negative), the focus to which they will converge after refraction lies between the principal focus and the surface (I, Fig. 61).

Formation of Images by Refraction.—In Fig. 62, A is the refracting surface whose centre is at C. The point I is conjugate to O; similarly I_1 is conjugate to O_1, and I_2 to O_2, and so on for intermediate points. Therefore, $I_1\ I\ I_2$ constitutes an image of $O_1\ O\ O_2$.

The unrefracted rays, $O\ I$, $O_1\ I_1$, and $O_2\ I_2$, all passing through the center C, are called *axes*. The centre C is called the *nodal point*.

Fig. 61

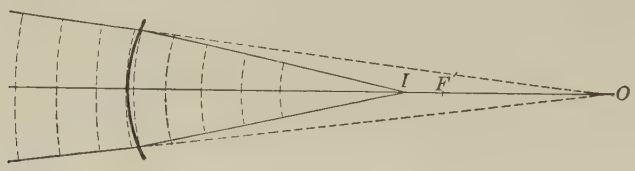

Fig. 62

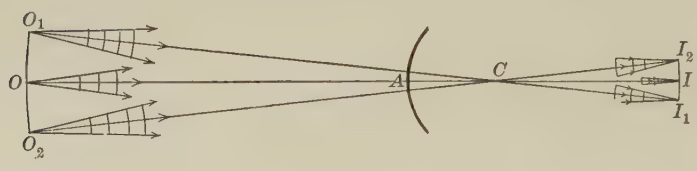

Aberration.—It is only when small pencils of light are isolated that we may assume that all the rays meet in their conjugate foci after refraction at a spherical surface. When a large sector of the wave passes into the second medium the angles of incidence of the rays increase so rapidly, as the distance from the axis increases, that the more peripheral rays are refracted too much in proportion to the central rays, so that the sharpness of the focus is marred. This constitutes *spherical aberration.*

Chromatic Aberration.—This results from the fact that the various colors are not equally refracted. The refraction increases as the wave length diminishes. Violet is, therefore, the color of greatest, and red is the color of least, refraction.

Lenses.—A lens is defined as a portion of refracting material bounded by one curved and one plane surface, or by two curved surfaces.

Classification.—Lenses are classified (Fig. 63) as (1) *plano-convex*, (2) *biconvex*, (3) *concavo-convex* and (4) *convexo-concave*, (5) *plano-concave*, and (6) *biconcave.* Concavo-convex and convexo-concave lenses are also called *menisci.* In ophthalmology they are more frequently called *periscopic lenses*, because when the concave side is placed toward the eye they afford a more extensive field of view than do lenses of other forms.

Lenses are also classified as *symmetrical* or *spherical*, and *asymmetrical—cylindrical* and *toric.* The latter class will be considered in connection with astigmia of the eye. We devote our attention for the present to spherical lenses.

Since lenses are made of glass whose density is greater than the density

of the surrounding air, it is evident, from our study of refraction at spherical surfaces, that plano-convex and biconvex lenses increase convergence or diminish divergence. They are called *collective lenses.* On the other hand, plano-concave and biconcave lenses diminish convergence or increase divergence. These are *dispersive lenses.* Periscopic lenses or menisci are collective or dispersive according as the convex or the concave side has the greater curvature.

Fig. 63

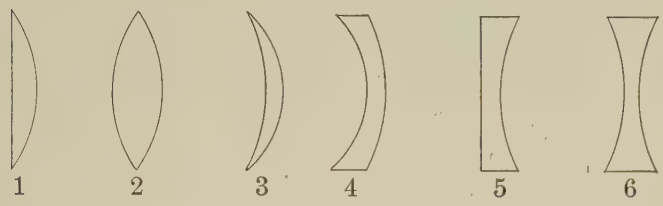

Foci of Lenses.—The foci of a lens are analogous to the foci of a single refracting surface, but there are two surfaces of the lens, and there can be only one straight line or axis which is perpendicular to both surfaces. This line is the *primary optic axis* of the lens. The foci lie on this axis. The *anterior principal focus* is the point on the optic axis from which rays must proceed in order that they may be parallel to the axis after passing through the lens. The *posterior principal focus* is the point on the axis where rays which are parallel to the axis before refraction are focused after passing through the lens.

The two principal foci are equally distant from the lens, and the distance from either focus to the lens is the *focal length* of the lens.

Fig. 64

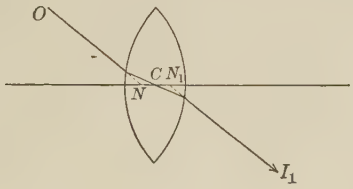

Cardinal Points of Lenses.—In refraction at a single surface, all rays which pass through the geometrical centre of the surface are unrefracted, but in a lens the only unrefracted ray is that which is perpendicular to both surfaces. There are, however, other rays which undergo no change of direction in passing through the lens. In Fig. 64, OCI_1 represents such a ray. Before entering the lens it is directed toward the point N on the optic axis; it is so refracted as to pass through C, and after refraction again at the second surface it proceeds in a direction N_1I_1, parallel to ON—*because at the points where the ray enters and*

leaves the lens the two surfaces are parallel. The points N and N_1 on the axis, toward which the ray is directed before retraction and from which it appears to proceed after leaving the lens, are called the *nodal points.*

In ophthalmological lenses the thickness is so slight as compared with the focal length that the distances between CN and CN_1 are inappreciable, and we may regard the two nodal points as merged in a single nodal point or *optic centre* at the centre of the lens.

Rays which pass through the lens without deviation are called *secondary axes.*

The two principal foci and the nodal point are the *cardinal points* of a lens, because when the positions of these points are known the image of an object can be constructed (Fig. 65).

Fig. 65

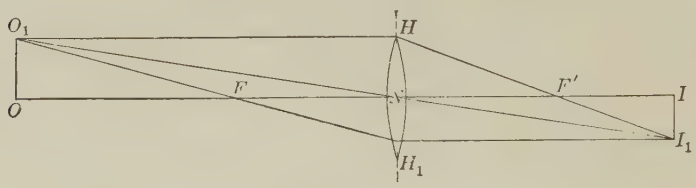

Images in Lens Refraction.—Although in the strictest sense the foci of a lens must lie on the primary axis, we may yet assume with approximate accuracy that a point on a secondary axis, not much removed from the primary axis, has a conjugate focus on this secondary axis, and that each point of a small object which is perpendicular to the primary axis will have a corresponding focus on a secondary axis. The object will, therefore, be reproduced in an image, which will also be perpendicular to the primary axis.

In refraction by convex or collective lenses a real inverted image of an object will be formed *when the object is more remote from the lens than the principal focus* (Fig. 65).

When the object is at one principal focus, the rays will be parallel after refraction, and no finite image will be formed.

When the object is infinitely distant (that is, so far that the rays may be regarded as parallel), the image is formed at the principal focus.

When the object lies within the principal focus, the rays will be still divergent after refraction and no image will be formed, *but the points where the rays meet on backward prolongation constitute the virtual image.*

When the rays are already convergent before entering the lens, their convergence is increased and a real image is formed between the lens and the principal focus.

In refraction by dispersive lenses no image can be formed unless the rays have been rendered convergent by previous refraction to such a degree as to overcome the dispersive effect of the lens.

In dispersive refraction rays which are parallel to the axis before meeting the lens are rendered divergent and leave the lens as if they

proceeded from F' (Fig. 66). Therefore, F' is one principal focus of the lens. Similarly, rays which are directed toward F (Fig. 67) are rendered parallel by the lens, and F is the other principal focus. Rays which proceed from a point O (Fig. 68) have their divergence increased by the lens and appear to proceed from I, which is therefore the virtual focus, conjugate to O.

Fig. 66

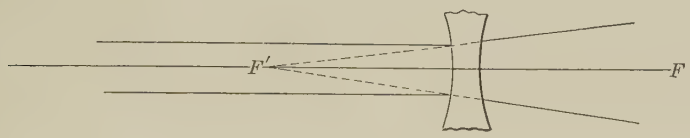

Fig. 67

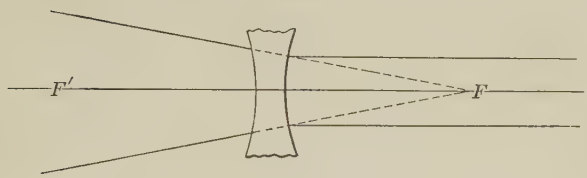

Fig. 68

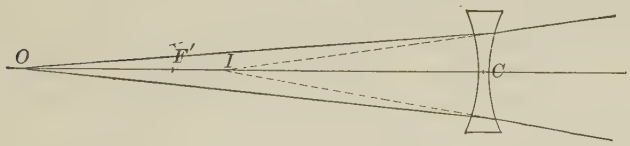

Numeration of Lenses.—Lenses are numbered according to their focal length or to their refractive power, the latter being inversely proportional to the former. If F expresses the focal length of a lens, $\frac{1}{F}$ expresses its refractive power.

In the inch system the unit lens has a focal length of 1 inch, and its power is expressed by the number 1. The power of a 10-inch lens is expressed by $\frac{1}{10}$. A serious disadvantage of this system in ophthalmology is that as all the lenses commonly used have a greater focal length than the unit lens, the refractive power must always be expressed by a fraction. Thus, if we wish to find the equivalent of a 20-inch lens combined with a 30-inch lens, we must add the fractions $\frac{1}{20}+\frac{1}{30}=\frac{5}{60}=\frac{1}{12}$. The equivalent is therefore a 12-inch lens. Another objection is that the "inch" differs in length in various countries; thus, the French and the German inch are longer than the English inch.

To overcome these inconveniences, the metric system was introduced. In this system the unit lens has a focal length of one meter, and the power of this lens is called a *dioptre*. A lens having a focal length of $\frac{1}{2}$ meter has a power of 2 dioptres (2 D.); a lens having a focal length of $\frac{1}{3}$ meter has a power of 3 D., etc. Fractional powers are expressed decimally; 0.25 D. expresses the power of a lens having a focal length of

4 meters, and 0.50 D. is the power of a lens having a focal length of 2 meters, etc.

The dioptric system has entirely displaced the old method in ophthalmology, yet it is sometimes desirable to transform the lens number from one system to the other. The meter is approximately equal to 40 (39.4) English or 36 Paris inches, and consequently the focal length as expressed in inches will contain 40 or 36 times as many units as in meters, according as the English or Paris inch is used. Thus, a lens of 3 D., having a focal length of $\frac{1}{3}$ meter, will have a focal length of $\frac{40}{3}$ in English inches; that is, a lens of 3 D. corresponds approximately with a 13-inch English lens, or to a 12-inch ($\frac{36}{3}$) French lens.

Conversely, the dioptric power is obtained by dividing 40 (or 36) by the lens number as expressed in inches.

Determination of the Power and Centre of a Lens.—The common method of ascertaining the power of a lens is by neutralization. If we hold a convex lens in front of one eye and look through it at a distant object, the object will appear more or less blurred according to the strength of the lens. If the optic centre lies in the line of vision, a vertical line, such as the edge of a test card, will not appear displaced, but as the lens is moved to the right the line will appear to move to the left, and *vice versa*. This is because of the prismatic action of the lens; the convex lens, being thickest in the centre, deviates the rays toward the periphery of the lens, which corresponds to the apex of the prism. On the other hand, if a concave lens is selected, the movement is in the same direction as the movement of the lens. By selecting from the case of trial lenses that lens which annuls this lateral deviation, we neutralize the refractive power of the lens. *The lens whose power is sought is of the same denomination but of opposite sign to that which produces this effect.*

To determine the position of the centre of the lens, we look at a straight line through the lens, and observe the position in which there is no break in the straight line, as seen through the lens and beyond its borders. Marking the points where this line appears to cut the lens, we connect these points by a straight line drawn in ink. Repeating this process in another meridian, we have two lines passing through the centre, and their point of intersection marks the centre.

The Eye as a Refractive Apparatus.—In passing through the dioptric media of the eye, light undergoes several refractions. The cornea, which first receives the rays from an object, is a convex, approximately spherical surface whose radius is about 8 mm., and the corneal tissue is of greater density (index 1.377[1]) than the air. The effect of this refraction is therefore collective. At the posterior corneal surface the rays pass into the aqueous humor (index 1.337) whose density is less than that of the cornea. As this surface is also convex to incident rays, while they pass from a denser to a rarer medium, the effect of this refraction is divergent. This divergence is, however, slight, and we

[1] The refractive index of each of these media as here given is the *absolute* index; that is, the index with reference to the ether of space, or, what is practically the same, with reference to air.

may regard the cornea and aqueous humor as a common medium. The rays next pass into the crystalline lens. This is a biconvex lens (index 1.437) whose anterior surface has an average radius of curvature of 10 mm., and the posterior surface a radius of 6 mm. The index of the vitreous is the same as that of the aqueous. The convergence of rays is therefore increased in passing through this lens.

It is apparent, therefore, that the combination of the cornea and the crystalline lens affords a strongly convergent refracting system, so that rays of light from an external object will be focused at some point not remote from the posterior surface of the crystalline lens. By mathematical calculation it is shown that the focus for parallel rays lies about 23 mm. behind the cornea, which corresponds very closely with the position of the retina in the normal eye as determined by anatomical examinations.

A compound system, such as the eye, has its principal foci and nodal points, which are comparable to those of a single refraction or of a lens. There is a difference, however, in that these foci are measured from two points, known as *principal points*. Thus H and H' (Fig. 69) are the principal points of the eye; HF is the anterior and $H'F'$ is the posterior principal focal distance. Similarly there are *two nodal* points, N and N', separated by the same interval as the principal points. *The schematic eye* is a diagrammatic eye constructed on the measurements of the average normal eye (Fig. 69).

Fig. 69

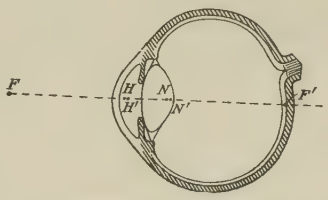

The schematic or average normal eye, natural size. The anterior and posterior principal foci are represented by F and F' respectively; the first and second principal points by H and H', and the nodal points by N and N'.

In the eye the interval between the two nodal points is only 0.37 mm.; consequently the nodal rays undergo an almost inappreciable lateral displacement, and these two points may be practically merged in a single point coinciding with the optic centre (Fig. 70), through which the nodal rays pass.

Fig. 70



Illustrating the projection of the retinal image along the nodal ray.

It is apparent from this diagram that the retinal image is always inverted with respect to the object seen. The mind, however, does not take cognizance of the retinal image; it possesses the power of external projection so that objects are normally seen in their true position.

The size of the image on the retina is determined by the distance of the object; for it is apparent that $O\,O_1$ (Fig. 70) is as many times longer than $I\,I_1$ as ON is longer than NI.

Emmetropia and Ametropia.—When the retina and posterior principal focus of the eye coincide in position, the eye is adapted to receive a clear impression of a distant object. This condition, occurring in relaxation of the ciliary muscle, is called *emmetropia.* Any deviation from emmetropia is called *ametropia.* An ametropic eye is said to be affected with an *error of refraction.*

Hyperopia.—Hyperopia is that form of ametropia in which the retina lies in front of the principal focus during relaxation of the ciliary muscle; that is, the hyperopic eye is relatively too short in its antero-posterior diameter. In this condition the image of a distant object will be blurred, that of a near object will be more so.

Myopia.—Myopia is that condition in which the retina lies behind the principal focus during relaxation of the ciliary muscle; that is, the eye is relatively too long antero-posteriorly. In myopia the image of a distant object will be blurred, but that of a near object may be clearly formed on the retina.

Accommodation.—Rays which enter the eye from objects not less than six meters (20 feet) distant may be regarded as parallel, and consequently they will be focused on the retina of the emmetropic eye, but rays from near objects will be intercepted by the retina before they have reached their focus, which is behind the principal focus. In order that this focus may be brought forward so that it will fall on the retina, the refractive power of the eye must be increased. This is normally accomplished by an increase of convexity of the crystalline lens (chiefly of the anterior surface) under the influence of the ciliary muscle. This adaptation of the eye for varying distances is called *accommodation.*

As the crystalline lens gradually increases in hardness from youth to old age, there comes a time, usually between the fortieth and forty-fifth year, when the lens is no longer able to change its shape sufficiently for the requirements of near work. When this condition is reached the person is affected with *presbyopia.*

In hyperopia accommodation is exercised even in distant vision in order to bring the principal focus forward to the retina. By a still further increase of convexity, provided sufficient accommodative power is available, the hyperopic eye may be adapted for near vision.

In myopia no accommodation is required for near vision unless the object is nearer than the focus which is conjugate to the retina, as determined with the ciliary muscle in relaxation. The external point which is thus conjugate to a point on the retina is called the *far point* of the eye.

Correction of Hyperopia with a Convex Lens.—In hyperopia the deficiency of refraction may be overcome by a convex lens placed before the eye. By this lens the rays from a distant point are rendered convergent, so that they are focused on the retina after passing through the dioptric system of the eye (Fig. 71). The strength of the lens required to bring the focus on the retina varies with the position of the lens, a stronger lens being required as the distance between the eye and lens is diminished. Spectacle lenses are usually worn about 15 mm. from the cornea. The

lens which, in this position, brings the focus for distant objects upon the retina, is taken as the measure of the hyperopia.

Fig. 71

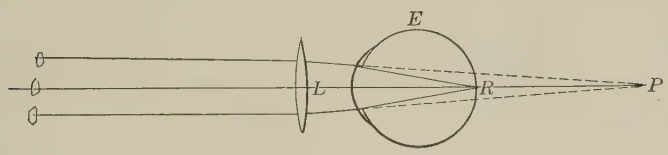

Correction of hyperopia with a convex lens. The point *O*, from which the rays diverge, is too far distant to be represented in the diagram.

Correction of Presbyopia.—The convex lens is also used in near work to overcome the deficiency of refraction when the accommodative power has failed from presbyopia.

A convex lens, when it is *farther* from the eye than the anterior focus of the latter, magnifies the retinal image; *at this focus* it exerts no effect on the size of the image; and *within*[1] the focus it minifies the image. Eyeglasses, being worn only slightly without the anterior focus of the eye, do not greatly alter the size of images. The magnification so often noticed when convex lenses are first worn is chiefly a psychic effect. It is probable that the degree of accommodation required to see an object clearly is an important factor in the estimation of its distance, and consequently of its size. When accommodation is first replaced by a convex lens, the person thinks the object is farther off than it really is, and this without diminution of the retinal image. Thus, the apparent size of the object is increased.

Correction of Myopia with a Concave Lens.—Since the concave lens renders parallel rays divergent, as if they came from a near point, such a lens may be used to focus rays from a distant object upon the retina of a myopic eye. In Fig. 72 the parallel rays are rendered divergent,

Fig. 72

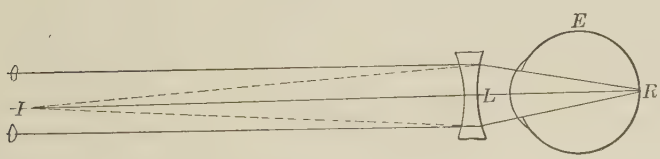

Correction of myopia with a concave lens.

so that they appear to proceed from *I*. If *I* is conjugate to the retina, parallel rays will be focused on the retina after passing through the lens and the dioptric system of the eye. The concave lens, which, when placed 15 mm. from the eye, focuses parallel rays on the retina, is the *measure of the myopia.*

[1] This refers to the focused image as formed without the lens, not to the diffusion image on the retina, which differs slightly from the former.

The effect on the size of images of concave lenses is opposite to that of convex lenses, that is, the concave lens minifies the retinal image when the lens is without the anterior focus of the eye. The diminution effected by spectacle lenses is slight except in the very strong glasses required for the correction of high myopia. Even in these cases the minification is largely a psychic phenomenon, being produced in the opposite manner to the psychic magnification of convex lenses.

Asymmetrical Refraction.—In the normal eye the refracting surfaces are so nearly spherical that we may regard them as being of that form. But in a large porportion of eyes the surfaces are asymmetrical, that is, the curvature, as measured in various meridians, is not the same. The meridians of greatest and least curvature are at right angles to each other; they are called the *principal meridians.* In refraction by an asymmetrical surface the rays which proceed from a point will not be united in a focus, and the condition is called *astigmia* (or astigmatism).[1]

FIG. 73

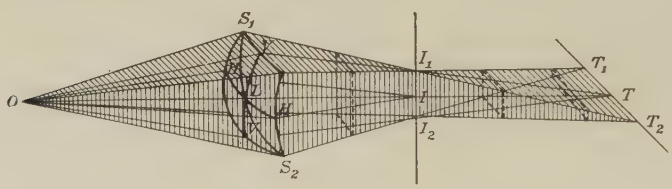

Asymmetrical refraction.

Asymmetrical refraction is illustrated in Fig. 73. The curvature in this diagram is greatest in the horizontal meridian (HH) and least in the vertical meridian (VV).[2] The focus for the rays passing in the horizontal meridian, HOH, is at I; while the focus for the rays passing in the vertical meridian, VOV, is at T. The manner in which oblique rays (as OS_1 and OS_2), not lying in either of the two principal meridians, are refracted is shown in the diagram. We see that all rays must pass through the lines I_1I_2 and T_1T_2. These two lines are called the *focal lines.* If a screen is placed at I the image of the point O will be the vertical line I_1I_2 and if the screen is at T the image will be the horizontal line T_1T_2. *Thus, at the horizontal focus the image of a point is a vertical line and at the vertical focus the image is a horizontal line.* In other positions of the screen the image according to our illustration would be rectangular or square; but if the corner rays were cut off by a circular diaphragm, *as the iris,* which permits the rays to enter the eye through the round pupil, the rectangular diffusion image would be elliptical and the square image in our diagram would be circular. In no case would the image of a point be a point, as it is in spherical refraction.

[1] This is *regular* astigmia, which is always indicated unless otherwise stated. *Irregular* astigmia is due to irregularity or unevenness of surface, or to heterogeneity of refractive index.

[2] This is opposite to what usually exists in the eye, the vertical curvature of the cornea being, as a rule, greater than the horizontal.

Correction of Regular Astigmia.—Regular astigmia may be overcome by placing a *cylindrical lens* before the affected eye. The action of a cylindrical lens is shown in Fig. 74. The rays are refracted in the meridian *HH*. This, the meridian of greatest curvature, is the refracting meridian of the cylindrical lens. In the other principal meridian there is no curvature, and the lens acts, so far as this direction is concerned, like a plate with parallel plane surfaces; that is, there is no deviation in this direction. A straight line drawn in this direction through the centre of the lens is the *axis of the lens*. It is apparent that if we place a suitable cylindrical lens before an eye affected with astigmia, the rays from an object may be properly focused on the retina. For, if in the meridian of greatest refraction the focus lies on the retina, while in the meridian of least refraction the focus lies behind the retina, a suitable convex cylinder having its axis parallel to the meridian of greatest refraction will supplement the deficient refraction in the meridian of least refraction of the eye (which is the refracting meridian of the lens) so as to bring the focus in this meridian forward to the retina; that is, *T*, in Fig. 73, will be brought into coincidence

Fig. 74

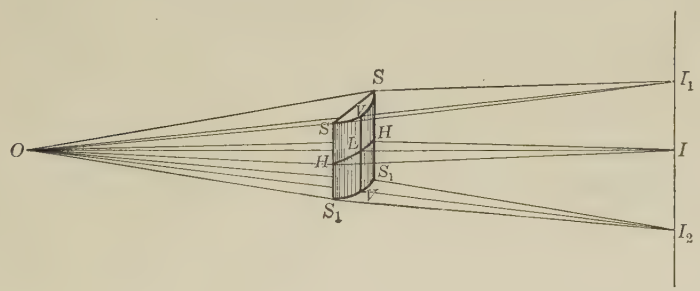

Refraction by a cylindrical lens.

with *I*, and the rays from *O* will be focused at the point *I*. If the focus lies on the retina in the meridian of least refraction and in front of it in the meridian of greatest refraction, a suitable concave cylinder will carry the focus of the too refracting meridian back to the retina; that is, a concave cylinder, axis vertical, will move the horizontal focus from *I* to *T* (Fig. 73), and the rays from *O* will be focused at *T*.

When the eye has hyperopia or myopia besides the astigmia the correcting lens may have on one side the proper spherical curvature and the cylinder on the other side, or an asymmetrical curvature may be ground on one side of the glass (*toric lens*), the other side being plane or spherical.

Determination of the Axis of a Cylindrical Lens.—Since a toric or spherocylindrical lens alters the direction of rays more in one principal meridian than in the other, and a plano-cylinder alters their direction in one meridian and not at all in the other, there is a distortion of objects as seen through these lenses. This is slight when the lenses are very near the eyes, as in spectacle lenses, but at a greater distance it becomes very marked. This property is used to ascertain the principal meridians

of asymmetrical lenses. If we hold one of these lenses before the eye and look at a distant straight line, the line will in general appear to be twisted out of its proper position (Fig. 75), but on rotating the lens we find a position in which there is no such apparent displacement of the line. The line then lies in one principal meridian of the lens, and the other principal meridian is at right angles to the line. If with a lateral movement of the lens there is no apparent movement of the line, the lens is a cylinder and the direction of lateral movement coincides with the direction of the axis of the cylinder. The refracting meridian is at right angles to this, and the kind and strength of the lens in this meridian can be determined by neutralization, as has been explained for spherical lenses. Similarly, a toric or a spherocylindrical lens may be neutralized, first in one principal meridian and then in the

Fig. 75

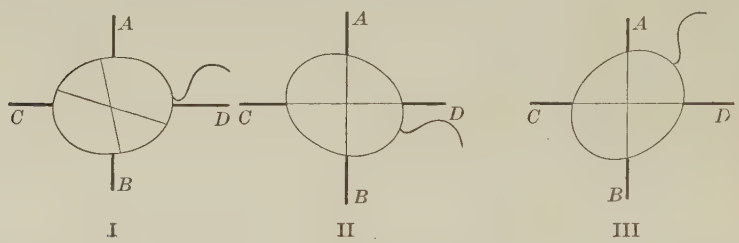

Distortion produced by a cylinder. Determination of the axis of a cylinder. A right-angled cross (*A B C D*) is seen through a glass containing a cylinder. If (I) the axis of the cylinder does not coincide with either *A B* or *C D*, the cross will appear twisted, so that the arms no longer make a right angle. The cross, however, is not displaced as a whole either to one side or the other. If now the glass is rotated until the axis of the cylinder coincides with one arm of the cross—*e. g.*, *A B* (II)—the cross will appear right-angled and unbroken. The same thing will happen if the glass is rotated 90 degrees more (III), so that the axis of the cylinder coincides with *C D*. (Posey and Wright.)

other; or to the spherical lens which neutralizes one meridian the proper cylinder may be added, whereby the lens is neutralized in both meridians, and it is equivalent to the neutralizing combination with a change of signs.

Principles of Ophthalmoscopy, Skiascopy, and Keratometry.—In the phenomena thus far described we have had no occasion to study the reflection of light. In ophthalmoscopy, skiascopy, and keratometry, both reflection and refraction take part. The *law of reflection* is that any ray meeting a reflecting surface has its direction reversed so that its angle of incidence (*ABD*, Fig. 76) is equal to the angle of reflection (*DBO*), both angles lying in the same plane. If *NM* is a smooth plane surface, the ray *AB* is reflected in the direction *BO*, and *AC* is reflected as the ray *CP*. The geometrical relations of the angles of incidence and reflection are such that on backward prolongation the reflected rays meet at *a*, which is as far behind the surface as *A* is in front of it. Hence if an object is situated at *A*, the eye at *E* will see by reflection the virtual image at *a*. If, instead of being plane, the surface of the mirror is concave, the rays will be collected into a real focus in front

of the mirror, provided the point of origin of the rays is farther than the centre of the surface. On the other hand, a convex mirror renders the reflected rays divergent, so that no real image will be formed, but a virtual reduced image behind the mirror. Thus, a convex mirror resembles a concave lens and a concave mirror resembles a convex lens.

When light is reflected from an uneven surface there is no regularity in the various reflected rays; in this case no image will be formed, but the reflected rays, entering the observer's eye from various points of the surface, render this visible. It is thus by irregularly reflected or *scattered* light that non-luminous objects are made visible.

Fig. 76

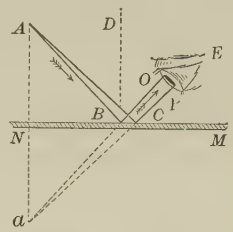

Illustrating the law of reflection.

Ophthalmoscopy.—The invisibility of the interior of the eye under ordinary circumstances is due to the fact that rays of light which by irregular reflection illuminate a portion of the fundus are so refracted in their return passage that their direction after emergence coincides very closely with that of entrance; consequently, if a candle is held before an eye to illuminate its interior, the observer's head, in his endeavor to receive the returning rays, will come between the examined eye and the candle, so that the eye will not be illuminated.

This difficulty was overcome by Helmholtz, who was the inventor of the ophthalmoscope (1851). Although the construction of the modern ophthalmoscope differs greatly from that of Helmholtz, the essential optic principles involved have not been changed. The ophthalmoscope as at present used consists essentially of a mirror (usually concave, since this form by its collective action gives better illumination than the plane mirror) with a sight-hole at its centre, through which the returning rays are received by the examiner's eye. Attached to the instrument there is a series of convex and concave lenses, any one of which may be brought to the sight-hole for the proper focusing of the rays upon the examiner's retina. A separate convex lens of about 13 D. is also supplied for use in the indirect method of examination.

Direct Method.—In the direct method the light from a flame is reflected by the mirror into the eye undergoing examination while the observer, having his eye at the sight-hole of the mirror, receives the returning rays, which are focused upon his retina, so that he receives a direct image of the fundus of the examined eye (Fig. 77). The examiner projects this image into space, so that it appears to be behind the examined eye and in the erect or upright position. The magnification by this method is about sixteen diameters.[1]

When the examined eye is hyperopic, the emergent rays will be divergent, so that in order to bring them to a focus on the retina of the

[1] That is, the image on the examiner's retina is about 16 times as great (in each dimension) as if the same portion of fundus were seen at a distance of 25 cm. (10 inches), and without the magnifying action of the examined eye.

emmetropic observer without exercise of his accommodation a convex lens, which is attached to the ophthalmoscope, must be brought to the sight-hole of the mirror.

On the other hand, if the examined eye is myopic, the emergent rays will be convergent and a concave lens must be used to bring them to a focus on the retina of the emmetropic observer.

If the observer is hyperopic or myopic, a suitable lens must be used to correct his ametropia.

Fig. 77

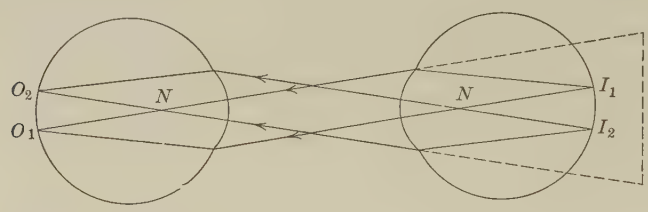

Illustrating the path of the refracted rays in direct ophthalmoscopy.

Indirect Method.—The indirect method differs from the direct in that in the former a convex lens (about 13 D.) is held near the eye under examination (at a distance about equal to the focal length of the lens), by means of which a real inverted aërial image of the illuminated portion of the fundus is formed. The examiner then having his eye about 25 cm. (10 inches) from this image, sees it either by aid of his accommodation or with a convex lens (4 D.). In this case the apparent position of the image is between the observer and the examined eye. The magnification is considerably less than by the direct method—about 4 or 5 diameters—but the field of view is correspondingly larger.

Skiascopy (*Shadow Test, Retinoscopy*).—This consists in reflecting light into an eye from a mirror held at a distance of about one meter, rotating the mirror, and observing the characteristic appearances. In one position of the mirror the whole pupil will be illuminated by the "*red reflex,*" but on rotation of the mirror a more or less swiftly moving shadow follows the reflex across the pupil until the whole pupil is in darkness. The character of this movement varies in accordance with the refractive condition of the examined eye. The explanation of the optic principles involved is too complex for the general student; only a brief outline can be here considered.

In Fig. 78, L represents a lamp; MM a plane mirror; E, the examiner's eye; and PP, the pupil of the examined eye. Light is thrown into the eye PP so as to illuminate the portion I_1I_2 of the retina. In the diagram this eye is myopic, so that rays emerging from I_1 are focused at O_1; those from I_2 are focused at O_2, and O_1O_2 is an inverted image of I_1I_2. The observer at E may, by the exercise of accommodation or with a convex lens, examine this image; or he may look beyond the image at the pupil PP. He will, in the latter case, see no details of the image O_1O_2, but only the red reflex filling the pupil. If, now, the observer

rotates the mirror downward, the illuminated portion of the retina will also move downward, and the image O_1O_2 will move upward. In a certain position of the mirror, $I\,I_1$ will no longer be illuminated, and then the corresponding part of the image OO_1 will also be unilluminated, and the lower half of the pupil will appear dark. Thus, as the mirror is rotated downward, the reflex and the attendant shadow move upward. Hence the rule in myopia, when the observer is beyond the far point of the eye (where the image O_1O_2 is formed), is that the shadow moves in the opposite direction to the rotation of the plane mirror.[1]

FIG. 78

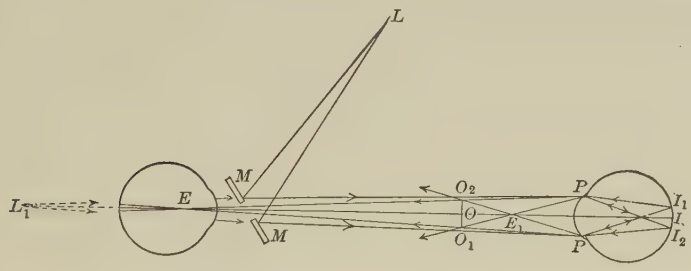

Illustrating the path of the reflected and refracted rays in indirect opthalmoscopy and in skiascopy. The rays emerging from the eye ($P\ P$) undergoing examination are rendered convergent by inherent myopia of this eye or by a convex lens placed in front of the eye.

If, on the other hand, the examiner's eye is nearer than O, the reverse condition prevails, because the inverted image O_1OO_2 falls (in an unfocused condition) directly upon his retina; and since in external projection all objects are seen inverted with respect to the retinal image, the point O_1, which receives light form I_1, will be projected toward the upper part of the pupil PP. Hence, when $I\,I_1$ becomes dark by downward rotation of the mirror, OO_1 (*which now represents the examiner's retina*) becomes dark and through external projection the upper part of the pupil PP appears to be in shadow. As the light continues to move downward on the examined eye, the apparent light and shade as seen by the observer also move downward. The place where this change of motion occurs is at O; when the examiner's nodal point is at O, neither accompanying nor reverse movement can be detected; the pupil becomes instantly dark on rotation of the mirror. Because O is the point at which the change of motion occurs, it is called the *point of reversal.*

If the examiner and his mirror are at a distance of 1 meter from the examined eye, he will always be within the point of reversal of the emmetropic and hyperopic eye, and in myopia of less than 1 D. Only in myopia of more than 1 D. will he be without the point of reversal so

[1] When the concave mirror is used the movement is in all cases opposite to that which occurs with the plane mirror, because a real inverted image of the light is formed by the concave mirror between the eye of the observer and that of the person undergoing examination. This image thus becomes the illuminating source, and its motion is in the same direction as that of the mirror, which is the opposite condition to that which prevails with the plane mirror.

as to observe the motion of the shadow contrary to (or against) the motion of the mirror.

The most convenient method of practically determining the refractive condition by skiascopy consists in placing before the eye undergoing examination such a lens as will bring the point of reversal to the examiner's eye, which is 1 meter distant from the examined eye. If rotation of the mirror produces the appearance characteristic of the point of reversal without any lens, the eye is myopic 1 D. If the shadow movement is with the mirror, and a convex lens of 1 D. neutralizes this movement, the eye is emmetropic (because a lens of 1 D. is required to produce 1 D. of myopia). If 3 D. is required to neutralize the movement, the eye is hyperopic 2 D., etc. But if a concave lens of 3 D. is required to neutralize a movement against the mirror-rotation, the eye is myopic 4 D., etc.

In astigmia there is a separate point of reversal for each of the two principal meridians. When the observer is at the point of reversal for one principal meridian, there will be a movement of the shadow on rotating the mirror in the other principal meridian. The difference in the power of the lenses which place the observer at the points of reversal in the two meridians measures the astigmia.

Fig. 79

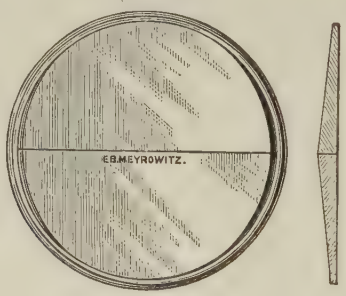

Maddox double prism: *a*, front view; *b*, sectional view.

Keratometry.—Keratometry or ophthalmometry, as it is usually called, consists in measuring the curvature of the anterior surface of the cornea. Clinically, it consists in estimating the corneal astigmia by measuring the difference of curvature in the two principal meridians of the cornea. This measurement is made by the method of double images. If we place a Maddox double prism (Fig. 79) before one eye so that the apex of the prism bisects the pupil, and then view through this eye and the prism an object such as is represented in Fig. 80, we see two images of the object, and when the object is at a certain distance the two images will appear in contact (Fig. 81). In this case the prismatic displacement is exactly equal to the length (AB) of the object. Hence, if the deflecting power of the prism and the distance are known, the length AB can be determined. Thus, if the prism has a deflecting power of 1 prism-dioptre, and the contact position occurs at a distance of 1 meter,

the length of AB must be 1 cm. If the contact position occurs at a distance of two meters, the length of AB must be 2 cm., etc.

The curvature of the anterior surface of the cornea is estimated from the size of the image reflected at this surface from an object of known size.

The size of the reflected image varies with the curvature of the cornea; the greater the curvature (the less the radius of curvature) the smaller is the image. From the mathematical formula expressing the relation between the radius of the cornea and the size of the image, the radius can be determined when the size of the image has been found by the foregoing method.

The essential parts of the ophthalmometer are a telescope, consisting of an objective and an eyepiece, and a device in the tube of the telescope for doubling the image.

In the ophthalmometer which was invented by Helmholtz (1854) the doubling was effected by two glass plates inclined at an angle. This instrument was intended only for laboratory investigations.

Fig. 80

Fig. 81

The first ophthalmometer suitable for every-day clinical measurement of corneal astigmia was designed by Javal and Schiötz (1882). In this the doubling device is a Wollaston prism of quartz, which, by its polarizing effect on light, gives a double image. The prism occupies a fixed position between the two lenses of the double objective, and it consequently produces a fixed amount of doubling (about 3 mm.). By varying the diameter of the object—the distance between the two mires—the double image is brought into the contact position. One of the mires is made in the form of a parallelogram, and the other consists of a series of steps. We bring the images into the contact position in the meridian of least curvature of the cornea (which we find by rotating the instrument), and then revolve the telescope and mires through ninety degrees and note the overlapping of the mires in the meridian of greatest curvature. The parts are so proportioned that the overlapping of each step represents one dioptre of astigmia.

Other ophthalmometers have been made which differ from the Javal-Schiötz model in several respects, but in all the principles involved in making the corneal measurements are the same.

CHAPTER IV.

EXAMINATION.

Examination of Patient and External Examination of Eye.—*Functional Testing.*—A systematic examination of the patient, as well as of the eyes, should be made in cases of grave import, and for that purpose a chart setting forth the order of procedure is convenient and useful as a means of record and as a precaution against omissions. The order advised by de Schweinitz, *Diseases of the Eye*, fourth edition, p. 55, is excellent; it is reproduced here with slight modifications:

Name and Residence.

Date.

Age.

Family history: Hereditary tendencies; general and ocular health of parents, brothers, sisters, etc.

Personal history: Children, their number and health; miscarriages; former illnesses; syphilis and gonorrhea; injuries.

Occupation: Relation of work to present indisposition.

Habits: Brain use; tobacco; alcohol; narcotics; sexual.

Organs of digestion: Teeth; tongue; stomach; bowels.

Organs of respiration: Nose; throat; lungs;

Organs of circulation: Heart; pulse; blood.

Kidneys: Examination of urine.

Abdominal organs: Liver; spleen.

Organs of generation: Menses; leucorrhea; uterine disease.

Nervous system: Intelligence; evidence of hysteria; hallucinations; sleep; vertigo; gait; tendon and muscle jerks; paralysis; tremor; pain; subjective sensations; convulsions; headaches and their position.

Eyes: Inspection of the skull and orbits (symmetry and asymmetry); ciliary borders; puncta lachrymalia; upper and lower culs-de-sac; conjunctivæ; caruncles; corneæ (oblique illumination and loupe); irides (mobility and color); anterior chamber (depth and character of contents); vision; accommodation; balance external eye muscles; adduction; abduction; sursumduction; position of eyes; mobility of globe; tension; light-sense; color-sense; fields of vision; ophthalmoscope.

Date and mode of onset and supposed cause of present trouble: Outline of its course.

Inspection of Eye.—The skin of the lids should be examined in reference to color, evidence of enlargement of the vessels of the lid, edema, presence or absence of the natural folds of the skin, the condition of the eyelashes, the presence of parasites on the eye lashes, of sebum, scales, and crusts at the roots of the lashes.

Lachrymal Apparatus.—The position of the puncta lachrymalia in relation to the ocular conjunctiva, their patency, also the condition of the canaliculi and of the lachrymal sac should be determined. Redness of the conjunctiva, particularly of the lower lid and globe to the nasal side, should direct attention to the lachrymal sac and to the canaliculi. Pressure should be made over the sac to determine the presence of retained secretion. Pouting of the punctum and swelling along the course of a canaliculus, if present, should be noted.

Conjunctiva.—For the purpose of examining the conjunctiva it is necessary to evert the upper lid (Fig. 82); this is done by seizing the eyelashes between the thumb and forefinger at the middle of the lid; the patient should then look downward, and gentle traction should be made on the eyelashes sufficient to draw the lid downward, and slightly away from the eyeball. The tissues of the brow may then be forced gently but

Fig. 82

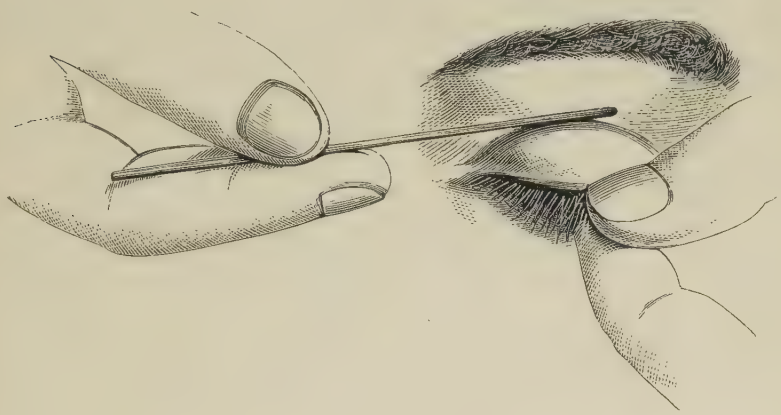

Eversion of the eyelid.

firmly downward by means of a finger or thumb of the other hand; the margin of the lower lid is then turned quickly backward over the mass of tissue. An easier procedure is to place the end of a small smooth instrument (such as the end of a small pencil), on the upper lid just above the upper margin of the tarsus, after the lid has been drawn downward and outward. The margin of the lid is then turned over the small instrument, which is at once withdrawn. This exposes the tarsal conjunctiva, and the lid is held in the inverted position by means of the finger or thumb.

If no eyelashes are present the patient is directed to look downward, the tissues of the upper lid are pressed gently but firmly downward, the margin of the lower lid pushed under the margin of the upper lid, until the margin of the upper lid can be engaged on its conjunctival surface by the back of the thumb or finger nail, when it can be turned up over the tissue of the lid or small instrument as before described.

If we desire to expose the conjunctiva at the fornix, we hold the margin of the upper lid well up against the brow, and press gently on the eyeball with one or two fingers of the other hand, the lower lid intervening. This will cause the fornix conjunctivæ to bulge forward, and will expose it almost completely.

To evert the lids of an infant, the child should be held on the lap of the nurse, with the back of the head resting on a towel across the surgeon's knees. The lids are then everted in the way described, or, as often happens, particularly if the lids are swollen, gentle separation of the lids by traction on the skin of the lids, accompanied by slight downward pressure at or slightly within the margin of the orbit, above or below, as the case may be, will suffice to expose the conjunctiva. This is particularly apt to occur if the child cries.

To expose the conjunctiva of the lower lid, the end of the index finger is placed at the margin of the lid at the union of the outer two-fifths with the inner three-fifths, and the lid is drawn gently but firmly downward and outward; at the same time gentle pressure is made on the eyeball through the upper lid; this pressure causes the conjunctiva at the bottom of the sac to bulge forward, exposing it completely.

All abnormalities of the conjunctiva should be carefully noted. Congestion, partial or complete; thickening from inflammatory processes—active, or from an œdema—passive, condition; transparency; condition of the surfaces; presence of foreign bodies; tumors, etc.

In studying the changes in the conjunctiva, it is helpful to remember that the blood supply virtually forms two systems, which may be designated as the *posterior*, and *anterior* or ciliary systems.

Congestion.—*Posterior System.*—Congestion of the posterior system of vessels produces thickening of the conjunctiva, often a velvety appearance and a brick-red color; the engorged vessels move with the conjunctiva over the underlying tissue. The congestion is *most marked in the fornix*, much less intense at the sclerocorneal margins; this is the congestion in all forms of conjunctivitis.

Anterior System.—When the arteries principally are engorged, the injected zone presents a bright pink or red color, the vessels lying nearly parallel to each other and radiating from the cornea. When the veins principally are affected, a dusky red or purplish color is observed.

Uniform injection of the anterior system is present in iritis, iridocyclitis, diffuse keratitis. Partial ciliary injection is present in episcleritis and keratitis limited to a portion of the cornea near the margin of the cornea.

In some forms of scleritis and episcleritis the injection presents a purple hue, due to partial venous stasis.

Ciliary System.—A form of injection which involves the capillaries of the ciliary system (designated by Nettleship as a third system) occurs at the limbus conjunctivæ. It seldom entirely encloses the cornea, but appears in small areas. It is of a bright red color, and encroaches on the margin of the cornea. (See Parenchymatous Keratitis.)

Temperature of Conjunctival Sac.—This may be determined by use of the curved thermometer with a flattened bulb. A drop of cocaine is

instilled into the eye and the bulb of the thermometer is buried in the lower cul-de-sac. According to Silex the temperature of the normal lower cul-de-sac is 35.55° C. (95.99° F.). My own measurements gave 97.5° F. (36.38° C.). The temperature is increased in active inflammatory conditions of the eyeball or eyelids.

Orbicularis Muscle.—The action of the orbicularis muscle should be determined by causing the patient to close the eyes gently and also forcibly. The length and symmetry of the palpebral fissures and the condition of the canthi should be noted.

Eyeballs.—The position of the globe in the orbit, its size, relation to the fellow eye, prominence (exophthalmos) or depression (enophthalmos) should be noted. The position of the eyes as regards their prominence cannot be readily ascertained by a front view, nor do measurements from the cheek or brow furnish reliable data, on account of the asymmetry of these parts. If the eyes are observed from above, and the relation of the apices of the corneæ to the edge of a rule held across the bridge of the nose, parallel to the plane of the face, is observed, any variation in the prominence of the eyes will be detected.

Fig. 83

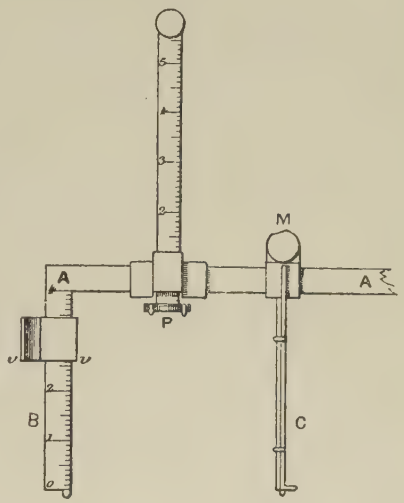

Statometer of Snellen for determining the depth of the globe in the orbit: *A*, bar; *B*, projecting arm, stationary, carrying *v*, a sight-vane; *C*, movable arm carrying *M*, a mirror. The distance between the arms is made to correspond to the diameter of the orbit. The end of *B* is placed on the outer margin of the orbit, about midway; the extremity of *C* on the inner margin of the orbit just below the inner canthus. The sight-vane is so adjusted that the cornea, its reflected image, and the vane are in the same line. The distance from the bar is then read off from the scale *B*. The plunger *P* may then be adjusted to rest on the closed upper lid over the pole of the cornea, and the distance of the plunger from the bar be recorded in millimeters, as indicated by the scale on the plunger.

Statometers.—A number of instruments (statometers) have been devised for the purpose of measuring the depth of the globe in the orbit, which permit of determining in millimeters the variation in position in individual cases. Such instruments, of which Snellen's is an example (Fig. 83), can be used to determine variations in individual cases, but cannot be used to indicate a departure from the normal, as the physiological variation between the relation of the depth of the globe to the margins of the orbit is such that no normal standard can be fixed.

Prominence of Eyeballs.—Prominence of the eyeballs may be due to enlargement of the globe, as in high myopia; staphyloma, to orbital tumor, to Graves' disease, paralysis of the extrinsic muscles, or tenotomy of one or more muscles.

Sinking of Eyeball (*Enophthalmos*).—This may be due to absorption of the orbital tissue as a result of traumatism, age, wasting disease; it may also be due to a small-sized globe.

Tension of Eyeball.—The tension of the normal eyeball varies slightly in different individuals, but under pathological conditions the variations may be very great, ranging from a degree of softness which permits of the very easy indentation with the finger, to a hardness almost like that of stone. Bowman, 1862, suggested the employment of symbols to designate the tension of the eyeball. A capital T was employed to designate tension; Tn = normal tension; there were represented four degrees of increased and four degrees of diminished tension. In the symbols as at present used the plus sign indicates increase in tension, the minus sign decrease in tension; the degrees are represented as follows: Tn., $T+\frac{1}{2}$, $T+1$, $T+2$, $T+3$; $T-\frac{1}{2}$, $T-1$, $T-2$, $T-3$.

Determination of Tension.—The patient is directed to look downward and to gently close the eyes; both forefingers are then placed on the upper lid of one eye so as to gently press on the sclera near the equator of the globe. Wells directs that one finger-tip be employed to steady the globe while the other presses against it to determine whether it can be readily dimpled or not. Alternate pressure with the fingers in contact with the lids, much as in palpating a small tumor or abscess, affords perhaps more accurate information. The tension of one eye should be compared with that of the other. If there is any doubt regarding the tension of eyes under examination, comparison should be made with the tension of the normal eye in some other individual. Should the lids be greatly swollen or the conjunctiva be chemotic, a drop of cocaine may be instilled, the patient be directed to look upward and palpation be made on the lower anterior segment of the sclera without the intervention of the eyelids.

The normal tension of the eye presents quite a wide range, depending on the age and the personal peculiarities of the individual. In young individuals the tension is, as a rule, slightly less than in the aged; this is in part due to an increase in the stiffness or rigidity of the fibrous coat of the eye, in part to increased arterial tension. In cases of very slight variation in tension, without other changes, a pathological significance can only be determined when the fellow eye is normal, so that one may be compared with the other. The eyes of the same individual do not vary in tension normally. The tension of the normal human eye equals the pressure of a column of mercury 25 mm. high (Priestley Smith) (26 mm. high, Wahlfors). In glaucoma the pressure may exceed 70 mm. (Wahlfors).

Tenometers.—Priestley Smith and others have devised instruments known as tenometers,[1] which are used to ascertain the intra-ocular tension by direct pressure on the eyeball. The findings with these instruments are not always uniform. The examination with the finger-

[1] The tenometer of Schiötz recently introduced gives very good results, and is of value in making critical observations regarding ocular tension.

tips can be made much more rapidly, and the educated touch is found to be fully as reliable as are the results obtained with the tenometer, possibly excepting the tenometer of Schiötz.

Orbit.—It is well to pass the fingers along the margin of the orbit to ascertain the presence or absence of irregularities. The character of the supra-orbital notch or foramen should be noted. The effect of pressure over the supra-orbital, supra- and infratrochlear nerve trunks should be determined; also the relation of the lachrymal gland to the margin of the orbit. Gentle pressure backward on the globe will serve to determine the sensitiveness of the orbital contents and to ascertain whether an exophthalmos is reducible or non-reducible.

Palpation.—On deep palation at the upper inner angle of the orbit the pulley of the trochlear muscle may be felt. Deep palpation is employed in examining orbital neoplasms.

Auscultation.—Auscultation may be employed by placing the end of the stethoscope on the closed eyelids, over the cornea, on the skin of the temporal and frontal regions. If an *abnormal* bruit is heard, it is safe to diagnosticate a pulsating tumor; particularly is this the case if, on pressure over the common carotid, the bruit can be made to disappear.

Fig. 84

Desmarres' lid retractor.

Fluoroscopy and Radiography.—In the determination of abnormalities of structure and the presence of foreign bodies, fluoroscopy and radiography are of great value.

Cornea.—In examining the cornea, its size, shape, character of its surface, transparency, relation to deeper parts of the eye, and comparison with the cornea of the fellow eye should be noted. A solution of cocaine should be instilled before instruments are employed to expose the cornea. To expose the cornea it is necessary to retract the lids. This can be done ordinarily by drying the surface of the lid and placing the dry finger on the skin of the lid, the tip of the finger lying at the margin of the lid. By gentle traction, without pressure on the globe, the margins of the lids may then be separated. It sometimes becomes necessary to use a lid retractor (Fig. 84) for one or both lids. In some cases it may be necessary to employ an eye speculum. In using lid retractors or specula, care must be observed not to injure the cornea. Simple inspection will serve to disclose gross changes.

Irregularities of the surface of the cornea may be detected by placing the patient before a window or other source of light and studying the image of the same as reflected from the various parts of the cornea. The observer should place himself directly in front of the patient and the patient's eye should be made to follow the movement of some object, such as the observer's finger. If the corneal surface is normal, the image, as it moves over the cornea, will be regular and undergo but little change; if the corneal surface is in the least irregular, the image will

be distorted. The disk of Placido (Fig. 85) is sometimes employed for this purpose. In using it the patient is placed with his back to the light. The disk should be held about one foot from the eye to be examined, and should be well illuminated. The surgeon stands in front of the patient and looks through the central opening in the disk. If the cornea is irregular, the image of the disk reflected from the cornea will be distorted.

Examination with Fluorescin.—If minute ulcers or abrasions of the cornea are suspected, and cannot be readily determined by inspection or by other methods of examination, a drop of an alkaline solution of fluorescin (Gruebler's fluorescin, 2 per cent. in solution carbonate of soda, 3.5 per cent.) may be placed on the cornea. The eye is then irrigated with normal saline or 3 per cent. boric acid solution. Areas presenting loss of tissue will be colored green. If debris or secretion is present, it will be colored yellow or yellowish green. Eosin and toluidin blue (Veasey) may be employed in the same manner and for the same purpose.

Fig. 85

Placido's disk.

Corneal Opacities.—Corneal opacities should be carefully studied and a record made of their location, density, extent, and other characteristics.

Fig. 86

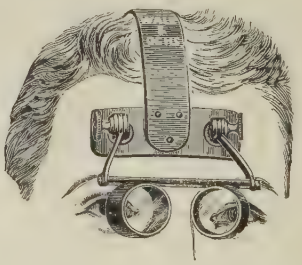

Jackson's binocular magnifier.

Minute Examination.—For the more minute examination of the cornea a lens or lens system may be employed. Jackson's binocular magnifier (Fig. 86) and the compound corneal microscope of Czapski are excellent instruments for this purpose.

Oblique Illumination (*Focal Illumination*).—This is a very valuable method of examining the anterior segment of the globe, as well as of the

cornea. The patient is placed in a darkened room in which there is a single source of light—an argand burner or some similar lamp. The light should be placed about three feet from the patient, at an angle of 35 degrees in front of the plane of the patient's face. A lens of two to three inches focal distance is interposed between the source of light and the eye, and the light focused on the part to be examined, the observer standing directly in front of the patient. The strong contrast between the illuminated and the non-illuminated parts enables the observer to determine even very slight departures from the normal. By use of magnifying lenses the examination is rendered more minute.

Fig. 87

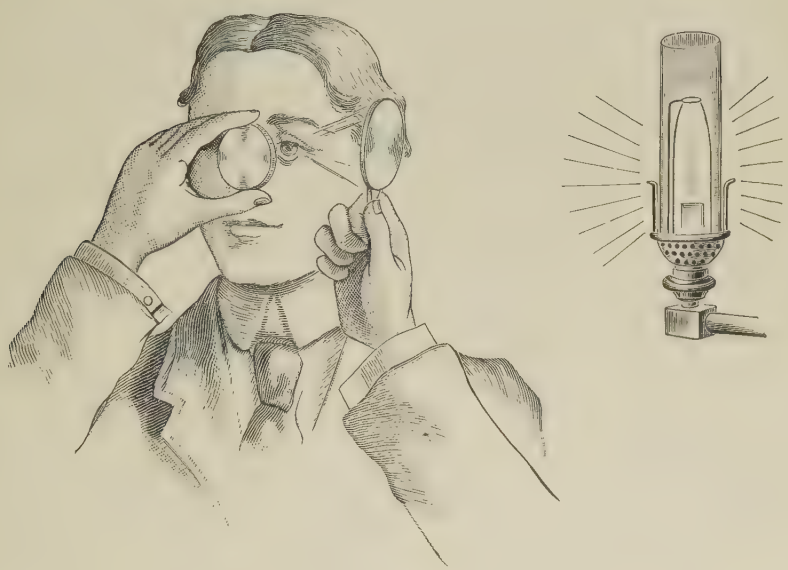

Oblique or focal illumination. (Posey and Wright.)

Irregularities affecting the posterior surface of the cornea, as deposits of all kinds, striæ, etc., can be studied by means of oblique illumination or by transmitted light with or without the aid of a magnifying glass.

Position of Defect.—The position of a defect of the cornea, whether on its anterior or posterior surface or in the substance of the cornea, can be determined by means of oblique illumination. This determination is effected with greater ease by use of the binocular loop. Reflection of light occurs from both surfaces of the cornea. When the cornea is being examined by oblique illumination, two reflections may be seen if the cornea is normal. If defects of the anterior surface are present, both reflections are interfered with; if the defect is in the parenchyma of the cornea, the posterior reflex is abolished; if the defect is on the posterior surface of the cornea, both reflexes are present (usually), the defect being situated posterior to the reflection.

Sensibility.—If the corneal surface is gently touched with a bit of tissue paper or a small piece of absorbent cotton twisted to a fine point, an immediate reflex action of the lids will occur if the sensibility of the cornea is normal. If below normal, the delicate touch will not excite the reflex. The fellow eye should be tested as a control, and in case both eyes are unaffected by the impact of the delicate object, the test may be tried on a normal eye.

Transmitted Light.—If light from any source is thrown into the eye, it traverses the transparent media (cornea, aqueous, crystalline lens, and vitreous humor), and a certain portion is reflected from the fundus of the eye, passing out through the pupil. If a small mirror, perforated in its centre, as the mirror of the ophthalmoscope, is made the source of light and the observer's eye is placed directly back of the aperture, the observer will see an illuminated area. Defects or changes in the transparent media may be studied by means of this form of illumination with or without the aid of a lens placed behind the aperture in the mirror. It is sometimes expedient to examine the changes in the cornea by this means.

Fig. 88



Sachs' transilluminator.

Transillumination. — It is well known that the interior of the eye may be illuminated through the sclera. This is apparent in the cases of retained perception of light by individuals whose corneæ have been destroyed by disease; also by the perception of the shadows cast on the retina by the retinal vessels when light is made to enter through the sclera at the equator of the globe (the Purkinje experiment). Sufficiently intense light introduced through the sclera back of the plane of the iris causes the pupil to become luminous from reflection from the fundus of the eye, the luminosity being visible even in the presence of cataract and a not too dense opacity of the cornea. A knowledge of these facts has led to the construction of special illuminating devices for examining the translucency of the tissues of the eyeball. The lamps of Leber, Sachs (Fig. 88), and Würdemann (Fig. 89) are now in use. They consist of an electric lamp which, with properly arranged mirrors and lenses, furnishes a more or less intense light. The light is conveyed through a glass rod, so arranged that it can be applied to the sclera or eyelids

at the time of the examination. The intensity of illumination may be regulated by means of a rheostat.

The examination should be made in a dark room, the only source of light being that from the transilluminating lamp. It is preferable to have the pupil dilated. The eye should be cocainized. The observer should place himself in front of the patient so that the pupil will be in full view; the illuminating point of the lamp may then be applied either to eyelids or sclera at various points, and the intensity of the illumination varied for the purpose of thoroughly determining the translucency of the tissues of the globe. The obstruction to the passage of light,

Fig. 89



Würdemann's transilluminator.

and consequently the variation in the luminosity of the pupil, afforded by neoplasms, exudation, blood clots and foreign bodies furnishes valuable aid in diagnosis. In cases in which a newgrowth is not large or dense, and in cases of exudation, the illumination must be less intense, in order to make the difference in translucency appreciable. When cataract or detachment of the retina is present, the illumination must be intense. Not only is transillumination of value in studying pathological conditions, but also in studying physiological conditions, particularly the relation of the crystalline lens to the ciliary body and iris.

Anterior Chamber.—The depth, extent and shape of the anterior chamber and the character of its contents should be determined. It is particularly desirable to note the condition of the iris-angle.

Iris.—The iris may first be examined by ordinary illumination; its shape, irregularities of any kind, as growths, defects or colobomata, color, etc., being noted. The eyes may be covered and reëxposed to note the effect of the stimulus of light on the pupils, *i. e.*, whether the irides react or not. Oblique illumination may be employed to study more closely the conditions present, using a lens to enlarge the image if desired.

Size and Shape.—A very narrow iris may be due to glaucoma or other disease of the eye; to the effect of a mydriatic applied locally or taken internally. There may be absence of the iris (aniridia); notching of the iris, due to traumatism, or absence of a portion (coloboma), either congenital or acquired; iridodialysis; atrophy, with multiple pupil (polycoria); adhesions of the iris to lens (posterior synechiæ) or cornea (anterior synechiæ).

Color.—The color of the iris in health usually conforms to the degree of pigmentation of the individual. The newborn have blue irides, almost without exception, change in color only occurring after a few weeks or months have elapsed, if at all. In blonds the iris is blue or gray; in brunettes, brown; in the negro, very dark brown; the albino possesses a light gray iris. In some individuals one iris is blue or gray, the other

brown (heterochromia). In many individuals the irides are irregularly pigmented. Variations in the degree of color in the irides often occur. Small pigmented patches are often mistaken for foreign bodies, sometimes thought to be on the cornea; their position may be ascertained by parallactic displacement tests (see page 146). In some irides pigment patches, more or less numerous, are present; they are located very near the surface of the iris, often possessing many processes, which project into the adjacent iris tissue much like the rays of a starfish. In disease the color of the iris changes; it may take on a greenish hue, may become yellow, or, as is usual in inflammation, a dusky brown.

Pupil.—The average size of the pupil varies with the age of the individual, as well as with the degree of illumination, convergence, and accommodation. In infants the pupil is small, in middle life larger, and in the aged small again. In hyperopic eyes the pupils are small; the reverse, as a rule, is true of myopes. The size of the pupil varies from 1.5 mm. to 9 mm., depending on the intensity of the illumination. The average diameter by moderate illumination is 4 mm. Normally the pupils are circular and symmetrical. The position of the pupil is, as a rule, a little to the nasal side of the centre of the iris. Slight differences in the size of the pupils frequently exist under normal conditions.

Methods of Measurement.—The diameter or width of the iris may be determined by means of a small millimeter measure, placing the measure before the eyes as close to the cornea as possible. The iris at its line of insertion at the ciliary body is somewhat hidden by the anterior border of the sclera. This fact must be taken into consideration in making the measurements just referred to. The keratometer of Priestley Smith[1] may also be employed for this purpose.

The size of the pupil may be measured by means of a millimeter rule, but, if this is employed, it must be remembered that the size of the pupil is actually greater than it appears to be on the rule, and that the difference in size is in direct proportion to the distance of the rule from the pupil, since the observer's line of vision cuts the rule before reaching the pupil.

Fig. 90

Pupillometer.

Pupillometer.—A very simple and excellent method is by means of the ordinary circular pupillometer. The little disk is held close to the cornea and is rotated until an aperture in the margin of the disk corresponds to the size of the pupil. The diameter of this opening, which is marked on the disk, is then recorded.

Light Reflexes, Reaction Originating in the Retina.—The reaction of the iris to light is excited (1) by the direct entrance of light—the *direct* light reflex; (2) by the entrance of light into one eye, the observed eye being

[1] Glaucoma, p. 96, Fig. 51.

PLATE IX

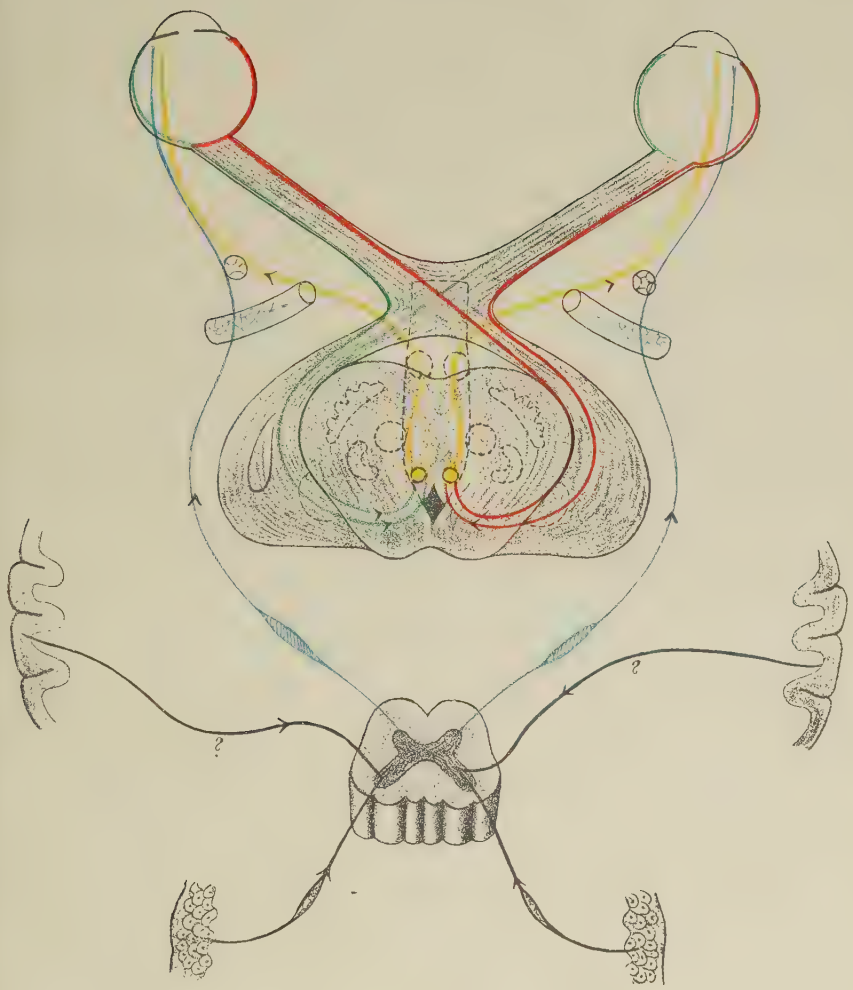

Pupillary Light Reflex Arc; Sympathetic, Cortical, and Sensory Dilator Tracts.

Red and Green.—Centripetal tract of the light reflex arc. (Crossing at the sphincter centres not shown.)

Yellow.—Centrifugal tract of the light reflex arc.

Blue.—Sympathetic tract containing the nerve fibers which innervate the dilator pupillæ.

Black.—Cortical and sensory tracts. (Uhthoff.)

shaded—the *indirect* or *consensual* light reflex. Both reactions are due to the integrity of what is termed the *light reflex arc*, which consists of fibers running from the eye to the brain, *centripetal* fibers, and fibers running from the brain (nucleus of the third nerve) to the iris, *centrifugal* fibers.

Centripetal Fibers.—The centripetal fibers have their origin in the retina, being apparently most plentiful in the region of the posterior pole, having the same distribution as the fibers concerned in vision, that is, those that decussate come from the nasal half of each retina, the non-decussating from the temporal half. They pass into the optic nerve and into the chiasm, they there undergo semidecussation and proceed along the optic tracts to the outer geniculate bodies, where they bend inward (Bernheimer), pass to the anterior part of the anterior corpora quadrigemina, and thence to the sphincter nucleus in the anterior portion of the nucleus of the third nerve.

Centrifugal Fibers.—These fibers arise from the sphincter nucleus of the side corresponding to the iris which they are to innervate, pass into the underlying tissue of the pons, where they are joined by fibers from the ciliary nucleus. They then pass into the trunk of the third nerve; then by the short root to the ciliary ganglion; then by the short ciliary nerves to the posterior part of the globe, through the sclera, and forward between chorioid and sclera into the ciliary body, from the anterior portion of which they pass into the iris tissue and to the sphincter.

Examination of Light Reflexes.—The examination of the light reflexes can be made either in strong daylight or by artificial light. The patient should face the light; the observer should place himself near the patient and in a position where he can detect any change in the iris.

(*a*) *Direct Reflex.*—Both eyes of the patient should be covered by means of a suitable screen (the hand is convenient) to exclude the light, and after the pupil has had time to dilate (one to three minutes), the screen should be quickly removed from one eye and the action of the iris noted.

(*b*) *Indirect or Consensual Reflex.*—Both eyes should be screened from the light, and after a few minutes have elapsed one eye should be uncovered. If the iris of the eye which is screened is closely observed, it will be found to contract to a degree exactly corresponding to the contraction of the pupil of the exposed eye (if the irides are normal).

If there is any doubt regarding the reaction of the pupil to light, the following method should be employed. The patient should be placed in a dark room facing and "fixing" a single source of light. The light should not be more than one meter from the patient. One eye of the patient should be excluded from the light by covering it with the hand or some opaque object. By means of a convex lens (15 to 20 D.) the light is now focused in the exposed eye, the patient not being permitted to look in any other direction than in a direct line to the light. The light may be thrown into the eye and shut out of the eye at the will of the examiner. The position and direction of regard eliminate any influence upon the

pupil by accommodation or by convergence. The strong illumination of the eye thus obtained makes it possible to determine with certainty the presence or absence of the pupillary light reflex.

To test the light reflex of *various parts* of the retina, it is necessary to arrange the illumination so that with the patient in diffuse light of sufficient brightness to permit the observer to discern the movements of the pupils, a pencil of light of sufficient intensity may be thrown into the pupil, so directed that only the part of the retina to be tested will be illuminated. It is difficult to illuminate a particular part of the retina without more or less diffusely illuminating other parts. For this reason the rays of light should be so directed that they will come to an approximate focus on the retina. The refractive error of the patient must be taken into consideration. The size of the incident cylinder of rays should be a little smaller than the pupil. The instrument of von Fragstein and Kempner (Fig. 91) may be employed, and if properly made is satisfactory.[1]

Fig. 91

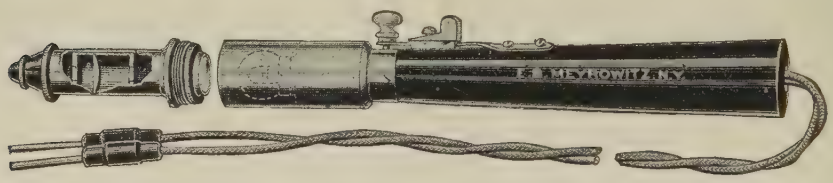

Von Fragstein and Kempner's apparatus for testing pupillary reaction.

Prevention of Reaction in Paralysis.—Reaction of the pupil to light may be prevented, even when perception of light is present, by paralysis of the motor oculi nerve, by the effect of mydriatics, mechanically as a result of increased tension, by contusions of the globe, by inflammation, by adhesions of the iris to the anterior capsule of the lens, by the presence of neoplasms and foregin bodies.

In the case of paralysis of the third nerve the afferent part of the reflex arc is interfered with, while the efferent part is intact; under these conditions, if light is thrown into the affected eye, the fellow eye (if normal) will show consensual contraction of the iris. In mechanical interference the reflex arc is intact and the consensual reaction will be produced in the normal fellow eye. Interruption in the course of the reflex arc as it occurs in spinal disease will also prevent this reaction to light although good vision be present. The iris may not respond to any stimuli, or it may react to accommodation and convergence (Argyll-Robertson pupil). The condition is due to destruction of the fibers that pass along the optic nerve, before they reach the nucleus of the third nerve. The connection with the nucleus of the third for impulses originating in the brain is not interrupted, consequently the reaction to accommodation and convergence is preserved.

[1] A modification of the Würdemann transilluminating lamp for this purpose is now on the market.

Reaction in Disease of Brain.—Reaction of the iris to light occurs in rare cases when there is absolutely no perception of light. This is the case when the blindness is due to disease affecting the cortical areas or the course of the cerebral fibers of the visual tracts, centrally from the fibers of the light reflex arc. Cases of this kind are of rare occurrence, as both hemispheres would necessarily have to be affected in order to produce total blindness (see Hysteria and Simulation).

Reaction Originating in the Brain (*Reaction of the Iris to Convergence and Accommodation*).—If the individual looks at a distant object, and is then directed to look at a small object situated 25 cm. from the eyes, the eyes will converge, the accommodation be brought into play, and the pupils become narrow. This action of the iris depends upon an impulse originating in the brain, and is arrested when lesion of the sphincter nucleus or of the trunk of the third nerve occurs. (See sensory reflex arc, Plate IX.) The remaining part of the tract over which the impulses that control this action pass is not definitely known. The position of a convergence nucleus is not definitely determined.[1] This reaction of the iris always accompanies convergence; it may be present or absent in accommodation. It is termed *associated action of the iris.* The associated action of the iris is less in degree than the direct light reflex reaction.

Sensory Reflex (*Pain Reaction of the Pupil*).—Reaction originating in the skin. (*a*) When the skin at the back of the neck is pricked or pinched, also when the faradic current is applied to this part, the pupil *dilates* moderately. Such reaction may also be obtained in some individuals by tickling the palm of the hand, and in others irritation of almost any part of the skin of the body will produce the reaction. (*b*) Originating in the brain. Sudden anger, grief, joy, or any violent emotion may produce dilatation of the pupils. (See sensory reflex arc, Plate IX.) In this case the initiative for the reaction originates in the brain.

Sympathetic Dilator Tract.—The fibers which innervate the dilator pupillæ have their origin in the ciliospinal centre of the spinal cord, situated in the anterior cornu in the lower part of the cervical and upper part of the dorsal cord.

Fibers from the dilator centre in the cord pass by the rami communicantes, which pass out of the spinal canal with the seventh and eighth cervical and first and second dorsal nerves, and enter the cervical sympathetic. The motor fibers reach the superior cervical ganglion, from which similar fibers pass to the internal carotid plexus; thence to the Gasserian ganglion and in the superior division of the fifth into the nasal branch and by way of the long ciliary nerves to the globe. These nerve filaments pierce the sclera near the optic nerve and pass between sclera and chorioid forward into the ciliary body, the outer layers of which they pierce, reaching the iris. In the case of a reflex originating in skin or mucous membrane, the path is by way of sensory nerves to the ciliospinal centre in the cord and by way of the sympathetic tract

[1] For a discussion of this subject, see Posey and Spiller, Philadelphia, 1906, p. 295.

to the iris. Originating in the brain, the path is from the cortex to the ciliospinal centre in the cord, thence to the iris.

Orbicularis or Lid Reaction (*Gifford-Galassi; Westphal-Piltz*).—This was first described by von Graefe as an accompaniment of a general contraction of ocular muscles excited by contraction of the orbicularis. The reaction has since been described by many writers. By forcibly closing the eye it often occurs that the pupil contracts. If the lids are held open by a speculum or by other means and an attempt is made to close the lids, the pupil, in many individuals, will contract.

Harold Gifford, in writing of this reflex, expresses the opinion that it is the result of an overflow stimulus passing from the nucleus of the facial to the nucleus of the third nerve, along the longitudinal fasciculus of Mendel. This view is also held by other writers.

Haab's Cortical Pupillary Reflex (*Attention Reflex*).—In 1885 Haab[1] described a reaction of the pupil observed under the following conditions: If, when the individual is in a dark room, his line of vision being directed forward into space or against a dark wall, a lamp or candle is placed at a few feet or yards distant (1 meter), at an angle of 45 degrees to the patient's line of vision and on the horizontal plane, the reflex will be excited, provided the *attention* (not the line of vision) can be directed to and held upon the flame. The reaction is a marked contraction of the pupil, which is maintained as long as the attention remains fixed on the flame, but is relaxed whenever the attention is relaxed. The reflex is marked in individuals whose irides are freely responsive to the stimulus of light. Some practice is often necessary to elicit the reflex. When the power to fix the attention as described is acquired, other luminous sources besides the lamp (small window, slit in a blind, etc.) may be substituted if desired. Auto-examination may be conducted. The degree of contraction of the pupil is in direct proportion to the degree of the illumination. If a piece of white paper, illuminated by a source of light not visible to the patient, be substituted for the lamp, the contraction of the pupil is less. If a piece of black paper or other black object be substituted, there is no contraction.

Variation in the position of the source of illumination causes variation in the degree of the contraction of the pupil. If the flame be carried backward beyond 45 degrees on the horizontal plane, letting the point of fixation on the line of vision be represented by zero, the contraction becomes less; if in advance of 45 degrees, greater. The reaction also becomes less marked if the source of illumination is above or below the horizontal plane.

Both pupils are affected equally with the light falling in one eye.

The reflex apparently depends on the normal condition of the visual fibers throughout, corresponding to the side of the retina on which the light falls and on the normal condition of the centrifugal fibers from the cortex that are concerned in this reflex. According to Haab, the centripetal pupillary light reflex fibers, central from the chiasm at least,

[1] Sitzungsbericht d. Ges. d. Aerzte in Zürich, November 21.

are not necessary (may be destroyed) for the production of this reflex.

Cortex Reflex.—Stimulation of the cortex of the brain has been found to produce an influence on the pupil, causing moderate dilatation. Many investigators have noted the fact that stimulation of the cortex of the brain, particularly of the occipital lobe, would cause dilatation of the pupil. Stimulation of the anterior four-fifths of the cortex of the cerebellum has caused dilatation.

Voluntary Iris.—This term has been applied to those rare cases in which, without change in convergence or accommodation, the individual is able to contract and permit the pupil to dilate at will. The action is always bilateral. The writer has observed one such case.

Reaction of Pupil to Remedies.—Certain remedies have the effect of dilating the pupil—*mydriatics.* Other remedies contract the pupil—*miotics.* Both classes of drugs influence the ciliary muscle, as well as the muscles of the iris.

Mydriatics.[1]—Atropine, hyoscyamine, ephedrine, daturine, hyoscine (scopolamine), gelsemine, coniin, cocaine.

The effect of strong mydriatics, of which atropine is the type, is to produce marked active dilatation of the iris. This is accomplished (*a*) by paralyzing the terminal filaments of the motor oculi at or near the sphincter iridis, and (*b*) (since the dilatation is greater than is produced by simple paralysis of the third nerve) by stimulation of the terminal fibers of the sympathetic that supply the dilator iridis. When the pupil is dilated to the maximum, the patient experiences dazzling because of the flood of light that enters the eye.

Miotics.—Eserine, pilocarpine, mucaine, morphine, arecoline, nicotine.

Remedies such as eserine produce an active contraction of the sphincter iridis by stimulating the endings of the branches of the motor oculi, passing to the sphincter; and a passive effect by paralyzing the filaments of the sympathetic nerve which serve to innervate the dilator iridis. That the active contraction occurs is proved by the fact that the miosis, after the use of a miotic, is greater than that produced by section of the cervical sympathetic. The effect on the ciliary muscle is like that upon the sphincter iridis, and when used in too strong dose the patient experiences pain because of the excessive tonic contraction of these two muscles. The vasomotor nerve filaments in the iris are affected much as are the sympathetic nerve filaments that pass to the dilator. The caliber of the vessels is increased, and in some cases the resulting irritation is sufficient to cause the appearance of a plastic exudation—a mild plastic iritis. With narrowing of the pupil the amount of light that enters the eye is much reduced, and the patient may have difficulty to see sufficiently well on this account. Fuchs makes the statement that objects appear larger (macropsia) to the patient with miosis if contraction of the muscle of accommodation is also present.

[1] For a full discussion of the effects of mydriatics on the iris, see Wood, Therapeutics, Materia Medica, and Toxicology, Philadelphia, 1877, p. 244.

In miosis of light degree the pupil is often irregular in outline, without posterior synechiæ.

It must be remembered that in eyes predisposed to glaucoma the use of any mydriatic may bring on an acute attack. On this account it is necessary that the tension of the eye be tested, and if it be found to be increased, the mydriatic should not be employed. This applies particularly to individuals more than forty-five years of age. In the use of miotics this precaution is not necessary. However, the stronger miotics cause excessive contraction of the ciliary muscle, and occasion pain to the eye and temple, which lasts as long as the contraction lasts.

Crystalline Lens.—The crystalline lens is examined (*a*) by direct inspection; (*b*) by oblique illumination; (*c*) by transmitted light; (*d*) by transillumination. Lenses may be employed to assist in the examination by any of these methods. The examination will be greatly facilitated by dilating the iris *ad maximum.* Attention should be directed to the position of the lens; its relation to the iris, whether adherent or not; opacities on or injury to the capsule of the lens; opacities of the lens substance (cataract); thickness of the lens, etc. Changes in the shape of the lens, such as occur in the act of accommodation, may be studied by observing the relation of the images reflected from the anterior surface of the cornea, from the anterior surface of the lens, and anterior surface of the vitreous body (catoptric images). If the rays from a small, bright flame in a dark room be permitted to fall obliquely on the eye from a suitable distance (1 to 3 feet), a bright upright image is reflected from the external surface of the cornea; a larger, less distinct, upright image is reflected from the anterior surface of the lens, and a smaller, inverted image, perhaps slightly brighter than the second image, from the anterior surface of the vitreous body. Change in the relation of these images one to the other determines a change in the relative positions of the surfaces (see Accommodation).

Vitreous Chamber.—The contents of the vitreous chamber may be examined (*a*) by simple inspection, by which under favorable conditions, namely, with a largely dilated pupil and sufficient light, changes that occur in the anterior half of the vitreous chamber may be studied. The presence of opacities, foreign bodies, neoplasms, detached retina, etc., may be determined (*b*) by transmitted light, employing the ophthalmoscope and transillumination lamp. Both are valuable aids in the examination of this part of the eye.

Ophthalmoscope.—In using the ophthalmoscope the convex mirror usually gives the best results. If the plain mirror is used, the observer should be at about thirty centimeters distance. Lenses are required if the observer approaches closer to the eye; their strength should be varied to give the desired results.

Construction.—The original ophthalmoscope of Helmholtz[1] contained four thin plates of glass, the surfaces of which were carefully

[1] Helmholtz announced the principles of ophthalmoscopy and gave his ophthalmoscope to the world in 1851. To him belongs the great credit of the discovery of a means of examining the interior of the eye. Babbage devised an instrument for this purpose in 1847; but it was not given to the world.

polished, for his virtual source of light (the function of the ophthalmoscopic mirror now in use). These were selected because it was known that part of the light that falls on a surface of polished glass obliquely is reflected from that surface (part passes through); that more light is reflected when two or more surfaces are combined. The thin plates of glass were fastened together in a metal frame, which was attached to the centre of a metal disk. The plates of glass formed an angle of 56 degrees to the disk. The disk was perforated in its centre and bore a clip, in which lenses of different refracting powers could be placed. The walls of the cavity enclosed by the glass plates, retaining metal frame, and disk were blackened. When light from a candle or other source was permitted to

Fig. 92



Loring's ophthalmoscope.

fall on the glass plates at the proper angle, and the reflected light passed into the observed eye, the observer could see the details of the fundus, provided the proper lens was in the clip at the back of the instrument. Helmholtz placed a —10 lens in the clip, evidently using his accommodation. This instrument was cumbersome as compared with the instruments of today, but, although the illumination was weak, it gave very good results. In the ophthalmoscope of today the glass plates of Helmholtz are replaced by the mirror with a central opening (which may be fixed or tilting), the clip, and separate lenses by a modification of Rekor's disk. There are many excellent instruments now on the market; the Loring and Morton instruments (Figs. 92 and 93) are good

examples. The *sight canal* (through lens and mirror) should be short, in order that the light reflected from the fundus may not be cut off from entering the observer's eye when the instrument is used in the various positions necessary for viewing all parts of the fundus.

These ophthalmoscopes, in contradistinction to the electric ophthalmoscope (Fig. 94), depend for their illumination on a source of light not connected with the instrument; the source of light may be a candle,

Fig. 93



The Morton ophthalmoscope.

oil, gas, acetylene, or electric lamp, or daylight. The candle, oil, or electric light serve very well at the bedside; gas or electric light for the consulting room. The source of light should be so arranged that it can be moved readily, in order to obtain the most desirable position. It should be possible to increase or diminish the intensity of the illumination at will. The intensity of the illumination throughout the area under examination should be even.

Interpretation of Ophthalmoscopic Examination.—The value of an ophthalmoscopic examination depends on a correct interpretation of what is seen. This depends to some degree on the intensity and color of the light employed. A knowledge of what details can be seen better by subdued illumination and what details can be seen better by intense illumination comes largely from experience; it can be indicated here only in a general way. In general, when a mydriatic is not used, the examination is best made with weak illumination. If diffuse opacity of the cornea, aqueous humor, crystalline lens or vitreous body is present, or there are thin pseudomembranes in the vitreous chamber or neoplasms of the chorioid, intense illumination is desirable. Lights of different colors impart different appearances to the ophthalmoscopic image, changing the color of the image principally. The light obtained from the candle, oil, and the ordinary gas burner contains more yellow rays than does that obtained from electric lamps, acetylene gas, or incandescent gas burners (as the Welsbach lamp). The examiner will do well to confine himself to the use of the light to which he is most accustomed, in order to avoid error in his interpretation of the findings. The source of light, whether the patient is seated or is standing, should be at the side of the patient's head (corresponding to the eye to be examined when the direct method is employed; on the side most agreeable to the examiner when the indirect method is employed) on about the same level with the eye, a little behind and at such an angle to the vertical anteroposterior plane of the patient's head that the rays of light may fall on the ophthalmoscopic mirror and just clear the side of the patient's head. The room should be darkened, diffuse light being excluded. Unless a weak illumination is desired, the concave ophthalmoscopic mirror having a focal distance of 22 to 30 cm. is preferable to the plane mirror.

Fig. 94

The luminous ophthalmoscope.

Methods of Examination.—The examination of the interior of the eye should be preceded by an examination of the anterior segment of the globe by oblique illumination. Error will frequently be avoided if this is done. The examination should then proceed in the following order: (1) Examination of the media of the eye with the ophthalmoscopic mirror under proper conditions (see Direct Method, page 131); (2) examination by the indirect method; (3) examination by the direct method.

Indirect Method.—(For the optical principles involved, see page 106.) By this method a larger field is obtained than by the direct method, and a comprehensive idea of the condition of the fundus can be obtained

more quickly. The observer does not approach the patient's face so closely, consequently it is of advantage in examining the patient when in the recumbent position. It is often more satisfactory in examining the fundus in high degrees of myopia and astigmatism. The *finer* details of the fundus are better seen by means of the *direct* method in all cases, except in those possessing the errors of refraction last mentioned, because of the higher magnification, the direct method is also much to be preferred in determining errors of refraction. In making the examination by the indirect method, the examiner should be at a distance of 30 to 35 cm. in front of the patient. The position of the light may be varied to suit the

Fig. 95

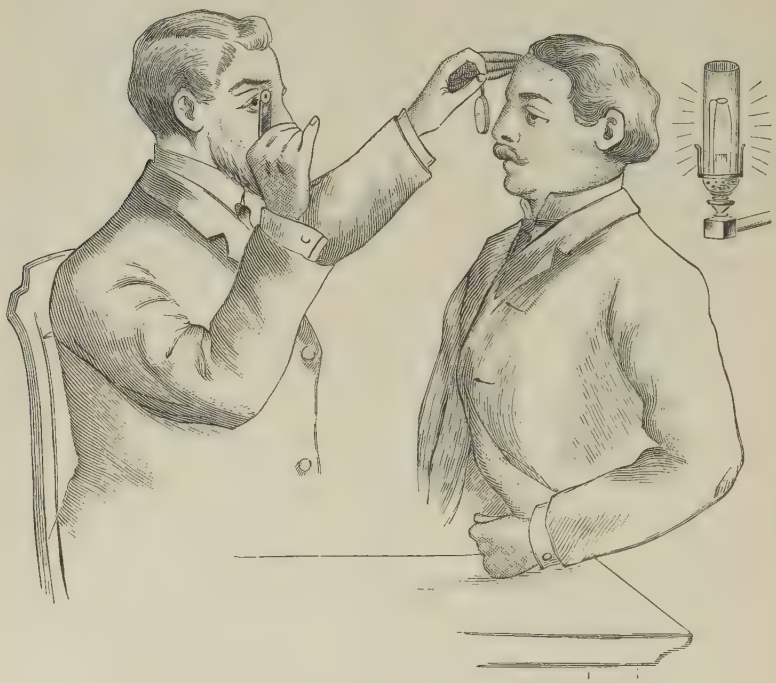

The indirect method of ophthalmoscopic examination. (Posey and Wright.)

convenience of the examiner. While it is desirable to use the corresponding eye in examining the right or left eye of the patient, it is not essential. The red reflex is obtained as by the direct method (see page 131). A convex lens of 13 to 16 D. focal power is interposed (the equator of the lens at right angles to the rays of light) between the patient's eye and the ophthalmoscopic mirror at about the focal distance of the interposed lens (6 to 8 cm.) from the patient's eye. (The most convenient size of lens is about 5.5 cm. in diameter.)

An inverted image of the details of that portion of the fundus visible through the pupillary area will be formed at a point corresponding approximately with the principal focus of the interposed lens, and will

be visible to the examiner (the examiner's accommodation being at rest) if the proper lens to render the rays of light coming from the inverted aërial image parallel, be rotated before the aperture of the ophthalmoscopic mirror. Ordinarily a + 4 D. lens is the proper one to use. By slightly varying the distance of the ophthalmoscope or of the interposed lens, or of both, from the patient's eye, a sharp image may be obtained. The optic disk is the objective point. A retinal vessel will probably be recognized first. This can be followed up until the disk is seen. From this point all parts of the fundus may be viewed by having the patient look in the desired directions. It is much easier to bring the different parts of the field into view by having the patient change his line of vision than for the examiner to change his position to the extent that would be necessary.

In recording the details of the image it must be remembered that the image is inverted, and that each side of the image corresponds to the opposite side of the fundus. It is much more difficult to master the indirect than the direct method. The reflexes from the interposed lens and the proper manipulation of this lens present many difficulties, but the advantages of this method are many, and facility in its use should be acquired.

Direct Method.—The patient, standing or comfortably seated, is directed to look straight forward and not to change the position of the eyes unless directed to do so. Dilatation of the pupil facilitates the examination and is often essential for the beginner.

If the examiner has any considerable error of refraction other than simple hyperopia or myopia, correcting glasses should be worn. He should place himself on the side of the patient corresponding to the eye to be examined, using the right eye for examining the right eye, the left for examining the left eye. Both eyes should be kept open in order to better relax the accommodation, except in the relatively rare cases in which the examiner cannot educate himself to suppress the image of one or the other eye, in which case the offending eye must be kept closed while using the other. The patient should keep both eyes open. In cases of squint the non-examined eye should be made to look in a direction that will cause the other eye to look straight forward. The examiner places the ophthalmoscope close to his eye so that the sight hole is opposite his pupil, and begins the examination at a distance of 40 to 50 cm. from the patient's eye. His line of vision should be at an angle of about 15 degrees to the temporal side of the patient's line of vision, in order that when the light is first reflected into the patient's eye it will fall on, or in the vicinity of the optic nerve, and not on the most sensitive part of the retina. The light is now reflected into the patient's eye, when the "red reflex" will be immediately observed, provided the media of the patient's eye are clear. The examiner should not employ his accommodation; if he is hyperopic or myopic, a suitable lens must be rotated behind the sighthole in the ophthalmoscope to correct the error.

The color of the reflex varies with the size of the pupil, the error of refraction, the transparency of the media, and the degree of pigmentation

of the membranes of the eye. With the mirror at the distance indicated, the reflex from all parts of the fundus is examined for the detection of opacities in the media. These usually appear black. If a blood clot, the reflex is red; if an exudate, gray or yellow. Detachment of the retina gives an uneven pearly gray reflex. Intra-ocular parasites or neoplasms give reflexes of various kinds. The reflex may be disturbed by irregularities in cornea or lens without opacification.

The patient's eye is now approached to within 2 or 3 cm., the patient's head being steadied by the free hand of the observer if necessary, and the optic disk sought for. From this objective point all parts of the

Fig. 96

The direct method of ophthalmoscopic examination. (Posey and Wright.)

fundus should be carefully examined. The foregoing has been written under the supposition that the *patient's* eye is emmetropic. In case he is hyperopic, or myopic in moderate degree, the observer may rotate suitable correcting lenses behind the sight-hole of the ophthalmoscope before proceeding with the examination. In high degrees of myopia, with or without astigmatism, it is often best to permit the patient to wear his own correcting lenses. Examination of the highly myopic eye by the direct method is difficult and not infrequently unsatisfactory.

This method is employed for determining the refraction of the eye (see Errors of Refraction and their Correction) and for determining the elevation of neoplasms, swollen nerve head, masses of exudation, new-

PLATE X

FIG. 1

Normal Eye Ground, Average Tint. (Posey and Wright.)

FIG. 2

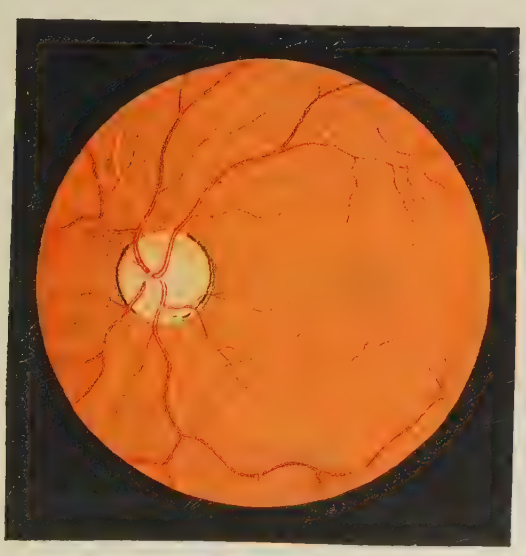

Normal Eye Ground, Brunette. (Posey and Wright.)

formed membranes, etc., above the level of the surrounding retina. In the latter case the table on a subsequent page gives the equivalent of differences in level, estimating from the emmetropic fundus, expressed in dioptres and millimeters.

In examining with the direct method, the vessels at the margin of the disk (those nearer the observer) appear to move in the direction opposite to the movement of the observer's eye; in examining with the indirect method, the vessels at the margin of the disk appear to move in the direction opposite to that of the biconvex lens used in the examination. This phenomenon is due to parallactic displacement (see page 146).

Luminous Ophthalmoscope.—In this instrument a small electric light, placed in the axis of the handle of the instrument, supplies the illumination. It may be used for all methods of ophthalmoscopy. It is very useful at the bedside, in examining the eyes of infants, and for cases in which intense illumination is required, as in neoplasms, opacities of vitreous, etc. (Fig. 94).

Skiascopy or the Shadow Test (*Retinoscopy*).—For the optical principles involved, see page 106. The application of this method of determining refraction is considered in the chapter on anomalies of refraction and their correction.

Retina and Chorioid.—The examination of the retina and chorioid is made by means of the ophthalmoscope and the lamp for transillumination.

Fundus Oculi.—Normal Appearance.—When the interior of the normal eye is illuminated, light is reflected from the membranes of the eye. If the illumination is sufficiently intense, the reflex from retina, chorioid, and sclera combined is red in color ("red reflex") when viewed through the pupil. The ordinary way of obtaining this reflex is by means of the ophthalmoscope.

Color.—The color of the reflex from the fundus oculi is due to the blood-vessels of the retina and chorioid and their contents, to the pigment in retina and chorioid, and to the connective tissue of chorioid and sclera. The variation in color is due to variation in pigmentation. In the albino the fundus reflex is a light pink color; in the negro, of a dark reddish slate-color. There are all degrees of variation between these two. Inspection with the plain ophthalmoscopic mirror at a distance of 30 cm. gives a uniform red reflex in the normal eye. In high degrees of myopia and in some cases of hyperopia *details of the fundus* more or less distinct may be seen. When the ophthalmoscope is employed in the "direct" or "indirect" method for examining the normal eye, the details of the fundus should be absolutely clearly visible.

Optic Disk.—The end of the optic nerve, where it shows in the fundus oculi, is termed the *optic disk.* It presents a nearly circular area, pink in color, sharply defined, measuring perhaps a trifle more than 1.5 mm. in diameter, situated a little to the nasal side of the posterior pole of the eye, its horizontal meridian lying 0.75 to 1 mm. above the horizontal meridian of the globe. The deeper color of the surrounding

retina is sometimes separated from the disk by a very narrow pigmented ring or crescent at the nasal side—the *chorioidal ring* or *crescent*—or by

Fig. 97

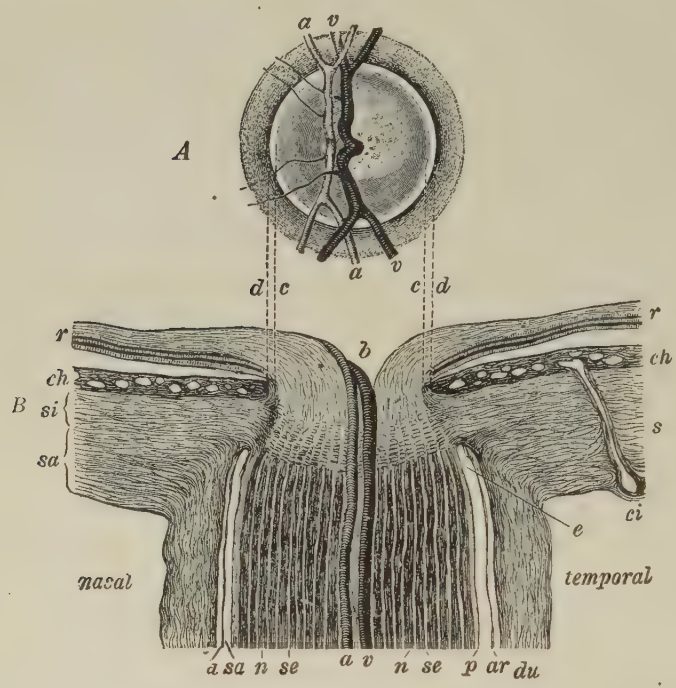

Head of the optic nerve: *A*, ophthalmoscopic view. Somewhat to the inner side of the centre of the papilla the central artery rises from below, and to the temporal side of it rises the central vein. To the temporal side of the latter lies the small physiological excavation with gray stippling of the lamina cribrosa. The papilla is encircled by the light scleral ring (between *c* and *d*) and the dark chorioidal ring at *d*. *B*, longitudinal section through the head of the optic nerve. Magnified 14 x 1. The trunk of the nerve up to the lamina cribosa of medullated nerve fibers (*n*). The clear interspaces (*se*) separating them correspond to the septa composed of connective tissue. The nerve trunk is enveloped by the sheath of pia mater (*p*), the arachnoid sheath (*ar*), and the sheath of dura mater (*du*). There is a free interspace remaining between the sheaths, consisting of the subdural space (*sd*) and the subarachnoid space (*sa*). Both spaces have a blind ending in the sclera at *e*. The sheath of dura mater passes into the external layers (*sa*) of the sclera, the sheath of pia mater into the internal layers (*si*), which latter extend as the lamina cribrosa transversely across the course of the optic nerve. The nerve is represented in front of the lamina as of light color, because here it consists of non-medullated and hence transparent nerve fibers. The optic nerve spreads out upon the retina (*r*) in such a way that at its centre there is produced a funnel-shaped depression, the vascular funnel (*b*), on whose inner wall the central artery (*a*) and the central vein (*v*) ascend. The chorioid (*ch*) shows a transverse section of its numerous blood-vessels, and toward the retina a dark line, the pigment epithelium; next the margin of the foramen for the optic nerve and corresponding to the situation of the chorioidal ring the chorioid is more darkly pigmented. *ci* is a posterior short ciliary artery which reaches the chorioid through the sclera. The posterior portion of the scleral canal forms a funnel directed backward, the anterior portion a funnel directed forward. The wall of the anterior funnel when seen in front appears to have the extent (*cd*), and corresponds to the scleral ring visible by the ophthalmoscope. (Fuchs.)

a narrow white annular band or crescent—the *scleral ring* or *crescent*. These features may vary considerably in size and position, or may be

absent. The outer border and the centre of the disk are slightly paler than the intervening zone, because of the greater depth of the tissue of the disk seen throughout this zone and the consequent greater number of capillaries.

Physiological Depression.—The central retinal vessels pierce the disk near its centre and usually slightly to the nasal side. The artery and vein each appears, as a rule, as two principal branches, coming from and disappearing into a funnel-like depression, the *physiological depression.* Branching of artery and vein may not take place until they emerge on the disk, or the branching may take place deep in the nerve and emerge on the disk at or remote from the centre. Not infrequently (7 to 10 per

Fig. 98

Cilioretinal artery. From the outer and lower margin of the papilla rises a cilioretinal artery (*a*) making a hook-like bend. In this case it is larger than usual, because it is destined to replace the main infero-external (inferior temporal) branch of the central artery, which branch is wanting. (Fuchs.)

Fig. 99

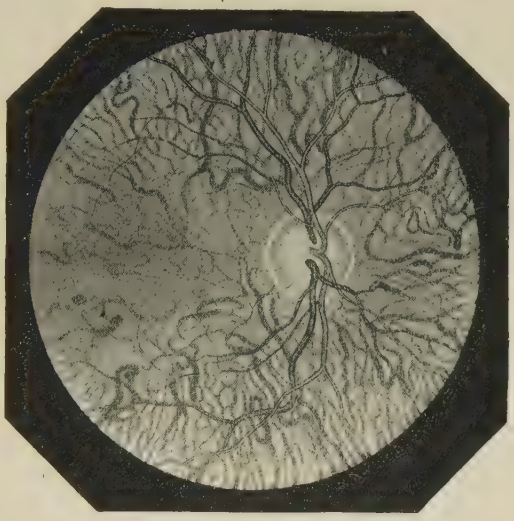

Ophthalmoscopic representation of the eye ground of an albino. (Jaeger.)

cent.) one or two arterial twigs derived from a ciliary artery or from the circle of Hyrtl appear on the temporal border of the disk and proceed toward the temporal region. The principal arterial and venous branches again divide on the disk, leaving it at its upper and lower margins. The color of the arteries is lighter than that of the veins; both show a double contour.[1] Arteries and veins may intertwine on the disk.

In many eyes the physiological depression in the disk appears as a *cup* (*physiological cup* or *excavation*), on account of the absence of the medullary sheaths of the nerve fibers and the transparency of axis cylinders and surrounding tissues; the trabeculæ of the lamina cribrosa appearing at the bottom of the apparent cup or excavation. The extent

[1] The double contour or streak of light is apparently due to the reflection of light from the anterior surface of the blood column in both arteries and veins. Light reflected from the lateral surfaces of the blood column does not reach the eye.

of the physiological cup is seldom more than two-thirds of the diameter of the disk.

The blood-vessels extend to the periphery of the fundus, branching as they proceed. The arteries pursue a straighter course than the veins.

In colored individuals and in brunettes the color of the fundus outside of the disk and macula lutea is often quite uniform. Examination by the "direct method" may disclose a very fine stippling, due to the visible pigment cells of the retina. In some cases the fundus appears mottled (tessellated fundus), the deeply pigmented spaces between the larger chorioidal vessels showing through the pigment layers of the retina. As the pigmentation of chorioid and retina decreases, in the gradations from the negro to the albino, the chorioidal vessels become more prominent until, in the blond and in the albino, the chorioidal vessels are very clearly seen (Fig. 99).

Region of Macula Lutea and Fovea Centralis.—The region of the macula lutea, or yellow spot, and of the fovea centralis is marked by the absence of blood-vessels and a slightly deeper tone of color. The fovea centralis, situated about two and a half disk diameters to the temporal side of and slightly below the horizontal meridian of the disk, presents itself as a minute bright point or crescent, the *foveal reflex*, surrounded by a more or less well-defined light circle. The bright point or crescent is due to direct reflection of light from the bottom of the depression in the retina, and the annular ring to the more diffuse reflection from the border of the crater-like depression in the retina—the macular reflex. The crescent and the point of direct reflection coming from the fovea centralis change their position as the line of vision of the observer is changed. The circular macular reflex is larger and broader in children than in adults; indeed, it is often absent in adults. The macula lutea sometimes contains a number of minute spots or granules (Gun's dots), which may be almost black, light colored, or glistening.

The details of the macular region and, in fact, of the entire fundus can be best studied by means of the direct method. The illumination must be subdued for the finer details, and, because of the contraction of the pupil on entrance of light to the eye, the iris should be under the influence of a mydriatic. The macular and foveal reflexes are best seen in young individuals; the macular reflex disappears in the aged, but the foveal reflex can usually be made out.

In young individuals the perivascular lymph spaces in the anterior layers of the retina, particularly at the macula lutea, impart a peculiar "shot-silk" appearance to the fundus, due to the peculiar reflection of light.

Field of Vision.—The field of vision is the extent in space through which objects can be seen, either distinctly or indistinctly, when one point in space is regarded, or "fixed."

A simple method of measuring the extent of the field of vision is by means of the fingers. The observer places himself directly in front of the patient at a distance of about one foot (the standing posture is best)

and causes the patient to look directly at his eye. If the left eye is being examined, the right eye of the patient and the left eye of the observer must be closed. The hand of the observer is now approached toward the eyes in turn from all directions, in a plane midway between the planes of the face of the patient and of the observer; the fingers should be in advance and moving slightly. If the patient's field of vision corresponds in extent to that of the observer, both will perceive the approaching fingers at the same instant. Gross defects in the field of vision for form may be detected in this manner. The method can be easily employed with patients who are confined to bed.

Fig. 100

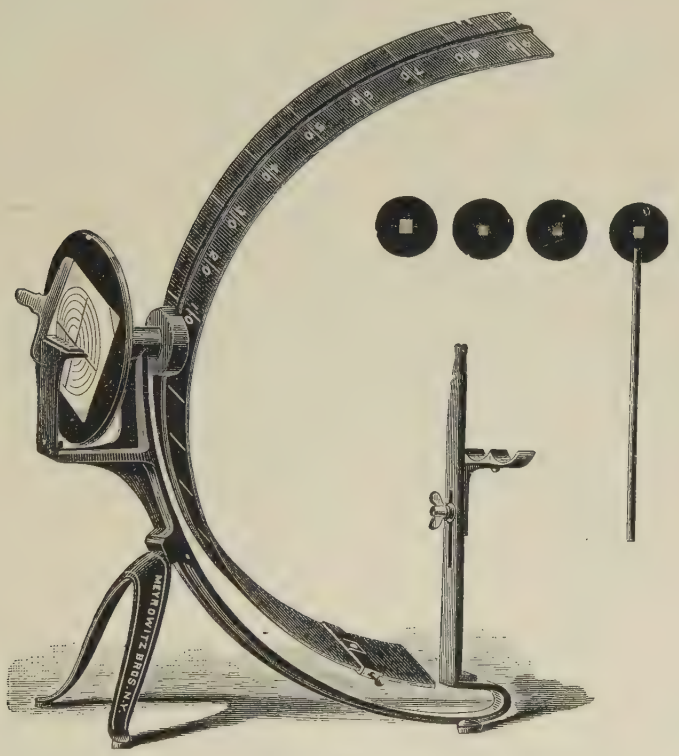

The Meyrowitz registering perimeter.

If the vision is so defective that the hand cannot be readily seen, a candle-flame or small incandescent lamp may be substituted. In this manner the field of vision is obtained in individuals with cataract.

Perimetry.—For the accurate measurement of the field of vision instruments known as *perimeters* are employed, and the process is known as *perimetry*. The perimeter is essentially an arc of half a circle or a quadrant, marked in degrees and fixed to a point around which it may be revolved. The radius of the perimeter is usually 30 cm. The instrument is so arranged that the eye of the patient may be held at the centre

of curvature of the arc of the perimeter, the centre of the pivot around which the arc revolves and the visual line of the patient being in the horizontal plane.

A number of excellent perimeters have been devised. Those of Skeel and McHardy are self-registering. A few are provided with cells in which the blank chart may be placed for facility in recording. Priestley Smith's is of this construction. The self-registering perimeters and some others are provided with test object carriers which move on the arc of the perimeter (Fig. 100). The test object can be manipulated much more rapidly if held by the hand of the examiner. The hand perimeter of Schweiger (Fig. 101) is an excellent instrument for use with intelligent patients. Accurate measurements may be obtained with the expenditure of a minimum of time.

Fig. 101



Schweiger's hand perimeter.

The field of vision may be taken on a plane surface placed parallel to the plane of the face, but as the field of vision extends to 90 degrees to the temporal side, it will be readily seen that the full extent of the field cannot be taken on such a surface if the visual line remains perpendicular to the surface. However, if the point of fixation is moved 30 degrees to the nasal side the entire extent of the temporal half of the visual field can be mapped out on the plane surface. The size of the surface required to map out the field of vision would depend on the distance that the eye examined was from the surface. Thus, a surface 75 cm. square (about 30 inches) would permit the recording of the field of vision to 75 degrees from the fixation point if the eye was 10 cm. from the surface; 60 degrees if at 20 cm., and 50 degrees if at 30 cm. in every direction. For the accurate outlining of small defects in the visual field and for determining the line between the seeing and the blind half of the field in hemianopsia, the flat surface can be employed to advantage.

A large screen may be employed, as suggested by Bjerrum, the patient being placed at a distance of 2 m. from the surface. Defects which at 30 cm., the distance at which the perimeter is ordinarily employed, would escape notice, would under these conditions be easily detected. At a distance of 2 m. the blind spot of Mariotte appears to be 20 cm. in diameter, while with the ordinary perimeter it is only 2.5 cm. in diameter. Bjerrum uses a black surface, the test objects being disks of ivory measuring 1 to 10 mm. in diameter, held on slender black rods. This method is

valuable in determining small defects. Bjerrum has employed it largely in determining the enlargement of the blind spot of Mariotte in glaucoma.

Forster's perimeter was so arranged that the patient fixed a small ivory ball which was placed excentrically 15 degrees to the nasal side of the centre of the perimeter arc, making the physiological blind spot the centre of the field.

Perimeters have been constructed in which the pivot around which the arc of the perimeter revolves is perforated. The patient is directed to look through the small hole and fix an object in a distant part of the room. This device is resorted to in order to prevent the contraction of the pupil which accompanies accommodation for an object at 30 cm.

Fig. 102

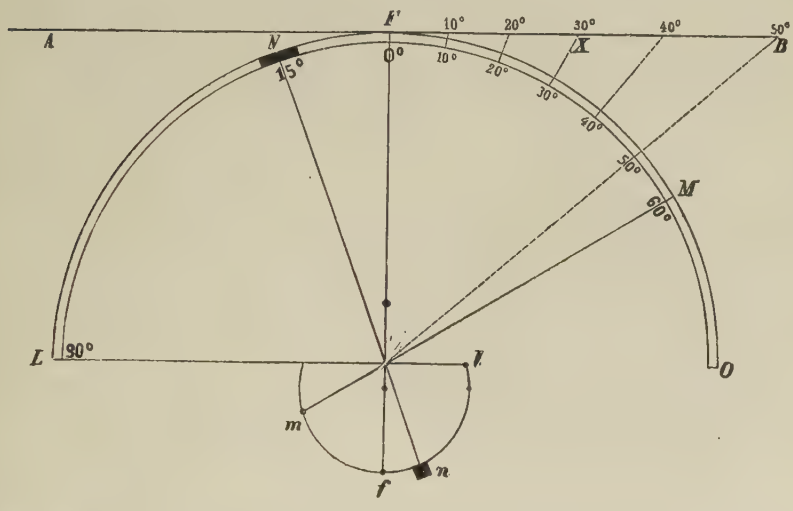

Monocular field of vision, horizontal meridian projected on an arc *O L* and on a tangent *A B*. *L*, *n*, lateral limit; *M*, *m*, median limit; *F*, *f*, point of "fixation;" *N*, *n*, physiological blind spot.

Examination.—The patient is placed in position with his back to the light. The eye not under examination must be covered. The eye to be examined is adjusted properly and the patient is requested to "fix" the centre of the pivot of the perimeter arc which should bear a white object 5 mm. in diameter. The test object, which may be a white ball, 1 cm. in diameter, mounted on a small black rod, or a white patch 1 cm. square mounted on a small black disk, should be approached from the end of the arc and the point where the patient is first able to see the test object or to detect the color of the test object when the color fields are being taken, should be noted. In making the examination, the patient's eye must be carefully watched to detect any movement, as a change in the point of fixation will give inaccurate results.

In slightly amblyopic eyes, from any cause, and in myopic eyes with a far point of less than 30 cm., and in cataractous eyes, the test object is sometimes not seen with sufficient distinctness to permit of an accurate

determination of the extent of the visual field. In these cases a small flame may be used as the fixing point. In high myopia a perimeter with a radius of curvature of 10 cm. (Purkinje) may be employed.

Limits of Normal Field.—The limit of the normal field of vision is given differently by different observers:

	Inward.	Outward.	Upward.	Downward.
Purkinje[1]	60	100	60	80
Young (1801)	60	90	50	70
Mauthner	55	88	54	70
The limits, as ordinarily accepted are	60	90	55	70

Encroachment of the tissues at the outer angle of the upper lid and brow, of the bridge and end of the nose, and of the lower lid and tissues of the cheek may slightly limit or obstruct the field of vision. In order to disclose the entire field of vision for form it is expedient to follow the suggestion of Mauthner, namely, not to "fix" the pivot point of the perimeter, but to attach a piece of white wax to one arm of the perimeter at 30 degrees from the centre and with the head in the ordinary position to "fix" this eccentric ball of wax measuring the full extent of the field as indicated by passing the test object along the opposite arm of the perimeter. Measuring in this way, Mauthner has found a maximum field as represented in Fig. 103, the gray border representing the maximum form field, the black central portion the field obtainable when the individual fixes the pivot around which the arc of the perimeter revolves. This portion Mauthner terms the true field of vision, while the outer maximum zone is termed the relative field of vision.

Fig. 103

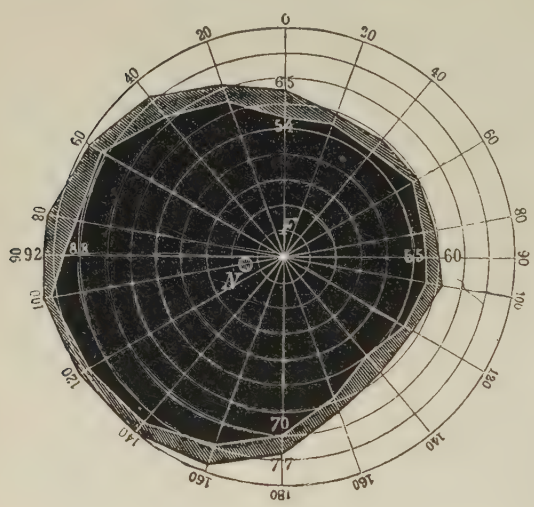

Field of Vision for Light Perception.—It has long been known that the field of vision for light perception is much greater in extent temporally and below than upward, nasally, or nasally and below. The difference in extent of light perception is estimated by Donders as 20 degrees to 22 degrees; by Mauthner as 30 degrees. This indicates that the light-perceiving elements of the retina do not extend as far toward the anterior portion of the eye in the temporal half as they do in the nasal

[1] Purkinje used a perimeter with a radius of 10 cm. He was nearsighted and measured his own field.

half of the retina, or that the fovea centralis is placed considerably to the temporal side of the posterior pole of the eye. Mauthner attempts to prove that a difference of 5 degrees may be accounted for in this way.

Blind Spot.—The physiological blind spot (Mariotte's blind spot) in the field of vision, described by Mariotte in 1668, corresponds to the

Fig. 104

Mariotte's blind spots. Experimental figure.

entrance of the optic nerve (optic disk). Since the horizontal plane which cuts the nodal point of the eye and the centre of the optic disk forms an angle of 3 degrees with a similar plane cutting the fovea centralis, the centre of the physiological blind spot occurs 3 degrees below the horizontal meridian of the field of vision, and as in normal eyes the angle between the plane which passes through the fovea centralis and the nodal point of the eye and a similar plane which passes through the centre of the optic disk is 15 degrees, the centre of the physiological blind spot is situated 15 degrees to the temporal side of the vertical meridian of the field of vision. The blind spot is usually circular and measures about 2.5 cm. at 30 cm. from the cornea. In some cases the outline of the blind spot is slightly oval. The contour of the blind spot in moderate illumination is not regular; two or three short projections marking the prolongations of the large branches of the arteria centralis retinæ may be determined. The field of vision of the hyperopic eye is greater than in the normal eye, and that of the myopic eye is less.

Fig. 105

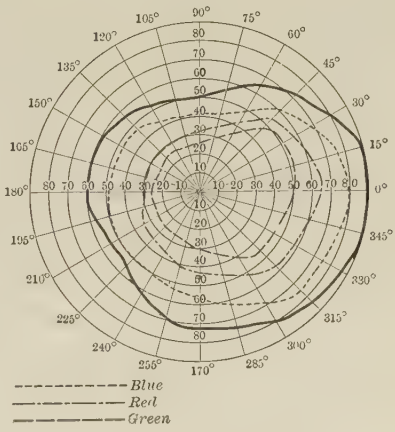

Normal extent of color fields.

With a dilated pupil the field is larger (about 2 degrees) than it is with a small pupil.

The extent of the field of vision is recorded on charts bearing

meridional lines at angles of 15 or 30 degrees and concentric lines in circles placed at regular intervals, conventionally marked to represent interval of 10 degrees.

Field of Vision for Color.—The visual fields for colors are tested by using test objects of the appropriate color. The test object is either a colored ball 1 cm. in diameter or a colored square of 1 cm. Small defects in the color fields are determined by the use of a ball or square measuring 5 mm. The mean normal color fields, when determined with a test object of 1 cm. in diameter or of 1 cm. square, are:

	Outward.	Inward.	Downward.	Upward.
For blue	80	45	58	40
For red	65	30	45	33
For green	50	25	30	27

The field for yellow is very similar to that for blue. Although the extent of the fields for color are as represented above when examined as indicated, it is well known that the fields for the different colors extend almost, if not quite, to the limit for form if the colored area is sufficiently large and well illuminated.[1]

Fig. 106

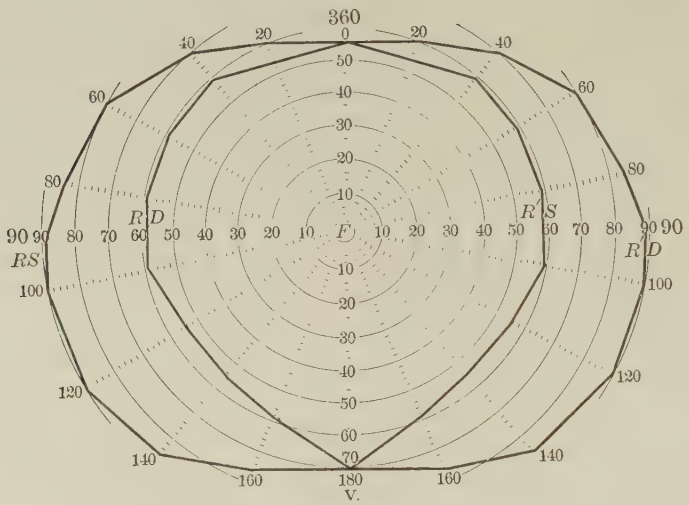

Combined fields of vision. (From Wilbrand and Saenger, after Förster.)

Combined Field of Vision.—We have heretofore considered the field of vision peculiar to one eye—the monocular field of vision. When the fields of vision are considered together, the total is known as the *combined field* of vision. The combined field is 180 degrees in extent in the horizontal meridian, and in the vertical meridian reaches a

[1] Chodin, Arch. f. Oph., Band xxiii; Landolt, A Manual of the Examination of the Eye; Grover's Subjective Sensations of Sight and Sound, London, 1904.

maximum corresponding to that of the single field of vision, namely, 125 degrees. It is evident that the combined field of vision presents a portion of the field in which the monocular fields overlap, forming a field of vision common to both eyes, the *common field of vision.* This comprises the central portion of the combined field of vision, and measures 120 degrees in the horizontal meridian.

Pathological Defects of Field of Vision.—These occur whenever there is any interference with the function of the perceptive elements of the retina, whenever there is any interruption in the path of conduction from the retina to the cortical cerebral visual centre, and whenever there is any defect in the cortical visual centre. The defects in the fields of vision due to defects in the retina, visual tracts, or cortical visual centre are often characteristic of the site of the lesion, thus making the determination of the defect in the field of vision of great diagnostic value. It is therefore very important that a careful determination of the size, shape, and location of defects in the fields of vision should be made and recorded, and, in many cases, that the fields of vision should be frequently examined for the purpose of noting changes that may take place.

"Functional" Disturbances.—Disturbances of the fields of vision that are "functional" in nature are experienced by nervous subjects. The phenomena are very varied—central scotomata, marked concentric limitation of the fields of vision, loss of the upper or lower halves of the fields of vision, homonymous hemianopsia. Other phenomena, as binocular or monocular diplopia, photopsia, visual hallucinations, pain in and about the orbits, macropsia, micropsia, the disappearance of objects looked at, and temporary loss of accommodative power are also experienced by these subjects. (A more complete description of these phenomena will be found under the headings Asthenopia and Hysteria.)

Scotomata.—Defects in the fields of vision are known as scotomata. In regard to the degree of the scotoma, they are classified as *absolute,* total absence of perception of light or form; *relative,* absence of perception of some or all colors, but retained or diminished perception for form and white; *indistinct,* diminished perception of white and colors, but not entire loss.

Defects in the fields of vision are classified in regard to their relation to the point of fixation, as *central,* indicating that the point of fixation, the fovea centralis, is involved; *pericentral,* the point of fixation lying in the centre of the scotoma; *paracentral,* the fixation point lying at or near the edge of the scotoma; *ring scotoma,* zonular defects encircling the point of fixation, removed to a greater or less extent; *peripheral,* situated at the periphery of the field.

Scotomata are classified in regard to form as *irregular,* varying much in shape; *zonular,* affecting a zone of the field only; *sector,* involving a sector of the field; *hemi-,* involving one-half of the field of vision (hemianopic field of vision); *crescentic,* crescentic portion of the periphery of the field.

Scotomata are classified, according to the sensation imparted to the

patient, into *positive*, the patient perceives a dark spot or cloud in the field of vision projected into space; *negative*, the patient recognizes a blurring or absence of images only and is not conscious of a blind spot.

Scotomata are spoken of as *unilateral*, affecting but one eye; *bilateral*, affecting both eyes; *symmetrical*, affecting corresponding portions of the retinæ (or fields of vision) of both eyes; *hemianopic*, affecting one-half of the field of vision; *scintillating* or *flittering* scotomata, transient scotomata with irregular, serrated, changing borders.

Enlargement of Blind Spot.—Under certain conditions the blind spot of Mariotte is increased in size, as in myopic cases, peripapillary chorio-retinitis, after papillitis, during the progress of which the chorioid and retina at the margins of the disk are disturbed; in cases of persistent opaque nerve fibers; connective tissue bands extending from the disk in congenital coloboma of the sheath; in glaucoma.

Ring Scotomata.—The intermediate zone of the retina (that part which lies between the fifteenth and forty-fifth degrees on the perimeter) not infrequently shows peculiar defects. This corresponds to the zone in the chorioid, which is supplied by the terminal branches of the short ciliary arteries. Disease of these branches and of their dependent capillaries produces the so-called ring scotomata which vary much in shape.

Hemeralopia.—There are certain pathological conditions in which the fields of vision for white are normal in extent by bright light and are greatly reduced by subdued light. These are (*a*) in hemeralopia from malnutrition; (*b*) in the early stage of optic nerve atrophy; (*c*) in the early stage of glaucoma, when an acute attack is not present; (*d*) in some cases of hysteria and other functional nervous diseases. The relation between the field for white and for colors is often greatly disturbed, the color fields becoming disproportionately reduced. The cause for this effect on the fields of vision may be termed "torpidity" of the retina in *a*, hemeralopia induced by malnutrition without permanent anatomical changes, recovery being complete as a result of proper diet and treatment. The cause in *b* is a lessening in the functionating retinal elements at the periphery of the retina, by the death of neurons centrally or peripherally, or the atrophy of nerve fibers. The hemeralopia of *c* is often induced by slightly excessive intra-ocular tension, attended in some cases by death of nervous elements. In *d* the hemeralopia is due to "torpidity" of the retina consequent on the general torpid condition of the central nervous system. Hemeralopia is a symptom in retinitis pigmentosa, chorioretinitis syphilitica, chorioiditis disseminata, high grade myopia, and senile eyes.

Defects of the Periphery of the Visual Fields.—(1) Equally concentric contraction; (2) general concentric contraction with sector-like defects; (3) sector or other shaped defects extending from the periphery.

Defects Due to Diseases of the Retina and Chorioid.—The nutrition of the retina depends on two systems of vascular distribution, that of the chorioid and of the retina itself. The chorioid, through its chorio-capillaris, nourishes the outer layers of the retina. An interference with

the circulation of the chorio-capillaris in part or in whole, produces definite scotomata in the field of vision corresponding with the area affected, because of death of the outer layers of the retina over that area. Obstruction of a branch of the central artery of the retina produces a positive scotoma corresponding to the area of the retina supplied by the arterial branch affected, because of death of the ganglion cells (neurons) in that area. Wilbrand[1] gives a table on which the following is based:

Diseases of the Optic Nerve, Optic Papilla, and Innermost Layers of the Retina.	Diseases of the Outer Layers of the Retina and of the Chorioid (Retinochorioiditis).
Perception of Light.	
Dark objects on a white ground seen readily.	Torpor retinæ.
Field of Vision by Diminished Light.	
As in the normal eye.	While by full daylight few defects are found, by reduced light concentric diminution or scotomata will become evident and the defects detected by full daylight will become much more marked.
Form of Defect of the Visual Fields.	
Concentric limitation; sector-shaped defects; color perception diminished; central scotomata.	Large irregular defects; circular scotomata.
Nature of Scotomata.	
Negative.	Often positive.
Central Vision Acuteness.	
Not greatly affected by diminished illumination; nyctalopia.	Diminished by diminished illumination; hemeralopia.
Perception of Color.	
The color perception gradually diminishes; green goes first, followed by red; blue last; in retrobulbar optic neuritis, central defects for color.	Loss of color perception corresponds more closely with loss of light perception; color defects more apparent by diminished than by full daylight; in disturbed portions green may appear bluish, yellow reddish, violet gray.
Metamorphopsia (Retinal).	
Not present.	Common.

Position of Opacities in the Interior of the Eye.—The position or location of opacities in the interior of the eye is determined by the relation of the opacity to certain known fixed points. (The methods of deciding the location of foreign bodies in the eye are described in the chapter on Foreign Bodies.) One of these points is the iris. It will be evident by simple inspection whether the opacity is situated in front of or behind the iris. The exact location when behind the iris is not always easy to judge without determining its relation to a point more deeply situated.

[1] Norris and Oliver, vol, ii, p, 215.

The second point of value is the centre of curvature of the cornea. The radius of curvature of the anterior surface of the cornea varies from 7.607 mm. to 8.01 mm. (Donders), a fair average being 7.8 mm. (Helmholtz gives 7.829 mm. as the average radius). When the eye is observed through the aperture of an opthalmoscopic mirror, the patient being in a dark room with the light at his back, the pupil more or less dilated, a red reflex from the fundus will be obtained under

Fig. 107



Determination of the position of opacities by their relation to the corneal reflex: *a* and *b*, position of reflex: *c*, referred position of reflex; *x*, 1 and 2, opacities.

ordinary circumstances and a sharp minute reflection of the light from the mirror, coming from the surface of the cornea will be observed.

The visual line of the observer forms a "normal" to the surface of the cornea where this reflex appears, which, if extended, would cut the centre of curvature of the cornea. This is, in fact, the point to which the reflex is referred (Fig. 107). Opacities visible to the observer situated anterior

Fig. 108

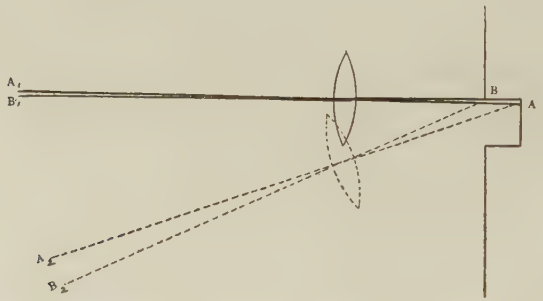

Parallactic displacement by the indirect method. The image is inverted.

to the centre of curvature of the cornea appear to move with the cornea whenever the patient's eyeball is rotated, or the observer changes the position of his head. Opacities situated back of the centre of curvature of the cornea appear to move in a direction opposite to the movement of the cornea. The extent of the arc through which the opacity appears to move will serve to determine with some degree of accuracy (particularly for the opacity situated anterior to the centre of curvature of the cornea)

the location of the opacity. Repeated measurements have determined the average distance of the posterior surface of the crystalline lens to be 7.6 mm. back of the anterior surface of the cornea. Since the arc through which an opacity moves is relative to the centre of curvature of the cornea, on movements of the eye it will be seen that opacities at or near the posterior surface of the lens would appear to move but little in relation to the reflex referred to.

The third point of value from which to judge the location of opacities is really the plane of the retina, including the optic disk. Location is determined by parallactic displacement (Fig. 108); and by the difference in the refraction of the eye at the retinal plane and at the location of the opacity as determined by use of the ophthalmoscope in the direct method.

Form Sense.—The ability to recognize the form of objects is known as the form sense, and its acuteness is termed visual acuity.

Visual Acuity.—It is measured by certain standard test figures, "test types" of the dimensions suggested by Snellen (Fig. 109) being most in use. It has been found by experimentation that the normal human retina is capable of distinguishing separate luminous points, when the rays of light which emanate from them subtend an angle of one minute as they intersect the anterior nodal point of the eye (see page 99) when the image falls on the fovea centralis.

Fig. 109

Snellen's test types.

Fig. 110



The visual angle.

Test Letters.—Acting on this knowledge, Snellen constructed test letters, each bar and space of which would subtend an angle of one minute at the distance at which the letters were to be read; the entire letter would therefore subtend an angle of five minutes. The *test card* (Fig. 111) is supplied with letters of different sizes, the distance at which each line of letters subtends the required angle being indicated. Since the effort of accommodation in the eye that has no error of refraction is not exerted at a distance of 6 m. and beyond, the test card for determining the acuity of vision for distant objects is placed at 6 m., and the patient is requested to read the letters, the card being properly illuminated. The ability of the patient to distinguish the letters is expressed in fractions, the *distance at which the test card is placed* being the numerator, and the *distance at which the letters dis-*

tinguished subtend an angle of five minutes the denominator; thus, if the letters that subtend an angle of five minutes at 6 m. are distinguished by the patient with the test card at six meters' distance, the acuity of vision is represented by the fraction $\frac{6}{6}$. If the patient cannot distinguish the largest letters on the test card at 6 m., the distance should be reduced until the letter can be seen; thus, if the letter that should be seen at 60 m. is seen only at 2 m., visual acuity equals $\frac{2}{60}$.

Fig. 111.

Test card for distant vision.

In English-speaking countries the metric system is but little used; test cards are often marked according to the foot system. The equivalents are given in the following table:

$\frac{6}{60} = \frac{20}{200}$ the largest letter on test card
$\frac{6}{36} = \frac{20}{120}\ (\frac{20}{100})$
$\frac{6}{24} = \frac{20}{80}\ (\frac{20}{70})$
$\frac{6}{18} = \frac{20}{60}\ (\frac{20}{50})$
$\frac{6}{12} = \frac{20}{40}$
$\frac{6}{9} = \frac{20}{30}$
$\frac{6}{6} = \frac{20}{20}$
$\frac{6}{4.5} = \frac{20}{15}$
$\frac{6}{3} = \frac{20}{10}$

English test types are often arranged to correspond to the fractions in brackets in the part of the card indicated. In certain cases the visual acuity exceeds the standard; for the purpose of determining this, letters that subtend an angle of less than five minutes at the standard distance of 6 m. should be placed on the test card.

Test Letters for Illiterates.—For illiterate individuals, test cards which bear dots placed at proper intervals (Buchardt's International tests) to conform to the required angulation may be employed.

The unfinished black letter E in various sizes to conform to the Snellen scale, arranged with the open side up, down, to the right, and to the left, makes a serviceable test card for illiterates. Dr. Wolffberg, of Breslau, has constructed a card bearing pictures of well-known objects arranged to conform to the standard angle as nearly as possible; this is of value in testing the visual acuity of children.

Testing Diminished Vision.—In testing diminished vision, the extended fingers against a dark background are often employed; the extended fingers should be seen at approximately 60 m., and may be recorded as V = F/s (F = fingers; s = the denominator, being the number of meters at which they are counted).

In testing the acuity of vision at the *reading* distance, small test type or figures of sizes to subtend an angle of 5 minutes at from 0.25 m. to 5 m. are employed; those of Snellen and of Jager are most in use.

Central Vision.—In testing the vision of the normal eye the acuity of vision is determined when the image of the test letters falls on the fovea centralis; this is termed central vision.

Eccentric Vision.—In certain eyes, in which the fovea centralis is defective, the image that is recognized does not fall on the fovea centralis, but to the side, above or below; this is known as eccentric vision, and should be so recorded.

Light Sense.—This consists in the power of the retina and cerebral centres to appreciate variations in the intensity of light. Some writers (Fick) have made a distinction between the power to distinguish the effect produced by the smallest possible quantity of light in the presence of otherwise absolute darkness, which is termed the "*sense of stimulation*," and the power to distinguish small shades of difference in the illumination of objects, which is termed the *sense of contrast or differentiation.* In one sense both depend on degree of illumination; however, we can readily conceive that the power to distinguish the presence of light in an otherwise dark chamber may not be the same as the power to differentiate between the degrees of illumination of objects.

Fig. 112

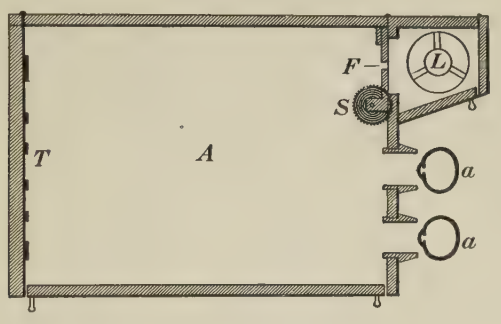

Photometer of Förster. (Fuchs.)

Photometer.—The minimum stimulus required may be tested by Förster's photometer[1] (Fig. 112.) "This consists of a box $\frac{1}{3}$ m. long, $\frac{1}{4}$ m. broad, and $\frac{1}{6}$ m. high, painted black on the inside. On one side are two peek holes, *a a*, for the eyes, with a curtain, to shut off either eye at will. Next to these holes is a window, *F*, covered with oiled paper and so arranged by movable shutters, that by turning the screw, *S*, a square hole of any desired size is adjusted at the window. The size of this hole can be read off on a scale, which is connected rigidly with the upper shutter, and slides on a standard below. The little window, *F*, admits light from a candle placed in a separate compartment, *L*, so that no light is thrown directly upon the eye under examination. On the wall opposite the peek holes there are black marks, *T*, on a white ground. The test consists in determining that size of window at which the black marks on the white ground become noticeable. The size of the window is the measure of the amount of light entering the box, and the amount of light that makes the marks visible measures the sense of stimulation of

[1] The description is taken from Fick's "Diseases of the Eye." English translation by A. B. Hale, A.B., M.D., p. 53.

the retina. (For example, if one eye can see the black marks when the size of the window is 2 sq. mm., while another does not see them until the window is 20 sq. mm., the functional activity of this last eye is ten times less, its light sense ten times smaller, than that of the first eye.)"

The conditions regarding illumination, to which the eye has been subjected immediately before the test with Förster's photometer, may produce a wide difference in the findings; thus, if the patient has been kept in a well-lighted room just previous to the making of the test, the amount of light required to excite the light sense will be much greater than that required if the individual has been in a dark room for some time before the test is made. The eye must be given time to *adapt* itself to the absence of light; the time required is approximately ten minutes, which should be passed in a dark room with the eyes lightly bandaged. The necessity for allowing time for adaptation may be realized if we remember the difficulty that all experience in seeing objects immediately, when we pass from sunlight into a moderately darkened room.

Mason's Disk.—The sense of contrast may be measured by Mason's disk, which consists of a white and a black disk mounted on an axle, and so arranged that a greater or smaller section of each disk may be shown. When rapidly revolved, the white and black sectors blend to form a gray color, which is lighter or darker according as a greater or smaller sector of white is exposed. If a smaller black disk is placed over the larger disks, the relative contrast sense may be determined by ascertaining the smallest area of the white disk that it is necessary to expose in order to enable the patient to detect a difference between the black centre and the outer margin of the compound disk.

Letters or figures of different shades of gray placed on a white or black card may also be employed. *Adaptation* must also be taken into consideration in making these tests.

Measurement of Field of Light Sense.—The extent of the field of light sense is a measure of the field of vision, and is considered under that head (see page 140).

Holden's Method.—The light sense *in the periphery* of the retina may be studied by Holden's method, which consists in determining the points in the arc of the perimeter at which certain test objects are perceived. For testing the zones between the centre of the field and the extreme periphery, Holden employs a card with a 1 mm. black point on one side and a 15 mm. quadrant of light gray, four-fifths of the intensity of white, on the other side. The normal eye perceives both the black point and the gray square at 45 degrees outward, 35 degrees inward, 30 degrees upward, and 35 degrees downward.

For detecting defects at the periphery he employs a similar card bearing a black dot 3 mm. in diameter on one side, and a gray patch, 15 mm. quadrant, three-fifths of the intensity of white on the other side. The normal eye detects each of these objects at 70 degrees outward, 55 degrees inward, 45 degrees upward, and 55 degrees downward. Examination of the light sense shows that it is not always diminished in proportion to the visual acuity. The diminution of the light sense is marked in those

cases in which hemeralopia exists; not infrequently the acuity of vision in good light is almost normal in hemeralopia, and the patient is virtually blind at twilight, or when the illumination is much reduced.

Color Sense.—The ability of the retinal element to respond in a different manner to the stimulus of light waves of different length and their proper interpretation by the brain constitute what is termed the color sense.[1] Many methods for testing the color sense have been devised. Some are of value in determining the color sense for some vocations in life, and are comparatively worthless for others. Thus, for those employed in mixing and matching colors, as workers in textile establishments, in pigments, etc., the selection and contrast tests are sufficient, while for those who must recognize colored signals other tests must be employed.

In testing the color sense, it should be remembered that the patient is usually interested in avoiding the finding of any defect, and that he will use every artifice to avoid detection. It must also be remembered that the color-blind can often name colors correctly even when his color sense is defective. In making tests of this nature it is advisable to permit the patient to name the color without any suggestion from the examiner.

The tests for color-blindness may be divided into selection tests, contrast tests, and pseudo-isochromatic tests.

1. **Selection Test.**—This consists in selecting different colors from a collection of colored areas or objects on request, and is quite crude and unreliable.

2. **Contrast Test.**—Holmgren's Method.—A large number of small skeins of colored worsted, one hundred and fifty to two hundred, made up of red, pink, orange, yellow, yellow green, green, blue green, blue, violet, purple, brown, and gray, of various shades and tints, are provided, and the patient is requested to select the skeins of lighter or darker shade that are of the same color as a sample skein that is given him. The sample test colors chosen by Holmgren are light pure green and rose[2].

First Test.—The light pure green test skein is put a little to one side. If his color sense is normal, the patient will rapidly select the shades of green that are similar in color to the test skein. If he is *completely color blind*, he will select grays, drabs, stone color, fawns, pinks, or yellows, with or without the greens. The *incompletely color blind* will select the greens and one or more skeins of fawn or gray.

If these colors are selected we know that there is a defect in the color sense. To determine the kind of defect we proceed to the second test.

Second Test with the Test Skein of Rose.—The lighter and darker shades of this color are to be selected. The individual whose *color sense is but slightly defective* will select the proper skeins without error. The individual with *incomplete color sense* will add the purples. The *completely red-blind* will select blue or violet either with or without purple.

[1] For an exhaustive discussion of the normal color perception, see Norris and Oliver's System of Diseases of the Eye, vol. i, p. 581.

[2] Holmgren, p. 183.

The *completely green-blind* will take green or gray or one alone, either with or without purple.

The violet blind are apt to select blue in the test with the skein of green, and red and orange, with or without purple, in the test with the rose-colored skein.

Third Test.—A third test may be made with a sample skein of *bright red.* The *red-blind* select, besides the red, green and brown shades darker than the red. The *green-blind* select shades lighter than the red. This test is serviceable only in marked cases of color-blindness.

Thompson,[1] Oliver,[2] and Jennings[3] have each devised a modification of Holmgren's method.

3. **Pseudo-isochromatic Tests.**—The difference between the bright portions and the less luminous portions of the spectrum is recognized by the color-blind and is utilized by them as a means of distinguishing colors, the difference between which is not recognized by actual perception of the colors. Individuals capable of passing the tests with the worsteds on account of their ability to name colors correctly from difference in tint and brightness would not make safe engineers or officers in marine service on account of liability to mistake the color of signals. In order to render intensity of light and of tint the same in all the colors employed, Stilling devised his "pseudo-isochromatic" plates, the colors for which were obtained by the aid of a red-green blind individual and a blue-yellow blind individual. A set of colors indistinguishable one from another was produced, and from these ten plates were constructed. The plates are divided into squares, some of which are tinted with one color to form figures or letters, the others with the confusion color. The plates are held in a good light and examined. The color-blind fail to detect the letters on some or all of the plates.

Mauthner[4] has devised pseudo-isochromatic powders.

Spectroscope.—The spectroscope, in which the spectrum is obtained either by means of prisms or by gratings (Ramsay, of Glasgow, has constructed an excellent spectroscope by the use of gratings for this purpose), chromatometers of various kinds, and the chromatophotometer of Chibert are used for this purpose.

Colored Shadows.—If a white and a colored light are permitted to fall on a white surface or a surface of neutral tint, and an opaque object, as a pencil, be held so as to cast a shadow of equal density from each light, the shadow from the white light will appear to be the color of the colored light, while the shadow from the colored light will appear in its complementary color. For example, if the colored light is red, the shadow from it will appear to be green.

Pflüger's-Tissue-paper Test.—This is a modification of Meyer's test, and consists in the use of letters cut out of gray or black paper, which are laid on colored grounds and covered with tissue paper. The letters appear in the color complementary to that of the ground color.

[1] Medical News, Philadelphia, August 13, 1894.
[2] Norris and Oliver, p. 194.
[3] Color-Vision and Color-Blindness, p. 71.
[4] Der Augenheilkunde, Wiesbaden, 1879, Heft iv, S. 242.

Special Tests.—When examining the color sense of men who intend to engage in railroad or marine service, requiring the recognition of signals, it is desirable to use tests closely corresponding to the colors of the signals and the conditions under which the signals are to be recognized. This implies not only a qualitative but also to some degree a quantitative test of the color sense.

Thomson's Lanterns.—For testing the color sense for different colored lights, the lanterns of William Thomson and of W. H. Williams[1] may be used. Dr. Thomson's description of his lantern follows:

"It consists of an asbestos chimney, which can be placed on the kerosene lamp in universal use on railroads, or over an Argand or other gas light, electric lamp, or spring candlestick. Two disks, four inches in diameter, are so placed upon the chimney as to permit of their being partly superimposed. The lower disk contains ten glasses in apertures 10 mm. in diameter, having the white, red, green, and blue colors in general use on railroads. This may be considered the 'examination in chief,' while the upper disk, when combined with the lower by turning one or both, furnishes the 'cross-examination.' The upper disk has four apertures, ranging from one to ten millimeters. The other six have one white ground glass, one deep London smoke, one medium London smoke, one pink, one green, and one Cobalt glass. The combination of the white ground and the smoke glasses with the reds and greens of the lower disk enables all atmospheric conditions to be imitated and the lights to be diminished in brightness and tint. The placing of the small openings enables size and distance to be imitated. The standard of normal color sense is taken as one millimeter opening at five meters."

Fig. 113



Thomson's lamp.

Flag Test.—Signal flags in red, green, blue, and white, of different degrees of cleanliness, may be employed, the flags being rapidly displayed at a suitable distance and their identity being required of the candidate, or a number may be piled on a table and the candidate be required to select the various colors.

Other Tests.—The spectroscope, the polariscope, and Maxwell's disk may be employed if further tests are required. These tests are not

[1] Trans. Am. Ophthal. Soc., 1897.

sufficiently easily employed to render them of service in routine office work.

Quantitative Determination of the Color Sense.—Donders' lantern consists of a blackened cylinder bearing a disk containing a red, a green, a blue, and a white glass. The colored glass in the disk can be rotated before a metal diaphragm with a changeable aperture. With the lantern at 5 m. the normal eye should detect the red with an aperture of 5 mm. If an aperture of 20 mm. is required the color sense $= \frac{1}{20}$.

The apparatus designed by Oliver[1] is convenient.

[1] Norris and Oliver, 1893, p. 83.

CHAPTER V.

THE EYELIDS.

ANOMALIES OF THE EYELIDS.

Ablepharia.—This is partial or complete absence of the lids. One or both eyes may be affected. In conditions of this nature, where the eyeball cannot be covered, the term *lagophthalmos* is employed.

Cryptophthalmos.—In rare cases the integument is continuous over the orbit, entirely covering the eyeball, which may be only partly developed. Manz has termed this condition *cryptophthalmos.*

Cleft Lid (*Coloboma Palpebræ*).—This consists in a vertical wedge-shaped defect, usually situated at about the middle of the upper lid. The cleft extends from the margin of the lid to the margin of the orbit, including the entire thickness of the lid. The margins of the defect

Fig. 114

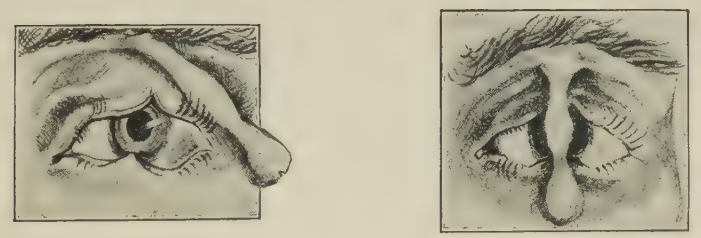

Coloboma of upper lid and symblepharon of lower lid. Congenital.

are rounded and sometimes thickened. In some of the cases a pendulous tongue of tissue hangs from the middle of the apex of the defect, and extends even beyond the margin of the lids; it is usually adherent to the globe. One or all of the lids may be affected. The upper lid is involved more frequently than the lower. When the defect appears in the lower lid, the upper lid of the same eye, in all cases so far observed, has also been involved. Zumsteeg[1] has collected and analyzed 63 cases.

Classification.—He classifies them as (1) simple coloboma, unilateral or bilateral; (2) with slight changes in the globe near the coloboma; (3) coloboma with dermoid formations between the lids and eyeball, and corneal changes; and (4) coloboma with other facial defects, as the oblique facial cleft. Harelip and cleft palate are observed in connection with coloboma of the eyelids.

[1] Dissert. Tübingen, F. Pietzker, 1899.

Treatment.—Operation should be resorted to in these cases as early as possible. This should consist in freshening the edges of the defect without sacrificing much tissue, loosening the lid flaps by free dissection, if necessary, and holding the parts in apposition by means of harelip needles until union has taken place. The tongue of tissue present in the cleft may be utilized to close the defect.

Epicanthus.—This condition is characterized by an excessive development of the skin at the root of the nose, causing a fold of skin to overlap each canthus. The skin ordinarily extends over the upper margin of the lid to a greater distance than over the lower margin, but in cases where epicanthus is associated with congenital ptosis the traction produced by contraction of the occipitofrontalis muscle reverses the rule of encroachment. Epicanthus is not common in the Caucasian, but is a characteristic in the Mongolian. Occurring at birth in the Anglo-Saxon, it usually disappears as the child develops and the bridge of the nose becomes prominent. In some cases the deformity persists and relief is sought.

Fig. 115

Epicanthus and ptosis.

The frequent association of epicanthus with ptosis, limitation of the movement of the eyes, particularly upward, and strabismus has been observed by many—von Ammon, von Graefe, and others mentioned by Manz.[1] Manz is of the opinion that the complex deformity depends on a common cause, but does not know whether it is due to a defect in innervation or insufficient muscular development, or to both. Heredity plays a prominent role in the production of epicanthus. Steinheim[2] mentions a family in which epicanthus and ptosis were observed fifteen times in the course of five generations. Epicanthus affecting the outer angle of the eye has been observed.

A high grade of epicanthus in adults is seldom seen.

Treatment.—This is wholly surgical. If the bridge of the nose is not developed in proportion to the tip of the nose it may be built up. The redundancy of skin in epicanthus may be removed by the operation of rhinorrhaphy (von Ammon), which consists in excising an elliptical piece of skin from over the bridge of the nose, the size of the flap being first determined by pinching up sufficient skin to reduce the deformity. The margins of the wound are brought together by means of harelip sutures,

[1] Graefe u. Saemisch, Band ii, Th. ii, p. 108.
[2] Centralb. f. prakt. Augenh., xxii, p. 249.

and closely placed superficial sutures. If the tissues are not strongly supported and the support continued until the union is firm (ten to twelve days) an unsightly cicatrix will result. Knapp[1] modifies von Ammon's operation by removing a rhomboidal piece of skin, undermining the skin at the sides, uniting the margins of the wound by closely placed silk sutures, and relieving the tension by supporting strips of adhesive plaster. The removal of elliptical pieces of skin from each side of the nose, and closing the wound after the method of Knapp, would avoid the unsightly scar over the bridge of the nose and correct the deformity.

Symblepharon.—As a congenital defect, this is among the very rarest anomalies. It occurs partially in cases of cleft lid (see page 155).

Ankyloblepharon (*Union of the Margins of the Lids*).—This malformation is seldom complete. When associated with anophthalmos, it may leave only a very small palpebral fissure at the inner canthus. Under the term "anchyloblepharon filiform adnatum," Hasner describes the union of upper and lower lid by a congenital thread of tissue. De Haas[2] describes a case in which a number of bands of tissue attached to the intermarginal space united the lids. He designates the condition "membrana palpebralis perseverans." The eyes were normal.

Fig. 116

Congenital ptosis.

Ptosis, Congenital.—This condition, in which the upper lid droops and cannot be raised to fully expose the pupil, is not uncommon. It is bilateral in approximately four-fifths of the cases. The action of the levator palpebræ superioris is partially or wholly abolished. The lid is raised a little by the contraction of the occipitofrontalis muscle, permitting the patient to look from under the lid margin by tilting the head backward. The position of the head, wrinkling of the forehead, due to contraction of the occipitofrontalis muscle, arched eyebrow, and smooth surface of the upper lid are characteristic. Not infrequently defective action of the muscles supplied by the third nerve accompanies the ptosis. Cases of synchronous movements of the drooping lid and the lower jaw have been reported by a number of observers.[3] When the mouth is opened the lid raises; also in some cases in lateral movements of the lower jaw. Epicanthus is sometimes associated with it (see page 156).

Etiology.—In many cases the condition is due to partial destruction of the nucleus of the third nerve. Insufficient development or absence of the levator palpebræ superioris is supposed to be the cause in some cases. Other muscles supplied by the motor oculi may be deficient. Defects in the cortical centre for the elevation of the lid, which, according to Lodata, lies in the sigmoid gyrus of the opposite side, whether con-

[1] Arch. of Ophth., vol. iii, p. 48.

[2] Med. Weckll., 1896, p. 489.

Bernhardt, Centralbl. f. prakt. Augenh., 1896, p. 7.

genital or acquired, may cause ptosis. Hysteria is apparently sometimes the cause of transient ptosis. Abadie[1] reports two cases.

Treatment.—This is always surgical (see chapter on Operations).

Distichiasis.—This condition is characterized by a malposition of the cilia, other parts of the lids being normal. The cilia, which normally are present in two or three rows, are present in distichiasis in four or five rows throughout part or whole of the lid margin; some or all of the inner one or two rows, which are often very much smaller than the outer rows, are directed against the eyeball. The friction of the eyelashes against the cornea and conjunctiva produces much irritation, which can only be relieved by their removal.

Treatment.—See Trichiasis and Entropion.

Dermoid Tumors.—They are probably always congenital. They are benign. If removal is desirable, they may be excised.

Lipomata (*Fatty Tumors*).—Cases of lipomata, congenital in origin, have been reported.[2]

Cysts of Lid.—These, occurring with dermoid tumor, with anophthalmos, and microphthalmos, have been observed.

Treatment.—Excision.

Failure of Contact of Lids with Globe.—Failure of the lids to come in contact with the globe at the outer canthus is sometimes observed, causing some disfigurement in the extreme cases.

Treatment.—Tarsorrhaphy (see chapter on Operations).

DISEASES OF THE EYELIDS.

Hyperemia; Erythema.—**Etiology.**—As a result of exposure to strong wind, glare of light, prolonged weeping, wakeful nights, excessive strain or use of the eyes, particularly when errors of refraction are uncorrected, burns, traumatism, poisoning, or the presence of irritating fluids, the skin of the lids at times becomes reddened, dry, and painful. The hyperemia may be *active* or *passive*. In the first the color of the lid is a lighter red than in the second. In the first the arteries and capillaries are overfull, the escape of venous blood is not impeded; in the second there is venous stasis, the color is a dusky red. Active hyperemia is the early stage of all inflammations of the lids.

Symptoms.—Sensations of fulness, stiffness, itching, and burning are experienced.

Treatment.—The cause should be ascertained and removed, if possible. A bland protective, in the form of an ointment of which vaseline is the base, is efficient to allay the burning, itching, and stiffness.

Urticaria.—Urticaria appears on the skin of the eyelid but rarely in the form of the characteristic eruption accompanied by burning and itching sensations. Urticaria of the eyelids is always accompanied by urticaria in other parts of the body.

[1] Rev. de Méd., January 10, 1900.

[2] Armaignac, Rev. clin. d'Ocul., 1884, No. 4, p. 84.

Impetigo.—Impetigo is another dermatosis that sometimes affects the skin of the lids.

Erysipelas.—**Etiology.**—This disease occasionally affects the eyelids primarily, but is almost always due to extension from the face or from some part of the head. It is characterized by a diffuse cellulitis caused by the streptococcus.

Symptoms.—The lids become very much swollen, red, and brawny. They are hot, stiff, and painful. Lachrymation is increased. There is always a decided rise of temperature.

Diagnosis.—Erysipelas may be confounded with phlegmon of the lachrymal sac. Tenderness over the sac and fluctuation will serve to differentiate between the two. Swelling from traumatism and herpes zoster in its early stage may also be mistaken for erysipelas.

Prognosis.—This is good in the majority of cases. Destruction of the eyelids by sloughing may occur, but the chief danger is of extension to the tissues of the orbit, when blindness may ensue, and death by meningitis may follow.

Treatment.—As in facial erysipelas. Locally, lead and opium wash applied by means of a gauze mask, which is kept moist. Systemically, iron, in the form of the tincture of the chloride (gtt. x every two hours), and quinine (gr. ij four times daily).

Ulcers of the Lids.—As a result of traumatism, burns, herpes, syphilis, lupus, or destruction of the skin from any cause, ulcers of the lids appear. They will be specifically described in the discussion of the affections which produce them. Generally considered, they should be treated antiseptically. Profuse granulations should be cut off, or destroyed by means of the stick of the nitrate of silver.

Furunculosis.—Furuncles develop very rarely in the lids. The course and treatment are the same as in furuncle developing in other parts of the body.

Anthrax (*Malignant Pustule*).—**Etiology.**—This rare disease is caused by the transfer of the anthrax bacillus to the eyelids from animals affected with anthrax. Consequently it is most frequently met with in those who are employed about animals or have to do with animal products.

Symptoms.—The anthrax pustule appears as an elevated, tense, indurated area, which soon presents a number of yellowish points at its apex. The adjacent tissue becomes reddened, edematous, and brawny, the lymphatic glands of the affected side of the face enlarged and painful. There is more or less fever and much depression. The infected area rapidly enlarges, and destruction of a portion or the whole of the affected lid ensues.

Diagnosis.—This cannot be made positively by simple inspection. Examination of secretions and of tissue by means of the microscope may suffice, but is not always conclusive. Cultivation and inoculation experiments may be necessary to establish the diagnosis.

Prognosis.—Iwanowsky[1] reports eight cases, three of which terminated fatally.

[1] Wjestnik Ophth., 1896, Nos. 4 and 5.

If death does not ensue, healing is followed by cicatricial contraction, with resulting ectropion. According to Fuchs, the ciliary margin of the lids is usually preserved; probably because of the excessive vascularity of the part, the tissue not succumbing readily to the necrotic influence.

Treatment.—As soon as there is evidence of pus, and even before, in rapidly advancing cases, a free crucial incision should be made. If pus is present, it should be evacuated. The constant application of compresses of gauze or absorbent cotton, dipped in a hot solution of bichloride of mercury (1 to 1000 to 1 to 3000), should be employed. Hypodermic injections of equal parts of a solution of cocaine (2 per cent.) and of bichloride of mercury (1 to 1000) may be made in and about the base of the infiltrated area once daily. Gurfinkel[1] reports a successful case in which the principal treatment consisted in the local injection of a 2 per cent. solution of carbolic acid.

The deformity due to cicatricial contraction, in cases of much loss of tissue, can be obviated by stitching the remaining margin of the lid to its fellow and covering the granulating surface, when practicable, with Thiersch grafts.

Gangrenous Ulcerations.—**Etiology.**—Gangrenous ulcerations of the lids occur from various causes. Stiffan[2] reports a case of gangrenous destruction of the inner angle of the lids, including the lachrymal sac, caruncle, and bulbar conjunctiva up to the limbus. A bacteriological examination revealed the Klebs-Loeffler bacillus. A gangrenous ulceration, resulting from the bite of a man, occurred in a woman, aged twenty-four years. The eyelids and both eyes were lost. No specific microörganism was found.[3] Noyes[4] refers to reports of cases of spontaneous symmetrical gangrene of the skin of the lid (noma), a condition of extreme rarity.

Treatment.—This should be systemic if there is any systemic irregularity, and also local. Locally the treatment should be thorough antisepsis. The dead tissue should be removed, the surface rendered clean, and an antiseptic dressing applied. Cicatricial contraction follows the loss of tissue. The results may be minimized by a plastic operative procedure resorted to at a favorable stage in the process of healing.

Abscess.—Phlegmon of the lid presents itself as an acute, somewhat circumscribed swelling, frequently of a dusky red color, tense and indurated, accompanied by intense throbbing pain, headache and fever. In the course of twenty-four to forty-eight hours fluctuation can be elicited. In individuals of depressed vitality, particularly in asthenic children, abscess of the lid may develop without acute symptoms.

Etiology.—Abscess may follow bruises, accompany orbital periostitis and the exanthematous fevers. It occurs in debilitated children, especially in the uncleanly and in those who live in unclean surroundings; it follows bites of insects. It may be due to extension of a suppurative

[1] Wjestnik Ophth., ix, 23.
[2] Klin. Monats. f. Augenh., xxxviii, p. 339.
[3] Burnett, Jour. Amer. Med. Assoc., June 24, 1899.
[4] Diseases of the Eye, second edition, p. 55.

process from the lachrymal sac. The micro-organisms found are the staphylococcus pyogenes, streptococcus, and the pneumococcus.

Prognosis.—Spontaneous opening may occur and the process terminate without resort to surgical procedure, and with little permanent damage to the tissues; or the pus may extend beneath the skin, undermining it for some distance, eventually causing death of considerable areas of the overlying skin.

Treatment.—In the early stage, before pus has formed, hot compresses or poultices may be applied. As soon as pus is present a free incision, parallel to the margin of the lids, should be made, the cavity evacuated, and the walls of the abscess curetted. The opening should be kept patent by inserting a strip of iodoform or other aseptic gauze until the cavity closes from below. Healing with but little scar will follow. Internal medication, by the exhibition of calomel in small, oft-repeated doses, and of the sulphide of calcium, is often of much value. The diet and hygienic conditions should be made as favorable as possible.

Hordeolum (*Stye*).—Characterized by a localized, acute swelling at or near the margin of the lid, accompanied by pain.

Forms.—Two forms are recognized.

Hordeolum Externum.—This is the form that develops from the sebaceous glands associated with the hair follicles (Zeiss' glands). It sometimes produces an edematous condition of the margin of the lid, which masks the exact site of the process. The pain during the first twenty-four to forty-eight hours is often acute. The apex of the swelling becomes yellow on the second or third day, and a spontaneous opening takes place on the surface of the lid.

Hordeolum Internum.—This is due to inflammation of a Meibomian gland, and is sometimes termed *hordeolum Meibomianum.* Since the seat of the inflammatory process is deeper than in hordeolum externum, lying as it does in dense fibrous tissue, the disturbance to the patient is greater. In some cases the lids are much swollen and painful. On everting the lid, which is not always possible, a red area in the tarsal conjunctiva is observable. This soon changes to yellow in its centre, and the stye may eventually rupture into the conjunctival sac. In some cases pus is discharged through the duct of the Meibomian gland; in some, rupture through the skin occurs.

Etiology.—The inflammation is due to the entrance of a pus-forming germ into a sebaceous gland, gland connected with a hair follicle, or Meibomian gland. Marginal blepharitis often precedes the development of hordeolum, the secretion at the margin of the lids affording a favorable nidus for the development of infectious bacteria. Successive hordeoli are apt to occur, and are due to auto-infection.

Prognosis.—Recovery without a trace is the usual result. An extension of the inflammatory process to neighboring tissue may take place. Goth[1] reports a case of involvement of orbital tissue, meningitis, and death.

[1] Prag. med. Woch., 1898, No. 3.

Treatment.—In the early stage moist heat, in the form of compresses of absorbent cotton, absorbent gauze, or spongiopilin dipped in hot water and frequently changed, or in the form of flaxseed poultices, is indicated. This gives some relief from pain, and hastens the formation of pus. As soon as the presence of pus is determined, a free incision should be made and the pus thoroughly removed. The pus cavity may then be treated with an antiseptic solution; the bichloride of mercury, 1 to 1000, is excellent. Rapid recovery will ensue. The opening in hordeolum internum should be made from the conjunctival surface, if feasible.

Affections of Lids Accompanying Exanthematous Fevers.—In all of the exanthemata the skin of the lids participates, as does that of other parts of the body. In scarlet fever they are reddened, and sometimes swollen. In measles the lids are swollen, sometimes very much, causing decided temporary narrowing of the palpebral fissure. In chickenpox and in smallpox the eruption often appears upon the lids, and may result in extensive ulceration, especially in the latter disease, as a result of infection, often because of mechanical interference on the part of the patient. If nothing more than the pitting, consequent on the eruption, follows, no displacement of the margin of the lids ensues; but if there is extensive ulceration, ectropium may develop. The hair bulbs and sebaceous glands may be attacked. Permanent loss of the lashes (madarosis) is a rare result.

Treatment.—Ulceration may be prevented by keeping the affected surface covered with a protective in the shape of vaseline, vaseline with 1 per cent. carbolic acid, or by dusting with starch and zinc oxide, equal parts. If ulcers with granulating tissue develop, they can be controlled by means of the nitrate of silver stick.

Eczema.—Eczema of the lids may appear in any of its various forms—the vesicular and the pustular varieties, which are frequently spoken of as moist eczema, and erythematous eczema, the dry or desquamative eczema.

Moist Eczema.—Moist eczema is the form most frequently met with in children. It is characterized by the appearance of minute translucent nodules on a reddened base. The nodules are numerous and frequently coalesce. They are at first translucent, then become yellow—particularly at their apices—from the presence of pus corpuscles. The epithelium covering them gives way, and a minute superficial ulcer results. This process may affect a relatively large area, over which pus and serum flow from the ruptured nodules; the secretion becomes dry and forms a yellow crust, or the flow of serum is so profuse that crusting does not take place, the surface remaining red, moist, and slightly swollen. The *papular* variety, formerly spoken of as *lichen simplex*, is not of frequent occurrence. It consists of minute papules, which do not tend to suppurate. It may be mixed with the other two varieties.

Etiology.—The development of eczema apparently depends on a predisposing condition of the system. Children that are anemic, poorly fed, and live in filthy surroundings; children with hypertrophied

lymphatic glands, with flabby tissue, especially those who appear to be the subjects of ptomaine absorption, favor the development of eczema. Maceration of the surface cells by the presence of fluids, irritating or non-irritating, purulent or mucopurulent secretions, and mechanical irritations prepare the area involved. The microörganism chiefly responsible for the acutal establishment of the disease appears to be the staphylococcus pyogenes.

Pathology.—The minute nodules consist of an aggregation of lymphoid cells immediately beneath the epithelium, which they elevate. The skin is somewhat thickened by infiltration of small cells, dilatation of minute vessels, and more or less of a serous exudate. The contents of a nodule will afford a culture of the staphylococcus pyogenes.

Symptoms.—Moist eczema is accompanied by sensations of burning and itching. The skin of the affected area is slightly thickened, the pre-auricular, cervical, and submaxillary glands on the affected side are more or less enlarged, the individual is irritable, and, if a child, constantly desires to rub or scratch the affected area. Absorption of ptomaines apparently accompanies the continuance of the disease, giving the patient more or less of a cachexia.

Treatment.—Moist eczema should be treated systemically as well as locally. The systemic treatment consists in the careful regulation of the diet and of the bowels, and efficient medication to correct the "vicious habit" of the system. Tonics may be prescribed. The writer has found mercury in some form (calomel or mercury with chalk) to be of great value. Calomel in 0.05 grain dose, one tablet every three or four hours, continued two to four weeks, is most serviceable.

Local.—The crusts and secretion should be gently removed by means of absorbent cotton, after softening by bathing with a warm solution of the biborate of soda. Subsequently an application of the nitrate of silver (2 to 5 per cent.) may be made. The surface may then be protected by smearing it with sterile vaseline. The treatment of moist eczema with ointments is often very satisfactory. Oil of cade in vaseline (10 per cent.), or ichthyol (20 to 50 per cent.), ointment of the yellow oxide of mercury in vaseline (1.5 per cent.), boric acid in vaseline (5 to 10 per cent.), may be employed, making the application twice or three times daily, and avoiding water for cleansing. Desiccating antiseptic powders may be employed. Calomel with starch is one of the best. The oxide of zinc with starch (oxide of zinc, one part; starch, four parts) may be used. Any one of these plans of local treatment may be efficacious. All may need to be tried.

Desquamative or Hypertrophic Eczema.—This is met with almost exclusively in adults, and usually in those of advanced years.

Etiology.—It depends apparently on constitutional dyscrasiæ; gout and rheumatism and diabetes undoubtedly predispose.

Symptoms.—The skin of the lids and the adjacent skin of the face has a dusky red hue, is thickened and somewhat indurated, and lies in folds. The papillæ are enlarged. The surface is furfuraceous. Fissures often form, and, in some cases, there is a flow of serum from

parts of the surface. Much irritation is experienced by the patient, and the desire to scratch and tear the surface is often irresistible. The conjunctiva is usually irritated in connection with the skin.

TREATMENT.—*Constitutional.*—The diet should be carefully regulated; wine to any extent should be interdicted, water should be taken freely, and some antacid, as lithia carbonate, should be given.

Local.—Water should not be used on the diseased surface. Remedies with an oily base should be employed, and the base should be bland and non-irritating. The ointment of the oil of cade (5 per cent.), ichthyol (5 per cent.), borated vaseline, diachylon ointment, citrine ointment (one-fourth officinal strength), or simple vaseline may be employed. Different cases require different remedies. It is often necessary to try a number of remedies before the one best suited is found.

FIG. 117

Herpes zoster. (Photograph by George S. Dixon.)

Herpes Zoster Ophthalmicus (*Herpes Zoster Orbitales*).—It is characterized by the appearance of clusters of vesicles over the area of distribution of the supra- or infra-orbital branches of the trigeminus. The formation of vesicles is preceded by one to three days of severe neuralgic pains, intermittent in character, with some redness of the skin over the affected area. The supra-orbital branch of the trigeminus is affected in approximately ninety per cent. of the cases (when this branch alone is affected, the disease is often termed herpes zoster frontalis); the infra-orbital branch in ten per cent.[1]

Etiology.—Herpes is thought to be due to an inflammation of the trunk of the trigeminus or to disease of the Gasserian ganglion. It has followed traumatism, refrigeration, the use of arsenic, and poisoning by carbonic acid gas. Head and Campbell[2] have made a number of autopsies on patients who have suffered from this disease. They invariably found lesions of the Gasserian ganglion similar to those found in the posterior root ganglion in zoster of the trunk and limbs. It is closely allied to neuroparalytic keratitis, and may be termed an irritation neurosis.

Symptoms.—It may occur at any age, but is most common in adults of advanced years (the writer has observed it in an infant aged eight months). It is almost without exception unilateral. Headache, a feeling of malaise, and some rise of temperature accompany the onset of the disease. The

[1] The area of the third division of the fifth nerve is extremely rarely affected.
[2] Brain, 1900, No. 9.

vesicles, which appear in clusters, are translucent and small at first. They gradually increase in size, open, and discharge a scanty seropus, which dries, forming crusts. On removing the crusts deep ulcers are found, disclosing the fact that the process involves the entire thickness of the skin. The skin over the affected area is swollen. Often the area supplied by the trochlearis nerves is affected conjointly with that of the supra-orbital. The pain is of a lancinating character and remitting. Headache, itching, and burning accompany the stage of eruption. The vesicles slowly disappear and the ulcers heal, leaving permanent scars. The neuralgic pains may continue for months after all traces of activity in the process have passed. The vesicular patch becomes anesthetic, but the surrounding tissue is quite sensitive.

Complications.—Vesicles may appear on the cornea, and occasion pain referable to the eye itself. The vesicles, which appear to affect the epithelium only, are accompanied by infiltration of the cornea, which may persist for a long time, causing much diminution of vision. The cornea may become entirely anesthetic, and ulcers at the lower part may occur from exposure (keratitis neuroparalytica). Tay[1] reports a case in which he observed paralysis of the facial nerve on one side, accompanying herpes of the second branch of the trigeminus on the same side. When the eyeball participates, the tension is often abnormally low. Rarely the tension is increased. Iritis, with or without implication of the cornea, may accompany herpes. Palsy of the ocular muscles has been observed.

Treatment.—In the early stage of the disease, when the vesicles are forming, the application of lead and opium wash by means of a mask composed of a number of layers of gauze to cover the affected area (which is kept moist) gives much relief. An ointment consisting of ung. hydrarg. and vaseline, equal parts, or bichloride (1 to 5000), applied freely and covered by a piece of gauze, gives relief and appears to hasten recovery. Desiccating powders are advised (Fuchs), rice starch being one of the best. This may be medicated by adding zinc oxide or calomel. The powder is dusted on the vesicles frequently. The crusts should not be disturbed; they drop off as the ulcer heals. The electric current, galvanic and faradic, has been advised for the purpose of relieving pain, but its application does not produce satisfactory results in all cases. The treatment of the keratitis and iritis is the same as in similar conditions from other causes. Internally, tonics and salicylates should be employed. The author has found iron in the form of the tincture of the chloride (gtt. x every two or three hours) and quinine (grs. ij three or four times daily) to be of much value in the acute stage of the affection. It may be necessary to resort to the use of morphine to relieve pain, but often some of the coal-tar derivatives are sufficient.

Vaccine Blepharitis (*Vaccine Ophthalmia, Vaccinia of the Eyelids*).—**Etiology.**—As a result of the conveyance of vaccine virus to the margin of the lid, usually from the vaccine pustule on the arm of a patient

[1] Ophthalmic Review, 1884.

or on the arm of a companion, a vaccine pustule or pustules appear on the margin of the lid, involving the skin of the lid, and sometimes extending to the conjunctiva and cornea.

Symptoms.—The lid (usually the lower, sometimes both upper and lower) is often very much swollen and dusky red in color. The site of the eruption on the margin of the lid is covered by a soft, grayish exudate. If the pustule extends to the skin of the lid to some distance from the margin, the portion of the exudate not moistened by tears forms a crust. The portion of the conjunctiva lying in contact with the original pustule and the opposite margin of the lid are often affected secondarily, and become the sites of secondary pustules.

Diagnosis.—If vaccine blepharitis is once seen and recognized, it is difficult to mistake it for anything else. Often the swelling of the lid is quite enormous, suggesting phlegmon, but the course is not always the same. A history of vaccination of the patient, or of some one with whom the patient has come in contact, is ordinarily easily obtained.

Treatment.—The application of a bland, slightly antiseptic ointment, two or three times a day, suffices. Boric acid in vaseline (5 per cent.), or the oil of cade in vaseline (5 per cent.), afford suitable ointments.

Inflammation of Border of Lids.—To this condition is given the generic term *blepharitis marginalis*. This includes hyperemia, seborrhea, squamous blepharitis, ulcerative or pustular blepharitis, tinea tonsurans, and favus.

Hyperemia.—The margin of the lids are red and often slightly thickened. There is often slight excess of secretion from the marginal glands, and, in cases where the hyperemia is long-continued, the growth of the eyelashes is stimulated and they become excessively stout and long.

Etiology.—Hyperemia of the margin of the lid is induced by exposure to strong wind, bright light, or to a dusty or smoky atmosphere, by eye strain consequent on use of the eyes (*a*) when errors of refraction are uncorrected, (*b*) by insufficient light, (*c*) from excessive use. Hyperemia of the margin of the lid also accompanies conjunctivitis in all of its forms.

Symptoms.—A sensation of heat and discomfort is frequently experienced, and at times the patient complains of stiffness of the lids.

Treatment.—Removal of the cause and the use of a bland ointment suffices.

Seborrhea.—It not infrequently happens that the secretion of the sebaceous glands of the lids becomes more profuse than normal; it undergoes a change, collects in the roots of the lashes, and is present as a yellowish-gray mass. The consistency of this hypersecretion varies in different cases, being quite dry in some—*seborrhea squamosa;* oily in others—*seborrhea oleosa.* This condition differs from the *blepharitis squamosa* in that the epidermis is but little affected. The margins of the lids are often not at all, or but very slightly, hyperemic.

Etiology.—Seborrhea of the margins of the lids may accompany seborrhea of the brow and scalp, and be due to microbic infection. It

may be the result of hyperemia of the margin of the lids induced by uncorrected errors of refraction, etc. Errors of diet may contribute.

Symptoms.—Aside from the cosmetic effect and the occasional entrance of dry sebum into the conjunctival sac, little annoyance is experienced.

Prognosis.—Long-continued seborrhea affects the nutrition of the eyelashes. They become thinner and are reduced in size.

Treatment.—The cause should be ascertained and removed if possible. Errors of refraction in particular should be corrected. Locally, the gentle removal of the scales by means of a small cotton probang and the application of a bland antiseptic ointment once in twenty-four or forty-eight hours, carefully followed up, are often sufficient.

Blepharitis Squamosa.—Closely allied to seborrhea, and always accompanied by it. In this condition the surface epithelium becomes exfoliated, and, in connection with the sebum, forms small scales between the eyelashes. These scales are loosened to some extent if the eyes are rubbed, and drop off. If the more adherent scales are forcibly removed, some of the lashes come away with them, and the skin of the lid is found to be hyperemic, but is not ulcerated. The effect on the eyelashes is slightly deleterious, but they show little change except in cases where the condition has lasted many years.

Fig. 118

Blepharitis. (Dalrymple.)

Blepharitis Ulcerosa.—This term is applied to all *ulcerative* processes which affect the margins of the lids only. The form ordinarily met with is characterized by the presence of yellowish crusts, which form between the eyelashes and are adherent to them, and by the formation of small pustules which are pierced at their apices by an eyelash. The margins of the lids are slightly hyperemic and are thickened. On removing the crusts the lid margin is found to be ulcerated, and bleeds slightly. The eyelashes are usually irregular in length and in distribution, and are reduced in number.

Prevalence.—Blepharitis ulcerosa occurs most frequently in children, especially in those who are subject to eczema, those who are poorly nourished and live in squalid surroundings, and in those who are apparently the victims of ptomaine absorption—the so-called scrofulous children. It occurs also in adults, especially in the uncleanly.

Etiology.—The causes of ulcerative blepharitis may be divided into (*a*) exciting, (*b*) contributing, and (*c*) predisposing. The exciting cause is the presence of pyogenic or pathogenic microörganisms. Under favorable conditions these invade the epithelium of the lid, the glands at the margin of the lid or the hair follicles, or both.

The contributing causes are the presence of secretions from the conjunctiva or from the lachrymal sac and canals, excessive flow of tears, exposure to heat, living in a smoky or vitiated atmosphere, eye strain, and undue irritation to the lids by rubbing, etc.

The predisposing causes are the dyscrasiæ due to faulty nutrition consequent on errors of digestion, and possibly to inherited tendencies. It is probable that eye strain, consequent on errors of refraction, is sufficient, unaided, to cause squamous blepharitis, but the ulcerative form requires infection of some kind. The microörganism most frequently found is the staphylococcus pyogenes.

Duration and Prognosis.—Blepharitis ulcerosa is, ordinarily, a very chronic affection; it may originate in childhood and continue throughout life. It is, however, amenable to treatment, and may be terminated at any stage. If of short duration, it produces no lasting results. If not corrected, it produces permanent thickening of the borders of the lids, with hypertrophy of the conjunctiva at the margin of the lids. The eyelashes drop out; they grow again, but are not so large. This process is repeated over and over again until eventually the lashes disappear entirely—*madarosis*—or they become scattered along the margin of the lid, vary much in size, some being extremely minute. The lower lid is always most affected. Hypertrophy of the tarsal conjunctiva forces the margin of the lower lid away from the globe, producing a moderate degree of ectropium. The lower punctum lachrymalis is everted and fails to carry off the tears, epiphora resulting. The skin of the lower lid, because of constant irritation induced by the presence of tears and secretion, becomes atrophic and shrinks, drawing the margin of the lower lid farther down. The margin of the upper lid in rare cases becomes sufficiently thickened to produce an appreciable drooping, in consequence of its weight.

Treatment.—The constitutional treatment consists in improving the nutrition and enforcing cleanliness. In addition to these, appropriate remedies should be administered. In children a mercurial (calomel) in small and frequently repeated dose, long-continued, is often beneficial. Eye strain should be relieved by the adjustment of suitable glasses. *Locally*, the scales and crusts should be removed, either by gently detaching them by means of forceps or, better, by macerating with warm solutions of the biborate of soda and gently removing by means of absorbent cotton. The best results are probably obtained by use of ointments, after having cleansed the lids. A bland antiseptic ointment should be employed. The red and the yellow oxides of mercury (Pagenstecher's ointment) and ammoniated mercury (1 to 2 per cent. in vaseline) give excellent results. The two last mentioned are the best. The salts of mercury should be finely incorporated with the vaseline. Ointment of the oil of cade (5 per cent.) is also excellent. The ointment should be applied to the margins of the lids at night. If the blepharitis is severe, a bandage may be applied. It is sometimes necessary to remove a part or all of the eyelashes by epilation, in order to promote a cure. This insures more rapid recovery in all cases, but will not be submitted to

by all patients. The application of the ointment should be continued in a moderate manner for some days after an apparent cure is secured. Excellent results are obtained by painting the ulcerated and inflamed area with a solution of the nitrate of silver (2 per cent.) after removing the crusts.

Sycosis Parasitica.—*Etiology.*—The follicles of the eyelashes, in connection with the hair follicles of the brow, are at times invaded by the fungus *tinea tonsurans*, the trichophyton tonsurans. Both eyes are affected and all of the lashes are involved. When this occurs the lid presents the appearance of an aggravated case of blepharitis marginalis. The lashes fall out or can be readily pulled out, the hair bulbs are enlarged and filled with a pustular secretion, which contains the fungus. The disease is contagious.

Treatment.—Epilation, cleansing with germicidal solutions, as the peroxide of hydrogen, or the bichloride of mercury (1 to 1000), and the application of ointments similar to those employed in blepharitis ulcerosa.

Favus.—Favus of the margin of the lids and of the brow is rarely seen. Microscopic examination (place the hair on a glass slide; add one or two drops of potass. hydrat., 40 per cent.; cover glass) of the hair bulb will disclose the presence of the specific fungus, the achorion Schoenleinii.

Sporotrichosis.—As shown by Morax and Carlotti,[1] and later by other writers, the eyelids and conjunctivæ are sometimes infected with sporotricha, the variety most frequently found being the sporotrichum Burmanni.

Symptoms.—Infection of the lids is characterized by rather hard follicular swelling which breaks down in a few days, forming an ulcer. The lesion is soon multiple and is accompanied by thickening and redness of the ciliary margin and by enlargement of the submaxillary and pre-auricular glands, with pronounced sensations of irritation. Involvement of the conjunctiva produces follicular lesions, with ill-defined pale yellow spots. The conjunctiva is reddened and secretes mucopus. Glandular involvement, as when the lids are affected, and marked eosinophiliā develop.

Diagnosis.—This may be established by cultivations on ascites agar from scrapings from the ulcers of the lids or white spots on the conjunctiva.

Treatment.—The iodide of potassium internally, 2 to 10 grains daily, and mild local antisepsis bring about recovery in from twelve to fourteen days.

Keratosis Nigricans (*Acanthosis Nigricans*).—This may affect the skin of the lids and the conjunctiva. The condition is characterized by the development of pigmented warty growths, accompanied by similar growths on the skin in other parts of the body.

Phthiriasis (*Crab Louse*).—Mites of various kinds have been found on the eyelashes and in the hair follicles. Of these one frequently met

[1] Annal. d'oculist., June, 1908.

with, in children particularly, sometimes in adults, is the common crab louse (Pediculus pubis). The deposition of the ova on the hairs of the lids gives the lids a peculiar black appearance. Close inspection is required to distinguish the ova from the scales of the blepharitis marginalis, which the parasite excites. The parasite itself lies at the base of the eyelashes.

Treatment.—Recovery can be readily brought about by treating the margins of the lids with an ointment of the red oxide of mercury, 1 to 2 per cent., applying the ointment twice daily.

Demodex Folliculorum.—The *Demodex folliculorum* is a mite which buries itself in the hair follicles between the hair shaft and the wall of the follicle. The female is 0.4 mm. and the male 0.22 mm. long. According to Raehlmann, the parasite is found in 2 per cent. of healthy eyes and in 25 per cent. of trachomatous eyes. It is absent in the usual forms of blepharitis. Hansch[1] states that it is almost always found in the hair follicles of healthy lids. By the use of a salve, composed of balsam of Peru and lanolin, a cure may be effected in six to eight days. The parasite produces no symptoms of moment.

Fig. 119

Chalazion. (Reeve.)

Chalazion.—This is a cystic tumor which arises from a low form of inflammation affecting a portion of a Meibomian gland. The growth develops slowly, sometimes accompanied by some redness of the skin of the lid. On everting the lid the conjunctiva is often found to be slightly injected over the area corresponding to the site of the growth, and is sometimes slightly thickened and velvety. From the effect of the irritation, which is the cause of the growth, the cells of the portion of the gland affected multiply and disintegrate, and the duct of the gland becomes closed. The fibrous wall of the cyst becomes distended, and often considerably thickened. The swelling causes an elevation on the surface of the lid. The skin of the lid is seldom involved, being freely movable over the small rounded tumor. The development of chalazion requires from two to ten weeks. It seldom grows to a size greater than 8 mm. in diameter. The contents of the chalazion is a gelatinous, pultaceous mass. One or many chalazia may be present at the same time; a number may appear at intervals, or one only may develop.

Etiology.—Chalazion is evidently due to infection of a Meibomian gland. Weyman[2] describes a fungus which he believes to be the cause.

[1] Münch. med. Woch., November 25, 1900, p. 1563.

[2] Oph. Rec., 1, 9, p. 307.

Hala[1] believes that the xerosis bacillus is the cause. Further research is necessary to settle the question.

Course and Symptoms.—Without treatment chalazion may remain without much change for many months or years. It sometimes opens spontaneously on the conjunctival surface, when the contents may be discharged and the cavity heal, or a more or less permanent fistula may form, from the margin of which polypoid granulation tissue may develop, the pultaceous contents of the chalazion being only partly lost. If the chalazion does not rupture, the fibrous wall increases in thickness until eventually there is little left but fibrous tissue. Chalazion gives the patient little trouble so far as pain is concerned. In some cases slight conjunctival irritation is occasioned. The chief annoyance to the individual is the appearance of the elevation on the lid. Chalazion does not tend to degenerate into malignant disease, but carcinoma has been observed apparently developing from a neglected fistula.

Diagnosis.—The skin is freely movable over chalazia, as a rule, and is not so over other growths that occur in the lid. This, with the history of the case, will enable one to make the diagnosis.

Treatment.—Surgical (see chapter on Operations).

Fibrous Tumors.—Fibrous tumors of the tarsus develop apparently much as chalazia develop. They are usually small, measuring about 5 mm. in diameter. They resemble chalazia in every respect, except that they are not saccules. They contain no gelatinous material, produce no irritation, and are objectionable only because of the deformity.

Treatment.—Fibrous tarsal tumors must be removed by dissection, as in the removal of chalazia.

Disorders of Meibomian Glands.—**Cystic Degeneration.**—In some cases a number of acini of Meibomian glands scattered throughout the lids become distended and produce small cysts, which bulge on the conjunctival surface and appear on eversion of the lids as small translucent elevations. The process occasions a more or less diffuse thickening of the lids, and the conjunctival irritation is sufficient to produce a scanty mucoid secretion. These are retention cysts; sometimes two or three occur in the course of one gland. The condition is usually bilateral. However, the lids of one eye are often much more affected than those of the other. The condition is met with in adults, seldom in children.

Etiology.—Degenerative changes taking place in the tarsus are probably accountable for the formation of the cysts. What excites this change is not known.

Symptoms.—The annoyance to the individual is often considerable. The sensation as of a foreign body in the eye is experienced, and there is often some interference with the use of the eyes because of the secretion present. Accompanying this condition, hypertrophy of the tissue about the mouth of one or more of the Meibomian glands may occur, producing a slight irregularily of the margin of the lid.

Treatment.—The cyst should be opened, the incision being made on the conjunctival surface in the long axis of the Meibomian gland.

[1] Zeit. f. Augenh., Nov., 1901.

The contents of the cyst, which is gelatinous, should be curetted out. An antiseptic ointment (bichloride vaseline, 1 to 4000) may be introduced into the conjunctival sac two or three times daily, or an antiseptic solution may be dropped into the eye, three of four times daily, until healing ensues. A cure may be effected in the course of a few weeks or months. As a result of treatment, the surface of the tarsal conjunctiva presents small cicatrices, and is somewhat irregular, but is not sufficiently rough to cause undue friction on the cornea.

Infarcts.—Some of the acini of the Meibomian glands, in elderly people especially, become filled with inspissated secretion which appears as small yellowish spots in the conjunctiva. These occasion no annoyance unless they contain lime salts, whose sharp edges perforate the conjunctiva and impinge on the surface of the bulbar conjunctiva or cornea, when they produce much irritation. This condition, as well as that in which the deposits of lime occur in parts of the conjunctiva other than the tarsal conjunctiva, is known as *lithiasis conjunctivæ.* It is most commonly seen in those with a rheumatic or gouty diathesis.

Treatment.—The minute masses should be removed as soon as they occasion any irritation whatever. This may be done under cocaine anesthesia by means of a sharp Graefe knife and small spud. The concretion is cut down upon and then lifted out of the depression which it occupies. Similar deposits of lime salts are apt to occur during the life of the individual.

Purulent Inflammation.—In certain cases, without marked swelling of the lids and with but little conjunctival irritation, a condition of *pyorrhea* of the Meibomian glands develops. On everting the lid the course of the gland is marked by a hyperemic line, and, on pressure, a small drop of pus appears at the mouth of the affected gland. The affection occurs in children and young adults, and is due to the entrance of pyogenic microörganisms into the gland.

Treatment.—This consists in slitting each gland from the opening of its duct to its distal extremity, or as far as it is affected, and by treating it with antiseptic solutions. It sometimes occurs that all of the Meibomian glands of the lids on one or both sides become involved. Nothing short of a free opening suffices to promote a cure.

Milium.—*Milium* of the lids is sometimes observed. It is associated with milium of the skin of the face. The condition is one of retention cysts of the sebaceous glands, and is manifested by small, whitish, rounded prominences on the lids.

Tophi.—In gouty individuals deposits of the biurate of soda sometimes take place in the skin of the lid, producing slightly elevated, bluish nodules, 5 to 8 mm. in diameter, hard and non-elastic. Slight pain may be occasioned.

Treatment.—Removal by incision and curetting or dissection. The patient should be given proper diet and remedies to correct the diathesis.

Retention Cysts.—Retention cysts of the glands of Moll, due to closure of the mouth of the duct, are observed. They occur in children and in adults, and are manifest in the form of small, translucent, hemi-

spherical elevations on the intermarginal space. They cause some annoyance to the individual by the irritation produced. The sensation is much as though an eyelash were in the eye. Often two or three cysts are observed on the margin of the lid at once. No redness of the lid and no change in secretion from the conjunctiva are occasioned, but lachrymation is increased.

Treatment.—The cyst should be opened with the point of a small knife, or by pressure. Healing takes place rapidly. No bad results occur.

Ephidrosis (*Hyperidrosis*).—This is a very rare condition. It is characterized by profuse sweating of the lids associated with profuse sweating of other parts of the face and body. It has been observed in cases of unilateral sweating. The secretion sometimes produces excoriation of the folds of the skin of the lids, particularly at the outer commissure.

Etiology.—The cause is not known.

Treatment.—Constitutional irregularities should be sought for and corrected, if existing. Locally, the treatment should be directed to the excoriation, which will be remedied by the use of protective ointments and desiccating powders.

Chromidrosis (*Ephidrosis Tincti; Seborrhea Nigricans*).—Colored sweating is of very rare occurrence. The lower lid is usually affected. It is characterized by the presence of a bluish or black oily secretion, which partly covers the lower lid. It may be wiped off with a cloth dipped in oil. The condition is most frequently met with in young women, and is supposed to be due to sexual or systemic irregularities.

Treatment.—Systemic irregularities should be corrected. The deposit may be removed by wiping with any bland oily substance, but it soon recurs. It eventually disappears spontaneously.

Syphilis.—This disease manifests itself in the lids in all the forms met with in the skin in other parts of the body. The primary sore (chancre), which is sometimes observed, occurs at the margin of the lid, and presents the same characteristics as chancre occurring in other parts of the body—slightly elevated dusky red base, furfuraceous or slightly ulcerated apex, induration. In some cases the ulcer is deep, the edges raised and irregular. The pre-auricular and submaxillary glands are enlarged. The papular syphilide and the copper-colored patches are observed as secondary manifestations. They do not differ from the same manifestations that appear on the skin in other parts of the body. As tertiary manifestations, tubercular syphilides, gummata and bullæ (rupia) occur. The lesions which appear as tertiary manifestations may result in quite extensive destruction of tissue. The tubercular syphilide appears as a purplish, rounded elevation, which may attain a diameter of 1 cm. or more. At first smooth, it breaks down in the course of a week or ten days, forming a large, deep ulcer. Syphilitic fissure of the external canthus occurs rarely.

Tarsitis.—The only manifestation of syphilis in the lids that differs from the manifestations that occur in other parts of the body is *tarsitis*, a chronic, often uniform, thickening of the tarsus. The upper lids are

chiefly affected. The disease is bilateral. There is no pain accompanying the thickening, which advances extremely slowly. Tarsitis is a manifestation of tertiary syphilis. It is sometimes observed in hereditary syphilis. Feuer[1] mentions a case of congenital tarsitis occuring in an infant of three months. The convex margin of the lid on the left side (the side more affected) reached the margin of the orbit. The eyelids could be opened, but very little. There were ulcers on the lids and enlarged cervical glands. Autopsy showed congenital syphilis.

In this condition the lid becomes twice, and sometimes even three times, as thick as in the normal. The skin is tense and there is evidence of slight venous congestion of the tissues above the tarsus, but there is little tendency to break down. However, this has been observed. The weight of the lid and the deformity occasioned are annoying to the patient. Incision discloses a bloodless, lardaceous condition of the tarsus, indicating an infiltration similar to that of gumma. The conjunctiva may become hyperemic and granular.

Treatment.—All of the manifestations of syphilis of the lid require vigorous systemic, antisyphilitic treatment. Locally, inunctions of mercurial ointment may be employed in the non-ulcerative forms. In the ulcerative forms, cleansing with a solution of bichloride of mercury, 1 to 2000, and the inspersion of calomel should be practised. In tarsitis spontaneous recession of the process may occur, leaving the tarsus in an atrophic condition, thinner even than in the normal state.

Chancroid.—Chancroid of the eyelids occurs rarely. It is characterized by the appearance of a shallow ulcer or ulcers at the margin of the lid, and is ordinarily due to autoinfection. The margin of the opposing lid where it comes in contact with the primary sore may become involved. The neighboring lymphatic glands may or may not become enlarged. The ulcer heals readily by the proper observation of cleanliness and the use of antiseptic remedies.

Leprosy.—The eyelids present a condition that does not differ from leprosy of the skin in other parts of the body. Destruction of a part or the whole of the eyelid may occur as a result of the formation of leprous tubercles. Loss of eyelashes and eyebrows occurs, and anesthetic patches of a color paler than the surrounding skin not infrequently develop.

Lupus Vulgaris (*Tuberculosis*).—Lupus affects the lids sometimes as a primary affection, but more often as an extension from the skin of the face.

Etiology.—It originates in the form of small reddish-brown papules (tubercles), in which the tubercle bacillus is found. These papules may coalesce and break down, forming a shallow ulcer with irregular outlines and an uneven base. The ulcer may advance and cause much loss of the tissue of the lid. The papules may exfoliate without ulceration and undergo atrophy. The process is essentially a chronic one, extending over many years. In some cases the ulcer is destructive to a high degree

[1] Ung. Med. Presse, 1898, 20.

(*lupus vorax*); in other cases but little damage is done to the deeper tissues. In many cases one part of the ulcer heals, leaving a superficial, glistening, reddish cicatrix; while another portion advances, involving a fresh area. By this process a track of cicatricial tissue is sometimes left.

Diagnosis.—The ulcerative form is at times confounded with epithelioma of the lid, but the history of the case and the presence of bordering cicatrices, which do not appear in epithelioma, with the microscopic findings will suffice to make the diagnosis.

Lupus erythematosus is a form characterized by well-defined patches, with reddish, elevated, irregular borders. The centre of the patch is atrophic and slightly sunken, and is covered by light yellow scales or crusts of sebaceous matter. The patches may coalesce. They may leave pale, superficial cicatrices, or the cicatrix may be bright red in color. Pustular miliary lupus, the same affection with an eruption that assumes various forms, may affect the eyelids.

Treatment.—Curetting followed by thorough cauterization gives excellent results. The ulcerated surface may be removed by caustic paste. Excision may be practised if the affected area is not too extensive, and the loss of tissue may be replaced by the appropriate transplantation of cutaneous flaps. Multiple scarification with the subsequent application of iodoform may be employed. It must be remembered that the tissue is superficially invaded by the tubercle bacillus, and that all bacilli must be removed to effect a cure. Therefore, all procedures to be successful must be sufficiently comprehensive to take in the entire affected area. Exposure to the Röntgen rays is now being tried with some promise of success.

Blastomycosis.—This disease, which may affect any part of the body, begins as a red papule with a scaly apex. It develops into a flat, elevated plaque with uneven surface and red, elevated borders. The surface is covered with scales, and bleeds on their removal. A mucopurulent discharge takes place. Small abscesses form in the floor and in the margins of the affected part. Large areas of the skin may become involved. The eyelids are affected in about twenty-five per cent. of the cases.

Etiology.—The disease is due to the presence of a fungus of the genus *oidium*.

Treatment.—Excision, curetting, *x*-ray. Large doses of potassium iodide internally. The iodides are found to be specifics in this disease. Of the cases reported, the greater number have occurred in or near Chicago, Ill., U. S. A. The characteristics of the disease have been well described by Wood[1] and by Wilder.

Botryomycosis.—Faber[2] reports the observance of a small tumor, which appeared four months before, in the middle of the margin of the upper lid. New nodules developed; the lid was irregularly thickened; numbers of small nodules were observed on everting the upper lid, each

[1] Annal. of Oph., Jan. 1904, xxii, 1.

[2] Nederlandsche Oogheelk. Rydragen, 1897, 3, p. 24.

of which presented a small opening from which a mucoid, granular mass could be expressed. The small spherical granules consisted of the fungus—botryomyces.

Treatment.—Evacuation, and the application of germicides.

Blepharochalasis (Fuchs).—**Etiology.**—This condition is due to a redundancy of skin of the upper lid, which hangs over the margin of the lid, particularly its outer half, and sometimes comes in contact with the eyeball. The skin is usually thin and atonic; it may show evidence of venous stasis and produce a marked ptosis by its weight. Microscopic examinations made by Fuchs, Fehr, and others disclose atrophy of the skin and subcutaneous connective tissue, with dilatation of lymph spaces. The condition is seldom met with in the young, although Fehr reports a case in a girl aged twenty-one years.

Treatment.—Treatment consists in the excision of enough of the fold of skin to correct the deformity. The results are satisfactory.

Elephantiasis.—This affection due to a chronic inflammatory obstructive disease of the lymphatics with associated thickening of the subcutaneous tissue, sometimes affects the lids. Enormous thickening of the lid ensues rendering it impossible, because of the weight, to open the eyes. The upper lids are more affected than the lower. To designate the cases in which the lymphatics alone are involved, the term *elephantiasis lymphangiectodes* is employed; in cases in which the bloodvessels are also involved, the term *elephantiasis telangiectodes* is used. The condition is sometimes congenital. Van Duyse[1] describes a case in an infant. A hemispherical, elastic tumor occupied the left frontal region, involving a portion of the cheek and extending beyond the median line. The skin was not movable over the tumor, but was smooth and unchanged. On incision (postmortem) a yellowish serum escaped. Many cysts, representing dilated lymph vessels, were found. These contained blood corpuscles as well, indicating a connection between the lymph spaces and the bloodvessels. Mowat[2] mentions a boy, aged eight years, who presented a soft swelling of the right eyelids. Pressure on the lower caused the upper lid to swell, and pressure on both produced a swelling behind the right ear.

Etiology.—It is not definitely known whether the Filaria hominis is causative in elephantiasis of the lids or not. Further investigation is necessary to determine the cause.

Treatment. Relief may be obtained by removal of sufficient tissue to enable the patient to open the eyes.

Morphœa (*Morphœa Alba Plassa*).—A trophoneurosis has been observed affecting the skin of the lid.[3] It is characterized by the formation of a well-defined smooth patch, often slightly elevated, hard to the touch; later atrophy ensues and the patch becomes slightly sunken.

Tumors of the Lids.—These may be divided into benign and malignant. Some of the so-called benign forms develop into malignant tumors under favorable conditions.

[1] Arch. d'ophth. xix, 5, p. 273.
[2] Trans. Ophth. Soc. Un. K., xvi., p. 42.
[3] Dodd, Trans. Ophth. Soc. U. K., xii., p. 31.

Adenoma.—Adenoma of the Meibomian glands, of the sebaceous glands, of the glands of Krause and of Moll has been observed. Adenoma of the Meibomian glands apparently degenerates into glandular carcinoma. The author has observed two cases, in the early stage of each of which the diagnosis of adenoma was made on microscopic examination of excised parts. In both cases the termination was one of malignancy.

Angioma.—Vascular tumors of the lids are observed in which enlargement and increase in the number of the capillaries and minute arterioles occur. These growths are known as *telangiectatic tumors.* They are bright red in color, affect the skin only, are but slightly elevated, and are flat. They are usually associated with similar areas on the face, and have little tendency to increase.

Aneurysms by anastomosis (angiomata that are composed largely of arterial vessels) are tumors of a bright red color, are somewhat elevated, and tend to increase slightly in size whenever the heart action is increased, or when the quantity of blood in the head is increased by position, exertion, or from whatever cause. These growths are frequently accompanied by enlarged veins, which serve to impart a bluish tone to portions of the tumor (*angioma venosum*)

Vascular tumors are observed in which large venous spaces are found (*angioma cavernosum*) between septa composed of connective tissue or of cells which closely resemble endothelial cells. The last named tumors have a bluish appearance. They increase in size when the head is dependent, when the venous circulation is interfered with by straining, coughing, or by position. The two last mentioned varieties tend to increase in size. They may advance until the upper part of the head, orbit, and brain cavity are involved. Angiomata are congenital in origin.

Pathology.—The character of the tissue in angioma differs considerably. The arterial growths present fairly well-formed vessel walls with intima, the vessels being of moderate size but numerous, anastomosing freely. A scant connective tissue-stroma is present. In the venous variety there is little wall structure, but the endothelium is backed up by septa that are clearly made up of fairly well-formed connective-tissue fibers. In cavernomata it is frequently found that the septa are composed of the same form of cells that line the venous wall, in fact, that the term *angio-caverno-endothelioma* more nearly describes the condition. This structure is not *always present* in the cavernomata, the septa being formed of young connective-tissue cells in some cases.

All angiomata tend to increase, those whose framework is composed of more mature connective-tissue elements less rapidly than those composed of young connective-tissue elements and of the endothelial cells. Thorough removal of the last two is very desirable. It is well-known that if parts of the tissue are left the growth recurs. A low degree of malignancy is possessed by these growths. Metastases do not occur.

Treatment.—The forms other than the telangiectatic variety should be removed, or treated so that they will not advance, at as early a time as possible. The methods employed are:

Electrolysis.—This is efficient if the growth is confined to the lid, that is, does not extend into the orbital tissue. The arterial tumors are more amenable to this form of treatment than are the venous and cavernous growths. The endeavor is to obliterate portions of the vessels and to coagulate the blood contained in them. The base of the tumor is pierced by the needles of the cathode and the anode, so placed that they do not approach each other nearer than 3 or 4 mm. at any point. Sufficient current should be supplied to produce the white foam about the cathode (3 to 6 milliamperes). The needles should be introduced at intervals of 2 to 3 mm. about the entire base of the tumor. A number of sittings may be required. A platinum needle for the positive pole, at least, is recommended.[1] Electrolysis is painful, and requires an anesthetic.

Excision.—In the early stage of the development of angioma, particularly of the venous type, excision can be satisfactorily practised. It will be found that the dilated veins or venous sinuses are inclosed in an imperfect, delicate, connective-tissue capsule. The tumor in its capsule should be carefully dissected out. Bleeding is profuse if the tumor is incised. It is expedient to control the hemorrhage by means of ligature or hemostatic forceps. When the growth has become very extensive, its removal by excision is very difficult, if not impossible.

Injections.—Hot-water injections for this form of growth have been advocated by Wyeth and by Griffith.[2] There is danger from embolism, but Griffith is of the opinion that this may be overcome by use of water that is very near the boiling point, securing immediate and firm coagulation. Gifford[3] employs absolute alcohol, injecting two or three drops into various parts of the tumor every two or three weeks until the growth has disappeared.

Ligatures.—It is sometimes possible to destroy the growth by cutting off its blood supply by subcutaneous ligature. A number of ligatures (which may be catgut) are required. This method is advantageously combined with electrolysis.

Fibroma.—Fibrous tumors are of rare occurrence. They appear as pendulous tumors springing from the chorium or from the subcutaneous tissue. Usually small, they may attain a large size (*molluscum fibrosum*). There is no evidence of inflammatory reaction, no tendency to return on removal. They occur in adults. They are closely associated with the neurofibromata.

Treatment.—Excision.

Plexiform Neurofibroma.—This growth (Fig. 120) is rather soft, elastic and diffuse; it usually affects the upper lid on one side throughout its entire thickness, extending into the brow and onto the temple. This form of tumor occurs in children and young adults. In a case observed by Friedenwald[4] the growth was congenital. The lid is much thickened, rendering it impossible to open the eye. The skin presents the appearance of slight venous congestion, its surface is irregular, as is also the conjunctival surface. The conjunctival surface is often suggestive of

[1] Nieden, Le Plat.
[2] New York Med. Jour., May 2, 1903.
[3] Oph. Rec., December, 1906.
[4] Johns Hopkins Hospital Reports, vol. ix.

trachoma. Pain at intervals, often very severe, is characteristic of these growths. They are often congenital.

Pathology.—The growth is composed of numerous loosely placed connective-tissue fibers, interlaced with a network of nerve fibers and bundles, medullated and non-medullated. In some cases the vessels are increased in number and in size.[1]

Treatment.—Excision gives the best results.

Fig. 120

Plexiform neurofibroma. (Friedenwald.)

Lipoma.—Fatty tumors rarely occur. They are small, soft, subcutaneous tumors which increase in size extremely slowly.

Treatment.—Excision.

Nevus.—Nevi are of various forms. The pigmented variety is usually small, slightly elevated, and hairy. The vascular, non-pigmented nevi are slightly elevated and composed of dilated arterial vessels ("strawberry patch"), sometimes containing many venous vessels, and presenting a bluish appearance.

Nevus vinosus, or the small, bright red patch with radiating ("spider leg") vessels, also occurs.

Treatment.—Electroylsis, excision. Nevus vinosus is successfully treated by destroying its head or central point with a small cautery, or by applying fuming nitric acid with a small, pointed piece of wood.

Papilloma.—Papilloma of the lid usually occurs as the ordinary wart (verruca), but it is sometimes observed on the margin of the lid as a red, villous mass, its base bathed in seropus.

[1] For an exhaustive discussion of the pathology, see Parsons, Path. of the Eye, vol. ii, p. 730.

Treatment.—Excision and cauterization of the base.

Cornu (Fig. 121).—Horny growths sometimes appear on the lids. They spring from the margin of the lid most frequently, and are usually long and thin. Often light in color, they may be very dark. When small and between the eyelashes, they may not be noticeable, but occurring on other parts of the lid, they are very conspicuous. They appear to develop from the walls of a sebaceous gland or cyst.

Treatment.—The base of the growth extends beneath the surface of the skin. This should be dissected out. If much defect in the lid is occasioned, it should be closed by a suitable plastic procedure.

Fig. 121

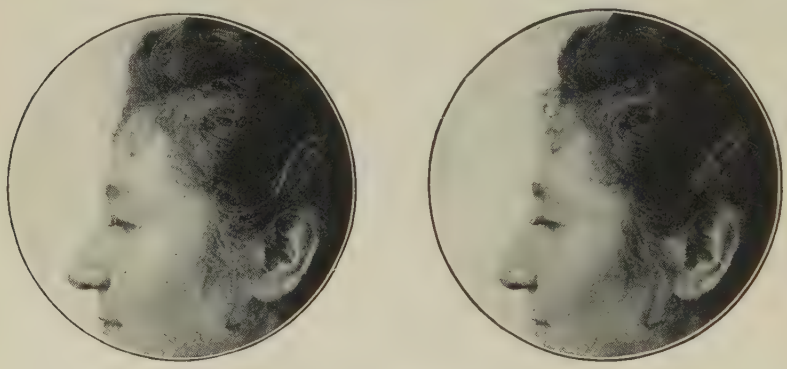

Cornu of eyelid. (Stereoscopic picture.)

Enchondroma.—Enchondroma is seldom met with.

Osteoma.—Osteoma is very rare. Sbrana[1] mentions a case of a bony tumor occurring in the upper lid of an Arab, aged forty-eight years. The growth was probably congenital.

Xanthelasma.—Xanthelasma appears as dull, yellow patches of irregular shape, flat and slightly elevated, in the skin, usually of the upper lid, most frequently near the inner canthus. The patches are almost always bilateral, but may be more extensive on one side than on the other. They produce no symptoms, and are objectionable only on account of the disfigurement. The growth occurs in elderly adults, and is more common in females than in males.

Pathology.—Rather large cells, which contain minute fat globules and granules of brown or yellow pigment, are numerous in these growths. Pincus and Pick[2] have found that the cells of xanthoma contain a body resulting from the combination of a fatty acid with cholesterin, to which the color is due.

Treatment.—Excision may be performed under cocaine infiltration anesthesia. If the growth is somewhat extensive, cicatricial contraction after excision may produce unpleasant deformity, but small areas may be removed without fear of this.

[1] Bull. d'oeul, vol. xxiii, p. 177.

[2] Deutsche med. Woch., 1908, p. 1426.

Electrolysis is also said to be very effective. Needles should be used on anode and cathode, and they should be made to pierce the growth at frequent intervals. Every part of the growth must be treated to insure success. After the needles are inserted into the growth the circuit is closed and the current is slowly increased by means of the slide on the rheostat, from zero up to 6 or 8 milliamperes, again reducing after two or three minutes.

Lymphoma.—A tumor, composed largely of lymphoid tissue. It occurs at times in connection with wounds of the lids.

Treatment.—Excision.

Molluscum Contagiosum (*M. Epitheliale; M. Sebaceum*).—This is a circular, elevated tumor varying from 1 to 10 mm. in diameter, and from 0.5 to 5 mm. in height, approximately cylindrical in shape, with slightly rounded top, umbilicated. Pressure on the sides of the growth will cause a small, white cylinder of secretion to escape from the umbilication If the pressure is excessive, the inner wall of the growth is forced from the nipple-like elevation and lies everted on the surface. These growths frequently occur in clusters; two or more may be distributed over the lids. They are not confined to the eyelid, but may occur on the skin on various parts of the body.

Molluscum contagiosum affects children most frequently. Its contagious nature is manifest by the affection of different members of a family, and by its diffusion among the inmates of asylums for children and residential schools, sometimes as an epidemic.

Pathology.—The growth springs from the chorium, and is thought to be due to the presence of a parasite (molluscum bodies) belonging to the class *coccidia.* The parasite invades the cells of the skin, stimulating the growth. The parasite multiples in the cells and is cast off. The epithelial detritus forms the white sebaceous mass that is found as the contents of the growth. The identity of the parasite is uncertain. Further confirmatory evidence is necessary. Microscopic section shows the wall of the growth to be composed of the skin, the interior of a fibrous wall thrown into many folds, the inner surface of which is covered by epithelium in a state of proliferation. Peculiar, capsulated, oval corpuscles (molluscum corpuscles) are present.

Diagnosis.—Molluscum contagiosum may be mistaken for epithelioma. This can be excluded by ascertaining the contents of the growth.

Treatment.—The mass may be excised, or the hypertrophied glandular mass may be extruded by firm pressure between the thumb nails or by means of forceps. On account of the contagious nature of the affection, the patient should sleep alone and use separate towels.

Dermoid Cysts.—Dermoid cysts (often termed sebaceous cysts, since they contain sebaceous material; see Cysts of the Orbit) appear as rounded eminences, the size of a pea or hazelnut, usually situated near the upper outer margin of the orbit—frequently at the upper inner angle of the orbit—and are nearly always attached to the periosteum. The skin is movable over them. They are congenital in origin. They contain hairs and cholesterin crystals in a mass of sebaceous material,

which is sometimes quite firm and lamellated. Dermoid cysts increase slowly in size. They are benign.

Sebaceous Cysts.—These may occur in the skin of the lids as in other parts of the body. They are usually small, 2 or 3 mm. in diameter, but may be much larger. Unlike dermoid cysts, the skin is not movable over them. The wall consists of connective tissue lined with cuboidal cells which are undergoing degeneration. They contain sebaceous material.

Treatment.—Excision. The dissection should be done carefully in order to remove the cyst entire without evacuating the contents. Every vestige of the wall of the cyst should be excised. A defect in the bony wall against which the tumor rests, due to absorption, is often observed with dermoid cysts.

Cysticercus.—This entozoon is met with occasionally in the eyelid. It appears as a small, rounded tumor. On opening the cyst a clear, sometimes turbid, liquid is discharged. The parasite or its remains will be found.

Treatment.—The cyst wall should be removed by dissection.

Echinococcus Cysts.—These are rarely observed. They are usually small, but may extend into the orbit, and even into neighboring cavities. The cyst contains a thin, transparent, or slightly turbid fluid, hooklets of the parasite, and sometimes "daughter" cells.

Treatment.—When practical, the cyst wall should be removed by dissection. If this cannot be done, the contents should be evacuated and adhesive suppuration established by treating the inner surface of the wall of the cyst with nitrate of silver or with strong carbolic acid. If the cyst wall is not changed in character, the opening into it closes and the cyst refills.

Fig. 122

Epithelioma of inner canthus. (Photograph by Geo. S. Dixon.)

Malignant Tumors. — Carcinoma, in the form of skin cancer or epithelioma, is not of infrequent occurrence. It is peculiar to advanced adult life (Fig 122). The growth appears at or near the margin of the lid, in the form of a small elevation, the apex of which at first becomes scaly, and may soon be covered by a light crust. The growth may remain in this state for years, the crust becoming detached and a new crust appearing. The elevation is seldom more than one to three millimeters. (In one patient observed by the writer the growth remained in this state, almost unchanged, for thirteen years.) As the process advances, an ulcer is formed, often of irregular shape, which may be shallow (flat carcinoma, rodent ulcer) or deep. The borders of the ulcer are slightly elevated, rounded, indurated, ragged, and often present a waxy appear-

ance. The growth advances and may involve the orbit and surrounding tissues, producing extensive destruction. The fibrous coat of the eyeball resists the encroachment of the growth for a long period of time. Enlargement of neighboring lymphatic glands, particularly the preauricular gland, accompanies the development of epithelioma, and in the later stages a cachectic condition is established. Metastasis may occur.

Etiology.—Unknown.

Pathology.—The growth is characterized by the development of epithelial processes which grow down into the subcutaneous tissue. Masses of epithelial cells are found growing in the deeper structures, entirely separate from the primary processes. Circular masses of cells (whorls) are met with in various parts of the growth. An infiltration of small cells is found in and about the growth.

Diagnosis.—Epithelioma may be confounded wi h lupus. However, the atter is a disease of youth and the history is decidedly different. Scars in the track of the growth are never met with in carcinoma. Epithelioma may be confounded with molluscum contagiosum (see Molluscum Contagiosum).

Treatment.—Very excellent results are obtained by subjecting the growth to the influence of radium bromide, if the growth has not involved the deeper structures to too great an extent. The tube containing the radium is strapped to the growth. Exposures are of ten minutes' duration and at intervals of ten days to two weeks until the maximum benefit is derived. The more recent the growth the better the results. The Röntgen rays are also of service, particularly in the treatment of early stages of epithe ioma. The exposures may be five to ten minutes in duration with a tube of medium tension at a distance of ten inches from the anode. The x-rays should pass through the aperture of a cylinder affixed to a lead mask which covers the x-ray tube. Exposures should be made twice a week until the maximum benefit has been derived. Relapses after apparent recovery are not uncommon.

Excision in the very early stage of the growth is followed by excellent results. The mass removed must extend well into the normal tissue to make the danger of return as remote as possible. The excised or destroyed tissue may be replaced by suitable skin flaps or Thiersch grafts. It is sometimes necessary to remove the lid or lids affected and part or the whole of the contents of the orbit. Caustic paste may be employed (consult works on dermatology). In advanced cases palliative measures only are advisable. The surface may be curetted and the tissues thoroughly cauterized; it may be cleansed with solutions of permanganate of potash or with hydrogen dioxide; aristol may be dusted on.

Adenocarcinoma.—This affects the eyelids in rare cases. Beginning apparently as a simple adenoma, it produces a thickening of the lid, soon involving the entire lid. The malignancy of the neoplasm appears to increase with its growth.

Treatment.—This should be radical, at an early stage.

Sarcoma.—This form of malignant tumor develops as a primary growth from the connective tissue of the lid. It appears as a rounded, usually slightly reddened, elevation in the lid. At first it somewhat resembles chalazion, but the position is not always over the tarsus and the skin is not freely movable over it. The growth may be very slow, but it may advance rapidly, become converted into an ulcer, affect the deeper structure, appear in other parts by metastasis, and rapidly prove fatal.

Etiology.—Traumatism is followed by sarcoma in a small percentage of cases. Causes other than this are unknown.

Pathology.—The growth may be composed of round or spindle cells, or both. In some of the cases the cells are pigmented, and pigment granules are found in the stroma (melanosarcoma).

Diagnosis.—This can be made quite readily with the microscope. It may be confounded with lymphoma, syphilitic tubercle, and gumma. In the last two named the Spirochæta pallida may be found. In cases where the microscope does not suffice to make the diagnosis clear, anti-syphilitic treatment should be employed sufficiently long to decide the character of the growth.

Treatment.—Excision at a very early stage is necessary in order to afford any chance of recovery. According to Wilmer, recurrences take place in 40 per cent. of cases in which early and thorough removal has been performed. The Röntgen rays are of little service in sarcoma. Radium promises very well in cases in which the growth is small. In a patient of Dr. P. A. Callan, treated by Dr. Robert Abbe, of New York, complete recovery ensued. The growth affected the lower lid, and was about 1 cm. in its longest axis.

Cylindroma.—A peculiar form of tumor allied to sarcoma, and presenting the same clinical picture. It occurs in adults, and develops slowly. Microscopically, the growth presents numerous hyaline cylinders, which take the stain poorly. The cylinders appear to develop from the small blood or lymph vessels. Such tissue has also been observed in endothelial tumors of the orbit, apparently forming the part of the tumor that has been poorly nourished and has undergone a partial degeneration or hyaline change. The "mixed tumors" of the lachrymal and parotid glands present this form of tissue.[1] Cylindroma is sometimes encapsulated. It is less malignant than ordinary forms of sarcoma.

Treatment.—Radium may be tried; if not successful, excision should be resorted to.

Burns of the Eyelids..—These occur from various causes; steam, flame, molten metal, gunpowder, ignited oils, etc., and result in partial or complete destruction of the skin of the lids. They resemble burns in other parts of the body, and should be treated by the application of bland, oily substances, as plain sterilized vaseline or vaseline with boric acid. The ordinary carron oil is excellent. The oily substances should be kept applied by means of a gauze mask if the burn is extensive. Healing

[1] Cylindroma of Orbits and Lids, Jour. Amer. Med. Assoc., September 30, 1905.

takes place by cicatrization, and is often followed by partial or complete eversion of the lid—*cicatricial ectropion.*

Gunpowder Burns.—These result usually in filling the skin with powder grains without much loss of tissue, producing a painful condition and considerable disfigurement. Little need be done in the way of picking out individual powder grains. The surface should be washed with the peroxide of hydrogen twice daily, using absorbent cotton and rubbing the skin quite vigorously. The cotton fiber catches and mechanically removes projecting particles, and the peroxide decolorizes the discolored tissue and remnants of powder grains almost completely. The surface of the skin should be smeared with sterile vaseline after each application of the peroxide. In severe cases sufficient vaseline or other bland oil should be kept in contact with the skin by means of a gauze or other suitable mask until recovery is complete.

Injuries of Eyelids.—Contusion of the lids is followed ordinarily by an escape of blood and serum into the tissue of the lid, causing a swelling and discoloration of the tissue known as "black eye," or *ecchymosis.* In some cases a hematoma is produced, which may break down and form an abscess.

Treatment.—If an application of cold, in the shape of compresses dipped in ice water, cracked ice in a napkin, or a piece of ice wrapped in a napkin, or in any available form, be made for thirty to sixty minutes very soon after the blow is received, but little swelling from the escape of blood and serum need occur. Cold acts as a hemostatic; it is only of value in the first twelve hours after the injury. Subsequently, heat, preferably moist heat, is serviceable. The problem now is to hasten absorption, and this is accomplished by applications of moist heat, the application being made for twenty or thirty minutes at a time, four or five times daily. As the blood is disappearing, the skin of the lid assumes a yellow color from the diffusion of the blood pigment. This gradually disappears.

Lacerating Injuries.—Lacerating injuries of all kinds occur. The wound is treated as wounds of other parts of the body, the surface rendered sterile by means of suitable solutions. The bichloride of mercury in solution (1 to 2000) is ordinarily employed. If small, the wound may be closed by means of a collodion dressing; if large, particularly if the lid margin is divided and fibers of the orbicularis are cut across, the parts must be carefully brought together and held in position by means of silk sutures. A collodion dressing may be placed over this. The sutures should be removed in six to eight days. Great care is necessary in the adjustment of the wound in these cases, as contraction of the fibers of the orbicularis palpebrarum would otherwise cause displacement of the flaps and deformity result.

Tetanus.—Tetanus following lacerating wounds of the lids has been reported by Ramsay, Keiper, Darier, and others. The tetanus developed two to three days after the wound was received.

Emphysema.—Fracture of the lachrymal, of the nasal, and of the frontal process of the superior maxillary bone permits the entrance

of air into the tissue of the lid from the nasal cavity. On blowing the nose after such an injury, the lid (sometimes both upper and lower) becomes enormously distended with air. The surface of the lid appears smooth, and is not particularly congested. On pressure, crepitation is produced. Forcibly blowing the nose may cause the air to enter the tissue of the lids for two or three days after the injury. The swelling subsides in one or two days if fresh air is not introduced.

Treatment.—No special treatment is required. The condition usually subsides without leaving a trace. The patient should be cautioned against disturbing the injured parts and against forcibly blowing the nose.

Alopecia.—Morax mentions alopecia of the lids due to keratosis pilaris. Alopecia occurs in hysterical girls who periodically pull out the eyelashes. The writer has observed such a case. Alopecia results from chronic blepharitis marginalis and syphilis.

Premature grayness of the eyelashes has been reported by Latin, following repeated attacks of migraine.

Edema of the Lids.—This, although a symptom, deserves special mention.

Passive Edema.—This occurs in connection with general anasarca, when both lids are affected; in old people whose tissues are atonic, particularly noticeable in the morning, affecting the lower lids; as an accompaniment of albuminuria in some cases, also affecting the lower lids most frequently. In gouty crises it is sometimes present, affecting both upper and lower lids. In these cases it is not entirely passive. Active edema accompanies inflammatory processes of the Meibomian glands, when it may extend along the border of the lid affected or be confined to one portion of the lid. It often masks the true affection. It accompanies inflammation of the lachrymal apparatus, mention of which will be made when diseases of this part are described. It is present in a peculiar manner, affecting the border of the upper lid in inflammatory affections of the ciliary body, and in inflammatory conditions of the conjunctiva. There is a class of cases, occurring most commonly in children, in which the edema of the lids is excessive, coming on in twelve to twenty-four hours, so intense that the lids are closed and cannot be opened. The skin is tense and sometimes even brawny. There is no point of marked tenderness. On inspection a slightly flushed area with a single red point near its centre indicates that the skin has been bitten by an insect. On separating the lids the ocular conjunctiva may be found to be slightly edematous, but there is no redness and no secretion. The patient can be assured that the swelling will disappear in a day or two without disagreeable results. Edema of the lids developing every month with menstruation, lasting two to four days, has been reported (Andrieux).

Angioneurotic Edema.—This is not very uncommon. The so-called *essential* edemas apparently belong to the gouty and rheumatic type.

Diseases of the Eyebrows.—**Eczema.**—Eczematous conditions affect the eyebrows as they affect the lids.

Pediculosis.—Pediculi are sometimes found in the eyebrows, but not so frequently as in the eyelashes.

Treatment.—As in phthiriasis palpebrarum.

Tinea Tonsurans.—The brow is invaded at times by the *tinea tonsurans*, which produces the characteristic inflammation of the hair follicles. The disease runs its course in two or three weeks.

Treatment.—Epilation. The surface should be thoroughly washed subsequently with peroxide of hydrogen, followed by the application of an ointment of the bichloride of mercury, 1 to 3000.

Favus.—Favus affects the eyebrows rarely. It appears as small, circular, bright yellow crusts, slightly elevated and depressed in the centre, situated over a hair follicle. The hairs fall out and are permanently destroyed if the disease is permitted to continue for any great period of time. The skin beneath the crusts is hyperemic. There is intense itching; a mouse-like odor may be detected.

Etiology.—The disease is due to *Achorion Schönleinii*, a vegetable parasite which most commonly affects the scalp.

Treatment.—The crusts should be removed by soaking with oil, and subsequently washing with detergent lotions. The hair should be removed by epilation and the surface washed with peroxide of hydrogen, after which applications of sulphur or bichloride ointments may be made.

Atrophy of Eyelashes and Hair of Brow.—This, associated with atrophy of the finger nails, congenital in origin and apparently influenced by heredity, has been reported (R. Tilley).

Ptosis, Acquired.—**Etiology.**—Lesion of the basal nucleus of the third nerve, of the cortical nucleus situated in the sigmoid gyrus,[1] of the trunk of the third nerve, of the branch that supplies the levator muscle of the lid, or lesion of that muscle itself will produce ptosis. The lesion may be due to trauma, syphilis, multiple sclerosis, hemorrhage, rheumatism, and gout, or any disease that may produce peripheral neuritis. Acquired ptosis may be due to thickening of the tissues of the lid itself, as from the presence of a tumor or inflammatory products.

Isolated ptosis, unaccompanied by paralysis of other muscles supplied by the motor oculi, is usually due to disease of the nucleus of the third nerve, but may be due to lesion of the cortical nucleus situated in the sigmoid gyrus.[2]

Treatment.—In acquired ptosis the cause should be ascertained, if possible, and suitable remedial measures instituted. If the ptosis is confirmed, which is always the case in congenital ptosis, operation must be resorted to. (See chapter on Operations.)

Trichiasis.—This is a condition in which a part or whole of the eyelashes are turned inward against the eyeball as a result of cicatricial contraction of the tarsus and tarsal conjunctiva. The lashes that turn inward are seldom normal. They are stunted, often very fine and short, and of a pale color. The cilia are so nearly the color of the margin

[1] Arch. di Ottal., vol. iii, p. 322.

[2] Herter, Jour. Nerv. and Ment. Dis., 1895, No. 1.

of the lid, and so fine in some cases, that it is extremely difficult to detect them with the unaided eye. The constant friction of the cilia against the cornea and bulbar conjunctiva produces irritation of these tissues. There is an increase of vascularity of the ocular conjunctiva, superficial ulcers of the cornea may form, and at times a decided pannus develops. At times irritation that may be intermittent is experienced without appreciable cause. On careful inspection, one or two minute hairs may be found that rest against the cornea.

Etiology.—The cause of trichiasis is the same as that which produces cicatricial entropion, from which it differs only in degree. It may follow any local cicatrix of the tarsal conjunctiva. Operations for the removal of chalazia, internal hordeolum, burns, and loss of conjunctival tissue as a result of diphtheria or gonorrhea of the conjunctiva may bring about this condition.

Treatment.—See chapter on Operations.

Entropion.—This condition is characterized by a turning inward of the margin of the lid, carrying the eyelashes with it. Two varieties of entropion are described, spasmodic and cicatricial.

Spasmodic Entropion (*Entropion Spasticum*).—In the disposition of the fibers of the orbicularis palpebrarum muscle, the orbital fibers describe the arc of a circle, the concavity of which is downward in the upper lid and upward in the lower lid. When these fibers are forcibly contracted they tend to form the cord of the arc, forcing the intervening tissue toward the margin of the lid. The *palpebral* fibers of the orbicularis palpebrarum also describe the arc of a circle above and below, the concavities of which look backward and downward above, backward and upward below. Contraction of these fibers tends to straighten the margins of the lids and force them backward in cases where the contents of the orbit are not sufficiently prominent to support them. When the skin and subcutaneous tissue are flabby, atonic, and abundant, contraction of both sets of fibers of the orbicularis palpebrarum forces the tissue toward the margin of the lids and tends to cause them to become inverted. Spasmodic entropion is rare in the young; it is not uncommon in the aged. The absorption of orbital fat is conducive. In case of absence of the eyeball, both lids may be inverted; when the eyeball is present, the upper lid is seldom inverted, the rigid tarsal plate preventing. In cases in which the eye is sunken and the tissues of the lid atonic, as in the aged, forcible contraction of the orbicularis, such as may be excited by chronic conjunctivitis or keratitis, by bandaging or by any irritation to the eye, may produce spastic entropion. This condition not infrequently accompanies, and greatly complicates, cataract operations.

Treatment.—In some cases the condition can be corrected by means of adhesive plaster. A strip 1 cm. wide is attached by one end to the lid immediately below the lashes, and the other end is drawn down and attached to the skin of the cheek; or the skin of the lower lid may be painted with flexible collodion. If the entropion is due to bandaging, it is sometimes sufficient to discontinue the bandage, but this is not

always desirable. In such cases the plaster or collodion may be resorted to.

Operative Treatment.—See chapter on Operations.

Cicatricial Entropion.—This condition is produced by cicatricial contraction of the conjunctiva and the posterior portion of the tarsus, usually following trachoma. The tarsus becomes narrower, thicker, and sometimes much shorter than normal. The radius of its vertical curvature is greatly shortened. The acuity of the vertical curvature of the tarsus is most marked immediately above the margin of the lid. The contraction of the fibers of the orbicularis palpebrarum muscle in connection with the cicatricial contraction forces the tissues of the lid to the lid margin, eventually turning the eyelashes against the cornea. (For other causes, see Trichiasis.)

Fig. 123

Spasmodic entropion. (After Mackenzie.)

Fig. 124

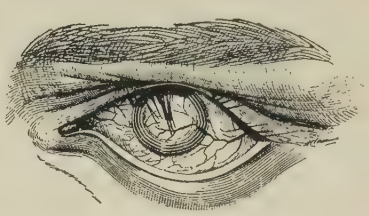

Cicatricial entropion. (Morax.)

Ectropion.—Ectropion is a condition in which the margin of the eyelid turns outward; it may be *partial or complete.* It is of four varieties—(1) spasmodic; (2) paralytic; (3) senile; (4) cicatricial.

1. **Spasmodic Ectropion.**—This occurs almost exclusively in infants and very young persons. The conditions favoring it are almost the opposite of those which favor spastic entropion. Tension of the skin of the lids is first necessary. This is occasioned either by swelling of the lids, as in acute conjunctivitis, or by an undue prominence of the eyeball, as in inflammation of the tissues of the orbit or exophthalmic goitre. Blepharospasm must also occur. The contraction of the arcs of fibers is the same as that which produces entropion (see page 188), the border of the arc of the orbital portion being at the curved margin of the tarsi. The margins of the lids are not particularly tense, and, as a consequence, the greatest constriction is at the curved borders of the tarsi, and the lids become everted. Examples of this form of ectropion are observed in infants with ophthalmia neonatorum. In attempts to treat the conjunctiva, slight traction is made on the skin of the lids. The infant cries, blepharospasm is induced, and the lids, both upper and lower, become everted. With increase in spasm, venous congestion becomes marked and the ectropion may be perpetuated. Ectropion formed in this way is complete. The normal condition is restored on subsidence of the swelling of the lid or reduction of the exophthalmos.

Treatment.—Spasmodic ectropion is remedied by reducing the conjunctival inflammation, in the cases due to this cause. In cases of non-inflammatory prominence of the contents of the orbit, a pressure bandage will usually suffice. In spasmodic ectropion due to tumor in, or inflammation of, the orbital tissue, surgical procedure, directed to the condition of the orbital tissue, may be necessary.

2. **Paralytic Ectropion.**—This variety is due to paralysis of the orbicularis palpebrarum muscle from disease of the facial nerve. The ectropion is partial, unilateral, and affects the lower lid only. The margin of the lower lid drops away from the eyeball, and often apparently becomes elongated. The weight of the upper lid maintains *it* in its proper relation to the eye. The lower punctum is removed from the eyeball, rendering it impossible for tears to escape by the natural way, and epiphora results. In paralytic ectropion lagophthalmos is present.

Treatment.—An effort must be made to restore the power of the orbicularis palpebrarum muscle. The cause of the paralysis must be carefully sought and suitable remedies given. Electricity is of some value after the immediate effects of traumatism, hemorrhage, exudation, or inflammation have subsided. If, after some months have elapsed, there is no evidence of improvement—medication and other treatment having been thoroughly tried—operative procedure may be resorted to.

3. **Senile Ectropion.**—This is partial, and affects the lower lid only. In old people the fibers of the orbicularis become relaxed, and the margin of the lower lid falls away from the eyeball. The lower punctum does not lie in contact with the ocular conjunctiva, consequently the tears do not flow into the canaliculi as they should, causing epiphora. Hypertrophy of the tarsal conjunctiva of the lower lid frequently results, which tends to increase the ectropion. This form is bilateral.

Treatment.—Massage of the lids and, in some cases, treatment of the conjunctiva of the lower lid by applications of solutions of nitrate of silver, 1 to 5 per cent., applied every second day, may do much to ameliorate the condition. In cases where considerable hypertrophy of the tarsal conjunctiva at the margin of the lid is present, the solid stick of the nitrate of silver may be thoroughly applied to the hypertrophied portion. The application may be repeated in five or six days if desirable. In cases not remedied by these procedures, operation may be resorted to, but it should be carefully considered before being attempted.

Fig. 125

Cicatricial ectropion.

4. **Cicatricial Ectropion.**—This may be partial or complete. Cicatricial ectropion which results from blepharitis marginalis (see page 166), associated with hypertrophy of the tarsal conjunctiva of the lower lid,

is partial, and affects the lower lid only. It is ordinarily bilateral. Other varieties of cicatricial ectropion follow destruction of some portion or the whole of the skin of the lids from burns, ulcers, operative procedures, or injuries; also from subcutaneous cicatricial tissue, as that following periostitis or caries of the orbital margin. The exposure of the conjunctiva to the atmosphere and particles of dust causes it to become thickened, uneven, and red. Sometimes it takes on a cutaneous appearance. The exposure of the eyeball in cases of extreme complete ectropion causes desiccation and often ulceration of the cornea.

Treatment.—Cicatricial ectropion is seldom remedied except by operation. (See chapter on Operations.)

Ankyloblepharon.—Ankyloblepharon is the condition present when the margins of the lids are adherent. It may be partial or complete. The condition is sometimes congenital (see page 157), but is more frequently due to operations, burns, ulcers, or disease processes which, at the same time, affect the conjunctiva.

Acquired ankyloblepharon is almost always associated with symblepharon, partial or total.

Treatment.—If the ankylosis is simple, that is, not associated with symblepharon, it is only necessary to divide the adhesions in order to restore the palpebral opening. In certain cases, where the ankylosis is broad and affects the canthi, a Thiersch graft may be required to cover the raw surface resulting from dividing the union between the lids.

Symblepharon.—See Conjunctiva.

Blepharophimosis.—This consists in the formation of a vertical fold of skin which overlaps the outer canthus. If the skin is retracted, it is found that the margins of the lids are not adherent, and that the tissues behind the fold are approximately normal. The condition is seen in individuals who suffer from chronic conjunctival or corneal affections, as a result of which blepharospasm is induced, and the lids are kept moistened more or less constantly with tears and secretion from the conjunctival sac. Contraction of the fibers of the orbicularis tends to drag the outer fold of skin over the outer canthus. In addition, shrinking of the skin occurs.

Lagophthalmos.—This term denotes a condition of the eyelids in which they cannot be completely closed, or in which they remain open during sleep. As a result of the inability to cover the eyeball, certain parts are constantly exposed and suffer from desiccation. In cases in which the constant aperture is narrow, the cornea is easily sheltered beneath the upper lid, a strip of ocular conjunctiva only being exposed. This becomes hyperemic, uneven, and somewhat thickened. As closure of the lids is necessary for the removal of the tears from the conjunctival sac, epiphora accompanies lagophthalmos. This always occurs, except in the rare cases of atrophy of the lachrymal gland.

Etiology.—1. *Mechanical or Structural.*—Anything which occasions undue shortening or narrowing of the lids causes lagophthalmos. Shortening or narrowing of the lids is due to congenital defects, results of operative procedure, burns, ulcers, chronic blepharitis. Protrusion of

the eye due to enlargement of the globe or increase in the volume of the contents of the orbit is another mechanical cause.

2. *Functional.*—Paralysis of the orbicularis palpebrarum or retraction of the upper lid from spasm of the levator palpebræ superioris or of Müller's muscle may cause it, inability to close the eyelids in individuals exhausted from disease, or loss of sensitiveness of the cornea which abolishes the necessary reflex.

Treatment.—In all cases of mechanical shortening of the lid, permanent relief must be secured by operative procedure. The operation of tarsorrhaphy is sometimes applicable, but those for blepharoplasty are most often required. In the forms of lagophthalmos due to paralysis of the orbicularis palpebrarum and to spasm of the levator, medicinal measures must be instituted to cause restoration of the function of the muscle. Some months and even a greater time must be allowed to determine the result of the medication. In cases that are not improved by medication, operation may be resorted to. Pending the permanent relief by means of operation, the lids may be closed by means of adhesive strips, and a light bandage at night, or a bland ointment—sterile vaseline or borated vaseline—may be introduced into the eye sufficiently often to protect it from desiccation.

It is the habit of some individuals to sleep with the lids slightly separated, without, however, suffering any ill effects other than a mild hyperemia of the ocular conjunctiva. Fuchs states that he has observed that the habit of sleeping with the eyes half open is hereditary in many families. In order to determine the amount of integument and the length of lid necessary to insure easy closure of the lids, Fuchs has made a number of measurements, proceeding as follows: The distance between the margin of the upper lid at its centre and the lower margin of the brow, when the lids are gently closed, is determined, and is called the "altitude" of the lid. The lid is then stretched by traction on the lashes and measured in the same line. This is termed the "length" of the lid. It is found that the "length" must exceed the "altitude" by one-half in order to afford easy and perfect closure of the lids.

Diseases of the Orbicularis Palpebrarum Muscle.—**Blepharospasm.**—This condition is characterized by a spasmodic contraction of the orbicularis palpebrarum muscle. It is not a disease *sui generis,* but is a manifestation accompanying disease or due to neurosis. In regard to duration, the spasm is *clonic* (momentary spasm) or *tonic* (continuous spasm). Excessive nictitation, a form of clonic blepharospasm, is sometimes due to eye strain consequent on errors of refraction, and is then bilateral. In diseases of the cornea and of the conjunctiva, particularly in eczema of these tissues, accompanying fissure of the outer canthus (Koller) and in cases of foreign body in the eye, blepharospasm of one or the other variety may be present. In the last-mentioned cases it may be unilateral. These fairly represent the forms of blepharospasm accompanying disease of the eye. They are reflex movements due to irritation of the terminal fibers of the trigeminus.

Spasm of the orbicularis, of hysterical origin, is met with in individuals

at the age of puberty, and may affect one eye or both. It is usually a tonic spasm. Although most common in females, hysterical blepharospasm is also met with in males. Such a case came under the notice of the writer. A young man was led into the office and made the statement that he was "blind." It was impossible for him to open his eyes. Examination of the eyelids and eyes failed to reveal any disease condition whatever. A drop of cocaine solution was instilled, and after a few minutes the young man was told that the condition was relieved and that he could open his eyes, which he did. In the course of an hour he left the office completely relieved. The inability to open the eyes had existed for three days. In hysterical patients examination sometimes enables the surgeon to find so-called "pressure points," namely, points or areas, pressure on which will enable the patient to open his eyes at once. The patient will sometimes indicate these points himself. They usually lie in the area supplied by the trigeminus. While the places of exit of the two upper branches of the trigeminus are often "pressure points," they may lie in the nasal cavity, in the mouth or throat, or in remote parts of the body.

A variety of blepharospasm is met with in old people (*senile blepharospasm*) which has some of the features of tic, since it is frequently associated with contraction of some of the upper facial muscles. It may affect one or both eyes, often affecting one side more than the other. The spasm comes on without premonition, and may prevent vision for some minutes. It gradually disappears, recurring at varying intervals. Periods of excitement may increase the frequency of the attacks. In senile blepharospasm pressure points sometimes exist. The blepharospasm of hysteria and senile blepharospasm are neuroses, and are not necessarily accompanied by disease of the eye or conjunctiva.

Treatment.—The treatment of symptomatic blepharospasm consists in curing the affection of the cornea or conjunctiva, or in correcting the error of refraction. It is sometimes advisable to employ electricity or to treat the conjunctiva with mild collyria in order to relieve an hysterical attack. Senile blepharospasm may never disappear. It is at times aggravated by eye strain and by hyperemic conditions of the conjunctiva.

A form of blepharospasm due to clonic contraction of a fasciculus of the orbicularis (*fibrillary blepharospasm*), usually on one side, is often met with. It is occasioned most frequently by eye strain consequent on excessive use of the eyes or due to errors of refraction. Rest and the use of suitable glasses usually suffice to correct the condition.

Paralysis of the Orbicularis Palpebrarum.—This occurs as a result of an affection of the facial nerve, either in its trunk, its nucleus or in the brain beyond the nucleus. It is almost always associated with paralysis of the other muscles supplied by the facial nerve.

Etiology.—The causes of paralysis of the facial nerve need only be briefly mentioned. They are tumors of various kinds along the course of the nerve, producing paralysis by involvement or by pressure, exposure to cold, traumatism, affections of the nerve in the canal accompanying middle

ear disease, interference during operations on the face, neck, or on the temporal bone, and syphilis. Paralysis due to cortical disease most often affects the lower facial muscles, fortunately not greatly interfering with the function of the orbicularis.

In recent paralysis of the orbicularis palpebrarum, especially in young individuals, the deformity is not very apparent at first; it tends to increase. In the aged the lack of tone in the tissues permits a dropping away of the lower lid much more readily than in young persons.

Treatment.—See Treatment of Lagophthalmos.

Paralysis of the Levator Palpebræ Superioris.—Paralysis of this muscle leads to a drooping of the eyelid. The condition is known as ptosis, and is treated of under that heading.

Affections of Müller's Muscle.—Both paralysis and spasm of Müller's muscle are observed. Slight ptosis results from the relaxation of this muscle accompanying paralysis of the cervical sympathetic. This is observed in atrophy affecting the cervical sympathetic, and after the operation of section or resection of the superior ganglion of the cervical sympathetic as performed for the cure of glaucoma. Miosis, increased lachrymation, and slight capillary dilatation usually accompany the paralysis of Müller's muscle. In spasm of this muscle the palpebral fissure is widened, and, on rotating the eyeball downward, the lid does not readily follow the cornea (Graefe's symptom). This condition obtains in Basedow's disease, and is thought to be due to irritation of the cervical sympathetic. Usually bilateral, it may be unilateral.

Treatment.—This does little good in traumatic or idiopathic paralysis of the cervical sympathetic. The ptosis in these cases is not sufficient to inconvenience the patient. In spasm of Müller's muscle the treatment consists in the endeavor to correct the disease which induces the spasm.

Vicarious Menstruation.—Vicarious menstruation through the skin of the lids is exceedingly rare. The observation of this phenomenon has been recorded from time to time. It occurs in young females. In a case reported by Dr. J. Herbert Claiborne, blood escaped from the median side of each lower lid at the time of each menstruation. The quantity of blood lost was very small. It occurred throughout parts of two days. In the interval the lids did not present any departure from the normal.

CHAPTER VI.

THE LACHRYMAL APPARATUS.

ANOMALIES OF THE LACHRYMAL APPARATUS.

Congenital Anomalies.—Absence of the lachrymal gland occurs extremely rarely. It is sometimes noted (De Wecker) as an accompaniment of malformation of the orbit and of anophthalmos. Morton[1] reports the case of a girl, aged six years, who shed tears on one side only; but, as Lang and Collins state, absence of tears does not necessarily imply absence of the gland. Congenital displacement, congenital enlargement, and congenital cystic degeneration of the gland have been observed.

Lachrymal Canals, Puncta, and Canaliculi.—Congenital closure of one or both of the puncta is not uncommon. A supernumerary punctum may be present near the apex or base of the lachrymal papilla above or below, and may open into a single canaliculus, which may pass to the lachrymal sac or may terminate in a blind extremity. One or both of the canaliculi may have failed to close in the process of development, presenting the appearance of a groove at the margin of the lachrymal lake; the closure may have been partial, one or more openings of varying length occurring along the course of the canaliculus. Entire absence of the lumen of the canaliculi may occur.

Lachrymal Sac.—There does not appear to be any record of absence of the lachrymal sac. Failure of complete closure of the wall of the sac has been observed not very infrequently. The opening is often very small, sometimes of the lumen of a capillary. It may be located anywhere between the middle and lower part of the sac. The writer has observed two such cases. In one the opening, which was extremely small, was situated just anterior to the caruncle; in the second the opening was on the lower extremity of the sac. The first was bilateral and symmetrical.

Lachrymal Canal.—The congenital anomalies of the canal consist of atresia of the lower third of the canal, or, as is by far a more common condition, non-patency of the lower extremity of the canal, a condition resembling an imperforate hymen. When this exists the tears secreted flow onto the cheek. Soon mucopus forms in the sac and conjunctiva, and the appearance of a mild mucopurulent conjunctivitis is present. In many of these cases the canal opens spontaneously in from one to six months; in others a sound must be passed.

[1] Trans. Ophth. Soc. United Kingdom, vol. iv, p. 350.

Congenital Dacryocystitis.—This has been reported by a number of observers. It is due in some cases to an imperforate lachrymal canal, causing retention of secretion in the sac, to which a pathogenic or pyogenic germ has been added. In all probability it may also occur when congenital occlusion of the sac is not present.

Mercanti[1] reports a case in which the Bacterium coli communis was recovered from the pus. He thinks that infection took place from the feces of the mother at the time of birth. Hirsch[2] found the pneumococcus in the secretion. He attributed infection to the entrance of the vaginal discharge of the mother.

Treatment.—Frequent expression of the contents of the sac, cleanliness, and the use of antiseptic solutions and ointments suffice to effect a cure in the majority of cases. The establishment of a free passage into the nose is necessary in some cases. This is accomplished by giving the infant an anesthetic and passing a small probe.

DISEASES OF THE LACHRYMAL APPARATUS.

Diseases of Secreting Portion.—Dacryo-adenitis.—Dacryo-adenitis, or inflammation of the lachrymal gland, occurs as an acute and as a subacute process.

Acute Dacryo-adenitis.—The disease is quite rare, occurring approximately once in ten thousand cases of disease of the eyes. It is more frequent in children after the age of ten years and in young adults. Both glands may be affected, but it is usually unilateral.

Etiology.—It has been attributed to traumatism, "cold," septic absorption (toxemia), extension of disease from the conjunctiva. Infection from some source is the undoubted cause. The protected position of the gland and the flow of the lachrymal fluid render exogenous infection difficult and uncommon. This seldom occurs except by traumatism. Endogenous or metastatic infection is probably the rule. The Staphylococcus aureus, streptococcus, pneumococcus, and the influenza bacillus have been recovered from the suppurating gland, the last two in connection with pneumococcus and influenza, respectively. Gutmann[3] reports two cases of acute dacryo-adenitis following chronic gonorrhea.

Symptoms.—The disease advances rapidly, reaching its height in from forty-eight to seventy-two hours. It is accompanied by some rise of temperature. Cephalalgia is most intense in the vicinity of the eye affected. Delirium as an accompaniment of the acute stage has been observed. The outer half of the upper lid and to a less degree the lower lid become much swollen, and may become tense and brawny, of a dusky red color, indicating venous stasis. The outer half of the palpebral and ocular conjunctiva become edematous. The eyeball may be crowded downward and inward. The swollen lid is very

[1] Ann. di Ottal., xxi, 2-3, 133.
[2] Arch. f. Augenheilk., xlv, 4, p. 291.
[3] Verhandl. d. X Int. Med. Congress, 1890, vi, No. 10, p. 129.

sensitive, particularly over the site of the gland and neighboring margin of the orbit. In many cases palpation will enable the surgeon to determine the limits of the swollen gland, but in nearly all cases the accessory portion is much involved,[1] and because of this and of the swollen condition of the lid, a definite mass representing the swollen gland cannot be made out. The lid cannot be everted at this stage except in very mild cases, but it can be raised a very little from the eyeball. When this is done and the patient looks downward and inward, a bulging mass may be brought into view, occupying the upper outer portion of the fornix, which is due to the swollen gland. Suppuration with a discharge of pus into the conjunctival sac occurs in many of the cases. The pus may escape through an opening in the skin of the lid, a periglandular abscess forming at the same time. In quite a large proportion of the cases suppuration does not occur. A scant mucopurulent secretion may originate from the conjunctiva; the pre-auricular and often the submaxillary glands are swollen, but do not suppurate. The process subsides rapidly, recovery taking place in from one to two weeks.

Diagnosis.—Acute dacryo-adenitis may be mistaken for orbital periostitis, orbital cellulitis, tenonitis, and acute purulent or mucopurulent conjunctivitis. If the peculiarity of the swelling is borne in mind, its limitations will serve to exclude all but periostitis. Palpation and the peculiar bulging of the fornix conjunctivæ on rotating the eye downward and inward, accompanied by the sudden onset without history of injury, will serve to make a differential diagnosis. After having seen a first case, subsequent cases are easily diagnosticated.

Treatment.—Applications of a hot solution of boric acid by means of absorbent cotton or gauze for an hour at a time, repeated four or five times daily, and the internal administration of small, frequently repeated doses of calomel (gr. 0.05 every hour), to be discontinued, or given at greater intervals if the bowels are disturbed or tenderness of the gums develops, produce excellent results.

If suppuration is extensive and an abscess is liable to open through the integument, an excision should be made and the cavity treated as abscess occurring in other parts of the body.

Subacute Dacryo-adenitis.—This develops more slowly than the acute form. It is rarely seen except as an accompaniment of mumps. Mumps of the lachrymal gland occurs in a very small percentage of the cases of parotitis. In some epidemics of parotitis the affection of the lachrymal gland is much more frequent than in others. Ordinarily the swelling of the gland is not great and suppuration does not occur. The condition seldom lasts more than four to seven days, and subsides without leaving a trace.

Metastatic Dacryo-adenitis.—Cases of this nature accompanying urethral gonorrhea have been observed and reported.[2] In Terson's case inunctions were employed. Recovery in one month.

[1] In a few cases the disease is confined to the lower or accessory portion of the lachrymal gland.

[2] Terson, Bull. de la Société l'Ophtal. de Paris, March 5, 1900.

Fistula of Lachrymal Gland.—This occurs in the form of a minute opening in the skin of the lid from which there is a continuous flow of tears. In the greater number of cases there is no inflammatory condition present.

Etiology.—Traumatism is the most common cause. Suppurative dacryo-adenitis discharging through the skin is the cause in a very few cases. In Bowman's case[1] the fistula appeared to be due to a dacryolith. It may follow operations on the lid.

Treatment.—Closure of the fistula without providing a canal for the discharge of the tears in another direction is followed by inflammatory reaction and a reopening of the fistula.

Bowman's Operation.—This operation for fistula of the lachrymal gland[2] is as follows: A double-armed silk ligature is employed. The point of one of the needles is passed into the fistula a short distance and is then made to pierce the tissues and emerge on the conjunctival surface well up in the cul-de-sac. The second needle is passed in a similar manner, emerging on the conjunctival surface a few millimeters from the first. The suture is then tied, the ends being secured to the temple, passing out of the conjunctival sac at the outer commissure. At the end of a week the fistula is closed by freshening the edges and suturing. Healing follows promptly. At the end of two weeks the small bridge of tissue between the two stitch canals is cut out and the opening thus formed remains patent.

Dacryops.—This is really a retention cyst due to closure of one of the common ducts of the lachrymal gland from whatever cause, injury, suppuration, cauterization, the presence of a dacryolith, etc. It appears as a gradually increasing tumor of the upper lid, usually unaccompanied by inflammatory symptoms. The skin is freely movable over it. It may be very small, or it may be as large as a small egg. It may project into the orbit and cause some displacement of the globe. If the lid be slightly raised and pressure be made on the tumor, it will appear in the palpebral aperture as a translucent bluish mass. The walls of the cyst are usually very thin.

Treatment.—If the cyst is opened through the skin, an external fistula is apt to occur. If opened on the conjunctival surface the opening may remain permanent and the tears be discharged into the proper space. Destruction of the cyst is sometimes necessary because of a tendency to become distended. This is best done by opening the cyst freely from the conjunctival surface and by destroying the epithelial surface of the sac by the application of pure carbolic acid, using a small cotton probang for the purpose. The complete removal of the lachrymal gland may be necessary in some cases.

Dacryoliths.—Chalky concretions sometimes form in the excretory ducts and in the lachrymal gland. They may produce irritation and should be removed. Removal through a conjunctival wound should be effected when possible, to avoid the danger of creating an external lachrymal fistula.

[1] Roval London Ophth. Hospt. Reports, January, 1859, p. 288. [2] Ibid.

Hypertrophy of Lachrymal Gland.—Simple hypertrophy is of exceedingly rare occurrence. It is sometimes seen as a congenital condition, sometimes develops slowly in young individuals. Hypertrophy is probably always symmetrical. It occasions a fulness or ptosis of the outer third of the upper lids. On palpation a firm, slightly movable mass is felt projecting beyond the margin of the orbit.

Treatment.—It must be borne in mind that hypertrophy of the lachrymal gland is sometimes due to syphilis;[1] in all of these cases antisyphilitic treatment should be tried before operative procedure is resorted to. If after thorough use of remedies the tumors do not disappear, the glands may be extirpated.

Atrophy of Lachrymal Gland.—In elderly individuals, particularly in those who suffer from chronic conjunctivitis followed by cicatricial xerosis, trachoma, pemphigus, etc., the gland may become much reduced in size and cease to functionate. In paralysis of the trigeminus the secretion of tears may cease and the gland may become smaller than normal.

Dislocation of Lachrymal Gland.—This takes place spontaneously and also as a result of traumatism. When dislocation occurs the upper lid droops and in some cases a fold of skin that conceals the gland projects over the outer commissure. The gland is usually freely movable, and can be readily put back into the lachrymal fossa. In a case reported by Galovine,[2] displacement occurred spontaneously in a patient aged eighteen years, reaching its maximum in about three years. In this case the outer commissure of both eyes was concealed by the overhanging fold of skin. A case of traumatic dislocation occurring in a child, aged thirteen years, was reported by Ahlströhm.[3] The injury was caused by a fall on the ice.

Treatment.—Removal of the dislocated gland, together with a portion of the fold of skin, gives good results. In case of spontaneous dislocation an attempt may be made to restore the gland to its natural position where it may be fixed by means of sutures. Galovine reports a successful issue in the single case in which he tried this procedure.

Tumors of Lachrymal Gland.—Tuberculosis of the lachrymal gland may appear as (*a*) *primary* growth, tubercular deposits not being recognized in any other tissues of the body; (*b*) as *secondary* growth, tuberculosis of the lungs or of some other part of the system preceding the growth in the lachrymal gland; or (*c*) as a result of infection after trauma.[4] Tuberculosis of the gland may affect individuals at all ages. The enlargement of the gland progresses slowly, is accompanied by very slight inflammatory reaction; the pre-auricular, submaxillary, and cervical glands on the affected side are usually somewhat enlarged.

Other neoplasms are *adenoma, adenocarcinoma,* and *adenosarcoma, fibroma, sarcoma,* either round- or spindle-celled, *myxosarcoma, myxofibrosarcoma, angioma, osteochondroma, lymphoma,* termed by Baquis *trachoma of the lachrymal gland,* since he observed it in a patient having

[1] Debierre, Rev. gén. d'opht., 1893, No. 10, p. 433.
[2] Arch. d'opht., xvi, 2, p. 104.
[3] Centralbl. f. prakt. Augenheilk., xxii, p. 300.
[4] Fikinadte, Wjest. Ophth., 1897, No. 2.

trachoma, *cylindroma*, *angiocavernoma*, *polymorphous epithelioma*, referred to by Dianoux,[1] *cystic* tumors with or without *entozoa*.

Symptoms.—All of the tumors mentioned develop slowly. The skin at the outer margin of the orbit is pushed forward, the outer portion of the palpebral fissures narrowed. The eyeball is pushed forward, downward, and inward. Palpation reveals a mass varying in size, which protrudes at the upper outer margin of the orbit. This may or may not be movable. Neuralgic pains, more or less severe, are experienced, referable to the temple on the affected side.

Treatment.—Tumors of the lachrymal gland not of syphilitic origin, whether benign or malignant, necessitate extirpation of the gland. Of the malignant tumors affecting the gland, sarcoma, carcinoma, cylindroma or mixed tumor, none present a very virulent type. Recurrences are not frequent after careful and complete removal. The malignant tumors are usually unilateral. Galovine reports a case of bilateral round-celled sarcoma of the lachrymal gland occurring in a man, aged seventy-seven years.

Syphilis of Lachrymal Gland.—This is of relatively rare occurrence. However, gummatous infiltration of the gland has been observed. Anagarsa has reported a case of initial lesion of the lachrymal gland in which the enlargement of the gland was regarded as tuberculous and the gland extirpated. The subsequent history of the case determined the syphilitic character of the growth.

Diseases of Conducting Portion.—Affections of Lachrymal Puncta.—Obstruction of the lachrymal puncta from any cause, burns, occluding inflammatory processes, the presence of foreign bodies, such as a cilium in a punctum, produces epiphora. If the lower punctum is displaced, particularly if slight eversion occurs and the punctum is removed from contact with the ocular conjunctiva, the tears cease to enter the punctum as they should, they suffuse the eye, and, if sufficiently copious, flow onto the cheek. The condition occurs as a result of cicatricial processes in the conjunctiva, in the skin of the lid, or from palsy of the orbicularis palpebrarum muscle; it is also met with in elderly individuals in whom there is a considerable loss of tone in the tissues of the lid, particularly of the orbicularis palpebrarum muscle. Malposition of the lower punctum is met with very much more frequently than malposition of the upper punctum, largely because of the effect of gravity. Malposition of the upper punctum—in fact, obliteration of the upper punctum—seldom results in distressing symptoms of any kind.

Treatment of Occlusion of Puncta.—Treatment of occlusion and of low degrees of eversion consists in the slitting up of the canaliculus. If the canaliculus is slit it shows relatively little tendency to close in the majority of cases; the passing of a probe lubricated with bichloride vaseline every day for two or three days suffices to obtain a permanent opening of the punctum and the adjoining portion of the canaliculus. If there is a great tendency to closure, the inner lip of the canaliculus may

[1] Ann. d'ocul., cxii, p. 81.

be snipped off. In cases of elongation of the margin of the lid and in senile ectropion of the punctum it may be necessary to shorten the margin of the lid, in order to restore the position of the punctum. In cases in which the punctum is but slightly removed from the conjunctiva a simple astringent applied to the conjunctiva of the lower lid will be sufficient. A solution of nitrate of silver, 1 to 2 per cent., applied to the palpebral conjunctiva by means of a small cotton probang, once every forty-eight hours, or the sulphate of zinc, 2 grains to the ounce, dropped into the eye once or twice daily, may suffice. In some cases it becomes necessary to slightly contract the conjunctival surface by cauterizing a narrow strip of conjunctiva 2 or 3 millimeters below the margin of the lower lid and parallel to it, by means of the actual cautery or the nitrate of silver crystal, the strip extending from the inner canthus toward the outer commissure as far as is thought necessary.

Atresia or Stenosis of Canaliculi.—Atresia or stenosis of the canaliculi may be congenital, or may be the result of ulcerative processes, the introduction of caustics, or traumatism. Stenosis of the upper canaliculus, while it lessens somewhat the flow of tears into the lachrymal sac, is of comparatively little consequence; but stenosis of the lower canaliculus results in epiphora.

Obstruction of the canaliculi may occur from various causes—the entrance of foreign bodies, such as a cinder or a cilium, the formation of a dacryolith,[1] the development of fungoid masses due to the presence of penicillium, Leptothrix buccalis, "Streptothrix Foesteri," or actinomyces.[2] The lower canaliculus is much more frequently the seat of obstructions than the upper; both may be involved. The presence of these obstructions is indicated not only by epiphora, but ordinarily by inflammation of a mild character. The tissues immediately over the canaliculus are somewhat swollen, sometimes by dilatation of the caliber of the canaliculus, and sometimes by a thickening of the tissues from inflammation. The punctum is usually enlarged and somewhat pouting, and on gentle pressure over the canaliculus a drop or two of mucopus escapes. When fungus is present it sometimes occurs that portions of the fungoid mass also escape. This is particularly true of actinomycoses. Hard foreign substances, such as dacryoliths or solid foreign bodies, impart a sensation of hardness on palpation. Pressure on the canaliculus also elicits more or less pain.

Treatment.—In cases of atresia of the canaliculus it may be necessary to make an opening into the sac direct, entering beneath the lower margin of the internal canthal ligament just anterior to the canaliculus.

[1] Dacryoliths are in the greater number of cases composed of calcium phosphate. Fisher (Central. f. prakt. Augenheilk., xxi, 207) has reported the removal of a dacryolith which was composed of magnesium salts.

[2] Fungoid masses in a canaliculus may remain for years, causing slight disturbance and a small amount of mucopurulent secretion. They cause a deposit of lime salts (calcium phosphate), which may eventually become a dacryolith of considerable size. The nucleus of a dacryolith may be a cilium or a minute foreign body of any kind. For an exhaustive discussion of the fungi found in canaliculi concretions, see Axenfeld, Die Bacteriologie in der Augenheilkunde, Jena, 1907, p. 257.

If the atresia is not complete the canaliculus may be slit up. Foreign bodies or fungoid masses require the slitting up of the canaliculus and the removal of the contents. When an opening is made directly into the lachrymal sac, the probe must be passed frequently until the margins of the canal have cicatrized, in order to insure a permanent opening. After removal of foreign bodies and fungoid masses, the canaliculus presents a patent caliber even if the slit in its wall should close, and there is no necessity for passing a probe or in any way endeavoring to maintain the opening made in the wall of the canal. Recovery is rapid and permanent.

Stenosis of the Lachrymal Duct.—This may be partial or complete.

Etiology.—Stenosis of the lachrymal duct is due in the vast majority of cases to thickening of the mucous membrane of the canal consequent on the extension of disease from the nasal cavity. Chronic rhinitis, whether hypertrophic or atrophic, may produce partial or complete stenosis of the lachrymal canal. Acute rhinitis produces epiphora in almost every case, and, if due to the presence of pyogenic germs, may determine the onset of an acute dacryocystitis in cases of preëxisting epiphora, mucocele, and dacryocystoblennorrhea. Atrophic rhinitis or periostitis (which occurs most frequently in children with inherited syphilis or who are poorly nourished; also in syphilitic adults), with caries of the bony canal, also produces stenosis of the lachrymal duct. Stenosis may be due to traumatism.

Symptoms.—Epiphora is the most common symptom. The eye swims in tears, particularly when the secretion is increased by emotion, exposure to cold, wind, rain, snow, dust, or from whatever cause. The tears flow on the cheek and are very annoying to the individual. The lachrymal sac is sometimes slightly distended, and pressure on it causes an escape of lachrymal fluid into the conjunctival sac and, in cases of partial stenosis, into the lachrymal duct. The superabundance of tears in the conjunctival sac causes more or less hyperemia of the conjunctiva, and the constant moisture of the integument of the lids causes maceration and excoriation. Stenosis of the lachrymal duct may lead to (1) mucocele, (2) subacute or chronic dacryocystitis, (3) acute dacryocystitis and phlegmon of the sac.

Fig. 126

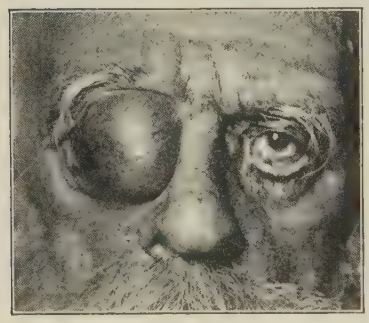

Mucocele.

Mucocele.—A continuation of a partial stenosis sometimes causes a simple epiphora, in which the lachrymal sac is slightly distended, to pass into the condition known as mucocele, in which the sac is distended, and the changed and thickened mucous membrane secretes abnormal quantities of mucus, forming a rather thick viscid fluid. The tumor produced at the inner canthus may be very small, not larger than an ordi-

nary pea. It may attain to an enormous size and entirely hide the eyeball (Fig. 126). In the early development of mucocele the tumor may be emptied on firm pressure, the fluid escaping through the nasal duct and, in small quantity, through the canaliculi. This condition may last for years without the slightest evidence of inflammatory reaction, the distention of the sac gradually increasing; or it may suddenly pass into acute dacryocystitis.

Symptoms.—The discomfort to the patient is relatively slight. When the sac is distended there is a sensation of tension and the tumor becomes quite prominent. If the patient then empties the sac by gentle but firm pressure all symptoms disappear.

Treatment.—On account of the great distention of the lachrymal sac and the production of abundant mucoid secretion, a free opening of the canaliculus and the establishment of the lumen of the lachrymal duct by probing seldom cause a cure. The redundant mucous membrane falls into and obstructs the lachrymal canal and perpetuates the trouble. The wearing of a style, or, better still, the excision of the sac are the measures that promise most.

Dacryocystitis.—Chronic Suppurative Dacryocystitis (*Dacryocystic Blennorrhea*).—The condition producing epiphora favors the development of an inflammation of the mucous membrane of the sac and of the canaliculi, as well as of the lachrymal duct, and the production of a purulent secretion. This is also true regarding mucocele, but to a less degree. The development of a purulent secretion may be preceded by slight subacute inflammation accompanied by a little fulness at the inner canthus and slight redness of the tissues. If the pus finds rather free exit through the canaliculi or lachrymal duct, the inflammation does not become acute. The secretion of pus may continue for many months or years without producing very much discomfort.

Symptoms.—Pressure over the lachrymal sac causes a flow of pus (which is sometimes quite thin from an admixture of tears, sometimes quite thick) from one or both puncta; but little flows through the lachrymal duct, as in the purulent condition affecting the sac the stenosis of the lachrymal duct is almost, if not quite, complete. The patient early learns to empty the lachrymal sac as soon as it becomes distended with secretion, and to wipe the pus from the conjunctival sac into which it flows. The presence of pus on the conjunctiva produces irritation and subacute inflammation of the palpebral and ocular conjunctiva at the inner part of the eye—lachrymal conjunctivitis. Because of its bacterial contents, this purulent secretion in the conjunctival sac, which is constantly replenished from the lachrymal sac, forms a medium for the infection of wounds of the cornea or of the conjunctiva. Penetrating wounds of the globe (as in the operation for cataract), by becoming infected, may lead to loss of the eye.

Acute Dacryocystitis (*Phlegmon of the Sac*).—Epiphora, mucocele, and subacute or chronic dacryocystitis may at any time pass into acute dacryocystitis. Acute dacryocystitis seldom occurs as a primary disease, that is, without having been preceded by one or other of these

conditions. Obstruction to the exit of secretion from the sac must take place before the acute process can be established, or at least before the symptoms peculiar to acute dacryocystitis become prominent. As a result of the entrance of some irritating substance or of virulent pyogenic or pathogenic microörganisms, the mucous membrane of the canal, sac, and canaliculi becomes thickened and swollen, closing the lumen of the canals completely, and the accumulation of pus in the sac proceeds.

Symptoms.—The tissues about the sac and in the immediate vicinity become injected, swollen, and red, and elevation of temperature, increase in pulse rate, headache, and more or less intense pain referable to the region of the lachrymal sac may be experienced. These symptoms may

Fig. 127

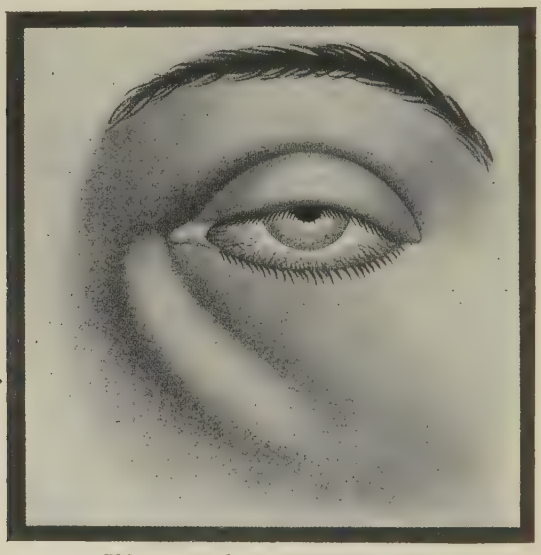

Phlegmonous dacryocystitis. (Veasey.)

last but a few hours and then subside, or the swelling may increase and become intense. The normal depression at the inner canthus may be entirely filled with the swollen tissue.

Diagnosis.—The intense swelling and redness opposite to and below the inner canthus (the swelling and injection gradually subsiding into the surrounding tissue), the exquisite sensitiveness, and the presence of an ill-defined tense or indurated area over the sac, particularly at its lower end, are ordinarily sufficient to enable the surgeon to make the diagnosis. The swelling is sometimes very extensive, making it difficult to differentiate it from erysipelas; but the margins are not so clearly defined and the tendency to spread is less than in erysipelas. Moreover, the temperature and constitutional disturbance are less.

Course.—Ordinarily within a day or two a yellow area appears in the skin at the inner canthus, just at the lower border of the inner canthal

ligament, and the abscess ruptures. Rarely, the "pointing" is above the inner canthal ligament; the sac has been known to open posteriorly, the pus finding its way into the nasal cavity, into the tissues of the orbit,[1] and even into the maxillary antrum; the pus may pass from the sac into the tissue of the cheek and open through the integument at a distance from the inner canthus. After the pressure is relieved by discharge of the pus, either by operation or spontaneously, the process subsides, the opening heals and, in some cases, eventually closes, with cessation of suppuration and reëstablishment of the patency of the normal passages. In some cases a permanent fistula remains; pus and tears dribble onto the cheek, forming a source of constant annoyance to the patient. The pus burrows beneath the integument in some cases, the canal thus formed usually following the furrow at the lower inner margin of the orbit. The canal becomes filled with granulation tissue and presents a number of small openings through the skin. If treatment is not instituted the most frequent result is subsidence to a chronic blennorrhea of the sac (dacryocystoblennorrhea), whether rupture of the sac does or does not occur.

Fig. 128

Fistula of lachrymal sac.

Treatment.—In the early stage of the process hot compresses may be applied to the swollen tissues over the sac. As soon as pus has formed it is advisable to permit it to escape either by slitting a canaliculus or by making an incision into the sac. (The operation of opening the canaliculus is described elsewhere.) A Beer's knife is an excellent instrument for making the incision. The knife is entered at a point just internal to the lower margin of the inner canthus, the cutting edge directed downward and outward at an angle of about 45 degrees to the vertical meridian, the point carried well to the bottom of the lachrymal sac, and the incision lengthened to 10 or 15 mm. The sac is then thoroughly cleansed with a solution of the bichloride of mercury (1 to 3000). If granulation tissue is present, it should be curetted away and the antiseptic again employed. The wound should be kept open by packing loosely with iodoform gauze until the swelling has subsided and the discharge of pus is greatly diminished. The oper-

[1] When pus from the lachrymal sac enters the orbital tissue, phlegmon or abscess of the orbit results, which may terminate in death from meningitis(Truc, Ann. d'ocul., February, 1900, p. 94), atrophy of the optic nerve (Businelli, Clin. moderna, iv, No. 30), or rarely in recovery with retained vision.

ation for the relief of the stenosis of the lachrymal duct may then be resorted to. Agnew advised opening the lachrymal sac by a vertical incision between the commissure of the lids and the caruncle, entering the sac behind the inner canthal ligament. "This point is rendered easier of access by the swelling of the surcharged sac. . . . You then may empty the sac without difficulty and avoid an external wound, nor does your procedure injure the canaliculi or damage any appendage of the eye or interfere with after treatment."

In cases of partial stenosis of the lachrymal duct, the nasal cavity should be examined and measures instituted to correct any abnormal condition that may be present. In hypertrophic rhinitis it is often sufficient to use a cleansing spray (of which Dobell's solution is a good example) twice daily and to interdict smoking if that is indulged in. An hypertrophied inferior turbinated body compressing the inferior portion of the canal should be reduced in size or partly removed. In addition to these measures it is often of value to treat the sac and partly closed

Fig. 129

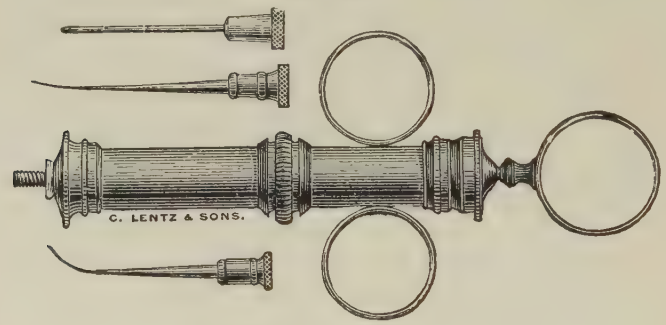

Anel's lachrymal syringe.

canal by the introduction of medicated solutions by means of an Anel (Fig. 129) or other canaliculus syringe. Before the nozzle of the lachrymal syringe will pass into the punctum it may be necessary to dilate the opening; this may be done by means of an instrument made for that purpose. The solutions employed may be of boric acid (saturated solution), bichloride of mercury (1 to 5000 to 1 to 10,000), argyrol (15 to 25 per cent.). The introduction of these solutions should be preceded by a solution of cocaine, 2 to 4 per cent., to which a very, little adrenalin chloride has been added. Solutions of the nitrate of silver are sometimes employed. Solutions of this salt should be very weak, not stronger than 0.5 per cent. If stronger solutions are employed, an adhesive inflammation may be set up which may result in obliterating the canaliculi. This treatment may be supplemented by passing small probes through the canaliculi and through the canal to the inferior nasal meatus. Small probes must be used with great care to avoid making false passages. The mild procedures described will suffice to correct many cases of partial stenosis and some cases of

chronic and acute dacryocystitis. In many of the severer cases operative procedure must be resorted to.

Probes.—Probes are employed for dilating the canal. Of these there are a number in use. Those of Bowman (Fig. 131, *A*) are made of silver wire or of copper wire silvered, of different sizes, the largest, No. 6, measuring about 1.3 mm., the smallest about 0.25 mm. in diameter

Fig. 130

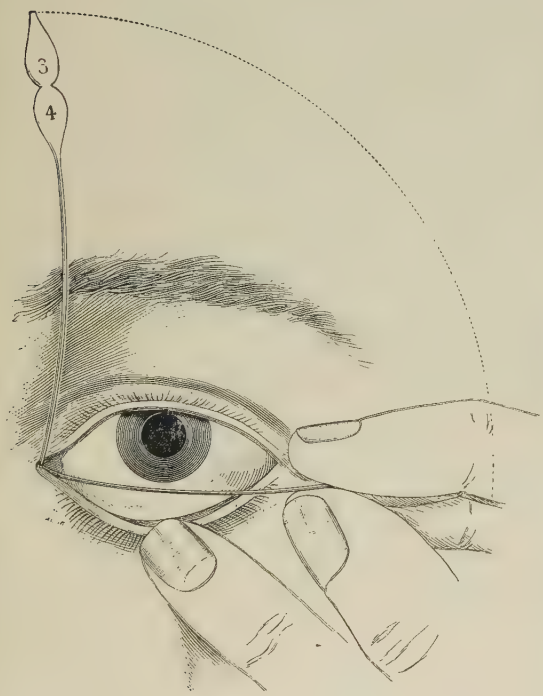

Method of inserting Bowman's probe. (Norris and Oliver.)

Fig. 131

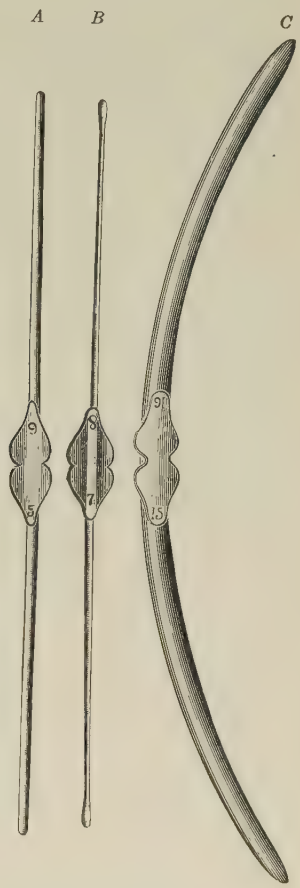

Lachrymal probes. *A*, Bowman's; *B*, Williams'; *C*, Theobald's.

Their ends are rather blunt. Theobald advocates the use of large probes, and increases the size as follows: No. 7, with a diameter of 1.75 mm.; successive numbers are added until No. 16 is reached, having a diameter of 4 mm. The points of Theobald's probes are conical (Fig. 131, *C*), a shape that greatly facilitates their use. After passing the conical tip the diameter of the probe is uniform. Bulbous probes have been devised by Dr. E. Williams, of Cincinnati (Fig. 131, *B*), the largest

bulb being 3.25 mm. in diameter. Noyes devised hard-rubber probes, the largest of which were 4 mm. in diameter. Weber's dilating probes, graduated and smooth, are also much used.

After slitting the canaliculus the lumen of the lachrymal duct may be reëstablished by dilating with probes, either with or without incision of the stricture or obstructing folds of tissue. The probe should be well lubricated and passed as illustrated in Fig. 130. As before stated, the average nasal duct measures about 5 mm. in diameter. The normal membranous lining of this duct diminishes the caliber by about 1.5 mm., making the average lachrymal duct 3.5 mm. in diameter. A probe should be chosen sufficiently large to exert some pressure on the membranous walls as well as to pass through the canal. When a large probe is used the danger of making a false passage is very slight. The probe should be inserted and permitted to remain in the canal fifteen to thirty minutes, unless a style or cannula is to be introduced. After probing the lachrymal duct, the duct and lachrymal sac should be cleansed by syringing with an antiseptic solution. Bichloride of mercury (1 to 5000), or a saturated solution of boric acid may be employed. Probing should be repeated sufficiently frequently to keep the canal patent until the tissues can resume an approximately normal condition. This means that the probing should be repeated every two or three days for the first week after the operation. After this the interval between the probings should be gradually lengthened and should cease when the canal shows no disposition to close. In some cases this plan of treatment will bring about recovery within a reasonable length of time.

Fig. 132

Varieties of styles.

Styles.—In cases with a great tendency to closure of the canal and where the patient cannot come regularly to have the probe passed, a cure may be accomplished by having the patient wear a style[1] until

[1] Probing the lachrymal canal from the nose is advocated by Polyak (Urgarische Med. Presse, January 30, 1902). This operation is very difficult and possesses little value. Electrolysis has been employed for the purpose of curing stenosis of the canal by Black (Jour. Amer. Med. Assoc., October, 8, 1898) and by Theobald (Norris and Oliver, p. 168). The wire of the negative pole of the battery is connected with a metallic lachrymal probe, a sponge electrode connected with the positive pole being applied to the cheek. With the electrodes in position, a current of 3 to 6 milliamperes is turned on. The results of this method of treatment are problematical.

recovery takes place. (Canulæ are of very little value.) The style may be made of lead, silver, or gold. Gold styles are the best, as they do not corrode and are less liable to be coated with deposits. The style should be about 2 mm. in diameter, smooth, shaped to the canal into which it is to be placed, and long enough to permit its smooth, rounded end to rest on the floor of the inferior nasal meatus. It should be supplied with a hook or a button at the upper end sufficiently large to prevent the style from slipping into the canal. The style may be introduced after gently dilating and cleansing the canal. It should be removed from time to time and cleansed, the frequency depending on the tendency to the accumulation of deposits or the necessity for treating the canal. Cases that would require years of probing may be brought to a successful issue by the use of appropriate styles with relatively little attention on the part of the surgeon.

Diphtheria of Lachrymal Sac.—This is met with most frequently as a complication of diphtheria affecting the nasal mucous membrane. It may be secondary to diphtheria of the conjunctiva. Caspar[1] reports a case in which the skin over the sac sloughed in diphtheria of the sac.

Treatment.—The subcutaneous injection of diphtheria antitoxin as for diphtheria of the conjunctiva.

Polypus of Lachrymal Sac.—Polypoid growths sometimes develop from the wall of the sac or from the upper part of the lachrymal canal, filling the sac and distending it. The flow of the tears is interfered with.

Treatment.—The sac should be opened, the polypoid mass or masses excised, and their bases cauterized. If the wall of the sac is much invloved the sac should be extirpated.

Actinomycosis of Lachrymal Sac.—This has been observed. Mitvalsky[2] reports a case occurring in a woman with fistula of the lachrymal sac. The sac was distended and hard. A green mass was evacuated which proved to be composed largely of actinomyces. The fungus was evidently secondary to a chronic dacryocystoblennorrhea.

Tuberculosis of Lachrymal Sac.—This may occur primarily in the sac,[3] secondary to tuberculosis in remote parts of the body,[4] and by extension from the nasal mucous membrane or from the conjunctiva. Ordinarily tuberculosis of the sac presents the appearance of chronic dacryocystitis, except that the walls of the sac are thickened. The discharge is thin and flaky. The mucous membrane of the canaliculi is involved in the superficial variety, the walls becoming thickened and the puncta lachrymalia distended, their margins being irregular and pouting. Nodular tubercles may develop, in which case the sac becomes distended and hard.

Diagnosis.—This is made by examining the secretion, or, where this fails, by examining some of the excised tissue for the tubercle bacillus.

Treatment.—Excision of the sac is the best treatment in cases where the process is apparently limited to the sac. If the process is an extension

[1] Centralbl. f. Augenheil., March, 1902.
[2] Arch. d'opht., xviii, 8, 508.
[3] Fick, Correspondzbl. f. Schweiz. Aerzte, 1891.
[4] Bock, Wiener med. Woch., 1891, No. 18.

from the nose, the lachrymal canal should be thoroughly scraped and cauterized and the affected nasal mucous membrane appropriately treated.

Follicular Inflammation of Mucous Membrane of Lachrymal Sac.—This has been described by Kalt[1] and termed by him follicular dacryocystitis. The conjunctiva of the lids and globe was normal. This condition is analogous to the round-cell infiltration of the mucous membrane of the sac which has been observed accompanying trachoma and which has been termed trachoma of the lachrymal sac.

Treatment.—If epiphora exists and the condition does not subside by treatment of the trachoma, the sac may be opened, the mucous membrane curetted, or the sac extirpated.

Sarcoma of Lachrymal Sac.—This has been observed rarely. Sylvestii[2] reports a case in which the tumor sprang from the wall of the sac. Extirpation was followed by recurrence in the orbit and parotid region.

Epithelioma of Lachrymal Sac.—This is usually secondary to epithelioma of the adjacent skin.

[1] Soc. franc. d'opht., 1894.

[2] Ann. di Ottal., xxvi, 5, 452.

CHAPTER VII.

THE CONJUNCTIVA.

ANOMALIES OF THE CONJUNCTIVA.

Dermoid Tumors.—These are rarely met with; they usually extend onto the cornea. They are elevated masses seldom affecting the palpebral conjunctiva, and, as a rule, are pale in color, but may be pigmented; they are supplied with a number of hairs, glands, etc., and may be cystic, and present the characteristics of the skin.

Fig. 133

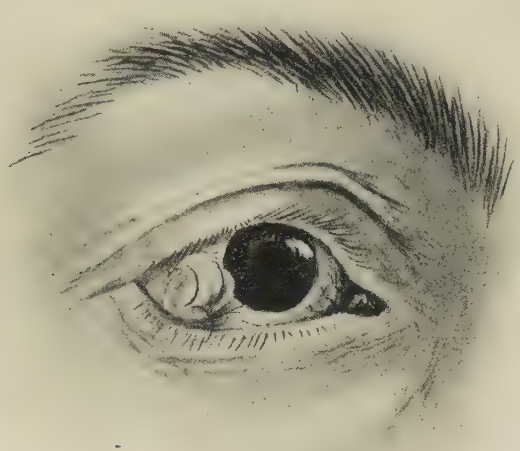

Dermoid tumor of the conjunctiva.

Lipomata (*Fatty Tumors*).—They are small in size, and are seen rarely. They are apparently situated beneath the conjunctiva; the epithelium is thickened over them.

Angioma, Angiocavernoma, and Telangiectatic Growths.—These are not very infrequent. They are seldom confined to the conjunctiva. For description and treatment, see Lids, page 177.

Bone.—*Bone* is occasionally found beneath the conjunctiva, and situated between the outer margin of the cornea and the commissure.

Moles or Pigmented Patches.—These occur most frequently in individuals who present similar spots on the skin.

Fibrous Growths.—Fibrous growths, often containing some lipomatous tissue, occur rarely in the upper outer portion of the ocular conjunctiva. They are crescentic in form, with the concave border toward the cornea; sometimes they are brought into view only when the eye is rotated downward and inward. The conjunctiva over them is somewhat thickened and is sometimes dermoid in character, containing fine hairs. They tend to increase in size at the age of puberty.

Treatment.—Removal by excision.

DISEASES OF THE CONJUNCTIVA.

Hyperemia of the Conjunctiva (*Dry Catarrh*).—The palpebral conjunctiva is the part usually affected. The mucous membrane is red, is very slightly roughened, and very slightly thickened.

Etiology.—Exposure to heat, bright light, glare from water, sand, etc., strong wind, cold, storms of rain or snow. A frequent cause is use of the eyes for fine work when an uncorrected error of refraction exists, causing eye strain; too constant use of the eyes by insufficient illumination; indigestion; alcoholism; gout; vasomotor disturbances; lachrymal disease; acute exanthematous fevers; blepharitis marginalis, etc.

Symptoms.—The lids feel stiff and dry and are moved with difficulty. A burning sensation is experienced, and there is increased lachrymation. The superficial epithelial cells are thrown off more rapidly than in health, and are found in small whitish masses at the canthi, and sometimes at the margins of the lid. Attempts to use the eyes by artificial light are accompanied by distress.

Pathology.—But little change in the tissues is found. There is slight infiltration of small cells, and the vessels are engorged.

Diagnosis.—The absence of secretion with the conditions described suffices to establish the diagnosis.

Treatment.—The cause should be sought for and removed. In addition, the eyes should be bathed with a 3 per cent. solution of boric acid or of biborate of soda, twice daily.

Conjunctivitis (*Ophthalmia*).—This term is applied to a number of well-defined diseases of the conjunctiva, all of which are accompanied by increased and altered secretion, by distressing symptoms, and by transient or permanent pathological changes in the membrane.

Classification.—Since the discovery of the gonococcus of Neisser, in 1879, the specific microörganism of a number of forms of conjunctivitis have been described, which makes it advisable to modify the older classification of diseases of this membrane. All of the forms of conjunctivitis may be included under two headings: (1) Those in which a specific cause has not been determined; (2) those forms in which a specific cause has been determined.

To the first belong simple conjunctivitis: (*a*) Lachrymal conjunctivitis,

(*b*) lithiasis conjunctivitis, (*c*) conjunctivitis petrificans, (*d*) herpetic conjunctivitis, (*e*) vernal conjunctivitis, (*f*) follicular conjunctivitis; (*g*) trachoma; (*h*) pemphigus; (*i*) Parinaud's conjunctivitis, (*j*) gouty conjunctivitis.

Some of these forms of conjunctivitis are probably due to specific microörganisms not as yet discovered.

To the second class belong (*a*) acute contagious conjunctivitis, (*b*) subacute conjunctivitis, (*c*) purulent conjunctivitis, (*d*) diphtheritic conjunctivitis, (*e*) xerosis epithelialis, (*f*) phlyctenular or eczematous conjunctivitis, (*g*) tuberculous conjunctivitis, (*h*) lupus, (*i*) leprosy.

Non-specific Forms of Conjunctivitis.—Simple Conjunctivitis (*Catarrhal Conjunctivitis*, or *Ophthalmia*).—It is characterized by injection and slight thickening of the conjunctiva, almost entirely confined to the palpebral portion, loss of transparency, slight roughening, and the presence of a very little mucus, which sticks the lids together in the morning.

Etiology.—The causes are numerous and permit of classification:

1. *Mechanical.*—Irritation of the conjunctiva, due to the entrance of particles of metal, dust, pollen, exposure to wind, glare of light.

2. *Associated.*—Accompanying the exanthematous fevers, rheumatism, nasal catarrh, bronchitis, eczema, facial erysipelas, impetigo contagiosa, molluscum contagiosum.

3. *Symptomatic.*—As those forms accompanying eye strain.

Symptoms.—Subjective.—Lids heavy, burning sensations in the eye, irritation on moving the eyes, some photophobia, annoyance in use of the eyes.

Objective.—Lachrymation more profuse, slight sticking together of the lids in the morning, slight thickening of the lids, hyperemia of the tarsal conjunctiva and of the retrotarsal folds.

Simple conjunctivitis, as is apparent by a glance at the list of causes, is most common in children, but no stage of life is exempt.

Prognosis.—The duration depends on the continuation of the cause. When this is removed (mechanical and symptomatic forms) or subsides (associated forms), recovery occurs spontaneously. No lasting injury results.

Treatment.—In addition to removing the cause, much relief may be obtained by bathing the eye with a solution of boric acid (3 per cent.) two to four times daily. A mild astringent collyrium may also be employed. Zinc (gr. ss to ʒj) is excellent.

Lachrymal Conjunctivitis.—*Etiology.*—A form of conjunctivitis which depends on the presence of irritating, purulent, or non-purulent secretion from the conducting portion of the lachrymal apparatus for its existence. Almost all of the cases could be suitably classed as simple conjunctivitis, but a few cases develop a purulent type, which may result in much damage to the eye.

Diagnosis.—The symptoms peculiar to obstruction of the lachrymal passages and frequently a dacryocystitis are present. The ocular and palpebral conjunctivæ at the inner half are most affected.

Treatment.—This consists in rendering the lachrymal canals patulous, and in correcting the disease of the lachrymal conducting apparatus supplemented by cleansing the conjunctiva with some bland aseptic solution, and the use of a mild astringent.

Lithiasis Conjunctivitis.—*Etiology.*—A form of irritation of the conjunctiva due to the presence of small calcareous deposits in the tissue of the palpebral conjunctiva. They occur most commonly in the tarsal conjunctiva, but are also met with in the palpebral portion of the retrotarsal folds. The small masses appear as yellowish-white bodies almost immediately beneath the epithelium, frequently multiple.

The deposits consist principally of carbonate of lime and cholesterin, or of the biurate of soda.

Symptoms.—They tend to penetrate the epithelial layer, and produce irritation of the eyeball and lids. When the concretion lies near the surface it is often surrounded by an area of congested conjunctiva. At the time of rupture through the epithelial layer, intense pain is occasioned by the impingement of the sharp, hard masses of lime on the sensitive epithelium of conjunctiva and cornea. Although occurring in individuals of middle age, it is commonly met with in those of advanced years, and is usually associated with rheumatism or gout.

Treatment.—Removal.

Conjunctivitis Petrificans.—This is a rare affection, first described by Leber (1895). It is characterized by the presence of numerous small, yellowish-white, slightly raised plaques in the palpebral conjunctiva. The plaques are covered by epithelium, but may become scaly. Both eyes are affected. In severe cases the plaques may appear on the ocular conjunctiva and margins of the lids. The eyes are slightly swollen; conjunctiva thickened and injected. The condition has been observed, almost without exception, in young and middle aged women. The plaques consist of deposits of lime with an organic base.

Etiology.—Unknown. The affection, which may begin relatively early in life (twelve years; case observed by Pusey, *Oph. Rec.*, xii, 2, 88), continues for years. (In two cases observed by the writer the condition has remained, with little change, for a number of years.) The scales that sometimes form contain lime deposits.

Symptoms.—The patient experiences but little annoyance except when the plaques become rough, when the ordinary symptoms of friction are produced.

Treatment.—The roughened plaques should be curetted away. Cleansing the eye when necessary with a 3 per cent. solution of the biborate of soda and the introduction of sterile or borated vaseline two or three times daily relieve symptoms.

Herpetic Conjunctivitis.—This condition is characterized by the formation of clusters of vesicles on a hyperemic base. The vesicles collapse, forming a superficial ulcer which heals rapidly, leaving a very slight superficial cicatrix. It accompanies herpes orbitalis (see page 164).

Vernal Conjunctivitis (*Saemisch Catarrh; Conjunctivitis Catarrhalis Æstiva; Phlyctena Pallida* (*Hirschberg*); *Spring Catarrh*).—A disease

characterized by roughening and thickening of the palpebral conjunctiva, accompanied by hypertrophy of the conjunctiva at the margin of the cornea, and a tendency to recur each year in spring or summer, when the weather becomes warm.

Etiology.—The disease is probably due to a specific microörganism, but what the microörganism is has not been determined. Pascheff[1] describes a bacillus resembling the pseudodiphtheria bacillus, which he found in a number of cases. His findings are yet to be verified. Heat is apparently the exciting cause. Dimmer thinks it probable that the visible rays of short undulation and the ultraviolet rays may cause the disease.

Fig. 134

Vernal conjunctivitis.

Pathology.—The changes in the conjunctiva consist in scanty, small-cell infiltration and the development of papillæ, particularly on the upper tarsal conjunctiva. The papillæ consist of a central loop of vessels and some connective-tissue stroma, covered with a thick layer of stratified epithelium. In old severe cases, fungoid excrescences form, consisting of fibrous papillæ covered by thickened stratified epithelium. The hypertrophied tissue at the margin of the cornea consists largely of epithelium on an elevated base, which appears to consist of a scant hyperplasia, of connective tissue, dilated lymph spaces, and hyaline granules.[2]

Symptoms and Description.—Children from the age of three to fifteen years are most frequently attacked, but it sometimes appears in adults.

[1] Graefe's Arch., February, 1908.

[2] For an exhaustive discussion of this subject, see Axenfeld, Trans. French Ophthal. Soc., 1907.

Those who live in the country are attacked more frequently than urban residents. Often two or more in a family are affected, a fact which points to a contagious quality. In almost all cases both eyes are involved. The patient suffers from irritation, as of a foreign body in the eye, photophobia, distress on use of eyes, burning and itching. There is excessive lachrymation, a scanty mucoid, "stringy" discharge, which is visible in the morning as a yellowish-white mass along the lashes and at the inner canthus. On everting the upper lid the tarsal conjunctiva is found to be slightly thickened, and the surface is roughened by the presence of numerous fine, papilliform elevations which resemble the pile of velvet much shortened. The surface of the palpebral conjunctiva, both above and below, presents a very faint, pearly hue or shimmer, as though a drop of skimmed milk had passed over it. This appearance is observed in the early as well as the later stages of the disease, and is due to thickened epithelium. The ocular conjunctiva, except at the margin of the cornea, is but slightly affected; at the limbus, particularly in the horizontal meridian, the epithelial layer in about 25 per cent. of the cases becomes much thickened. The elevations have a pearly, translucent appearance at the apices, which is quite characteristic. The hypertrophied tissue often encroaches onto the cornea 1 or 2 millimeters, a narrow grayish zone separating the hypertrophied tissue from clear cornea. When cold weather comes the affection subsides and almost disappears. However, the peculiar appearance of the tarsal conjunctiva is not entirely lost even in the winter months. In the later stages, in severe cases, flattened fungoid, often pedunculated, elevations appear on the palpebral conjunctiva of the upper and lower lids. These often resemble trachoma granules. Superficial corneal ulcers, as a result of friction from roughened lids, may develop.

Diagnosis.—Vernal catarrh is mistaken for trachoma and for phlyctenular conjunctivitis. It may be differentiated from both by the history and pathological findings.

Prognosis.—The disease recurs every summer for a time—two to twenty years—when it subsides, usually leaving but little deformity.

Treatment.—Protective glasses, a bland wash (boric acid solution) two or three times daily, and the introduction of an ointment of the yellow oxide of mercury (1 to 1.5 per cent.) once daily, at night, usually give the best results so far as remedies are concerned. Calomel, in impalpable powder, dusted onto the palpebral conjunctiva, in very thin layer, every second day, is advantageous. Climatic changes do most good; the sufferer should go to a cool climate during the hot months. Allport[1] reports very excellent results from the use of the *x*-rays. Radium has been employed with reported good results. Protecting glasses that shut out ultraviolet rays should be worn.

Follicular Conjunctivitis (*Conjunctivitis Folliculosis Simplex*).—This form is characterized by the appearance of small, oval elevations, arranged often in rows, which occupy the outer portion of the fornix of the

[1] Oph. Rec., October, 1903.

lower lid, occasionally being present at the outer and inner portions of the palpebral conjunctiva of the upper lids. These bodies are oval in shape, translucent, and pink in color.

Etiology.—There is no known specific cause. The disease occurs most frequently in children who live in unhygienic surroundings. Filth evidently favors its development. The disease is infectious, perhaps contagious. It is met with frequently in children who are massed together, as in asylums and residential schools.

Pathology.—Similar to that of trachoma in its first stage, except that the trachoma body of Prowazek is not present so far as is now known.

Symptoms.—There is often considerable irritation; the lids are slightly thickened. There is some mucoid secretion on the lids in the morning. Use of the eyes causes sensations of burning and smarting. The ocular conjunctiva and cornea are seldom involved. The palpebral conjunctiva is congested.

Prognosis.—Favorable.

Treatment.—The eyes should be bathed with a 3 per cent. solution of boric acid sufficiently often to keep them free from secretion. A solution of bichloride of mercury (1 to 10,000 to 1 to 4000) should be dropped into the conjunctival sac three times daily, and the bichloride of mercury in vaseline (1 to 5000) should be put into the eye by means of a glass rod twice daily in severe cases; once daily, at night, in mild cases. The treatment should be continued for a long period of time. Aristol, iodoform, bismuth and calomel, equal parts, or calomel alone, may be employed as inspersion powders. In persistent cases expression of the contents of the follicles may be resorted to. Errors of refraction should be corrected. To prevent the spread of the disease, the patient should sleep alone and use individual washing appliances. Isolation should be resorted to when it occurs in asylums.

Trachoma (*Granular Conjunctivitis*; *Egyptian Ophthalmia*; *Military Ophthalmia*).—This disease is characterized by the presence of numerous small, oval masses in the palpebral conjunctiva, by chronicity and by grave subsequent changes in the conjunctiva, lids, and often in the cornea and globe. It occurs most frequently in children, but may affect individuals at any age, except perhaps during the first year of life.

Description.—Trachoma may be conveniently divided into three stages: (1) The stage of hypertrophy, in which the granules are discrete. (2) The stage of coalescence or beginning cicatrization. (3) The stage of atrophy.

1. *Stage of Hypertrophy.*—In the first stage the area of the conjunctiva is as great or greater than in the normal. It presents three quite distinct phases:

(*a*) The granules develop without discomfort to the patient, there being very little mucous secretion, not enough to seal the lids in the morning; there is a slight excess of lachrymation, and the lids appear to be slightly thickened. There is no redness of the ocular conjunctiva, nor is the cornea affected. It often happens that the condition is discovered accidentally; the physician on everting the lids is surprised to

find the palpebral conjunctiva studded by numerous, well-formed, pale, translucent granules. Seen in this stage, this phase of onset is frequently termed folliculosis of the conjunctiva.

(*b*) This is the form of onset most frequently observed. The patient complains of pain in the eyelids, which feel hot and rough. There is evidence of pronounced irritation, lachrymation is increased, and in a few days after the discomfort is first experienced a scanty mucopurulent discharge is present; the lachrymation continues. The ocular conjunctiva becomes injected, and even in the relatively early part of this stage the cornea may give evidence of involvement. On everting the lids the conjunctiva is found to be deeply injected and thickened, and, if the inflamed condition has lasted two to four weeks, granules may be seen

Fig. 135

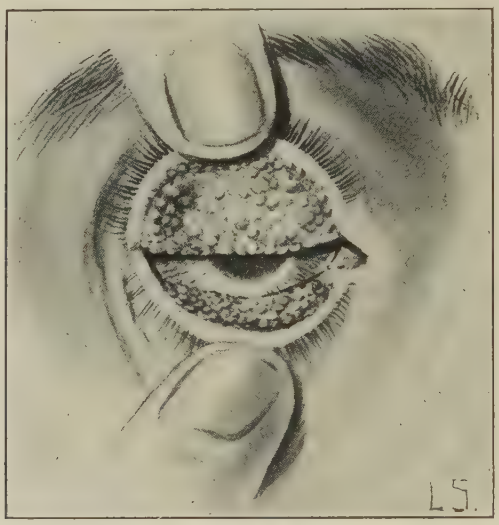

Trachoma.

on the tarsal conjunctiva, and possibly in the retrotarsal folds. Often the hypertrophy of the conjunctiva at the onset is sufficient to mask the presence of the granules, and they become visible only after the swelling has subsided. The pre-auricular glands are enlarged. When occurring in residential schools, asylums, reformatories, and in families, the disease spreads rapidly unless isolation is practised.

(*c*) This phase is fortunately rare; it is the most severe, usually affecting young and middle-aged adults. The onset is quite rapid. Burning and scratching of the lids are complained of. The lids become swollen moderately. There is lachrymation, and in a day or two mucopurulent and sanguinolent discharge. Hypertrophy of the conjunctiva is present after a few days; at the end of ten days or two weeks the conjunctiva is greatly thickened, the entire fornix presenting a plaque of

lymphoid tissue. The ocular conjunctiva becomes deeply injected, and it is not unusual to observe evidence of corneal irritation early in the course of the disease. The pre-auricular lymph glands are swollen, and in some cases the submaxillary glands are similarly affected.

2. *Stage of Coalescence, or Beginning Cicatrization.*—The first stage of trachoma may last six weeks to a year; it gradually passes over into the *second stage*, the stage of coalescence, or beginning cicatrization. This stage is common to the three phases of onset, appearing later in the first phase than in either of the others. The granules, which before were discrete in the first two phases of onset, coalesce, and cicatricial tissue appears in the form of narrow bands throughout portions of the palpebral conjunctiva. The area of the conjunctival surface diminishes and the culs-de-sac decrease in depth. With this change the tarsus becomes narrower and shorter and abnormally acutely curved. The rough surface of the lids rubs against the cornea and disturbs its epithelium. Vascular pannus forms. Superficial ulcerations of the cornea follow, and if pathogenic germs find entrance to the corneal tissue, deep ulcers with more or less destruction of the cornea ensue. The margins of the lids become inverted (entropion) and the lashes rub against the cornea. The palpebral fissure is narrowed and shortened.

Fig. 136

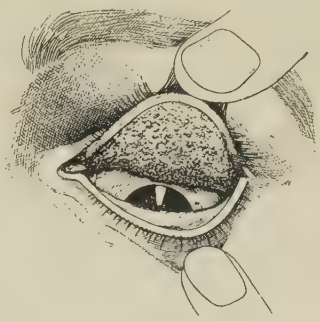

Trachoma. (Morax.)

Trachomatous tissue may appear on the ocular conjunctiva, the caruncle, or even on the cornea.

3. *Stage of Atrophy.*—Years may elapse before the second stage passes into the *third stage*, the stage of atrophy, or cicatrization. The conjunctiva is much reduced in area, and presents none of the appearances of the normal mucous membrane; the surfaces are dry except, perhaps, for the presence of a few islets of approximately normal tissue. The conjunctival surface, as well as the cornea, is dry (xerosis cicatricialis) and pale in color. Vision is reduced to perception of light.

Trachoma need not necessarily pass through all of these stages, but may be arrested, with the preservation of what normal tissue remains, at any part of the first or second stages. It ceases spontaneously in rare cases, but too frequently persists throughout the life of the patient, if treatment is not resorted to.

Etiology.—While trachoma is not confined to the poor, it is much more frequently met with among them; filth, overcrowding, vitiated atmosphere, and improper and insufficient food contributing to its production. It is possible that a contagium must be added to produce the disease. Many researches have been undertaken to discover the specific cause, and a microörganism has been isolated which bears a close relation to the disease. This microörganism, which is a small double coccus, has been described by Sattler and Michel. Muttermilch

has described a fungus which he terms microsporon trachomatorum. Pfeifer and Ridley have described parasitic protozoa. Although it is believed to be a microphytic disease, sufficient evidence is not yet at hand to establish the identity of any known germ as the specific cause.[1]

Trachoma Body of Halberstadler and Prowazek.—A microörganism in the nature of a protozoan has been studied and described by Halberstadler and Prowazek, Greeff, Hertzog, Lindner, A. Leber, and others. The parasite was termed *chlamydozoan* (cloak animal) by Halberstadler and Prowazek, *trachoma body* by Greeff. It is found in the superficial epithelial cells in trachoma in the first and second stages of the disease, and also in pannus.

Fig. 137

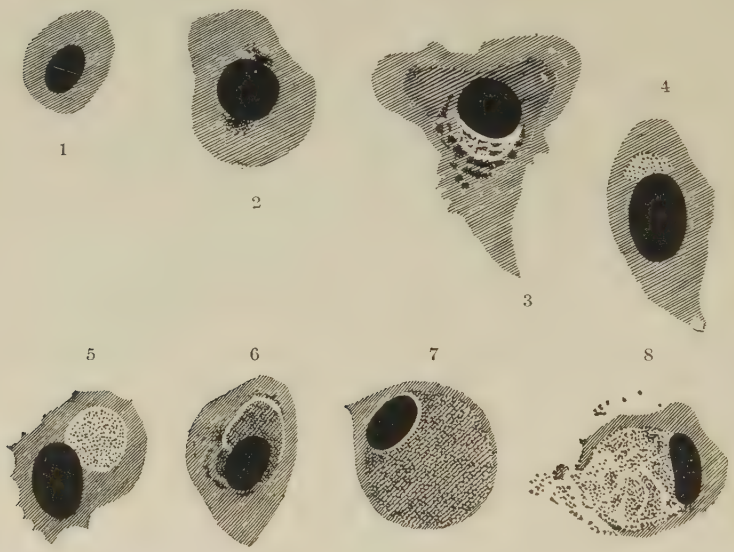

Trachoma bodies. (Greeff.)

Various stages of development are recognized. The very early appearance is of a minute double body or coccus, much smaller than the gonococcus, in the protoplasm of the cell surrounded by a clear zone (Fig. 137,1). These minute bodies multiply and become arranged close to the nucleus of the cell (Fig. 137, 2). As they increase in number, reaction products, which stain blue with Giemsa, make their appearance in the protoplasm of the cell (Fig. 137, 3), the "plastin" masses of von Prowazek, in which the minute double bodies are embedded. As the number of double bodies increases, they appear to be contained in a limiting mantle. The plastin disappears. The mantle expands as the double bodies increase in number, eventually occupying almost the entire protoplasm of the cell (Fig. 137, 4, 5, 6, and 7). The cell becomes enlarged, the nucleus

[1] For a comprehensive discussion of this part of the subject, see Axenfeld, Bakteriologie i. d. Augen., Jena, 1907.

PLATE XI

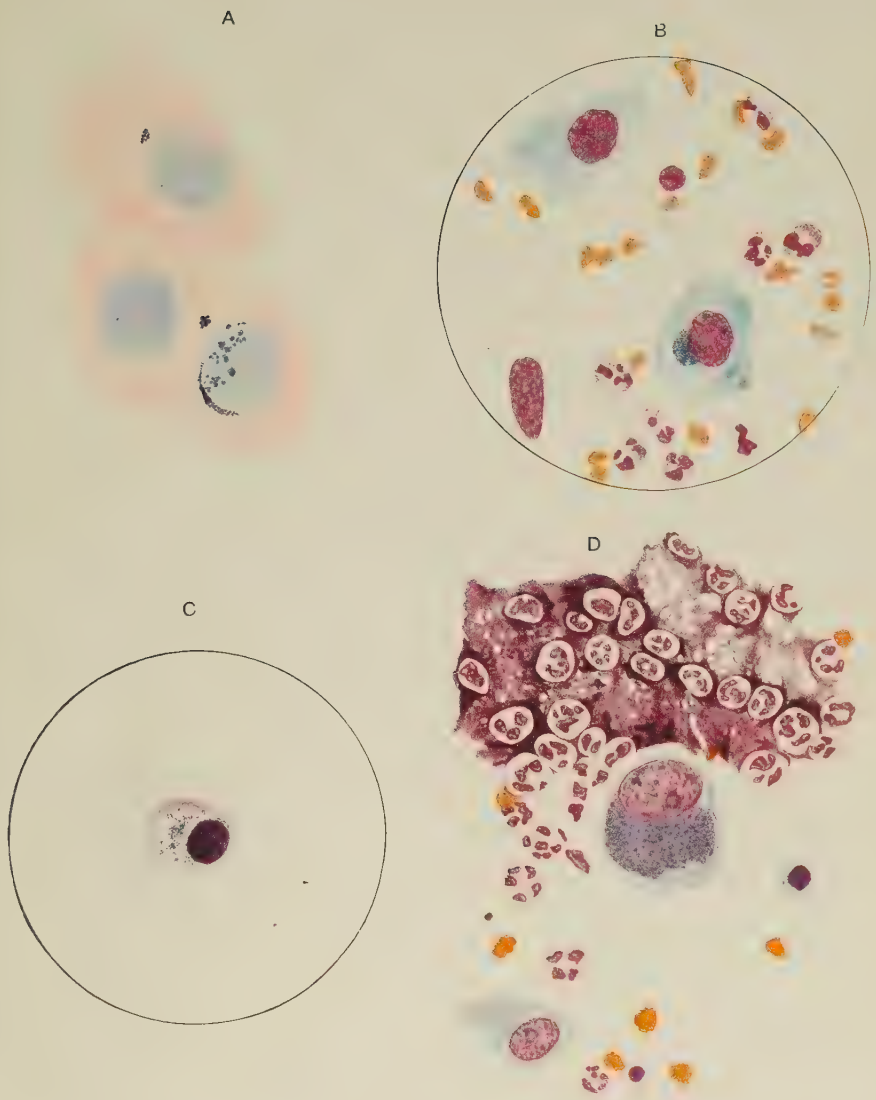

The Trachoma Microörganism of Halberstädter and Prowazek in various stages.

A, early, D, advanced stage. (Drawings by Dr. K. Lindner, Vienna.)

pushed to one side and flattened. Eventually the protoplasm of the cell gives way at some point and the contents become scattered (Fig. 137, 8).

Bodies that cannot be differentiated from the trachoma bodies of Prowazek have been found in non-gonorrheic ophthalmia neonatorum (Schmeichler,[1] Heymann[2]). Erdmann[3] has found similar bodies in chronic conjunctivitis and in vernal catarrh.

It is not proved that the chlamydozoan is the cause of trachoma. Schmeichler remarks that in the early stage of acute cases of trachoma the bodies are relatively few, not in any way bearing the relation in numbers to the case that is borne by pathogenic microörganisms in the acute stage of the conjunctival affections that they produce. Further studies must be made before the truth regarding the relation of this protozoan to trachoma is determined.

It cannot be demonstrated that any condition of the system predisposes to trachoma. The disease is found in the robust as well as in the poorly nourished. Lymphatic constitutions do not appear to contract the disease more readily than others.

The geographical distribution of trachoma is very wide. In this country trachoma is seen most commonly among those of foreign birth. The Irish, Germans, and Jews furnish the greater number of cases. The negro of pure blood is almost exempt (Burnett).

Pathology.—In the first stage the blood-vessels are enlarged and engorged; there is some small-cell infiltration and increase in connective-tissue elements in the substantia propria of the conjunctiva. The trachoma follicle, which is substantially a miniature lymph gland, is the essential element. These follicles consist of a delicate connective-tissue capsule containing a mass of lymphoid cells, this collection of cells being traversed by very fine connective-tissue trabeculæ. Small blood-vessels ramify in the connective-tissue stroma that surrounds the follicle, and capillaries are found in the mass of cells that form the follicle.

Formerly, no histological difference was found between the follicles in follicular conjunctivitis and those in trachoma, but recently S. Mayou[4] concludes from his investigations that the secretion and the tissue of the follicle in trachoma contain many more "plasma" cells than are found in other forms of conjunctivitis. Goldzieher[5] finds plasma and "mast" cells. As the disease passes into the second stage, the septa between individual follicles disappear and the lymphoid masses become continuous, forming plaques of various sizes. The substantia propria of the conjunctiva gradually gives place to cicatricial tissue. The layer of epithelium covering the granules is thin; it varies in thickness, and is irregular. As the process of cicatrization or atrophy advances, the mucous membrane loses its character and is replaced by cicatricial tissue to a great degree. In advanced cases cystic formations are observed in the shallow conjunctival sacs.

[1] Trans. Wiener Ophth. Gesell., June 16, 1909.
[2] Trans. Sec. on Ophth. XVI Internat. Med. Congress, 1909.
[3] Trans. Ophth. Soc. Heidelberg, 1908.
[4] Lancet, March 4, 11, 18, 1905.
[5] Arch. f. Ophth., lxiii, Heft 2, 1906.

Diagnosis.—Trachoma in its first stage may be confounded with vernal catarrh, tuberculosis of the conjunctiva, and Parinaud's disease. The history of the case will suffice to distinguish it from the first, or if the history is not sufficient, a microscopic examination of a nodule will suffice. In vernal catarrh the nodule is a fibroma. The microscopic examination with the history of the case will suffice to distinguish it from tuberculosis, and in Parinaud's disease the excessive involvement of the cervical and pre-auricular glands, with the affection confined to one side (as it usually occurs), will be sufficient.

Prognosis.—This is favorable when the disease is seen in the first or early part of the second stage, and, in fact, so long as any possibility of obtaining clear cornea exists. The danger of impairment of vision is not so much from suppuration and loss of the eyeball as from the development of opacities of the corneæ.

Treatment.—This is prophylactic, medicinal, and surgical.

Prophylaxis.—Trachoma should be treated as a contagious disease. The patient should be required to sleep alone. In homes care should be taken to prevent other members of the family from using towels, handkerchiefs, washing utensils, etc., that are employed by the patient. In asylums, barracks, etc., isolation, with individual towels, etc., should be resorted to. Washing from water running from the tap is better than the use of basins.

Medicinal.—This is applicable in the first and second stages. The eyes should be thoroughly cleansed as often as is necessary to keep them free from discharge by bathing with a solution of boric acid, or of bichloride of mercury (1 to 15,000).

Solutions: Innumerable remedies for the cure of trachoma have been advocated. Only those that possess some value will be mentioned. Eye drops of the bichloride of mercury (1 to 5000 to 1 to 3000), formalin (1 to 3000), or sulphate of copper in glycerin (1 to 5 per cent.) may be instilled into the eye three or four times daily; the conjunctival surface may be sprayed with tannic acid and glycerin (gr. 30 to 60 to oz. j) once daily. Iodine in benzoinal, 2 per cent. (Seabrook). The nitrate of silver in solution (1 to 5 per cent.) may be applied once daily with benefit when the discharge is profuse. Jequirity bean in infusion and in powder is employed to excite a counterinflammation to cause absorption of the follicles. The inflammation induced must not be too severe, as there is some danger of serious corneal involvement. In using jequirity, the susceptibility of the individual should be carefully watched, and the dose regulated accordingly.

Solid Applications: The remedy that finds most favor in cases of trachoma where the discharge is not profuse is the crystal of the sulphate of copper. This is applied by lightly and rapidly passing the smooth crystal over the affected portions of the conjunctiva. If the application (which should be made every forty-eight hours) is made quickly, it need not be followed by washing; but if the copper is permitted to rest too long on the surface of the conjunctiva, it should be washed off at once, as the irritation produced is apt to be excessive. The sulphate of

aluminum and potassium crystal and the mitigated stick of the nitrate of silver are also employed with benefit. The latter must be used cautiously.

Of the powders, iodoform, iodol, aristol, boric acid, and calomel are employed by dusting on or rubbing into the affected parts after cleansing. Morax recommends the use of a powder composed of boric acid, 50 parts, sulphate of copper dehydrated, 1 part. The lids are everted and the powder applied by massage, using the finger or thumb. The friction employed is sufficient to produce very slight bleeding. Application twice a week. Corneal complications usually require atropine in addition.

Surgical.—This is the most satisfactory method of treatment in the first and early part of the second stage. It consists in the various methods employed for removing the granules.

In cases where the palpebral fissure is narrowed and the cornea is suffering from undue pressure from the lids, canthoplasty may be resorted to. (See chapter on Operations.)

Röntgen Rays.—The treatment of trachoma by means of the Röntgen rays is reported on favorably by some, unfavorably by other investigators. The weight of evidence is in its favor, however. Special apparatus is required, and the results, as a rule, are not as satisfactory as those obtained by the usual methods. Burns may result.

Radium.—Radium has been used with satisfactory results by the greater number of observers. The exposures are from three to twenty minutes twice a week. Ten to twenty applications are necessary. There is no pain; no ill effects have been recorded thus far.

Pemphigus (*Essential Shrinking*).—This affection, which runs a specific course, is extremely rare, occurring but three times in 70,000 cases of eye disease observed by Horner. It is characterized by the formation of transient bullæ, which form on the palpebral, and at times on the ocular, conjunctiva on a reddened base. The bullæ soon break, leaving a floor, which is covered by a fibrinous exudation, slightly paler than the surrounding conjunctiva, with shreds of epithelium hanging to its borders; the denuded surface is soon covered by new-formed epithelium, and the process is soon again repeated. The denuded surfaces become agglutinated to opposing denuded surfaces, and soon bands of connective tissue join ocular and palpebral conjunctiva. Cicatricial tissue slowly forms in the substantia propria of the conjunctiva, and, after many years, the conjunctival sacs become obliterated. Superficial ulceration and opacification of the cornea develop. A condition of cicatricial xerosis is gradually reached and vision is reduced to perception of light. This process may occupy many years in its development, but its progress is unchecked by remedial measures. The affection is bilateral; it attacks individuals of all ages.

Etiology.—Pemphigus usually accompanies pemphigus vulgaris or pemphigus foliaceus, and depends on a dyscrasia of the system. A history of pemphigus affecting the mucous membrane of the nose, mouth, pharynx, or skin can usually be obtained. Syphilis cannot be

considered a cause. In 28 cases observed by Morris and Roberts,[1] only one gave a history of syphilis.

Treatment.—Treatment is of little value. Arsenic in large dose may be given internally with benefit in some cases. Ointment and mucilaginous preparations may be employed to relieve the dryness of the conjunctiva. Operative measures for restoring the conjunctival culs-de-sac may be resorted to.

Parinaud's Conjunctivitis.—This form is characterized by the formation of rather large granules or elevations on the conjunctiva (which are sometimes pedunculated, Gifford), with a mucopurulent discharge, accompanied by pronounced swelling of the pre-auricular, retromaxillary, and cervical glands. The glands sometimes suppurate. It attacks individuals of all ages, is monolateral, and does not appear to be contagious.

Etiology.—The disease is supposed to be due to infection of animal origin. No specific microörganism has been discovered, although the nature of the disease points strongly to a specific cause.

Symptoms.—The onset of Parinaud's disease, so far as the eye is concerned, is much like that of acute trachoma—lachrymation, followed in forty-eight to seventy-two hours by a mucopurulent secretion, with swelling of the lids, which in severe cases is very pronounced. On everting the upper lid on the third to fourth day, elevations are observed, which resemble the granules in acute trachoma. These nodules generally become somewhat larger than in trachoma, and soon superficial ulcers are observed in the sulci between the small nodules. The ulcers seem to bear some relation to the degree of involvement of the pre-auricular and cervical glands; when the ulcers are numerous the glands are most severely affected. Ulceration of the cornea, which is an occasional complication, is also more apt to occur when the conjunctival ulceration is most marked.

Prognosis.—The disease may terminate in three weeks, or it may persist for six to eight months. Relapses are very apt to occur, but eventually perfect recovery takes place. In two cases observed by the writer rapid improvement took place by keeping the patient in the hospital on a generous diet and bathing the eyes frequently with a hot 3 per cent. solution of boric acid.

Treatment.—Calomel (gr. $\frac{1}{10}$) given internally every four hours during the daytime for a number of days is beneficial. No special treatment directed to the nodules is necessary. A solution of the bichloride of mercury (1 to 3000) may be instilled every four hours, or some calomel may be dusted onto the conjunctiva; but frequent cleansing with a solution of boric acid seems to be sufficient.

Gout of the Conjunctiva.—An intense edematous swelling of the conjunctiva of the lids and of the eyeball, accompanied by profuse lachrymation, with little mucus, and occasioning great discomfort to the patient, is met with in individuals who suffer from gout.

[1] British Jour. of Dermat., 1889, p. 175.

PLATE XII

FIG. 1

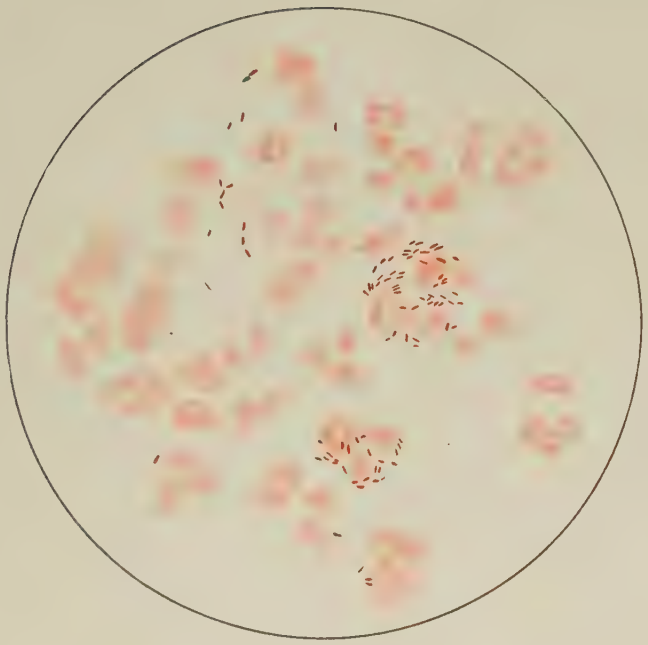

Koch-Weeks Bacillus. (Posey and Wright.)

FIG. 2

Bacterium Pneumoniæ in Blood of Rabbit. Stained by method of Gram. Decolorization not Complete. (Abbott.)

Symptoms.—This form of conjunctival irritation closely resembles the manifestations of gout as observed in the swelling of the great toe, the edema of the ankles and other distal articulations. It appears suddenly, reaching its height in twenty-four to forty-eight hours, and recedes in five to ten days. Chemosis may be marked. It is usually acompanied by gouty manifestations in other parts of the system, and is the occasional manifestation of a gouty crisis.

Treatment.—Locally, cleansing of the conjunctival sac three or four times daily with a solution of boric acid and the application of cool lead and opium wash compresses to the lids. Internally, treatment should be directed against the gouty condition.

Forms of Conjunctivitis in Which the Etiological Factor Has Been Determined.—Conjunctivitis due to the hemophile (Axenfeld) group of bacteria—Koch-Weeks bacillus, influenza bacillus of Pfeiffer.

Koch-Weeks Bacillus Conjunctivitis (*Acute Contagious Conjunctivitis; Pink Eye*).—*Etiology.*—It is due to the presence of a small bacillus first mentioned by Koch (1883),[1] proved to be the specific microörganism by Weeks[2] (1886). Size, 1 to 2 μ long; 0.1 to 0.15 μ in diameter. It is extremely difficult to cultivate; grows on ascites or blood agar. (For morphology and other characteristics, see table of bacteria at end of book.)

Susceptibility.—All conjunctivæ are susceptible to the influence of this microörganism. One attack of the disease does not produce immunity.

Symptoms.—For thirty-six to forty-eight hours after the inception of the contagium nothing further than a slight itching of the eye is experienced. On the morning of the second day the margins of the lids are stuck together by a mucopurulent secretion. The palpebral conjunctiva is congested and slightly swollen. The flow of tears is increased. There is a burning sensation in the lids. The interference with vision is slight. Toward evening the mucopurulent secretion increases and the general discomfort is more marked. By the fourth day the secretion has assumed a yellowish color and is quite copious. The height of the disease is usually reached on the fourth day. The acute stage lasts from three to seven days, and may be accompanied by coryza and frontal headache. In the early part of the acute stage numerous small extravasations of blood are frequently observed in the ocular conjunctiva. This symptom is so pronounced that some English surgeons have termed the disease "hemorrhagic conjunctivitis." The congestion of the ocular conjunctiva, in the acute stage, gives the eye a vivid red appearance, which has caused this form of conjunctivitis to be popularly known as "pink eye." As the acute stage subsides, the secretion is less copious and is thicker. A bright yellow mass of secretion is present at the inner canthus in the morning, a sign that is almost pathognomonic of the disease. The congestion of the ocular subsides more rapidly than does

[1] Wien. med. Woch., 1883, No. 52. No cultures were made by Koch.

[2] N. Y. Med. Record, 1886. Observed without knowledge of the mention of the bacillus by Koch. Cultivated and proved to be the specific microörganism by seven inoculations of human conjunctivæ, all of which were positive.

that of the palpebral conjunctiva, hypertrophy of the papillary body often persisting for a long time. With a subsidence of the secretion, and of the swelling of the lids and conjunctiva, the painful symptoms disappear; however, a peculiar sensation of dryness of the conjunctiva persists for some weeks, particularly noticeable on use of the eyes by artificial light.

Duration.—If simple cleanliness is observed, the disease usually runs its course in two or three weeks, all of the symptoms disappearing. It may last for six months if no treatment is instituted. Under suitable treatment the average duration is eight to twelve days.

Contagious Qualities.—Mucopurulent conjunctivitis is extremely contagious. In residential schools, asylums, barracks, penal institutions, communities, and families it is frequently epidemic. It may become endemic. Communication from one individual to another is, probably, by means of towels, common bathing water, etc., as well as by direct contact. There is little doubt that the contagious element may be carried by drafts of air and by the water in public baths.

Diagnosis.—In a typical case the diagnosis is comparatively easy. In the severe cases the condition may be mistaken for gonorrheal conjunctivitis, or even for diphtheria in cases where a pseudomembrane occurs. The microscope is necessary to clear up the diagnosis in these cases.

Complications.—Corneal ulcer (extremely rare), phlyctenular conjunctivitis and keratitis, trachoma, and pseudomembrane[1] may complicate this disease. In approximately three thousand cases the writer has seen corneal ulcer in three cases, not particularly severe. Phlyctenulæ and trachoma are due to added infection. Pseudomembrane occurs in those cases (4 to 6 per cent.) in which the disease is severe and there is a tendency to fibrinous exudation.

Prognosis.—Favorable in all cases.

Prophylaxis.—This is all-important, and consists in strict isolation until all of the secretion has disappeared.

Treatment.—A knowledge of the contagious qualities of the small bacillus and of its life history determines the rationale of treatment.

Since the thermal range of growth is between 35° and 42° C., the growth of the bacillus can be limited by reducing or elevating the temperature of the conjunctival sac beyond this range. It is not difficult to lower the temperature of the conjunctival sac to 32° C. by making cold applications to the lids by means of pledgets of linen or of small pads of absorbent cotton placed on a cake of ice and changed to the eye every one and one-half minutes. If this is done for three hours at

[1] Pseudomembrane of the conjunctiva is met with in conjunctivitis occasioned by the Koch-Weeks bacillus, the pneumococcus, the gonococcus, streptococcus, Klebs-Loeffler bacillus, after thermal and chemical cauterization, and after injury resulting in abrasion of the conjunctival epithelium. The basis of all conjunctival pseudomembranes is a layer of fibrin-coagulated lymph. The plasma of the blood escapes from the minute vessels of the conjunctiva and coagulates on the surface of the mucous membrane, holding enmeshed epithelial cells, leukocytes, blood corpuscles, and whatever bacteria may be present. The construction of all pseudomembranes is the same in all cases, except in regard to the bacterial content.

a time three times in twenty-four hours during the acute stage, two or three days will suffice to cause the inflammation to subside. Frequent cleansing with sterile boric acid solution, 3 per cent., should be resorted to. As the acute stage begins to subside, much benefit will be derived by applying a 0.5 per cent. solution of the nitrate of silver to the conjunctival surface once daily until the secretion ceases. Argyrol (25 per cent. solution) or protargol (10 per cent. solution) may be used as soon as the disease is recognized, and continued during the acute stage; the argyrol to be dropped into the eye every one to three hours, the protargol every three to four hours.

Bandaging the Eyes.—The application of bandages, of poultices, tea leaves, oysters, bread and milk, etc., should be avoided; they serve to retard recovery and to originate severe complications.

Fig. 138

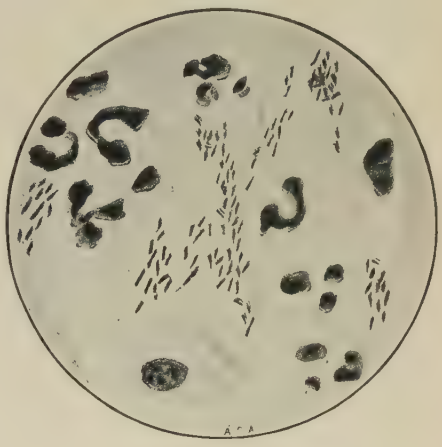

Bacterium influenzæ in sputum. (Abbott.)

Influenza-Bacillus Conjunctivitis.—*Etiology.*—The influenza bacillus (bacillus of Pfeiffer). Young children are most frequently affected. The type of conjunctivitis is mucopurulent. The influenza-bacillus conjunctivitis closely resembles a mild case of conjunctivitis due to the Koch-Weeks bacillus, from which it can be diagnosticated only by microscopic or culture examinations. Of 13 cases investigated by Nedden, the influenza baccillus was found pratically alone in 10 cases, with the pneumococcus in 3 cases. In 5 cases the eyes were primarily involved. With the conjunctivitis was associated, either primarily or secondarily, bronchitis, dacryocystitis, rhinitis, or otitis media.

Prognosis.—Favorable so far as the eyes are concerned. Corneal involvement is rare.

Treatment.—As in Koch-Weeks bacillus conjunctivitis.

Conjunctivitis Due to the Chain-forming Micrococcus Group.—Pneumococcus (Fraenkel-Weichselbaum), Streptococcus pyogenes.

Pneumococcus Conjunctivitis.—*Etiology.*—Acute contagious conjunctivitis due to the presence of the pneumococcus was first described by Morax, in 1894. The clinical features of this disease are similar to those of the disease just described, except that, as a rule, the disturbance is less severe. The *description* and *treatment* just given will suffice for this form of conjunctivitis.

Contagious Qualities.—Pneumococcus conjunctivitis may affect children and adults; usually sporadic, it may become epidemic. It has been proved by the researches of Gasperini, Gifford, and others that a

susceptible condition of the conjunctiva must exist before this disease can be produced. It is well-known that the Weichselbaum pneumococcus may exist in the normal conjunctival sac without producing inflammation.

Diagnosis.—It is difficult to differentiate pneumococcus conjunctivitis from the conjunctivitis due to the Koch-Weeks bacillus clinically. The microscope will serve to establish the diagnosis.

Duration.—Three days to two weeks.

Prognosis.—Good in all cases.

Streptococcus Pyogenes Conjunctivitis.—Streptococcus conjunctivitis is rare, but apparently does occur. The streptococcus pyogenes is apparently the cause of some of the cases of pseudomembranous conjunctivitis of the type described on page 241, and is not infrequently associated with dacryocystitis, impetigo, and abscess of the lid. The affection is monocular in quite a large proportion of the cases. Vision may be lost from ulceration of the cornea. The general health may suffer very greatly. The writer observed a case of this nature in which the pseudomembrane persisted for three and a half to four months. There was secondary dacryocystitis of the right eye and several small abscesses of the lids. The right eye was destroyed; the left eye impaired. For diagnosis, treatment, etc., see page 241.

Fig. 139

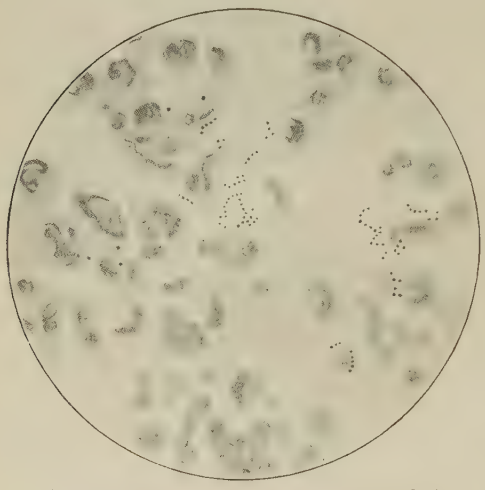

Streptococcus pyogenes. (Posey and Wright.)

Conjunctivitis Due to the Diplobacillus Group.—Diplobacillus, Morax-Axenfeld; diplobacillus Liquéfiant, Petit. (For morphology, etc., see table of bacteria at end of book.)

Subacute Conjunctivitis (*Diplobacillus Conjunctivitis*).—*Etiology.*—Morax and later Axenfeld have described a bacillus as the cause of this disease, and their studies have been confirmed by Gifford and others.

Symptoms.—This form of conjunctivitis is insidious in its onset, producing some redness and slight thickening of the conjunctiva, largely confined to the conjunctiva of the lids and fornices. It affects both eyes almost without exception. Two or three days after the first, the second eye becomes involved. There is slight increase in lachrymation, a scanty secretion of mucus, with some pus corpuscles; irritation as of a foreign body in the eye; burning sensations on use of the eyes, particularly at night. The annoyance is relatively slight, but persistent. The eyelids may become

PLATE XIII

FIG. 1

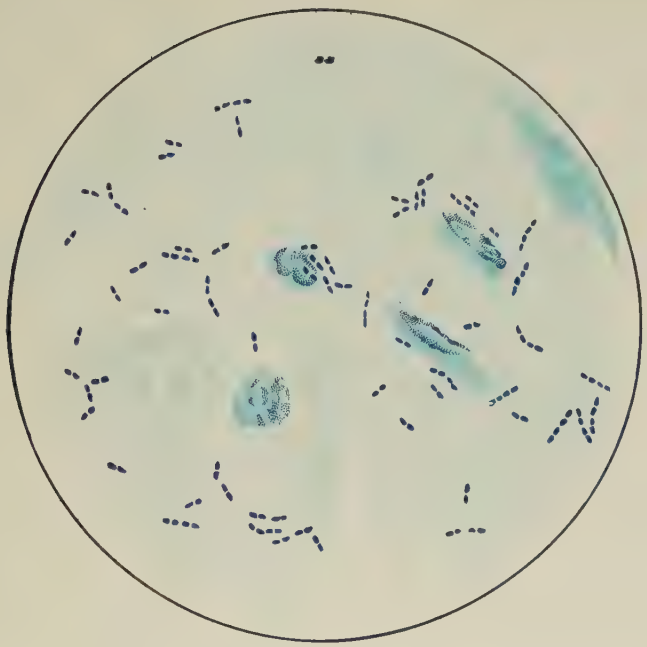

Morax-Axenfeld Diplobacillus. (Posey and Wright.)

FIG. 2

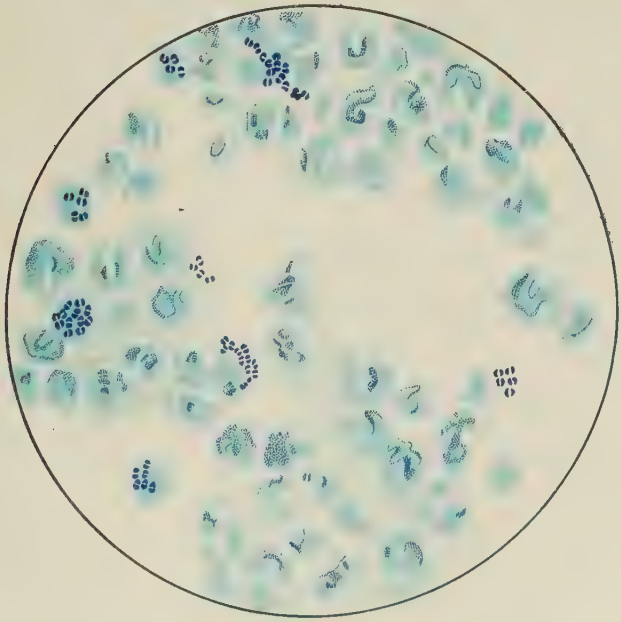

Gonococcus. (Posey and Wright.)

somewhat congested, but they are not appreciably thickened. After some days the skin of the lids may become red and eroded at the outer or inner angle. The term *conjunctivitis angularis* has been applied to this phase of the disease. In rare cases the cornea becomes involved, a superficial marginal keratitis being produced, followed by cloudiness of the affected area; this may advance and cut the transparent area of the cornea down to very small limits.

Contagiousness.—When introduced into the conjunctival sac of man, positive results are obtained in every case. The bacillus is not pathogenic for conjunctivæ other than human. While the affection is met with frequently, it does not appear in epidemic form.

Diagnosis.—The diagnosis from the clinical appearance is usually easily made. Examination of the secretion by the microscope makes the diagnosis certain.

Duration.—The disease may last six weeks or as many months.

Treatment.—The eye should be cleansed with a boric acid solution, and zinc sulphate or zinc chloride (gr. j to oz. j) should be instilled twice or three times a day. The zinc salts appear to be specific in the treatment of this form of conjunctivitis. Morax recommends the following:

℞—Vaseline	15.0
Lanoline	5.0
Oxide of zinc	2.0
Ichthyol	0.5 to 1—M.

Sig.—Apply twice daily.

Petit's[1] Diplobacillus Conjunctivitis.—*Etiology.*—This microörganism was first observed in hypopyon keratitis. Later, Morax and McNab found it in a very few cases of conjunctivitis, and Erdman succeeded in producing conjunctivitis by the introduction of a pure culture into the conjunctival sac. It is a very infrequent cause of conjunctivitis.

Symptoms.—The effect on the conjunctiva is the same as by the Morax-Axenfeld diplobacillus.

Treatment.—As for the Morax Axenfeld diplobacillus conjunctivitis.

Conjunctivitis Due to the Diplococcus.—Gram negative group—gonococcus, D. intracellularis meningitides, Micrococcus catarrhalis. (For morphology, etc., see table of bacteria at end of book.)

Gonococcus Conjunctivitis (*Purulent Conjunctivitis; Acute Blennorrhea*).—When gonorrheal conjunctivitis occurs in infants it is termed *ophthalmia neonatorum.*

Etiology.—This affection is due to the presence in the conjunctival sac of the gonococcus of Neisser described by him in 1879. The contagium is most frequently conveyed by the finger from an active gonorrheal urethritis or from a gleet; towels, washing utensils, soiled linen, etc., may be the means of carrying it. This microörganism attacks all human conjunctivæ with which it comes in contact, regardless of the condition of the individual.

[1] Described by Petit in 1900, Recherch. Clin. et Bact., sur les infections aigües de la cornée, Paris.

Pathology.—The pathology of gonorrheal ophthalmia and that of ophthalmia neonatorum are similar. The tissue of the lids is infiltrated by serum, plastic exudation, and small cells. This infiltration is undoubtedly excited by ptomaines produced by the development of the gonococcus in the superficial layer of the conjunctiva. The vessels of the conjunctiva and lids become enlarged and engorged and a varying degree of venous stasis is produced. The conjunctiva is much thickened, the papillæ enlarged. As the disease subsides all the inflammatory products disappear without leaving a trace, except in the very severe cases, in which there may be loss of conjunctival tissue, replaced by

Fig. 140

State of the lids in gonorrheal conjunctivitis. (After Dalrymple.)

Fig. 141

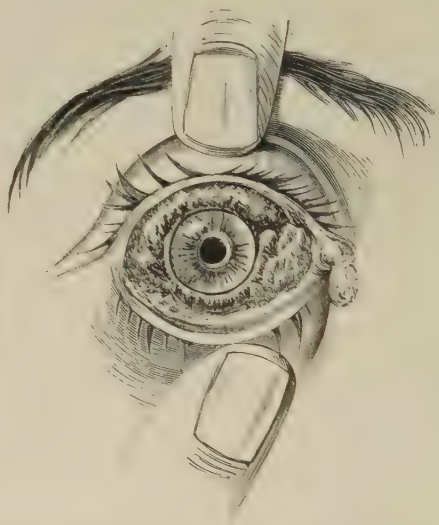

Gonorrheal conjunctivitis. Shows the swollen and chemotic condition of the conjunctiva of an eye in which the disease has existed four or five days. (After Dalrymple.)

cicatricial tissue; and in the very chronic cases in which nodular masses remain in the conjunctiva, and the papillary body remains permanently hypertrophied.

Symptoms.—*Acute Stage.*—A period of twelve to thirty-six hours is required after the entrance of the contagium to produce any marked disturbances, then lachrymation is increased, the conjunctiva soon becomes injected, and swells rapidly. Twenty-four hours later the lids have become much swollen, the conjunctiva thickened and deeply injected, the secretion mucopurulent, sometimes sanguinolent, and mixed with the lachrymal fluid. Burning and gritty sensations are experienced, dull pain in the eye is occasioned by the pressure of the lids; in two or three days the height of the acute stage is reached. The swelling of the lids is often enormous. The eye cannot be opened by

the patient, and is opened with difficulty by the surgeon. The palpebral conjunctiva is much thickened and velvety, the ocular conjunctiva swollen, and often glistening, small ecchymotic spots are sometimes present; chemosis is marked. The secretion, which is yellow, not very thick and almost entirely free from mucine, flows from beneath the upper lid onto the cheek, matting the cilia together. The acute stage continues five to eight days, when it gradually passes into the subacute stage. The tense swelling of the lids subsides, the venous stasis is relieved. The secretion, which is copious, is creamy; the conjunctiva is thickened and thrown into folds and nodules; the chemosis is less marked. With a diminution in the weight and tension of the lids the pain becomes less severe. This stage may last two or three weeks and recovery then be established, or the disease may pass into a chronic stage which may continue for some weeks or even months.

Severity.—The description just given applies to the average case. Cases occur in which the affection is exceedingly light, the discharge scanty and not free from mucus. Some cases are extremely severe, the swelling of the lids and conjunctiva being very great. Pseudomembranes form on the surface of the palpebral conjunctiva, often closely resembling diphtheria. The severe cases occur most frequently in adults.

Diagnosis.—Light forms of the disease may be confounded with acute contagious conjunctivitis, and, rarely, with micrococcus catarrhalis and with meningococcus conjunctivitis. Severe cases may be mistaken for diphtheria. The microscopic examination of the secretion will serve to make the diagnosis clear in all but a very few cases. In doubtful cases culture tests must be resorted to. In cases that have been under treatment for some time and in the very mild cases it is difficult to find the gonococcus, but patient search will usually meet with reward. It is advisable to examine the urethra in all males, and to ascertain the presence or absence of vaginitis and urethritis in all females affected. This is particularly desirable when the patients are inmates of institutions.

Prognosis and Complications.—The cornea is involved in about 70 per cent. of the cases occurring in adults. The ultimate impairment of vision varies much.

Holmes-Spicer[1] analyzed 158 cases of gonococcic conjunctivitis in children and adults. One hundred and twenty-six were men. Restoration of vision without great diminution occurred in 110 cases. In 98 cases the cornea became involved. In every patient over thirty-eight years of age, with one exception, the eye was lost. Gonorrheal rheumatism developed in 16 cases. Ulcer of the cornea in gonorrheal ophthalmia begins with a haziness and slight roughness at the margin of the cornea, either where there has been a loss of superficial epithelium, due to cleansing the eye or from some slight traumatism, or at a dependent portion where the secretion has lain in contact with the cornea for some time. The haziness is soon followed by a shallow, grayish ulcer, which

[1] R. L. O. Hospital Reports, xxiii, p. 221

tends to extend more or less rapidly. The ulcer may stop at any stage; it may totally destroy the cornea, permitting loss of lens and vitreous, and causing panophthalmitis. Ulcer of the cornea does not occur ordinarily until the second week of the disease. Gonorrheal iritis and iridochorioiditis may complicate the attack. Gonorrheal rheumatism occurs in the late stages of this disease only. Pseudomembrane forms on the palpebral conjunctiva in perhaps 40 per cent. of the cases that occur in adults.

Prophylaxis.—One who has gonorrheal urethritis should be cautioned regarding the danger of infecting the conjunctiva. After a gonorrheal conjunctivitis is established in one eye, care should be observed not to convey the contagion to the other eye. In adults it is wise to protect

Fig. 142

Buller's shield.

the eye either by a carefully applied aseptic bandage sealed at the nasal half with collodion, or, better, a Buller shield may be employed (Fig. 142). This consists of a watch glass which is secured over the eye by means of rubber adhesive plaster. All dressings that come from the eye should be destroyed, and the greatest care should be observed in the disinfection of appliances used. The nurse and those in attendance should be instructed regarding the danger and the precautions necessary.

Treatment.—It is possible in some cases that are seen in twenty-four or thirty-six hours after the eye has been infected to abort the disease. This is done by thoroughly cleansing the eye with a solution of boric acid, freeing it from all secretion, thoroughly applying a solution

of the nitrate of silver (1 to 2 per cent.) to the entire surface of the conjunctiva twice in twenty-four hours, and making cold applications to the lids. After three applications the silver may be stopped. The use of boric acid for cleansing the conjunctiva should be continued for a few days. The greater number of cases have progressed too far when seen by the surgeon to permit of abortive treatment. In these cases careful, vigorous treatment must be commenced at once, and continued night and day.

Indications.—The indications for treatment are (1) to eliminate the microörganism (*a*) by mechanical removal, (*b*) by inhibiting their growth, (*c*) by destroying them; (2) to relieve symptoms; (3) to prevent and treat complications as they arise.

Mechanical Removal.—Removal of the microörganism can be but partially effected. This is accomplished by frequently irrigating the conjunctival sacs with a solution of boric acid (3 per cent.), bichloride of mercury (1 to 15,000), permanganate of potash (1 to 500 to 1 to 5000), or peroxide of hydrogen (1.5 to 3 volumes). In cleansing the eye *great care* must be observed not to injure the corneal epithelium.

Inhibition of Growth.—Since the thermal range of the growth of the gonococcus is, according to Axenfeld, 77° to 102.2° F. (25° to 39° C.), it is manifestly impossible to inhibit greatly their growth by hot or cold applications to the lids. Cold applications reduce the suffering of the patient in the acute stage in the greater number of cases, and probably inhibit the growth of the microörganism to some extent. The applications should be made two or three hours at a time, omitted one hour, and again continued. This may be kept up during the acute stage.

Method of Making Cold Applications.—Pledgets of linen one and one-half by two inches square, of three or four thicknesses, or thin pads of absorbent cotton, should be prepared to the number of a dozen or more, and after being moistened, placed on a cake of ice. (A thin piece of linen may be spread on the ice and the pads laid on the linen.) A pledget must be changed from ice to eye every one to two minutes, or often enough to keep the pledget that rests on the eye cool. To carry out this treatment requires the constant attendance of two nurses—one for the day and one for the night duty.

It may occur that the eye is kept too cold and the corneal tissue loses its vitality. In such cases the cornea becomes uniformly hazy, taking on the appearance of ground glass. This calamity can easily be avoided by inspecting the cornea from time to time. Heat is not desirable until the gonococci have disappeared; in the later stage of the disease it may be of service.

Germicides.—A number of remedies for the elimination of the micro-organism, the exact germicidal value of which is still in question, are in favorable use. Some of these remedies may serve to render the tissues less favorable for the growth of the microörganisms, aside from their germicidal value. Argyrol and protargol belong to this class; both are valuable. Argyrol may be used in a solution of 15 to 35 per cent., dropped

into the eye every hour in severe cases, less frequently in milder cases. Some surgeons (Standish) employ argyrol for the mechanical removal of the secretion as well, keeping the eye flooded with a 15 to 25 per cent. solution, a dam of putty being built along the lower margin of the orbit. The use of argyrol may be continued until the secretion has almost, if not quite, disappeared. Protargol is used in 10 per cent. solution, dropped into the eye every two to four hours. The nitrate of silver, bichloride of mercury, and formaldehyde are decidedly germicidal in the strength of solution employed. The nitrate of silver is of great value in the treatment of gonorrheal ophthalmia; it may be used in connection with argyrol. The application of the nitrate of silver in the strength of 1 to 2 per cent. should be made to the entire conjunctival surface, so far as possible, once daily in severe cases; once in forty-eight hours in milder cases. When the discharge has almost ceased, the silver may be applied in the strength of 0.5 per cent. The bichloride of mercury may be employed in a similar way in the strength of 1 to 50 to 1 to 500, the strength of the solution depending to some extent on the reaction produced. Formaldehyde in the strength solution of 1 to 200 to 1 to 2000 may be applied in a similar manner. The effect of the two last-mentioned remedies is not so generally satisfactory.

A very satisfactory plan of treatment for severe cases is the following: Irrigations with a solution of boric acid (3 per cent.), every half to one hour, as required, or a solution of the permanganate of potash (Kalt) (1 to 3000), four times in twenty-four hours, using one to two pints of the solution at each irrigation, should be continued until all secretion has ceased; applications of the nitrate of silver (2 per cent.) once every twenty-four hours; cold applications, principally for the comfort of the patient, during the acute stage, two hours at a time, with intervals of one or two hours; the strength of the solutions of the nitrate of silver should be lessened as improvement advances.

Depletion.—Leeches are not of much value. If the lids are greatly swollen and the cornea likely to suffer from pressure, a free canthotomy may be performed, which affords depletion as well as release of tension. Critchett's operation, which consists in splitting the upper lid vertically through its entire thickness and stitching the flaps to the brow, restoring the lid by a plastic operation after the disease has subsided, is heroic, but may be resorted to in desperate cases. Scarification of the chemotic tissue may be advisable in some cases.

When ulcer of the cornea is threatened, borated vaseline should be applied to the corneal surface, after thoroughly cleansing the cornea and conjunctiva, at least every two hours. Atropine (the alkaloid) may be added to the vaseline in the proportion of one grain to the ounce; or atropine sulphate in solution (1 per cent.) may be instilled twice daily. If perforation is imminent, paracentesis or Saemisch's incision may be done through the floor of the ulcer. If there is no evidence of congestion or inflammation of the iris, and the ulcer progresses, eserine (0.25 per cent.) or pilocarpine (1 per cent.) may be instilled twice daily.

The leucomata and staphylomata and the shrunken globe that follow in some cases must be treated as thought most expedient. In threatened cases of staphyloma the *tension* of the globe should be watched and iridectomy performed as soon as increase is manifest.

Metastatic Gonorrheal Conjunctivitis.—*Etiology.*—A form of conjunctivitis due to endogenous infection of the subepithelial tissue of the conjunctiva, occurring some days or weeks after the onset of an acute gonorrheal urethritis, is sometimes observed.

Symptoms.—The affection is characterized by an edematous swelling of the conjunctiva, principally the ocular conjunctiva, with some hyperemia, increased lachrymation, but no purulent discharge. There is a sensation of stiffness of the lids, with heat and sometimes dull pain. The eyelids are slightly swollen. The condition may be unilateral, but is more frequently bilateral. It may or may not be accompanied or preceded by gonorrheal rheumatism or gonorrheal iritis.

This form of gonorrheal affection occurs in adults almost exclusively.

Duration.—Five days to two weeks.

Prognosis.—Recovery occurs, as a rule, without leaving a trace.

Treatment.—This consists in treating the gonorrhea and freeing the system of the pathogenic microörganisms. The gonococcic vaccine in dose of 5,000,000 to 20,000,000 repeated every third day may be of value.

Gonococcic Conjunctivitis in Infants (*Ophthalmia Neonatorum*).—Etiology.—The term ophthalmia neonatorum (ophthalmia of the newborn) includes all cases of conjunctivitis that occur in infants, at least before the end of the first month after birth, from whatever cause.

All who have made careful bacteriological examinations of the secretion in cases of ophthalmia neonatorum are convinced that the cases that occur before the end of the third day after birth are due almost without exception to the presence of the gonococcus. Cases that occur later may be due to the gonococcus, but not a few are due to the Koch-Weeks bacillus, the pneumococcus, the Klebs-Loeffler bacillus, or some other form of pathogenic germ or irritating substance. We shall consider here the cases caused by the gonococcus only.

In almost all of the cases infection undoubtedly occurs during the passage of the child along the genital tract of the mother and just at the time of delivery, due to the entrance of the vaginal secretion containing gonococci into the conjunctival sacs. In rare cases infection takes place antepartum, the disease being well advanced at birth. In some cases destruction of the cornea has already taken place. Infection by the nurse's hands, by unclean washes, and by soiled linen may occur. Both eyes are usually involved.

Symptoms.—A slight redness of the conjunctiva is usually observed on the second day, and on the third morning the lids are glued together by a small quantity of mucopus. The lids begin to swell, and soon the upper lids become enormously thickened, dusky red, and very tense; they overlap the lower lids. In the early part of the acute stage some seromucopus, tinged often with bile pigment, oozes from the palpebral fissure. Bleeding from the conjunctival surface occurs easily on attempt

to evert the lids. The height of the acute stage is reached on the third or fourth day. Soon the character of the discharge changes to a creamy pus, large quantities of which escape from the eyes; the conjunctiva becomes greatly thickened, the palpebral conjunctiva more than the ocular. The acute stage gradually passes into a subacute condition, in which the swelling of the lids subsides; the conjunctiva, although rough, becomes pale and atonic; the discharge a little less creamy and less in quantity. This condition may continue for some weeks or months.

Severity.—The above is a description of a case of medium severity. Cases of much greater severity are occasionally observed. The onset is more rapid; the secretion serosanguinolent at first; pseudomembrane forms on the palpebral conjunctiva, and the disease resembles diphtheria of the conjunctiva. A number of cases are extremely mild, the onset very slow, and recovery rapid.

Diagnosis.—The age of the patient determines the term to be applied to the disease. A microscopic examination of the secretion of every case of ophthalmia neonatorum should be made. This will serve to relegate each one to its proper category.

Complications.—Corneal ulcer, destruction of the cornea, panophthalmitis, iritis, and gonorrheal rheumatism may complicate ophthalmia neonatorum. If the patient is seen early and proper treatment instituted, involvement of the cornea will be extremely rare. It is seldom that grave complications arise in any but neglected cases. Iritis and rheumatism that develop as a result of gonococcic conjunctivitis appear, as a rule, during the third and fourth weeks. When rheumatism develops, the knee-, ankle-, elbow-, and wrist-joints are most frequently affected. Abscesses may occur. The gonococcus has been recovered from the fluid in the joints.

Prophylaxis.—It has been fully demonstrated that efficient measures taken to prevent the development of ophthalmia neonatorum serve to reduce the percentage from 9 or 10 per cent. to 0.5 per cent. or less.

It is estimated by competent observers that 10 per cent. of the blind in the United States become blind from ophthalmia neonatorum,[1] consequently the importance of prophylaxis in this disease is very great.

Just before and during labor the genitals of the mother should be rendered as aseptic as possible by the use of suitable douches and washes. Very shortly after the birth of the child the lids should be freed of secretion by wiping with absorbent cotton, the lids parted, and one drop of a 2 per cent. solution of the nitrate of silver instilled from the end of a glass rod. If more than one drop enters the eye, the solution should be neutralized in one-half to one minute by irrigating with normal saline solution. If the reaction is considerable, cold applications should be made to the lids for an hour after the application. This is the method of Credé, introduced by him at the Lying-in Hospital at Leipzig in 1880.

Treatment.—Again, cold applications are desirable in the acute stage. In severe cases applications should be made two hours at a

[1] Trans. Amer. Ophthal. Soc., 1898, p. 265.

time, with intervals of one or two hours. In mild cases one hour three times daily will suffice. Irrigation with boric acid solution should be done frequently, every half hour in the ordinary case, to keep the eye free of secretion. Permanganate of potash solution, 1 to 5000, or sublimate, 1 to 15,000, may be substituted from time to time for the boric acid solution. As soon as the tense, brawny condition of the lid has partly subsided, applications of silver nitrate (0.5 to 2 per cent.) should be made once in twenty-four hours. Protargol (10 per cent.) may be substituted for the silver, instilled every three hours; but the prolonged use of the protargol must be avoided, as it tends to produce a thickening and chronic irritable condition of the conjunctiva. Argyrol in 25 per cent. solution, instilled every one to three hours, may be employed.

Micrococcus Catarrhalis Conjunctivitis.—*Etiology.*—The conjunctivitis developed by the presence of the micrococcus catarrhalis is of a mild type, is infrequent, and is often accompanied by rhinitis and pharyngitis, the microörganism being present in the secretion from these membranes. For the characteristics of this diplococcus, see table of bacteria at end of book.

Diagnosis.—The micrococcus catarrhalis is larger than the gonococcus, but the difference is difficult to determine morphologically. When it is necessary to differentiate, culture tests should be employed.

Treatment.—As for the mild forms of gonococcic conjunctivitis.

Fig. 143

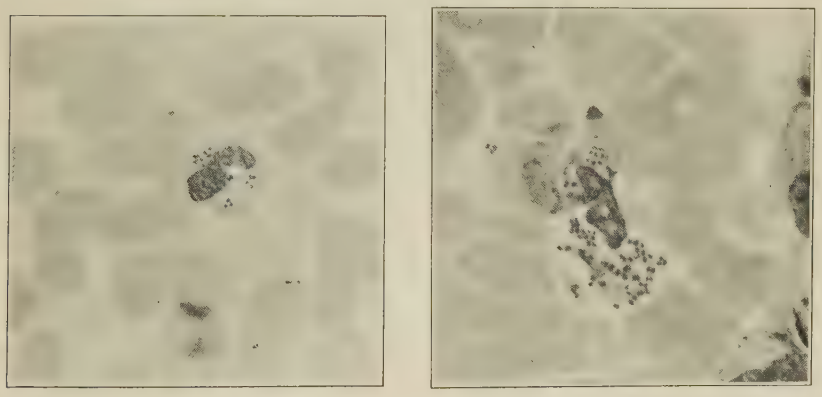

Diplococcus intracellularis meningitidis.

Meningococcus Conjunctivitis.—The Diplococcus intracellularis meningitidis (Weichselbaum) has been reported as having been found in the secretion from a mild form of conjunctivitis[1] accompanying cerebrospinal meningitis without culture tests. Axenfeld reports one case which was combined with keratomalacia from the pneumococcus, in which there was no meningitis. The meningococcus was recovered by cultivation. It is as yet doubtful whether the meningococcus is

[1] D. Smith, Arch. of Oph., 1905, xxxiv, 48; Robinson, Am. Jour. Med. Sci., April, 1906.

capable of causing conjunctivitis. If it does, the conjunctivitis is of mild form. That the meningococcus is at times present in the conjunctival sac cannot be doubted. As it closely resembles the gonococcus and is Gram negative, culture tests should be made before a positive diagnosis is made.

Conjunctivitis Due to the Diphtheria Group of Bacteria (*Clubbed Bacteria*).—The diphtheria group consists of the corynebacterium diphtheriæ (Klebs-Loeffler), the corynebacterium pseudodiphtheriticum, and the corynebacterium xerosis. Of these, the Klebs-Loeffler variety only is pathogenic for the conjunctiva. (For morphology, etc., see table of bacteria at end of book.)

Fig. 144



Diphtheria bacillus. (Posey and Wright.)

Klebs-Loeffler Conjunctivitis (*Diphtheritic Conjunctivitis*).—This is a violent inflammation of the conjunctiva, accompanied by the formation of a pseudomembrane, and frequently accompanying diphtheria of the nose and fauces.

Etiology.—The Klebs-Loeffler bacillus is the only cause of this form of conjunctivitis; but this microörganism is soon joined by others, notably the streptococcus and the staphylococcus, which modify the effect of the Klebs-Loeffler bacillus, often increasing the severity of the disease. The Klebs-Loeffler bacillus is not pathogenic for all conjunctivæ; a favorable condition of the mucous membrane must exist, as is necessary in the pharynx, fauces, and nose, before the specific

disease can be established. It is probable that the other two forms of corynebacteria may be present in the reaction accompanying the Klebs-Loeffler bacillus conjunctivitis.

Pathology.—The development of the microörganism, with the resulting toxins, on the conjunctiva appears to cause destruction of the superficial epithelial cells, and to so affect the blood-vessels that a portion of the plasma of the blood escapes into the tissue of the conjunctiva and lids, there coagulating, producing the tense, firm thickening. The plasma of the blood also escapes onto the conjunctival surface, there coagulating and forming the pseudomembrane. In mild cases where the lid does not become hard, the coagulation of plastic lymph in the tissues of the lids does not occur. While the formation of pseudomembrane is

Fig. 145

Diphtheria bacillus. (Posey and Wright.)

not pathognomonic of diphtheria, it almost without exception occurs in diphtheria of the conjunctiva. The greater number of cases known as croupous conjunctivitis are in reality diphtheria; they bear the same relation to the more severe forms that membranous croup does to diphtheria of the nose and pharynx.

Symptoms.—The period of incubation is from twelve to thirty-six hours. Intense swelling of the upper lid, which becomes brawny, dusky red, and very tense, develops very rapidly, the firm condition being due to a plastic exudation into the tissue of the lids, venous stasis from pressure imparting the cyanotic appearance. The secretion from the lids is scant at first, being composed of lachrymal fluid, serum and blood.

Very little pus or mucus is seen earlier than the second day after the onset. Gradually the secretion becomes flaky, mucopurulent, with some blood and shreds of fibrin; which character it assumes in the subacute stage, becoming purulent at the end of this stage. The intense swelling of the lids lasts from two to five days, after which the lids become flabby, but remain thickened one to three weeks. Restoration to the normal progresses very slowly.

Pseudomembrane.—This occurs very early in the course of the disease. At the end of twenty-four hours after the congestion of the conjunctiva begins the palpebral conjunctiva is covered by a thin pseudomembrane, which rapidly increases in thickness and extends to the ocular conjunctiva. The pseudomembrane persists until the subacute stage is well established. It reaches the thickness of 1 millimeter, rarely more; when it becomes detached it often presents a perfect cast of the fornix.

Fig. 146

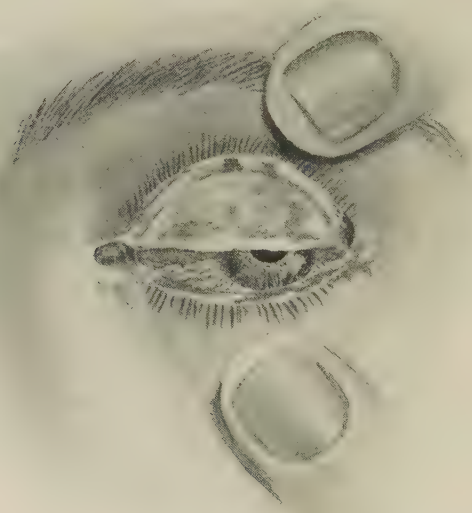

Diphtheritic conjunctivitis.

Severity.—Diphtheritic conjunctivitis may exist without the intense thickening of the lids that has been described, but a pseudomembrane forms and is persistent. The pseudomembrane may be very little and the whole affection extremely mild. Some cases may be termed "fulminating," so rapid are they in the onset, so intense the swelling, and so disastrous the result to the cornea.

Complications.—Ulcer of the cornea, total destruction of the cornea panophthalmitis, and sloughing of parts of the conjunctiva and lids

are the complications met with. The toxins of the Klebs-Loeffler bacillus alone may cause ulcer of the cornea (Coppez).

Diagnosis.—When diphtheria of the conjunctiva is associated with diphtheria of the nose or pharynx, the diagnosis is easily made. However, primary diphtheria of the conjunctiva may occur and may be confounded with gonorrhea of the conjunctiva, or even with mucopurulent conjunctivitis in rare cases. The bacteriological examination by means of the microscope and by cultivation will serve to establish the diagnosis.

Treatment.—As soon as it is known that diphtheria of the conjunctiva exists, the patient should be given a hypodermic injection of 2500 to 5000 units of diphtheria antitoxin, making the injections either in the loose tissue in the sides of the abdomen or in the loose tissues of the back. If the pseudomembrane does not begin to soften at the end of twenty-four hours, a second injection of 1500 to 5000 units of the antitoxin may be given.

Cold applications, if they mitigate symptoms, may be made as in gonorrheal conjunctivitis. As soon as the pseudomembrane is removed, nitrate of silver may be applied once daily in the strength of 0.5 to 1 per cent. The eye should be cleansed every hour with a saturated solution of boric acid, a weak solution of potassium permanganate, salicylic acid, or bichloride of mercury. Peroxide of hydrogen is of service in the removal of the membrane, if for any reason this is thought advisable. It does no good to remove the pseudomembrane forcibly, unless for the purpose of applying remedies directly to the surface of the conjunctiva (even then it is of doubtful expediency), as the membrane quickly reforms.

If sloughing of portions of the conjunctiva occurs, the endeavor must be made to prevent adhesions between opposing surfaces. This may be done by separating the surfaces daily by introducing mercuric chloride (1 to 5000), vaseline, or borated vaseline (5 per cent.) between the surfaces.

Membranous Conjunctivitis.—There is a rare form of conjunctivitis which differs decidedly clinically from the ordinary form of diphtheritic conjunctivitis, which is apparently due, in the majority of the cases at least, to the presence of the Klebs-Loeffler bacillus and the streptococcus pyogenes. It occurs most frequently in children, but adults are not exempt. At the beginning the lids are only slightly swollen and red, there is excessive lachrymation and some mucopurulent secretion, the conjunctiva is slightly thickened. On everting the upper lid a pseudomembrane is found, which extends into the fornix. It is usually not very thick. It can be removed without exerting much force, and on removal discloses a mucous membrane that bleeds only very slightly; it is not deeply injected, nor does it exhibit the characteristics of very active inflammation. The pseudomembrane promptly reforms after removal, and may continue to reform indefinitely. Although commonly affecting both eyes, it is sometimes confined to one eye. The individual suffers but little pain; there is but slight photophobia. In a number of the cases recovery occurs in from three to five weeks; but in some cases the pseudomembrane persists for as many months in spite of all treatment.

Etiology.—In a number of the cases Klebs-Loeffler bacillus is found. hese cases respond readily to treatment. In a few cases the strepto-

coccus is found; these cases are very persistent. The affection may be associated with dacryocystitis; it may occur as an accompaniment of measles, scarlet fever, and influenza (de Schweinitz). The *prognosis* is unfavorable as to vision, and in some cases unfavorable as to life. Membranous conjunctivitis may accompany impetigo (Morax).

The staphylococcus and the pneumococcus, as well as the micro-organisms already referred to, have been found in the secretion in these cases, probably being accidental.

Diagnosis.—When pseudomembrane occurs in the conjunctiva it is not always possible to determine the cause. The bacteriological examination will suffice in a number of cases, and the history of the case will determine others.

Treatment.—Membranous conjunctivitis may also accompany the eruptive fevers and may also be due to burns and injury; it disappears in these cases when the constitutional disease is recovered from, or when the effect of the burn or injury has passed away.

In some of the indeterminate forms, which are exceptionally rare, treatment seems to have little influence. The diphtheria antitoxins should be given a thorough trial. Cleansing solutions, such as saturated solution of boric acid, salicylic acid (saturated aqueous solution), sublimate (1 to 5000 to 1 to 15,000), permanganate of potash (1 to 5000), and hydrogen peroxide, may be employed to keep the conjunctiva free from secretion. Cold applications in the more acute stage may be used intermittently with benefit. It is seldom beneficial to employ moist heat, except in the latter stages of the affection, when stimulation is found to be necessary.

Antiseptic powders, as iodoform, iodol, aristol, calomel, may be dusted onto the palpebral conjunctiva.

Neighboring disease processes, as dacryocystitis, abscess of lids, eczema, etc., must be properly treated, and the general system should be put in a healthy condition.

Xerosis Epithelialis (*Xerosis Triangularis; Xerosis Infantilis*).—This is characterized by a lustreless, grayish-white, foamy, greasy deposit on the conjunctiva which is not moistened by the tears, and is very persistent. The disease attacks individuals of all ages, except the very old.

Etiology.—A specific bacillus in this disease was first mentioned by Colmiatti,[1] carefully studied by Leber[2] three years later, and termed by him the diplobacillus of xerosis. The bacillus is short and often appears in pairs joined end to end. One of the members is often broader at one end than at the other (clubbed). The cheesy secretion contains multitudes of the bacilli, almost in pure culture. (See table of bacteria, at end of book.) A receptive condition of the system appears to be necessary to permit the development of the disease. When infants are attacked, it is always the marasmatic infant; the robust never. Children and adults always give a history of malnutrition, due to scanty food, with

[1] Cong. periodique inter. d'Ophth. Annexes, 1880.
[2] Graefe's Arch., 1883, Band xxix, iv, S. 225.

scarcity of fresh vegetables and fresh meats. This is the case with those who are confined in barracks, prisons, or who work remote from a base of plentiful food supply, as in mines, or railroads, or on plantations.

Pathology.—Aside from the presence of the bacilli, the superficial epithelial layers undergo fatty degeneration and are cast off. The secretion consists of these degenerated epithelial cells, some leukocytes, and the bacilli. On examining the conjunctival tissue, little change is found except a slight increase in size of blood-vessels, some small-cell infiltration, and the thickened and superficially degenerated epithelial layer.

Symptoms.—In infants the lids become slightly swollen, a thin flaky secretion escapes from the eye. On everting the lids the conjunctiva in the fornices is more or less covered by the characteristic secretion. The secretion may extend over the whole conjunctiva and cornea. Both eyes are affected. In children more than one year of age the secretion may first show itself either on the palpebral or ocular conjunctiva; in adults almost always on the latter, the patch occupying the ocular conjunctiva in the horizontal meridian on both sides of the cornea, usually triangular in shape, the base being next to the margin of the cornea. The sensation to the adult is that of a dry substance on the conjunctiva. One patient spoke of it as his "dry patch." Slight irritation of the conjunctiva is noticeable about the margin of the patch. In children and in adults a condition of *hemeralopia* obtains. The disease is not a local one. In a number of autopsies that have been made the bacillus has been found in the parenchyma of the liver, spleen, kidneys, and pancreas.

Fig. 147

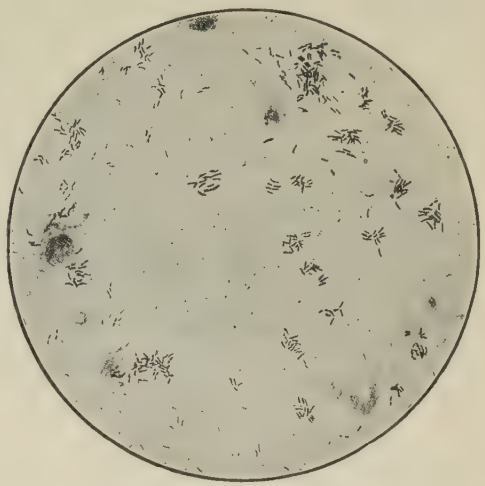

Xerosis bacillus. (Graefe and Saemisch.)

Duration.—In infants this disease lasts until death, which ordinarily occurs in a few weeks or months. In adults the secretion persists for months, and in many cases for years.

Complications.—In infants the cornea is deprived of nutrition and sloughs, producing the condition known as keratomalacia. Infants under one year of age, with few exceptions, die. In children and adults the cornea may become involved, the patches which produce the exudation gradually advancing from the margin of the cornea, or appearing in small islets slowly encroaching on the pupillary area. Years may

pass before the pupillary area is completely covered. Fortunately in the greater number of adults and children the cornea does not become involved.

Diagnosis.—The condition cannot be mistaken for anything else after the clinical picture is known to the surgeon.

Treatment.—In very young infants treatment is of no avail. In children and adults the local treatment consists in the use of antiseptic lotions and washes, and of ointments, such as bichloride vaseline (1 to 5000); the use of powders, calomel, iodoform, aristol, the powders to be dusted on the affected area after the secretion has been scraped off. Thermal cauterization is efficient and may be employed on small areas. Unless the local treatment is supplemented by a nutritious and varied diet, a cure cannot be expected. Suitable tonic remedies must supplement the diet.

Staphylococcus Group.—Staphylococcus pyogenes aureus, Staphylococcus pyogenes citreus, Staphylococcus pyogenes albus. Of the microörganisms in this group, the Staphylococcus pyogenes aureus is the most virulent in a pathogenic and pyogenic sense. All are capable of causing the formation of pus under favorable conditions. The Staphylococcus pyogenes aureus appears to be the active agent in the production of the nodules in eczematous conjunctivitis, and in some cases of mucopurulent conjunctivitis.

Fig. 148



Phlyctenular conjunctivitis.

Eczematous conjunctivitis (phlyctenular conjunctivitis) is characterized by the appearance on the bulbar conjunctiva of one or more small nodular elevations, which are situated at the apex of a triangular leash of vessels, the base of the leash being directed toward the fornix conjunctivæ.

Etiology.—The writer has felt justified in including this affection among those that are caused by a specific microörganism, because of the researches of others, as well as of himself.

If an unbroken phlyctenule be carefully rendered aseptic externally and the contents of the phlyctenule conveyed to a tube of nutrient agar, a cultivation of the staphylococcus will invariably be obtained. The same is true of the nodules of eczema. Similar nodules may be produced by introducing the staphylococci beneath the epithelium in suitable subjects. Pustular blepharitis marginalis and moist eczema are frequently accompanied by phlyctenular conjunctivitis or keratitis, being apparently sources of infection. Phlyctenular conjunctivitis is most frequent in children of the poorer classes who have inherited taints or are tuberculous, suffer from malnutrition accompanied by lymphadenitis, by moist eczema on some part of the body, particularly on the head,

face and ears, eczematous rhinitis, etc. Adults are not exempt, but they are rarely attacked. Occasionally an apparently robust individual is affected. Acute conjunctivitis, the exanthemata, and debilitating illness of any kind predispose to eczematous conjunctivitis.

Pathology.—The elevation or nodule is composed of an accumulation of small cells resting on the basement membrane and causing an elevation of the epithelium. The blood-vessels at the base of the nodules are engorged and enlarged, and there is a scant small-cell infiltration in the surrounding tissues.

Symptoms and Course.—In the early stages small translucent nodules appear at the limbus conjunctivæ or on the bulbar conjunctiva. The bloodvessels of the conjunctiva radiating from the nodule become injected. The nodules may be single or multiple. Soon the contents of the vesicle takes on a yellowish appearance, forming an ulcer, the apex of the nodule softens and disappears. The softening progresses until the nodule has reached the level of the conjunctiva, when the ulcer becomes clean. Epithelium is developed on its surface, and recovery occurs without leaving a scar. Recurrences are the rule. The process from the first stage, the stage of efflorescence (Fuchs), to complete recovery requires eight to fourteen days.

When but one or two nodules are present, the redness of the conjunctiva is partial and is largely confined to the vicinity of the nodule. There is but slight increase in lachrymation and little irritation; no photophobia. When many nodules exist, the redness may extend to the palpebral conjunctiva, the lachrymation and secretion may be much increased, and some photophobia may be experienced.

Diagnosis.—Phlyctenular conjunctivitis may be confounded with herpes of the conjunctiva, pinguecula, lymphangiectasis, and vernal catarrh; the history of the case will serve to make the differential diagnosis.

Treatment.—This should be local and constitutional.

Local.—A cleansing aseptic wash should be used to bathe the eye three or four times daily. An ointment of the yellow oxide of mercury (1 per cent.) should be put into the eye twice daily. After the nodule has been converted into an ulcer, calomel may be dusted over the affected area once daily if the patient is not taking iodides.

Internal.—Suitable tonic remedies should be given. Small and frequently repeated doses of calomel (gr. 0.05 to 0.1, t. i. d.), continued for some weeks if no disturbance of the bowels is occasioned, are of much value. The nasal and pharyngeal mucous membrane should be examined and, if necessary, treated. Adenoids and hypertrophied tonsils frequently accompany this disease; they should receive proper attention.

Staphylococcic Conjunctivitis.—It is the opinion of a number of investigators that primary staphylococcic conjunctivitis seldom occurs, but that in suitable cases in which the conjunctiva has been prepared by previous irritation, mechanical or otherwise, a mild conjunctivitis may be produced by the Staphylococcus aureus. The frequent association of this microörganism with diphtheria of the conjunctiva, gono-

coccic conjunctivitis, and membranous conjunctivitis, points to a secondary or mixed infection, and usually means an increase in severity.

Treatment.—The treatment of forms of conjunctivitis in which the Staphylococcus pyogenes aureus is found is like that for simple conjunctivitis or that of the disease in which it occurs as a mixed infection.

Fig. 149



Staphylococcus pyogenes aureus. (Posey and Wright.)

Tuberculosis of the Conjunctiva.—This may be primary or secondary: primary when it originates in the conjunctiva itself, and secondary when it proceeds from some tuberculous focus in other parts of the body. In primary tuberculosis of the conjunctiva the tubercle bacilli enter the conjunctival tissue through wounds of the conjunctiva, sometimes due to operative procedure. According to Valude, tubercle bacilli cannot penetrate the intact epithelial layer.

Etiology.—Mycobacterium tuberculosis (Koch).

Forms.—There are two forms of onset: (1) The acute form, which is peculiar to primary infection, followed by the development of miliary tubercles; and (2) the subacute form, observed in the extension of tuberculous infection from contiguous tissues.

Acute Form.—In the *first* form of onset, within a week or ten days after the entrance of the bacilli, the conjunctiva in the vicinity of the place of entrance becomes injected, and numerous small nodules—miliary tubercles—resembling trachoma granules, appear. This may occur on the ocular or on the palpebral conjunctiva or both. The

lids become slightly swollen; a not very copious mucopurulent secretion forms; there is some irritation and photophobia. The little nodules rapidly increase in number, and may coalesce in places. Within a few days after the onset the pre-auricular and inferior maxillary glands on the affected side become swollen and may suppurate. The tubercular process may extend to other parts of the body. The disease runs a very protracted course, and may involve the cornea and result in loss of vision. Some rise of temperature accompanies the early stages of this form of onset.

Diagnosis.—This form of tuberculosis may be mistaken for acute trachoma and for Parinaud's conjunctivitis. Its monocular character and the marked involvement of the lymphatics on the affected side will be sufficient to exclude trachoma. An examination of a section of the nodule will disclose the bacilli, differentiating it from Parinaud's disease.

Treatment.—Aside from the very early excision of the affected tissue, little can be done by local treatment. The patient should receive appropriate constitutional treatment and attention to the symptoms as they arise. Injections of tuberculin, particularly the "new tuberculin" of Koch, should be tried. (See chapter on Special Therapeutics.)

Chronic Form.—The *second* form of onset of tuberculosis of the conjunctiva is chronic from the beginning. It is the disease formerly known as *lupus vulgaris,* and is most frequently due to extension from the nasal mucous membrane by way of the lachrymal passages.

Pathology.—The change in the tissue in the first form is such as is found in miliary tuberculosis. In the second form the margin of the ulcer is made up of a small-cell infiltration of the conjunctival tissue, with increase in vascularity. In the tissue of the wall of the ulcer the tubercle bacilli are found.

Symptoms.—This form is characterized by the appearance of an irregular, shallow ulcer on the palpebral or ocular conjunctiva (more frequently on the palpebral conjunctiva), with raised edges, grayish, uneven floors, often presenting granulation tissue. The surrounding conjunctiva is but slightly injected; lids slightly thickened; a small amount of rather thin, flaky mucopus is present; there is little pain, and the disturbance to the patient, except by the presence of the mucus, is slight. The pre-auricular gland on the affected side is enlarged, but there is little tendency to suppuration. An affected area may eventually be occupied in whole or in part by cicatricial tissue. In old cases the conjunctival sacs may be entirely obliterated by the cicatricial process; the cornea may become involved and vision lost. Years may pass with but little change, but the tendency is to slow and steady progress.

Diagnosis.—Tuberculosis of this form may be mistaken for epithelioma, or for chalazia which open on the conjunctival surface. The study of a section of the tissue with the microscope will suffice to make a diagnosis. If, as sometimes occurs, the bacilli are so few that a positive finding is not made, the anterior chamber of a rabbit's eye may be inoculated with a piece of excised tissue, when tubercular iritis will be produced.

Treatment.—Excision of the diseased parts; thorough scraping of the base, and the frequent inspersion of iodoform will produce good results. The ulcerated areas may also be destroyed by means of the cautery. S. Stephenson[1] reports the successful treatment of tuberculosis of the conjunctiva by means of the *x*-rays. Anode 6 to 10 inches from the eye. Exposures ten minutes each, at intervals of three or four days. He predicts that this form of treatment will supplant all others for this affection. The Finsen rays have given good results. Tuberculin may be tried.

Leprosy of the Conjunctiva.—This may occur as a primary infection, but it is secondary to leprosy in other parts of the body in by far the greater number of cases. Morrow[2] cites one case in which a leprous tubercle appeared on the eye and was mistaken for sarcoma. Cutaneous tubercles followed. A sclerosed, anesthetic condition of the

Fig. 150

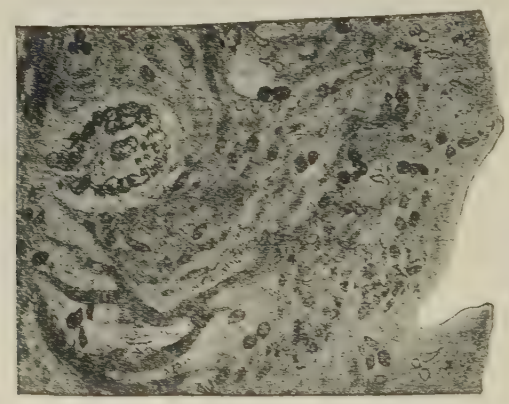

Leprosy bacilli in nodule. (Kolle and Wassermann.)

conjunctiva follows the appearance of leprous nodules. The limbus conjunctivæ is the favorable site for the development of the nodules. Irregular pterygia are sometimes produced. A mild, persistent irritation of the conjunctiva, with slight redness, papilliform elevations, and increased lachrymation have been observed by the writer in cases of leprosy. Fuchs mentions iritis and cyclitis as accompanying leprosy of the ocular conjunctiva and cornea.

Syphilis of the Conjunctiva.—**Etiology.**—Spirochæta pallida (Schaudinn) in all probability.

Forms and Symptoms.—Syphilis manifests itself in a number of forms corresponding with the stage of the disease—chancre, papillary syphilide, copper-colored spots, mucous patches, gummata, nodular syphilides, and syphilitic ulcer.

[1] Brit. Med. Jour., June 6, 1903. [2] System of Diseases of the Skin: Dermatology, vol. iii, p. 587.

Chancre appears most frequently on the tarsal conjunctiva, extending to the margin of the lid, but may occur on the fornix or ocular conjunctiva. It possesses an indurated base, much resembling a piece of parchment. Considerable irritation is produced and a rather profuse mucopurulent secretion develops. The elevated mass sometimes disappears without ulceration, but usually the apex of the chancre softens and breaks down and a shallow ulcer, with indurated sides and base, is present. The *papillary syphilide* is not common. It accompanies papillary syphilides on the face and lids. *Copper-colored* spots are not of common occurrence, but have been observed accompanying the same condition of the skin.

Mucous patches occur in the second and early tertiary stages. They are most commonly seen at the margin of the lid, extending onto the tarsal conjunctiva, but may occur on any part of the membrane. They

Fig. 151

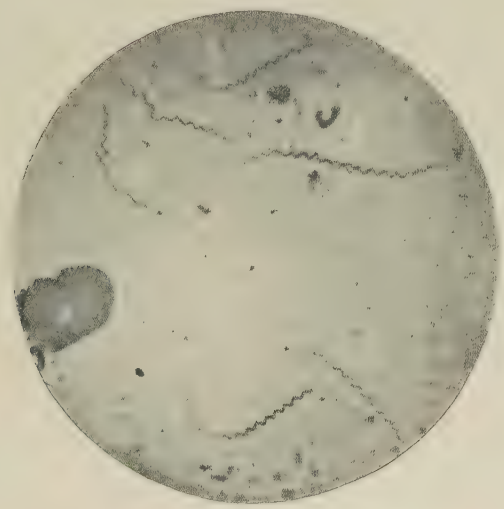

Spirochæta pallida. (Simon.)

are slightly elevated, with an even, grayish, furfuraceous surface. *Gummata* affect the conjunctiva of the lids, or the bulbar conjunctiva near the limbus. They appear as reddish nodules, having a light-colored apex. The base of the gumma is injected. The gumma develops rapidly and involves the underlying structures. If not properly treated it eventually breaks down, producing a deep ulcer, the healing of which is long delayed. It leaves a deep cicatrix. This lesion is usually single. It may be mistaken for sarcoma. *Nodular syphilides* are less destructive and pursue a much less violent course than the gummata. They appear as deep red, sometimes bluish, nodular masses, with little tendency to break down. They may eventually disappear without leaving a trace, except, perhaps, evidence of deep-seated cicatricial tissue. They may break down and form an ulcer. *Syphilitic ulcer* is probably

in all cases the result of the breaking down of a gumma or of a tubercular syphilide.

Prognosis.—If recognized early, the prognosis, with suitable treatment, is favorable in all cases.

Treatment.—Systemic antisyphilitic treatment must be active, sufficient, and long-continued. Locally, the eye should be cleansed frequently with a solution of the bichloride of mercury (1 to 10,000). An ointment of the bichloride of mercury (1 to 4000) in vaseline may be placed in the eye after each cleansing, or at least three times a day. Calomel must not be dusted over the conjunctiva if the patient is taking iodine, as the calomel unites with the iodine contained in the lachrymal fluid, forming the irritating iodide of mercury. Atropine should be instilled if the iris is affected by the process.

Bacterium Coli Conjunctivitis.—This has been observed by Axenfeld[1] and later by Bietti, Zur Nedden, Saemisch, and others. The cases, which are few in number, have, almost without exception, occurred in infants. The conjunctivitis produced is a rather mild purulent form which, according to Axenfeld, is recovered from more rapidly than that due to the gonococcus.

Diagnosis.—Microscopic and cultural examinations are necessary.

Pneumobacillus Conjunctivitis (*Ozena Bacillus* (*Lowenberg*); *Bacillus Mucosus Capsulatus*).—Axenfeld is of the opinion that the pneumobacillus seldom produces conjunctivitis primarily. The cases are sporadic, are mild in character, and respond relatively quickly to treatment. Gourfein reports 23 cases in 450 cases of conjunctivitis observed. It is evident that a favorable condition of the conjunctiva must exist before this form of conjunctivitis can develop. Inoculation experiments thus far have been negative.

Diagnosis.—Microscopic examination is sufficient if the morphological appearances are pronounced, but care must be observed not to confound this microörganism with the diplobacillus, or with the pneumococcus.

Treatment.—As in Koch-Weeks bacillus conjunctivitis.

Bacillus Subtilis Conjunctivitis.—It is doubtful whether Bacillus subtilis alone can produce conjunctivitis. The writer has inoculated a number of conjunctivæ with pure cultures without effect. However, cases of "Bacillus subtilis conjunctivitis" have been reported by Gourfein[2] and a few others. In the greater number of reported cases the Bacillus subtilis has been accompanied by other bacilli, themselves capable of producing conjunctivitis. In wounds of the conjunctiva the Bacillus subtilis may excite a mild conjunctivitis in the vicinity.

Bacillus of Glanders.—Cases have been reported (Strzeminski) in which the bacillus of glanders has found entrance to the general system through the conjunctiva.

Amyloid Disease of Conjunctiva.—This is a very rare affection. It is characterized by the appearance of waxy, translucent, polypoid

[1] Deutsch. med. Woch., 1898, No. 1.

[2] Internat. Oph. Congress, Luzerne, 1904.

masses which commonly spring from the lower fornix, but may involve the entire conjunctiva, converting it into large folds which overlap the cornea and greatly obstruct vision.

Pathology.—The masses are found to be made up largely of lymphoid cells which in parts near the surface undergo a change converting them into a homogeneous mass, which in the greater number of cases give the starch reaction in the presence of the iodine test. Some of the tissue does not give the amyloid reaction, but is of the nature of hyaline. These forms of degeneration are very closely allied, the hyaline sometimes passing into the amyloid form. When the amyloid tissue is most abundant, the translucency of the growth is greatest. Calcareous deposits and the development of bone may take place in the tissue.

Treatment.—Excision of the masses is necessary. Recurrences are the rule. If the bases are treated by superficial cauterization, return is less liable to take place.

Pseudoleukemic Disease of Conjunctiva.—This has been reported by Berl.[1] "The eyelids were thickened by subconjunctival, grayish-red, homogeneous, opaque nodules," which were composed of lymphoid tissue.

Chronic Conjunctivitis (*Chronic Ophthalmia*).—**Etiology.**—A thickened, injected condition of the conjunctiva sometimes follows an acute conjunctivitis; accompanies blepharitis marginalis, in old people particularly; depends on partial or complete closure of the canaliculi, or eversion of the puncta, atrophic or hypertrophic rhinitis. Errors of refraction and muscle anomalies serve to perpetuate such a condition. In old people a flabby, slightly congested, swollen condition of the conjunctiva sometimes exists, associated with enlargement of the caruncle. These cases are almost always accompanied by a slight, mucopurulent discharge.

Treatment.—It consists in correcting all conditions that stand in a causative relation to the conjunctivitis. The nasal and lachrymal passages should receive careful attention. The conjunctiva itself should be brushed with a solution of the nitrate of silver (1 to 2 per cent.) if secretion is present, and should be kept free of secretion by bathing with a simple cleansing solution.

Egyptian Ophthalmia.—This term has been used indiscriminately to describe all forms of ophthalmia that affect large numbers of individuals, especially the forms that appear as epidemics. The term has been made to include acute contagious conjunctivitis, gonorrheal conjunctivitis, and trachoma. The last-named disease has been most generally indicated when the term was employed.

Atrophy of Conjunctiva (*Xerophthalmia*).—This condition, not accompanied by the presence of the xerosis bacillus, occurs in a number of forms.

Forms.—1. Cicatricial, as from trachoma, extensive burns of the conjunctiva from lime or from liquid ammonia. In cicatricial xerosis

[1] Arch. of Oph., xxviii, No. 4.

the ducts of the lachrymal glands are obliterated, and the gland itself atrophies. In addition, the character of the conjunctiva is entirely changed, so that no mucus or other lubricating fluid is secreted from it. The cornea becomes opaque, and vision is reduced to perception of light.

2. Xerosis from constant exposure to the air, as in ectropion and in lagophthalmos. In cases of this kind the exposed conjunctiva and cornea take on a cutaneous appearance; the epithelium becomes thickened, corneous, and dry, a provision on the part of nature to protect the deeper layers from desiccation. In the latter form the remedy lies in the operative procedure necessary for the restoration of a proper protection to the exposed parts.

Toxic Conjunctivitis.—This term is applied to the forms of conjunctival irritations that are caused by the chemical action of certain substances. Of these may be mentioned the mydriatics, the myotics, chrysarobin, calomel, the dust from aniline dyes, bites of insects, caterpillar hairs, dust from hops, fumes from formalin, menthol, etc., intense light, as from the electric arc light, the reflection of sunlight from the snow.

Atropine produces two forms of disturbance:

1. After long use of a non-sterile solution the conjunctiva becomes hyperemic, and follicles develop in the fornix and tarsal conjunctivæ. There is a scanty mucopurulent discharge. The picture is one of mild trachoma in the early stage. The cause of this form of conjunctivitis is probably bacterial infection, the bacteria being carried into the conjunctival sac with the solution.

2. Six to twelve hours after the instillation of a few drops of a solution (the solution may be sterile) of atropine into the eye the lids become swollen and brawny, the conjunctiva injected. There is excessive lachrymation, a sensation of heat, and much irritation. Hyoscyamine duboisin, and homatropine sometimes produce this disturbance also, but in less degree. The effect is thought to be due to idiosyncrasy.

The treatment of the first form consists in discontinuing the atropine, or using sterile solutions; cleansing the eye frequently with a saturated solution of boric acid and using suitable astringents. Of the second form, in discontinuing the use of the atropine. *Eserine solutions* sometimes cause irritation of the conjunctiva.

Chrysarobin, used in the form of an ointment on the skin in psoriasis, may produce violent irritation of the conjunctiva. Calomel, if dusted on the conjunctiva when the patient is taking the iodides, results in local ulceration and intense irritation of the conjunctiva. Fumes from formalin and menthol and dust from aniline dyes produce marked, but transient, irritation. Intense light from snow and from the electric arc light produces irritation and intense photophobia, because of destruction of the superficial conjunctival and corneal epithelial cells, due to the action of the ultraviolet light waves (Widmark).

The bites of insects commonly occur on the lids, and the affection of the conjunctiva, which sometimes becomes greatly edematous, is due to extension of the poison.

Treatment.—All of these forms of conjunctival irritation subside in a few days if the cause is removed and simple cleanliness observed.

Ophthalmia Nodosa (Saemisch).—The presence of caterpillar hairs on the conjunctiva produces a nodular inflammation of the conjunctiva (ophthalmia nodosa), which may extend to the cornea, and even to the iris. The nodules are yellowish, semitranslucent, and have been compared to tubercles. On excising such nodules and examining them under the microscope, Pagenstecher found the hairs of the caterpillar.

Fig. 152

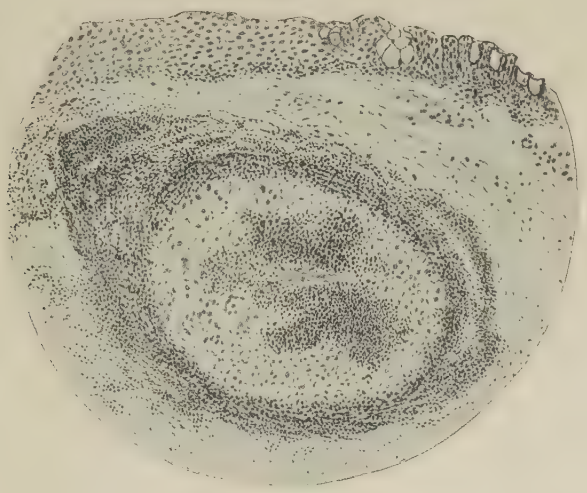

Section through a nodule in ophthalmia nodosa. In the centre, surrounded by leukocytes, the cross-section of a hair is shown. A zone of giant cells and epithelioid cells surrounds them. (Graefe and Saemisch.)

Hop Picker's Conjunctivitis.—Women and children employed in picking hops are, according to Adams,[1] subject to a form of acute conjunctivitis, sometimes accompanied by keratitis and hypopyon, due to the hairs of the bracts and katkins of the plant.

Cocaine Conjunctivitis.—Cocaine, when used in the conjunctiva, produces at first a contraction of the blood-vessels; but, as its effect wears away, there is an engorgement of the vessels, which stimulates and irritates the conjunctiva, producing a mild form of conjunctivitis if long-continued. The addition of cocaine to collyria that are to be used for some days or weeks is not advisable on this account.

Tea-leaf Conjunctivitis.—A poultice of tea leaves is thought by many of the laity to be of benefit in the treatment of acute conjunctivitis. In reality, a tea-leaf poultice greatly aggravates the inflammatory condition, and should never be employed.

Pseudotuberculosis of Conjunctiva.—See Conjunctivitis Nodosa.

Larval Conjunctivitis.—Flies may deposit their eggs in the conjunctival sac; the eggs may hatch out and the larvæ may produce a

[1] Brit. Med. Jour., May, 1893.

decided irritation, resulting in some swelling of the conjunctiva and the production of a mucopurulent secretion. Children are most apt to be affected. The larvæ reside in the lower cul-de-sac, and may be discovered by fully everting the eyelid. The writer has seen two cases.[1]

Treatment.—Thorough removal of the larvæ and irrigation with a bland antiseptic solution.

Abscess of the Conjunctiva.—This is of rare occurrence. It forms in the subconjunctival tissue, and is almost always traumatic.

Treatment.—The treatment should be as of abscesses in other parts of the body.

Ecchymosis of the Conjunctiva (*Subconjunctival Hemorrhage*).—This is due to the escape of blood beneath the conjunctiva, from whatever cause. It may accompany purpura hemorrhagica (scurvy) (of grave import when it occurs in very young children); it may follow rupture of a small vessel due to straining in coughing or sneezing at stool. It is not infrequently seen in children with pertussis. It produces bright or dark red patches, and may affect all but the tarsal conjunctiva.

Treatment.—The blood becomes absorbed slowly. Bathing with hot solutions will hasten absorption.

Chemosis.—This is a condition characterized by swelling and thickening of the ocular conjunctiva, the swelling at the corneal margin forming a raised wall, producing a shallow circular pit, of which the cornea forms the floor.

Pathology.—Chemosis is more than a simple edema in many cases. Particularly is this so when the chemosis is the result of a slow inflammation of the cornea, iris, ciliary body, and chorioid. Section of chemotic tissue in acute cases shows little but a distention of the conjunctival tissue by serous or seroplastic infiltration. But in the subacute or chronic forms there are a dense infiltration of small cells and increase in the connective-tissue elements and in the size and number of the blood-vessels.

Chemosis, except in the subacute or chronic form, subsides on subsidence of the disease to which it is due. If it is so considerable that it obstructs vision, scarification may be resorted to.

Emphysema of Conjunctiva.—This is characterized by puffiness of the conjunctiva, with little injection, and usually with the appearance of small, circular, pale points just beneath the conjunctiva, which indicate the presence of air in the tissue. On pressing the conjunctiva there is a faint crepitation and the circular points change their position.

The condition is due to the entrance of air into the subconjunctival tissue as a result of traumatism, the injury that most frequently produces it being fracture of the lachrymal bone. On blowing the nose violently the air sometimes finds its way into the orbital and subconjunctival tissues, causing them to puff up.

Treatment.—The air in the tissues disappears by absorption in a few days without injury of any kind.

[1] Schultz, Destruction of Both Eyes by Fly Larvæ, Centralb. f. Augen., October 1905, p. 289 to 300.

PLATE XIV

Subconjunctival Hemorrhage.

Siderosis Conjunctivæ.—This has been reported as being due to the prolonged use of sulphate of iron. A yellowish-brown discoloration was the result.

Injuries of Conjunctiva—It frequently happens that foreign bodies enter the conjunctival sacs. These first impinge upon the globe, and are then brushed downward by the upper lid. They may remain in the lower conjunctival pouch, but often are caught on the tarsal conjunctiva of the upper lid. When so lodged they are most commonly found in the shallow groove which lies immediately above the inner angle of the margin of the lid (sulcus marginalis or sulcus tarsalis). It occurs, rarely, that the foreign body lodges in the retrotarsal fold. Slight pressure backward on the globe after the lid is everted will serve to expose this fold, when the foreign body may be seen. Bits of steel are sometimes embedded in the conjunctiva; they may be removed by the ordinary surgical procedures. Grains of powder that are deeply embedded need not be disturbed, as they produce no irritation after the wound made by their entrance has healed.

Wounds.—These may be associated with extensive injuries to the orbit and lids, or may be simple lacerations. Under suitable circumstances they may be cleansed and the margins of the wounds approximated by sutures.

Burns.—Burns are occasioned by the entrance of flames, glowing wood or metal, powder, ashes, steam, hot water, molten metal, acids, alkalies, nitrate of silver, and other substances.

When the burn is occasioned by thermal agencies alone, the treatment should be by means of bland oils or vaseline, to be placed in the conjunctival sac every two or three hours. If molten metal has entered the eye, all of the particles should be removed as early as possible and the treatment as above outlined instituted. Burns from *x*-rays have been reported; they are extremely infrequent. Sherer[1] reports a case. The patient had been exposed to the *x*-rays almost every day for three years.

Burns from *acids*, if recent, should be treated by means of a weak alkaline solution (bicarbonate of soda, sodium hydrate, or very dilute ammonia); subsequently the conjunctiva may be well washed with water, and the oils then employed.

Burns from lime should be treated by first removing all particles of lime or mortar by means of forceps or cotton pledgets, then by washing thoroughly with oil and subsequently dropping in simple syrup made from cane sugar, as this forms an insoluble combination with lime. Oil or vaseline, perhaps medicated with boric acid (5 per cent.), may then be used until healing has taken place.

Burns from acids are followed very rapidly by swelling of the conjunctiva, with possibly some haziness of the cornea, and a flaky, mucopurulent discharge; but the prognosis from these burns is good, except in severe cases.

Burns from lime and ammonia present a pale condition of the con-

[1] N. Y. Med. Jour., September 21, 1901.

junctiva, and usually a white eschar where the caustic has come in direct contact with the tissue, or where the effect has been concentrated, the cornea may be slightly hazy. The prognosis is usually worse than at first supposed.

The result to be feared in burns of the conjunctiva is symblepharon. To prevent this the surfaces must be separated daily by means of a probe, and oil interposed. If the burn is extensive, a pledget of gauze or pad of cotton dipped in oil may be interposed and kept between the opposing burned surfaces. A shell of glass or of lead may be worn to prevent symblepharon. In severe cases all measures to prevent symblepharon fail.

Symblepharon.—Cicatricial union of the palpebral to the bulbar conjunctiva is termed symblepharon. It occurs after burns, injuries, some operative procedures, and as a result of purulent conjunctivitis, pemphigus and trachoma. The bands of cicatricial tissue may extend onto the cornea. If the union between the lids and globe is complete the condition is termed *total symblepharon.* If the union extends from the bottom of the fornix, partially uniting the ocular and palpebral conjunctivæ, it is termed *posterior symblepharon.* If the margin of the lid only is affected, it is known as *anterior symblepharon.* If the union is in the form of a radial band, it is termed *frenular* or *columnar* symblepharon. Obliteration of the conjunctival sacs from atrophy of the conjunctiva, as occurs in the third stage of trachoma, although a somewhat similar condition, cannot be termed symblepharon. The lower conjunctival sac, because of its position, suffers much more frequently than the upper.

Fig. 153

Symblepharon.

Treatment.—Surgical (see chapter on Operations).

Argyria (Argyrosis) Conjunctivæ.—Long-continued use of the nitrate of silver on the conjunctiva produces a discoloration of the mucous membrane, due to the deposition of the carbonate or albuminate of silver in the tissue of the conjunctiva (elastic fibers, Fuchs). This stain varies in color from a light ochre to a very dark brown. The stain is indelible. A solution of the hyposulphate of sodium or of potassium iodide in the strength of one to ten in water has been suggested for the removal of the stains. In some cases the conjunctiva becomes atonic and apparently hypertrophied, redundant folds forming. In such cases the patient is rendered uncomfortable by the redundancy of tissue. This may be remedied by excising the superfluous mucous membrane.

Pinguecula.—In many individuals who have been exposed to much dust or high winds there appears in the ocular conjunctiva, on the nasal side of the cornea, later on the temporal side of the cornea, both in the horizontal meridian, a small yellowish elevation measuring 2 or 3 millimeters in diameter. This small tumor is at first movable on the

sclera. It consists of a thickening of the conjunctiva, particularly in an increase of the elastic fibers, and the deposition of numerous minute hyaline particles. The yellow elastic tissue and the hyaline bodies give it the yellow color. If the tumor causes annoyance by its appearance or by becoming inflamed, it may be removed by excision.

Fig. 154



Pterygium.

Pterygium (a wing).—Pterygia may be classed as *regular* and *irregular*. The regular form of pterygium consists of a triangular fold of mucous membrane, occurring on the ocular conjunctiva in the horizontal meridian, its base being at the canthus, its apex at the margin of or on the cornea. The portion on the cornea is termed the head; at the limbus, the neck; and on the ocular conjunctiva, the body. The blood-vessels enter at the base, diminish in size, and converge at the apex. Pterygium occurs in individuals of middle and advanced life, most frequently developing on the nasal side of the cornea. They may appear on the temporal side subsequently, or may develop on both sides of the cornea at the same time.

Pterygium may be either progressive or stationary.

Progressive Pterygium.—In this form the fold of mucous membrane has a fleshy appearance, and its vessels are pronounced. The apex of the growth is preceded by a grayish zone, one to one and a half millimeters wide, which is very slightly raised at the margin of the apex of the growth.

Non-progressive Pterygium.—In this the growth is pale, flat, and the grayish zone in the cornea is narrow and flat or slightly sunken, appearing like a cicatrix.

Pterygium may advance until it passes the pupil; it may stop at any point on the cornea short of this.

Regular Pterygium.—Regular pterygium is undoubtedly due to the irritation of the conjunctiva in its most exposed part, corresponding with the palpebral fissure, by particles of dust and various minute bodies that impinge on the ocular conjunctiva. This irritation first results in the formation of pinguecula; extending it produces pterygium.

Irregular or Pseudopterygium.—This is the result of burns or ulcers of the cornea. It may occur at any part of the periphery of the cornea. It has the same general shape as the regular pterygium, but the apex is often very irregular in contour, taking on the shape of the margin of the ulcer farthest removed from the limbus conjunctivæ. The pterygium never progresses beyond the margin of the ulcer.

Pterygium is prone to become inflamed, because of the lodgement of noxious germs or irritating particles in the folds of the mucous membrane. These inflammations may lead to ulcer of the conjunctiva, ulcer of the cornea, and serious damage to vision.

Diagnosis.—Pterygium cannot well be mistaken for anything else.

Prognosis.—Pterygium affects the vision by producing astigmatism before the head has reached the pupillary area, and should be removed before it advances onto the cornea.

Treatment.—Dionin tends to reduce greatly the volume of pterygium. It may be used in solution or in powder, applied once daily for a few days, an interval of a few days allowed, and again applied as before. The cautery may be used to destroy the head of the growth or to cut off its nutrition by making one or two deep grooves across the neck of the pterygium. (For the surgical treatment of pterygium, see chapter on Operations.)

Lymphangiectasis.—This consists in dilatation of some of the lymph channels, usually of the ocular conjunctiva. It appears as small, slightly elevated, transparent vesicles, usually associated in chains, very superficially situated in the outer or inner half of the bulbar conjunctiva. The vesicles are irregular in shape and vary much in size, seldom exceeding a diameter of three millimeters. The vesicles may be readily moved over the underlying tissue. They sometimes produce irritation, and are accompanied by congestion of the conjunctiva in which they lie, but are not, as a rule, a source of pain. The vesicles are due to interference with the lymph stream by obstruction. Elderly individuals are more frequently affected than young individuals.

Treatment.—The vesicles may be excised, or they may be very satisfactorily destroyed by means of the fine galvanocautery point.

Vascular Growths.—They are seldom primary in the conjunctiva, but are commonly extensions from the tissues of the lids. They appear as arterial growths, when they are of a bright red color, slightly elevated; as venous growths (cavernous angioma), located deep in the conjunctiva, dark purple in color; or as telangiectatic growths—bright red patches in the conjunctiva. All these conditions may be present in the same growth. Vascular growths are congenital. They tend to increase in size. Early removal is advisable. (See Removal of Vascular Tissues of the Lids.)

Polypi.—The occurrence of polypi on the conjunctiva is probably always associated with ulcerative processes of a more or less chronic nature in the conjunctiva.

Etiology.—Wounds of the conjunctiva that do not properly close, syphilitic or tubercular ulcers, sinuses from chalazia opening onto the

conjunctival surface, sinuses from areas of orbital necrosis—all may give rise to the development of polypi. The irritation from wearing an artificial eye may result in the development of polypi.

Pathology.—Polypi of the conjunctiva are composed of myxomatous tissue, with more or less small-cell infiltration, according to the degree of irritation.

Treatment.—Removal and correction of the conditions favoring their formation.

Benign Tumors.—Those that develop primarily in the conjunctiva are adenoma, fibroma, granuloma, lipoma, myxoma, osteoma, papilloma, simple cystic tumors, and those due to cysticerci and echinococci.

Adenoma.—Adenoma occurs rarely as an extension from the tarsus, or as a development from lachrymal glandular tissue, or from the caruncle.

Epithelial Plaques.—These appear on the bulbar conjunctiva, usually in individuals of advanced years. They present as dull white, slightly raised, smooth masses near the corneal margin. They may be single or multiple. There are no signs of irritation. Microscopically they consist in greater part of epithelium.

Treatment.—They may be excised, but, as a rule, give no annoyance and require no treatment.

Xanthelasma.—This is sometimes met with in the ocular conjunctiva. It occurs as irregular, slightly raised yellowish plaques, usually at the margin of the cornea in the horizontal meridian.

Fibroma.—Fibromata are usually the result of chronic conjunctivitis, particularly of vernal catarrh. They appear as small, flattened, often pedunculated bodies on the tarsal conjunctiva.

Granuloma.—This develops from the base of an ulcer and from wounds.

Lipoma.—This occurs in the fornix, in the shape of a soft yellowish mass.

Myxoma.—Polypus is the most common form.

Osteoma.—This is of extremely rare occurrence. It develops as a flat tumor in the ocular conjunctiva at the temporal side of the cornea. The bone is usually deposited in a mass of fibrolipomatous tissue.

Papilloma.—Tumors of this nature exist as small multiple papillæ, forming soft, pale pink, villous masses. They may develop from any part of the ocular or palpebral conjunctiva, but are seen most commonly on or near the caruncle. Papilloma is not infrequently mistaken for granulation tissue. To avoid recurrence, removal must be thorough.

Simple Cystic Tumors.—Simple cystic tumors appear in the palpebral conjunctiva after chronic conjunctivitis; after plastic operations on the conjunctiva, and after operations on the ocular muscles. They usually form as a result of the invagination of epithelium.

Treatment.—Excision.

Entozoa Cysts.—Cysts due to entozoa are very rare.

Cysticercus Cysts.—Cysticercus cysts are small; if the walls are thin, the head is visible as a white spot at some part of the cyst. They are

easily removed by splitting the conjunctiva over the cyst and turning the cyst, with its thin capsule of connective tissue, out of the wound.

Echinococcus Cysts.—Echinococcus cysts are large. They develop slowly, and may extend into the orbit and produce marked exophthalmos. Daughter cysts and hooklets may be found as part of the contents of the cyst.

Malignant Tumors—Epithelioma and sarcoma are the most common. Russell describes a rare growth known as cylindroma. It is probably a form of sarcoma.

Epithelioma.—Epithelioma affecting the conjunctiva is much more frequently secondary than primary, that is, an extension of a growth originating in the lids. When it is primary it springs from the limbus and extends on to the cornea. It is of slow growth, appearing as a slightly raised patch with a roughened grayish surface.

Sarcoma.—Sarcoma, primary in the conjunctiva, is almost always pigmented. It occurs where pigment is often normally present, at the limbus, where it is more frequently met with, and in the conjunctiva of the lids. It has been observed at the caruncle. Sarcoma of the conjunctiva may remain quiescent for years, suddenly take on activity, and reach a fatal termination in a short time. Metastasis to the preauricular and cervical glands and to remote parts of the body may occur. Pigmented patches occurring at the limbus conjunctivæ should either be excised at once or carefully observed and excised as soon as increase in size is manifest.

Treatment.—Excision, thorough and complete, is the only treatment that is of any value.

Endothelioma.—Tumors, the cells of which are of the endothelial type, are sometimes found in the conjunctiva.

Lupus Erythematosus.—When it affects the conjunctiva, it appears as small, irregular plaques covered by grayish masses of exudation and superficial cicatrices, sometimes with punctate excoriations. Lupus erythematosus of the face accompanies this affection of the conjunctiva. The disease progresses slowly, and is accompanied by slight irritation and increased lachrymation.

Etiology.—Is not well understood.

Diagnosis.—When disease of the face accompanies that of the conjunctiva the diagnosis is not difficult.

Treatment.—Exposure to x-rays appears to be of value.

Acne of the Conjunctiva.—This condition sometimes accompanies acne indurata of the face. The ocular conjunctiva is usually affected. The condition resembles phlyctenular conjunctivitis quite closely.

Caruncle.—The small mass of tissue (island of modified skin, Waldeyer) which lies in the horseshoe-like space, the lachrymal lake, at the inner canthus, is known as the caruncle. It is covered by mucous membrane. Its surface is uneven and presents the openings of a number of ducts. It frequently bears a number of small, light-colored hairs. In the connective-tissue stroma are found some striated and a few

non-striated muscle fibers, sebaceous and modified sweat glands and hair bulbs, with their associated sebaceous glands.

Affections of the Caruncle.—In all general inflammation of the conjunctiva the caruncle is enlarged. It may also be enlarged by local inflammatory processes. Enlargement of the caruncle is termed encanthus, *benign* when associated with benign processes, *malignant*, when associated with destructive processes. Excessive development of hairs on the caruncle is sometimes observed. This condition is termed *trichosis carunculæ*. The caruncle is sometimes irritated by the impinging of misplaced and abnormally developed hair from the margin of the lids.

Abscess of the caruncle sometimes develops; it usually opens spontaneously. If this does not occur early, incision may be practised.

Foreign bodies may lodge in or under the margin of the caruncle and occasion irritation.

Tumors of many kinds may affect the caruncle—papilloma, which resembles papilloma of the conjunctiva, adenoma, primary sarcoma, angiosarcoma, lymphosarcoma, carcinoma, dermoid tumors, fibroma, angioma, lymphangioma, tuberculosis. Chalky deposits may form in the glands of the caruncle. Cystoid enlargement and degeneration have been observed.

Swollen and congested caruncles are seen in individuals suffering from eye strain, particularly "in cases with imperfect amplitude of convergence." The conjunctiva at the inner canthus, as well as the caruncle, is red and angry looking; the patient complains of a "pricking" pain on prolonged use of the eyes. De Schweinitz suggests the name of symptomatic or functional encanthus for this condition.

Treatment.—Foreign bodies, hairs, etc., should be removed. When excessively enlarged or the seat of a growth, the caruncle may be excised.

CHAPTER VIII.

THE CORNEA.

DISEASES OF THE CORNEA.

THE term *keratitis* is employed to designate all inflammatory processes affecting the cornea.

Histological Considerations.—Regeneration of Corneal Tissue.—It is at present conceded that the regeneration of corneal tissue proceeds from cells that migrate into the corneal tissue and from the fixed cells of the cornea, principally from the latter. When regression of a corneal ulcer has commenced, formative elements are found at the edge of the ulcer which gradually develop into connective-tissue fibers, and this process continues until the defect in the cornea is filled up by the new-formed tissue. The new fibers are not arranged in lamellæ, nor are they disposed parallel to the surface of the cornea. This irregularity of the disposition of the fibers causes a loss in transparency. As an ulcer of the cornea heals, the surface becomes covered with epithelium before the defect has been filled up by the deposition of the new-formed tissue. When the surface is still devoid of epithelium, it has much the appearance of ground glass. After the epithelium has been restored the surface is smooth and glistening, but may be irregular. The development of new-formed tissue continues until eventually the epithelial layer is raised to its normal height. In a certain proportion of cases the complete filling of the defect does not take place. The area involved in the ulcerative process in these cases is often flat, forming what are known as *facets*. Bowman's membrane is never regenerated. The new-formed tissue, if it occupy the cornea to some depth, becomes eventually white in appearance. If the new-formed tissue consists of a very thin layer, it presents a pearly white appearance. This opaque tissue tends to become more transparent as the age of the scar increases.

Hypopyon.—In all pronounced cases of corneal ulcer the anterior segment of the vascular coat of the eye (iris and ciliary body) is more or less irritated. As a result exudation from the vessels ensues. The aqueous humor becomes more albuminous and fibrin forms. Some fibrin is deposited on the posterior surface of the cornea and often on the other surfaces in contact with the aqueous humor. Ift he irritation is sufficient, leukocytes escape from the vessels of the iris and ciliary body and enter the anterior chamber. There they gravitate to the bottom of the anterior chamber. If sufficient fibrin is present, the leukocytes become embedded, forming a pultaceous mass which

PLATE XV

FIG. 1

Irregular Pterygium.

FIG. 2

Lymphangiectasis.

does not change its position on change of the position of the head. In absence of sufficient fibrin the collection remains fluid and changes its position as the position of the head is changed. The mass is yellow in color and resembles pus. It really contains no pathogenic germs and is innocuous. Its presence constitutes hypopyon. The superior border of the hypopyon is often slightly convex. On looking obliquely into the anterior chamber it will be seen that the exudate constituting the hypopyon is deposited chiefly on the posterior surface of the cornea, the surface of the iris being free to a considerable distance below the upper margin of the deposit.

The researches of Leber make it evident that the presence of the leukocytes and fibrin is an attempt on the part of nature to aid in preventing destruction of the corneal tissue. Many of the leukocytes penetrate into the corneal tissue by way of Fontana's spaces and proceed to the vicinity of the ulcer. The excess remains in the anterior chamber, and there forms the collection just described. Older observers, noting the convex upper border of the mass of exudation in the anterior chamber and the fact that the iris was free, supposed that the collection of pus was between the lamellæ of the cornea and, because of the resemblance to the lunula of the finger nail, termed it unguis or onyx (nail). The presence of hypopyon in itself calls for no particular treatment. With a subsidence of the disease which calls it into existence, it disappears by absorption, sometimes slowly, sometimes rapidly. It may disappear and reappear. It may vary in amount from day to day.

Classification.—Diseases of the cornea may be considered under two headings, suppurative and non-suppurative.

Suppurative Keratitis.—To this form belong all varieties of ulcer of the cornea.

Ulcers of the Cornea.—Ulcers are variously classified. In regard to their development, they are *primary*, beginning in the cornea itself, or *secondary*, an extension of the process from the conjunctiva or from contiguous tissues into the cornea. In regard to position, they are *marginal* or *central*. As to involvement of tissue, they are *superficial*, *deep*, or *perforating*. As to shape, they are *circular*, *crescentic*, *punctate*, *dendritiform*, *filamentous*, *irregular*, and *undermined*. In character they are *simple* or *infected*. In regard to the stage of development, they are *progressive or regressive*.

Ulcers of the cornea present certain symptoms in common. In all there is loss of corneal substance and more or less opacity of the cornea at the site of the ulcer and in its vicinity. Photophobia and pain are present in all but the neuroparalytic form. Impairment of vision occurs in all cases in which the pupillary area is involved. Pericorneal injection, partial or complete, with more or less secretion, is always present.

Eczematous Keratitis (*Phlyctenular Keratitis; Scrofulous Keratitis; Lymphatic Keratitis*).—This affection is characterized by the appearance of small translucent nodules on the cornea, usually at the

margin. In a day or two the nodule acquires a yellowish color; the apex disappears and a superficial ulcer results. The ocular conjunctiva in the region of the lesion is congested. The small ulcer or ulcers heal (Fig. 155).

Etiology.—The cause and the pathology, except in regard to the affection of the tissues of the cornea, is the same as in eczematous conjunctivitis. The disease is met with most frequently in children between the ages of two and twelve years, but may appear in adults. It seldom occurs after the age of forty. Eczematous keratitis may be primary, but it is more frequently secondary to eczema of the conjunctiva.

Fig. 155

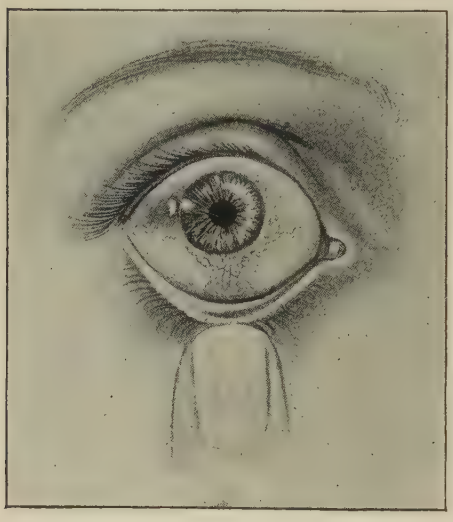

Eczematous (phlyctenular) keratitis. (Dalrymple.)

In many of the patients with eczematous (phlyctenular) keratitis, obstructive rhinitis and adenoid tissue in the vault of the pharynx are found.

Symptoms.—Quite severe irritation, as of a foreign body in the eye, pain of a neuralgic type, often extending to the orbit and temple, profuse lachrymation, photophobia, which is often intense, causing clonic blepharospasm in the milder cases and tonic blepharospasm in the severe cases. In some cases the photophobia is so intense that the patient cannot be induced to open the eyes, even in a moderately lighted room, but avoids the light in every way possible. The intense photophobia is due to irritation of the terminal sensory nerve filaments which are so richly supplied to the corneal epithelium. On forcibly opening the eyes there is often a gush of lachrymal fluid mixed with some flakes of pus. There is hyperemia of the ocular conjunctiva, particularly in the vicinity of the lesion.

Course and Results.—The lesions may form at the margin of the cornea only, may be distributed over the surface of the cornea, or may produce peculiar figures. The ulcer involves the superficial lamellæ of the cornea and leaves a faint opacity when it heals, due to the presence of a thin layer of cicatricial tissue. The phlyctenulæ may have been so numerous and have covered the cornea so completely that the opacities may cover the greater portion of the cornea, producing the so-called phlyctenular pannus. The small ulcer may become secondarily infected and lead to perforation, and in some cases to extensive destruction of the cornea.

PLATE XVI

Hypopyon Keratitis.

Fascicular (Snail's Track or Frenular) Keratitis.—A peculiar form of eczematous keratitis is that known as fascicular, snail's track or frenular, keratitis (Fig. 156). This is characterized by the formation of successive phlyctenulæ, one appearing directly in advance of its predecessor, the process beginning at the margin of the cornea. The phlyctenule at the apex is connected with the conjunctiva by a leash of vessels which lie in the track of the disease. The process often extends far onto the cornea and forms a curved track. On subsiding, an opaque stripe is left, which has been termed the *scrofulous band.*

Fig. 156

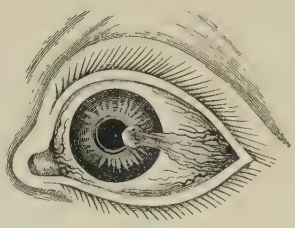

Fascicular keratitis. (Travers.)

Diagnosis.—Eczematous keratitis may be confounded with herpes of the cornea and tubercular keratitis, and the pannus resulting in severe cases, with syphilitic interstitial keratitis; but the history of the case will suffice to enable the physician to differentiate between them.

Prognosis.—This is favorable in nearly all cases. A phlyctenule develops, and healing takes place ordinarily in from five to fourteen days. The resulting ulcer may remain much longer. Successive crops of nodules may appear, causing the affection to last a number of months. Recurrences are the rule.

Treatment.—Local and constitutional treatment must be employed. It is often difficult to inspect the cornea on account of the photophobia and blepharospasm. If a drop of a solution of cocaine be instilled, the photophobia and blepharospasm will be much relieved. It is necessary with some children to place the head between the physician's knees before attempting to expose the cornea; a lid retractor is often required. The cornea is sometimes hidden under the upper lid, and it is necessary to wait with the lid retracted for the cornea to gradually come into view. In severe cases a little ether or chloroform may be given to facilitate the examination.

The eye should be bathed or douched three or four times a day with a solution of boric acid. Atropine may be instilled sufficiently often to keep the pupil dilated. If the phlyctenule has broken down, calomel may be dusted on the cornea once daily. An ointment of the yellow oxide of mercury (1 to 2 per cent. in vaseline) may be put into the eye three times daily. Fissure of the outer commissure often exists in these cases. The blepharospasm may be relieved to some extent by touching the fissure with the nitrate-of-silver stick or with the crystal of the sulphate of copper (Koller). Postnasal growths and obstructive rhinitis should receive appropriate treatment.

Systemic treatment, which is of much importance, is as for eczema of the conjunctiva (see page 245).

In fascicular keratitis the cure can be hastened by cutting the leash

of vessels at the sclerocorneal margin by means of a sharp spud (partial peritomy). In severe cases the peritomy may be made complete.

Simple Ulcer.—Simple ulcer of the cornea is one that does not tend to advance. It may possess a grayish base, but it is often clear and clean. It tends to heal rapidly. The ulcer is usually circular, but may be irregular in form.

Fig. 157

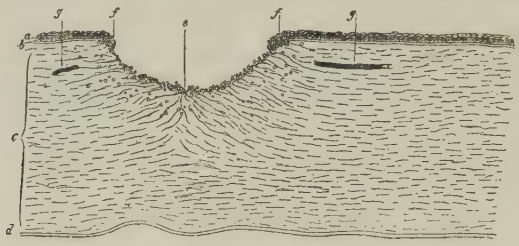

Corneal ulcer: *a*, epithelium; *b*, Bowman's membrane; *c*, substantia propria; *d*, Descemet's membrane; *e*, floor of ulcer; *f*, margins of ulcer; *g*, blood-vessels. (Saemisch.)

Etiology.—Simple ulcer is uusally traumatic, but the term is also applied to those forms of infected ulcer in which the progress is speedily arrested.

Treatment.—Cleanliness, with perhaps the use of boric acid solution, or a solution of the bichloride of mercury, 1 to 10,000, is all that is required.

Infected Ulcer.—The term "infected ulcer" is applied to ulcers which are due to invasion of the cornea by pyogenic or pathogenic micro-organisms, the Staphylococcus pyogenes aureus, streptococcus, pneumococcus, etc. All infected ulcers are associated with an infiltration of the corneal tissue, which extends to a greater or less degree from the margin of the ulcer. Infected ulcers may be marginal or central, circular or crescentic, irregular and undermined in form, and pursue a course dependent upon the nature of the microörganism that has invaded the tissue, on the location, and on the condition of the corneal tissue in regard to its resistance to the influence of the bacterium.

Fig. 158

Marginal ulcer.

Marginal Keratitis.—This form is usually applied to the keratitis that accompanies eczema of the conjunctiva which has been described under the heading of eczematous keratitis (see page 263). Another form of marginal keratitis is that which appears in the shape of a long crescent, involving from one-fifth to two-thirds of the circumference of the cornea, sometimes the entire circumference of the cornea, and to which the term *crescentic ulcer* is applied.

Etiology.—The microörganisms that have been found in marginal and crescentic ulcers are the Streptococcus pyogenes aureus, the bacillus ulceris corneæ (Zur Nedden's bacillus), the diplobacillus (Morax-Axenfeld), pneumococcus, and the diphtheria bacillus (Klebs-Loeffler).

Fig. 159

Bacillus ulceris corneæ. (After Zur Nedden.)

Ulcer Due to the Bacillus Ulceris Corneæ.—**Etiology.**—Zur Nedden[1] reported his observations in the study of ulcer of the cornea, and announced that he had found a bacillus which was constant in a certain form of mild corneal ulcer, considered by him to be the cause of the corneal ulceration. He termed the bacillus the bacillus ulceris corneæ (Fig. 159). The lesion produced is generally in the form of a crescentic ulcer (Fig. 160). It is not necessarily preceded or accompanied by

Fig. 160

Crescentic ulcer. (Zur Nedden.)

conjunctivitis. The affection is usually monocular, but both eyes may be involved. Adults of advanced years are most frequently attacked. This form of ulcer of the cornea is not very common. Zur Nedden reports having seen 65 cases in four years at the clinic in Bonn. Macnab (London), Paul (Breslau), and Morax (Paris) have observed the bacillus of Zur Nedden in similar cases.

[1] Graefe's Arch., vol. lxiv, p. 1.

Description.—The cornea becomes dull and slightly gray near the limbus and superficial loss of substance of punctate or crescentic form occurs. Small, punctate, grayish spots may extend from the horns of the crescent, being separated from or connected with the superficial infiltrated area of the ulcer. The epithelium may be slightly raised over these punctate spots or may be lost, a small ulcer taking its place. These may coalesce with the primary ulcer. The infiltration and loss of substance may extend toward the centre of the cornea. The floor of the ulcer is gray, but not very dense. The edges are clearly defined and irregular. The anterior chamber is often slightly cloudy. Mild iritis and hypopyon may be present.

Symptoms.—These are not very severe; slight photophobia, increased lachrymation, and some flaky mucopurulent secretion. The conjunctiva may be injected and thickened to some degree. Irritation, as of a foreign body in the eye, is experienced, and some neuralgic pain, referable to the brow and temple, may be present.

Diagnosis.—This is suggested by the appearance. The early stage may resemble a beginning interstitial keratitis, but in a few hours or days this resemblance disappears. An examination of the scrapings from the base of the ulcer serves to confirm the diagnosis.

Prognosis.—The course is usually benign. In rare instances in which the patient's vitality is greatly below par, perforation may ensue.

Treatment.—The eye should be cleansed with a solution of boric acid (3 per cent.) four or five times daily. The conjunctiva should be brushed with a 1 per cent. solution of the nitrate of silver once a day. The ulcer should be syringed with a solution of zinc sulphate (gr. ij to ℥j) once daily, and a zinc collyrium of the same strength should be dropped into the eye every three or four hours (McNab). Zur Nedden advised against the use of the cautery as unnecessary. He recommends a solution of the oxycyanate of mercury (1 to 1500) as an antiseptic in this condition.

Diplobacillary Ulceration of the Cornea (Morax-Axenfeld, Petit).—**Etiology.**—The diplobacillus of Morax-Axenfeld and of Petit. The morphology of these bacilli is almost, if not quite, identical. They undoubtedly belong to the same family, but present different cultural characteristics. (See table of bacteria at end of book.) Agricola[1] reports the finding of diplobacilli in 22 cases of corneal ulcer. In 6 cases the bacillus was the Morax-Axenfeld variety, in 10 it was Petit's, in 6 it was undetermined. Of 75 cases of ulcer of the cornea observed by Zur Nedden, 9 were due to the diplobacillus of Morax-Axenfeld, 4 to Petit's bacillus. In 342 cases of diplobacillary conjunctivitis, Erdmann saw corneal ulcer 30 times.

Symptoms.—Ulceration from this cause is invariably accompanied by conjunctivitis. The ulceration does not, as a rule, develop until the conjunctivitis has been present for some time. It is most frequently met with in the severe forms of conjunctivitis, particularly in those

[1] Klin. Monatsbl. f. Augenheilk., 1906, Suppl. 141.

cases of "angular" conjunctivitis in which the erosion of the lids is marked. The corneal lesions are *infiltrations* of varying density occurring most frequently near the margin of the cornea; *marginal ulcers,* resembling those present in some cases of eczematous keratitis, having a tendency to spread superficially toward the centre of the cornea; *shallow ulcers,* with but little infiltration of the cornea, frequently oval and situated concentrically to the margin of the cornea; and *deep ulcers,* sometimes irregular with overhanging margins (undermined) accompanied by iritis and hypopyon.

Diplobacillary ulcers of the cornea do not tend to advance rapidly. All but the severe form heal quite readily. There is a marked tendency to recur. The severe form is accompanied by infiltrated borders. The floor is covered by necrotic, purulent material. The edges may overhang. Perforation may occur.

Diagnosis.—This is to be made from scrapings from the floor or margins of the ulcer examined in smear preparations or by means of cultures.

Differential Diagnosis.—The characteristic differences between this and pneumococcic ulceration of the cornea are set forth in the following table after MacNab, with slight modification.

Infiltrated Diplobacillary Ulcer.	Pneumococcal Ulcer.
History of chronic or recurrent angular conjunctivitis, or marginal blepharitis.	History of "watery eye," and often the presence of a mucocele or nasal-duct stricture.
Generally no mucocele or nasal duct affection.	
Traumatism frequent.	Traumatism generally.
Small and deep.	Large and shallow.
Outline circular.	Outline irregular.
Border not well defined, sometimes undermined, less infiltrated than base.	Densely infiltrated, undermined border advancing in one direction.
Floor irregularly infiltrated.	
Iritis of mild type, not constant.	Iritis varies greatly in intensity.
Hypopyon small, flat upper border.	Hypopyon usually large.
Other gray infiltrates in cornea, often marginal in position.	Rarely other infiltrates. When present, dense, white, round, and rapidly breaking down.
Pain sometimes absent, usually slight.	Pain usually intense; insomnia.
Progress usually slow; rarely more than 3 to 4 mm. in extent after a week's duration.	Progress rapid—whole cornea may be destroyed in a few days.
Diplobacilli in ulcer.	Pneumococci in ulcer.

Treatment.—As the ulcer is secondary to the conjunctival condition, the treatment should be principally directed to the conjunctiva. The zinc salts are specific against the diplobacillus. The sulphate or the chloride of zinc solution (gr. ij to ℥j) is dropped into the conjunctival sac every three or four hours. In all deep ulcers the ulcer should be irrigated before each application of zinc by means of a solution of boric acid or biborate of soda (3 per cent.), using a fine nozzle, and directing the stream into the ulcer. An Anel syringe is well adapted for irrigating the ulcer.

Pneumococcal Ulcer of the Cornea.—**Etiology.**—It has been abundantly proved that by far the most common cause of severe suppurative keratitis is the Pneumococcus lanceolatus (Fraenkel, Weichselbaum).

The important role of the pneumococcus in the production of severe corneal ulcer was first indicated by Gasparini,[1] who, by observations on man and experiments on animals, proved beyond question the pathogenesis of this microörganism in the production of suppurative processes in the cornea and globe. His views have been confirmed by many other investigators, notably Uhthoff and Axenfeld.

Mode of Entrance.—The pneumococcus enters the corneal tissue through an abrasion of the epithelium, the unbroken epithelium being proof against it. The source of the infection may be (1) direct infection

Fig. 161

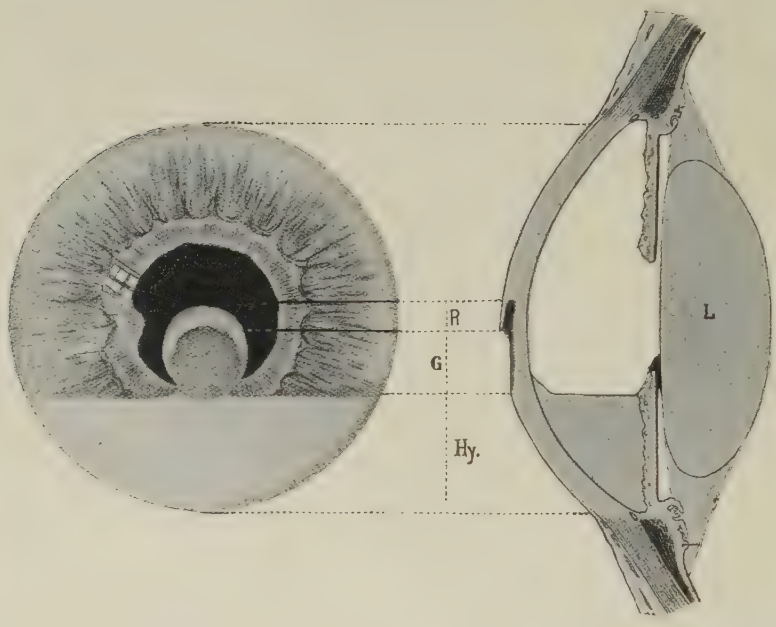

Pneumococcal ulcer: *R*, undermined portion of cornea; *G*, open ulcer; *Hy*, hypopyon. (Axenfeld.)

from an inoculated conjunctiva, mucocele, or chronic dacryocystitis; (2) sputum entering the eye; (3) the foreign body itself may carry the microörganism with it.

Description.—The typical pneumococcal ulcer (serpent ulcer of Saemisch[2]) is characterized by a yellowish, irregular, undermined, elevated, advancing border, which may extend entirely around the ulcer, but more frequently is pronounced on one side, the other side being gray, more shallow, not undermined, and not advancing. The floor of the ulcer is gray, uneven, covered by purulent debris, and

[1] Annal. d'Ophtalm., vol. xxii, 1893.

[2] The term "serpent ulcer," since it is in no way descriptive of the condition, should not be employed.

slopes toward the undermined border. Infiltration of the cornea extends some distance from the advancing border, often in the form of fine gray striæ radiating from the undermined margin. Hypopyon and frequently iritis of greater or less degree are present.

Pneumococcal ulcer is subject to variation (1) depending on the resistance of the tissues to the pneumococcus. When this is great the ulcer is superficial and less active. Augstein is of the opinion that in trachoma we have a condition antagonistic to the development of the pneumococcus. In a number of cases of ulcer of the cornea occurring with trachoma, in which the pneumococcus was found, the ulcers were very mild and did not show virulence. (2) When there is a mixed infection, as with the Staphylococcus pyogenes aureus or the Streptococcus pyogenes, the ulcer is deeper and may pass on to perforation more rapidly. (3) When pneumococcal infection follows operations on the eyeball, as after cataract extraction, the resulting process involves the entire thickness of the cornea. Its shape is determined by the shape of the wound. In the early stage of primary pneumococcal ulcer, a round, grayish opacity appears at or near the centre of the cornea. The superficial layers are soon cast off and the typical appearance is established. The ulcer spreads out, covering large areas of the cornea, the advance being always in the direction of the raised and undermined margin. Adults are more frequently affected than children. It is seldom seen in young children. Of 261 cases observed in Bonn, 230 were above the age of forty years; of 245 in Giessen, 200 were more than forty years of age; in 53 per cent. of the last series dacryocystoblennorrhea was present.

Pathology.—The tissue changes and the location of the microörganisms may be clearly seen by studying sagittal and longitudinal sections of the cornea properly stained. The alteration in the tissue elements is one of necrosis, apparently due more to the ptomaines produced than to the simple presence of the pneumococcus. The pneumococci are found in the parenchyma of the cornea between the lamella, well under the overhanging lip. The changes in the epithelial cells consist in swelling affecting protoplasm and nucleus, vacuolation and breaking down, forming granular detritus. Bowman's membrane swells, becomes indistinctly fibrillar, and disappears. The lamellæ of the cornea swell and break up. There is a dense small-cell infiltration of the tissue surrounding the ulcer, most marked in the direction of the advancing border. The floor of the ulcer is covered by debris of necrotic tissue and by innumerable small cells. Beneath the floor of the ulcer the infiltration extends between a few lamellæ of the substantia propria only. As the floor of the ulcer approaches Descemet's membrane, the endothelium corresponding to the area of the floor becomes swollen and disappears. Descemet's membrane resists the destructive influence of the process longer than other tissues of the cornea. It may bulge into the defect, forming a keratocele, and resist perforation for twenty-four or forty-eight hours.

The infiltrating cells may be derived in part from proliferation of the

fixed corneal cells, but they apparently come in greater part from the marginal blood-vessels and from the iris and ciliary body as a result of the irritation from ptomaines, the cells from the latter source entering by way of Fontana's spaces. The small-cell infiltration is undoubtedly an attempt on the part of nature to protect the tissues. The small cells not only infiltrate the cornea, but are enmeshed in fibrin in the anterior and posterior chambers, forming the hypopyon. They are distributed over the posterior surface of the cornea and surfaces of the iris, also in the tissues of iris and ciliary body to some extent. The hypopyon is sterile before perforation has occurred.

Symptoms.—A slight irritation as of a foreign substance in the eye is first experienced, with little pain. In two or three days the ulcer assumes a typical appearance, associated with congestion of the iris and hypopyon. Continuous, deep-seated, severe pain now develops. The conjunctiva, particularly the ocular conjunctiva, becomes congested, swollen and chemotic. As the ulcer extends the lids may also become swollen.

Diagnosis.—The irregular form, yellowish, raised border confined to, or most marked, on one side, the area of infiltration, grayish lines radiating from the ulcer, more particularly from the raised margin, and the fact that the advancing margin is undermined, as can be demonstrated on examination by means of a small probe (the undermined border permits the entrance of a probe to about 1 mm.), make the diagnosis highly probable. If the floor of the ulcer is quite irregular, with deep pits, and the infiltration dense away from the raised border, the ulcer is not due to the pneumococcus, or the pneumococcus plays a secondary role. Microscopic and cultural examination of scrapings from that portion of the ulcer below the overhanging lip of the advancing border, make the diagnosis positive.

Prognosis.—If not treated, the eye may be lost from extensive destruction of the cornea or by the resulting conditions, staphyloma, anterior phthisis, secondary glaucoma, or panophthalmitis. There are some cases which advance to destruction of the eye in spite of all efforts to arrest the disease. If prompt and radical measures are taken, useful vision may be preserved in the majority of cases.

Treatment.—The indications for treatment are (1) securing and maintaining asepsis; (2) the destruction of the pneumococci; (3) the treatment of accompanying conditions; (4) rendering the tissues unfavorable to the development of the pneumococcus.

1. The conjunctival sac and the ulcer, if not very far advanced, should be thoroughly irrigated with sterile water, boric acid solution, or, better still, a solution of the bichloride of mercury (1 to 10,000 or 1 to 15,000) or of the permanganate of potash (1 to 2000 to 1 to 5000), using it freely (℥viij to xvj). The lachrymal sac should be washed with a bland solution and, after emptying it by pressure, filled with protargol (10 to 15 per cent.) solution. If mucocele or subacute dacryocystitis is present, the lachrymal sac should be extirpated at the earliest convenient moment.

2. Having obtained comparative asepsis in the surrounding parts, radical measures for the destruction of the pneumococcus should be instituted. Under cocaine anesthesia, the ulcer is cleansed and dried by means of an absorbent-cotton swab. The overhanging edge, the comparatively clear floor of the ulcer, and the infiltrated areas will then be clearly seen. The overhanging lip is cut away by means of delicate scissors. The infiltrated areas are gently scraped with a small, sharp curette and cauterized by means of the galvano- or actual cautery, or with pure carbolic, nitric, or glacial acetic acid. If the last three are employed they should be applied by means of a very small, hard, wooden stick in order to control the effect. After cauterizing, the eye may be filled with bichloride vaseline, 1 to 3000, or the following ointment, advised by MacNab, may be employed every two or three hours.

℞—Hydrarg. bichlor.	gr. ss
Iodoform	gr. xj
Atropine (alk.)	gr. ij to viij
Vaseline	ʒ j—M.

The cauterization may be followed by constant hot applications if there is much pain or if it is thought to be desirable for other reasons. If the pain is very severe, asperin or codeine may be given by the mouth, or morphine may be given hypodermically. The conjunctival sac should be irrigated every two hours with a large quantity of mild antiseptic solution. After the irrigation the ointment may be introduced. The writer has found that very satisfactory results are apparently obtained by instilling two or three drops of a solution of argyrol, 25 per cent., into the eye eyerv hour.

3. Accompanying conditions, such as iritis and cyclitis, if present, deserve attention. The pupil must be kept moderately dilated if possible. Atropine in ointment or in solution may be employed. The crystal of the sulphate of atropine may be required and its effect is enhanced by a few drops of adrenalin (1 to 2000). If the intra-ocular tension becomes much increased, it may be relieved by the alternate use of atropine and pilocarpine (1 per cent. solution) or eserine ($\frac{1}{4}$ per cent. solution) every 4 to 6 hours. It may become necessary to permit the aqueous to escape by paracentesis through clear cornea. Repeated paracentesis does no harm.

Römer[1] prepared a serum which he employs as follows: Five cubic centimeters are injected subconjunctivally away from the cornea. The ulcer is dried and the serum is dropped into the eye every two hours. Ten cubic centimeters may be injected into the tissues of the back. The subconjunctival injection is repeated every twelve hours. Römer has also endeavored to increase the "opsonic index" against the pneumococcus by injecting intramuscularly one cubic centimeter of a bouillon culture of dead pneumococci, repeating the injection as he thought necessary. He has obtained excellent results from his method of treat-

[1] Arch. f. Ophth., Band liv, 1, 1902.

ment, but others, with the exception, perhaps, of Mayweg,[1] have not been so fortunate. All that can be said for this serum therapy is that it is still under trial. Cases in the very early stage treated with large doses have given the best results.

The course of the ulcer must be carefully watched, and if it advances the cauterization may be repeated. In cases that are not controlled by other treatment, those which are accompanied by much hypopyon and threaten to perforate, the Saemisch section may be resorted to. This has for its objects the relief of tension, a free opening into the anterior chamber, and the removal of the hypopyon.

Prophylaxis.—Individuals with mucocele and chronic dacryocystitis and those whose eyes are suffused with tears because of everted puncta are in danger of the development of pneumococcal ulcer after any slight injury to the cornea. These conditions should be properly treated. Those individuals who have mucocele or chronic dacryocystitis, and who cannot carry out the longer treatment of cleansing and probing, should submit to excision of the sac.

Atypical Hypopyon Keratitis.—Other bacteria that may produce hypopyon keratitis, which MacNab terms atypical hypopyon keratitis, are (1) Streptococcus pyogenes, (2) Bacillus pyocyaneus, (3) Friedländer's pneumobacillus, (4) Bacterium coli communis, (5) Staphylococcus pyogenes aureus, (6) Rosa hefa, (7) hay bacillus, (8) aspergillus.

Streptococcic Ulcer—The Streptococcus pygenes is conceded to be the cause of ulcer of the cornea in a small percentage of cases. The type is sufficiently well understood to warrant description. It is mostly central, is circular, its borders slightly raised, but not undermined. The ulcer is deep and is filled with a yellowish necrotic mass. The cornea for a short distance around the ulcer is densely infiltrated.

Bacteriology.—The microörganism, which is the Streptococcus pyogenes, is most plentiful in the floor of the ulcer, but may be found in the sides of the ulcer and in the debris that fills it.

Symptoms.—There is severe pain with pronounced swelling and congestion of the conjunctiva with chemosis.

Course.—The progress is usually more rapid than in the pneumococcal ulcer. Perforation, which takes place, as a rule, is preceded by hypopyon. Descemet's membrane may resist the influence of the process for some hours after all of the lamellæ of the substantia propria have been destroyed, bulging forward and forming a keratocele. With rupture of this membrane the ordinary conditions of perforating ulcer obtain.

Prognosis.—Ulcers due to this cause that have been described (Hertel) have been of a virulent type, with loss of a large portion of the cornea, followed by adherent leukoma and its consequence.

Treatment.—The treatment, in general, should be like that described for the treatment of pneumococcal ulcer (page 272), with the exception that in disinfecting the ulcer the central portion of the ulcer calls

[1] Klin. Monatsbl. f. Augenheilk., July and August, 1906.

for more attention than does the pneumoccal ulcer, since the microorganisms are probably more plentiful there.

Bacillus Pyocyaneus Ulcer.—Infection of the eye due to this microörganism not infrequently produces panophthalmitis, but the observation of MacNab,[1] Szczybalski, Bjetti, Callan,[2] Ewing, and others puts it beyond doubt that this bacillus may cause ulcer of the cornea, which may heal without causing destruction of the globe. Infection has followed injury in all of the cases in which a history of the onset could be obtained.

Bacteriology.—The bacillus can be readily found in the pus from the conjunctiva and from the débris in the floor of the ulcer.

Symptoms.—Shortly after the injury severe pain is experienced which continues; the lids become swollen, the conjunctiva swollen and chemotic. A greenish-yellow, flaky, purulent discharge develops. The infection is one of great virulence. Destruction of cornea, with the formation of a large ulcer and marked hypopyon, may develop within forty-eight hours. The ulcer is approximately circular, margins ragged and thickened, not undermined, the surrounding corneal tissues densely infiltrated. The ulcer is filled with greenish-yellow pus and necrotic tissue.

Complications.—Panophthalmitis develops in this infection of the cornea probably more than in any other. The iris and ciliary body become congested and active in the production of small cells and fibrinous exudate at an early stage. Tenonitis may develop. The results of perforation, namely, prolapse of iris, adherent leukoma, staphyloma, etc., are the same that are observed in perforation occurring in other forms of ulcer.

Prognosis.—Grave.

Treatment.—This must be vigorous and radical, as advised in the treatment of pneumococcal ulcer. Saemisch section will be required more frequently than in other forms of corneal ulcer except, perhaps, in the streptococcic ulcer.

Friedländer's Pneumobacillus Ulcer.—This bacillus, which is occasionally found in the normal conjunctival sac and in the secretion in chronic dacryococystitis, is an occasional cause of corneal ulcer. MacNab describes this ulcer as follows: "The loss of substance is round, spreading outward as well as deeply, so that a shallow, funnel-shaped depression results. The destructive process seems to develop equally rapidly in all directions . . . The floor of the ulcer is covered by a gelatinous debris." The hypopyon is considerable. The iris is involved early. The exudation is of a more plastic nature than occurs in other forms of hypopyon keratitis. Difficulty is experienced in securing dilatation of the pupil (MacNab). The progress of the ulcer is attended by much pain, probably greater on account of involvement of the iris.

Prognosis.—This is favorable if proper treatment is instituted. Perforation need not take place except in the very severe cases.

[1] Klin. Monatsbl. f. Augenheilk., January, 1904.
[2] Trans. American Ophth, Society, 1906.

Treatment.—This is the same as for pneumococcal ulcer in general. The actual cautery may not be needed so frequently. Carbolic acid or glacial acetic acid may be employed instead. Particular attention must be given to obtaining dilatation of the pupil. The conjunctivitis must have appropriate treatment as advised in pneumococcic conjunctivitis.

Keratitis due to other Microörganisms.—Hypopyon keratitis due to the Staphylococcus pyogenes aureus, citreus, and albus has been observed. The cases are not many. The type of ulcer is circular, deep, with infiltrated margins. The ulcer does not develop very rapidly, nor does it lead to great destruction of tissue. The staphylococcus may be recovered from the débris filling the ulcer, from the tissue in the floor and walls of the ulcer.

The Bacterium coli communis, Rosa hefa, and the Bacillus subtilis have been reported as the cause of hypopyon keratitis in a very few cases. The ulceration due to the Bacterium coli communis is severe.

Aspergillus Keratitis (*Mycotic Keratitis*).—**Etiology.**—The varieties of aspergillus that are pathogenic for the cornea are A. fumigatus, A. flavus, A. niger, and A. picrum. Their virulence is in the order named.

Aspergillus fumigatus is by far the most commonly met with in this form of infection of the cornea. It produces two clinical pictures, due apparently to varying degrees of virulence of the different strains of the fungus. For the first full description of the severe form we are indebted to Leber.[1]

In order to have development in the cornea the fungus must be introduced into the corneal tissue. It is carried in by an infected foreign body, a splinter of wood, a husk of corn, wheat beard, chestnut burr, particle of earth, etc. (earthy or vegetable foreign body). In some cases the foreign body which has introduced the fungus is found attached to the cornea. The incubation period varies from a few days to two or three weeks.

Pathology.—The epithelial layer and Bowman's membrane are destroyed over the area of the patch. A firm layer of the mycelium of the fungus is encountered which invades the necrotic corneal tissue lying below. Fruit heads of the fungus are not present.

Symptoms.—The development of the ulcer is accompanied by pain referred to the eye, symptoms of irritation, a scalding sensation, lachrymation, congestion, and swelling of the conjunctiva and mucopurulent secretion corresponding in degree to the severity of the case.

In severe cases a relatively large area of the cornea is occupied by a dirty, grayish-yellow, lack-lustre patch, which may be slightly sunken in the centre, but is on a level with or slightly raised at the margin. This patch is sharply defined, a minute groove being traceable between patch and surrounding cornea throughout all or a part of the border. The remaining cornea is infiltrated, particularly in the vicinity of the patch. On touching the surface with a probe it is found to be quite firm.

[1] Arch. f. Ophth., Band xxv., 2, S. 285.

The hypopyon varies in amount. The iris and ciliary body are involved much as in typical pneumococcal ulcer.

The disease progresses slowly and may invade or cause destruction of the entire cornea.

The milder type of invasion of the cornea resembles to some extent the fascicular form of eczematous keratitis. A circular, grayish-yellow, lack-lustre patch appears on some part of the cornea. It is slightly raised. Its margins are sharply defined and separated from the uninvaded cornea by a shallow groove. A leash of vessels develops from the margin of the cornea nearest the patch and extends to it. Slight infiltration of the surrounding cornea is present. There is no iritis or hypopyon. The symptoms are correspondingly mild. A case of this type may continue for some time but little changed. It probably would either pass into the severe form if not treated, or the grayish mass would eventually be cast off and healing follow.

Diagnosis.—This is made by examining properly stained scrapings or excised portions of the grayish patch. On attempts to scrape it the patch will be found to be tough and portions can be more satisfactorily removed by excision. Under the microscope necrotic corneal tissue traversed by numerous refractile, branching threads (mycelium) will be found.

Treatment.—Thorough removal of the patch ("sequestrum") by scraping or by excision, mild cauterization of the walls of the defect, and subsequent asepsis will insure recovery. Hot fomentations, as they tend to raise the temperature of the cornea and favor the development of the fungus, should be avoided.

Mooren's Ulcer (*Rodent Ulcer*).—**Etiology.**—Not known.

Pathology.—The changes that take place are very well shown in Fig. 162. Bowman's membrane and the outer third of the substantia propria are destroyed and the cornea is much reduced in thickness. The remaining lamellæ are covered by new-formed tissue in which blood-vessels ramify, this being covered by an irregular layer of stratified epithelium. The overhanging border consists of a few degenerating lamellæ of corneal tissue covered by Bowman's membrane and epithelium, both of which are undergoing degenerative changes. Descemet's membrane and the endothelium are intact.

Description.—This ulcer, described by Bowman in 1849, by Mooren in 1867, presents a distinct clinical entity. It is characterized by chronicity, is remitting in its progress, and is superficial. Adults are attacked. Frequently both eyes are involved. The ulcer begins as an indistinctly punctate, not very dense, infiltration of the cornea, usually at the upper and lower border. Soon the epithelium covering the infiltrated area is lost and a superficial ulcer is established. The margin of the ulcer toward the centre of the cornea is limited by an irregular, frequently interrupted, grayish-white line which measures about 1 mm wide and is approximately level with the corneal epithelium. This line represents the advancing border of the ulcer. It may extend onto the conjunctiva. It is undermined. A fine probe can be passed beneath

this border 0.5 to 1 mm. The area between the border and the periphery of the cornea is sunken very slightly and is covered by a thin cicatricial tissue representing the superficial layers of the cornea that have been lost. This tissue is very slightly vascular and is covered by epithelium to within about 1 mm. from the advancing border. At the places where the border of the defect passes imperceptibly into normal corneal tissue the surface is covered by epithelium and the ulcer is not progressing. The progress of the ulcer is extremely slow and irregular. There may be weeks of apparent arrest; then at some point of the border the shallow infiltration becomes more marked and advances slightly. This may continue for months or even years, until the entire cornea is traversed.

Fig. 162

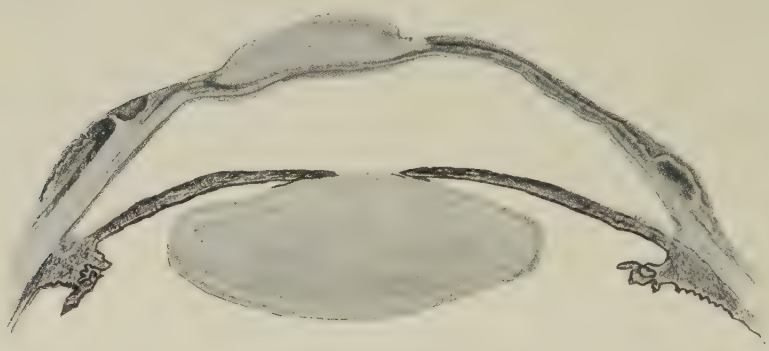

Mooren's (rodent) ulcer, much magnified. (Klin. Monatsblt. f. Augenheilkunde.)

Symptoms.—At the commencement of the attack and when the ulcer is advancing, there is marked irritation, increased lachrymation, and some neuralgic pain. The unaffected area is normally sensitive, but the cicatrized surface is not sensitive.

Diagnosis.—Chronicity is one of the principal features. If the ulcer does not last more than three months, it should not, according to MacNab, be termed rodent ulcer. If chronicity and the other features just described exist, a correct diagnosis can easily be made.

Prognosis.—It is extremely doubtful whether the progress of the disease can be arrested. If this is done the resulting vision may be normal. Vision through the cicatrix, should the ulcer extend over the pupillary area, would be about $\frac{1}{10}$.

Treatment.—On the whole, treatment is not very satisfactory. A careful examination of the border should be made and all overhanging tissue cut away with fine scissors. The infiltration should be scraped away and the defect cauterized either with the actual cautery or with carbolic acid. After the slough has separated the surface may be gently scraped and a conjunctival flap brought into place over the defect. Should there be a recurrence the treatment may be repeated. Arrest of the disease in a small percentage of cases may be expected. If the ulcer encroaches on the pupillary area, the cautery should not be used, as the resulting scar

will be greater than that produced by the ulcer. During the progress of the treatment the cornea and conjunctiva should be kept as nearly sterile as possible. The introduction of bichloride vaseline (1 to 3000 or 1 to 5000) every four hours, or of iodoform ointment (5 to 10 per cent.), may suffice. Tincture of iodine has been highly recommended (Handmann). The overhanging lip is cut away and the iodine applied to the surface. If perforation threatens, which is sometimes the case when there is an added infection, the Saemisch section may be resorted to.

Fig. 163

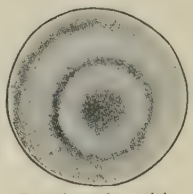

Disciform keratitis. (Graefe's Archiv.)

Keratitis Marginalis Superficialis.—Fuchs has described under this name a chronic progressive ulcer, occurring in adults past middle age, which closely resembles Mooren's ulcer, differing apparently only in degree of severity. Fuchs mentions the fact that pseudopterygium may develop with this form of ulcer.

Disciform Keratitis (*Abscessus Siccus*).—**Description.**—This form of keratitis (Fuchs[1]) presents a distinct clinical picture. It is characterized by the development in the parenchyma near or at the centre of the cornea of a round or oval disk-shaped opacity, gray or grayish-yellow in color, which is limited by a sharply defined narrow zone or zones (one to three) denser than the main portion of the opacity. One or more dense spots, varying in size, often irregular in shape, appear within the area of the opacity. Radiating lines may traverse the opacity and may project a short distance from its border. The surface of the cornea over the opacity is dull and insensitive. At times it is roughened by the presence of small vesicular thickenings of the epithelium, while in exceptional cases the epithelium breaks down and small ulcers form. The surrounding cornea is clear. The degree of irritation varies greatly in different cases, but is approximately in proportion to the severity of the process. It may run its course with very little irritation. Iritis, anterior uveitis, with deposits on Descemet's membrane and hypopyon, may develop. The cornea may become vascular to some degree. Perforation of the cornea has not been reported.

Etiology.—Fuchs is of the opinion that the process is due to ectogenic infection, probably following minute superficial wounds. The bacteriology is not well understood. Staphylococci have been found several times. Morax-Axenfeld bacillus (Grunert) has also been found in such ulcers. Shirmer[2] produced a similar condition in guinea-pigs by inoculating the cornea with vaccine virus, the etiological factor of which is supposed to be a protozoan. Herpes zoster or herpes febrilis sometimes precedes the attack.

Pathology.—The condition is one of inflammatory infiltration (Meller).

Course.—The affection runs a chronic course, two to five months, usually resulting in a permanent opacity more or less dense. Individuals

[1] Klin. Monatsbl. f. Augenheilk., xxxiv, p. 513.
[2] Arch. f. Ophth., Band lix, 1, S. 133.

of all ages except the very young may be attacked. Fuchs very aptly places it, so far as severity is concerned, between the ulceration which follows herpes of the cornea and pneumococcic ulcer.

Treatment.—The process is not greatly influenced by therapeutic measures. As the tendency is to heal without breaking down, destructive measures, such as the cautery, are not indicated. In the treatment of three relatively recent cases the writer has thought that the patients have been benefited by the use of hot fomentations (1 hour at a time four or five times daily), bichloride vaseline (1 to 3000 to 1 to 5000) t. i. d., dionin solution (5 to 10 per cent.) once daily, four days in succession, repeated as was thought best, and atropine to maintain moderate dilatation of the pupil. In addition, remedies were employed to improve the systemic condition.

Ring Abscess (Fuchs).—**Description.**—This is a form of infection of the cornea occurring after wounds, surgical or otherwise, which presents characteristic features. There is a rapidly developing infiltration of corneal tissue, beginning near the margin and extending entirely around the cornea. Fuchs and Hanke describe two rings of infiltration, one in which the pus cells are derived from the blood-vessels at the limbus, superficial; one in which the cells are derived from deeper vessels and possibly from the iris, the ring being just in front of Descemet's membrane. The infiltration advances rapidly; the whole cornea becomes cloudy and sloughs in a few days. Panophthalmitis frequently develops. Ring abscess is not always disastrous. Fuchs reports one recovery after cauterization of the wound.

Fig. 164

Filamentous keratitis. (Graefe's Archiv.)

Etiology.—A specific cause has not been determined. As it is a wound infection, it is very probable that the pneumococcus, streptococcus, or the Bacillus pyocyaneus may produce it. Apparently the microörganisms develop chiefly in the anterior chamber and excite the infiltration by the toxins that they produce.

Treatment.—Early, rigorous antiseptic treatment, using the cautery freely as indicated.

Filamentous Keratitis (*Fädchen Keratitis*).—This disease may be classified as (*a*) *idiopathic* or (*b*) *traumatic.*

Idiopathic Filamentous Keratitis.—This form is characterized by the formation in the corneal epithelium of small epithelial globules, measuring usually one to one and a half millimeters in diameter, which are pushed above the level of the epithelium and finally become pendent

from the epithelial surface, connected by small pedicles (Nuel, Hess[1]). The globule consists of epithelial cells of the tesselated variety, which are undergoing mucoid degeneration. A hyaline body is usually observed in the centre, resembling the coccidium. The pedicle consists of epithelial cells which have become elongated until they assume the appearance of fibrillæ. These are twisted into a small thread. The masses rise and fall with the movements of the lids. The surface of the cornea in the vicinity is covered by a thin layer of secretion and has a grayish appearance. The filaments last from three to four days. Recurrent eruptions are not infrequent. The number of globules may be but two or three; they may be numerous and cover almost the entire cornea.

Fig. 165

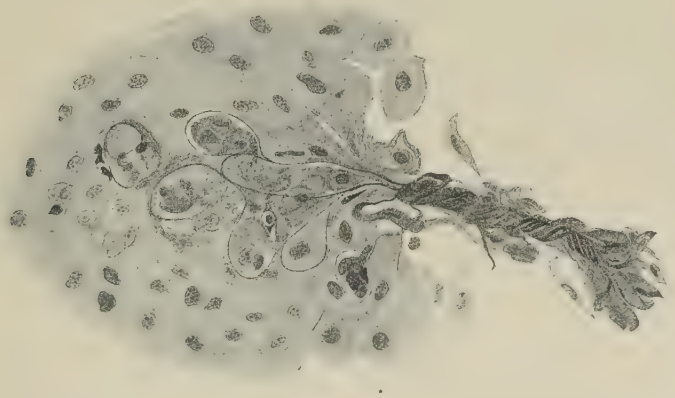

Filamentous keratitis, showing development of filaments from elongated and twisted epithelial cells. (Graefe's Archiv.)

Etiology.—What causes filamentous keratitis is not known. It is peculiar to advanced adult life, and is more frequently observed in eyes that have been the seat of an inflammatory process affecting the anterior segment. Similar globules may form from the floors of ulcers that are in the process of healing.

Traumatic Filamentous Keratitis.—*Etiology.*—This form is probably due to the adherence of partly detached threads of epithelium to an abraided corneal surface, rather than to filaments derived from the eruption of globules as above described.

Symptoms.—The development of filamentous keratitis is accompanied by symptoms of irritation, slight injection of the ocular conjunctiva, sense as of a foreign body in the eye, and the presence of scanty mucoid or mucopurulent secretion, portions of which adhere to the corneal surface. Slight febrile reaction is sometimes observed.

Treatment.—Treatment should be general as well as local. Local treatment consists in keeping the cornea cleansed, using mild anti-

[1] Graefe's Arch., xxxix, 2, p. 199.

septic solutions, such as boric acid solution (3 per cent.) or permanganate of potash (1 to 5000). In addition, much comfort is given to the patient if a lubricant in the form of borated (5 per cent.) or bichloride (1 to 5000) vaseline is introduced into the eye three or four times daily. If the condition is persistent, the filaments may be curetted away by means of a sharp spoon, and their bases lightly cauterized with carbolic acid.

The systemic treatment consists in the employment of general tonic remedies.

Dendritic Keratitis (*Furrow Keratitis; Keratitis Arborescens*).—**Description.**—The term is applied to a superficial form of keratitis which usually begins near the periphery, but may also begin at the centre of the cornea. It is characterized by the appearance of a narrow, grayish line of infiltration in the corneal tissue near the surface, accompanied by an elevation of the epithelium. The epithelium covering this line of infiltration breaks down and a shallow groove ("furrow") is formed. Preceding or following the destruction of the epithelium over the primary groove, offshoots from the original line of infiltration develop. These offshoots frequently terminate in a minute grayish enlargement, and the process as first described is repeated. The offshoots multiply until eventually a tree-like ("aborescent") formation is presented. The affection is not confined to the grooves and lines, but advances superficially into the surrounding tissue, producing punctate or patch-like defects in the epithelium. The advance of the process differs in different cases. As a rule, it is relatively slow and intermittent. The superficial nature of the process may be continued throughout its course. When this occurs, nebulous opacity of the cornea with very slight unevenness of the surface results. As a result of added infection the deeper tissues may become involved, and in exceptional cases perforation of the cornea may take place. Dendritic keratitis is very rare under the age of sixteen. Adults of middle age are most frequently attacked. It is monocular as a rule. Recurrences are not infrequent.

Fig. 166

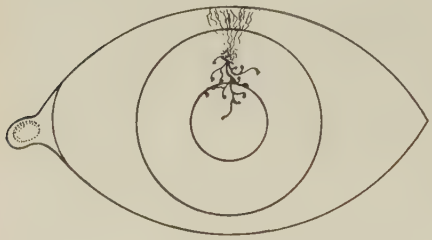

Dendritic keratitis.

Etiology.—A cause has not as yet been determined. The appearances indicate the presence of a microörganism. Emmert, in 1885, and Keiper and Spencer, in 1906, described bacilli, which they regard as the cause in the cases examined. Kipp and, later, Ellet observed the disease in malarious subjects and assign malaria as a cause. Fuchs and others are of the opinion that it is due to a terminal nerve lesion of the nature of herpes. It has been observed accompanying herpes febrilis.

Symptoms.—The symptoms are frequently very distressing. The patient complains of a sensation as of a foreign body in the eye. Photo-

phobia to a very annoying degree develops. Neuralgic pains affecting the distribution of the supra- and infra-orbital branches of the fifth nerve are experienced. These symptoms may suddenly cease and be absent for a day or two, and then suddenly recur. The subsidence of symptoms marks an arrest of development. The recurrence of symptoms indicates advance of the disease. The intensity of the symptoms depends directly upon the activity of the process. Areas of loss of sensitiveness develop in the cornea. There is very little, if any, secretion.

Treatment.—The infiltrated grooves and spots may be scraped and touched either with the cautery, with carbolic acid, or with formalin (10 per cent. solution). Application of the tincture of iodine once in twenty-four or forty-eight hours, also the instillation of argyrol (25 per cent.) every two hours, give good results. Bathing with a hot solution of boric acid three or four times daily for half an hour at a time is apparently beneficial. Systemic treatment for the purpose of correcting any abnormal condition of the system should also be given.

Desiccation Keratitis (*Keratitis e Lagophthalmos*).—**Etiology.**—When the cornea is exposed for any length of time without suitable lubrication from lachrymal fluid or from the presence of an oily substance, the epithelial cells become dry and irregular, and the cornea becomes slightly opaque. Exposure leads to one of two things—the corneal tissue either takes on a cutaneous condition or the epithelial layer is lost and ulcer occurs. The keratitis from desiccation occurs in cases of extreme exophthalmos, tonic spasmodic retraction of the levator palpebræ superioris, extreme ectropion, and paralysis of the orbicularis palpebrarum muscle preventing closure of the eyes, in depressing diseases, such as typhoid fever, smallpox, and in the later stages of disease ending in death of the patient, where, from inability to close the eyes, the cornea is exposed. In all cases of desiccation keratitis the portion of cornea first affected is the more exposed portion.

Desiccation keratitis is probably most frequently observed in paralytic lagophthalmos. If ulceration occurs, it may progress and destroy more or less of the cornea. The *direct cause* of the *ulceration* is the entrance of microörganisms, usually staphylococci, into the corneal tissue.

Symptoms.—The symptoms are, as a rule, not severe. More or less pain referable to the eye is complained of, and in cases of involvement of the iris and ciliary body symptoms peculiar to disease of these structures develop.

Treatment.—The treatment consists in providing protection for the exposed cornea. This, in cases of paralytic lagophthalmos and exophthalmos, is effected by the application of protective bandages, the use of lubricating ointments, or, in cases not admitting of relief by spontaneous recovery, tarsorrhaphy to an extent sufficient for the protection of the cornea. After cicatricial ectropion, plastic operations for restoring the lids should be resorted to. The usual local treatment for corneal ulcer and its complications should be employed.

Keratomalacia (*Marasmic Ulcer*).—Keratomalacia accompanies xerosis epithelialis affecting infants, marasmus without xerosis, and

the later stages of exhausting diseases, such as typhoid fever, scorbutus, etc.

Forms.—It may present two clinical pictures: (1) In infants it is characterized by a grayish discoloration of the cornea, increase in thickness of the corneal tissue, accompanied by softening and complete loss of the cornea by sloughing. Both eyes are affected, as a rule. A lethal result almost invariably follows. (2) In adults the affection resembles a dry necrosis or gangrene. The conjunctiva and cornea become dry to some extent, the cornea gray and insensible, and is cast off in the form of a slough. The inflammatory reaction is very slight.

Knaebel[1] collected 18 cases of keratomalacia infantum. The youngest infant was three weeks, the oldest six months. In 9 the condition was bilateral. Nine infants died. Of 13 eyes affected in the remaining 9 infants, 11 became totally blind. All but 3 of the patients had accompanying xerosis of the conjunctiva.

Etiology.—Inherited syphilis is thought to be a cause in some cases. Digestive disturbances have been present in all or nearly all. The bacteria found are the pneumococcus, streptococcus, staphylococcus, Bacterium coli communis, and xerosis bacillus.

Treatment.—Manifestly of little value, the general condition of the patent should be improved if possible. Antisyphilitic treatment should be given in syphilitic cases. The cornea and conjunctival sacs should be cleansed and protective ointments introduced.

Neuroparalytic Keratitis[2] (*Neuropathic Keratitis*).—**Description.**—In 1824 Magendie observed that secretion of the trigeminus in rabbits was followed by a destructive keratitis. He attributed this to a lesion of trophic nerve fibers supplying the cornea—the trophic theory. Later, Snellen came to the conclusion that loss of corneal sensibility and the consequent diminution of lid reflex due to injury to the trigeminus permitted of exposure, desiccation, and injury to the cornea from the entrance of foreign bodies, and that this was sufficient to explain the corneal changes observed—the exposure theory. All admit lesion of the trigeminus.

After a thorough analysis of the evidence at hand, Wilbrand and Saenger have arrived at the conclusion that neuroparalytic keratitis is closely allied to herpes of the cornea; that it is the result of irritation affecting the trigeminus in some part of its tract ("Reizzustände in Trigeminus-gebiete").

The establishment of the keratitis depends on the character of the irritation. It is usually accompanied by loss of sensibility of the area supplied by the trigeminus, particularly of the ophthalmic division, but this is not necessary. The theory of trophic nerve fiber participation is as yet unsettled.

Etiology.—Surgical or accidental injury to the fifth nerve, sarcoma, syphilis, tuberculosis affecting the fifth nerve, may cause the keratitis to

[1] Inaug. Dissert., Tübingen, 1901.

[2] For a full discussion of this subject see Wilbrand und Saenger, Neurologie des Auges, vol. ii. p. 206.

develop, but does not always do so. Of 170 cases of lesion from all causes collected by Wilbrand and Saenger, 64 developed neuroparalytic keratitis. Of 21 cases in which the Hartley-Krauss operation on the Gasserian ganglion had been done, keratitis developed in eleven.[1] An infection from one or a number of microörganisms may take place after the epithelium is destroyed. The Streptococcus pyogenes, staphylococcus, and the pneumococcus are the microörganisms most frequently found.

Diagnosis.—A history of a lesion of the fifth nerve, with the typical changes in the cornea without lagophthalmos, presents a condition that is easy of diagnosis. If lagophthalmos is present and the changes in the cornea atypical, the diagnosis may be difficult.

Course and Results.—In the cases following operation on or injury to the fifth nerve, the keratitis begins five to twelve days later in the form of a more or less distinctly marked vesicular elevation of the epithelium in the centre of the cornea, which soon breaks down, causing pit-like depressions. This disturbance of the epithelium extends almost to the margin of the cornea, a zone of one or two millimeters usually remaining comparatively free. A grayish infiltration of corneal tissue, deepest in the centre of the cornea, develops, and sloughing may follow, with entire loss of the cornea. The sensibility of the cornea and conjunctiva has been abolished, as a rule, before the ulceration begins. The cornea may be less moist than normal, or it may appear to be suffused with tears. There is some injection of the ocular conjunctiva, but the signs of irritation are very slight. There is no photophobia, nor does the patient experience pain. Vision is, of course, greatly reduced, and eventually is abolished in the severe cases.

Paralyses of motor ocular nerves and of the sympathetic, with their attending symptoms, may accompany the keratitis. The rapidity and the extent of the keratitis depends on the character of the lesion. It may be rapid; it may be slow or intermittent. Only part of the cornea may be affected.

Treatment.—The systemic treatment, aside from that for the improvement of the general health, depends entirely upon the cause of the affection of the fifth nerve. The local treatment consists in protecting the cornea and the prevention of infection. The cornea may be protected and infection prevented by introducing bland ointments into the eye sufficiently often (every two or three hours) during the daytime, and by applying a light bandage at night. Cleansing the eye with a mild aseptic or antiseptic solution (boric acid, 3 per cent.; bichloride of mercury, 1 to 15,000) should be performed when necessary. If infection has already taken place the form of infection should be determined and the ulceration treated on the plan designated for the particular infection.

Herpes.—Forms.—Herpetic eruption of the cornea appears under three different forms: (*a*) Herpes corneæ neuralgicus (Schmidt-Rimpler); (*b*) herpes febrilis corneæ (Horner); (*c*) herpes zoster corneæ.

[1] Davis and Hall, Brit. Med. Jour., January 11, 1908.

Herpes Corneæ Neuralgicus.—This is accompanied by severe pain over the course of the supra-orbital branch of the fifth nerve. It is characterized by the development of a number of small vesicles on the corresponding cornea, clear or pearl gray in color, accompanied by lessening of the sensibility of the cornea and hypotony of the globe. The vesicles disappear after twelve to eighteen hours, recurring periodically. The periodicity and pain impart a neuralgic character to the affection. Females are most frequently attacked. Schmidt-Rimpler reports the case of a girl, aged nineteen years, who suffered from recurrences of an eruption of vesicles on the cornea which took place daily for a number of weeks. The eruption was preceded by severe frontal pain lasting an hour or two. By evening the vesicles would heal. Ranzohoff reports a case in which the herpetic eruption occurred at every menstrual period, preceded by pain in the head and loss of appetite.

The affection disappears without leaving a trace except in the very long-continued cases, when a very thin nebulous opacity remains.

Fig. 167



Herpes of the cornea. *a*. Group of herpes vesicles in the centre of the cornea. Toward the top small, infiltrated spots lacking epithelium. *b*. Herpes vesicles, inward and upward. At the top and outward an ulcer with deep upper edge somewhat infiltrated. × 2. (Wilbrand and Saenger.)

Herpes Corneæ Febrilis.—In some febrile conditions accompanied by the development of vesicles about the base of the nose, lips, and cheeks, herpetic eruptions on the cornea appear. The affection is usually monocular. Herpes corneæ febrilis presents the same picture so far as the cornea is concerned as herpes zoster corneæ, except that it is, as a rule, milder and *may* be recovered from without leaving a trace. Usually a delicate macular opacity of the affected portion of the cornea remains.

Herpes Zoster Corneæ.—Twelve to twenty days after the development of herpes zoster frontalis, vesicles in clusters may appear on the cornea of the corresponding side. The vesicles are small, varying from 0.25 to 1.5 mm. in diameter, are transparent at first, but soon become cloudy and rupture, leaving a superficial ulcer with shreds of epithelium hanging from the edges of the vesicles. The ulcer involves the very superficial lamellæ of the cornea, has an uneven, grayish floor and an irregular border. The margins are not raised. Where vesicles have ruptured the cornea is anesthetic. Other parts preserve their normal sensitiveness. The eruption of the vesicles is preceded by sharp, pricking pain referable to the eye, by increased lachrymation, and at times by some mucopurulent secretion. Unless there be an added infection,

infiltration of surrounding corneal tissue is very slight. Fine gray lines may extend from the ulcer for a short distance into the neighboring corneal tissue. The keratitis accompanying herpes zoster varies much in severity. The typical appearance, as described above, also varies much—diffuse superficial haziness of corneal tissue, with uneven surface, representing minute defects in the epithelium, extending over a great part of the cornea; punctate infiltration areas covered by roughened epithelium; striate and band-like areas of superficial infiltration.

Frequency.—Wilbrand and Saenger collected 235 cases of herpes zoster frontalis observed by a number of surgeons. The cornea was affected in 83 cases (35.32 per cent.).

Etiology.—A neurosis of the fifth nerve often confined to the first branch. Herpetic keratitis is closely allied with keratitis neuroparalytica.

Course.—The first eruption of vesicles may be followed by eruptions of clusters of vesicles in adjacent parts of the cornea. Recovery is very slow in spite of all treatment. The epithelium is restored very slowly and is often defective. The infiltration slowly disappears, leaving more or less nebulous opacity. In very superficial cases the opacity may virtually disappear. Extensive destruction of corneal tissue appears as a result of secondary infection only.

Complications.—Iritis not infrequently accompanies herpetic keratitis.

Treatment.—The local treatment is the same in all forms of herpes of the cornea. It consists in keeping the eye clean by use of bland aseptic or antiseptic washes (boric acid solution, 3 per cent.; bichloride solution, 1 to 10,000, etc.), protection of the denuded surface, for which purpose bichloride vaseline (1 to 5000) and borated vaseline (3 per cent.) introduced into the eye every three or four hours are excellent. The process may be stimulated to more rapid healing by use of moist applications. Accompanying iritis requires the use of atropine. The systemic treatment must be directed against the cause of the herpes.

Bullous Keratitis.—This condition consists in the formation of a large vesicle or vesicles on the cornea, usually in its lower portion. It occurs in eyes that are affected with chronic iridocyclitis, with glaucoma, and after superficial traumatism. The presence of the bleb or bulla is accompanied by symptoms of irritation. There is excessive lachrymation, photophobia, and some mucopurulent secretion. The affection occurs in adult life almost exclusively.

Pathology.—The outer wall of the bleb consists usually of the entire thickness of the epithelial layer of the cornea which has become raised from Bowman's membrane by the transudation of fluid through Bowman's membrane. Clefts appear between the epithelial cells. The cells become swollen and are vacuolated, and the basement cells (foot cells) lose their normal shape, becoming cuboidal (de Schweinitz). Brugger[1] believes that the first step is an infiltration of the substantia propria of the cornea with fluid which could not escape by the limbus.

[1] Monats. f. Augenheilk., 1886, xxiv, 500.

New tissue elements of the nature of the tissue in vascular pannus form beneath the epithelium on Bowman's membrane, but this tissue is not necessarily present over the area from which the epithelium becomes detached.

Duration.—The bleb usually persists for a few days and ruptures, threads of epithelium hanging from the margins. The denuded surface is rapidly recovered with epithelium. Rarely the bleb wall becomes reattached to the cornea after the bleb ruptures. Recurrences are frequent, in some cases within a few days; in others after months or years.

Treatment.—The first indication is to correct the condition which makes the development of bullous keratitis possible. It is sometimes sufficient to puncture the vesicle and apply a compress bandage. It sometimes becomes necessary to remove the anterior wall of the vesicle and to treat the denuded surface by an application of a solution of the nitrate of silver (0.5 to 1 per cent.), or by superficial cauterization. Removal of the superficial parts of the cornea has been resorted to.

Relapsing Traumatic Keratitis (*Relapsing Erosion of the Cornea, Traumatic Keratalgia*).—Abrasion of the cornea produced by the contact of a foreign body (twig, finger nail, cuff) tangentially with the surface, after apparently healing, is followed a few days, weeks, or months later by a loss of epithelium over part of the affected area. The loss may occur in the form of a simple disappearance of epithelium, comprising the superficial cells, or large vesicles (bullæ) may develop, the outer walls of which are composed of the epithelial layer.

Symptoms.—On waking, usually after a prolonged sleep, the patient has difficulty in opening the eye. When the lids are raised, sharp neuralgic pain is experienced. There is lachrymation and photophobia. On examining the cornea an eroded area or a bullous elevation of the epithelium, corresponding with the site of the injury, is found. The epithelium is soon replaced, when the symptoms subside to again develop on recurrence of the process.

Treatment.—Touching the eroded spots with the nitrate of silver (2 per cent.) gives speedy relief (Schroeder). The compress bandage and borated vaseline or bichloride vaseline (1 to 5000) are recommended by Wagenman. Massage with an ointment of the yellow oxide of mercury (de Schweinitz) may be employed. In obstinate cases it is best to excise the affected part. The writer has brought about rapid and permanent recovery by gently curetting the affected area, touching it with formalin (10 per cent.), introducing borated vaseline (3 per cent.) ever four hours, and closing the eye for a few days until new epithelium has formed.

Pannus.—This is a form of superficial vascular keratitis, and is the result of an attempt on the part of nature to protect the cornea from irritating influences. It is most frequently observed in trachoma, and occurs in that stage of the disease in which the elevations on the surface of the conjunctiva are hard and dense and are capable of producing displacement of the epithelium of the cornea. The vascularity may affect the whole or part of the cornea. In cases of trachoma in which the

lower lid is only slightly involved, the pannus of the cornea may be limited exclusively to the upper half. It sometimes occurs that the irritation affects only the lower half of the cornea, in which case the pannus is limited to this part. Vascular pannus may be extremely slight (*pannus tenuis*), or the vascularity may be very pronounced (*pannus vasculosus*); it may be so intense that the cornea is converted into a condition resembling a fleshy mass (*pannus crassus* or *carnosus*). The vascularity remains as long as the irritation is present, and then gradually subsides, often leaving but few traces. In severe cases complete opacification of the cornea may result. In the later stages when few blood-vessels are present and more or less opacification results from the presence of cicatricial tissue the condition is known as *pannus siccus*.

Fig. 168



Pannus affecting upper half of cornea.

Pathology.—The blood-vessels in pannus, in the earlier stages and lighter forms, are found immediately beneath the epithelial layer. They lie in a scant stroma of new-formed connective tissue or formative cells, and are accompanied by a more or less plentiful small-cell infiltration. In pannus tenuis Bowman's membrane remains almost, if not quite, intact; in the severer forms of pannus the superficial lamellæ of the substantia propria are involved and Bowman's membrane is greatly changed, losing its character entirely. It is never restored.

Tuberculosis of the Cornea.—Tuberculosis of the cornea is seldom primary; however, it is very probable that primary tuberculosis does occur, since tuberculosis of the cornea may be produced by direct inoculation, as shown by Panas and Vassaux[1] in their experiments on rabbits. As a rule, it is secondary to tuberculosis of the uveal tract or of the conjunctiva and sclera.

Forms.—Tuberculosis of the cornea may appear (*a*) as interstitial keratitis, usually presenting a number of dense foci, and become associated with uveal tuberculosis; (*b*) as sclerosing keratitis; (*c*) as grayish opacities situated deep in the corneal tissues or more superficially, leading to superficial ulceration of the cornea. These opacities or nodules are miliary tubercles modified by the dense tissue and poor culture medium in which they occur. When near the surface of the cornea they are distinctly nodular. Infiltration of the surrounding corneal tissue, most dense near the foci, takes place, but is not, as a rule, as dense as in syphilitic interstitial keratitis.

Tubercular keratitis may affect one or both eyes. It may be associated with enlarged cervical glands, which may suppurate. The interstitial form is attributed to the effect of toxins (Bach). It is possible that the sclerosing form is also due to the same cause. It is extremely difficult to find tubercle bacilli in tubercular tissue from the cornea because of

[1] Arch. d'ophtal., 1885, p. 193.

their scarcity. If they are demonstrated at all, it must be by inoculation experiments.

Symptoms.—In the interstitial (parenchymatous) and in the sclerosing form there may be but few symptoms—slight photophobia, increased lachrymation in the early stage, impairment of vision, infiltration of the cornea, and in some cases deep-seated, but not very intense, pain. In the more superficial, more active, suppurating form, in addition to the symptoms mentioned, there is some mucopurulent or flocculent secretion, injection and swelling of the ocular conjunctiva, and injection of the palpebral conjunctiva, with enlargement of pre-auricular and infra-maxillary glands.

Diagnosis.—The interstitial and sclerosing forms are diagnosticated clinically only by their association with uveal or conjunctival and scleral tuberculosis. As a rule, the color of the cornea presents a more yellow tone than in syphilitic keratitis.

The nodular and ulcerative form is differentiated from phlyctenulæ by their greater persistence, deeper location of the nodules in the tissue, yellowish color, and slower development. The tubercle bacilli may be demonstrated in some of these cases by inoculation experiments. The systemic and local reaction from the injection of tuberculin are of value in making a diagnosis. In employing this means it must be borne in mind that the characteristic systemic reaction will occur if there is a tubercular focus in any part of the body. If, in addition to the systemic, there is local reaction, the diagnosis of corneal tuberculosis is established.

Prognosis.—Spontaneous recovery, that is, recovery without specific treatment, with more or less permanent opacification of the cornea, sometimes occurs. If not properly treated, vision is greatly reduced, as a rule, because of the opacification of the cornea. Extensive loss of corneal tissue may occur.

Treatment.—Cleanliness, scraping and cauterizing nodules and ulcers will be followed by fair results. Injections of tuberculin are usually of much value. If the iris is involved, atropine should be employed to dilate the pupil.

Parenchymatous Keratitis (*Interstitial, Diffuse Interstitial, Syphilitic, Inherited, Specific, Strumous Keratitis*).—Parenchymatous keratitis is characterized by the development of a diffuse, inflammatory infiltration of the substantia propria of the cornea, attended with symptoms of irritation. The infiltration may proceed (*a*) from the periphery of the cornea, or (*b*) be primarily most dense at the centre of the cornea, spreading toward the periphery. It may involve part or the whole of the cornea. Both eyes are usually attacked, but often not simultaneously.

When advancing from the periphery, the free border of the infiltration is irregular and less dense than at the margin of the cornea. If examined with a lens, the infiltration will be found to be uneven in density, frequently being made up of a number of foci. Thickening of the conjunctiva at the sclerocorneal junction accompanies the process, the limbus conjunctivæ deeply congested and presenting a bright red

border, apparently advancing on to the cornea a short distance in some cases. The extension of the vessels of the conjunctiva on to the cornea is limited by a sharp line of demarcation and seldom exceeds more than one or one and one-half millimeters. Soon vessels from the margin of the cornea make their appearance in the parenchyma of the cornea, extending into the infiltrated area. The infiltration advances toward the centre of the cornea. In the majority of cases infiltration begins in the lower inner quadrant.

Fig. 169



Parenchymatous keratitis. (After Haab.)

The second mode of onset is that in which the opacity first manifests itself in the centre of the cornea; the infiltration occurs in numerous foci, gradually spreading until the greater part of the cornea is involved. The vessels of the limbus throughout the whole periphery of the cornea are somewhat injected, but the important vascularity occurs in the deep layers of the cornea, advancing from the periphery. In both forms of onset the surface of the cornea becomes somewhat roughened. Vision is impaired in proportion to the density of the infiltration. The infiltration advances rapidly in some cases, involving the entire corneal tissue in from two to four weeks. In others the advance is much less rapid, the height of the affection being reached only after two or three months. The attack in one eye may precede the attack in the other by some days, weeks, or even months.

Etiology.—The causes of interstitial keratitis follow in the order of their importance: Syphilis, (*a*) hereditary (45 to 65 per cent.), (*b*) acquired (6 to 10 per cent.); tuberculosis; rheumatism; malaria; diabetes; influenza (Greeff); rachitis; depressed nutrition; the climacteric (de Schweinitz). When due to *inherited syphilis,* it may affect individuals between the ages of five and forty-five. It occurs most frequently in children between the ages of seven and fifteen years. The sexes are affected with about equal frequency. Certain peculiarities in the conformation of the face and head accompany parenchymatous keratitis due to inherited syphilis. The forehead and cranium are often larger in proportion to the lower part of the face, evidences of hydrocephalus being present. The inferior and superior maxillary bones are often narrower than normal, the superior maxillæ being acutely arched. The skin of the face has an old or parchment-like appearance; the skin about the mouth is wrinkled; small scars are observable at the angles of the mouth and also in the lips near the angles of the mouth, indicating the presence at some period of life of fissures of the lips. The dentition in many (approximately 70 per cent.) of these cases is of a peculiar type, affecting principally the upper incisors. The teeth are not placed close together. They are usually smaller than normal, are broader at the base than at the apex, are peg-shaped, and

present a notching of the free border—*Hutchinson teeth* (Fig. 170). This form of dentition must not be confounded with that in which the enamel is defective at the apex of the teeth, or in which by a terraced appearance in the enamel different phases in its development are represented. Teeth of this character are usually the result of rickets and of other forms of malnutrition in the infant. Not infrequently the hearing in individuals with parenchymatous keratitis is defective, due to involvement of the auditory nerve.

Fig. 170

Dentition in rickets.

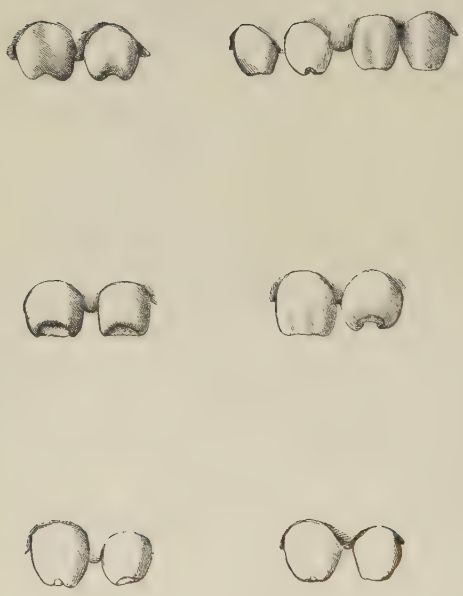

Dentition in inherited syphilis.

In parenchymatous keratitis the result of acquired syphilis, the involvement of the cornea occurs three weeks to twenty-eight years after the appearance of the primary sore (Stevenson). As a rule, the course is more rapid than in interstitial keratitis due to inherited syphilis, and there is more inflammatory reaction. The iris and ciliary body are more frequently involved. A quite distinctive clinical picture of punctate parenchymatous keratitis in acquired syphilis, in which the course is unattended by much irritation and recovery is rapid, has been described by a number of writers. Vossius has described a case of annular parenchymatous keratitis.

Pathology.—The essential change is an infiltration of the substantia propria with lymphoid cells, denser in some places than in others, most marked in the middle and posterior layers. Vascularization of the middle and deeper layers develops from the periphery. The small-cell infiltration often extends to the iris and ciliary body. Deposits may be found on the ligamentum pectinatum and posterior surface of the cornea. It is possible that these changes in syphilitic parenchymatous keratitis are excited by the presence of the Spirochæta pallida in the tissues of the cornea. The experimental studies of Schulze[1] are strongly confirmatory of this supposition.

[1] Klin. Monatsbl. f. Augenheilk., May and June, 1907, p. 466.

Symptoms.—Parenchymatous keratitis is accompanied in all cases by more or less irritation, increased lachrymation, and photophobia in proportion to the rapidity of the advancement of the disease. Pain, sometimes extremely mild, sometimes quite severe, referable to the eye and to the temple, is experienced. The severity of the pain depends to some extent on the degree of involvement of the iris and ciliary body. Slight ciliary injection with increased lachrymation develops with the beginning of the infiltration. As the infiltration advances the photophobia becomes marked.

Diagnosis.—The symptoms and appearances are so characteristic that it is not difficult to recognize the condition. The history of the case will serve to differentiate it from old maculæ and the haziness of the cornea that sometimes follows injury. The history, the appearance, and the absence of tension will serve to distinguish it from glaucoma.

Fig. 171

Parenchymatous keratitis. (Axenfeld.)

Duration.—In the average case the disease runs its course in from five to ten months—seldom less than five months even in the mild cases. In the severer cases the clearing up of the cornea does not reach the maximum in less than two or three years.

Degree of Severity.—Parenchymatous keratitis may be confined to one eye and affect only a small portion of the cornea at the periphery. It may occur only in one or two small punctate patches near the centre of the cornea. These areas of infiltration may produce but slight impairment in the transparency of the cornea. They advance for a few weeks extremely slowly and subside, leaving scarcely a trace. Severe forms may cause complete opacification of the cornea, resulting in the transformation of the cornea into a membrane of opaque tissue, reducing vision to perception of light. Between these two extremes there are all degrees of severity.

Results and Complications.—In the greater number of cases the corneal tissue again recovers its transparency almost entirely, but on close examination with a lens, by bright illumination particularly, opaque tissue may be detected and a fine network of lines representing the

site of the blood-vessels can be made out. In many cases the tissue of the cornea does not appear to have been greatly affected by the process, but in all cases there is some sclerosis. In the severer cases the cornea becomes thin, bulges, and its diameter is increased. A portion of the cornea only may become sclerosed and ectatic.

Parenchymatous keratitis is not infrequently accompanied by involvement of the sclera and of the anterior portion of the vascular membrane of the eye—iris, ciliary body, and chorioid.

Treatment.—The treatment must be local and constitutional. The local treatment consists in the use of atropine for the purpose of maintaining dilatation of the pupil; the use, ordinarily, of stimulating applications to induce vascularization of the cornea; modification of the light by dark glasses, of suitable shades, or by keeping the patient in a darkened room.

In many cases of this disease due to inherited syphilis, stimulation is not *necessary* in the early stage; but stimulation, if not necessary, is never harmful, and, in the opinion of the writer, is desirable even in those cases in which the onset is relatively rapid. Stimulation of the corneal tissue is effected (*a*) by the introduction of suitable ointment—the yellow oxide of mercury (1 to 1.5 per cent.) or the bichloride of mercury (1 to 3000), (*b*) by the instillation of stimulating drugs, such as the wine of opium, (*c*) by the inspersion of various powders, calomel, boric acid, or iodoform (if the iodides are being taken, calomel should not be used, or (*d*) by hot applications to the eye, usually moist heat, hot bathing with salt water or a hot solution of boric acid, three or four times a day, fifteen to thirty minutes each time. Steam may also be employed.

General tonic treatment is indicated in all cases. The diet should be wholesome and nutritious. The systemic treatment employed is determined by the cause of the keratitis. Antisyphilitic treatment should be administered in the parenchymatous keratitis due to inherited syphilis. Mercurials have apparently a better effect than the iodides. The mercurial may be administered satisfactorily to children in the shape of calomel, grain 0.1 four times a day. Children bear mercury even better than adults. Mercury may also be introduced by inunction or by deep intramuscular injection if thought desirable.

Parenchymatous keratitis due to acquired syphilis ordinarily does not require stimulation. In other respects the local treatment is like that employed in the inherited form. The constitutional treatment is like that usually employed in acquired syphilis. It should be pushed vigorously. Dionin may be used in the later stage.

Deep Vascular Keratitis (*Salmon Patch*).—This disease of the cornea develops by the advancement of minute vessels from the margin of the cornea into the deep layers of the substantia propria of the cornea. It appears as a uniform pale red or salmon-colored patch occupying a small portion of the margin of the cornea, gradually broadens and extends and advances into the corneal tissue, usually not passing beyond the pupillary margin and seldom involving more than one-quarter of the

circumference of the cornea. A very narrow margin of infiltration precedes the vascular patch. The patch is dense at the margin of the cornea, and becomes gradually thinner until it ceases abruptly at its free border.

Etiology.—Inherited or acquired syphilis. It is probably met with more frequently in acquired than in inherited syphilis.

Symptoms.—The development of deep vascular keratitis is accompanied by symptoms of irritation, slight disturbances of vision and photophobia. The ocular conjunctiva is congested in the vicinity of the vascularization of the cornea.

Fig. 172

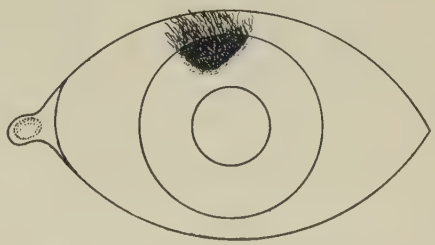

To illustrate the density of the vascularization in salmon patch of the cornea.

Duration.—The condition advances very slowly, and if not interfered with by treatment may last from three to six months.

Resolution.—The cornea again becomes transparent with the exception of a very slight cloudiness. Keratectasia may eventually follow.

Treatment.—Treatment should be local and systemic. Local treatment consists in stimulating the process by bathing with hot solutions (solution of boric acid, 3 per cent., usually being employed), the use of atropine to prevent posterior synechiæ in case of involvement of the iris, and the frequent introduction of some ointment of mercury (yellow oxide, 1 to 2 per cent., the bichloride, 1 to 5000) into the conjunctival sac.

The systemic treatment should be the ordinary antisyphilitic treatment employed vigorously for the first few weeks and continued in a moderate way for some months subsequently.

Infiltration of the Cornea Originating from the Posterior Surface.—In cases where an exudation, a lens dislocated into the anterior chamber, or a cyst of the iris lies against the cornea, an opacity of the cornea may form, gradually progressing through the cornea. The cornea appears to be macerated at the point of contact, the surface slightly elevated above that of the surrounding cornea.

After removal of the cause the opacity persists, but the swelling disappears.

Superficial Punctate Keratitis of Bombay.—This is a name given by Major H. Herbert to a form of keratitis very prevalent in Bombay in warm weather at the close of the rainy season. An encapsulated bacillus, as yet uncultivated on artificial food media, is found in the epithelium of the cornea and is supposed to be the cause of the keratitis.

Death of Corneal Tissue.—This condition due to exposure to extreme cold and wind has been reported (Kurtizin). Ulcers were produced on both corneæ. Healing with slight opacity occurred.

Sclerosing Keratitis (Von Graefe).—This condition accompanies scleritis; is, in fact, an extension of the process into the cornea. The opacity is of a grayish-white color and involves the deeper layers of the cornea. It advances slowly, seldom reaching the pupillary area. The opacification of the cornea does not extend beyond the affection of the sclera at the periphery of the cornea, but if the scleritis entirely encircles the cornea the sclerosis of the cornea may have the same extent and may eventually produce cloudiness of the entire cornea. The density of the opacity is least in the parts farthest removed from the margin of the cornea. The density may vary in the different parts of the sclerosed portion. On the subsidence of the scleritis, the opacification of the cornea subsides to a certain degree. It seldom occurs that the opacification disappears entirely.

In sclerosing keratitis the corneal tissue is at no time thickened; as the opacification disappears, the corneal tissue may become somewhat reduced in thickness. The surface of the cornea usually remains smooth, but in not a few cases the epithelium at the margin of the cornea becomes irregular and some defects may occur in it.

Symptoms.—The symptoms are those referable to the scleritis, and will be described under that heading.

Treatment.—The treatment is the same that is employed in treating the primary affection—the scleritis.

Striated Opacities of Cornea.—After operations necessitating incision of the corneal tissue, as a result of tight bandaging, in some cases of uveitis, disciform keratitis, and ulceration of the cornea, long, narrow, grayish stripes are observed which traverse the cornea in various directions. The striations that follow incisions of the corneal tissue, particularly after cataract operations, commence apparently at the margin of the incision and extend in parallel or slightly diverging lines to a considerable distance from the wound, sometimes traversing the entire cornea. They appear in from twenty-four to forty-eight hours after the incision in the cornea has been made, and apparently reach their full dimensions in from twenty-four to forty-eight hours; they then gradually disappear, sometimes in two or three days, sometimes requiring a much longer time. Cases have been recorded where the grayish lines remained permanently.

Fig. 173

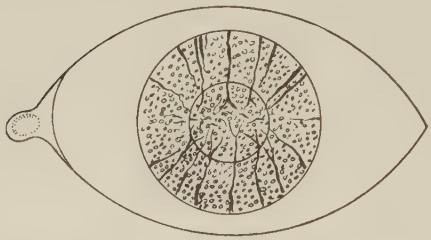

Striate keratitis with deposits on Descemet's membrane in a case of uveitis. Subsequent complete clearing of the cornea. (Author's case.)

The linear opacification may be so slight as not to interfere with vision in any way, or may be sufficiently dense to cause a decided diminution in vision. In striated opacity of the cornea resulting from excessively tight bandaging, uveitis, and disciform keratitis, the lines may cross

each other in all directions. They are usually most marked near the centre of the cornea. In striated opacification accompanying corneal ulcer the striæ radiate from the margin of the ulceration. Knies, Fuchs, Hess, and others attribute this form of striated opacification to *wrinkling of Descemet's membrane,* that occurring after incision of the cornea being due to relaxation of the tension on the membrane at the place of the incision; that from pressure bandage, to a reduction in the tension of the globe or flattening of the cornea. Edema of the posterior lamellæ of the substantia propria may play a part in the production of the wrinkling. In cases in which diffuse cloudiness accompanies the lines there has been some imbibition of fluid into corneal tissue through defective endothelium in the course of the striæ.

Becker and Recklinghausen demonstrated the fact that the lymph channels in the cornea are sometimes distended and that their contents become turbid. These lymph channels, or tubes, extend between the lamellæ of the cornea in straight, branching lines. It has been thought that the channels through which the nerve trunks pass become filled with turbid fluid and form striations in some cases.

Parsons and others have observed corneal striæ occurring in phthisical eyes which were due to irregularities in Bowman's membrane.

Treatment.—There is little to do for this condition. Resolution takes place in the majority of cases and the transparency of the cornea is restored. Only in very rare cases is there any permanent remnant of the opacification.

Gumma of Cornea.—This has been reported (Terson). There was a yellowish localized opacity of the cornea, accompanied by violent iritis. There was no alteration of the corneal level. Under antisyphilitic treatment the infiltration disappeared and gave place to a gray scar.

Hyaline Degeneration of Cornea.—This occurs in some cases of degenerating staphyloma and in eyes with secondary glaucoma. The hyaline masses are developed from the epithelial cells and, according to Sachsalber, from the quantities of elastic fibers which appear at the sclerocorneal margin in staphyloma of the cornea, the elastic fibers undergoing hyaline degeneration; calcareous deposits form in the hyaline mass.

Family Degeneration of Cornea.—Under this heading may be included the various forms of opacification of the cornea which develop in different members of a family and sometimes in successive generations. The condition is hereditary (Freund). The opacification begins from the twelfth to the eighteenth year and becomes stationary about the thirtieth year. Males and females are affected in about the same proportion. The opacity is greatest at the centre of the cornea, never reaching the limbus. The development is extremely slow, beginning as minute dots or lines. "Examination at an early stage shows that the opacity is made up of little light gray streaks and dots, which by transmitted light appear transparent like threads of glass and little drops of water on a glass plate." Fehr[1] is of the opinion that the changes are

[1] Centralblt. f. prakt. Augen., January, 1904.

due to the development of hyaline masses in the superficial lamellæ of the cornea, in which the crystals of phosphate of sodium urate are subsequently deposited.

Fuchs removed a portion of the cornea for examination in one case. He found the cornea softened and Bowman's membrane absent. The deposit was in the substantia propria, and was amorphous.

The figures produced in the cornea differ in different cases. In some the lines predominate. To these cases the names grill-like keratitis (gittrige keratitis, Biber, Haab), lattice-like opacity, trellised opacity, have been given. In some cases the nodules, dots, or punctate spots are most prominent. The names family, punctate degeneration of the cornea (Fehr), and nodular or guttate opacities (Fuchs) have been given to these cases.

Fig. 174 Fig. 175

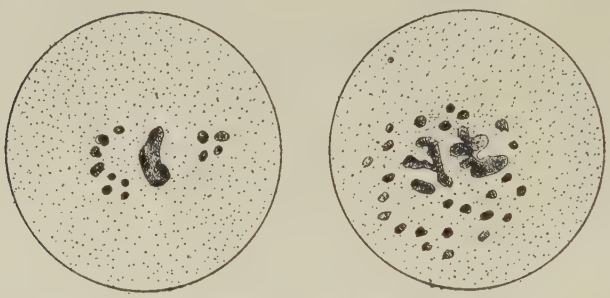

Guttate opacities of the cornea. (Fuchs.)

The opacity advances until vision is greatly reduced. Both eyes are always affected. In some cases the surface of the cornea remains smooth, but in the greater number there is more or less roughness of the surface, the epithelium being elevated over the superficial spots and lines.

Treatment.—Treatment is of no avail.

Affections of the Cornea Characterized by the Deposit of Salts of Lime, Soda, etc., in the Corneal Tissue.—**Sequestrating Cicatricial Keratitis** (*Ulcus Atheromatosum Corneæ*).—Under this name Fuchs[1] describes a condition in which, in consequence of a degeneration of the scar tissue in adherent leukoma, hyaline and calcareous deposits are formed. The nutrition of the overlying epithelium is affected, and it is cast off.

Ribbon-shaped Opacities of the Cornea (*Ribbon Keratitis; Keratitis Petrificans; Trophic Keratitis; Bandolet Keratitis*).—This condition is characterized by the development of a band-like, whitish opacity of the cornea, the zone occupying that part of the cornea most frequently exposed in the palpebral fissure.

Forms.—Two forms are recognized (Leber). The first affects elderly individuals, particularly those with chronic rheumatism. Kalt terms this form "primary zonular opacity of the cornea." Both eyes

[1] Graefe's Arch., liii, p. 61.

are involved symmetrically. The overlying epithelium is usually smooth. Iritis, retinal hemorrhage, and glaucoma have been observed to develop in such eyes. The second form develops in eyes that have suffered from inflammation of the uveal tract with or without ulceration of the cornea, or after glaucoma.

Fig. 176

Ribbon keratitis. (Axenfeld.)

Histology.—The histological conditions are the same in both forms (Leber). Minute hyaline masses and fine granules of the carbonate or of the phosphate of lime are deposited in Bowman's membrane and in the basal epithelial cells in the early stage; later the superficial lamellæ of the substantia propria are invaded. External influences determine the deposition of the lime salts. Bowman's membrane becomes thickened and uneven, the epithelial layer uneven and eventually lost in places. Minute chalky scales may develop and be exfoliated. Very little, if any, inflammatory reaction occurs. The process develops extremely slowly. Vision is much interfered with.

Treatment.—In cases in which the retina is still unimpaired some improvement in vision may be obtained by scraping or cutting the opacity away over the pupillary area and subsequently improving the nutrition of the cornea by hot bathing or other suitable stimulating measures. An artificial pupil may be made for visual purposes.

In atypical cases of precipitation of the phosphate of lime in the cornea, Bernbacher has found that treatment with hydrochloric acid (5 per cent.) neutralized with carbonate of soda (5 per cent.) gives good results.

Deposits of Lime in the Corneal Tissue.—When resulting from burns with lime, these occur in the form of the albuminate of lime (Gullery, Andreæ). They are not to be confounded with the later results of such burns. Gullery obtained good results in the treatment of such deposits by bathing the eye with solutions of ammonium chloride (20 per cent.).

Gouty Keratitis.—In a case reported by Chevallereau, irregular white spots, 1.5 mm. in diameter, appeared in the centre of each cornea, situated in the lamina elastica and substantia propria. One of the deposits was removed and proved to consist of crystals of the urate of soda.

Lead Incrustations of the Cornea.—When collyria containing the acetate of lead are used in the presence of corneal ulcer or abrasion, a deposit of the carbonate of lead in the superficial layers of the cornea may take place. The plaques appear as dense white or slightly yellowish masses, and are permanent.

Treatment.—Schiele recommends nascent iodine obtained by the first action of iodine (3 to 5 per cent. solution) on the iodide of potash (3 per cent. solution). The writer has found it more satisfactory to slice off a thin section of corneal tissue containing the lead deposit.

Silver Deposits in the Cornea.—If a corneal ulcer be cauterized with the nitrate of silver, or if a solution of the nitrate of silver be dropped into an eye in which the cornea is ulcerated, for some days, a deposit in the

corneal tissue of brown oxide of silver may take place. Such a deposit is very persistent and may give rise to slight irritation.

Treatment.—Removal by curetting or by dissection is fairly satisfactory.

Arcus Senilis Corneæ (*Gerontoxon*).—This occurs as a narrow grayish-white crescent or band, which appears at the margin of the cornea. In the early stage crescents appear at the upper and lower borders of the cornea. Both eyes are affected. The band is separated from the limbus by a narrow strip of perfectly clean cornea; the line of transition is sharply cut; toward the centre of the cornea the gray band fades gradually into transparent cornea. This gray band is due to the presence of minute fat globules (Parsons[1]), hyaline masses, and sometimes calcareous granules (Fuchs) in the superficial layers of the cornea. This change, which develops in adults, but may occur in quite young adults, rarely in children, depends on senile partial atrophy of the vessels at the limbus (see page 298). The condition is closely allied to that known as ribbon keratitis, as it occurs primarily in elderly people.

Fig. 177

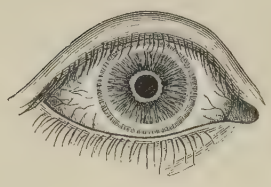

Arcus senilis. (From a sketch by Dr. Herringham.)

Treatment.—Treatment is not necessary. The condition does not extend to the pupillary area, nor does it interfere with the healing of corneal wounds.

Sclerosis and Atrophy of Corneal Margin.—These may develop in connection with arcus senilis (Fuchs) without ulceration.

Lymph Stasis in Cornea.—Rampoldi and, later, Capei have described cases of infiltration of the cornea characterized by the appearance of finely granular and star-shaped opacities, which increased when the head was bent down for ten or fifteen minutes, and decreased very perceptibly, in some cases disappearing entirely, when the head was held erect. This condition occurs in poorly nourished children or adults. In marked cases the vision may be reduced to seeing movements only.

Treatment.—This consists in improving the diet and employing massage. Eserine or atropine is used as may be indicated.

Scabies of cornea has been observed (Saemisch). The condition resembles fascicular keratitis. After using an ointment of the red oxide of mercury, a white mass appears at the seat of the inflammation. Examination with the microscope discloses the presence of a female acarus scabei and ova.

Acne Rosacea of Cornea.—This may occur in connection with acne rosacea of the skin and of the conjunctiva (Capauner). Women are most frequently affected.

Treatment.—The local application of calomel and the galvano-cautery are the best measures to employ to destroy the conjunctival and corneal infiltrations.

[1] For an exhaustive discussion of the subject, see Parsons' Pathology of the Eye, vol. i, p. 230.

Toxic Keratitis.—Punctate superficial corneal infiltration and erosions of the cornea have been observed in patients who have used antipyrine freely, applying it to the skin of the face and taking it internally (Inouye). The lesion disappears when the drug is discontinued.

Ectasiæ.—The classification adopted by Fuchs is a very excellent one. He divides ectasiæ into those of inflammatory origin, which include staphyloma and keratectasiæ; those of non-inflammatory origin, which include keratoconus and keratoglobus.

Staphyloma.—Staphyloma may be either *partial, total,* or *multiple.* Staphyloma is a protuberant cicatrix the result of a perforating ulcer of the cornea with involvement of the iris. The iris may be simply incarcerated, but it is usually primarily prolapsed. After a perforating ulcer of the cornea the cicatrix that forms may bulge as healing progresses, this is termed *primary staphyloma;* or the cicatrix may be flat and bulge subsequensly, *secondary staphyloma.* The shape of the staphyloma is usually conical, particularly in the partial form; in total staphyloma it may be spherical; the edges are often abrupt, they may even overhang. The degree of the protrustion varies greatly. In certain staphylomata cicatricial bands develop across the surface, extending in various directions, producing a lobulated condition, *racemose staphyloma.*

Fig. 178

Staphyloma.

Staphyloma may develop either because of the protrusion of the cicatrix due to the normal tension of the globe, the tissue being too weak to withstand the pressure; or, as is most frequently the case, because of an increase of intra-ocular tension—a condition of secondary glaucoma. In cases where the entire pupillary margin of the iris is involved in the cicatrix, the communication between the anterior and posterior chambers is shut off; an increase in tension naturally follows because of a closure of the filtration angle.

Pathology.—The iris always lines the posterior surface of the protruding portion. Superimposed on this layer of iris is a layer of cicatricial tissue *plus* the elements of the cornea that have not been destroyed by the ulcerative process. Covering this is a layer of epithelium. The epithelial layer is thickened and irregular. The thickness of the staphyloma varies in different parts, depending on the amount of cicatricial tissue formed and on the amount of corneal tissue present. At the apex of the staphyloma no corneal tissue is found. The walls of the staphyloma may be extremely thin, perhaps one-third of the thickness of the normal cornea; or they may be thick and dense, and contain calcareous deposits. Accompanying the protrusion of the cicatrix of the cornea there may also be a general enlargement of the globe.

Consequences.—In the early stages of the formation of staphyloma vision is interfered with in proportion to the extent of opacification of the cornea and the involvement of the free margin of the iris. Unless secondary glaucoma supervenes, perception of light is maintained because of retention of the integrity of the deeper tissues of the globe. If there is increase in tension the staphyloma continues to enlarge, the retina, chorioid, and the ciliary body become atrophic. In many cases the transparency of the lens is lost; the lens shrinks and in some cases is transformed into a thin, opaque disk. In large staphylomata the apex is frequently exposed and becomes ulcerated, and spontaneous perforation may occur. The apex sometimes takes on a cutaneous condition. Ectropion of the lower lid sometimes results. Partial staphyloma is self-limited in a large number of cases. Total staphyloma is progressive.

Treatment.—During the process of healing of a perforating ulcer of the cornea, a compress bandage should be retained until a firm, flat cicatrix is formed. The eye should be examined from time to time, and if there is any evidence of increased tension or any evidence of bulging of the cicatrix a broad iridectomy should be made. After a staphyloma has formed, if it is partial and if the anterior chamber has not become entirely obliterated, excision may be practiced in connection with the iridectomy. It is frequently better to make a curved incision with the convexity below, and, if the wound does not gape sufficiently, to excise a small crescent-shaped piece of the staphyloma. The eye may then be bandaged and the bandage retained until a firm cicatrix has formed. It may be necessary to remove the lens in some of the cases treated in this manner.

Ablation of the apex of the staphyloma may be practised in partial and in total staphyloma, the lens being removed at the same time. The gape thus produced may be permitted to close under a compress bandage, or it may be closed with sutures. In extensive staphyloma a very excellent plan is to close the opening by means of the conjunctiva, with or without a primary closure, with catgut sutures. In closure by means of the conjunctiva, the conjunctiva is dissected away from the globe, beginning at the limbus, and then either by a continuous (tobacco pouch) suture or by interrupted sutures drawn over the wound and the margins brought together.

In not a few cases of total staphyloma, ablation of the staphyloma simply does not suffice.

Removal of the contents of the globe (exenteration) or enucleation must be resorted to. (See chapter on Operations.)

Keratocele.—Keratocele is a condition due to the bulging of Descemet's membrane, accompanying an ulcerative process that has destroyed the anterior layers of the cornea. It presents as a transparent bead-like bulging of Descemet's membrane in the centre of a grayish area—the infiltrated margins of the ulcer. Keratectasiæ may follow keratocele as a result of the deposition of cicatricial tissue over the protruding portion of Descemet's membrane. Ordinarily, keratocele ruptures,

incarceration or prolapse of the iris follows with the subsequent formation of adherent leukoma.

Keratectasia.—By this term is meant a bulging of the cornea as a result of inflammation without perforation and without involvement of the iris. The condition may follow interstitial keratitis, ulceration of the cornea, softening of the cornea accompanying pannus, and a thin cornea due to filamentous keratitis. An opacity is always present at the apex of the protrusion. Keratectasia is almost always partial.

Results.—Vision is disturbed not only on account of the opacification of the cornea, but also because of the irregularity of the curvature of the cornea affecting the pupillary area.

Treatment.—Keratectasia may be treated as partial staphyloma, by incision followed by a compress bandage, ablation of a crescent-shaped piece of the corneal tissue, or by superficial cauterization. In cases where the opacity occupies a large portion of the pupillary area, iridectomy for reduction in tension as well as for visual purposes may be resorted to.

Keratoconus (*Conical Cornea; Staphyloma Pellucida*).—This condition resembles keratectasia; it, however, is unassociated with inflammation, and does not present opacification of the apex until the condition has reached an advanced stage. It is due to a thinning of the cornea and the inability on the part of that membrane to withstand the intra-ocular tension. It develops in those who suffer from malnutrition, those debilitated by illness, and occasionally in those who use the eyes excessively for close work. Females are more frequently affected than males. Keratoconus begins between the ages of twelve and twenty years. It is self-limiting, development ceasing between the ages of twenty-three and thirty years. The apex of the cone is always just below the horizontal meridian of the cornea, the position of the apex being influenced by the pressure of the upper lids.

Fig. 179

Keratoconus.

Symptoms.—The development of keratoconus is brought to the notice of the patient by the effect on vision. With the bulging of the cornea, myopia and astigmatism are produced. The patient seeks relief and is supplied with glasses, which soon require change. With advance in the condition vision becomes much impaired. Because of the conical shape of the cornea, satisfactory relief cannot always be obtained by glasses. The change in the shape of the cornea advances in many cases until the conical condition is very marked. Pulsation of the cornea synchronous with the beat of the heart may be observed in some cases. Spontaneous perforation and resolution do not occur.

Diagnosis.—In the very early stage of keratoconus diagnosis is not easy, but careful examination by means of the ophthalmometer and by Placido's keratoscope makes the diagnosis possible.

Treatment.—The use of glasses in the early stage is advisable. The writer has found the following procedure to give good results. He would not advise it in cases with vision $\frac{20}{70}$ or better. (1) Small, complete iridectomy upward. (2) Cauterization of the apex of the cone without perforation, the area cauterized being sufficiently large and of oval shape, the long axis vertical and the greater part of the cauterized area lying below the apex of the cone. The cauterization should be done some days after the iridectomy. (3) Bandaging after the cauterization preceded by the use of eserine, $\frac{1}{3}$ per cent., in liquid vaseline.

Improvement in vision may be obtained by the use of the stenopeic slit. Raehlman's hyperbolic lenses are of service in some cases. In advanced cases improvement in vision may be obtained by many methods calculated to produce cicatricial contraction of the cornea. This may be brought about by puncture of the apex, by the excision of a portion of the tissue at the apex, as well as by the use of the cautery. The trephine for removing a small circular portion at the apex of the cornea has been resorted to. Operative measures affecting the apex of the cornea increase the opacification, which is in almost every case at the lower border of the pupillary area.

Buphthalmos (*Hydrothalmos, Keratoglobus, Megalocornea*).—This affection consists in the uniform enlargement of the globe. It appears at or shortly after birth, and is supposed to be due to congenital glaucoma. The condition usually affects both eyes. It progresses extremely slowly. In buphthalmos the diameter of the cornea is increased, the curvature of the cornea is less acute, the anterior chamber usually deeper. The lens frequently becomes dislocated and, as the disease advances, vision is slowly reduced and sometimes entirely lost. In some cases the cornea remains clear (*keratoglobus pellucida*); in others it becomes cloudy (*keratoglobus turbidus*).

Treatment.—Treatment is of little avail. The general condition of the patient should be improved as much as possible. Should the tension of the globe be increased, pilocarpine or eserine may be employed. Iridectomy may be resorted to with good effect in favorable cases. At the best the prognosis for satisfactory vision is unfavorable.

Wounds of Cornea.—These may be classified as non-perforating and perforating.

Non-perforating Wounds.—1. *Contusion of the Cornea.*—This may occur from direct pressure or as a result of a blow on the eye with a blunt object. Wounds of this nature are accompanied by pain only at the time of injury. *Diffuse opacity* of the cornea may follow shortly after the contusion, due to disturbance of the corneal elements and edematous infiltration. This clears up after a few days or weeks. Rupture of Descemet's membrane has been observed as a result of contusion. This is followed by a permanent white cicatricial band in the cornea corresponding with the rupture.

2. *Abrasion of the Cornea.*—This usually occurs as a result of glancing blows from any object, finger nail, edge of cuff, twig, etc. These injuries are usually harmless unless the corneal tissue becomes infected, when great damage may be done. Recurrent erosion (see page 288) may follow this form of injury. Erosion of the cornea is followed by intense irritation due to the sudden exposure of terminal sensory nerve filaments. This continues until the surface is again covered by epithelium, except in cases of infection, in which event the intense irritation disappears to a great extent when the deeper layers of the cornea are invaded.

3. *Incised and Lacerating Wounds.*—These are occasioned by any object with sharp edges that may come in contact with the cornea. The pain is not so severe as that which follows abrasion, but is in proportion to the area of sensory nerve filaments exposed. The great danger from these wounds is infection.

Treatment.—Contusion of the cornea needs no particular treatment. Abrasions and incised wounds should be cleansed as thoroughly as possible, using antiseptic solutions, of which the bichloride of mercury (1 to 5000) is excellent. The comfort of the patient will be quickly secured by introducing a bland, sterile, antiseptic ointment or oil and applying a light compress bandage.

Perforating Wounds.—These injuries are very frequently, but not always, accompanied by injury to deeper structures. Punctured, incised, lacerating, and perforating wounds are often infected wounds.

Treatment.—All possible precautions must be employed to cleanse such wounds and to treat them antiseptically to prevent infection. Lacerating wounds may require suturing. The suturing of corneal tissue to close gaping wounds is usually quite successful. It is advisable to keep both eyes quiet by means of a dressing (bandage) applied to both eyes until healing is assured.

Foreign Bodies in Cornea.—When a foreign body strikes the cornea, if the sensitiveness of the cornea is normal, the eyelids close involuntarily. If the foreign body is not fixed in the corneal tissue, it will fall into the lower cul-de-sac or become fixed on the conjunctiva of the upper lid. If the foreign body remains attached to the cornea or embedded in its tissues, a scratching sensation in the lids, usually the upper lid, is experienced, which is repeated whenever the eye is opened or closed. The foreign body may be simply adherent to the epithelial layer; it may penetrate the epithelium and project from the surface; it may become totally embedded in the cornea, or it may pierce the corneal tissue and project into the anterior chamber. Particles that enter the cornea do not, as a rule, produce discoloration of the corneal tissue; however, a hot cinder produces an eschar which, after the removal of the cinder, appears as a circular ring of brown, necrotic, discolored tissue.

The presence of a foreign body on the cornea is accompanied by photophobia, lachrymation, and often by pain that does not entirely depart even when the lids are kept quiet—pain referable to the eyeball and to the corresponding side of the head. Soon injection of the ocular

conjunctiva develops; this injection may be very mild or it may be quite marked, varying according to the degree of irritation produced. If the foreign body is permitted to remain in the cornea, it may become loosened in a few hours or days and be removed from the cornea by the mechanical action of the lids. It may have carried microörganisms into the tissues of the cornea, producing ulcer. The defect in the cornea may become invaded by germs from the conjunctiva, which, gaining entrance into the tissues of the cornea, may set up a destructive keratitis.

Treatment.—After instilling a drop of cocaine (4 to 10 per cent. solution), the removal of the foreign body may be attempted. Foreign bodies, if superficially embedded, can often be removed by means of a small probang of absorbent cotton wound around the end of an applicator. If the foreign body is firmly embedded, it must be lifted from the corneal tissue by means of a spud or sharp-pointed foreign body needle (Fig. 180). In certain cases it is necessary to cut the corneal tissue about the margin of the foreign body to get beneath it to lift it out. In cases where the foreign body has penetrated the cornea and projects into the anterior chamber, it is at times necessary to support the foreign body from behind while the tissues are cut away sufficiently to enable the surgeon to grasp the foreign body with small forceps. The magnet is very useful in the removal of deeply embedded magnetic foreign bodies. After the removal of the foreign body, the defect in the cornea occasions the individual some annoyance until the epithelium has extended over the affected area. During this time the eye should be cleansed from time to time with an antiseptic solution (boric acid, 3 per cent.). If infection is feared, more energetic antiseptic measures should be employed.

Fig. 180

Foreign body needle and spud.

Blood-staining of Cornea.—Blood-staining of the cornea sometimes follows injuries to the eye which result in hemorrhage into the anterior and posterior chambers.

Etiology.—The pigmentation of the cornea is primarily due to the entrance of hemoglobin in solution into the corneal tissue by way of Fontana's spaces, the hemoglobin being the result of the disintegration of red blood corpuscles. It permeates the lymph canalicular system of the cornea, and there undergoes a change into hemosiderin, an insoluble product which is deposited in the corneal tissue in the shape of minute irregular octahedron crystals. These crystals occupy not only the spaces between the lamellæ, but the spaces between the connective-tissue bundles and fibers of the cornea.

Symptoms.—The color of the cornea at an early stage is olive, with a tendency to red. This soon becomes a deep brown. The staining of the cornea occupies the central portion, reaching almost to the limbus in marked cases. At the limbus an annular ring of transparent cornea is found, measuring one-half to one and one-half millimeters in width. The transparent ring of cornea is due to the removal of the hemoglobin from the corneal tissue by absorption into the marginal blood-

vessels; also to the fact that the alkalinity of the cornea is maintained at the periphery through the influence of blood in the capillaries of the limbus conjunctivæ. The staining of the cornea develops relatively slowly after the first appearance is noticed. It may take from one to four weeks for it to reach its height. In some cases the staining of the cornea remains with but little change for months, but in many, absorption goes on slowly, and eventually the cornea may regain its transparency. Accompanying this condition there may be secondary glaucoma, with loss of vision and pain, depending not on the condition of the cornea, but on the condition of the eye itself.

Treatment.—There is no treatment aside from stimulation by moist heat that is of value in this condition. Frequently the condition of the globe is such that enucleation becomes necessary.

Burns of Cornea.—Burns of the cornea may be thermal or chemical. Thermal burns are not very infrequent. They are due to the entrance of molten lead, cinders, steam, burning gunpowder, matchheads, etc. Molten metal impinging upon the cornea seldom does much harm, but may destroy the eye. The metal usually escapes from the eye at once or falls into the conjunctival sac, where the greater damage is done. Glowing embers alighting on the cornea may become adherent and destroy the corneal tissue to some depth. Ordinarily the burn is superficial. Glowing cinders that fly into the eye sometimes become embedded in the cornea, rendering necrotic the tissue that comes in direct contact with the cinder. Before recovery takes place this necrotic layer of tissue must be cast off. Steam entering the eye may destroy the epithelial layer in the portion of cornea exposed, usually a narrow strip lying in the horizontal meridian corresponding to the palpebral fissure.

Treatment.—The treatment consists in cleansing the eye and instilling an antiseptic or aseptic oily preparation sufficiently often to protect the affected area—usually three to four times daily. Olive oil or vaseline with 5 per cent. of boric acid may be used.

Gunpowder Burns.—Burns from gunpowder usually result in the lodgment of embedded grains of powder in the cornea and the consequent pigmentation.

Treatment.—The granules that can be readily reached may be picked out with a foreign-body needle. The cornea may then be treated as advised in similar burns of the lids (see page 185). Jackson uses a small galvanocautery. The result is a minute scar.

Chemical Burns.—Burns of the cornea from acid usually affect the entire surface of the cornea, turning it a grayish hue, destroying the epithelium, the superficial layers of which soon become detached. With burns of this character there are usually some secretion from the conjunctiva and increased lachrymation, some swelling of the lids, the appearance presented indicating a grave lesion. As a matter of fact, burns from acids are usually recovered from with very little loss of tissue or permanent injury to the eye.

Treatment.—The treatment consists in thoroughly cleansing the eye, using weak alkaline solutions (bicarbonate of soda or very weak

ammonium), and, as in burns due to thermal agencies, the instillation of an oily substance.

Burns Due to an Alkali.—These are most frequently occasioned by the entrance of quicklime into the eye (Fig. 181), but may be due to the entrance of caustic potash, soda, or ammonium. The fine particles of lime become embedded in the corneal tissue and the escharotic action is continued for some time. When first seen the affected area presents a grayish discoloration, frequently not very dense. The appearance of the cornea as first presented usually induces a more favorable prognosis than is warrantable. The opacification in almost all cases increases in intensity as the healing process advances. This is also true to some extent of the other alkalies mentioned.

Fig. 181

Burn with quicklime.

Treatment.—In the cases of burn from lime, the treatment is to free the cornea as rapidly as possible from particles of lime by washing with olive oil, which is probably the most suitable for this purpose. After the particles of lime have been removed the eye should be filled with a syrup of cane sugar, as sugar forms an insoluble compound with lime, and thus prevents the extension of the destructive process. The subsequent treatment of burns from lime is like that of burns with acids and thermal agencies. The objects to be attained are rapid and painless healing with minimum loss of tissue, and the prevention of symblepharon. Frequent instillations of oily antiseptic preparations into the conjunctival sac and the application of light compress bandages, until healing is well under way, accomplish the first. Frequent detachment of the eyeball from the lids (once in twenty-four hours) by means of probes, or the wearing of a suitable shell or plate will serve to accomplish the latter in many, but not in all cases.

Tumors of Cornea.—Very few tumors originate in the cornea. The greater number of growths that appear on the cornea are extensions from adjacent tissues, that is, from conjunctiva, sclera, or iris. The tumors observed are dermoid, fibroma, myxoma, papilloma, endothelioma, and sarcoma.

Dermoid (Teratoid) Tumors.—Such tumors strictly limited to the cornea are seldom seen. They are congenital, pale in color, elevated,

slightly vascular, and contain some glandular tissue. The epithelium is stratified and may be corneous; hairs are seldom present.

Treatment.—Excision.

Fibroma.—This is also rare. The greater number of cases consist of hyperplastic scar tissue originating after injury to the cornea. They have been spoken of as keloid growths. True fibroma of the cornea has been described growing from the centre of the cornea. The tumors are sometimes pedunculated.

Treatment.—Excision.

Myxomata or Polypoid Growths.—These sometimes follow suppurating wounds of the cornea or a perforating corneal ulcer. They are reddish, pedunculated, smooth, globular masses, sometimes reaching the size of a cherry.

Treatment.—Excision.

Papilloma.—This appears in two forms: (1) Warty or horny papilloma, which appears as a pale elevation, sometimes flattened and sometimes hemispherical, and grows very slowly; it is unattended by irritation of moment. (2) Soft, red, villous papilloma, having a fairly uniform height of from 2 to 3 mm. The surface is described as mammillated or cauliflower in form; ocular conjunctiva injected; mass usually bathed in scant mucoid or mucopurulent secretion; growth quite rapid.

Nearly all of these tumors take their origin at the limbus, but they may spring from the cornea. They do not produce metastases.

Anatomical Appearance.—Both forms are made up of true papillæ. The first form shows but little evidence of irritation. The epithelium is in a thick stratified layer and may be corneous. The second form is composed of delicate, long papillæ; epithelial layers thin; small-cell infiltration at the base and in the superficial lamellæ of the cornea. The blood-vessels are in and above Bowman's membrane. In some cases there is staphylococcic infection.

Treatment.—If the entire mass is thoroughly removed and the base cauterized, a cure may result; however, it is necessary to remove every vestige of the growth as recurrence is sure to follow if this is not done. Tumors of this nature have been described as angiocarcinomata because of the great tendency to recur.

Epithelioma.—This occurs as a grayish, slightly elevated mass, with an irregular surface, which advances slowly from the limbus. It is seen in adults of advanced years. It is not painful and is unaccompanied by marked symptoms of irritation. It invades the deeper structure of all the tissues in which it develops.

Treatment.—Excision in the very early stage followed by treatment with the *x*-rays. Radium without excision. In cases of much involvement of tissue, the globe and orbital contents should be removed.

Endothelioma (*Perithelioma*).—A very few tumors of this variety have been observed. The mass develops from the limbus, is grayish in color, slightly elevated, covered with corneal epithelium. The cells of the growth are contained in ill-formed alveoli.

Sarcoma.—Primary sarcoma of the cornea has been described (Fumaguli Rumschewitsch), but it is extremely rare. The growth almost invariably springs from the limbus. It may be pigmented or non-pigmented, and varies in color from a gray to a dark red. Its rapidity of growth determines the degree of vascularity and evidence of irritation present in the surrounding tissues. But little pain is experienced. Young and middle-aged adults are affected. A history of an injury preceding the growth is usually obtained. The growth is, as a rule, extremely slow in the early stage; it may become very rapid.

Treatment.—Thorough excision; radium. If a recurrence takes place the globe and contents of orbit should be removed.

Corneal Cysts.—Cysts of the cornea (Fig. 182) may develop in the epithelial layer, between superimposed conjunctiva in cases of pseudopterygia and in the parenchyma of the cornea. They may be multilocular. Those forming in the epithelium are usually small. They develop in eyes affected with secondary glaucoma and in staphylomatous eyes. When large, the condition resembles bullous keratitis.

Fig. 182

Cyst of the cornea. (Collins.)

Cysts forming under pseudopterygia are due to inclusion of epithelial cells. They may attain to a considerable size. The wall of the cyst is lined with an irregular, usually thin layer of epithelium.

Cysts in the parenchyma of the cornea are, as a rule, implantation cysts, following a wound of the cornea; the healing of the wound results in inclusion of epithelium, the upper borders of the wound closing over some deep epithelial cells. These proliferate between the lamellæ of the cornea. The centre of the mass of cells disintegrates and a cavity lined with epithelium is formed. The cavity contains clear fluid and detritus. Such cysts form after incised wounds of the cornea, as for iridectomy (Gruening) and cataract operations.

Cysts lined with endothelium may form in a similar manner, the endothelium being derived from the endothelium of Descemet's membrane or the ligamentum pectinatum. Oatman is of the opinion that atrophy of corneal lamellæ from malnutrition may result in an increase in the area of preëxisting lymph spaces, their walls being covered by endotheliod cells derived from the corneal cells. The loose arrangement of corneal lamellæ not infrequently seen in staphylomatous corneæ is due to edematous dilatation of lymph spaces. They are not true cysts. Corneal scars involving the iris may become cystic; in these cases the cyst may have a pigmented lining.

Diagnosis.—It is not always easy to differentiate between a cyst of the cornea, especially when it occurs at the limbus, and a staphyloma. In suspected cases it is best to aspirate by means of a hypodermic needle or to tap the cyst.

Treatment.—Excision of the outer wall of the cyst, when it is situated superficially, is all that is required. Deep-seated cysts may be opened and the lining cells destroyed by the cautious application of carbolic acid.

Aniline Staining.—Workers in aniline factories sometimes suffer from staining of conjunctiva and cornea, the latter to such a degree that vision is much interfered with (Mackinlay). Injuries of the cornea with aniline pencils may produce deep and quite persistent staining.

Treatment.—Praun found that aniline staining could be cleared up by the instillation of a 3 per cent. solution of hydrogen peroxide (Merck).

Some of the Results of Destruction of Corneal Tissue and Their Treatment.—**Leukomata.**—Thiosinamin, said to be a general glandular and leukocytic stimulant (Suker), is recommended for the reduction of the opacity of the cornea. It is taken internally in 1 to 3 grain doses, twice or three times daily, for a long period of time.

A concentrated solution of citric acid is employed by Simi. The drug is pencilled on to the opacity every day. After a number of days the scar is replaced by a depression. This is allowed to fill. If the opacity has not disappeared the process is repeated.

Stevenson treats corneal opacities by electrolysis. The cathode is applied in the form of a small silver rod with rounded end to the opacity in the cornea and a current of from one to four milliamperes is permitted to pass for a few minutes at each sitting.

Hubert employs bipolar electrolysis.

Tattooing.—This is resorted to for cosmetic purposes.

CHAPTER IX.

THE SCLERA.

DISEASES OF THE SCLERA.

Congenital Pigmentation.—Congenital pigmentation of the sclera (melanosis scleræ) occurs in patches and in spots; the patches are most common near the sclerocorneal margin, the spots being most marked about the minute canals for the passage of the anterior ciliary vessels. The corneal margin of the sclera is not uncommonly pigmented; particularly is this the case in the negro.

Scleritis.—Inflammations of the sclera are of relatively rare occurrence.

Classification.—Scleritis is divided clinically into two forms: *episcleritis*, (*a*) fugacious and (*b*) persistent; and *deep scleritis*. The conjunctival and subconjunctival tissue are always involved, where they overlie the inflamed sclera.

Episcleritis.—**Fugacious Episcleritis** (*Episcleritis Partialis Fugax*).—A transient inflammation of the episcleral tissue sometimes occurs, the attack being characterized by the appearance of an injected area with slight elevation of the conjunctiva; the area usually occupying from $\frac{1}{6}$ to $\frac{1}{5}$ of the anterior half of the surface of the sclera. The development of the inflamed area is accompanied by symptoms of irritation, manifested by an increase of lachrymation, very slight mucoid secretion, slight pain in the eyeball, radiating to the temple and forehead, and photophobia. The irritation is increased on the use of the eyes for close work. The inflammation reaches its height in from three to four days and then gradually subsides, every trace having disappeared at the end of a week or ten days.

The affection is met with in individuals at the age of puberty and in adult life.

Etiology.—A lithemic diathesis, undue use of the eyes, eye strain consequent on imperfectly corrected errors of refraction and imbalance of the ocular muscles, exposure to inclement weather, use of the eyes in a very bright light, disturbance of digestion—all may contribute to bring on an attack. A history of rheumatism or gout is obtained in many cases.

Treatment.—Treatment consists in correcting any error of refraction that may exist, in correcting the condition of the system which predisposes to this affection and in protecting the eyes from the influence of bright light when this is a cause. Salines, potassium iodide, and the

salicylates in particular, are often of much value in bringing about recovery.

Persistent Episcleritis.—This form is characterized by the development of inflamed, sensitive areas at or near the margin of the cornea, which are elevated. The affected areas may be single or multiple; they are of a deep red or purplish hue. The blood-vessels of the conjunctiva overlying the inflamed area are enlarged and injected. The inflammation advances slowly without ulceration, and is attended by pain and irritation that are much more severe in some cases than in others. Photophobia is also experienced. One or both eyes may be attacked; fresh areas may be involved before the subsidence of the process in the part first affected.

Etiology.—Rheumatism and gout. The tubercle bacillus rarely. In some cases the cause is obscure. It is probable that digestive disturbances are accountable for some of the cases.

Duration.—The affection usually persists from six to eight weeks, but may continue for a much longer period. Recurrences are the rule; another attack may occur immediately after the subsidence of one attack or may not occur until years have elapsed.

As a result of the inflammatory process the sclera may become thinned and the uveal pigment may show through, but recovery may take place without leaving a trace. This disease usually attacks adults, but may occur at the period of adolescence.

Prognosis.—The prognosis is favorable, as a rule. In rare cases ectasiæ, with inflammation of the deeper structures, may result.

Treatment.—Reuss advocates the use of the constant current. Scarification has been advised in the cases where pain is severe, and ointments of various kinds are employed. The process is most favorably influenced by internal medication consisting of the salicylates, iodide of potassium, and the mercurials in small *long-continued* dose. In cases of tuberculous origin, the use of tuberculin should be resorted to.

Deep Scleritis—The deep form of scleritis cannot be readily distinguished, in its onset, from the superficial form except in degree of severity; pain accompanying deep scleritis is usually more severe. The affected area is of a deep red or purplish hue. The elevation is somewhat more pronounced. The affected area is larger and may extend around the entire cornea (annular scleritis).

Inflammation of the cornea in the vicinity of the affected area frequently accompanies deep scleritis; the iris, ciliary body, and anterior portions of the chorioid may also be affected. The process usually attacks both eyes; it progresses extremely slowly.

The change that takes place in the sclera is one which leads to attenuation (sclerosis) of the tissue of the sclera, reduces it in thickness and in its power of resistance, so that it cannot withstand the normal intraocular pressure and becomes ectatic. The bulging of the sclera is usually irregular; seldom extends around the entire cornea, but does so in a few cases, resulting in pushing the entire cornea forward. The ectasia occurs during and after the subsidence of the inflammation.

When the scleritis subsides the affected area presents a dark blue appearance on account of thinning, which permits the pigment of the uveal tract to show through. Disorganization of the interior of the globe is observed as an accompaniment of the formation of the staphylomatous protrusions (Fig. 183).

Fig. 183

Ciliary staphylomata.

Etiology.—The tubercle bacillus is probably the most frequent cause. Other causes are as in other forms of scleritis.

Sclerokerato-iritis (*Scrofulous Scleritis, Anterior Uveitis*). — This condition is one closely allied to deep scleritis, but differs from it in that the whole anterior segment of the globe is affected. The inflammatory process begins usually at or near the sclerocorneal conjunction, involving the cornea, the iris, ciliary body, and anterior portion of the chorioid.

Etiology.—As in deep scleritis.

Symptoms.—In addition to the appearances and symptoms that accompany scleritis and sclerosing keratitis, symptoms peculiar to involvement of the anterior portion of the uveal tract are present. The iris becomes congested, loses its transparency, takes on a dusky hue, and is thickened. The aqueous humor becomes turbid by the transudation of plastic lymph from the blood-vessels of the iris and ciliary body. There is pain, referable generally to the temple and forehead. The anterior portion of the vitreous body becomes filled with flocculi, consisting of fibrin with some cellular elements. The disease progresses very slowly. Both eyes are commonly affected. Individuals in early childhood and at the age of puberty, who suffer from inherited syphilis, or some other debilitating dyscrasia, are most frequently attacked. As a result of sclerokerato-iritis, sclerosis of the anterior portion of the sclera and of the cornea occurs, followed in many cases by sclero-ectasiæ. The ordinary results of severe iritis are also present. The chorioiditis is followed by atrophic changes in that membrane. The ciliary body becomes atrophic and much elongated by the stretching that accompanies the ectatic process. The cornea is thinned throughout the area involved in the sclerosis and becomes more or less opaque. The effect on vision is pronounced, the diminution depending on the degree of opacity and irregularity of the cornea and the interference with the transparency of the media of the eye.

The crystalline lens not infrequently becomes opaque, shrunken, and

the site of calcareous deposits. In consequence of the changes affecting the filtration angle, increase in the tension of the eyeball sometimes develops and secondary glaucoma results; total destruction of vision may follow. The increase in tension may also lead to spontaneous rupture of the globe, the rupture occurring at some point in the ectatic portion.

Treatment.—Treatment directed to the correction of any dyscrasia of the system that may exist should be instituted. Local treatment consists in the endeavor to prevent the formation of posterior synechiæ. Hot bathing with a solution of boric acid and the introduction of a mercurial locally are of service. Ointments of the yellow oxide and the bichloride of mercury appear to be best suited. As a matter of fact, local treatment appears to have little effect in arresting the progress of this condition. In all eyes affected by this disease more or less serious damage is wrought.

Suppurative Scleritis.—Purulent inflammation of the sclera occurs rarely as the result of infection due to the entrance of a foreign body. Staderini[1] reports a case in which the sclera was wounded by a thorn entering near the insertion of the external rectus muscle. A small abscess formed in the tissue of the sclera which, when opened, discharged a piece of thorn. Other parts of the sclera were involved. The disease lasted four months, but complete recovery ultimately resulted. Suppuration following strabismus operations has been reported (von Graefe). Suppuration of the sclerotic from within is more common; it occurs as an accompaniment of purulent chorioiditis. The most frequent site is in the zone pierced by the anterior ciliary vessels, the softening and infiltration proceeding from the minute canals. The writer has observed a case in which, as a result of metastatic purulent chorioiditis, suppuration and perforation of the sclera occurred at the equator, the involvement of the sclera evidently proceeding from the canal for the passage of a vena vorticosa. Microscopic examination disclosed great thickening of the sclera at the margins of the opening and infiltration with small cells.

Treatment.—Suppuration affecting the outer layers of the sclera should be treated antiseptically.

Syphilis of Sclera.—Syphilitic involvement of the sclera is sometimes observed. It manifests itself in the form of gummata, usually affecting the anterior segment of the sclera. Cases have been observed in which the posterior portion of the sclera has been the seat of a gummatous mass.

When gumma of the sclera occurs in a visible portion it presents itself first as a small nodule simulating a large phlyctenule. It increases in size quite rapidly, the elevation becoming pronounced, the base of the elevation being of a deep red color, the congestion extending for some distance into the surrounding tissue. The apex of the elevation is of a yellowish-pink hue. The growth is circular at its base. It may

[1] Ann. di Ottal., vi., 5, 6, 574.

reach a diameter of more than a centimeter. If treatment is not instituted, ulceration takes place at the apex, due to breaking down of the tissue, and destruction of the eye may ensue. The tumor is rather firm in consistence and is elastic. It may be mistaken for sarcoma. A microscopic examination of excised parts may disclose the presence of cells which closely resemble those of sarcomatous tissue. Sarcoma of the sclera as a primary disease is extremely rare, and the presence of a growth such as has just been described should always awaken the suspicion of a syphilitic origin. The history of the case is not always to be relied upon to substantiate the diagnosis. Gumma of the sclera is a manifestation of tertiary syphilis in adults. The writer has never seen gumma of the sclera occurring as a result of inherited syphilis.

Pathology.—The tissue of the sclera is invaded by a small-cell infiltration. Fibers of the sclera are pressed apart and some absolutely disappear. As the process subsides, if scleral tissue has been destroyed it is partly replaced by cicatricial tissue.

Treatment.—Under vigorous antisyphilitic treatment gumma of the sclera subsides with marvellous rapidity, and if the deeper tissues of the globe are not involved, no trace of the tumor is left.

Tuberculosis of Sclera.—Cases of apparent primary tuberculosis of the sclera have been reported, one each by Brailey and Müller, but the occurrence is extremely rare. Tuberculous involvement of the sclera by extension from the uveal tract, from Tenon's capsule, from the optic nerve, and from the cornea may take place. Miliary tubercles or conglomerate tubercle with caseous degeneration may form. Many of the cases of scleritis and sclero kerato-iritis are due to tubercular infection. The writer has observed a number of cases of this character in which the process was very favorably affected by injections of tuberculin, bringing about an arrest of the process after other measures had failed.

Treatment.—If an attempt is to be made to save the globe the system must be put in the best possible condition by an appropriate diet and tonic remedies. Tuberculin subcutaneously, and locally if desired, should be employed. The local treatment is as in sclero keratitis from other causes. Enucleation in hopeless cases.

Leprosy of Sclera.—This is similar to leprosy of the cornea and sclerocorneal margin.

Ossification and Calcification.—Ossification and calcification of the sclera occur in some degenerated eyes.

Posterior Scleritis.—Recognized cases of this nature are rare, as a diagnosis is difficult except after enucleation. Fuchs describes a case occurring in a boy, aged sixteen years, affecting both eyes, accompanied by deep-seated pain. The retina was pushed forward at the macular region and was of a steel gray color. Vision impaired. Recovery in a week. Fuchs attributed the phenomena to an inflammatory process in the posterior part of the sclera, accompanied by swelling of the overlying chorioid and retina. In cases reported by Wagenmann and Salzer the eyes were enucleated because of suspected neoplasm. A

tumor-like thickening of the sclera was found, which was due to inflammatory products in scleral tissue.

Pathology.—The pathology of scleritis is much the same in all of the cases not syphilitic or tubercular. The tissue of the sclera is edematous, the lamellæ separated, and the fusiform spaces filled by fibrin, mono- and polynuclear leukocytes. The blood-vessels are increased in number and size. The lymphatic vessels are dilated and crowded with lymphocytes. In some cases giant cells are found. When these are present, a tubercular or syphilitic origin may be inferred. When the inflammation subsides the cellular elements and blood-vessels disappear, and the structure of the sclera becomes sclerosed.

Malignant Growths of the Sclera.—Primary malignant growths of the sclera are almost unknown. Auerbach (Parsons) reports a case of melanosarcoma which apparently sprang from the pigmented cells of the sclera about a posterior ciliary nerve.

Secondary invasions by sarcoma, glioma, epithelioma, and carcinoma occur, but the invasion is extremely slow because of the structure of the sclera.

Scleral Ectasiæ (*Staphyloma of the Sclera*)—These are most frequently due to scleritis. When intra-ocular pressure only is the cause, equatorial staphyloma usually results. If the weakness is structural and congenital, the staphyloma usually occurs at the posterior pole. Staphyloma not infrequently accompanies neoplasms of the interior of the eye. In certain cases, ectasia of the sclera reaches enormous dimensions, as in the case of scleral cyst accompanying microphthalmos.

Classification.—Scleral ectasiæ are classified as *anterior, equatorial,* and *posterior.* Anterior ectasiæ may be single or multiple. They may be annular, extending entirely around the periphery of the cornea. At the equator the ectasiæ may present the same conditions present in the anterior segment. Posterior ectasiæ are usually single; they frequently include the optic nerve entrance. Scleral ectasiæ present a bluish appearance because of the pigmented uvea which shows through the thinned sclera.

Etiology.—Staphylomata are produced either because of a reduction in the power of the sclera to withstand the normal intra-ocular pressure or tension, weakness of the scleral coat being inherent, or as the result of disease, or are due to an increase in the intra-ocular tension above the normal and above the power of the sclera to withstand.

Treatment.—After ectasiæ of the sclera have developed, treatment is of no avail. As a prophylactic measure in inflammatory conditions which have resulted in the formation of posterior synechiæ, iridectomy as performed for glaucoma is useful. This is of value particularly if increase in tension (secondary glaucoma) develops.

Injuries to Sclera.—The sclera is subject to injuries of various kinds; perforating wounds, incised wounds, lacerating wounds, and rupture of the sclera.

Perforating Wounds.—Perforating wounds of the sclera, if made with sharp and non-infected instruments, are usually of little importance,

provided the perforation is small and occur back of the ciliary region. If, however, the wound is large, permitting prolapse of a portion of the ciliary body, the effect on vision may be disastrous. Non-infected wounds heal rapidly. It occurs from time to time that small perforating wounds of the sclera result in total detachment of the retina, without suppuration and without inflammatory reaction of any appreciable degree. A case in point is that of a woman who, when shaking a carpet, felt a twinge in the eye and found that a carpet tack had pierced the sclera about seven millimeters from the sclerocorneal margin. She removed the tack and presented herself at the hospital within twenty-four hours. At that time a small opening could be detected in the sclera, filled by a bead of vitreous. There was but slight injection of the sclera and conjunctiva. Examination with the ophthalmoscope disclosed the point of entrance of the tack. There was no hemorrhage in the vitreous and very little blood surrounded the opening. The eye was bandaged and the patient returned to her home. No inflammation resulted. In the course of four weeks complete detachment of the retina developed.

Perforating wounds of the sclera may result in infection of the eyeball and loss of the globe by panophthalmitis.

Incised and Lacerating Wounds.—Incised wounds of the sclera, if they occur posterior to the ciliary region and are not of great extent, may be closed either by a scleral or conjunctival suture and recovery may occur with little or no loss of vision. Incised clean wounds of the sclera, even those which involve the ciliary region, may also heal, if properly closed, without loss of vision. In the latter form of wound prolapse of vitreous or of the ciliary body, if it occurs, should be excised.

Lacerated wounds affecting the ciliary body result in almost every case in loss of the eye, removal of the eye frequently not being necessary at once; but as the scar contracts painful symptoms develop, and in some cases symptoms of sympathetic disturbance of the other eye become pronounced and render enucleation necessary.

Treatment.—All cases of wound to the sclera should be treated on strictly antiseptic principles. Under ordinary circumstances the patient, whether suffering from a perforating wound, an incised or a lacerating wound of the globe, should be put to bed and compress bandages applied until recovery is well advanced.

Rupture of Sclera.—Rupture of the sclera occurs in the majority of cases within the zone included in a strip 7 mm. wide from the margin of the cornea. A blow on the eye from whatever source may produce such a rupture. The rupture takes place above most frequently. It occurs in the shape of an irregular line extending from near the margin of the cornea diagonally backward, and measures, in the majority of cases, more than a centimeter in length. The ciliary body and the anterior portion of the chorioid are usually pushed into the wound and present as a dark line following the wound; subconjunctival hemorrhage occurs, which extends to some distance from the wound. The anterior and vitreous chambers are more or less filled with blood. Such wounds frequently occur without any rupture of the conjunctiva, but rupture

of the conjunctiva may take place. Rupture of the sclera is not necessarily confined to the anterior segment of the globe. In rare cases it occurs in the posterior segment of the globe. It is then accompanied by a greater or less degree of exophthalmos, due to the presence of blood in the orbital tissues.

Cases in which the rupture is very slight and does not involve the ciliary region may result in recovery without loss of vision and without a painful globe, but cases of this character are very rare. In the early stage of rupture of the sclera in the ciliary region pain may be relatively slight, and to the inexperienced the prospects of a favorable recovery may appear bright. However, eventually the conditions above described almost invariably develop and enucleation must be resorted to.

Foreign Bodies in Sclera.—Foreign bodies in the sclera are seldom present without perforation and entrance into the posterior chamber of the eye. The result to the sclera is usually a wound simply. When the body has remained embedded in the sclera, it should be removed, its removal being effected by the means ordinarily employed to remove foreign bodies from other tissues of the eye.

CHAPTER X.

THE IRIS.

Function of the Iris.—The pigmented iris, in connection with the pigmented ciliary body and chorioid and the pigment layer of the retina, serves to convert the space enclosed by the vascular tunic into a dark chamber. The function of the iris is to regulate the quantity of light that enters this chamber.

The movements of the iris are involuntary and are made unconsciously. The physiological movements are induced by stimuli which act through certain reflex arcs. When the eyes are exposed to light the pupils become narrow (direct light reflex) to prevent the entrance of an undue quantity of light. When the light is diminished the pupils become dilated to admit sufficient light to carry on the function of vision. The muscles of the iris contract and dilate conjointly and to the same degree. If light enters one eye, the fellow iris also contracts (consensual light reflex). (For description of the reflex movements of the iris, see page 120.) This phenomenon is employed to advantage to determine objectively whether the eye sees or not. In hysterical amblyopia and in the case of malingerers this reaction is very valuable as a means of diagnosis.

Stimulation of the motor oculi nerve causes contraction of the sphincter iridis muscle, with consequent narrowing of the pupil. Paralysis of this nerve causes the sphincter to relax, and widens the pupil. Stimulation of the ciliospinal centre in the cervical spinal cord or of the superior portion of the cervical sympathetic causes contraction of the dilatator iridis muscle, resulting in a widening of the pupil to a greater extent than obtains on paralysis of the motor oculi. Paralysis of the sympathetic causes a narrowing of the pupil (miosis).

Hippus.—Under certain conditions, especially when both eyes are shaded from the light and then quickly uncovered, the patient being placed before a window or other source of light, the pupils will alternately dilate and contract. This change in size of the pupil under uniform illumination and without the influence of accommodation or convergence is known as *hippus*. It is a clonic spasm of the sphincter pupillæ (Fick). It may not be associated with impaired vision, but is occasionally observed in developing cataract. It is sometimes associated with nystagmus, and is also seen in neurasthenia, hysteria, epilepsy, disseminated sclerosis, cerebrospinal sclerosis, in acute meningitis, and in some cases of brain tumor.

ANOMALIES OF THE IRIS.

Corectopia (*Ectopia Pupillæ*).—An eccentric position of the pupil inward and slightly downward is, when of very slight degree, a normal condition. Sometimes it is very pronounced, the pupil being symmetrically displaced inward and slightly upward or downward. The condition is rare; it has been observed as an inherited anomaly, appearing in different members of a family. Ectopia lentis, microphthalmos, coloboma of the chorioid, high degree of astigmatism, and high myopia may be associated with corectopia. Vision may be greatly diminished.[1]

Polycoria (*Multiple Pupil*).—This condition is of very rare occurrence as a congenital anomaly; it is present more frequently as a result of injury or disease. The secondary openings in the iris are small and are placed near the principal pupil. Development of outgrowths from the margin of the pupil may meet and connect the pupillary space with numerous small openings. Complete supernumerary pupils having a sphincter peculiar to each have not been observed.

Fig. 184

Coloboma of iris. (Sichel.)

Coloboma Iridis.—This condition is of relatively common occurrence. It is due to defective closure of the retinal fissure (see page 20), which may affect all of the tissues of the globe from the optic nerve, including the sheath of the nerve, to the margin of the pupil, including chorioid, ciliary body, iris, and sclera (coloboma oculi). Coloboma of the lens is also present in some cases. The defect in the iris may exist alone. The form most frequently observed is approximately wedge-shaped, the base being at the pupillary margin, the rounded apex at or slightly removed from its ciliary border (complete and partial coloboma of the iris).

Position.—The position of the coloboma is almost always downward and inward, rarely inward, and still more rarely upward and inward.

[1] Manz, Graefe's Arch., Band ii, tome 2, p. 92.

The writer has recently observed a case of the latter kind occurring in an infant of three months; both eyes were affected; there was no coloboma of the chorioid. Frost has reported observing a coloboma of iris and chorioid to the temporal side.

One eye is more frequently affected than both, but the preponderance in favor of one eye is not great.

The sphincter pupillæ does not extend above the border of the coloboma to any appreciable degree, consequently is defective at the base of the coloboma.

Congenital coloboma is often a family or inherited defect. Imperfect vision is the rule, due in many cases to opacities in the lens.

Aniridia (*Irideremia*).—Aniridia is classified as partial or total. Partial aniridia is a condition in which a part of the iris only is wanting, one-half or a third remaining, the defect extending to the ciliary border. This condition suggests an exaggerated coloboma, but differs from it in that the defect is very much larger, and is not due to the same cause. Total aniridia and partial aniridia may exist in the same individual. Aniridia (partial) with coloboma has never been observed (Manz).

In the cases that fall under the classification of total aniridia, a narrow rim of iris tissue is often present, extending 0.5 mm. to 1 mm. from the ciliary insertion; the tissue, however, does not possess contractile power. *The pupil* is black or slightly gray, the grayish tone being observable even with perfect transparency of the lens. If the position of the observer and the direction of the light are favorable the red reflex from the fundus oculi is readily seen.

Corneal Defects.—Corneal defects in aniridia, characterized by the apparent encroachment of the sclera onto the cornea, have been observed, also irregularities of corneal curvature; the anterior chamber is usually deep, but cases have been observed (Reute) in which the lens was located close behind the cornea.

Crystalline Lens.—Defects in the lens occur frequently in aniridia. The form of opacification usually seen is anterior and posterior polar cataract. Equational zonular diffuse and complete cataract have been observed. Developmental defects in the suspensory ligament, with subluxation of the lens, are frequently present in these cases, together with strabismus, nystagmus, amblyopia, and photophobia.

Aniridia is almost invariably bilateral; it may be total in one eye and partial in the other. It is often hereditary. Guthrie[1] observed it ten times in four generations of one family. Some of the children of parents, one or both of whom show aniridia, may have normal eyes, while the iris may be wanting in the brothers and sisters. Acquired aniridia may follow choriocyclitis (Manolescu), and the iris may be reduced to a very narrow band in absolute glaucoma.

Persistent Pupillary Membrane.—When the tissue that forms the fetal pupillary membrane is being absorbed (this membrane dis-

[1] Von Ammon's Zeitschrift, v, Psd., p. 78.

appears normally about the seventh month of fetal life), it sometimes happens that bands or filaments of connective tissue, more or less numerous, remain. These filaments apparently represent the remains of blood-vessels. They are attached to the iris at the irregular line or ridge that separates the pupillary from the ciliary zones of the iris, and are often found to be continuous with the radiating folds of iris stroma which lodge the larger iris vessels. The fibers or cords of tissue are usually white, but may be pigmented; they may cross the pupil at the periphery or they may pass to the lens capsule and there terminate separately, or become united and form small, opaque plaques, apparently composed of remnants of the fetal vascular capsule of the lens, as well as the remaining connective-tissue fibers of the pupillary membrane with which it is united. The condition is seldom associated with other congenital defects. Persistent pupillary membrane was observed by Stephenson in 1.7 per cent. of cases examined; by Franke in 0.9 per cent. of cases. It is more frequently unilateral than bilateral. Stephenson collected 68 cases, 55 of which were bilateral, 13 unilateral. Vision is but little interfered with. In the case figured the vision was $\frac{20}{20}$ in each eye with the proper correction. The filaments may be broad and numerous or small and few in number; one or two minute tags of tissue only may be observed. Examination by oblique illumination and with a magnifying lens is an excellent way to observe the condition.

Fig. 185



Remnants of pupillary membrane. (Randall.)

Diagnosis.—The differential diagnosis between this condition and that of filamentous adhesions due to iritis or cyclitis is made by determining the place of attachment of the filaments. Filaments due to exudation are attached to the pupillary margin. The filaments of persistent pupillary membrane have been injected shortly after birth by Jacob, showing that they are remnants of fetal blood-vessels.

Treatment.—None is necessary.

Congenital Ectropion of Uvea.—This is sometimes observed in man. It is common in the horse, pig, and other of the lower animals. The condition is characterized by the presence of small nodular pigmented masses that develop at the pupillary margin and project into the anterior chamber. They are usually multiple and are sometimes mistaken for neoplasms. In rare instances these masses become separated or detached from the iris and float about in the anterior chamber, causing no irritation and eventually disappearing.

Diagnosis.—Congenital ectropion uveæ is to be distinguished from a similar condition resulting from disease of the iris. In the former there is no atrophy of iris tissue, the pupil is of normal size, and is normally situated; in the latter the iris tissue anterior to the uvea is atrophic (Collins), the pupil is dilated and may be irregular; the traction of the atrophic tissue on the non-atrophic uveal layer causes it to present at the pupillary margins (see Glaucoma). Cysts and atrophies are observed as congenital defects very rarely.

Melanoma.—Under the heading of simple melanoma of the iris, Knapp[1] describes a case in an adult, aged thirty-one years. There were three nodules, 3 to 5 mm. in diameter, and three smaller nodules in the iris, of a grayish-brown color and velvety in appearance. These had been noticed fifteen years. They had occasioned hemorrhages into the anterior chamber, but did not interfere with vision, and were considered benign. "Melanoma of the iris is an entirely benign hyperplasia, similar to pigmented warts of the skin, which they resemble also in their tendency to become transformed into melanosarcoma." Small melanotic spots, which are flat and project but little, if at all, above the plane of the iris, and which do not change, are observed from time to time.

Nevi.—Telangiectatic nevi are of rare occurrence. They may include a relatively large area and project into the anterior chamber. Aside from occasional spontaneous hemorrhage, they occasion no disturbance.

Heterochromia and albinism are not very infrequent.

DISEASES OF THE IRIS.

Hyperemia.—Hyperemia of the iris is characterized by congestion of the blood-vessels, increase of the bulk of the iris as a consequence, and a slight change in the color of the iris. One or both eyes may be affected.

Etiology.—Traumatism, such as contused or perforating wounds; exposure to excessive light; infection; gout; dislocation of the lens against the iris; keratitis of every form; foreign bodies in the cornea; cauterization of the cornea; scleritis; diseases of the chorioid and ciliary body. All inflammations of the iris are preceded by hyperemia of the iris.

Symptoms.—The iris presents a deepened color as compared with its fellow, due to excess of blood. In blue irides a greenish yellow, in brown irides a deep, dusky brown color is produced. The pupil is slightly contracted and the anterior chamber very slightly encroached upon by the increase in the volume of the iris. The iris reacts to light more slowly than normal. Very slight pericorneal injection may be present. Slight pain in the temple may be experienced, becoming more noticeable at night. The transparency of the iris tissue is lost to some degree. There is no exudation and no impairment of vision, except, perhaps, a slight appreciation of lack of illumination as a result of the narrowing of the pupil.

Diagnosis.—This is not always easy. The sluggishness of the iris to the various stimuli, slow dilatation when a mydriatic is used, and discoloration will suffice; but the miosis accompanying spinal and cerebral disease must be carefully excluded.

Treatment.—The cause should be carefully inquired into and the proper treatment instituted to remove it. Instillations of atropine should be made and neutral tinted glasses worn.

[1] Intra-ocular Tumors, New York, 1869, p. 298.

Inflammation of Iris (*Iritis*).—Few, if any, inflammatory affections of the iris are strictly confined to that portion of the vascular tunic. The close anatomical relation between the iris, ciliary body, and chorioid and the tissues of the filtration angle unavoidably necessitates involvement to a greater or less degree of these structures. However, when the inflammation affects the iris principally, symptoms are produced which render it desirable to describe such inflammation as peculiar to the iris.

Classification.—Inflammation of the iris may be classified as follows: (1) *Idiopathic*, occurring without assignable cause; (2) *symptomatic*, consequent on disease of other parts of the eye or of the system; (3) *traumatic*.

In regard to the nature of the exudation, iritis is (*a*) serofibrinous (serous), (*b*) spongy, (*c*) plastic, (*d*) purulent, (*e*) hemorrhagic.

In regard to cause, iritis may be classified as (*a*) idiopathic, (*b*) syphilitic, (*c*) rheumatic or gouty, (*d*) gonorrheal, (*e*) due to infectious diseases, as mumps, measles, scarlet fever, diphtheria, typhoid fever, (*f*) diabetic, (*g*) sympathetic, (*h*) tubercular, (*i*) secondary, *i. e.*, accompanying disease of adjacent parts.

Fig. 186

Pericorneal injection.

Common Characteristics in Various Forms.—Iritis of all forms presents certain conditions in common which may be considered collectively.

1. *Pericorneal Injection.*—Except in the very mild cases (quiet iritis of Hutchinson) there is pericorneal injection (Fig. 186). It consists in an injection of the anterior ciliary vessels, namely, those that are derived from the anterior muscular arteries (ciliary injection). This injection is uniform and varies from the faintest flush to a decided redness with slight elevation which may occupy almost, if not all, of the anterior segment of the globe.

2. *Turbidity of the Aqueous.*—This is due to the exudation of serum and fibrin-forming elements from the vessels of the iris and from the vessels of the ciliary body.

3. *Change in Color.*—This is due partly to the turbidity of the aqueous and partly to the congestion of the iris and the presence of exudates in or on the iris.

4. *Impairment of Mobility.*

5. *Impairment of Vision.*—This is due to turbidity of the aqueous.

6. *Miosis.*—The pupil is narrow in all cases of iritis.

7. *Pain.*—This is referable to the eye and to the side of the head corresponding to the eye affected, and is worse at night.

8. *Photophobia and Lachrymation.*—This varies in degree.

9. *Tenderness of the Globe.*—This is not always present.

10. *Tension.*—The tension of the eye in iritis is usually normal or slightly subnormal. Sometimes, on account of the blocking of the filtration angle by the exudate, it becomes increased, necessitating measures for its reduction.

Fig. 187

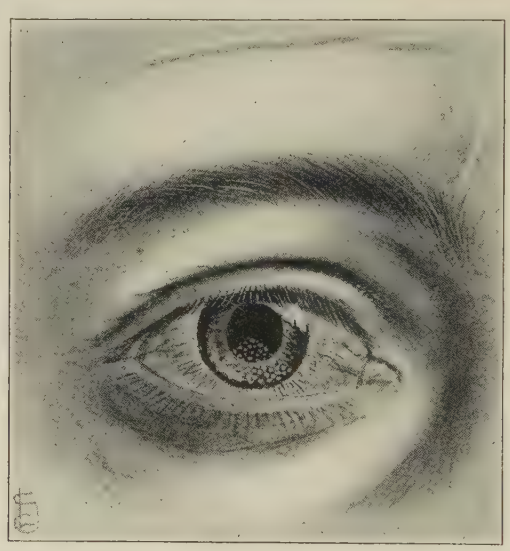

Defects on Descemet's membrane (Descemetitis).

Serofibrinous Iritis (*Serous Iritis*).—This term applies to a mild form of iritis presenting the symptoms enumerated above; also, at times, to forms in which punctate masses of fibrin and small cells become deposited on the posterior surface of the cornea; often in pyramidal form (Fig. 187) (serofibrinous cyclitis, Descemetitis, aqueocapsulitis, keratitis punctata), and on the surface of the iris and anterior portion of the lens capsule. The latter form properly belongs to the diseases iridocyclitis and uveitis and will be described under those terms.

Etiology.—There may be no assignable cause discoverable (idiopathic). It is often observed as an accompaniment of other diseases of the eye, as cyclitis, chorioiditis, sympathetic ophthalmia, intra-ocular tumor, diseases of the cornea. Anemic, poorly nourished females with pelvic and menstrual disorders may present this form (de Schweinitz). It occurs more frequently in females than in males. It may be due to syphilis, rheumatism, infectious diseases, diabetes, and injury.

Pathology.—A scant round-cell infiltration is found in the iris, ciliary body, particularly in the ciliary processes, and in the tissues at the filtration angle. Small, flocculent masses of fibrin are found in the aqueous humor, and fibrin and small cells compose the minute deposits on the posterior surface of the cornea (Fig. 188). The corneal endothelium and Descemet's membrane are normal.[1]

Fig. 188

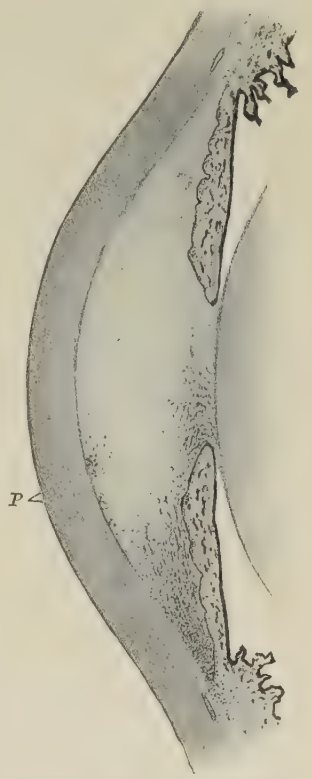

Fibrinous iritis: *P*, precipitates on the posterior corneal wall. (Axenfeld.)

Symptoms.—If the iris is the part principally involved the symptoms are never very severe. They are sufficiently described on page 325.

Duration.—If confined to the iris the process soon subsides without leaving a trace—within a few days or weeks. When complicated with involvement of other parts of the vascular tunic, it may last many months.

Results.—Secondary glaucoma may occur in the course of this affection, necessitating operative procedure.

Treatment.—The cause should be sought and appropriate constitutional treatment instituted. Locally, atropine sufficiently often and of sufficient strength to avoid posterior synechiæ. As there is some danger of secondary glaucoma, atropine must be used with caution and the tension must be watched. Moist heat is of value. The eye should be bathed with a hot normal saline or boric acid solution three or four times daily, one-half hour or longer each time.

Spongy Iritis (*Croupous Iritis*, Alt).—This is a peculiar form of iritis met with relatively infrequently. It is characterized by the presence in the anterior chamber of a mass of fibrin which at first fills the anterior chamber, obscuring the iris and the pupil. The mass of fibrin, which includes some leukocytes, forms a coagulum which subsequently shrinks, producing at certain stages the appearance of the

[1] Groenouw, Klin. Monatsbl. f. Augenheilk., xxxviii, p. 186.

crystalline lens dislocated into the anterior chamber. The shrinking continues and absorption progresses until eventually the mass entirely disappears. In the majority of cases no trace of the disorder remains. The onset of spongy iritis is relatively sudden, the flocculent mass being developed in from one to three days. The pericorneal injection is quite intense and pain severe.

Etiology.—Spongy iritis may be the result of traumatism, rheumatism, gout, or syphilis. Its duration, up to the time of the complete disappearance of the exudate, is ordinarily about three weeks. The symptoms of inflammation subside rapidly thereafter.

Treatment.—The cause of the disease must be determined and appropriate constitutional treatment instituted. Locally, atropine sufficiently often and in solution of sufficient strength to insure dilatation of the pupils should be employed. Bathing with a hot solution of sodium chloride or boric acid four or five times daily, one half-hour each time, is of much value. If increase of tension develops, paracentesis of the anterior chamber should be done.

Plastic Iritis.—This form is characterized by the development of a plastic exudation (Fig. 189) having a decided tendency to unite the posterior surface of the iris at its margin to the capsule of the crystalline lens and to blocking of the pupil.

Fig. 189



Plastic iritis with nodules in the angle of the anterior chamber, not syphilitic. (From an original drawing by Holmes Spicer.)

Etiology.—Plastic iritis is due to syphilis in perhaps 75 per cent. of the cases, to rheumatism in approximately 20 per cent. of the cases, while infectious diseases, gonorrhea, diabetes, trauma, and sympathy may account for the remaining 5 per cent. Werthoff[1] reports having observed two attacks of iritis with purulent exudate in a patient to whom he was giving potassium iodide; the attack ceased when the potassium was discontinued.

Onset.—This may be relatively sudden, the disease being established in from twenty-four to forty-eight hours, the attack accompanied by intense pain, referable to the eye or to the corresponding side of the head. The onset may be insidious, little disturbance being experienced for some days, until gradually failing vision, with perhaps some pain, causes the patient to seek relief. In insidious cases quite persistent adhesions are usually present when the patient is first seen by the surgeon.

Symptoms.—It presents the symptoms and conditions enumerated as common to all forms of iritis, in a severe form. Pericorneal injection in plastic iritis may be very slight or it may be very intense, extending over the whole anterior portion of the globe, causing slight elevation of the ocular conjunctiva, and it may be accompanied by hyperemia of the palpebral conjunctiva. The turbidity of the aqueous humor is

[1] Med. Woch., 1898, No. 16.

marked. The color of the iris is a dusky reddish brown, particularly in brown irides. The iris is thickened and its markings are obliterated, the iris tissue becoming opaque. The margin of the iris becomes attached to the capsule of the lens at an early stage of the disease, particularly in the acute form. The pain accompanying plastic iritis may be intense or relatively slight, depending upon the nature of the attack. The exudation in plastic iritis may be very profuse and may gravitate to the lower part of the anterior chamber, presenting a condition similar to hypopyon. The mass, which is yellow, is often mistaken for infectious pus, and may be thought to indicate a destructive process. In reality the exudate is non-infectious, and is absorbed without doing injury to the eye. It is not correct to designate all cases of iritis in which a collection of yellow material appears in the bottom of the anterior chamber as purulent. It is true that the mass contains many leukocytes, and that it has somewhat the appearance of infectious pus, but it is free from germs and possesses none of the injurious tendencies usually attributed to that form of exudate.

Course.—This depends largely upon the cause.

Treatment.—The general treatment depends upon the cause, supporting diet, etc., being indicated in all cases. Locally, atropine in sufficient strength (0.5 to 3 per cent.) should be instilled into the eye often enough to maintain dilatation of the pupil, and hot bathing with a saline solution or a solution of boric acid (3 per cent.) should be employed from four to six times daily, one-half hour each time. Paracentesis of the anterior chamber may be required if the tension becomes greatly elevated, which is sometimes the case from blocking of the filtration angle.

Purulent Iritis.—This is one of the most violent, if not the most violent form of iritis with which the ophthalmic surgeon has to deal. Its onset is usually rapid; the injection of the ocular conjunctiva is intense; the lids are swollen, lachrymation is profuse, and pain referable to the eye and to the side of the head corresponding to the eye affected is severe. The affection is not confined to the iris, but soon involves the deeper structures of the eye, extending by way of the vascular coat. It runs a relatively rapid course and results, almost without exception, in destruction of the eye. At the end of the first twenty-four hours after the inception of the attack the iris takes on a yellowish-green color; the anterior chamber begins to fill with a flocculent mass, which is pus; the cornea soon becomes cloudy, and perforation of some part of the cornea or of the sclera often results.

Etiology.—Traumatism, in the form of a perforating wound of the globe, is the most frequent cause. It occurs rarely in typhoid fever and in syphilis. Variola is sometimes a cause; a metastasis from purulent processes occurring in distant parts of the body may produce it.

Diagnosis.—It is often very difficult to determine the differential diagnosis between the iritis with a yellowish exudation which may form hypopyon, and an infectious purulent iritis; in the first form the prognosis is favorable, in the second extremely unfavorable. Iritis that develops

in an eye presenting no evidence of recent perforation or perforating wound belongs, *as a rule*, to the first category.

Treatment.—Energetic constitutional treatment directed to the systemic conditions contributing should be instituted. Mercurials internally are of service whether there is a history of syphilis or not. Locally, atropine and moist heat, with mercurial ointment to the forehead and temple. Subconjunctival injections of solutions of the bichloride of mercury (1 to 5000 to 1 to 2000) may be thoroughly tried. In sloughing or perforating ulcer of the cornea, with threatened panophthalmitis, and in infections due to perforation, Haab and other surgeons introduce small pencils of iodoform into the anterior chamber. In desperate cases this may be tried.

Hemorrhagic Iritis.—Under certain conditions the blood-vessels of the iris in the anterior layers become enlarged and engorged. Rupture of some of the swollen vessels may occur and blood escape into the tissues of the iris or into the anterior chamber. This may occur in any form of iritis; it is not infrequent in diabetic iritis. In some cases of leukemia and in purpura hemorrhagica, hemorrhage may occur without previous inflammation of the iris. In the greater number of cases some form of iritis accompanies the hemorrhages.

Parenchymatous Iritis.—Parenchymatous iritis is characterized by a localized or general thickening of the iris tissue by proliferation of the cells of the iris or by infiltration of small cells and the presence of exudation within the tissue of the iris. When the infection is confined to a number of foci, as in tuberculous and syphilitic iritis, small elevations occur which present the appearance peculiar to this particular form. Diffuse thickening presents a dusky red appearance of the surface of the iris. The iris may be thrown into broad folds, and tortuous blood-vessels may be visible lying just below the limiting endothelium. In some cases small extravasations of blood occur in the iris tissue. Pus may form in the parenchyma of the iris.

Etiology.—Syphilis, tuberculosis, the entrance of foreign substances into the iris, etc.

Syphilitic Iritis.—The greater number of cases of iritis are due to syphilis, either inherited or acquired. Mautner puts the percentage at from 60 to 75; Acosta, 52; de Schweinitz, 50 to 60.

Forms.—Iritis due to syphilis may assume many of the forms just described and present no appearance in the iris pathognomonic of syphilis. There are two forms of iritis that are peculiar to syphilis, namely, papillary iritis and gummatous iritis.

Iritis from *inherited* syphilis is (*a*) serofibrinous, (*b*) plastic, or (*c*) gummatous. The serofibrinous form affects individuals between the ages of five and thirty-five years. The plastic form occurs early in life; cases have been observed in from one month to two years after birth. Gummatous iritis from inherited syphilis may occur at any time after the individual is six months old, but it is seldom seen after the age of thirty. Syphilitic iritis of the forms mentioned includes about 20 per cent. of the cases (Knies).

Iritis due to acquired syphilis, according to the statistics of Brunson,[1] occurs in 3.2 per cent. of the cases of acquired syphilis,

Serofibrinous iritis is more frequently a manifestation of the third stage of syphilis than of any of the other stages. Whether due to inherited or acquired syphilis, it is probably always accompanied by disease of the ciliary body and of the chorioid. The sclera, cornea, and tissues of the filtration angle are also involved in many of the cases of iritis of this form.

Papillary Iritis.—This form resembles plastic iritis very closely. It is, in fact, identical with that form of the disease with the addition of minute nodules of a dusky red hue, which appear in the iris and are confined to the minor or pupillary zone. The papules originate in tissue-bearing capillaries and devoid of large blood-vessels, and resemble the papillary syphilides of the skin. They occur contemporaneously with the skin eruption in many cases. *One* or *more* nodules may be present. In the majority of cases the number is more than one. The entire pupillary zone may be crowded with them to such an extent that they appear to coalesce.

Fig. 190



Nodules occurring in the secondary stage of syphilis, situated at the pupillary border of the iris. (From a drawing by Mr. W. G. Laws.)

Onset.—The onset of this form of iritis is similar to that of plastic iritis from other causes.

Symptoms.—The symptoms are those described under the head of "symptoms common to all forms of iritis" (page 325); they may be rather mild, but ordinarily are quite severe, the pericorneal injection and congestion of the ocular conjunctiva being marked. The papules appear in from three to four days after the onset of the disease and persist or disappear rapidly in proportion to the rapidity with which the system is brought under the influence of specific remedies. This form of iritis is almost always binocular, and is a disease which occurs as a secondary manifestation of syphilis. It may appear in from six weeks to two years after the initial lesion.

Diagnosis.—Papillary iritis can be confounded with miliary tuberculosis of the iris and with iritis nodosa. If it is remembered that the nodules occurring in these two conditions are not confined to the minor zone and that they are not greatly influenced by antisyphilitic treatment, the differential diagnosis can be readily made.

Duration.—Papillary iritis is recovered from ordinarily in from five to seven weeks, the papules disappearing without leaving a trace that can be detected by the naked eye; microscopically minute deposits of scar tissue can be found.

Gummatous Iritis.—This form is present only as a tertiary manifestation of syphilis. It may occur as a result of inherited syphilis, but is more frequently met with in acquired syphilis. In inherited syphilis it may

[1] Ophthalmic Record, November, 1899.

be present in the early years of life; in acquired syphilis it is seldom seen earlier than the twenty-fifth year of life. Gummatous iritis is usually monocular and appears in the form of a single isolated growth. Two or more foci may be merged together, forming a lobulated elevation. Gumma of the iris occurs most frequently in the ciliary zone; it may originate in the pupillary zone. The gummatous mass may extend from the iris to the ciliary body; it more frequently happens that the original growth develops in the ciliary body and advances into the iris.

Symptoms.—Gummatous iritis is characterized by the development of a nodular mass having a pale, yellowish-pink apex and a dusky-red base. The congested area at the base merges quickly into iris that is more or less normal. Fibrinous exudation occurs which serves to unite the iris to the capsule of the lens. In gummatous iritis the growth appears relatively rapidly, the tumor showing itself within two or three days after the commencement of the symptoms, rapidly advancing to its maximum dimensions. The pain is sometimes excruciating; often, however, it is not severe.

Duration.—The duration of gummatous iritis depends almost entirely upon the treatment. When the system is rapidly brought under the influence of antisyphilitic remedies, the gumma melts away as if by magic, disappearing in from one to two weeks, recovery taking place in from four to six weeks after the onset of the disease.

Pathology.—Syphilitic iritis, like syphilitic manifestations in other parts of the body, originates primarily as a local perivascular, small-cell infiltration. In the seroplastic form an infiltration of small cells is found around the blood-vessels of the iris, of the ciliary body, the ciliary process, and the blood-vessels of the chorioid throughout the parts involved. Perivascular infiltration of small cells is very pronounced in *plastic iritis* due to syphilis. In cases of *papillary* iritis collections of round cells occur, forming the nodules which have been described as being present in the pupillary zone.

In gumma of the iris the mass is made up of small cells and inflammatory tissue (embryonal connective tissue); rarely a few giant cells are present; the accumulation of small cells is very great. Necrosis of the centre of the mass sometimes occurs because of pressure of the surrounding cells and interference with nutrition. On the subsidence of the tumor a scar is left in the tissue of the iris which is sometimes quite large.

Treatment.—The constitutional treatment consists in getting the patient under the influence of mercury and potassium in the quickest possible time. It is the opinion of the writer that potassium is not of great value in these cases; the remedy to be relied upon above all others is mercury, and probably the most efficient way of introducing it into the system is by inunction (see chapter on "Special Therapeutics"). Mercury by the stomach, by deep intramuscular injection, or by vapor baths, will suffice in many cases. It is the custom of the writer to prescribe mercury and potassium to be taken in relatively small doses by the stomach, and in addition to

employ inunction. If the patient enters a hospital and is under direct observation, the inunction is made once daily until the physiological effect of mercury is manifested. The inunctions are repeated only sufficiently often to keep the patient at the "point of saturation." This condition is maintained for from two to four weeks, and then the mercury in much smaller dose is kept up for a varying period of time. As the acute attack of iritis subsides the patient is allowed to be up about the ward. If the patient applies the ointment and makes the inunctions himself, he is given the remedy put up in packages of $\frac{1}{2}$ dram, and is told to rub the ointment into the thin skin of the thighs and under the arms morning and night; he is required to report sufficiently often to enable the surgeon to determine when the desired systemic effect is produced. The dose is then modified after the manner previously described. Locally, the treatment consists in instilling atropine sufficiently often to maintain dilatation of the pupil, and hot bathing with a weak solution (about 3 per cent.) of boric acid or sodium chloride, the bathing to be kept up for an hour at each sitting, five times a day.

Rheumatic Iritis.—Iritis due to rheumatism presents no characteristics that are pathognomonic. The iritis is usually of the plastic variety. Iritis occurs as a result of the rheumatic diathesis in whatever form it may present itself. It is met with in individuals of all ages after the fifth year of life. The statistics of Brunson[1] indicate that it occurs in approximately 1.5 per cent. of all cases of rheumatism. These statistics show a greater percentage of iritis than those of other writers; they are, in all probability, higher than they should be. Garrod[2] writes that the so-called rheumatic iritis cannot be included among the accidents of rheumatic *fever*. He quotes Nettleship as being of the opinion that iritis is not an event of rheumatic fever, but that those who suffer from chronic rheumatism are not infrequently subject to relapsing iritis; and that some of the patients give a history of acute rheumatism as the starting point of their iritis. Garrod is of the opinion, in which the writer concurs, that iritis of gonorrheal origin is often mistaken for rheumatic iritis, the cause of the joint lesion and the fever being mistaken for rheumatism. He is rather skeptical regarding iritis due to rheumatism being of frequent occurrence, and thinks the subject requires much closer investigation.

Pathology.—The pathology of rheumatic iritis does not differ from that of plastic iritis from other causes.

Symptoms.—The symptoms and the tendency to the formation of synechiæ are identical with those found in plastic iritis due to other causes.

Duration.—In rheumatic iritis both eyes are usually affected, often not at the same time; the attack is apt to last longer than in iritis due to other causes. Recurrences are not infrequent. The recurrences may take place at short intervals, or long periods of time may elapse between the attacks. Jonathan Hutchinson has described a form of rheumatic iritis which comes on very insidiously, producing but little pain and

[1] Ophth. Record, 1899.

[2] Treatise on Rheumatism, p. 176.

but very slight pericorneal injection. He has given the name "quiet" iritis to this form. When the patient presents himself for treatment, it is found that the disease has already progressed to such an extent that posterior synechiæ have formed, and frequently are so firm that atropine does not suffice to break them up. The disease progresses and is apt to assume a chronic form, frequently lasting many months.

Treatment.—The treatment, as in other forms of iritis, may be divided into local and constitutional. The local treatment is identical with that employed for plastic iritis due to any cause. The constitutional treatment consists in the administration of the remedies directed against the diathesis. The salicylates, in connection with mercury in small doses, and the iodide of potassium, produce most excellent results. It is the custom of the writer to give biniodide of mercury, in connection with iodide of potassium, in doses of $\frac{1}{40}$ grain and 5 to 8 grains, respectively, in water or milk before meals; and to give the salicylate of soda and bicarbonate of soda, 8 to 15 grains each, well diluted, after meals or more frequently. This treatment is continued until the attack subsides, and for some time thereafter, the salicylate being discontinued first, the mercury and potassium continued for a relatively long period of time. Various remedies, such as the oil of wintergreen, Rochelle salt, salicylic acid, may also be employed. According to some writers, pilocarpine hypodermically is useful. If there is a suspicion of a gouty condition, colchicum may be added. Lithia waters are of value. The condition of the skin should be inquired into, and baths of various kinds, especially Turkish baths, may be employed with benefit in many cases. It sometimes happens that recurrences are not controlled by remedies alone. When this occurs operative treatment may be resorted to; the operation required is iridectomy. In the experience of the writer, iridectomy gives most satisfactory and gratifying results, recurrences being prevented in a large percentage of cases. The operation should be performed when the eye is free from inflammation.

Gouty Iritis.—Gout is probably the cause of iritis in a small percentage of the cases; it resembles iritis due to rheumatism. An outbreak of gout may follow the iritis. The treatment of this form of iritis is similar to that employed in the form due to rheumatism, with the exception that colchicum is added.

Gonorrheal Iritis.—This form is of the plastic variety. It is alway painful, and is frequently accompanied by more edema of the ocular conjunctiva (the non-purulent gonorrheal conjunctivitis of writers) than is observed in plastic iritis from other causes. The aqueous and vitreous humor often contain numerous small particles of fibrin—the amount of fibrin is so great in some cases that the condition known as "spongy" iritis obtains. Iritis as a result of gonorrhea is preceded by or accompanied by gonorrheal rheumatism in by far the greater number of cases. Cheatham[1] quotes Nettleship's statistics of 40 cases of gonorrheal iritis, in which 6 had not had rheumatic symptoms. The disease is

[1] Arch. of Ophth., 1896, xxv, No. 4.

usually bilateral. It occurs in both sexes, but is more frequent in males.

Etiology.—Whether the effect on the iris is due to the presence of gonococci or to some product of the gonococcus is not known; it has been proved that the gonococci are present in the synovial fluid of gonorrheal joints, but they have not as yet been demonstrated in the fluids of the eye.

Diagnosis.—Iritis occurring in the course of a long-continued urethritis, with a history of arthritis, may, in the absence of a history of syphilis and of conditions *pathognomonic* of some other cause, be classed as gonorrheal.

Prognosis.—The type of the disease is not severe. Posterior synechiæ may form and become firm, but this is not common. Recurrences are apt to take place on the outbreak of fresh attacks of gonorrhea and on exacerbations of a gleet.

Treatment.—Local treatment of the eye is the same as in iritis due to other causes. The urethritis should be corrected as quickly as possible. Much benefit is derived from systemic treatment in connection with the local treatment of the eye and urethra. Satisfactory results have been obtained by the administration of the salicylates given after meals, and moderate doses of iodide of potassium and the biniodide of mercury given before meals. The oil of gaultheria (Cheatham), pilocarpine sweats, and subconjunctival injections of sodium chloride (2 per cent). have been recommended.

Iritis Due to Infectious Diseases.—Acute seroplastic iritis of moderate severity and transient in nature is observed from time to time as a complication of malaria, typhus and typhoid fever, smallpox, la grippe, and relapsing fever.

Pyemia and cerebrospinal meningitis give rise to a metastatic plastic or purulent iritis.

Leprosy may produce serofibrinous, plastic, and nodular iritis. The plastic form often terminates in occlusion of the pupil. The nodular form may fill the anterior chamber and lead to perforation of the cornea or sclera. Recovery without damage to the eye may occur in the serofibrinous and plastic forms.

Iritis Catamenialis.—An iritis just preceding or during menstruation, which may occur at regular intervals, has been described. It has been suggested that the iritis is due to abnormalities in the secretion from the uterus (de Schweinitz).

Iritis Nodosa.—A nodular form of iritis has been observed as a result of the penetration of caterpillar hairs through the cornea or sclera into the iris. In these cases similar nodules are observed in the conjunctiva.

Iritis Due to Disorders of Teeth and Nose.—*Dental* irritation and suppurative rhinitis are given as causes in the production of iritis. Carious teeth and alveolar abscess are mentioned as causes of iritis (Campbell), and attention to the condition of the mouth is urged in cases of iritis, particularly in those cases in which the cause is obscure.

Diabetic Iritis.—The form of iritis observed in diabetes is usually of the mild plastic type. Copious exudate with hypopyon may form, and hemorrhage in the anterior chamber may occur in the course of diabetic iritis.[1] The observations of Galezowski[2] indicate that iritis occurs in about 5 per cent. of diabetics.

Prognosis.—This is favorable even in those cases in which hypopyon occurs.

Treatment.—Treatment consists in the employment of local remedies, as in plastic iritis. Opium may be employed for the relief of pain, if necessary.

Idiopathic Iritis.—Iritis occurring without a cause that can be determined is known as idiopathic iritis. It may occur in individuals of both sexes at puberty and in young adults. This form of iritis is plastic and is of a mild character. External influences, such as exposure to cold and to glare of light, are looked upon as causes. Cases of idiopathic iritis are extremely rare and are becoming more so as knowledge of disease in general advances. Probably all cases are due to some underlying abnormal systemic condition which is not recognized.

Sympathetic Iritis.—See Sympathetic Iridocyclitis.

Tubercular Iritis.—Tuberculosis of the iris occurs in children and young adults, seldom later than the twenty-fifth year. It may be primary in the iris or, as is more frequently the case, secondary to tuberculosis affecting other parts of the body.

Forms.—It appears in two forms: (*a*) As miliary tubercles of the iris, in which small, grayish elevations, having a thickened hyperemic base, develop in the iris. The entire iris may be hyperemic or the congested area may be confined to the base of the nodule. The nodules are more numerous in the pupillary zone. They may be discrete or may coalesce. Sometimes only two or three tubercles are present. In other cases the iris may be quite thickly studded with them. The tubercles develop slowly and are accompanied by little evidence of inflammation. The mobility of the iris is interfered with and posterior synechiæ may develop. (*b*) As conglomerate tubercle, a large mass of tubercular tissue developing from one or from numerous foci. In these cases the mass, which is of a yellowish-gray color at its apex, with a slightly congested base, usually appears in the ciliary zone of the iris, not infre-

Fig. 191

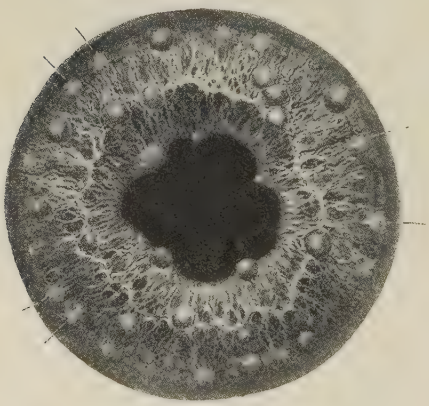

Miliary tuberculous iritis. (Axenfeld.)

[1] Knies, edited by Noyes, N. Y., 1895, p. 438.

[2] Jahr. f. Aug., 1883.

quently being an extension from a tubercular mass in the ciliary body. A mass of plastic lymph frequently obstructs the pupil.

Diagnosis.—Both forms of tuberculous iritis may be mistaken for syphilitic iritis, but the slow development, comparative absence of inflammation, and the negative effect of antisyphilitic treatment serve to make the differential diagnosis possible. Conglomerate tubercle may be mistaken for sarcoma of the iris; however, the tubercular mass is paler in color, and on examination with a lens will be found to be made up of a number of nodules. Sarcoma is red or pigmented and is uniform in appearance. The systemic and local reaction to tuberculin, either injected subcutaneously or introduced into the conjunctival sac (method of Calmette), may serve to confirm, if not to definitely establish, a diagnosis.

Course.—Spontaneous recovery takes place in some of the cases of miliary tuberculosis of the iris.[1] Spontaneous recovery seldom occurs in cases of conglomerate tubercle of the iris. If not arrested, the eye is, as a rule, destroyed.

Treatment.—Syphilis should be excluded. The cases should be closely watched, and if after careful treatment with tuberculin no tendency to improvement is manifested the eye should be removed. General tuberculosis, if present, should receive appropriate treatment. A general tonic treatment should be given in all cases. Schieck,[2] who has collected 116 cases of tuberculosis of the iris, states that the prognosis is less favorable in the first decade of life and more favorable the older the patient. He advises the use of tuberculin. The systematic long-continued use of tuberculin effects a cure in at least 90 per cent. of the cases, the time required being four months to a year and a half.

Secondary Iritis.—Inflammations of the iris due to the extension of disease from other parts of the eye are known as secondary iritis. Ulcerative affections of the cornea are the most frequent cause of this form of iritis. It accompanies the deep form of scleritis and at times the superficial form of scleritis. Cyclitis, chorioiditis, and in some cases, detachment of the retina, swelling of the lens, dislocation of the lens, intra-ocular tumors, foreign bodies in the eye, etc., are accompanied by iritis as a secondary condition. A low-grade iritis is the form usually produced.

Herpetic Iritis.—Herpes of the iris has been observed in the course of herpes zoster frontalis.[3] There was pain, followed by hyperemia of the iris and inflammation, with plastic exudation, localized swelling of the iris tissue, necrosis of the swollen parts, hemorrhage from ruptured vessels, and finally healing by cicatrization. The process extended over a period of three months.

Results of Iritis.—**Synechiæ.**—Adhesions to the capsule of the lens (posterior synechiæ) may be temporary or permanent.

[1] Machek, Wien. med. Wochenschr., 1894, No. 24, 25; Sandford, Trans. Ophth. Soc. Unit. Kingdom, xiv, p. 90.

[2] Graefe's Arch., i, p. 247.

[3] Machek, Arch. f. Augenheilk., xxxi, p. 1.

Temporary Adhesions.—Temporary adhesions to the capsule of the lens are prevented from becoming permanent by the use of a mydriatic which causes contraction of the iris and the withdrawal of the iris from the capsule of the lens. Weak solutions of atropine are often inefficient, and the stronger solutions, up to the strength of 3 per cent., are not infrequently employed. In recent cases in which the synechiæ are quite strong, and in which solutions of atropine as usually employed are not efficient, a few small crystals of atropine may be introduced into the conjunctival sac, and after five or ten minutes have elapsed dionin (5 to 10 per cent.) may be instilled. The combined effect of the two remedies is sometimes sufficient to break the adhesions.

It often requires a number of days to determine just how much effect may be produced on synechiæ by the use of atropine. If the adhesions are not broken up at the end of five to seven days when strong solutions are used, such adhesions are usually permanent. On detachment of posterior synechiæ, it frequently occurs that a portion of the pigment of the iris remains attached to the lens capsule, forming a more or less perfect circle of minute pigment patches which correspond to the size of the pupil where the iris came in contact with the lens capsule. These minute particles of pigment, which may often be associated with remnants of an inflammatory pupillary pseudomembrane, seldom disappear. Vision is permanently interfered with to a degree corresponding to the density of the deposit in the pupillary area.

Permanent Adhesions.—Permanent adhesions to the capsule of the lens may be filamentous, multiple, annular, incomplete, or complete. Permanent filamentous synechiæ are not infrequently hidden when the pupil is of normal size. When the pupil is dilated they become visible and exert traction on the iris and on the capsule of the lens. In eyes that are somewhat sensitive, traction acts as a source of irritation, and the eye may become injected and slightly painful. This, however, does not always follow; many individuals have no inconvenience in the presence of these synechiæ. It is thought that the irritation occasioned is sufficient to bring on a genuine attack of iritis in some cases, but such cases are very rare.

The remnants of fetal pupillary membrane must not be mistaken for posterior synechiæ due to inflammatory processes which sometimes serve to unite the iris to the capsule of the lens (see page 322). If the fact is borne in mind that synechiæ from inflammation always involve the margin of the iris, and that persistent fetal pupillary membrane takes its departure from the iris at the irregular line which separates the pupillary from the ciliary zone of the iris, mistakes cannot be made. Attempts to detach the iris from the capsule of the crystalline lens are uncertain of success and dangerous of execution.

Annular Synechiæ.—If half or two-thirds of the margin of the iris are bound down to the capsule of the lens, it may be termed incomplete annular synechia. If the adhesion to the capsule of the lens includes the whole of the pupillary margin, it is termed complete annular synechia.

The last named condition limits the boundary of the pupil and is

known as *seclusio pupillæ*. If, in addition to the annular synechia, the pupillary area is covered by an inflammatory exudate, the condition is known as *occlusio pupillæ*. In seclusio pupillæ the vision may be but slightly impaired. In occlusion pupillæ the exudation deposited in the

Fig. 192



Seclusio pupillæ and bombé iris in a case of traumatic detachment of retina. (Photograph by Geo. S. Dixon.)

pupillary area may be dense and even vascular; vision under these conditions is reduced to perception of light.

As a result of seclusio pupillæ, with or without occlusion, the communication between the anterior and posterior chambers is interrupted, and an accumulation of aqueous takes place in the posterior chamber,

Fig. 193

Occlusio pupillæ. (Axenfeld.)

causing the iris to bulge forward. At its periphery it may come in contact with the cornea; at the pupillary margin it describes an acute curve, converting the pupillary space into a pit, the bottom of which is formed by the capsule of the lens or by the inflammatory exudation

which may fill the pupillary area. This condition is known as "crater pupil" or "bombé iris." An increase in the tension of the globe accompanies this condition, constituting secondary glaucoma. If the tension of the globe is not reduced, degeneration of the eye, particularly of the retina, takes place and complete loss of vision results.

Treatment.—If posterior synechiæ of the forms already described produce symptoms that are painful or threatening to the eye, operative measures must be resorted to. The operation indicated is iridectomy.

Complete Posterior Synechia.—Another form of synechia is that in which the entire posterior surface of the iris, except a narrow zone at the ciliary border, becomes agglutinated to the capsule of the lens. This condition follows severe plastic iritis, associated with cyclitis and sometimes chorioiditis. The anterior surface of the iris conforms to the anterior surface of the crystalline lens, and at the iris angle (filtration

Fig. 194

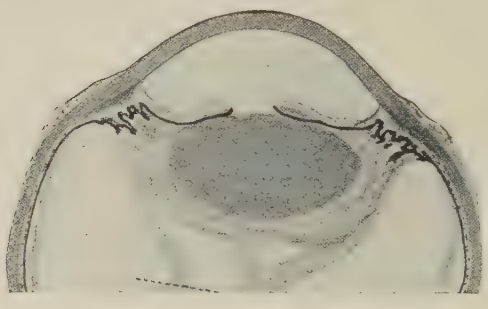

Complete posterior synechiæ. (Axenfeld.)

angle) there is a deep groove caused by the sinking of the iris at this part. When this condition obtains, the tension of the eyeball is seldom increased, but is more often decreased, the crystalline lens becomes more or less opaque, and degeneration of the globe follows. As a result of long-continued annular, incomplete annular, and complete posterior synechiæ, the iris often becomes atrophic and is reduced to a very thin membrane, presenting here and there openings which are secondary pupils, the condition known as acquired polychoria.

Effect of Iritis on Lens.—The lens in by far the greater number of cases of iritis preserves its transparency. Deposits of pigment and inflammatory exudate occur on the capsule of the lens, but do not affect the transparency of the substance of the lens. In gummatous and tubercular iritis the pressure of the iris on the lens may induce opacification of its substance, which may eventually go on to the formation of complete cataract.

Effect of Iritis on Tension of Eye.—The tension of the eyeball in iritis is usually normal or very slightly subnormal; but in certain cases of plastic iritis, particularly if the process is an acute one accompanied by considerable fibrin in the aqueous humor, the tension of the eyeball

may become increased. The tension may continue for five or six days, greatly reducing vision. The increase in tension is due to a clogging of the lymph spaces at the filtration angle. The use of a mydriatic at this stage is detrimental, and the question arises as to whether a miotic should not be employed. It is usually better, when this condition arises, to discontinue the mydriatic. If the tension does not decrease within twenty-four hours a mild miotic (pilocarpine) may be employed. However, the preferable procedure in cases of threatened damage due to increase in tension is paracentesis of the anterior chamber. This brings about the required decrease in tension, and is often sufficient to bridge over the period. As a rule, increase in tension disappears as the fibrin shrinks or is absorbed, and little or no damage is done to the eye.

Cysts of Iris.—Classification.—Cysts of the iris may be classified as (1) idiopathic cysts; (2) traumatic or implantation cysts.

Idiopathic Cysts.—These are extremely rare. They are of two varieties, (*a*) forming in the stroma of the iris, (*b*) forming in the pigmented posterior epithelial layer—the uvea of the iris. The former are characterized by the development of thin-walled cysts lined with endothelium and filled with a clear serous fluid. They bulge into the anterior chamber, forming a hemispherical mass, and may become sufficiently large to fill the anterior chamber. They are unilateral, as a rule. Terrier[1] believes that they arise from closure of a crypt of the iris. A unique case of congenital dermoid cyst of the iris bearing hairs has been reported.[2] The symptoms produced are the same as those accompanying traumatic cysts (see below).

Fig. 195

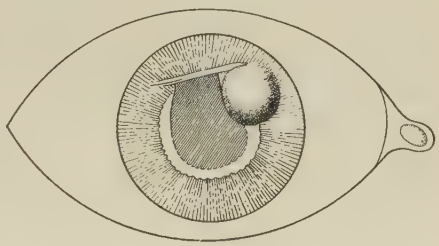

Cyst of the iris.

Cysts of Uveal Layer.—In aged people and in eyes that have been subject to corneal inflammatory processes and chronic glaucoma irregularities of the pigment layer are observed which on section prove to be minute cysts. It seldom occurs that these cysts become large enough to be diagnosticated before removal of the eye, or attain a size that occasions any symptoms. They are the result of degenerative changes and do not call for treatment. It sometimes happens that a small uveal cyst becomes detached from the uveal layer, finds its way into the anterior chamber, and floats around, gravitating to the lower part as a minute black ball.

Traumatic or Implantation Cysts.—Traumatic or implantation cysts of the iris are due to the implantation of epithelium from the lid, conjunctiva, cornea, or bulb of eyelash. A history of perforating injury

[1] Arch. d'ophtal., 1901, xxi, 651.
[2] Snell, Annals of Ophthalmology, January, 1902.

to the globe or operation can almost always be elecited. The wall of the cyst will be lined by stratified epithelium or by endothelium, depending on the character of the implanted cells. As a rule, the content of the cyst is transparent, but in some cases it is opalescent, particularly in those cases in which the cyst originates from the implantation of an eyelash. These are termed "pearl cysts," and contain masses of cholesterin and degenerating epithelial cells.

Symptoms.—Cysts of the iris stroma do not produce symptoms until the area of the pupil is encroached upon, when vision is impaired or increase in tension has been occasioned, when the symptoms common to secondary glaucoma are produced, or until pressure on the ciliary body is excessive, when the symptoms are those of irritation or inflammation of the iris and ciliary body.

Results.—Unless properly treated, cysts of the stroma of the iris almost without exception continue to grow until they produce decided increase of tension and cause complete loss of vision. The pain occasioned in neglected cases renders it necessary to remove the eyeball.

Treatment.—The object of treatment is the removal of the cyst or the destruction of the secreting surface of the cyst wall. In its early development the entire cyst may frequently be removed by iridectomy. In advanced stages it has been found possible to preserve the eyeball by making an incision through the cornea, evacuating the contents of the cyst and removing portions of the cyst wall by means of forceps.

Tumors of Iris.—Gumma.—See Syphilitic Iritis.

Tubercle.—See Tubercular Iritis.

Sarcoma.—Tumors of this nature are extremely rare. Wood and Pusey,[1] in a recent exhaustive paper, have collected 83 cases in which a histological examination has confirmed the diagnosis. Sarcoma of the iris occurs most frequently between the ages of forty and sixty years, but it has been observed as early as the second year of life and as late as the seventy-fifth year. It is more frequent in females than in males, and is usually monolateral, in rare instances bilateral. The tumor is pigmented in the greater number of cases, but some cases of unpigmented sarcoma (leukosarcoma) of the iris have been reported.

Fig. 196

Sarcoma of the iris. (After Haab.)

Growth and Appearance.—The growth of the tumor may be divided into four stages, conforming to those of other tumors of the eye.

[1] Arch. of Ophth., vol. xxxi, No. 4, p. 323. The author begs to refer the reader to this most excellent paper if complete information on this subject is desired.

1. Stage of growth without pain or other subjective symptoms other than disturbance of vision in those cases in which the tumor grows into the pupillary space.

2. Inflammatory stage, in which secondary glaucoma develops accompanied by pain, etc.

3. Stage of invasion of subjacent tissues.

4. Invasion of tissues in other parts of the body metastasis.

The tumor appears most frequently in the lower half of the iris, and presents as a nodule or a nodular mass, almost always pigmented, confined to a portion of the iris but not sharply circumscribed. The iris at the base of the tumor may show slight evidence of irritation, but other portions of the iris remain unchanged. The *growth* of the *tumor* is very slow, as a rule, more rapid in children than in adults; many years may elapse before the second stage is entered upon. Spontaneous hemorrhage occurs in many of the cases during the first as well as in the later stages.

Etiology.—The histories of the recorded cases point to the probability that the growths take their origin in pigmented nevi of the iris; a number of cases appear to owe their origin to traumatism. In the majority of cases a cause is not assignable.

Pathology.—Iris sarcoma is composed of small round and small spindle cells. Karyokinetic figures have not been observed, indicating an extremely slow growth. The endothelium of the vessels takes part in this production of the cellular elements of some of the tumors, forming what may be termed sarcoma-endothelioma. The cells of the uveal layer of the iris rarely enter into the composition of the tumor, but a few cases in which this has occurred have been reported.

Diagnosis.—Sarcoma of the iris may be confounded with melanoma, gumma, and tubercle. Simple melanoma projects but little above the level of the iris; it does not increase in size, nor does it give rise to symptoms. Gumma and tubercle cause inflammation of the iris. In doubtful cases potassium and mercury, or tuberculin in suspected tuberculosis, may be administered; the history should be carefully obtained—it will serve to establish the diagnosis in almost all cases.

Prognosis.—Safety depends upon the early and complete removal of the growth. Metastases occur very seldom if the globe is removed in the first stage of the development of the growth. The frequency of metastasis increases in the later stages of growth.

Treatment.—While a broad iridectomy, with complete removal of the growth, is permissible in cases in which the tumor is very small (Knapp), the safest mode of procedure is enucleation.

Melanoma.—Authors describe a tumor of the iris, not congenital, called melanoma, in which there is a very dark mass, occurring ordinarily at the margin of the pupil, "grape-seed" masses. The diagnosis of melanoma must be a guarded one, as the mass may turn out to be the early stage of sarcoma.

Vascular growths, papillomata, leprosy nodules, and lymphomata have been observed in the iris.

Granuloma.—Granuloma of the iris may sometimes appear after wounds to, or operations on, the iris. This was apparently more often the case in the pre-aseptic age (Knapp), as it is spoken of by older writers. It is occasionally seen as a development after perforating ulcer of the cornea, the mass filling the perforation being composed of iris tissue and granulation tissue springing from the iris. The appearance of granulations springing from the iris is the same as that of granulations springing from other tissues.

Lipoma.—Mooren, referred to by Knapp,[1] reports having observed in a girl of ten years a "smooth, whitish-yellow tumor," the size of a large pea, which had developed on the outer segment of the iris. Microscopic examination proved the growth to be composed of lipomatous tissue. The case is unique.

Injuries of Iris.—Wounds.—The iris may be injured as a result of contused and of penetrating wounds of the eyeball. A blow on the eyeball not infrequently results in a laceration of the pupillary margin of the iris, which may be single or multiple. The laceration seldom extends more than part way through the sphincter, but may extend to the ciliary margin. More or less hemorrhage accompanies these lacerations, except in cases where the laceration is extremely minute. If the laceration is very minute, it becomes manifest only on dilatation of the pupil, when the pupillary margin is found to be irregular. The irregularity is permanent to a degree somewhat less than that presented immediately after the injury.

Iridodialysis.—The iris not infrequently becomes detached throughout part of its ciliary insertion as a result of a blow on the eyeball. The detachment may take place at any part of the circumference of the iris. It may be extremely small or very extensive. The appearance produced is that of a dark, crescentic body at the periphery of the iris, through which the reflex from the fundus may be obtained by transillumination—*traumatic polychoria.* The detachment permits that part of the iris to sag, producing a change in the contour of the pupil on the corresponding side (a flattening). Iridodialysis is accompanied by more or less hemorrhage, the clot sinking to the bottom of the anterior chamber.

Results.—Iridodialysis remains permanent, with few exceptions. If small, reattachment of the iris to the ciliary body may occur.

Treatment.—Treatment is of no avail.

Retroversion.—This may follow injury, may be complete or partial. A contused or perforating wound ruptures the suspensory ligament, causes a backward dislocation of the lens, and permits the vitreous to come forward through the pupil. The retroverted portion of the iris lies backward against the ciliary body.

Dislocation.—Dislocation backward occurs in cases of partial or complete rupture of the annular ligament of the ciliary body (see ciliary body).

Traumatic Paralysis of Muscles of Iris.—As a result of traumatism in some cases the contractility of the muscles of the iris is abolished (see page 346).

[1] Intra-ocular Tumors, p. 295.

Penetrating and Lacerating Wounds.—Penetrating and lacerating wounds of the iris of all kinds occur. The entire iris may be torn from its insertion and drawn out of the eye. A great number of cases of injury to the iris accompanied by perforating wounds of the cornea result in protrusion of a part of the iris (prolapse) or incarceration of the iris in the wound. These conditions call for operative procedure for the purpose of releasing the iris. When prolapse occurs, the iris should be freed from the margins of the corneal wound, drawn out by means of suitable forceps, and excised. When incarceration occurs it is sometimes advisable to attempt to release the iris, but in many cases this is not feasible.

Fig. 197



Prolapse of the iris following perforating ulcer of the cornea.

Penetrating and lacerating wounds of the iris are frequently followed by infection of the iris tissue, and plastic and purulent iritis follow. Iritis may result from injury to the eye without perforation. When such injury is the cause, the iritis is serofibrinous, or plastic in character.

Foreign Bodies of the Iris.—A foreign body may perforate the cornea and lie on or become embedded in the iris tissue. There are but few substances that are tolerated by the iris under any circumstances. Minute pieces of glass and, in rare cases, particles of steel may not produce irritation, but, generally speaking, all foreign bodies that lie in or on the iris are irritating to that membrane and must be removed. The operations that are resorted to for the removal of these foreign bodies involve an incision of some kind through the cornea, through which the foreign body is brought, either by means of forceps or by the magnet, without including a piece of the iris if possible, but in many instances together with a piece of the iris. The location, character, and form of the foreign body must determine the operative procedure to be employed in any given case.

Functional Disturbances of Iris.—**Irregularity in Size of Pupil.**—Slight difference in the size of the pupil may exist as a normal condition, but it is not common; marked differences are always pathological.

Mydriasis.—*Etiology.*—This condition may be due (*a*) to a paralytic affection of the motor oculi, (*b*) to stimulation of the cervical sympathetic, (*c*) to traumatism directly affecting the sphincter pupillæ. Paralytic affections of the motor oculi frequently affect both eyes at once, but often affect one eye only; the lesion may be confined to the sphincter centre, some

or all of the other centres of the nucleus may be involved, or the lesion may be peripheral, occurring at any point along the course of the nerve. If the sphincter centre alone is affected, there are no symptoms other than the moderate dilatation of the pupil. If the paralysis is not complete, slight direct response to the stimulus of light may be obtained.

Nuclear lesions are due to syphilis in the greater number of cases; exudation from atheromatous vessels may cause them. Intracranial pressure from hydrocephalus, hemorrhage into the brain, and brain tumor may produce temporary paralytic mydriasis.

Peripheral lesions may be due to exposure to cold, to post-diphtheritic processes, rarely to la grippe, to the abuse of alcohol, atrophy of the optic nerve or retina, producing non-conductivity of light, and to the effect of the class of remedies known as mydriatics.

Mydriasis due to *stimulation* of the sympathetic is often greater than that due to paralysis of the sphincter; it is sometimes unilateral, but usually bilateral; the movements of the pupil are not abolished, response to the stimuli of light, convergence, and accommodation being obtained to a moderate degree, but the dilatation returns as soon as these stimuli are removed or much modified.

In diseases affecting the meninges of the medulla or of the cord, in hyperemia of the meninges, and sometimes in tumor of the cord or brain, sufficient irritation of the spinal branches of the sympathetic to stimulate its action sufficiently to cause more or less contraction of muscular tissue innervated by that nervous system, may occur. In fright, excessive emotion, vomiting, forced respiration, neurasthenia, cerebral anemia, etc., dilatation of the pupil occurs.

Traumatic Paralysis of Sphincter Pupillæ.—This, as the result of blunt force, appears very soon after the injury. In these cases the iris does not respond to the stimulus of light; the condition may or may not be accompanied by paralysis of accommodation.

Prognosis.—This is good, recovery usually taking place spontaneously, but the paralysis may continue for a number of weeks or months.

Treatment.—Treatment appears to be of little value.

Miosis.—Contraction of the pupil not due to inflammatory disease of the iris may be occasioned by paralysis of the sympathetic, or to stimulation of the third nerve, or both; it may be unilateral, but is more commonly bilateral.

Paralytic Miosis.—This occurs in lesions of the cord that affect the portion above the dorsal vertebræ, in lesions of the cervical sympathetic, and of the sympathetic nerves forming the tract between the cervical sympathetic and the dilator muscle of the iris, in which cases the pupil responds to the stimulus of light but to a very small degree. The so-called Argyll-Robertson pupil (a form of reflex iridoplegia), in which the pupil reacts to accommodation and convergence, but not to the stimulus of light, is, according to recent writers, due to disease of the brain tissue lying between the proximal end of the optic tract (external geniculate body) and the oculomotor nucleus. When disease of the sympathetic nervous system as described and the lesions producing

Argyll-Robertson pupil are associated, miosis and reflex iridoplegia are the result, a condition often seen in tabes dorsalis (Argyll-Robertson pupil is not necessarily associated with miosis). The development of miosis due to spinal disease and the lesion which produces the Argyll-Robertson pupil, is slow and may affect one eye much in advance of the other, the miosis and reflex iridoplegia varying in degree in the two eyes. This condition is met with in the paralysis of the insane, also in some cases of multiple neuritis.

In paralytic miosis due to disease of or removal of the cervical sympathetic, symptoms other than those associated with the pupil are present; ptosis, slight hyperemia of the ocular conjunctiva, and increased lachrymation.

Irritation Miosis.—Irritation miosis is met with in the early stages of diseases of the brain of all forms, meningitis, brain tumor, etc., when the irritation is sufficient to stimulate the function of the sphincter nucleus. It may change to mydriasis on extension of the disease to a sufficient degree to interfere with the function of the sphincter nucleus or the fibers that proceed from it. The interference may be intermittent, as in pressure from hydrocephalus, or it may be constant and complete; the change from miosis to mydriasis in disease of the brain indicates a grave condition, often preceding a lethal issue.

Mydriatics have the effect of slightly dilating the pupil even in paralytic miosis, due, in all probability, to a direct effect on the dilatator pupillæ muscle. In *irritation* miosis the pupil dilates *ad maximum* when mydriatics are employed. Miotics serve to make the miosis from either of the above-mentioned causes greater.

Paralytic miosis is sometimes seen in patients with multiple sclerosis, in bulbar paralysis, and at times in individuals who present no other demonstrable nerve lesion and without a history of syphilis.

Miosis Produced by Drugs.—See page 125.

Unilateral Reflex Iridoplegia.—This is a condition in which one pupil does not respond to the stimulus of light, either directly or consensually, but does respond to efforts of convergence. It may be associated with paralysis of accommodation. The affected eye almost always presents a pupil larger than its fellow and pronounced mydriasis is the condition in a large number of cases. Vision is not impaired. The lesion is probably at or near the sphincter nucleus.

Etiology.—Syphilis, either inherited or acquired, is the cause in almost all cases. The prognosis is fairly favorable if vigorous antisyphilitic treatment is instituted *early* in the course of the affection. If some months or years have elapsed very little can be expected from treatment.

Condition of the Pupil in Blindness of One or Both Eyes.—If blindness of both eyes occurs from lesions affecting the retina or the visual tract anywhere from the corpora quadrigemina to the globes, mydriasis is present. If the lesion is between the cortex and the corpora quadrigemina, mydriasis is not necessarily present, although moderate mydriasis is the rule in bilateral blindness due to such a lesion. This is due to the fact that

in its first condition the light reflex arc (Plate IX) is broken; in the second condition it is not interfered with. If the retina or optic nerve of one side is the seat of disease that produces blindness of one eye, mydriasis is present in the blind eye when the seeing eye is covered; light entering the blind eye does not cause the pupil to contract (direct reaction), nor does it produce contraction of the pupil in the fellow eye; but if light is thrown into the fellow eye, its pupil and also the pupil of the blind eye contract (consensual contraction). If the chiasm is encroached upon anteriorly or posteriorly, or if either tractus is the seat of the lesion, hemianopsia results, with loss of pupillary reaction to light from the blind part of the retina. If the lesion affects the visual tract between the cortex and the corpora quadrigemina or in the cortex, the pupillary reflex is not influenced.

Paradoxical Pupillary Reaction.—Dilatation of the pupil in the presence of light and contraction of the pupil when the light is withdrawn are said to occur at times in meningitis. This phenomenon is termed the "paradoxical pupillary reaction." Doubt has been expressed as to the accuracy of the observation.

Tabes Dorsalis.—In 77 tabetic patients studied by Rochon-Duvignand and Helys,[1] in relation to the condition of the iris, the Argyll-Robertson pupil was present bilaterally in 30 per cent., unilaterally in 13 per cent., and incomplete in 3 per cent.—46 per cent. of the cases observed. Miosis is said to be present when the Argyll-Robertson pupil is pure. When mydriasis is present with a normal fundus there is usually complete iridoplegia interna. Mydriasis is present when all perception of light is lost. Contraction to convergence may be lost in tabes.

Uhthoff[2] found Argyll-Robertson pupil in 67 per cent. of all tabetics examined; pupils of unequal width in 25 per cent.; unilateral paralysis of accommodation in 5 per cent. of 92 cases; reflex immobility without reaction on convergence in 3 of 166 cases observed.

[1] Rev. in Med. Rev. of Reviews, January 25, 1904.
[2] Berlin. klin. Woch., 1886, No. 3.

CHAPTER XI.

THE CILIARY BODY.

ANOMALIES OF THE CILIARY BODY.

Congenital Defects.—These are few and are rarely met with. They are invariably associated with congenital defects of the iris or chorioid, and have been considered with those divisions of the vascular tunic.

DISEASES OF THE CILIARY BODY.

Disease of the ciliary body alone is rarely encountered. Inflammatory processes affecting the ciliary body are almost without exception participated in by the iris, and in many cases the anterior portion of the chorioid is also involved. This must necessarily be so because of the close anatomical relation of these parts, each forming a portion of one and the same membrane. The ciliary body alone may be involved by neoplasms, traumatism, and rarely paralysis.

Hyperemia.—Hyperemia of the ciliary body accompanies all forms of iritis. It may also appear with only slight participation of the iris as a result of eye strain, following excessive use of the eyes by unfavorable illumination or without the proper correction of errors of refraction. The condition manifests itself by a feeling of soreness in the eyes, slight ciliary injection, and ciliary tenderness. This may last a few hours or a few days. If the eye strain is continued the soreness of the eyeball may persist for quite a long period,

Inflammation of Ciliary Body (*Iridocyclitis*).—This is always accompanied by changes more or less extensive in the iris, and should be considered under the term iridocyclitis.

Forms.—Three forms of iridocyclitis due to injury may be designated: (1) A mild form which may be termed serofibrinous (serous cyclitis); (2) plastic iridocyclitis; and (3) purulent iridocyclitis.

1. *Serofibrinous Iridocyclitis* (Serous Cyclitis).—A discission of cataract or operation of any kind on a membranous cataract not infrequently is attended with undue traction on the ciliary processes and in some cases with bruising of the processes. As a result of the traumatism a hyperemic condition of the ciliary body is induced, and at the end of twenty-four to forty-eight hours ciliary tenderness to some degree develops. There is often slight ciliary injection and some serofibrinous exudation.

2. *Plastic Iridocyclitis.*—Ordinarily the disease advances insidiously. From two to five days after the receipt of an injury or an operation for removal of the crystalline lens (operations on the iris and on the cornea are seldom followed by iridocyclitis) there is ciliary injection, often chemosis, increased lachrymation, photophobia, slight discoloration and cloudiness of the iris, plastic exudation with proportionate decrease of vision, edema of the margin of the upper lid which may extend to the entire lid, and pain referable to the eye, the forehead, and temple. The pain is most marked at night. The severity of the symptoms increases for three or four days, the pain sometimes becoming excruciating. The plastic exudate is poured into the posterior chamber, fills the pupillary area, blocking up the pupil, and forming adhesions between the iris and the capsule of the crystalline lens. It may bring about contraction of the pupil with occlusion. The adhesions are of all degrees (see Iris, page 338), depending on the severity of the cyclitis. Organization of the plastic exudate occurs at the equator of the lens and in the anterior portion of the vitreous, sometimes forming a complete diaphragm of pseudomembrane back of the lens. Great contraction in this tissue follows. Masses of plastic exudate may form in the vitreous and appear as floating opacities. The iris, which in the acute stage is thickened and thrown into meridional folds by the presence of the plastic exudate in its stroma, shrinks and becomes atrophic. The lens becomes contracted and cataractous. The ciliary body may be detached in part from its scleral insertion. The chorioid and retina may also be detached anteriorly by the traction exerted by the shrinking exudate. The tension of the globe is usually reduced and may reach T-3, but during the early stages temporary increase of tension may occur. Chemosis may develop. It may continue for a long time and in some cases may become, to some degree, permanent. Ciliary injection remains for some weeks. The edema of the margin of the upper lid passes away in three days to as many weeks. The active process may subside in two weeks; often it requires much longer; recurrences are common. The changes that follow the acute or active stage continue for months and years.

3. *Purulent Iridocyclitis.*—This condition is excited by the entrance into the anterior segment of the globe, usually by perforating injury, of pathogenic microörganisms of sufficient virulence and in sufficient quantity to establish the disease.

Etiology.—Iridocyclitis is produced by the same causes that produce iritis, but the most frequent cause is trauma. Iridocyclitis is particularly apt to follow operative procedures on the crystalline lens. It is common after the entrance of a foreign body and after rupture or a lacerating wound in this region.

Pathology.—The punctate deposits on the posterior surface of the cornea are composed of fibrin, small cells, some granular debris, and often a few pigment granules. The pigment granules are found in the small cells and free in the fibrin, and apparently come from the ciliary body (Lawford).

Cyclitic Membrane.—In the early development of this membrane plastic lymph is thrown out from the ciliary processes. This passes into the anterior part of the vitreous, into the posterior chamber, and to some extent into the anterior chamber. A transudation of small cells also occurs. A coagulum is formed which is composed of fibrin and leukocytes. This is either absorbed or it becomes organized. Some of the leukocytes become fibroblasts; new formed blood-vessels make their appearance, and cells from the pars ciliaris retinæ may proliferate into the new tissue. The formative elements increase and this new tissue becomes converted into connective tissue of the cicatricial type. Pseudomembrane does not readily occur in the posterior or anterior chamber, except where opposing surfaces lie in apposition,

Fig. 198

Cyclitic membrane. (Photographed by Geo. S. Dixon.)

as between the pupillary margin of the iris and the lens capsule; apparently because of the ready absorption of the plastic exudation from these chambers. Where secure lodgment of the coagulum is afforded, as in the anterior portion of the vitreous humor and among the fibers of the suspensory ligament, organization is much more apt to occur. The pseudomembrane is attached to the ciliary body from the heads of the ciliary processes to the ora serrata. Tubular outgrowths from the ciliary processes are at times present in the cyclitic membrane. The pseudomembrane may surround the lens or, in absence of the lens, the entire capsule, but is always more dense over the posterior surface. After the membrane is formed, the vessels disappear and the contraction

characteristic of cicatricial tissue follows. Subsequently degenerative changes may occur, such as fatty degeneration, deposits of lime salts, and the development of osseous tissue. A diaphragm of osseous tissue may develop in the cyclitic membrane and may encase the lens.

Symptoms.—Iridocyclitis is accompanied by lachrymation, pain, photophobia, ciliary injection, tenderness, exudation into the interior of the eye, disturbances of vision, miscellaneous signs and symptoms.

Lachrymation, pain and photophobia become pronounced in proportion to the severity of the inflammation and continue until the active inflammatory process has subsided.

Ciliary injection resembles that present in iritis except that it is apt to be of a purple hue and may be "patchy." In some cases the ciliary zone is hidden by chemosis. Ciliary tenderness is apparent on pressure over the ciliary region. This may be determined by pressure over any part of the region in severe cases. In subacute cases and in cases of very mild degree, especially at the onset of the disease, pressure over the lower part of the ciliary region may elicit tenderness when all other parts are negative in this respect.

The exudation may be *serous, serofibrinous, plastic, or purulent.* The presence of serous exudate is not appreciable unless there is increase in tension without evidence of obstruction of the filtration angle, when it may be inferred. Exudation with fibrin-forming elements is always accompanied by serum and by small cells to a greater or less degree. In the milder forms of iridocyclitis there is but little tendency to the formation of pseudomembranes, synechiæ, etc. In these cases the exudate is serofibrinous.

Serofibrinous exudation manifests itself by the deposition of minute masses on the posterior surface of the cornea, often arranged in the form of a pyramid with the base downward, as in Fig. 200, *B*. Similar deposits may often be found on the iris and anterior capsule of the lens. Numerous minute particles may be present in the aqueous humor and in the anterior portion of the vitreous. As the patient recovers, these masses disappear without leaving a trace.

In the severe forms the secretion is plastic. Posterior synechiæ, pupillary membranes and cyclitic membranes form in addition to the deposits observed in serofibrinous cases.

In chronic cases of cyclitis masses of exudate may appear in the iris angle, pushing forward the root of the iris or projecting beyond the iris at its insertion, having the appearance of minute, irregular tumors that are more or less pigmented. These masses slowly disappear on subsidence of the process.

Purulent exudation is seldom observed. In some cases the number of small cells present in a plastic exudation give the impression of a destructive process. Transient hypopyon may form. Eventually, recovery may take place with little permanent damage. In a small number of cases the process is destructive; panophthalmitis develops and the eye is destroyed.

Impairment of vision follows in all cases, the degree depending on

the severity of the process and the amount and character of the exudation.

In the early stage of a cyclitis, twelve to thirty-six hours after its inception, there is often edema of the margin of the upper lid. This edema gradually extends over the entire tarsal portion of the lid; it is often the first symptom to warn the surgeon that cyclitis is developing. The tension of the eyeball varies greatly—usually minus (sometimes to a marked degree), it may be plus; the tension may increase, and subside to normal or subnormal, a number of times during the

Fig. 199

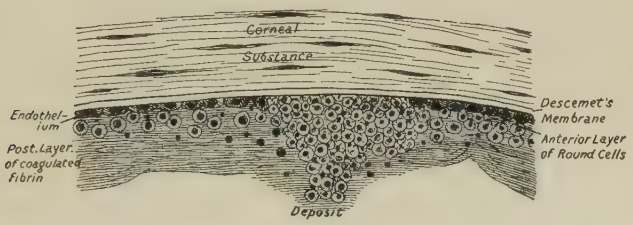

Deposit upon posterior surface of the cornea in cyclitis. The endothelium is intact except where the deposit is thickest. (After Fuchs.)

acute stage of the affection. In the subacute or chronic stage the tension is usually minus. It may become necessary to combat the increase in tension either by the use of miotics (always bearing in mind the danger of the formation of synechiæ) or by paracentesis. Hemorrhage into the anterior chamber is not an infrequent complication of iridocyclitis.

Whitening of the eyelashes has been described.

Disturbances of vision in the way of entoptic phenomena have been observed.

Fig. 200

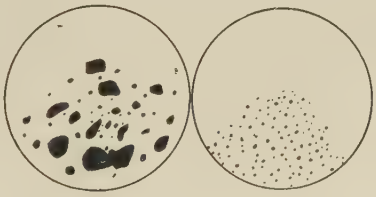

A *B*

Deposits on posterior surface of cornea in cyclitis. *A*, larger deposits; *B*, smaller. (Posey and Wright.)

Results.—Serofibrinous iridocyclitis results in recovery with few exceptions. Some permanent impairment of vision due to the presence of floating opacities in the vitreous may remain.

Plastic iridocyclitis in the mild cases may be recovered from with retention of fair vision, but the cases are indeed rare in which permanent impairment of vision is not considerable. In many cases vision is

reduced to perception of light by the organization of permanent pseudomembranes which block the pupil and invade the anterior portion of the vitreous. In not a few cases atrophy of the ciliary body and globe follows. The traction of the cyclitic membrane and of other cicatricial tissue may produce a painful, sensitive globe (cyclitis dolens).

In purulent iridocyclitis vision is destroyed and *phthisis bulbi* results.

Treatment.—The local treatment consists in the use of atropine to prevent the formation of adhesions between the margin of the iris and the capsule of the lens and to put the ciliary muscle and the sphincter pupillæ at rest. It sometimes occurs that the use of atropine appears to be followed by an increase in the inflammatory symptoms and it becomes necessary to discontinue it. If increased tension develops it may even be necessary to employ a miotic. Under these circumstances pilocarpine in 0.5 to 2 per cent. solution should first be tried. Eserine can be used subsequently if necessary. Applications of moist heat by means of moist compresses or bathing with hot normal saline solution often serve to relieve the pain and afford a sense of relief. The application should be made one-half to one hour at each sitting, and should be repeated four to six times daily. Local bloodletting by the application of the natural or artificial leech to the temple is advised by many, but has never seemed to be of value when used by the writer.

The systemic treatment consists in the use of remedies directed to the removal of the cause. If syphilis is the cause, antisyphilitic remedies should be pushed vigorously. If there is a history of rheumatism or gout or if there is an excess of uric acid in the system, the salicylates should be employed. Subconjunctival injections are resorted to by some surgeons.

The diet should be plain and nutritious and of such a quality that the digestion will not be disturbed. Alcoholic beverages are contraindicated.

Senile Changes.—Senile degeneration of the ciliary body has been studied by Kerschbaumer.[1] The ciliary processes become elongated and enlarged at the anterior extremities, encroaching on the posterior chamber. They may influence the development of glaucoma. By hyperplasia of the epithelium, cyst spaces may form. The connective tissue increases throughout. Vessel walls undergo degenerative changes common to senility. The muscle fibers degenerate, losing their nuclei and shrinking.

Syphilis.—The ciliary body may be the seat of syphilitic manifestations in the second and third stages of syphilis. The diffuse manifestations of syphilis affecting the ciliary body common to the second stage of syphilis are always accompanied by involvement of the iris and have been sufficiently considered in the discussion of syphilis of the iris (see page 330). The localized syphilitic lesions are gumma and tubercular syphilides peculiar to the early and advanced tertiary state, respectively.

[1] Arch. f. Ophth., xxxiv, 4, 1888.

Gumma.—Gumma of the ciliary body is rarely met with. It develops relatively rapidly, reaching an appreciable size in from three to five days. It is accompanied by ciliary injection, ciliary neuralgic pains, a seropurulent exudation of greater or less amount according to the activity of the process. The iris may be but slightly involved, but if the gumma is located well forward, congestion of the iris will be present. The affection is usually monocular, and is seen in subjects with acquired syphilis much more often than in those with inherited syphilis.

Diagnosis.—The pupil should be well dilated. If this can be effected, it is sometimes possible to detect the presence of a tumor projecting from the ciliary body, but is often impossible because of the presence of exudation. When the gumma can be seen it presents a yellowish-red color at its apex and a dark base, due to the presence of the pigment layer which the gumma penetrates. The rather sudden growth of the mass with a history of syphilis will suffice to make the diagnosis.

Tubercular Syphilide.—This growth is much slower in its development and is accompanied by little pain and but little disturbance to tissue other than those directly involved. Inherited syphilis furnishes the greatest number of the cases of this extremely rare condition.

Symptoms.—These are but few. There is little pain, slight ciliary injection localized over the site of the growth, some serofibrinous exudation, and gradual impairment of vision.

Diagnosis.—With the pupil dilated the mass may come into view. It is lobulated and presents a grayish appearance with a slight pinkish flush, difficult to differentiate from tubercle. In some cases a differential diagnosis can only be made from the effect of treatment.

Tumors of Ciliary Body.—Tubercle.—Tuberculosis of the ciliary body occurs as a solitary irregular mass, which may attain to large proportions and may invade the sclera, cornea, and iris, and occupy the entire anterior portion of the globe. It occurs as a grayish, irregular mass, exhibiting but slight evidence of vascularity except at its base, where there is usually evidence of hyperemia. Tubercle of the ciliary body does not produce marked inflammatory symptoms. It occurs in children and young adults.

Diagnosis and Treatment.—Tubercle of the ciliary body may be confounded with a tubercular syphilide and with leukosarcoma. The exhibition of mercury will serve to differentiate it from the former. It is not necessary to differentiate it from the latter, as the treatment, which is enucleation of the globe, is the same in either case.

Cysts of Ciliary Body.—These develop either (*a*) as a result of detachment of the pars ciliaris retinæ from the underlying tissue, (*b*) as a separation of one epithelial layer from the other, (*c*) as an invagination or occlusion of one or more of the ciliary glands (page 62). Hyperplasia of the epithelium or the influences of inflammatory products bring about the detachment of the epithelial layers and the occlusion of the glands. The formation of cysts is similar to that taking place in the iris (page 341). It sometimes, but rarely, occurs that the cyst becomes sufficiently

large to be seen through the dilated pupil.[1] As a rule, the cysts are small and give no trouble. They are recognized only when the eye comes to section.

Epithelial Hyperplasia.—Minute nodular masses projecting from the ciliary processes have been observed from time to time in eyes that have come to section. The masses consist of folds of epithelial cells within a limiting cell wall of similar cells which are usually the more densely pigmented. The masses appear in the eyes of adults and are apparently benign.

Other tumors are sarcoma, myoma, carcinoma (primary and metastatic), and vascular nevi.

Sarcoma.—Sarcoma may be composed of round or of spindle cells, or both, and may be pigmented (which is usually the case), or non-pigmented. Usually globular or lobulated, they may be flat. Groenouw[2] collected 50 cases of sarcoma of the ciliary body from the literature: 90 per cent. were pigmented, 10 per cent. unpigmented. Spindle-cell sarcoma was most frequent, mixed-cell next, and round-cell rarest. The average age of the patients with spindle-cell sarcoma was thirty-five years. The patients with unpigmented were, as a rule, younger than those with pigmented sarcoma. The prognosis is better in sarcoma of the ciliary body than in sarcoma of the chorioid (12 per cent. of cures in the former), probably because it is recognized and operated on earlier.

Secondary Sarcoma.—This, as the result of extension from iris or chorioid, is sometimes encountered.

Myoma.—Tumors composed of non-striated muscle fibers are extremely rare. One observed by the writer occurred as a globular tumor, measuring 7.5 mm. in diameter. It developed very slowly without producing pain, finally causing diminution of vision by partial opacification of the lens and by serofibrinous exudation. It was supposed to be a sarcoma. Microscopic examination showed it to be composed of non-striated muscle fibers, densely packed in an irregular, concentric arrangement. Myoma has also been described by Iwanhoff.[3]

Glioma.—Primary glioma of the ciliary body may develop from the pars ciliaris retinæ. Parsons is of the opinion that growths of this nature developing from the ciliary body should be termed neuro-epitheliomata, since they cannot be regarded as being derived from or containing neuroglia. Emanuel[4] describes a case that occurred in a child, five and a half years of age. The growth presented all of the characteristics of glioma.

Carcinoma.—The development of carcinoma of the ciliary body takes place from the pars ciliaris retinæ from the zone of glands of the ciliary body in the majority of the cases (Collins). The neoplasm is characterized by the presence of epithelial cells arranged in tubules with scant small-celled infiltration and a few fusiform, apparently young,

[1] Greeff, Arch. f. Aug., xxv, 1892. [2] Graefe's Arch., xlvii, p. 398.
[3] Compte-rendu du Congres International d'ophtal., Paris, 1868, p. 118.
[4] Virchow's Arch., clxi, 1900.

connective-tissue cells between the tubules. The growths are not very vascular. They are irregularly pigmented. Development is slow, but the growth may attain to a considerable size.

Schliff[1] reports a tumor of this character which filled the interior of the eyeball. The writer has examined two growths of this nature. The larger was approximately 8 mm. in diameter; both were irregularly globular. Primary carcinoma of the ciliary body does not appear to be very malignant. No cases of recurrence after removal of the globe have been reported.

Secondary Carcinoma.—This has been observed, but only as an extension of metastatic carcinoma from the chorioid.

Endothelioma (*Perithelioma*).—Rare tumors that have apparently originated from endothelial cells have been described (Michel, Schleich). Clinically they present the appearance of pigmented sarcoma. They occur in adults and develop slowly.

Treatment.—Tumors of the ciliary body, not syphilitic, require removal of the globe, excepting possibly some cases of tuberculosis which may be favorably influenced by the use of tuberculin.

Wounds of Ciliary Body.—These may be of all varieties. Punctured wounds, clean incised wounds, lacerated wounds, wounds from blows associated with rupture of the sclera, wounds from foreign bodies, which enter through the sclera in the ciliary region or through remote parts of the fibrous coat, and wounds due to operation on the lens and iris. All wounds of the ciliary body should be regarded as serious because of the possibility of the production of sympathetic ophthalmia. Infected and lacerated wounds and clean wounds with much incarceration of ciliary body demand enucleation almost without exception.

The *ciliary zone* has been justly named the danger zone of the eye, but the assertion sometimes made that all eyes that have received a perforating wound in this zone should be removed, to insure against sympathetic ophthalmia, should be taken with some allowance. The advance in aseptic surgery has made it possible to save some of the eyes so injured. If the patient resides where competent surgical advice can be obtained without delay in case of the occurrence of inflammation in the injured eye, an attempt to save an eye so injured, which would demand enucleation under other circumstances, is justifiable.

Punctured Wounds.—Punctured wounds, if aseptic, seldom lead to serious consequences. If sufficiently large and deep, a very little of the vitreous humor may escape, or the opening may be closed by incarceration of a portion of the ciliary body; healing is not followed by serious complications, as a rule.

Clean Incised Wounds.—These, if not very extensive, may be treated in such a manner that a useful globe with more or less vision may be preserved.

Prolapse of ciliary body or iris must be excised as thoroughly as possible, under strict antiseptic precautions, and the scleral wound, if gaping,

[1] Graefe's Arch., xlviii, 2, p. 353.

should be sutured. This is best done by means of fine silk sutures. Dilatation of the pupil should be obtained.

Wounds from Blows Associated with Rupture of Sclera.—These call for enucleation almost without exception.

Wounds from Foreign Bodies.—These must be treated according to the merits of the individual case.

Detachment of the Ciliary Body.—Detachment of the ciliary body by rupture of the annular ligament may be partial or complete. It may be the result of contused wounds to the globe, or it may complicate the operation for the extraction of cataract. When extensive rupture of the annular ligament occurs, the iris is pulled backward, the iris angle slightly deepened, and the pupil greatly enlarged in the direction of the detachment. Only a small rim of iris may be visible. In total rupture the effect is much like aniridia. Detachment of the chorioid to some extent follows this injury.

CHAPTER XII.

THE CHORIOID.

ANOMALIES OF THE CHORIOID.

Pigmentation.—The amount of pigment present in the chorioid differs greatly in different individuals, corresponding closely to the complexion. In the albino there is absence of pigment (leukosis). In the blonde there is relatively little, but in the brunette and in the negro the pigment is very dense. The degree of pigmentation has a marked influence on the appearance of the fundus of the eye viewed with the ophthalmoscope. (See Ophthalmoscopy.)

Coloboma.—This is a defect in the chorioid usually situated below the papilla. It is primarily due to imperfect closure of the retinal fissure during the development of the eye, and the consequent imperfect

Fig. 201

Coloboma of the chorioid. (Jaeger.

formation of the chorioid over the secondary eye vesicle. The retinal fissure, which begins to close at its posterior extremity, should be completely closed by the end of the second month of fetal life. It may be arrested at any stage of development; hence the various differences in shape seen in coloboma of the chorioid. The defect is often separated from the optic disk by a bridge of normal chorioid; it broadens out

and extends toward the ciliary body. The border of the defect is irregularly pigmented. The anterior layers of the retina pass over the defect, but all perceptive elements are wanting. Viewed with the ophthalmoscope the defect presents a pearly white appearance traversed by a few retinal vessels. Coloboma of the iris not infrequently accompanies coloboma of the chorioid, and coloboma of the lens is sometimes present. Bulging of the sclera at the site of the coloboma may occur. This may assume the character of a cyst; the globe in these cases is frequently microphthalmic. Irregular congenital defects in the chorioid not involving the optic disk have been termed *extrapapillary colobomata* (Johnson). These are irregularly circular in shape, and are usually located in the macular region. When this is the case they are termed *macular colobomata.* Various theories are advanced to explain the origin of these defects, none of which are substantiated.

Angiocavernomata.—These are sometimes observed as congenital defects in the chorioid.[1] They may occur in any part of the membrane.

DISEASES OF THE CHORIOID.

Hyperemia.—This condition is undoubtedly present much more frequently than it is recognized. In congestion of the head—preceding a general or local inflammation of the chorioid, accompanying an exudative retinitis, in leukemia and pernicious anemia, hyperemia of the chorioid is present. In this condition the color of the fundus is intensified and slight reddening of the optic disk occurs. Unless one eye alone is affected the change in the appearance of the fundus is so slight that it is impossible to diagnosticate it by means of the ophthalmoscope. It is held by some writers that hyperemia of the chorioid is accompanied by certain subjective symptoms such as meteoric flashes of light, wavy effects as that observed in the atmosphere over a heated surface—photopsia. These phenomena are due to disturbance of the perceptive elements of the retina and do not always accompany hyperemia of the chorioid. They often precede destructive processes affecting the chorioidal blood-vessels, and should be given careful attention.

Chorioiditis.—All forms of chorioiditis are *exudative,* but for convenience they may be divided into non-suppurative and suppurative. Non-suppurative chorioiditis includes the serofibrinous, plastic, disseminate, diffuse, areolar, circumscript, hemorrhagic, sclerochorioiditis anterior, and some forms of central chorioiditis.

Serofibrinous Chorioiditis.—This form is characterized by a relatively sudden onset and the appearance of a serofibrinous exudate in the vitreous. The same form of exudate is present in the posterior and anterior chambers in many cases. There is more or less congestion of the deep vessels of the ocular conjunctiva. The entire vascular tunic is frequently involved.

[1] Lawford, Trans. Ophth. Soc. Unit. Kingdom, vol. v, p. 136.

Etiology.—Serofibrinous chorioiditis may be due to syphilis, occurring in the second or early part of the third stage. It is probable that tuberculosis is not an infrequent cause. Gonorrhea and la grippe occasionally produce this form of chorioidal disease. When from these causes the exudation appears very rapidly, the vitreous may be filled with the fine particles or masses of fibrin in from twenty-four to forty-eight hours.

Rheumatism and gout are supposed to stand in a causative relation in a small percentage of cases. Malaria, typhoid and typhus fever may be considered occasional causes.

Pathology.—In this form of chorioiditis perivascular infiltration of small cells is sometimes found. The chorioidal vessels are engorged and the chorioid is slightly edematous. When the acute stage is passed there may be little change in the chorioid, but in not a few cases slight atrophic changes occur affecting the choriocapillaris, causing disturbances in the chorioidal and retinal pigment.

Symptoms.—Unless the ciliary body and iris are involved to a considerable degree no pain is experienced in the cases which do not develop secondary glaucoma. The vitreous body becomes filled with minute particles of fibrin, which obscure the view of the fundus, and the aqueous may be invaded by particles which often become attached to the posterior surface of the cornea. The vision is correspondingly obscured, as in the same form of disease when the iris or ciliary body or both are the principal parts of the vascular tunic involved. Photopsia is not a prominent symptom. The anterior chamber is shallow because of an increase in the contents of the vitreous chamber. The pupil is moderately dilated.

Course.—The disease runs its course in from six weeks to as many months. The opacities in the aqueous humor gradually disappear. Those in the vitreous body may entirely disappear, but in many cases some large shreds of exudation remain and are movable. In some cases no evidences of changes in the chorioid are discernible; in others atrophic patches at the periphery may be seen. Vision may return to the degree of acuity present before the inflammation began; often there is some permanent loss. If atropine is not instilled, adhesion between the iris and anterior lens capsule may occur and the synechia become permanent. Recurrence is not uncommon.

Treatment.—The local treatment consists in the instillation of atropine to prevent the formation of posterior synechiæ. The systemic treatment depends upon the cause. This should be carefully sought for and when determined the treatment indicated should be vigorously conducted.

Chorioretinitis Syphilitica.—Since in all forms of chorioiditis the retina is more or less implicated, it would be more exact to include the retina in all of the terms used to indicate the different forms of chorioiditis, but as the involvement of the retina is not a striking part of the picture portrayed by the disease in many of the forms of chorioiditis, the retina is not mentioned. Some of the forms involve the retina very seriously and to one of these the term chorioretinitis syphilitica

is given. Chorioretinitis syphilitica may develop six months to as many years after the initial lesion of syphilis.

Symptoms.—The diffuse haziness of the vitreous is present usually to a less extent than in serofibrinous chorioiditis. Shreds of exudation appear in the vitreous, and isolated large or small spots of exudation occur in the chorioid. The retina appears hazy because of edema; retinal hemorrhages may occur. The evidence of perivasculitis of the retinal and chorioidal vessels is unmistakable. The vision is frequently greatly diminished; flashes of light, photopsia, micropsia and macropsia may be experienced. Slight injection of the ocular conjunctiva may occur in the acute stage, pain is not experienced, as a rule. In many of the cases the vitreous remains sufficiently transparent to permit of a more or less satisfactory examination of the fundus. The exudation into the chorioid and retina is seroplastic. Circular patches of plastic exudation may occur in the chorioid, which pursue the same course (ending in atrophy) as in disseminate chorioiditis. The retinal pigment may disappear over a large area of the fundus, exposing the chorioidal arteries and veins. As a result of plastic exudation in the retina, cicatricial bands may develop in that membrane; cicatricial bands may also develop in the plastic exudation that sometimes extends into the vitreous body.

Detachment of the retina, as a result of contraction of cicatricial bands in the vitreous body, is rare, as the chorioid and retina are adherent in many places; but detachment of the chorioid and retina together is sometimes seen, following degenerative changes in the vitreous. Cataract and atrophy of the globe are rare results.

Fig. 202



Diffuse chorioiditis with partial atrophy of the retina and the optic nerve. (Posey and Wright.)

Treatment.—The inflammatory stage usually responds quite readily to antisyphilitic treatment, but the treatment must be vigorous and long-continued.

Diffuse Chorioiditis.—This form of chorioiditis is characterized by the appearance of large, pale plaques of exudation in the chorioid, most extensive at the periphery. These patches at first are of quite a uniform orange or pale yellowish-pink color *not bordered by pigment.* The retina over the areas of exudation is slightly edematous. The patches coalesce, forming irregular areas with indentations of normal fundus. The forms assumed have been likened to continents and islands, and have been termed "map-like." Sometimes they assume the shape of leaves which has caused them to be termed "leaf-like." Children and young adults are most frequently affected.

The disease is extremely slow in its development. The exudate appears slowly and as slowly disappears, leaving irregular, scanty

pigmentation over the affected areas and a little pigmentation at their borders in some places. The pigment layer of the retina and the superficial layers of the chorioid, the choriocapillaris particularly, atrophy and disappear. The deeper layers of the chorioid remain nearly if not quite intact. Perivasculitis occurs, and sometimes there is almost complete conversion of the larger vessels of the chorioid into connective-tissue bands. The retinal vessels in severe cases become reduced in size and the optic disk presents hazy edges and becomes slightly pale, giving evidence of partial atrophy of the optic nerve. Individuals affected almost always present the stigmata of inherited syphilis.

Symptoms.—The patient experiences no pain, nor is there any injection of the external ocular tissues. Night-blindness may be experienced; there are scotomata in the parts of the visual field corresponding to the affected areas of the chorioid.

Prognosis.—The prognosis for recovery of vision is not good, but much can be done to prevent the further advance of the disease.

Treatment.—Antisyphilitic treatment in moderate dose, long-continued. Iron, if indicated, and careful regulation of the diet, directed to improving the general condition, effect the best results.

Fig. 203

Late stage of disseminate chorioiditis.

Disseminate Chorioiditis.—This form of chorioiditis consists in the development of foci of exudation which are spread out over a large part, often the entire fundus, in the shape of circular patches which vary in size, but, as a rule, average in diameter less than that of the optic disk. After a time the exudation becomes absorbed or changed into

fixed products, and atrophic areas occupy the site of the areas of exudation. Although it may affect but one eye the disease is binocular in the greater number of cases.

Forms.—Two stages are recognized, acute and atrophic.

Acute Stage.—In the early part of the acute stage, circular spots of exudation appear in certain parts of the fundus, usually beginning at the periphery, which are paler than the surrounding normal fundus. These spots have not very sharply defined borders. The retina immediately over the masses of exudation is not elevated, as may readily be determined by examination with the ophthalmoscope; but there is often an invasion of the retina by the exudate, evidenced by the hazy appearance of the retina at these points. The spots multiply in number if not interfered with, resembling in many cases the groupings of papillary syphilides as they appear on the skin. The areas of exudation are primarily discrete, but may eventually coalesce. The greater part of the fundus may become studded over in two or three weeks, but in not a few cases some of the spots may have passed to the second stage when others have but just appeared. Ordinarily the cornea and media remain clear, but a parenchymatous keratitis may occur at the time of the onset of the chorioiditis and the presence of the affection of the chorioid may not be discovered until the cornea again becomes clear.

Atrophic Stage.—The first stage passes slowly into the second. The exudation gradually disappears, the spots become paler, the border of the affected area becomes irregularly pigmented, the pigment being heaped up at different points. Flecks of pigment are often seen over the area of the spot itself. Entire absence of pigment has been observed. All degrees of change may occur in all the layers of the chorioid, from little impairment to complete atrophy, with disappearance of all vessels. The cicatricial tissue, lying over the exposed sclera, presents a whitish color slightly tinged with yellow. The pigment changes noted are due to destruction and more or less complete disappearance of the chorioidal and retinal pigment throughout the affected area. In many cases not treated, the affected areas coalesce and form large patches. It is also known that atrophic spots may increase in size and affect larger areas without the appearance of fresh exudation, probably because of the interference with the nutrition of adjacent tissues.

Etiology.—Syphilis, inherited and acquired, is probably the most frequent cause, although the research work of W. Stock[1] and the observations of Axenfeld, von Hippel, Michel, Griffith,[2] and others indicate that tuberculosis is frequently the etiological factor. Any profound disturbance of nutrition, such as occurs in anemia and in malaria, is thought by some to cause the affection. Meier[3] examined 238 cases of chorioiditis disseminata in respect to cause. In females chlorosis was usually present; scarlatina and acute rheumatism seemed to be causes; syphilis and tuberculosis rarely.

[1] Graefe's Arch., lxvi, 1, S. 1.
[2] Norris and Oliver, System of Diseases of the Eye, p. 351.
[3] Inaug. Dissert., Tübingen, 1902.

Pathology.—In the acute stage a small-cell infiltration into the chorioid takes place at the site of each lesion, accompanied by local congestion of small blood-vessels and capillaries and a plastic exudate. At many of the foci small cells and plastic exudate penetrate into the retina.

More or less atrophy follows the disappearance of the exudate, the atrophy affecting not only the chorioid but also the posterior layers of the retina. Destruction of the choriocapillaris probably always occurs at the site of the exudation. With destruction of this layer the posterior layers of the retina are deprived of adequate nutrition, and degenerate; cicatricial tissue is found not only in the chorioid, but often in the deep layers of the retina. This frequently unites these two membranes. Impairment of the retina, if extensive, results in atrophy of many of the afferent nerve axis cylinders and consequent partial atrophy of the optic nerve. The portions of the retina that are sufficiently nourished preserve the axis cylinders which go from them. Degenerative changes in the vitreous and in the crystalline lens may take place. The pathology is indicative of a syphilitic rather than of a tubercular process.

Symptoms.—Pain is not a prominent symptom. It may be experienced in small degree, referable to the eye and temple. Loss of vision in portions of the fields of vision corresponding to the affected areas and diminution of vision in contiguous parts from impairment of nutrition; photopsia manifested variously during the acute stage; micropsia is sometimes observed; slight photophobia in the acute stage in some cases.

Duration.—The stage of exudation may last a period of years. As a rule, the exudation disappears in six months to two years, and the stage of atrophy follows. Fresh outbreaks of exudation may occur. A chorioid that has remained quiet for years may present recent foci of exudation.

Treatment.—Much can be accomplished by vigorous judicious treatment in the acute stage of disseminate chorioiditis, but nothing of importance can be done to correct the condition when the atrophic stage is reached. The treatment is almost wholly constitutional. The exudation is due to localized vasculitis. Nourishing diet must be insisted upon. Rest in bed is valuable in the early part of the acute stage. The use of colored glasses and the prohibition of the use of the eyes for close work should be enjoined. In the acute stage of syphilitic origin, mercury by inunction or by the stomach or hypodermically should be given to saturation, and potassium iodide until the physiological effects are obtained. These remedies should be continued, a little short of saturation, until the exudation has very nearly or quite disappeared. The treatment in a less vigorous manner should be continued for six months to two years, according to the exigencies of the case. On account of their power as absorbents, mercury and the iodide of potash should be given whatever the cause. The salicylates (sodium or strontium—the latter is less irritating to the stomach) may be given in rather large dose (1 to 3 gm.), frequently repeated (every two or three hours), two or three days in succession during the acute stage, if well borne and

followed by evidences of improvement, and repeated after an interval of a few days, if required. In all cases in which tuberculosis is suspected and in the cases in which antisyphilitic treatment and the salicylates are not followed by improvement, tuberculin should be employed (1) as an aid to diagnosis and (2) for its therapeutic effect.

Chorioiditis Centralis.—Chorioiditis affecting the region of the macula is spoken of as central chorioiditis. There is always more or less photopsia, often with micropsia or macropsia.

Etiology.—As in disseminate chorioiditis (page 364).

Results.—Permanent impairment of central vision, varying in degree with the amount of damage done to the retina.

Treatment.—As in disseminate chorioiditis.

Chorioiditis Areolaris (Förster).—This form is probably a variety of chorioiditis disseminata. It first presents itself as a plaque of pigment. Soon the centre of the plaque becomes pale; the pale area enlarges and eventually an atrophic patch forms, surrounded by a relatively broad border of pigment. These patches coalesce and form rather large irregular patches situated at or near the posterior pole of the globe, sometimes at the periphery. There are seldom more than two or three foci. The patch sometimes looks like a filagree of iron, through the openings of which the white tissue (sclera and cicatricial tissue) appears as though it were placed a short distance back of the screen. This form of chorioiditis is met with in young children and is thought to be congenital in some cases. It develops also at all ages. There may be few or many patches. The vision may remain very good for a number of years. It may fail quite suddenly without apparent cause.

Fig. 204

Central guttate senile chorioiditis.

Etiology.—Inherited syphilis is the most frequent cause. The causes of disseminate chorioiditis also apply to this form. It is held by some writers that undue use of the eyes by intense illumination, with or without uncorrected errors of refraction, causes central and areolar chorioiditis in a small percentage of the cases.

Guttate Chorioiditis (Hutchinson and Tay).—The region of the macula is occupied by a number of small, whitish or yellowish dots which are often clustered together. The dots are circular in form and their borders are not very sharply defined. They seldom reach more than one-fourth the diameter of the disk, and are often very minute. These spots may be very numerous. They do not tend to disappear, but rather to increase in number; they produce no impairment of vision. This condition is due to the formation of excrescences on the lamina

vitrea which project slightly into the retina. It is peculiar to adult life. Such spots are sometimes observed scattered more or less densely over the entire fundus, but in the greater number of cases they extend from a point a little to the nasal side of the macula well to the temporal side in an irregular, broad, horizontal oval. The condition is always approximately symmetrical.

Embolic Chorioiditis (Metastatic), Plastic and Suppurative.—Embolism of one or more chorioidal vessels probably occurs more frequently than is recognized. The dozen or more short ciliary arteries that pierce the sclera anastomose freely when they reach the chorioid, consequently the plugging of one artery can make but little difference in the circulation in this membrane. If the plug that enters a short ciliary artery does not contain pathogenic germs the disturbance occasioned is slight. Knapp[1] describes two cases of simple embolism in which the onset of the symptoms was quite sudden. The patient noticed a blurring of vision which at first included the whole field, but later became confined to the central portion. In one case the vision equaled $\frac{1}{10}$; in the other case the patient could read the finest print. The patient noticed a large scotoma lying near the axis of vision. There was marked chromatopsia and photopsia. On ophthalmoscopic examination a circumscribed cloud or veil was observed in the central portion of the fundus, corresponding to the scotoma, which involved the retina and extended to the disk. In each case vision was completely restored. Each patient had well-marked cardiac disease. From a suppurative process taking place in some distant part of the body a minute mass of pyogenic or pathogenic microörganism may enter the circulation and be conveyed to the chorioid of one or both eyes; a plastic, suppurative, or tubercular chorioiditis according to the character of the microörganism is the result. Ulcerative processes in the alimentary canal, in the genital tract, or on the skin may be the foci from which microörganisms proceed by way of the blood to the chorioid. The metastasis may occur in cerebrospinal meningitis, puerperal fever, pyemia, smallpox, pneumonia, influenza, erysipelas, cholera, malignant pustule. It has been observed accompanying ulceration of the umbilical cord of the newborn. In some cases no focus or origin could be discovered. Plastic chorioiditis and tubercular chorioiditis are seldom due to injury, but suppurative chorioiditis is frequently the result of perforating wounds of the eyeball as well as of metastasis.

Plastic Embolic Chorioiditis.—The onset of this disease is similar to that of suppurative chorioiditis (see below), but is not so severe. The vitreous body becomes hazy, the anterior chamber usually shallow, sometimes deepened, the ocular conjunctiva hyperemic. The tension is usually less than normal, but may be slightly increased in the early stage, in the later stage the tension of the globe is much reduced.

Symptoms.—There is pain during the first stage, which is of a dull, continuous character; also systemic disturbances, such as nausea and

[1] Arch. f. Ophth., xiv. 1.

vomiting, rise of temperature, and acceleration of pulse. The vision is reduced to perception of light, or may fail entirely. Posterior synechiæ develop. Soon a yellowish reflex is observable from behind the pupil due to the presence of plastic lymph in the vitreous chamber. Plastic lymph may fill the whole vitreous chamber, or it may be spread in a layer of varying thickness over the entire fundus. In the average case of this form of chorioiditis the globe, which at first appears to be slightly distended, gradually shrinks, becomes smaller than its fellow, and maintains this atrophic condition, vision being entirely lost. In the very mild cases some degree of vision may be retained.

Fig. 205

Metastatic chorioiditis. Early stage. (Axenfeld.)

Diagnosis.—In the severe cases the inflammatory reaction is such and the progress of the case to *atrophy of the globe* is so unmistakable that the diagnosis is readily made; but in the milder cases the color of the reflex, the tension, size of globe, presence of vessels, and the situation of the exudate are such that it is very difficult to differentiate the condition from glioma retinæ and some forms of tubercular and syphilitic disease of the chorioid and retina. In making a differential diagnosis the history of the case is probably the most important factor; a history of meningitis, pneumonia, some of the eruptive fevers, or of a suppurative process just preceding or occurring at the time of the onset of the eye disease, aids much to clear up the diagnosis. Locally, broad adhesions between iris and lens, with a broadening of the sinus of the anterior chamber, atrophy of the iris, minus tension, reduction in the size of the globe (atrophy) occur in metastatic plastic chorioiditis, but are seldom met with in glioma, tubercular or syphilitic growths. There may be tenderness on pressure, but this may also be present in glioma.

Treatment.—In the mild cases the vigorous use of mercury and iodide of potassium seems to benefit by preventing plastic formations. Subconjunctival injections and other special forms of treatment are apparently of no value. In all cases where vision is nil and the question of glioma cannot be settled or the globe is at all painful, enucleation may be resorted to. Recurrent inflammation may also render enucleation advisable.

Suppurative Chorioiditis (*Panophthalmitis*).—Suppurative processes originating in the chorioid are not confined to this membrane, but involve all the tissues of the interior of the eye, often perforating the sclera or cornea. The general nature of the affection entitles it to the term panophthalmitis.

Etiology.—The cause is most commonly injury, accompanied by the introduction of pyogenic or pathogenic germs. Metastasis may be the manner of infection, pus-producing microörganisms being carried to the chorioid from purulent processes occurring in distant parts of the system. The germ most often found is the staphylococcus, but the streptococcus, the pneumococcus, the Bacillus coli communis, and the Bacillus pyocyaneus have also been found as causative factors. Panophthalmitis from the presence of the pneumococcus has been observed in patients in whom no focus for the origin of the infection could be discovered.

Pathology.—In plastic and in purulent chorioiditis, the chorioidal vessels become greatly engorged and the stroma of chorioid and retina become densely filled with small cells. In plastic chorioiditis a fibrinous exudate, containing many small cells, partly or wholly fills the vitreous and an exudate may form between chorioid and sclera, separating these membranes. In purulent chorioiditis the vitreous chamber becomes filled with pus.

Symptoms.—Severe continuous pain is experienced almost from the beginning. Sight is lost very early. After the inception of the infectious material a period of from twenty-four to forty-eight hours elapses before the disease obtains sufficient headway to occasion great discomfort. Then the ocular conjunctiva becomes swollen and hyperemic. Chemosis, sometimes to an enormous degree, causing the conjunctiva to protrude between the lids, develops. The lids are frequently enormously swollen. The tissues of the orbit also frequently partake of this condition, causing the eyeball to bulge forward. The flow of tears is increased and some mucopurulent discharge from the conjunctiva is often observed. The anterior chamber becomes shallow and the aqueous humor turbid. A yellow reflex is often seen through the pupil. The tension is sometimes raised, although in many cases the tension is reduced. The cornea becomes gray and frequently sloughs, permitting the escape of pus from the interior of the eye. The pain is not confined to the eyeball, but extends over the side of the head corresponding with the affected eye. In from eight to fourteen days the inflammation subsides, pain diminishes, and the process terminates, the globe gradually shrinks, passing into atrophy or the condition known as *phthisis bulbi.*

Treatment.—The application of moist heat by means of compresses dipped in hot water, or by means of hot poultices, hastens the process. Laxatives should be administered and the pain controlled. The more modern treatment is to regard panophthalmitis as an abscess or phlegmon of the eyeball and treat it as an abscess or phlegmon is treated when it occurs in other parts of the body, namely, by a crucial incision through the cornea, followed by frequent cleansing of the eye with an antiseptic solution (bichloride, 1 to 1000) and hot poulticing. This does much to shorten the process and to relieve pain. Complete evacuation of the contents of the globe—evisceration, packing the cavity subsequently with strips of iodoform gauze (see chapter on Operations), is excellent treatment in the early stage of the affection. If it is evident when the

patient is seen within twenty-four or forty-eight hours after the onset of the affection, that panophthalmitis will develop, the eye may be enucleated with a real benefit to the patient, provided little pus has formed and the pus is confined to the eyeball.

Tubercular Chorioiditis.—This form of chorioiditis is usually due to the development of miliary tubercles in the stroma of the chorioid. However, in some cases large conglomerate tubercular masses develop in the chorioid. Tubercular chorioiditis is metastatic in origin and commonly accompanies miliary tubercular processes in other parts of the body. The disease appears most freqently in children and is more common in individuals who suffer from tubercular meningitis. Chorioidal miliary tubercles develop in from four to six days, and may serve to aid in the diagnosis of the general condition. Michel[1] puts the percentage of miliary tubercle of the chorioid accompanying tubercular meningitis in children at 35 to 40 per cent. Tubercle of the chorioid is seldom seen in chronic pulmonary tuberculosis.

Diagnosis.—Miliary tubercles usually appear at the posterior part of the fundus and are not visible until they occasion disturbance of the retinal pigment layer. At first a small spot more deeply colored than the surrounding fundus is observed, due to slight prominence of the pigment layer over the tubercle. Soon the centre of the pigment patch takes on a pale yellowish color, circular or oval in shape, due to absorption of the pigment. The patch is sometimes smaller, sometimes a little larger than the optic disk. According to many writers, they have an average diameter of 1 mm. If a number of miliary tubercles are grouped together, as is often the case, the size and shape of the patch are changed. Many tubercles may be scattered over the fundus, or there may be but one or two present. Retinal vessels pass over the patch. The retina is slightly raised and in some cases a slight local detachment occurs. As a rule, miliary tubercle develops in the choriocapillaris, but occasionally the development is from the layer of large vessels, when the tubercle may project toward the sclera and produce very little disturbance of the retina (Margulies). Vision is but little interfered with, except in the portion of the field corresponding with the site of the tubercle, where there is a relative or complete scotoma. Large tubercular masses which develop slowly and are associated with detachment of the retina have been observed. They are very rare. They may accompany chronic tuberculosis of any part of the body or may appear when tubercular processes in other parts of the body cannot be demonstrated. The masses are nodular and of a pale gray color. The presence of small, white nodules at the base of the mass serves to aid in differentiating this form of tumor from other forms of intra-ocular neoplasm. Large tubercular masses appear to be made up of numerous small tubercles.

Treatment.—In miliary tubercle of the chorioid, if the system is not involved, much can be accomplished by the use of tuberculins. If the

[1] Augenheilk., p. 404.

PLATE XVII



Chorioiditis Tuberculosa Miliaris. (Posey and Wright.)

general system is involved nothing need be done, as the disease which occasions the metastasis usually proves fatal. In large tubercle of the chorioid enucleation should be resorted to for the purpose of relieving symptoms due to the local process and to prevent the spread of the tuberculosis.

Leprosy of Chorioid.—The chorioid is sometimes invaded by the bacillus of leprosy as an extension from the ciliary body. The disturbance occasioned is slight.

Hemorrhagic Chorioiditis.—The vessels of the chorioid, like those in other parts of the body, may be the seat of disease and their walls may become so weakened that the fluid and at times the corpuscular portions of the blood may escape into the tissue of the chorioid and also beneath the retina. The escaped blood may break through the retina and enter the vitreous body.

Small hemorrhages assume the shape of circular or oval patches quite uniform in color. Large masses of blood-clot may bulge the retina forward. By gravity the upper border may assume a horizontal line in these cases, the lower border being convex. Above the clot the tissues are tinged a yellowish red by the partly absorbed blood pigment. The clot gradually becomes absorbed, leaving a white patch of atrophy with some pigment scattered over it. Chorioidal hemorrhage may produce acute secondary glaucoma.

Treatment.—The treatment consists in correcting the condition of the vascular system that permits of the escape of blood.

Detachment of Chorioid.—The cases may be conveniently divided into four groups.

1. Due to trauma: Fuchs, Bietti, and others have described detachment of the chorioid as being due to trauma accompanying the extraction of cataract. Fuchs[1] reports 4.4 per cent. of detachment of the chorioid after extraction with iridectomy in 318 cases, and 5.17 per cent. in 175 cases of simple extraction. He also reports 10 per cent. of detachment after iridectomy for glaucoma in 111 cases. The detachment occurred in from two to eight days after the operation, and was manifested by circumscribed prominence of the fundus without detachment of the retina. Such a high percentage of detachment has not been reported by any other surgeon. Limited detachments are easily overlooked. Detachment after operation results from a small partial detachment of the annular ligament of the ciliary body and the subsequent presence of serous fluid between the chorioid and sclera.

2. Due to traction on the retina and chorioid by pseudomembranes formed in the vitreous body.

3. Due to hemorrhage between chorioid and sclera.

4. Due to the presence of inflammatory exudate between chorioid and sclera.

Diagnosis.—This is difficult since the retina is carried into the vitreous chamber in advance of the chorioid and the condition of retinal detach-

[1] Graefe's Arch., liii, p. 375.

ment is diagnosticated. If the system of chorioidal vessels can be seen, the true state of the condition can be determined.

Prognosis.—The prognosis is fairly good for complete recovery in the first group; the second group is not favorable. Groups 3 and 4 present the possibility of recovery.

Detachment of the chorioid aside from detachment following cataract extraction seldom occurs in other than degenerated, sightless globes, consequently the condition is of little importance.

Treatment.—Rest in bed and the employment of diaphoretics and laxatives as in the treatment of detachment of the retina in its early stage (see Retina) are beneficial in Groups 1, 3, and 4.

Fig. 206

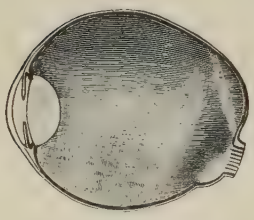

Section of a highly myopic eyeball. The retina has been removed. (Nettleship.)

Affections of Chorioid Related to True Atrophies.—Affections of the chorioid that present little or no evidence of inflammation but belong more nearly to the true atrophies are the condition of the chorioid accompanying posterior staphyloma (sclerochorioiditis posterior), superficial senile chorioiditis, and chorioretinitis pigmentosa.

Posterior Staphyloma.—It is commonly met with in high degrees of myopia, but the milder forms are not infrequently seen in eyes that were in early life highly hyperopic, the hyperopia diminishing or gradually passing over into myopia.

As the process advances atrophy of the chorioid occurs. This takes place along the border of the scleral crescent, augmenting the crescent and being greatest in the direction of the greatest distention of the sclera, usually to the temporal side and below. When the retinal pigment disappears and the tissue of the chorioid atrophies, the appearance is that of a greatly enlarged scleral crescent, the outer border of which is more or less irregular. If portions of either retina or chorioid remain the surface will be more or less flecked with pigment or traversed by blood-vessels, or both.

Fig. 207

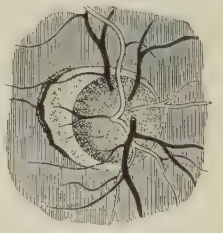

Myopic crescent or small posterior staphyloma. (Wecker and Jaeger.)

The crescent may present the appearance of two or more zones differently colored. These, according to Fuchs, represent different periods of the enlargement of the staphyloma. The most deeply pigmented crescentic zone occupies the portion nearest the normal chorioid (Fig. 206). It may be slightly or very deeply pigmented. The line separating the crescent, due to the staphyloma, is well defined in those cases in which the process has not advanced to a high degree and usually indicates that the condition is stationary. In progressive cases the border of the crescent nearest to the healthy chorioid is ill-defined and irregular.

As the staphyloma advances the chorioid and retina lining the staphyloma undergo changes that interfere with their function to a greater or

less degree. They become much thinner than normal, their component parts being spread out over the increased area. This permits the sclera to shine through to a greater extent, giving the fundus over this area a pale appearance often referred to as *rarefaction* of the chorioid and retina. Minute rents in the chorioid, accompanied by small hemorrhages and atrophy more or less extensive, may develop. The affected area often extends completely around the disk (annular staphyloma). The variety of appearances that these changes may present is infinite. The condition is sometimes termed posterior central chorioiditis, but there is no small-cell infiltration or exudation, the characteristic accompaniment of inflammation. When the affection of the chorioid accompanying posterior staphyloma involves the region of the posterior pole of the globe at the fovea centralis, vision is seriously interfered with.

Diagnosis.—Crescentic defects in the chorioid, due to progressive staphyloma should be differentiated from the scleral crescent which is observed in cases of coloboma of the sheath of the optic nerve. The crescents may be similar, but in the latter condition they occur below and often slightly to the inner side of the optic disk.

Annular posterior staphyloma should not be confounded with the scleral ring that accompanies glaucoma. The latter is usually of uniform width and is associated with increased tension. (See Glaucoma, page 403.)

Effect on the Field of Vision.—The moderate-sized scleral crescent causes an enlargement of the normal blind spot in the field of vision. The large atrophic patches in the chorioid and the accompanying atrophy of the retina produce large central scotomata which are partly or wholly absolute; the periphery of the field is normal in extent.

Treatment.—See Myopia.

Superficial Senile Chorioiditis.—Atrophy of the choriocapillaris over larger or smaller areas occurs in adults of advanced years, and is accompanied by greater or less-change in, or loss of, retinal pigment over the affected area. Accompanying this there is often obliterating arteritis affecting the arterial trunks of the layer of larger vessels, causing localized atrophy of the deeper structures of the chorioid. Peripheral portions of the chorioid are most frequently affected. The change may occur at the posterior pole of the eye alone. It may also develop in a zone concentric to the macula lutea. (See Retina.)

Pathology.—The walls of the capillaries and small blood-vessels become thickened and their lumen obliterated, the change affecting the choriocapillaris particularly. Retinal pigment disappears and the outer layers of the retina become atrophic throughout the affected area.

Treatment.—The best results, in the experience of the writer, are obtained by the long-continued administration of the iodides and mercury in moderate dose—iron, if the hemoglobin is below normal, and in proper attention to diet.

Chorioretinitis Pigmentosa.—This is a non-inflammatory degeneration, affecting the vessels and the structures of both membranes. It is described under the heading Retinitis Pigmentosa.

The affection known as retinitis proliferans is also a disease in which atrophy of the chorioid is an accompanying condition.

Injuries of Chorioid.—Injury may affect this membrane in a number of ways.

Rupture of Chorioid.—Hemorrhage and rupture of the chorioid are frequently met with as a result of a non-perforating blow on the eye, the lesion usually appearing at a spot opposite to the point of impaction; the rupture is due to contrecoup. In rupture of the chorioid, the injured portion is at first obscured by the hemorrhage and by exudation, which usually increases for a few hours. The exudation passes into the retina and extends into the vitreous. When the exudation and blood have become absorbed, an atrophic patch is usually seen in the posterior part of the fundus, concentric to the optic disk. The retinal vessels pass over this patch, showing clearly that it affects a tissue beneath the anterior layers of the retina. Although usually arranged in a manner concentric to the disk, ruptures of the chorioid may assume almost any shape. The ruptures may be single or multiple. A scotoma is present in the visual field corresponding to the location of the rupture.

Fig. 208

Rupture of the chorioid. (Posey and Wright.)

Prognosis.—Favorable.

Treatment.—In rupture of the chorioid from contrecoup but little can be done. It is probably best to put the patient to bed and to give remedies that will prevent the development of plastic processes or the organization of plastic exudates.

Perforating Wounds of Chorioid.—These are of all kinds and of all degrees—punctured, lacerating, incised, clean, infected. Clean, incised wounds, if not too extensive, will heal without great injury to the eye. Considerable hemorrhage is apt to follow perforating wounds of the chorioid. If the blood extends into the vitreous body, we may apprehend the formation of fibrous bands in the vitreous, and these may ultimately result in detachment of the retina. Infected wounds often lead to panophthalmitis.

Cartilage in the Chorioid.—Pes[1] describes a unique case of the formation of a plate of hyaline cartilage in the chorioid of a man seventy-eight years of age, as a result of an injury which occurred thirty-eight years before.

[1] Arch. f. Augenheilk., October, 1903.

Bone Formation.—This takes place in many eyes that have been lost through inflammatory processes affecting the uveal tract. Bone is seldom present earlier than three years after the eye has become blind, and it requires many more years to reach a maximum development.

Etiology.—The development of bone apparently takes place in the tissue which results from the inflammatory process. The exudation involves the anterior layers of the chorioid, and this is the site of the commencement of bone formation. The formation begins most frequently at or near the posterior pole of the eye and develops into a plate of bone. The posterior surface is relatively smooth and regular and seldom reaches the outer surface of the chorioid. The inner surface is irregular and extends toward the vitreous chamber without invading the tissue of the retina. The plate of bone may be very small and thin. It may extend throughout the chorioid, and if there is a cyclitic membrane posterior to the lens, it may extend in this membrane and form a complete capsule having approximately the shape of the chorioid, being perforated posteriorly for the entrance of the optic nerve. The shell of bone may be very thin; it may attain a thickness of 9 mm.[1] Sometimes an irregular mass of bone only is formed, and at times only a spicula.

Histology.—The structure in ossification of the chorioid is that of true bone, except that the Haversian canals are not present.

Diagnosis.—It is often possible to determine the presence of bone in the shrunken globe by palpation. That portion of the globe lying over the bony shell will be firm and non-elastic, while the part away from the bone may present *minus* tension. In some cases the edge of the shell of bone can be quite definitely felt through the sclera.

Course.—Globes with ossification of the chorioid become sensitive and painful eventually, and may create sympathetic irritation in the fellow eye. They should be removed. Guaila[2] mentions one case of the enucleation of a degenerated globe on account of sympathetic ophthalmia in which a plate of bone was found in the chorioid.

Calcareous Deposits.—They are sometimes met with in degenerated globes and occur in circumscribed areas. They produce no disturbance and call for no special treatment.

Fig. 209

Excrescences of the chorioid. (Graefe's Archiv.)

Warty Excrescences.—In elderly individuals excrescences develop on the retinal surface of the lamina vitrea of the chorioid, which, under the microscope, are slightly lamellar, usually hyaline, but may contain lime salts. The excrescences are seldom more than 1 mm. in diameter and in height, and may be very much smaller. They may be few or

[1] Taravelli, Ann. d. Ottalm., xvii, No. 2, 139.

[2] Ann. d. Ottalm., xxiv, 1, 25.

numerous. When viewed with the ophthalmoscope they appear as pale spots in the fundus, having an average diameter of one-fifth of a millimeter. The tone of the fundus at the base of the pale object may be slightly deepened. The retina over the nodules may be slightly elevated. The excrescences are bilateral, but not necessarily symmetrical. They may occur in clusters or may be scattered over the fundus. They are most frequently seen near the posterior pole. Vision is seldom disturbed. When viewed with the microscope the appearance is much as in Fig. 209.

Tumors of Chorioid.—Multiple Pedunculated Polypoid Granulation Tumors.—These have been described by Ginsberg[1] and granulation tumors by Leber, Wedlbock, and others. In Ginsberg's case the appearance before removal was that of glioma.

Plexiform Neuroma.—A decided thickening of the chorioid due to increase in the connective-tissue elements and the presence of nerve fibers and oval bodies resembling nerve endings has been described by Collins.[2]

Angioma and Angiocavernoma.—Vascular tumors of the chorioid are extremely rare. They are congenital and tend to increase in size, resembling in this respect angiomata occurring in other parts of the body. They may be associated with angioma of the neighboring tissues. Miller[3] reports a case which he observed in a boy, aged fifteen years. The right eye was blind, the retina detached. The eye was enucleated and a simple angioma of the chorioid, 20 mm. in diameter, was found. There was angioma of the eyelids of the right eye.

Myoma.—A very few cases of myoma of the chorioid have been observed (Guiata).

Treatment.—Enucleation.

Sarcoma.—Classification.—The sarcomatous growths of the chorioid are classed by Coppez as follows: (1) Interfascicular endotheliomata, those which develop from the endothelial cells of the lymph-vessels. (2) Peritheliomata, those which arise from the perithelial cells of the blood-vessels. (3) Sarcomata proper, those which arise from the cells of the stroma of the chorioid and of the adventitia of the vessels. Alveolar sarcoma, which is rare in the chorioid but common in the tissues of the orbit, is undoubtedly largely formed of endothelial cells. As the varieties of tumor mentioned in this paragraph all spring from mesoblastic tissues, they should be considered as belonging to the same group.

Sarcoma of the chorioid may be primary or metastatic. Primary sarcoma is by far the most common neoplasm of the chorioid, constituting 85 per cent. of the growths occurring in the chorioid.[4]

Frequency and Age.—It occurs in advanced adult life. Of 134 cases mentioned by Marshall,[5] which included the cases reported by Lawford

[1] Centralbl. f. Augenheilk., xviii, p. 322.
[2] Trans. O. S., 1905, xxv.
[3] Rep. Ophth. Soc. Great Britain, p. 168.
[4] Noyes, Diseases of the Eye, p. 89.
[5] R. L. Ophth. Hosp. Reports, May, 1899, xv.

and Collins,[1] the youngest patient affected was aged fifteen years, the oldest between eighty and ninety years; the average age was about fifty years.

One eye only is affected. Of 422 cases in which the eye affected was stated by these authors, the growth occurred in the right eye 201 times, in the left 221 times.

The frequency of the occurrence of sarcoma in eye patients is stated by Fuchs[2] as 1 to 1560; by Hill-Griffith[3] as 1 to 3000.

Fig. 210

Sarcoma of the chorioid.

General Characteristics.—Primary sarcoma of the chorioid is always single. It may be nodular. It rises from a broad base and usually projects into the vitreous chamber in the shape of a knot-like process. It is sometimes constricted at its base, forming the "neck" of the tumor. In the early stages the free surface of the tumor is relatively smooth and is covered by retinal pigment and the lamina vitrea. When the lamina vitrea gives way over the apex of the neoplasm the growth projects through the opening and develops more rapidly, spreading out beyond the opening. The obstruction furnished by the margin of this opening in the lamina vitrea causes the constriction known as the "neck" of the tumor. The retina over the tumor becomes detached.

The tumor is devoid of pigment (*leukosarcoma*) or is of a lighter or darker brown (*melanosarcoma*), according to the amount of pigment that it contains. It is sometimes possible to make out a system of vessels peculiar

[1] R. L. Ophth. Hosp. Reports, December, 1891, xiii.
[2] Das Sarcom d. Uvealtractus, Wien, 1882.
[3] Norris and Oliver, viii, p. 365.

to the tumor in the superficial layers of the tumor. In the advanced cases the retina is frequently too opaque to permit a view of these vessels.

Etiology.—The history of sarcoma of the chorioid makes it highly probable that traumatism is the cause in a small number of the cases. Collins gives 6.79 per cent. with a definite history of injury, and Marshall 10.34 per cent. Some of the cases were undoubtedly coincident only. Schiem-Gemusens[1] reports a case of injury followed by chorioidal sarcoma four months later.

Place of Origin.—All investigators agree that the growth originates in the layer of large vessels. Extension takes place by invasion of adjacent tissues and metastasis by way of the blood-vessels.

Pathology.—*Structure.*—The body of the tumor is largely composed of round or spindle cells, or of both combined. In by far the greater number of cases the cells are more or less pigmented. Round cells are most frequently met with in younger individuals and in the tumors that grow most rapidly. The cells of the tumor apparently develop from the stroma cells of the chorioid. In tumors of rapid growth the cells retain the embryonic type more nearly; in those of slow growth the cells approach the mature condition, become fusiform, and in some cases stellate. It sometimes occurs that parts of the tumor, the parts that are developing more rapidly, contain cells of embryonic type in greater number than obtain in other less rapidly developing portions. The cells are arranged irregularly, their disposition depending on the relation of the different foci of most rapid multiplication to each other.

The form of the tumor, hemispherical or globular, indicates that the most rapid increase is from the vicinity of the centre of the tumor. In rare cases only does the tumor tend to spread more rapidly into the surrounding chorioid. In such cases the tumor becomes flat or disciform.

Pigmentation.—This differs very widely in degree. A very few chorioidal sarcomata are practically devoid of pigment (leukosarcoma). All grades of pigmentation are encountered, from the leukosarcoma to the intensely pigmented. Different parts of the same tumor may present different degrees of pigmentation. Part of the tumor sharply defined from the remaining part may be almost devoid of pigment presenting the peculiar impression of leuko- and pigmented sarcoma developing together. The pigment occurs in the form of minute cuboidal masses and is found in the protoplasm of the cells. Free pigment is not observed, except as a result of the breaking up of cells. Masses of pigmented cells (chromatophores) are sometimes encountered, in which the pigmentation is so dense that the individual cells cannot be distinguished. Decolorized sections disclose the true nature of the structure.

Vascular Changes.—The vessels of the chorioid are either crowded to the outer surface or are involved in the growth. The vessel walls

[1] Jahresbericht d. Augenheilk., Basel, 1884, 1885.

lose their normal structure, the cells apparently taking part in the development of the new tissue. Some semblance of a vessel wall remains in the old vessels, but new-formed vessels have no wall proper. They are vascular channels through the structure of the growth. In some cases blood-vessels and vascular channels are almost entirely absent.

SYMPTOMS.—*Clinical History.*—The development of all malignant growths of the interior of the eye may be divided into four stages.[1]

1. *Stage of Quiescence.*—During this stage the tumor develops without inducing inflammatory symptoms. The subjective symptoms during this stage are: gradual failure of vision, sometimes appreciable as a cloud or veil encroaching on the field of vision from the side corresponding to the growth, sometimes as a general diminution of vision. If the tumor begins at the macula the patient may first notice a central total positive scotoma, which gradually increases. Such was the case in a patient observed by the writer.

Objectively the tumor may be discovered in its very early stage, either by the difference in level between the apex of the tumor and the surrounding fundus, determined by examination with the direct method, by the appearance of a circumscribed nodular brownish mass seen through the transparent retina or by a circumscribed globular detachment of the retina, the retina being so opaque that the growth is obscured. In the latter case the presence of the growth can be surmised only. Oblique illumination with the pupil widely dilated may disclose the site of the growth, which may appear as a brownish mass covered by detached retina. The field of vision will show an absolute scotoma corresponding to the tumor area. There is seldom any local congestion of the ocular conjunctiva in this stage; the eye usually appears normal. The first stage may last a few months only, or it may last a few years. The tension of the eye during this period is normal or but slightly increased. As the growth increases the eye becomes blind, the detachment of the retina becomes complete, the subretinal exudation and retina becoming so opaque that nothing can be seen behind them; the lens may become cataractous.

2. *The Painful or Inflammatory Stage.*—The eye becomes painful. Ocular conjunctiva injected. Iritis may develop. Ordinarily the pain characteristic of this stage is due to acute inflammatory secondary glaucoma, presenting all of the symptoms of that condition—increased tension, shallow anterior chamber, dilated, immobile pupil, hazy cornea, etc. Not infrequently the injection of the episcleral vessels is most marked over the site of the tumor, but this is not always so. The pain may subside and again occur, but it is frequently more or less constant until the sclera has been perforated and involvement of the extra-ocular tissues has begun.

Iridocyclitis may develop and shrinking of the globe follow.[2] Sympathetic ophthalmia has been known to result from such a globe.[3]

[1] Knapp, Intra-ocular Tumors, p. 240, American edition.
[2] Jarnotowski, Arch. f. Augen., xxxviii, p. 382.
[3] Fuchs, Das Sarcom d. Uvealtractus, Wien, 1882, p. 253.

3. *Stage of Extra-ocular Involvement.*—In this the adjacent extra-ocular tissues are involved. The cells of the neoplasm find their way through the sclera and develop secondary masses on the external surface of the sclera or in the orbital tissues. The growth passes through the sclera, most frequently on the posterior part of the globe, often following the canals through which the posterior ciliary nerves and arteries gain entrance into the globe. The growth may extend backward along the nerve and may enter the cranial cavity by simple extension. The entire orbit may be filled and a mass bearing the globe on its apex may protrude from the orbit. Superficial and deep ulceration may occur.

4. *Stage of Metastasis.*—Secondary growths appearing in parts of the body remote from the eye. Metastasis occurs through the blood-vessels, and may take place at any time during the progress of the growth. It is more liable to occur when the tumor is growing rapidly and during the later stages of the growth, when extravasations of blood are common.

Diagnosis.—There are three conditions with which sarcoma of the chorioid may be confounded, namely, detachment of the retina, subretinal hemorrhage or exudation, and absolute glaucoma. If seen in the first half of the first stage the diagnosis can usually be made with comparative ease. The retina is separated from the tumor very early in its development, as a rule, but it and the subretinal fluid remain clear for some time and the outlines of the growth may be determined or the elevation as compared with the surrounding retina can be ascertained. Often before the second stage is entered upon the retina becomes totally detached, opaque, and the site of deposits of lime salts and the subretinal fluid opaque, so that absolutely nothing of a tumor can be seen. The history of the case, slow failure of vision, no variation in vision due to transient reattachments, no history of myopia or traumatism, the fact that the tension of the globe with tumor is seldom minus (increased in 66.66 per cent.; normal in 30.3 per cent.; decreased in 3.03 per cent., Marshall[1]); that with detachment of the retina it is almost always minus, will aid in making a diagnosis by exclusion.

Aspiration of the globe is of doubtful value, as the needle may enter the subretinal space and the withdrawal of fluid seem to confirm a diagnosis of simple detachment. If, fortunately, the needle enter the tumor, a small amount of blood and perhaps some tumor cells may be withdrawn and a positive diagnosis made, but the danger of metastasis may be increased.

Differential Diagnosis.—The differential diagnosis between sarcoma and subretinal hemorrhage cannot at times be made by the appearance alone, but the history of the case will be conclusive, the sudden onset of hemorrhage being in strong contrast to the slow development of tumor.

The erroneous diagnosis of absolute glaucoma has led to the performance of iridectomy and sclerotomy for the relief of pain in eyes affected with sarcoma. If the fellow eye were glaucomatous, a differential diagnosis in the early part of the second stage would be very

[1] R. L. Ophth. Hosp. Rep., May, 1889, vol. xv, p. 57.

difficult unless transillumination were employed. The affection of one eye only should lead the surgeon to suspect the presence of a neoplasm, and if any operation is advised, to advise enucleation rather than temporizing surgical procedures. The ophthalmoscopic examination should be made with intense illumination with widely dilated pupils. An electric ophthalmoscope or a large concave mirror with short focus will serve. The observer is thus enabled to see more deeply into the eye. The method of examination that is of greatest value when the growth cannot be seen with the ophthalmoscope, before the advent of the third stage, is transillumination of the globe by means of Leber's, Sachs', or Würdemann's electric lamps (see chapter on Examination). The variation in the luminosity of the pupil can be determined even if the lens is opaque (cataractous). A blood clot or a firm exudate may offer obstruction to the passage of light, but in almost all cases a differential diagnosis can be made by the history or conditions present.

Prognosis.—The prognosis is more favorable the earlier the eye is removed. The percentage of recurrence is given differently by different authors, ranging from 8.86 per cent.[1] to 32.9 per cent.[2] Inquiry regarding Collins' series made eight years later by Marshall[3] raised the percentage of recurrences in the traceable cases to 58.62 per cent. Local and general recurrences took place in one case eleven years and five months after operation. One-third of the recurrences are local and general, that is, affect the orbit; two-thirds are metastatic; the greater number occur within three years after operation.

Treatment.—Enucleation at the earliest possible period is imperative. If the tumor has extended into the orbital tissue, the entire contents of the orbit (exenteration), including the periosteum, should be removed; the more thorough the removal the greater are the chances for recovery. It should be remembered that infiltration of the optic nerve with sarcoma cells takes place in not a few cases early in the development of the growth; for this reason as much of the optic nerve as possible should be excised.

Metastatic Sarcoma.—The only well-authenticated cases of metastatic sarcoma of the chorioid are that reported by Meigs and de Schweinitz,[4] and that reported by Wiener.[5] In both cases the primary growth apparently began in the mediastinum. Numerous nodules were present in other parts of the body, especially in the brain. The chorioid of each eye was affected in both cases. De Schweinitz's case was described as round-cell sarcoma; Wiener's as round-cell with a few spindle cells.

Metastatic Carcinoma.—In a very small percentage of the cases of carcinoma occurring in various parts of the body, the growth is metastatic in the chorioid. The literature of the subject has been gone over very thoroughly by Oatman.[6] He has collected 30 cases, in 26 of which

[1] Würdemann, Diseases of Eye, Ear, Throat, and Nose, Wright and Posey, p. 383.
[2] Collins, Royal London Ophth. Hosp. Reports, December, 1891, vol. xiii, p. 111.
[3] Royal London Ophth. Hosp. Reports, vol. xv, p. 54.
[4] Amer. Jour. Med. Sciences, vol. xviii, No. 2, p. 193.
[5] Trans. Section on Ophth., Amer. Med. Assoc., 1902, p. 347.
[6] Amer. Jour. Med. Sciences, March, 1903.

microscopic examinations were made. One of the cases was observed by him. Carcinoma of the chorioid is always metastatic. The mesoblastic origin of the chorioid precludes the possiblity of primary carcinoma. Metastasis occurs most frequently in cases of carcinoma of the breast.

In 28 cases collected by Oatman, 20 were situated in the breast, 3 in the lungs, 2 in the liver, 1 in the stomach and liver, 1 in the thyroid, and 1 in a dermoid cyst of the suprarenal body.

Females are more frequently affected than males. The metastasis which takes place through the lymphatics may occur before the primary carcinoma is discovered (as happened in 5 of Oatman's cases and in 1

Fig. 211

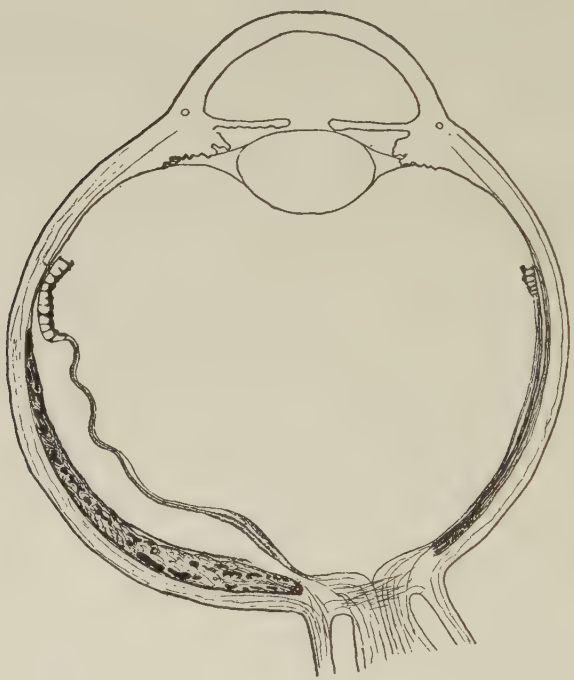

Metastatic carcinoma of chorioid. (Schapringer.)

observed by the writer), or at any time during the development of the primary growth. Both eyes were involved in about one-third of the reported cases. Vision fails rapidly, blindness coming on in from two to eight weeks. The average duration of life after the eye is invaded is given as six and a half months.

On account of the brevity of life the growth in the chorioid seldom attains large dimensions, and as a consequence the *tension* is but little affected. In the series of cases referred to the tension was increased in one-third of the cases, normal in all others but three, in which the tension was slightly minus. Pain is seldom severe, but it is very troublesome in some cases.

Pathology.—The growth develops in the chorioid at or near the posterior pole of the eye and spreads out usually with greater rapidity toward the temporal side. It forms a flat, disk-like mass, brown in color, over which the retina is detached. In color it resembles the surrounding chorioid. It may reach a thickness of 4 mm., but seldom exceeds 3 mm. The carcinomatous cells that invade the chorioid are of glandular epithelial type; they are arranged in irregular alveoli, of which the connective tissue trabeculæ may be very delicate or may be thick and dense. In the former the alveoli may be large and the cells arranged in single or double rows on the connective-tissue framework, presenting bead-like processes here and there, the centres of the alveoli being occupied by fluid. The arrangement causes the growth to present the appearance of adenoma, with which it has been confounded (Gayet). The term adenocarcinoma has been applied to this form. In the latter form the alveoli are filled with cells and the growth may be firm and dense. Transition forms of all degrees are met with. The retina and optic nerve may become secondarily involved, deposits of carcinoma cells appearing in them.

The vascular supply is small. The normal chorioidal vessels are crowded to the periphery and may present a congested condition at the margins of the growth. There is a scant accumulation of small cells in the tissues of the chorioid in the vicinity of the growth.

Diagnosis.—On account of the color and the discoid form of the growth, it is often difficult to determine its presence. The determination of the level of the different parts of the fundus by means of the ophthalmoscope is valuable in these cases. If the normal part of the fundus is emmetropic, it will be found that the centre of the growth is hypermetropic to the extent of 3 to 9 dioptres. This, accompanied by detachment of the retina and almost complete blindness, will aid in making the diagnosis.

Treatment.—This is of no avail. Should there be much pain not readily controlled by ordinary medicinal means, enucleation may be resorted to.

CHAPTER XIII.

UVEITIS

The term uveitis is employed to designate a low form of inflammation of the vascular tunic of the eye in which the various parts of this tunic, iris, ciliary body, and chorioid may be involved in varying degree during the progress of the affection.

The disease develops insidiously. It is characterized in the early stage by the appearance of minute opacities in the vitreous body, anterior and posterior chamber. The delicate, minute opacities in the vitreous body may unite to form large, cloud-like masses. The opacities in the aqueous chamber tend to become deposited in small masses on the posterior surface of the cornea, being arranged ordinarily in a pyramidal form, the base of the pyramid being at the lower part of the cornea (Fig. 212). The deposits consist of fibrin, small cells, and granular detritus. The deposition of these masses also takes place on the surface of the iris and lens capsule.

The vision is impaired in proportion to the density and number of the masses of exudate in the media of the eye. As a rule, there is slight congestion of the ocular conjunctiva in the early stage. This disappears in the later stage. Slight pain, usually of a dull character, may be experienced referable to the eye and corresponding side of the head.

Uveitis occurs rarely in children. It is most frequent in young adult life, but is not uncommon in individuals of advanced years. It is more frequently monocular than binocular, but its occurrence in both eyes is not uncommon. When one eye is affected there is no particular tendency for the other to become involved. When both eyes are affected the disease presents itself at approximately the same time in each, as a rule. While recurrences do take place in some cases, they are not common.

The affection differs greatly in degree of severity. In mild cases the exudate is of a serofibrinous type. The duration is relatively short (two to six months), and recovery takes place without great permanent impairment of vision. In severe cases the exudate is largely plastic in nature. The duration may be long (one-half to two years). Vision may be entirely lost; however, in the greater number of cases, some degree of vision is retained.

Etiology.—It is probable that uveitis is caused by the action of toxins on the vascular tunic of the eye, the toxins having their origin remote from the eye and circulating in the blood, or from microörganisms situated in the tissues of the eye. Uveitis accompanies rheumatism, gout, and diabetes in a very small percentage of the cases. The research

work of W. Stock[1] and others indicates that tuberculosis is the most frequent cause. Syphilis, gonorrhea, influenza, and the infectious fevers each contribute a number of cases. Quite a number of cases appear to be metastatic, due to local microbic activity, as ulcer or abscess in the pelvic region, nasopharynx, alveolar processes. Diseases and anomalies of the blood, as anemia, are apparently accountable for some of the cases.

Effects on Various Parts of the Eyeball.—**Cornea.**—Deposits on the posterior surface of the cornea are always present during a part of the duration of the affection, at least. The pyramidal form in punctate masses is most common. The masses vary much in size, sometimes being quite small, $\frac{1}{5}$ to $\frac{1}{4}$ mm. in diameter, sometimes large, $\frac{1}{2}$ to 1 mm., with small masses interspersed. In some cases the deposits are distributed over the entire posterior surface of the cornea without definite arrangement. Gray striations and grill-like figures may appear in the cornea. In a case observed by the writer the appearance was as indicated in Fig. 173. A scant small-cell interstitial infiltration of the cornea may develop. The cornea recovers its transparency, as a rule, but there are some cases in which permanent nebulous opacities remain and sclerosis of corneal tissue ensues.

Fig. 212

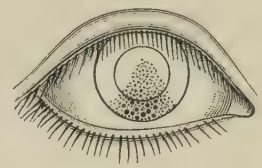

Deposits on Descemet's membrane. (Nettleship.)

Sclera.—The sclera may become thinned and ectatic at any point, but particularly in the ciliary zone and at the posterior pole about and near the optic nerve entrance. The staphylomata that form are preceded and accompanied by increased tension.

Crystalline Lens.—Cataract develops in many of the severe cases and in some of the mild cases, from impairment of nutrition due to the effect on the blood-vessels of the ciliary processes. Deposits of fibrin similar to those that are seen on the cornea may form on the anterior and also on the posterior surface of the lens. They may assume a brownish or pigmented appearance.

Iris.—In the mild cases permanent synechiæ seldom develop. In the severe cases permanent synechiæ are the rule. Complete *annular* synechia and in some cases complete *posterior* synechia develop. In these cases subsequent atrophy of the iris may and often does occur. Bombé iris may develop. The entire process may pass with almost no iritis. In some cases the iritis is very mild, in some, very severe. A number of exacerbations of iritis may occur during the progress of the disease.

Ciliary Body.—The ciliary body, particularly the vascular tissue of the ciliary processes, probably always participates. It is very probable that the flocculent exudate is derived from the ciliary process and the glandular zone of the ciliary body.

[1] Graefe's Arch., lxvi, 1, S, 1.

Chorioid.—Exudation into the chorioid, particularly in its anterior portion, takes place in probably all cases, demonstrating beyond a doubt that it is always affected. In some cases the involvement of the chorioid is much greater than in others. In the severe cases subsequent atrophy of the chorioid is extensive.

Retina and Optic Nerve.—These structures are apparently affected secondarily only. The exudation from the chorioid passes into the retina and interferes with the function of the retina. Involvement of the choriocapillaris interferes with the nutrition of the retina.

The fields of vision may be normal in extent or may be very defective, assuming various forms.

The affection of the optic nerve is a secondary atrophy. It occurs in the malignant type of uveitis.

Vitreous Body.—In mild cases the vitreous body does not suffer greatly. The minute masses of fibrin which are usually most numerous in the anterior portion of the vitreous may disappear entirely. In severe cases the masses may be large and dense. They may remain, greatly reduced in size, for many years. The nutrition of the vitreous body may be so impaired that it degenerates and shrinks.

Globe.—The tension of the eyeball is, as a rule, slightly below normal. In the greater number of the severe cases it is much below the normal. The globe may become extremely soft. The great reduction in tension usually occurs in the later stages of the disease and is accompanied by some shrinking of the globe. In a small percentage of the cases increase in tension develops. As a rule, the anterior chamber is shallow in such cases, but the tension may become increased even when the anterior chamber is deep. Both conditions are probably due to obstruction of the iris angle; the first because of encroachment of the iris; the second because of the presence of fibrin in the lymph-channels at the iris angle. The symptoms of increase of tension may cause much anxiety because of the pain induced and because of the deleterious effect on vision. The globe may become *much* shrunken in the later stages of the disease.

Treatment.—The cause should be determined, if possible. To this end a careful history should be taken, a careful physical examination should be made, when possible, and, in addition, the condition of the blood and of the urine should be determined. The data obtained will indicate the special features of the treatment.

Rest in bed during the early part of the attack should be enjoined. The nutrition of the patient should be kept at the highest possible point, the bowels free, and other functions normal. Sweats, either thermal or by means of pilocarpine, are often of value in the early stage of the affection. The eyes should be shaded by means of colored glasses or other appliances, if the light is bright or annoying. The treatment should be local and systemic. The local treatment should be directed principally to keeping the pupil dilated. Energetic mydriatics are usually required. Atropine is most generally useful, and should be faithfully employed unless there is an idiosyncrasy against it, when duboisin or other mydriatic may be substituted. In some cases it will

be impossible to maintain mydriasis, but the attempt should not be abandoned. If secondary glaucoma develops, pilocarpine or eserine should be employed. In persistent and in severe cases of secondary glaucoma, iridectomy must be resorted to. Subconjunctival injections of sodium chloride and sodium iodide have been recommended. If the eye is painful, hot applications or hot bathing, one-half hour at intervals of one or two hours, will usually give relief. Leeches, natural or artificial, may be applied to the temples to relieve pain, but they are seldom necessary. The systemic medication must be depended upon for the promotion of a cure. There are two principal plans: (*a*) The use of mercury with some potassium; (*b*) the use of the salicylates. These should be supplemented by the exhibition of iron if the hemoglobin is below normal.

The mercurial treatment has given good results in the hands of the writer. A very important point is that it *must be persisted in* until the eye has recovered from the inflammation, that is, from three months to one and a half years, or even longer. Introduction by inunction has given good results, but whatever the avenue of introduction, the patient should be kept at the point of "saturation" for at least the first four weeks of the attack. After this the amount may be slightly reduced. *Moderate* doses of potassium iodide may be given at the same time. If it is thought best to try the treatment by the salicylates, the salicylate of soda should be administered in dose of approximately one grain to the pound of body weight (Gifford) in the twenty-four hours. Combination with two-thirds the amount of bicarbonate of soda makes the salicylate less disturbing and more efficient. This treatment should be continued over a number of days until its influence over the inflammation can be determined. Tuberculin may be employed in tuberculous cases. If cataract develops it can be removed with fair prospects of improving vision in cases in which the projection is good, provided the removal is not attempted until all inflammatory conditions have passed. In some rare cases of shrunken, painful globe, enucleation must be resorted to.

CHAPTER XIV.

SYMPATHETIC OCULAR MANIFESTATIONS.

Disturbing symptoms or disease developing in a previously sound eye, due to irritation or disease in the fellow eye or its adnexa, are known as sympathetic manifestations. The eye which gives rise to the manifestation is termed the *exciting* eye, the eye secondarily involved, the *sympathizing* eye. Two forms of manifestations are recognized—(1) sympathetic irritation; (2) sympathetic inflammation.

Sympathetic Irritation.—This is characterized by a well-recognized train of symptoms, apparently due to irritation of the branches of the trigeminus and motor oculi nerves in the exciting eye, accompanied by irritation in the terminal branches of corresponding nerves in the sympathizing eye. The patient suffers from intermitting neuralgic pains in and about the eyeball and throughout the distribution of the first and second branches of the trigeminus. The pain is of a fleeting nature, may disappear entirely and reappear. Photophobia, photopsia, lessened visual acuity, narrowing of the visual field (fatigue field), inability to read and use the eyes for close work, lessened range of accommodation, blepharospasm, increased lachrymation, pain on pressure over the ciliary region, slight pericorneal injection, hyperemia of the optic disk, and spasm of the ciliary muscle are also symptoms some or all of which may be present.

It is held by some writers that sympathetic irritation never passes over into sympathetic inflammation. This is probably true except in the relatively few cases in which true sympathetic inflammation is preceded by prodromal symptoms of irritation for a few days or weeks.

Etiology.—Foreign bodies of the conjunctiva, cornea, globe, or orbit, ulcer of the conjunctiva or cornea, a corneal staphyloma, a luxated lens, irritation from a defective artificial eye, inflammation of the iris and ciliary body of the fellow eye; also all of the conditions that may produce sympathetic inflammation (page 391) are causes.

Diagnosis.—Sympathetic irritation due to causes other than those that may produce sympathetic inflammation is only of importance because of the distress to the patient and its value in directing attention to the exciting eye. When due to conditions of the exciting eye which it is thought may produce sympathetic inflammation, a differential diagnosis is of the greatest importance. The points of difference of greatest value are tabulated as follows:

PLATE XVIII

FIG. 1

Sympathetic Ophthalmia, early stage.

FIG. 2

Sympathetic Ophthalmia, later stage.

Sympathetic Irritation.	Sympathetic Inflammation.
1. Symptoms may develop a few minutes after the receipt of the injury.	1. Symptoms seldom develop earlier than a month after injury to the exciting eye; minimum reported length of time, two weeks.
2. The symptoms continue absolutely without evidence of inflammation (congestion or exudation), except a slight pericorneal flush.	2. The premonitory symptoms may resemble those of sympathetic irritation, but they are rapidly followed by objective evidences of inflammation.

Prognosis.—When the cause is removed the irritation ceases. If the cause is not removed the symptoms of irritation may continue indefinitely without damage to the eye.

Treatment.—It is evident that the cause of the irritation should be removed, if possible. If posterior synechiæ are the cause, an iridectomy may correct the difficulty. A sensitive stump after enucleation may require resection of the end of the optic nerve or the release of conjunctival adhesions.

Sympathetic Inflammation (*Migrating Ophthalmia*).—Sympathetic inflammation manifests itself in a number of forms.

Forms.—(1) Uveitis of various forms (iridocyclitis, sympathetic ophthalmia); (2) neuroretinitis; (3) optic neuritis followed by recovery or by atrophy; (4) miscellaneous sympathetic disturbances.

1. Uveitis.—The variety of uveitis produced differs greatly in degree of severity. It may be conveniently divided into two types according to the form of exudation: (*a*) serofibrinous, (*b*) plastic. There is no definite dividing line between the two. A feature of sympathetic uveitis that differs from the non-sympathetic form is the greater involvement of the iris and ciliary body. Aside from this the corresponding forms closely resemble each other (see Uveitis). The onset is insidious, often without premonitory symptoms of irritation. The iris becomes congested, cloudy, and less actively responsive to the various stimuli. Posterior synechiæ develop. The aqueous and the anterior portion of the vitreous body become slightly hazy. Deposits appear on Descemet's membrane. Pericorneal injection not very intense. Increased lachrymation. Slight ciliary tenderness. Diminution in vision. Not very much pain. Tension, at first possibly slightly increased, soon becoming normal or less than normal. The serofibrinous form may pass over into the plastic form or it may continue as it began. The mild or serofibrinous form continues for a few weeks or a number of months and terminates in recovery without, as a rule, greatly impairing vision. If the effect on the ciliary blood-vessels is sufficient to impair the nutrition of the crystalline lens, cataract may result.

Plastic Sympathetic Uveitis (Sympathetic Ophthalmia).—This is the more common and the severer form. Its onset may be the same as in the serofibrinous variety, or it may be more energetic. The symptoms are much more pronounced. The very first sign of the onset of either variety may be a slight papillitis or neuroretinitis. A slight ciliary injection affecting the area just below the cornea, early deposits on Descemet's membrane, muddy iris, fine flocculent masses in the aqueous

and occupying the pupillary space may also be early symptoms. Slight pain is common. Severe pain sometimes occurs, accompanied by more or less chemosis and swelling of the eyelids. The iris becomes greatly thickened and thrown into meridional folds. In the very early stage of the disease the iris may respond to atropine, but when it becomes thickened, atropine has little effect. The anterior chamber may be deep, but is often shallow. The tension at the onset may be increased; after some days or weeks it decreases; the eye may become very soft. In the early stage the fibrinous exudate may be so abundant that it drops to the bottom of the anterior chamber, forming hypopyon. The vitreous body, particularly the anterior portion, contains much of the fibrinous exudate.

As the disease progresses the iris becomes firmly attached to the capsule of the lens, either by narrow annular adhesions, in which case crater pupil (iris bombé) may form, or by complete posterior synechia; when the latter occurs the iris, as it resumes its normal thickness, conforms to the shape of the anterior surface of the crystalline lens, receding from the cornea at the iris angle; the pupil becomes densely blocked, the lens cataractous, and vision, in consequence, reduced to perception of light. This form of sympathetic uveitis runs its course, often but little influenced by treatment, in from three months to two years. In favorable cases a fair degree of vision is retained; in quite a large percentage of the cases vision is reduced to perception of light or is lost entirely.

2. Sympathetic Neuroretinitis.—This condition is, as previously stated, a forerunner of uveitis in a small percentage of cases. It may develop without involvement of other parts of the eye. It is not of a severe type, as a rule. The symptoms and appearance do not differ from those of the similar affection, not sympathetic. A very little exudate and a few small hemorrhages may occur. Some cases of reduction of vision have been reported (Schirmer), but, as a rule, vision is but little impaired during the attack and is restored to the normal on recovery. Rare cases of ultimate optic-nerve atrophy have been observed (Rosenmeyer).

3. Optic Neuritis.—Optic neuritis without other manifestations, followed by recovery (Galezwoski) in some cases, and by atrophy of the optic nerve (Mulder, Rosenmeyer) in others, has been observed. Sympathetic amblyopia has been described by Noel, which he attributes to optic neuritis located near the chiasm.

4. Miscellaneous Forms.—Other sympathetic disturbances that have been reported are keratitis, detachment of the retina, conjunctivitis, blanching of the eyebrows, disseminated chorioiditis (Eversbusch, Coppez). In all probability none but possibly the last was due to sympathy.

Frequency.—Sympathetic inflammation is fortunately rare. In 280,452 cases of eye affection recorded at the New York Eye and Ear Infirmary, sympathetic inflammation occurred five times; at the Ophthalmic and Aural Institute in 86,127 cases, sympathetic inflammation

occurred four times; Mooren reports 146 cases in 108,416 patients seen in private and hospital practice (0.134 per cent.); Ohlemann reported 556 severe injuries to the globe in which sympathetic inflammation followed in only two. Of 200 eyes enucleated because of supposed danger of sympathy, Fuchs[1] found that sympathetic inflammation had been produced in 29 cases only (14.5 per cent.). It is unquestionably a fact that sympathetic ophthalmia is decreasing in frequency because of the improved methods of treating wounds. Males are more frequently affected than females.

Time.—The development of sympathetic inflammation may occur any time after the second week following the injury. In the 35 cases reported by Fuchs[2] the shortest time was four weeks, the longest twenty years. The greater number of cases develop between the end of the third week and before the end of the fourth month after the establishment of the exciting cause. Sympathetic inflammation may follow after a much greater period of time has elapsed. Lee[3] reports a case occurring forty-seven years after the primary affection of the exciting eye. The writer reported a case which occurred forty-two years after the injury to the exciting eye. In all cases of delayed sympathetic inflammation the exciting eye will be found to have been inflamed or to have presented symptoms of irritation within three months of the onset of inflammation in the sympathizing eye.

Etiology.—Sympathetic inflammation is most frequently the result of infected, penetrating wounds of the eye, the infection being followed by a slow non-suppurative inflammation in the injured (exciting) eye. Wounds in and about the ciliary zone are most dangerous. Sympathetic inflammation has followed wounds by bullets, abscission of one-half of the globe, fragments of percussion caps entering the eye, splinter of brass in the retina, blasting injuries, after cataract extraction, after enucleation (two weeks, Mal, to forty-seven days, Shaw), after partial neurectomy, tattooing the cornea when anterior synechiæ were present, resection of the optic nerve, excision of staphyloma, wearing an artificial eye, after Mules' operation, following panophthalmitis, concussion of the eyeball, sarcoma of the chorioid, rupture of the sclera with escape of lens beneath the conjunctiva, perforating ulcer of cornea, bone formation in the chorioid of a degenerated eye.

It is believed by the greater number of observers that the inflammation is the result of bacterial infection, but the examination of exciting eyes has failed to thoroughly confirm this belief. Angelucci[4] examined bacteriologically 12 exciting eyes. Cocci and diplococci were found in two eyes. On inoculating the eyes of rabbits with these microörganisms, inflammatory changes similar to those observed in sympathetic ophthalmia were induced. Wagenmann[5] found microörganisms in two cases. Greeff examined 3 cases, but found no microörganisms. Deutschmann claims to have found microörganisms in 16 out of 17 cases.

[1] Graefe's Arch., Bd. lxi, Heft 2, S. 365.
[2] Ibid.
[3] Brit. Med. Jour., 1885, vol. ii, p. 397.
[4] Arch. d. ottal, iv, 1 to 3 and 3 to 4.
[5] Heidelberg Ophth. Soc., 1893.

Shaw examined 8 eyes, but no microörganisms were found. Poucet examined 6 eyeballs, but no microörganisms were found.

Rahlmann,[1] working with the ultramicroscope under a magnification of 2400 diameters, claims to have found the aqueous humor in a "dangerous" eye, removed three days after a perforating wound, swarming with motile bacteria of several types. It is his view that the smaller of these "are undeveloped forms which carry the infection through the tissue-channels to the sound eye."

Zur Nedden[2] implanted pieces of the tissue from eyes producing sympathetic ophthalmia into rabbits' eyes and injected blood from patients suffering from sympathetic inflammation into the vitreous body. Two of these experiments were positive. In one case Zur Nedden succeeded in isolating and cultivating a delicate bacillus from the vitreous body of the rabbit which he places in the pseudodiphtheria group. By injecting the bacilli into the eyes of other rabbits a chronic plastic inflammation, resembling sympathetic inflammation, was produced. The findings await confirmation.

Transmission of Sympathetic Ophthalmia.—In regard to the transmission of sympathetic ophthalmia, four principal theories are advanced:

1. *The old Theory of Mackenzie*[3] (*"Migration" Theory*).—He writes: "It is extremely probable that the retina of the injured eye is in a state of inflammation which is propagated along the corresponding optic nerve to the chiasm, and that thence the irritation which gives rise to inflammation is reflected to the retina of the opposite eye, along its optic nerve." This theory found supporters from time to time, notably Horner and Knies. The materies morbi was conjectural until Deutschmann[4] sought to supply it in the form of pathogenic and pyogenic microörganisms, which he injected into the globes of rabbits and, in some experiments, into the end of the optic nerve, near the apex of the orbit. An inflammatory condition of the fellow eye was established in some of the cases, and it was demonstrated that in some cases the microörganisms found their way along the optic nerve of the inoculated eye to the opposite nerve and thence to the opposite globe; however, the general infection of the animal developed rapidly and the animal died before a typical sympathetic inflammation was developed. Although the inoculation experiments were not wholly successful, Deutschmann concluded that the optic nerve and sheath are the tract of communication in the conveyance of sympathetic ophthalmia. Other investigators, notably Gifford,[5] attempted to confirm Deutschmann's experiments without success.

2. *Reflex Inflammation through the Medium of the Ciliary Nerves.*—This theory, advanced by Heinrich Müller, found strong supporters in Bowman, von Graefe, and others. Since the process in the exciting eye occurs largely in the ciliary body and anterior portion of the chorioid, it was thought logical to conclude that the ciliary nerves were always

[1] Deutsch. med. Woch., 1904, No. 13.
[2] Graefe's Arch., lxii, Heft 2.
[3] Diseases of the Eye, Philadelphia, 1855, p. 597.
[4] Arch. f. Ophth., xxviii, xxix, xxx.
[5] Arch. of Ophth., xv, 1886.

much irritated, and that this irritation affected the nutrition and secretion of the ciliary body of the fellow eye. Many observers have found disease of the ciliary nerves in the exciting eye. Many have found the ciliary nerves to be normal in some exciting eyes. These facts have been used in arguments for and against the ciliary-nerve theory, one class of observers arguing that disease of the ciliary nerves would prevent transmission of the sympathetic inflammation, the other that it would favor transmission. The theory of transmission by ciliary-nerve reflex, which implies vasomotor disturbances and changes in nutrition favoring endogenous infection and possible inflammatory changes from the effect of toxins in the blood, has not been substantiated by experimentation and is now practically abandoned.

3. *Theory of Metastasis.*—This theory is based on the supposition that the cause of sympathetic inflammation is a microörganism (Snellen, Berlin, Leber), or that it is cellular and that the transmission takes place as in metastatic sarcoma or carcinoma (Fuchs). Although it cannot be said that this theory is proved, the researches recently made go to show that it is the most plausible.

Berlin[1] contended "that a portion of the inflammatory products of the first diseased eye was taken into the general circulation." They do not develop pathological processes in parts of the body other than the eye because they do not find suitable conditions. However, when they pass into the ciliary body of the fellow eye they find suitable soil and there develop inflammation. The researches of Rugi,[2] Fuchs,[3] Römer,[4] and others favor the theory of metastasis.

4. *Toxin Theory.*—A theory of the production of sympathetic ophthalmia by means of toxins has been advanced. It has been supported by Gasparini[5] and by Bellarminoff and Selenkowski.[6] Gasparini maintains that the transference of microörganisms from one eye to the other is impossible; toxins only could pass in this manner. Bellarminoff and Selenkowski did much experimental work, using the toxin of Staphylococcus aureus in dogs and rabbits. The toxin was introduced (1) into the end of the cut optic nerve near the optic foramen; (2) into the subdural space of the optic nerve near the globe; (3) into the posterior portion of the vitreous. In 34 experiments of Class 2 and Class 3 they obtained sympathetic ophthalmia similar to that seen in man in 12.

Brown Pusey (1904) has suggested that certain cytotoxins may be produced in the exciting eye which pass by the blood-current or by lymph-channels and produce inflammatory changes in the fellow eye.

Golovine[7] some years later advanced a similar theory, and attempted to prove his opinion by experiments which he considered conclusive.

Pathology.—The changes observed in the exciting and in the sympathizing eye are identical, except those due to the injury itself. The condition is one of chronic nodular iridocyclochorioiditis. The changes

[1] Volkmann's Sammlung klin. Vortrage, 186.
[2] Graefe's Arch., lvii, 2, 401.
[3] Ibid., lxi, 2, 365.
[4] Arch. f. Augenheilk., 1906.
[5] Ann. d. ottal., xxx, 4, p. 285.
[6] Arch. f. Augenheilk., 1907, p. 696.
[7] Arch. d'opht., February, 1905.

consist in a small-cell infiltration about the blood-vessels of the deeper layers of the chorioid, of the blood-vessels of the ciliary body and iris, the chorioid being more involved than any other part of the vascular tunic. The small cells, which Fuchs (loc. cit.) describes as lymphocytes, are derived from the blood-vessels and collect in nodules. Epithelioid cells which, according to Fuchs, are derived from the pigmented stroma cells, appear in the nodules. Giant cells are found in the nodular masses surrounded by small cells. They appear to be derived from the endothelium of the adventitia of the arteries (Axenfeld, Uhr). They are often very large, the nuclei being arranged irregularly. Giant cells are found in the greater number of cases, but are not constant.

The nodular character of the cellular infiltration resembles tubercle, but the nodules differ from tubercle in that there are no tubercle bacilli, no caseation, and the arrangement of the giant cells is not the same. As the process advances, the small-cell infiltration becomes more diffuse. The infiltration is largely confined to the vascular tunic. Some small cells appear in the retina and optic nerve and may wander into the vitreous body. There is infiltration of the sheaths of the ciliary nerves, also of the sheaths of the blood-vessels as they pass through the sclera. A fibrinous albuminoid exudation may appear in the subchorioidal space, accompanying and possibly causing detachment of the chorioid. The walls of the blood-vessels may become sclerosed. The proliferation of the cells of the walls of some of the vessels may result in the conversion of the wall of the vessel into a mass of cells, bringing new-formed cells into contact with the blood-current. As the stage of proliferation passes, the epithelioid cells are apparently converted into connective-tissue cells, and a connective-tissue degeneration of the affected parts of the vascular tunic takes place. If the inflammation is reëstablished, as occurs not infrequently, the infiltration again takes place, restricted somewhat by the connective-tissue degeneration of the former process.

Results.—In Fuchs' 33 cases recovery took place in 3; blindness resulted in 9; vision was reduced to perception of light in 9; some degree of vision was retained in 12 cases.

Treatment.—This may be divided into (1) prophylactic and (2) direct.

Prophylactic.—The prophylactic treatment consists in (*a*) enucleation of eyes that may be thought capable of exciting sympathetic inflammation (these have been enumerated in the paragraph on Etiology); (*b*) in resection of the optic and posterior ciliary nerves; (*c*) in section of the optic and ciliary nerves (opticociliary neurectomy); (*d*) in the use of medicine. Of these measures, enucleation is by far the most commonly employed and the best.

Dianoux[1] endeavored to ascertain within what limits enucleation protects from sympathetic inflammation. He found a few cases reported in which sympathetic inflammation had developed four to twenty days after enucleation, one extreme case forty-seven days after enucleation.

[1] Annal. d'ocul., 1903, cxxix, p. 443.

Compared with the number of enucleations, the subsequent cases of sympathetic inflammation are infinitesimal in number. Wecker, Galezowski, Dor, Badal, de Lapersonne, Truc, and Valude, to whom a circular letter was addressed by Dianoux, and whose opportunities for observation have been very great, have never observed sympathetic inflammation follow the removal of an injured eye as a prophylactic measure.

Resection of the optic nerve and posterior ciliary nerve and section of the optic and ciliary nerves can be of little or no value if the transmission of sympathetic inflammation is by the blood-stream. Cases of sympathetic inflammation following these procedures have been reported (Rohmer, Trousseau, Marchal), and they have occurred in a much higher percentage than after enucleation. If resorted to at all, they should be used only in cases in which enucleation is refused.

Prophylactic treatment by means of remedies consists in the use of mercury in some form. If an eye that is thought capable of exciting sympathetic inflammation possesses the possibilities of useful vision (vision of $\frac{20}{70}$ or better), particularly if the fellow eye has defective vision, an attempt to prevent sympathetic inflammation by the use of drugs is permissible. Mercury by the stomach, by inunctions, hypodermically, or subconjunctivally, should be vigorously employed until all signs of inflammation have subsided, and if inflammation again occurs the mercury should be resumed.

Direct Treatment.—After sympathetic inflammation is established, the indication for treatment is first to prevent further infection, second, to combat the inflammation. The first may be accomplished by removing the exciting eye. If the exciting eye possesses the possibilities of useful vision, enucleation may not be advisable. In such a case, mercury is the principal remedy to be employed. Cases of recovery from sympathetic inflammation without enucleation of the exciting eye are reported by many observers. When the exciting eye is retained the possibility of the recurrence of sympathetic inflammation is always present. The second must be accomplished principally by medicinal treatment.

The medicinal treatment in established sympathetic inflammation must be local and systemic.

Local Treatment.—The pupil should be kept dilated if possible. It is often necessary to employ very energetic mydriatics. It is sometimes very difficult to maintain dilatation of the pupil, but the attempt should be persisted in. Atropine is the principal mydriatic. The crystals may be employed if solutions do not suffice.

Systemic Treatment.—The salicylates (salicylate of soda) in large dose, one grain to each pound of body weight in twenty-four hours, are advised by Gifford, the remedy to be continued for a number of days or a week, then in modified dose until the acute stage has subsided. Excellent results are reported. The writer has found the treatment with the salicylates to be very beneficial in some cases, but he has also obtained excellent results by the use of mercury and the iodides supplemented by pilocarpine sweats. The mercury should be employed

vigorously, the iodides in moderate dose. Both should be long continued. If increase in tension occurs, paracentesis of the cornea may be practised.

Operative.—Operative procedures involving the iris should never be undertaken until all signs of inflammation have long subsided; a year at least should have elapsed, except in the cases in which annular posterior synechia forms with retention of aqueous in the posterior chamber (bombé iris), or in cases of secondary glaucoma from other causes, when iridectomy for relief of tension may be resorted to. The tendency to the excitement of plastic formation continues for a long period of time.

In cases in which an iridectomy promises to improve vision in either eye, the piece of iris removed must be large, in order to provide against closure of the coloboma by subsequent plastic exudation. In cases in which cataract has developed in the sympathizing or exciting eye (when this is retained), the restoration of useful vision may be obtained in favorable cases if the operations necessary are performed at a favorable time.

CHAPTER XV.

GLAUCOMA.

GLAUCOMA[1] is a disease which produces as an essential condition the symptom of increased tension of the globe. Mackenzie, in 1830, was the first to point out the importance of this symptom, to study it systematically, and to take measures for its relief, namely, corneal and scleral puncture.

In a number of cases of increase of tension the change comes on without any antecedent condition which can be detected and which can be regarded as the cause. This form of glaucoma is known as *primary glaucoma.* In other cases the increase of tension follows injury or disease of the eye, the tension being a result of a previous pathological condition. This form is known as *secondary glaucoma.*

Common Characteristics.—Glaucoma, whether primary or secondary, presents certain characteristics which are largely common. These are (*a*) shallow anterior chamber (with some exceptions); (*b*) arterial pulsation (usually present at the beginning of an attack); (*c*) diminution in vision; (*d*) cupping of the optic disk (when increase of tension has existed from three to six weeks); (*e*) halos about a light (many exceptions).

Shallow Anterior Chamber.—This is due to the advancement of the lens and iris, consequent on increase in the volume of the contents of the vitreous chamber, and also, in many cases, to increase in the volume of the lens due to the age of the patient.

Arterial Pulsation.—Normally, the tension of the eyeball is sufficiently low to permit of an even flow of arterial blood into the eye under the influence of the arterial tension in systole and diastole. With increased tension of the eyeball, the volume of the blood-current in the arteries in diastole is retarded. The increase in blood-pressure in the arteries at the time of diastole overcomes the obstruction wholly or in part, and the flow is correspondingly increased. This variation in flow (the arterial pulse) can be observed with the ophthalmoscope. Pulsation is often observed in only one of the major branches of the artery; it seldom extends beyond the margin of the disk. If pulsation is not present in a glaucomatous eye it can readily be produced by pressure on the eyeball with the finger, the degree of pressure required being much less than that necessary to produce arterial pulsation in the normal eye.

[1] The term glaucoma was applied by Hippocrates to all opacities situated behind the pupil. After a time it was confined to those which presented a green appearance,

Venous Pulsation.—This is often present in the normal eye. It may be readily excited by pressure on the globe. It is observed in glaucoma, but cannot be relied upon as a diagnostic symptom.

Diminution in Vision.—This occurs in a number of ways in glaucoma: (*a*) By impairment of the function of the perceptive elements of the retina consequent on direct pressure and diminution in the nutrition to these elements, due to high tension rapidly brought about. (*b*) By obscuration occasioned by cloudiness of the cornea. (*c*) By death of the perceptive elements of the retina and atrophy of the nerve fibers due to impaired retinal circulation preceded by long-continued increase of tension, which may never be very high and may be intermittent. The first and second permit of recovery; the third does not. Diminution of vision of all degrees, resembling the first condition, can be readily produced experimentally by exerting pressure on the normal eye. If pressure sufficient to produce arterial pulsation is made, the outlines of objects lose their distinctness; if the pressure is increased, complete temporary blindness will be produced. This phenomenon is due to interference with the circulation in the retina. Restoration of tension to the normal, before death of part or all of the chain of cells that conduct the visual impulses takes place, will restore vision; if deferred, vision will be permanently lost. In the second form the vision improves greatly when the haziness of the cornea clears (see page 408). In the third form of diminution and loss of vision the drag on the nerve fibers at the margin of the disk may be of importance in interfering with the tract for the transmission of visual impulses. However, the interference with the circulation is the chief factor. Atrophy of the retina usually accompanies the development of the excavation. Decrease of vision does not bear a constant relation to the depth of the excavation.

Cupping of the Optic Disk.—After the increase in intra-ocular tension has existed three to six weeks, cupping of the optic disk begins to develop. This can be readily seen with the ophthalmoscope in eyes in which the media are clear. The *cupping* or *excavation* includes the entire disk and is accompanied by recession of the lamina cribrosa, which is the weakest part of the fibrous tunic of the eye. The depth of the excavation varies with the duration of the disease and with the degree of intra-ocular tension, but seldom exceeds 2 mm. The edges of the cup are abrupt, sometimes overhanging, the diameter of the lower part of the cup being greater than the diameter of the mouth of the cup. The retinal blood-vessels are crowded to the nasal side. They describe an abrupt curve as they pass the edge of the depression, sometimes disappear, again coming into view at the bottom of the cup, where they appear paler than at the margin. If the observer changes the position of his head while examining the optic disk with the ophthalmoscope, the phenomenon of parallactic displacement may be seen. The vessels at the margin of the disk appear to move more rapidly than those at the bottom of the excavation. This will be understood by consulting Fig. 108.[1]

[1] The problem is not so simple as represented above on account of the interposition of the refracting media of the eye examined. In the interest of clearness this has been ignored.

The phenomenon just referred to shows that the different parts of the vessels occupy different levels, but does not permit of the ready determination of the depth of the excavation. This point can be easily

Fig. 213

Ophthalmoscopic appearance of chronic glaucoma. (Jaeger).

determined by use of the direct method of ophthalmoscopy (see page 131), a variation of one dioptre in the refraction of the parts being approximately equivalent to a difference of $\frac{1}{3}$ mm. in the depth of the excavation.

Fig. 214

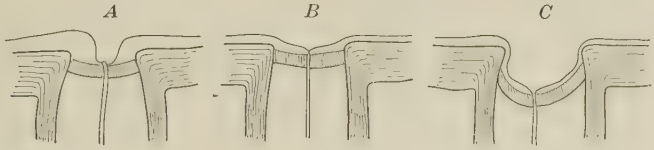

The three forms of cupping of the optic disk. Schematic. *A*. Physiological excavation, funnel-shaped, partial, lamina cribosa normal. *B*. Atrophic excavation, trough-shaped, total, lamina cribosa normal. *C*. Glaucomatous excavation, ampulla-shaped, total, lamina cribosa bulging behind. (After Fuchs.)

"Physiological cupping" never takes place in the entire disk, but sometimes includes one-half of the area of the disk. The vessels come up on the inner border, but do not bend so abruptly; the lamina cribrosa is not depressed. The capillaries in the tissue of the disk have not suffered, consequently the outer zone of the disk presents the normal pink appearance.

Cupping due to atrophy of the nerve fibers, disappearance of the greater number of capillaries and a diminution in the size of the larger vessels of the nerve and retina. The cupping is gradual and begins even beyond the border of the disk; it is shallow and is not accompanied by depression of the lamina cribrosa.

In this excavation the entire disk is included; the margins are abrupt; the mesh-work of the lamina cribrosa may be seen, the trabeculæ appearing as indefinite white bars, the spaces of a bluish tone. The excavated disk is pale in color, with a bluish tone. Capillaries have disappeared in large part.

Cupping of the optic disk (Figs. 214 and 215) occurs in other conditions than that of glaucoma, but the cupping with abrupt edges that includes the entire disk probably never occurs in any eye that has not been subject to increase of tension. There are three types of cupping of the optic disk: (1) The cupping that occurs in the normal eye—"physiological cup" (see page 135, description of the normal disk); (2) the cupping that accompanies atrophy of the optic nerve; (3) the cupping of the optic nerve or disk in glaucoma.

Fig. 215



Cupping of optic disk in a case of absolute glaucoma. (From a photograph by Geo. S. Dixon.)

Halos.—If the moon is looked at through a slightly misty atmosphere it will appear to be surrounded by a circle of light which indistinctly possesses the colors of the spectrum. The same phenomenon will be observed if one looks through a slightly steamed glass at a flame—street lamp, candle flame, etc. Defraction and refraction of rays of light by the minute particles of water in the atmosphere and on the glass are the cause. This phenomenon may be produced by an edematous (steamy) condition of the cornea and also, rarely, by haziness of the crystalline lens. In the early stage of glaucoma the cornea becomes slightly edematous, the surface takes on the appearance of a steamed glass, and the patient perceives halos about all lights. This is not true for all, but is true for many cases of glaucoma.

Primary Glaucoma.—This is a relatively common disease. Priestley Smith asserts that it forms 1 per cent. of all diseases of the eye. The statistics of Schussele[1] show it to be 0.73 per cent. of the cases of eye disease in the Tübingen clinic. Of 202,705 cases of eye disease treated at the New York Eye and Ear Infirmary in ten years, 611 (0.3 + per cent.) were cases of primary glaucoma. Primary glaucoma almost invariably affects both eyes, although one may be affected much in advance of the other.

Two forms of *primary glaucoma* are recognized—one accompanied by symptoms of congestion or inflammation, known as *inflammatory glaucoma*, and one in which symptoms of inflammation are almost, if not entirely, absent, known as *simple glaucoma.*

Primary Inflammatory Glaucoma.—This is a disease peculiar to advanced adult life. It presents various forms differing principally in degree of severity. In order of severity they are termed fulminating, acute, and subacute.

Acute Inflammatory Glaucoma.—This runs a uniform course and is typical. It may be divided into four stages: (1) Stage of prodromes; (2)

[1] Inaug. Dissert., Tübingen, 1899.

glaucoma evolutum (stage of acute attack, von Graefe), (3) absolute glaucoma; (4) glaucomatous degeneration.

Prodromal Stage.—The period of this stage differs much in length in different individuals. Temporary transient obscuration of vision is observed accompanied by slight neuralgic pain in the temple, more marked on the more affected side. (It is the exception to have both eyes affected with equal severity at the same time.) The neuralgic pain is often too slight to excite the notice of the patient, or the patient does not associate the pain in the head with the condition of the eye. At such times there is often an indefinite sensation of pain in the eye, a slight soreness or stiffness. Halos (luminous ring about a light) are seen. Inspection of the cornea will disclose a slight haziness, as though the surface were steamed. The haziness is diffuse, possibly being a little more dense in the centre of the cornea than elsewhere. The cornea is slightly anesthetic. The anterior chamber is shallow, the pupil slightly dilated, and the iris sluggish. The tension of the eye is increased, and there is often a little ciliary injection.

These are really mild attacks of acute glaucoma. They pass off in a few hours, permitting the eye to return to the normal state except, perhaps, that the accommodation remains slightly impaired. They increase in frequency and eventually lead up to a severe attack. Chromatopsia is sometimes complained of. The accommodation is interfered with, the distance of the near-point being abnormally increased. The inability to read with glasses that have before been satisfactory not infrequently induces the patient to consult the surgeon before there is any marked diminution in vision. Prodromal attacks occur in some patients on arising in the morning. Digestive disturbances, constipation, excessive use of the eyes, and excitement may bring on an attack. About 75 per cent. of cases of acute glaucoma are preceded by well-defined prodromata which may last a month or may last many years.

Glaucoma Evolutum (von Graefe) (Stage of Acute Attack, Glaucomatous Crisis or Explosion).—A typical attack of acute glaucoma is ushered in by severe headache, more intense on the side corresponding to the eye attacked; nausea with vomiting in many cases; rise of temperature; pain in the eye which is sometimes excruciating, sometimes masked by the headache; loss of consciousness in a small number of cases; edema of the eyelids and ocular conjunctiva with hyperemia of the latter, varying in degree; increased lachrymation; diffuse haziness of the cornea which presents the appearance of having been steamed; insensitiveness of the cornea; shallow anterior chamber; aqueous and vitreous humors sometimes slightly and uniformly hazy; pupil dilated, oval, with the long axis approximately vertical. The iris is pushed forward and may lie against the cornea. The iris is slightly discolored, sluggish or immovable. There is a greenish reflex from the pupil on examination by oblique illumination. If the fundus can be seen, which is often impossible because of the haziness of the cornea, the veins will be found to be overful, and the arteries, which may pulsate, perhaps a little reduced in size. Some edema of the disk is often present. Brailey

and Edmonds assert that actual neuritis usually precedes increased tension, but this statement is not substantiated by pathological examination. Small points of retinal hemorrhage may be observed. On palpation the eyeball will be found to be increased in tension, sometimes of stony hardness. The vision is sometimes greatly diminished, sometimes completely lost, in part due to haziness of the media—the cornea in particular. Subjective visual phenomena are noticed by the patient, flashes of light, falling balls of various colored lights, showers of bright sparks, etc.

The acute attack, if untreated, runs its course in a few days or weeks, seldom lasting more than three weeks. After the attack the vision may remain entirely abolished, or it may improve almost to the normal; the cornea becomes clear; the pupil contracts; the iris reacts sometimes sluggishly to the usual stimuli; the field of vision is reduced; the anterior chamber is shallow. The condition known as the glaucomatous state (*habitus glaucomatosus*) is established. Excavation of the optic disk is not present unless a long prodromal period has been passed.

After a period of comparative quiet a fresh attack occurs, usually more severe than the first. These are repeated until blindness results.

Absolute Glaucoma.—Von Graefe terms this "*glaucoma absolutum consummatum.*" Complete blindness from glaucoma may exist for some years before much evidence of degeneration is observed. The tension continues. There may be little or no pain, or it may be so severe in spite of medication that operative treatment may become necessary. Although the eye is devoid of vision, the patient often perceives a luminous haze which causes him to believe that he may again recover vision. The patient may declare that he can count fingers, but can never see any but his own. The illusion is due to the consciousness of how many fingers he holds up.

Glaucomatous Degeneration.—This stage ordinarily begins shortly after the condition of absolute glaucoma is reached. The eye now presents the following conditions: The sclera is bluish white; the anterior ciliary veins are dilated and tortuous, and seem to be increased in number; the cornea may be clear, but is insensitive; the anterior chamber is shallow; the iris is often reduced to a narrow band, grayish in color. The pupillary margin presents a narrow, pigmented ring—the everted uvea (ectropion uveæ). The iris at its root lies against the cornea, to which it may be firmly attached, obliterating the iris angle. A grayish-green reflex is obtainable from the pupil. The lens is forced forward and lies close to the cornea; it is frequently opaque, forming the so-called glaucomatous cataract. If a view of the fundus can be obtained, the characteristic glaucomatous excavation is found to be present; the blood-vessels are reduced in size, particularly the arteries; the retina and chorioid are undergoing degenerative changes; the tension of the eye is increased, sometimes to almost stony hardness. The eye may be painful or it may be painless; often the pain is very severe. If the eye is painful, there is more or less hyperemia of the ocular conjunctiva and the lids are slightly swollen.

With a continuation of the increase of tension, scleral ectasiæ develop. These are situated near the cornea in the anterior segment of the sclera or at the equator. General irregular enlargement may occur. Spontaneous rupture of the fibrous coat of the eye has been observed. If pain persists, operation must be resorted to in order to give relief. Atrophy of the globe with softening, ulcer of the cornea, iridocyclitis, panophthalmitis, and phthisis bulbi may occur in glaucomatous eyes in the stage of degeneration.

Inflammatory glaucoma occurs in all degrees of severity. Cases present certain clinical features which have caused writers to assign them to different classes.

Subacute Glaucoma.—A form of glaucoma, in which the attacks are much less severe than those just described, is known as subacute glaucoma. The attacks are similar to those that occur in the prodromal stage of acute glaucoma, but are more severe. At first the attacks may be infrequent—once in one to three months, lasting twelve hours to two days. The frequency of the attacks increases. In the intervals between the attacks there is no pain; the tension becomes normal or very nearly so; and the vision is restored to the normal. After a few attacks permanent evidence of the disease remains. The visual field for white and for colors is very slightly narrowed, particularly at the nasal side. The anterior chamber is not so deep as normal. The optic disk shows slight cupping, particularly in the temporal half, and is surrounded by a narrow, pale margin, known as the *glaucomatous ring*.

Chronic Inflammatory Glaucoma.—The preceding condition passes into that known as chronic inflammatory glaucoma. The ocular conjunctiva shows evidence of slight venous stasis; the anterior ciliary veins are enlarged and tortuous; the cornea is clear in many cases, but sometimes presents slight haziness. The iris is often adherent to the cornea at the iris angle; the pupil is dilated to some extent and often eccentric. The optic disk is pale and more or less excavated; the retinal veins are tortuous and overful; the arteries are smaller than normal. Pain varies in intensity. It may be quite severe, manifesting itself as cephalalgia, more pronounced on the side of the eye affected, or it may be dull and persistent in the eyeball. If treatment is not instituted, the vision gradually fails and the eye passes into the stage of absolute glaucoma, and thence slowly into the degenerative stage.

Glaucoma Fulminans.—Cases of glaucoma occur in which the vision is lost in twelve or twenty-four hours. The onset is very rapid and severe. Von Graefe has given the name *glaucoma fulminans* to this form. The cases fortunately are rare.

Simple Chronic Glaucoma.—This is an affection unaccompanied by inflammatory symptoms of moment, without pain, occurring in an eye that externally appears to be normal during the early stages, but in which the vision gradually fails. The patient consults the surgeon after the disease has existed for some time because he has experienced temporary obscurations of vision and has, perhaps, observed colored rings about a light, because he has difficulty in using the eyes for close work,

or because of failing vision. The tension of the eye is often normal, but there are certain times—after a hearty dinner, after undue excitement, after a fatiguing day, when the patient has remained up late at night, or during an attack of indigestion—when, if examined, the cornea will be very slightly hazy, the tension a little above the normal, the pupil a very little larger than in the other eye, and the iris less active. Often, repeated examinations—carefully comparing the affected eye with its fellow, or, if both eyes are affected, with a normal eye—will be necessary to positively determine the points above referred to. Ophthalmoscopic examination at an early stage will show the optic disk to be a little paler than normal, and there may be very slight excavation affecting its outer half. Arterial pulsation may be excited by slight pressure on the globe. The glaucomatous ring is present, but not in a very marked degree. Later in the development of simple glaucoma the cupping of

Fig. 216

Right

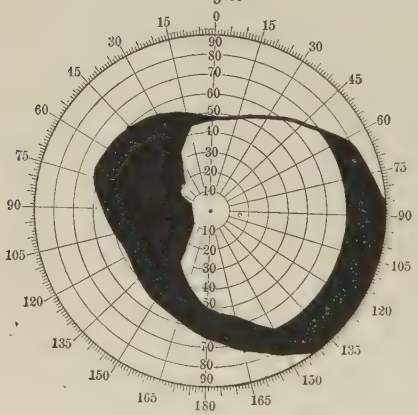

Field of vision from a case of advanced non-inflammatory glaucoma. Central vision normal. Operation declined.

Fig. 217

Right

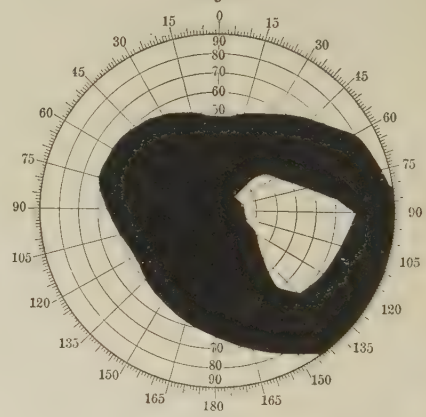

Field of vision from same case, four months later. Central vision lost.

the optic disk becomes very pronounced. The nerve head presents a very pale, bluish-white appearance. It sometimes occurs that a surprisingly high degree of vision exists, with deep, glaucomatous excavation and pale disk. The field of vision becomes much contracted, usually more marked on the nasal side; the contraction may be concentric; many different forms of visual field may be observed. The fields for colors diminish, frequently more rapidly than for white. If the field of vision is examined by *good illumination*, particularly in the early stage, but little diminution may be detected. If the examination be made by *subdued light*, a surprising defect may be found. As the disease advances, dilatation and tortuosity of the anterior ciliary veins become pronounced, and the sclera may assume a very slightly bluish tone. The disease lasts for years. It may go on to great diminution of vision without developing any marked inflammatory conditions—amaurosis

with glaucomatous excavation of the optic nerve (von Graefe). Or it may gradually pass over into subacute or even acute inflammatory glaucoma. Eyes that have become blind without inflammatory periods may pass into acute inflammatory glaucoma. Simple glaucoma appears in younger individuals than does inflammatory glaucoma. One eye may be affected some time in advance of its fellow, but ultimately both eyes are involved. Males and females are affected with about equal frequency.

Etiology.—Theories of Increase in Tension.—The theories regarding glaucoma have to do with the manner of the development of the increase in tension. The problem is a very complex one. All of the symptoms and pathological changes that occur subsequent to increase of tension are results. The increase of tension is undoubtedly the result of a loss of balance between the increase of the volume of the contents of the eye (inflow) and the escape of fluids from the eye (outflow). In those affected with primary glaucoma, the sclera appears to be more dense and less elastic than it is in those not so affected. With an increase in the density of the fibrous coat, the minute excretory channels, particularly the oblique channels which afford exit to the venæ vorticosæ, must of necessity be somewhat reduced in caliber.

As previously pointed out, the filtration angle (iris angle, sinus of the anterior chamber) is the most important avenue for the escape of the intra-ocular fluids. If the channels there present are encroached upon in any way the outflow is interfered with. Advancement or thickening of the root of the iris from whatever cause; advancement of the iris at its attachment, as after the use of a mydriatic or from inflammatory causes; advancement of the lens forcing the iris before it, due to increase in the volume of the contents of the vitreous chamber or from partial dislocation of the lens; dislocation of the lens into the anterior chamber; partial filling of Fontana's spaces and Schlemm's canal with plastic lymph; the partial obliteration of the spaces by inflammatory processes affecting the cornea and sclera—all of these conditions affect the outflow. Narrowing of the avenues for the escape of the fluid contents of the globe is undoubtedly part of the cause of primary glaucoma. It is apparently of importance in some cases of acute inflammatory glaucoma, in many cases of simple glaucoma, and in the greater number of cases of secondary glaucoma.

Von Graefe was of the opinion that increase of inflow was the principal factor in the production of increase of tension, and attributed it to a chorioiditis, assuming that the chorioiditis was of the serous variety. This, it was thought, would give rise to increased secretion without presenting gross lesions. Gross lesions of the chorioid are not necessarily present in acute glaucoma.

Donders, who considered glaucoma simplex as the primordial type of glaucoma, believed that increase of the fluids of the eye and consequent increase of tension were due to a neurosis, namely, that because of the irritation or excitation of the nerves that govern the intra-ocular secretion, an increase takes place, much as the increase of the secretion

of glands on excitation of the nerves governing them. These nerves Donders believed to be derived from the trigeminus.

Abadie is of the opinion that glaucoma arises from disease of the sympathetic nervous system; that irritation of that portion from which the vasomotor nerves of the eye are derived increases vascular tension and consequently increases intra-ocular secretion.

Priestley Smith[1] concludes that interference with the outflow, by the partial or complete blocking of the filtration angle, is the cause of the increase of tension. He has shown by measurements that eyes affected by glaucoma are, as a rule, smaller than those not so affected. The crystalline lens does not cease to grow when adult life is reached; it averages one-third larger at the age of sixty-five than at twenty-five. With this enlargement of the lens occurring in an abnormally small eye, the space between the lens and the ciliary body is much reduced, interfering with the free passage of lymph from the vitreous into the posterior chamber. Contraction of the ciliary muscle, which is more or less constant in hypermetropia, causes still further narrowing of this space. Increase of the contents of the vitreous chamber would cause the lens to advance, pushing the ciliary processes and the iris into the anterior chamber and blocking the filtration angle. This theory, based upon careful observations and experiments, explains much. It is well known that increase of tension (glaucoma) occurs very frequently in hypermetropic or small eyes. Glaucoma occurs at an age when the lens is large (88 per cent. were over forty years of age). It occurs in some cases of aniridia and in eyes from which the lens has been removed. In many of these cases obstruction of the filtration angle, to some degree, undoubtedly exists. Priestley Smith dwells almost entirely on diminished outflow because of obstruction at the filtration angle.

Stellwag believes that obstruction to the circulation by narrowing of the canals in the sclera for the passage of the venæ vorticosæ, which, he concludes, occurs with senile changes in the sclera, is a potent factor, the overfilling of the vessels compromising the capacity of the vitreous chamber, causing the lens and iris to advance into the anterior chamber.

The various theories condensed may be said to indicate that the vasomotor nervous system, the condition of the vessel walls, the change in the character of the aqueous humor (Troncosa) (see page 410), and the narrowing of the channels of outflow are collectively concerned in the production of increased tension. Any theory that does not recognize these factors cannot satisfactorily explain the phenomena. In an eye predisposed to increase of tension by congenital or acquired narrowness of the channels for the outflow of intra-ocular fluids, a disturbance in the circulation causing increased arterial pressure followed by venous stasis and subsequent slight serous exudation, or turgescence of the vessels of the chorioid and ciliary processes, increase in the volume of the contents of the vitreous chamber will result. The previously narrow channels of exit will become more completely choked, and the

[1] Glaucoma, London, 1891.

phenomena of a glaucomatous attack will be induced. The increase in volume of the contents of the globe is not always due to increase of secretion or transudation of serous fluid. Sudden distention of the vessels of the interior of the eye, as in venous stasis, hemorrhage from retina or chorioid, increase of volume by the presence of a neoplasm—all may serve.

Conditions Influencing Development.—1. *Age.*—Glaucoma is rare in the young. Not more than 1 per cent. of the cases occur before the twentieth year (Priestley Smith). Schlussele[1] reports only 12 per cent. under forty years of age in 494 cases. The greater number occur between the ages of forty and fifty-five years. Simple glaucoma occurs earlier than any other form.

2. *Race.*—Glaucoma is much more frequent in Hebrews than in other races (Knapp). Carra[2] observes that not only is glaucoma more prevalent in Hebrews, but that it also appears at an earlier age than in other races. The habit of intermarriage is probably in part responsible.

3. *Sex.*—Primary glaucoma affects the sexes about equally. Acute inflammatory glaucoma is more often met with in females, and comes on after the menopause. Simple glaucoma affects males more often than females.

4. *Heredity.*—Glaucoma occurs in the members of a family from generation to generation, appearing at an earlier age in succeeding generations (von Graefe). The type of the disease may vary in the different individuals in the family. Many of the cases of glaucoma afford a history of inherited tendency. It is observed in these cases that an increased rigidity of the fibrous coat of the eye, or, possibly, slight increase in tension exists early in life—the glaucoma not developing until late in life.

5. *Systemic Conditions.*—Arthritic rheumatism and gout. The latter, dependent on the uric-acid diathesis, may easily supply the excitant which, operating on the vasomotor nervous system, may initiate the glaucomatous attack. Both exert a deleterious influence on the walls of the blood-vessels. Atheromatous vessels, arteriosclerosis, aortic insufficiency—in cases of this nature the increased arterial tension accompanying exertion produces, in favorable cases, increase of intraocular tension, probably by temporarily increasing secretion into the eye.

Size of the Globe.—As Priestley Smith has shown, the globe in glaucoma is, on an average, smaller than in the non-glaucomatous eye. The diameter of the cornea, which averages 11.6 mm. in normal eyes, in glaucomatous eyes averages 11.1 mm. Microphthalmic eyes present a greater percentage of glaucoma than full-sized eyes.

Predisposing Causes.—In Schlussele's[3] 494 cases, 41.2 per cent. were reported as hyperopic, 43.4 per cent. emmetropic, and 15 per cent.

[1] Inaug. Dissert., Tübingen, 1899.
[2] Ann. di. Ottal., v, 1898.
[3] Inaug. Dissert., Tübingen, 1899.

myopic. The statistics of Zentmayer and Posey in 167 cases of glaucoma simplex give approximately 42 per cent. hyperopic and 10.8 per cent. myopic. It must be remembered that increased intra-ocular tension would tend to lengthen the radius of curvature of the cornea and change the refraction of the eye in the direction of hyperopia. The same influence may, and does in some cases, increase the length of the antero-posterior axis of the globe, changing the refraction in the direction of myopia. This has been observed by the writer in a number of cases. Small eyes are naturally hyperopic. In eyes predisposed to glaucoma, continued contraction of the ciliary muscle may determine an attack.

Exciting Causes.—Excitement of any kind, excessive use of the eyes, a hearty dinner, the use of mydriatics causing a thickening of the iris near its attachment, encroaching on the iris angle,[1] remaining up late at night and being exposed to artificial light, emotions of joy, grief, anger are exciting causes. Astigmia as an element in the production of eye strain may be an exciting cause. Increased arterial tension[2] has been observed to precede increase in intra-ocular tension.[3]

Pathology.—Lids and Conjunctiva.—The only change observed in these tissues is a reflex edema, excited, apparently, by pressure on the ciliary nerves, and, probably, irritation of the vasomotor fibers of the sympathetic.

Lachrymal Gland.—Hypersecretion due to reflex irritation.

Cornea.—During the exacerbations (attacks of glaucoma) the cornea presents a condition of edema. The surface of the cornea will be found to be uneven, minute elevations occurring over its entire surface. These are due to the transudation of fluid through the parenchyma of the cornea and Bowman's membrane, probably passing through the canals that permit the passage of the nerve twigs into the layer of epithelium, causing an elevation of surface cells. Knies[4] showed by injection experiments that fluids may pass from the anterior chamber to the epithelium through the parenchyma of the cornea. On microscopic examination the lymph spaces in the anterior lamellæ of the cornea were found to be distended and apparently filled with fluid. In the advanced stage the cornea becomes sclerosed, particularly at the periphery where the iris lies in contact with it. Minute, permanent cystic cavities are also found in the superficial layers of the corneal epithelium.

[1] Dr. Lippincott, American *Text-Book on Diseases of the Eye*, p. 376, mentions the case of a patient under his observation who could bring on an attack of glaucoma at will by "abruptly entering a dark or dimly lighted room."

[2] Bajardi, Report XV Italian Ophth. Cong., Turin, 1899.

[3] Sulzer (Ann. d'ocul., cxvii, p. 81) is of the opinion that the most frequent cause of a glaucomatous attack is a disturbance in balance between intra-ocular and arterial pressure, occurring in eyes already predisposed by rigidity of the sclera and narrowing of the channels of outlet. He terms these cases *circulatory* glaucoma, including in this class all of the cases of "inflammatory" glaucoma. In a second category he places the cases in which the disturbance depends upon a change in the walls of the vessels. Hemorrhagic glaucoma belongs to this class. A third category is termed "nervous glaucoma." To this class belongs simple glaucoma, which Sulzer believes is due to an affection of the vasomotor nervous system.

[4] Virch. Arch., lxii, p. 542.

Sclera.—The sclera is denser than normal. It is, in fact, in a sclerosed condition. The oblique openings—passages for the venæ vorticosæ—are said to be narrowed. The openings for the passage of the anterior ciliary vessels are enlarged in many cases, particularly in advanced cases. Minute herniæ at these openings are sometimes present. Dilatation and tortuosity of the anterior ciliary veins are due, apparently, to excessive flow of blood through them on account of the abnormally small amount carried off by the venæ vorticosæ. In the stage of degeneration, ectasiæ of the sclera occur most frequently near the equator of the globe. Spontaneous rupture may take place.

Fig. 218

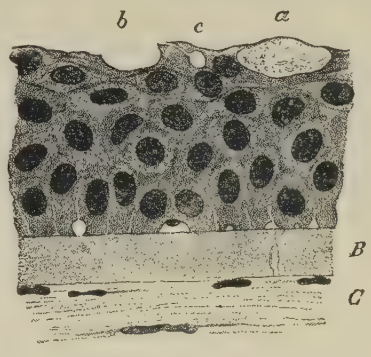

Corneal epithelium in a case of increase of tension: *C*, parenchyma of the cornea; *B*, Bowman's membrane, showing at two places minute nerve filaments passing through it. The light-colored rounded spaces at the anterior ends of these nerve filaments and at other spots, as between the bases of the lowermost cylindrical cells (foot cells), represent very minute droplets of liquid. The lines of division between the foot cells are in general represented by lighter colored lines, indicating that the cells are to a certain extent pressed apart by fluid and their interconnections broken up. Numerous cells in the uppermost layers are altered by imbibition of fluid. *a*, a cell in which the fluid occupies the greater part of the cell body. At *b*, the anterior wall of a cell that was filled with fluid has fallen off. At *c*, the liquefied contents of a cell have been evacuated through a slender opening. (Fuchs.)

Iris.—The primary changes that take place in the iris are indicative of paresis of the fibers of the motor oculi that supply the sphincter pupillæ, and stimulation of the fibers from the sympathetic producing vasomotor spasm. The long diameter of the pupil apparently lies in the direction of the terminal vessels of the two principal branches of each long ciliary artery which form the circulus iridis major, where the vasomotor spasm would have the greatest effect in lessening the blood supply. Venous congestion, to some degree, exists in the acute stage, as evidenced by the dusky hue of the iris, slight edema, and consequent blurring of detail. The haziness of the cornea and slight turbidity of the aqueous contribute greatly to the apparent change in the color of the iris. In the cases of simple glaucoma there is no evidence of edema of the iris. In acute attacks the iris may lie against the cornea and sclera at its periphery. The iris recedes on subsidence of the acute attack, reëstablishing the filtration angle. If the iris lies in contact with the sclera and cornea for some time, it becomes adherent (peripheral anterior synechia). As the disease progresses, the stroma of the iris atrophies and contracts. There is no evidence of small-cell infiltration or the formation of cicatricial tissue. Numerous slits may develop in the iris through which the fundus of the eye may be seen (polycoria). The pigment layer does not atrophy in proportion to the stroma of the iris; it is doubled upon itself at the pupillary margin, forming a black ring of greater or less width (ectropion uveæ). Where the iris tissue lies

in contact with the cornea, the stroma of the iris almost entirely disappears. In some cases, the iris becomes totally adherent to the cornea.

Aqueous Humor.—This becomes slightly turbid in acute attacks, containing more albumin (Troncoso) and coagulating more readily than the normal. The plastic principle contained in the aqueous is rarely sufficient to cause adhesion between the margin of the iris and the lens capsule (posterior synechia), but the colloid nature of the aqueous, according to Troncoso, lessens its diffusibility and prevents its free passage into the lymph channels.

Fig. 219

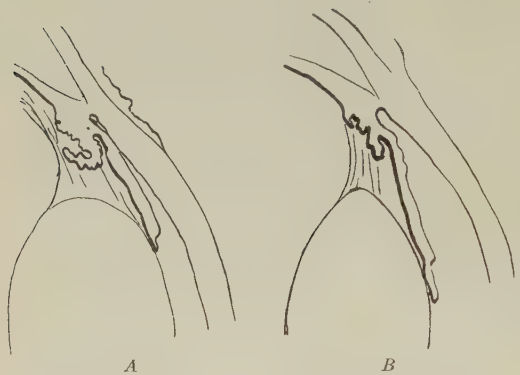

Closing of filtration angle. *A*. Glaucoma. *B*. Normal. (Birnbacher.)

Vitreous.—During the acute attack the vitreous may become slightly turbid by transudation of serum from the vessels of the ciliary body and the chorioid. In some chronic cases, in which absolute glaucoma is reached, the development of small blood-vessels in convoluted loops, springing from the vessels of the disk, has been observed.

Lens.—In the stage of degeneration the lens often becomes cataractous. Aside from this change the lens is little affected.

Ciliary Body and Chorioid.—In the periods of the acute attacks, the ciliary body, the ciliary processes in particular, and the chorioid are in a state of pronounced venous congestion. Excessive secretion takes place from the ciliary processes in particular, and it is probable that there is some transudation of serum from the vessels of the chorioid as well. Small-cell infiltration, the phenomenon of true inflammation, is not present, or, at most, is present in extremely slight degree. As the disease advances, atrophy of the ciliary body and chorioid develop, and when the stage of glaucomatous degeneration begins, the ciliary body is thin and flat, and the ciliary processes are much smaller than the normal. In hemorrhagic glaucoma, a sclerosis or a hyaline degeneration of the walls of the blood-vessels, with obliteration of the caliber of many, is found.

Optic Nerve and Retina.—In the acute form, the retina and optic nerve present the same phenomena peculiar to the vascular tunic, namely, that of venous stasis with the consequent edema. Frequently minute hemorrhages occur in the retina, particularly in violent acute attacks. Cupping of the disk slowly develops, causing more or less stretching of the nerve fibers over the edge of the cup. The gradual diminution of the field of vision is due in greater part to death of peripheral nervous elements of the retina, those parts of the field farthest removed from the

large arterial trunks suffering first. The arrangement of the arteries at the disk, passing out as they do from the nasal side, of necessity makes the vessels that pass to the temporal part of the retina longest and of less caliber. These vessels and their terminals are first to suffer marked diminution in size; death of the perceptive elements, supplied with nutrition by these vessels, follows. For this reason the nasal part of the field of vision is more often the first to disappear. In congestive (inflammatory) glaucoma, the typical field of vision shows most marked contraction on the nasal side. The disturbance of the nutrition of the retina accounts in greater part for the various forms of visual field met with in glaucoma.

Death of all of the perceptive elements of the retina eventually occurs. The loss of nutrition is apparently not the whole cause of blindness. Atrophy of the nerve fibers follows death of retinal neurons, but atrophy of some of the nerve fibers may be, and probably is, due to the pressure and traction exerted upon them at the margin of the disk. It is probable that too much importance has been given to this mode of interference with the nerve fibers. However, the change in the position of the lamina cribrosa must exert a deleterious effect, particularly on those fibers which pass through the peripheral meshes, the shape of which must necessarily be much distorted. In glaucoma simplex, which is largely devoid of marked congestive periods (acute attacks), a surprisingly high degree of acuity of vision may exist with a deep excavation and pale nerve.

Glaucomatous Ring.—The development of the pale circle which surrounds the disk, particularly in glaucomatous eyes, is due to a very slight recession of the pigment layer of the retina and of the margin of the chorioid at this point with some atrophy, apparently consequent on beginning retraction of the lamina cribrosa and slightly increased pressure of the nerve-fiber layer on the underlying tissues at the margin of the disk. This permits the sclera to show through a very little at this part. In some eyes in which there is a beginning sclerochorioiditis posterior, the condition is very similar to that presented by the glaucomatous ring.

Field of Vision.—The two pathological processes that operate to destroy the function of the retina suffice to produce scotomata in the field of vision of varying shapes. The typical glaucomatous field in the acute cases shows a defect most pronounced to the nasal side. As has been shown by Bjerrum, the blind spot corresponding with the optic disk is enlarged in glaucoma, a relative scotoma often connecting it with the blind nasal portion of the field either above or below the horizontal meridian (Straub). The field in simple glaucoma is apt to approach concentric limitation, namely, more like the field in simple atrophy. This is consistent with the fact that simple glaucoma in many cases possesses the characteristics of glaucoma plus atrophy of the optic nerve.

The Color Fields.—The fields for form and for colors do not bear any constant relation to each other. The field for form may be much reduced, while those for colors may show only moderate changes. The reverse may be true. The color fields may be greatly contracted. Great

reduction in color fields is regarded as characteristic of those cases in which the prognosis is unfavorable.[1]

Diagnosis.—The diagnosis of acute glaucoma is not always a simple matter: (1) It may be mistaken for iritis—in fact, plastic iritis sometimes presents increase of tension with swelling of the lids and injection of the ocular conjunctiva and chemosis. In such cases the previous history must be carefully inquired into, and this, in connection with the condition of the pupil, should suffice. In iritis the pupil will be small unless atropine has been instilled. If atropine has been used, evidence of posterior synechia will be present almost without exception. In the rare cases, where atropine has been used with moderate dilatation of the iris and increased tension, the internal remedies employed for iritis should be given and pilocarpine substituted for atropine until the true nature of the case can be decided. In iritis the tension never goes above +2, seldom above +1.

2. The condition of the eye may be overlooked, the severe cephalalgia and the nausea being mistaken for some affection of the brain or for an acute attack of indigestion. Examination of the eye will disclose the glaucomatous condition. When the acute stage has sufficiently subsided to permit of an examination of the interior of the eye or of the visual fields, the diagnosis may be made with certainty, but it is hazardous to permit so much time to elapse. In *simple* glaucoma, it is often difficult to decide whether the case should be termed glaucoma or atrophy of the optic nerve. Careful study of the field of vision and of the tension of the eye from day to day, and at different times of the day, will, in almost all cases, suffice to make the diagnosis. The history, if carefully inquired into, will be of great value.

Treatment.—The object of all treatment is to reduce the tension of the eyeball to the normal, if possible, and to maintain it in that condition. Treatment is medicinal and surgical.

Medicinal Treatment.—This in many cases, although palliative only, is often of great service; not only does it serve to prevent immediate great damage to vision, but it enables the surgeon to control the disease so that the condition will be favorable if operation becomes necessary. Systemic and local medication are indicated. Systemic medication should be directed to the correction of any disorder of the system that may exist. Saline laxatives should be employed to correct any tendency to constipation. The bowels should be kept freely open. In some cases the administration of miotics internally, as a supplement to the local use of miotics, appears to be of service. The fluidextract of jaborandi may be given in one-fourth to one dram dose in a suitable menstruum three times daily, or one-eighth to one-half of a grain of pilocarpine hydrochlorate may be given. This medication may be continued indefinitely if the patient is not disturbed by the drug.

Locally, the miotics are of the greatest value. Those that are of service are pilocarpine and eserine. Pilocarpine may be used in the strength of

[1] Gruening, Trans. Am. Opth. Soc., 1902.

1 or 2 per cent., one or two drops being instilled two or three or more times daily, as required. In prodromal glaucoma and in the early stages of simple glaucoma, also in intervals between acute attacks, pilocarpine is of service. Pilocarpine does not affect the sphincter pupillæ and ciliary muscle as powerfully as does eserine. The tonic spasm of these muscles is less violent than when eserine is used, and consequently occasions less disturbance to the patient. (See physiological effect of pilocarpine and eserine, page 125, chapter on Examination of the Eye.)

In acute glaucoma eserine must be employed in order to produce miosis. The strength of the solution should vary with the susceptibility of the patient. One-fourth or one-half of 1 per cent. is sufficient in some cases, and 1 per cent. is necessary in others. The installation is to be made sufficiently often to maintain miosis; in an acute attack, every three hours; as the congestion of the eye subsides, once in twenty-four or forty-eight hours is sufficient. Cocaine combined with pilocarpine or eserine is of value on account of its stimulating effect on the vasomotor fibers. It adds to the efficiency of both if combined in the strength of a 1 per cent. solution. In the use of eserine with cocaine, the danger of exudation from the ciliary processes and iris is less than when eserine is used alone and the distressing symptoms due to its use are minimized. Dionin (10 per cent. sol.) combined with pilocarpine or eserine, or both, is thought of very highly by some ophthalmic surgeons. All solutions should be sterile when used. Pilocarpine keeps better than eserine. The latter is of a pale color when prepared, gradually changing to pink. If sterile, the effect of eserine on the iris, after it has assumed the pink color, is almost as energetic as when first prepared. The effect gradually diminishes.

It has been found that some cases of glaucoma can be held in abeyance for a very long period of time by a proper use of miotics. This is notably so in cases of subacute and simple chronic glaucoma. Since the results of operative treatment are not always satisfactory, especially in cases of simple chronic glaucoma, it is better to give miotics a thorough trial and resort to operative procedure only when miotics fail. The choice of the remedy to be used in a given case must depend on the efficiency of the remedy in maintaining the desired reduction in tension. A patient under treatment with miotics should be seen by the surgeon at frequent intervals. He should be informed that an acute attack of glaucoma might develop, and cautioned to go to the surgeon without delay should failure of vision, with or without pain, occur. Many cases of chronic glaucoma may be controlled for years by local treatment with miotics and regulation of the system. In cases in which diminution in the size of the visual field advances in spite of the use of miotics, operation should be resorted to, except in the very aged, in whom, if the failure of vision is very gradual, unless the patient is very vigorous, the use of miotics should be continued, as the prospect of the retention of some vision so long as the patient lives is good and the patient would not be subjected to the annoyance and uncertainty of operation. Statistics, as collected by

Zentmayer and Posey,[1] make a very favorable showing for the treatment by miotics.

Operative Treatment.—The principal operative procedures resorted to in glaucoma are (1) iridectomy; (2) sclerotomy, anterior or posterior; (3) paracentesis of the sclera with ciliotomy (Hancock's method); (4) division of the tissues at the iris angle; (5) partial detachment of the ciliary body (cyclodialysis, Heine); (6) resection of the superior ganglion of the cervical sympathetic (sympathectomy).

Iridectomy.—This operation is by far the most valuable that has been devised for the treatment of glaucoma. Humanity owes its discovery to the genius of von Graefe, who, having observed the favorable effect of iridectomy in reducing tension, employed it in 1856 for the cure of glaucoma.

The iridectomy should be made upward, so that the upper lid will cover the peripheral portion of the coloboma. If for any reason it is not possible to make the iridectomy upward satisfactorily, it may be made wherever advisable.

In acute glaucoma, general anesthesia is advisable in the greater number of cases, as the congested and edematous tissues do not readily absorb remedies. Local anesthesia is usually sufficient in chronic glaucoma. In employing local anesthesia, a 4 per cent. cocaine solution should be instilled first. At the end of five minutes, cocaine solution instillation should be followed by a drop of a solution of adrenalin. Two or three instillations of cocaine should now be made within the next ten minutes, when the operation can be commenced. Just after the incision is completed a few drops of a solution of holocaine may be dropped into the wound. Ordinarily, the anesthesia produced by this procedure will be sufficient to abolish all pain. The injection of a few drops of a 2 per cent. solution of cocaine immediately beneath the ocular conjunctiva near the margin of the cornea away from the site of the operation, three to five minutes before beginning the operation, as advised by Koller, is of value in producing the desired anesthesia. The edema induced by the injection is sometimes obstructive.

Recognizing the fact that with the firm closure of the wound in the sclera after iridectomy for glaucoma a return of tension is not uncommon, a number of modifications of the operation of iridectomy have been devised for the purpose of establishing a permanent filtration cicatrix.

Accidents and Complications that May Follow Iridectomy. —*Recovery after Operation.*—The healing process often progresses extremely slowly. If the volume of the contents of the vitreous chamber is too great, the lens is pushed forward, the wound gapes and must heal by the deposition of new-formed tissue. This may occur even when the wound is closed over by a conjunctival flap. Incarceration or prolapse of iris may occur. A tag of iris may lie in the wound; filtration of aqueous may take place and continue for many weeks. Reëstablish-

[1] Wills Eye Hospital Reports, January, 1895.

ment of the anterior chamber is often slow. When the cicatricial tissue is new, if the intra-ocular tension is considerable, it is apt to bulge, being forced up by the aqueous, forming a translucent vesicle, the so-called *cystoid cicatrix*. The aqueous may escape beneath the conjunctiva, producing edema of the tissue, or it may be retained by the distended cicatrix. Eyes with cystoid cicatrix are constantly in danger of infection by rupture of the cyst and the entrance of pyogenic germs. In some cases the anterior chamber does not refill, and vision sinks. In these cases the volume of the contents of the vitreous chamber is too great—the lens is crowded forward against the iris. Weber managed this condition by doing posterior sclerotomy and, while permitting some vitreous to escape, gently pushing the lens backward by pressure on the cornea through the partly closed upper eyelid.

Lens.—The lens may be wounded by the instruments, when cataract will ensue. The pressure from the vitreous chamber associated, possibly, in some cases, with a weak suspensory ligament will cause the lens to become partly dislocated and to move up toward, or slightly into the wound, on completion of the section or of the iridectomy. It may heal in the wound, becoming cataractous subsequently. The lens has been known to escape from the wound on completion of the iridectomy. When incipient cataract exists the operation hastens the development of cataract.

Tension.—The tension is sometimes but little affected by the operation or returns shortly after closure of the wound. In these cases, a second iridectomy or a sclerotomy should be performed.

Intra-ocular hemorrhage occurs rarely, either following the incision immediately or some hours afterward. The too sudden escape of aqueous may precipitate a hemorrhage. The result is destruction of the eye.

The operation sometimes excites an attack of acute glaucoma in the fellow eye. When this occurs, iridectomy must be performed on the fellow eye.

Noyes[1] advises the use of atropine (1 per cent.) twenty-four hours after the operation, to prevent the development of posterior synechiæ, the atropine to be continued for several days. Atropine may be employed when needed, but it is not required in many cases, and may be injurious.

The way in which iridectomy does good is, perhaps, not fully understood. It has been inferred by some that the secreting surface has been diminished, under the supposition that the iris, as well as the ciliary processes, is concerned in the secretion of fluids into the interior of the eye. A mysterious beneficial influence on the nerves governing secretion has been attributed to the operation. The mechanical freeing of the filtration angle, by removal of a portion of the iris to its ciliary insertion and by traction on the iris during the operation, is thought to account for the beneficial result. The latter theory seems to be the most plausible.

[1] Diseases of the Eye, 2d ed., p. 569.

Time of Operation.—The urgency of operation depends not so much on the tension as on the condition of the vision. If the sight is much impaired and the vision sinking rapidly, iridectomy should not be delayed. In fulminating glaucoma an effort should be made to control the attack by the local use of eserine, inducing rather free catharsis and stimulating the action of the skin by hot baths or the hypodermic injection of pilocarpine. If the attack can be controlled, the operation may be delayed until the edema and chemosis have subsided, provided the vision is not failing. In acute and subacute glaucoma and in simple glaucoma, a time convenient to the patient and surgeon can be chosen. The operation should be performed as early in the disease as possible, before structural changes have taken place in the eye.

Prognosis.—If not treated, glaucoma results in blindness. In *fulminating glaucoma,* if iridectomy is performed before vision is lost, we may expect considerable gain in vision and an effect that is ordinarily permanent. Even if blindness has existed some hours or days some degree of vision may be regained in some cases.

The prognosis in *acute glaucoma* depends largely on the time of the performance of the iridectomy, not particularly in regard to the recent attack, but in regard to the anatomical changes that have taken place. If performed early, the prognosis for arrest of the disease with preservation of vision is good—better, in fact, than in any other form of glaucoma. Iridectomy in acute glaucoma is followed by hemorrhage from the iris and frequently from the retina in small degree. This ceases shortly and the blood becomes absorbed without injury unless a retinal hemorrhage involves the macula. The congested condition of the tissues and the defective vessel walls make hemorrhage possible on lessening of the intra-ocular tension.

In *subacute glaucoma,* if iridectomy is *performed early,* the prognosis is favorable. If operation is deferred the immediate result may be gratifying, but increase in tension is apt to again occur and the vision to gradually fail.

In *simple glaucoma* iridectomy is of value *if performed early,* more particularly so in the cases in which periodical exacerbations occur. In about 50 per cent. of the cases the disease progresses after iridectomy. The tension may remain reduced, but the atrophy of the optic nerve continues. In cases where the field of vision is small and its confines approach the macula, according to many writers the blind portion may pass beyond the point of fixation and central vision be lost on the performance of iridectomy. The writer has not had this occur in his practice.

In all forms of glaucoma, if relapses occur, a second and even a third iridectomy may be made. Arrest of the disease has been observed after two-thirds of the iris has been removed. Von Graefe estimated that, as a result of iridectomy, glaucoma was arrested in 50 per cent. of the cases; in 2 per cent. the vision was made worse; in the other 48 per cent. atrophy of the optic nerve progressed.

Sulzer[1] reports as follows: Acute glaucoma, 149 cases; improved, 72.5 per cent.; serviceable vision preserved, 11.3 per cent.; vision impaired at once, 4.08 per cent.; very little vision, 12.12 per cent.

Zentmayer and Posey:[2] In simple glaucoma central vision increased in 60 per cent.; remained the same in 20 per cent.; diminished in 20 per cent.

Wygodski:[3] Inflammatory glaucoma, 37 cases; improvement, 76 per cent.; unimproved, 5 per cent.; deterioration, 19 per cent. Subacute (chronic inflammatory), 147 cases; improvement, 10 per cent.; unimproved (condition the same as before iridectomy), 40 per cent.; deterioration, 30 per cent.; blindness, 20 per cent. Cases operated on at an early stage gave 85 per cent. of good results. Simple glaucoma, 104 cases; improvement, 0.96 per cent.; condition as before, 10.5 per cent.; deterioration, 52 per cent.; amaurosis, 36.5 per cent.

Hahnloser and Sidler:[4] 172 eyes observed not less than ten years after operation; acute inflammatory, 31 eyes; good results, 64 per cent.; relatively good, 13 per cent.; blind, 23 per cent.; chronic inflammatory, 37 eyes; good result, 29.9 per cent.; relatively good, 27 per cent.; blind, 43 per cent.; simple glaucoma, 76 eyes; good results, 42 per cent.; relatively good, 28.9 per cent.; blind, 28.9 per cent.

Anterior Sclerotomy.—See chapter on Operations.

Posterior Sclerotomy.—If the vitreous chamber is opened and a quantity of vitreous is permitted to escape, the lens recedes, the anterior chamber deepens, and the filtration angle—if the iris is not adherent to the cornea—is reëstablished and tension reduced. Because of this, Priestley Smith, Gifford, and others have advocated posterior sclerotomy as a preliminary to iridectomy in certain advanced cases of glaucoma in which the anterior chamber is very shallow. The sclerotomy should not be large and should be performed some days before the iridectomy. In some cases in which vision is much impaired the operation is advantageous, not only for the facility afforded for making an iridectomy, but for the benefit derived by lessening the contents of the vitreous chamber. Posterior sclerotomy in seeing eyes is not permissible except in the cases mentioned. In absolute glaucoma with painful globe, lasting relief from pain may be obtained by means of a large posterior sclerotomy. The writer has performed the operation in cases of absolute glaucoma a number of times, with excellent results.

Paracentesis.—Puncture of the anterior chamber is resorted to for temporary relief of tension.

Sclerociliotomy.—This operation, advocated by Hancock, is employed but by few. It certainly relieves tension temporarily, and, according to Pollock,[5] is curative in a large percentage of cases. The writer has had no experience with this operation; he would advise caution in performing section of the ciliary body.

[1] Zürich, 1882, Operations in Horner's Clinic.
[2] Wills Eye Hospital Reports, January 1, 1895.
[3] Klin. Monatsbl. f. Aug., September 25, 1903.
[4] O. Haab, "Das Glaucom und Seine Behandlung," 1902, p. 50.
[5] Amer. Jour. of Ophth., March, 1899.

Stretching of Supratrochlear Nerve.—This has been resorted to by Brailey[1] for the relief of pain in absolute glaucoma.

Laceration of the Infratrochlear Nerve.[2]—This operation has been advocated for the relief of pain in glaucoma.

Optic Ciliary Neurotomy (see Sympathetic Ophthalmia).—This is resorted to in cases of painful globe in absolute glaucoma. The results are satisfactory in some cases; in others trophic changes occur which result in corneal ulcer and atrophy of the globe. Resection (neurectomy) of a portion of the nerve trunk, not simple section, should be done. Less severe operative procedures should be tried before this is resorted to. It should be performed only in vigorous individuals and in cases where it is *very* desirable to save the globe.

Trephining of Sclera.—This may be practised in cases of absolute glaucoma with pain in cases in which it is not desirable to enucleate. The reduction in tension may continue for some months. It may eventually return.

Cyclodialysis.—This operation was devised by Heine[3] for relief of tension in glaucoma.

Resection of Superior Ganglion of Cervical Sympathetic.—Irritation of the cervical sympathetic, as pointed out by Hamer,[4] produces dilatation of the iris, protrusion of the globe, etc. Experiments on animals by Admück, 1866 to 1868, and by von Hippel and Gruenhager, referred to by Jonnesco,[5] show that irritation of the cervical sympathetic produces temporary increase of intra-ocular tension.

Destructive disease of the sympathetic, as has long been observed, causes miosis, slight ptosis, and decrease in intra-ocular tension. The experiments of Lagrange and Pachon,[6] Hertel,[7] and Logandorff[8] prove that excision of the superior ganglion of the cervical sympathetic produces temporary reduction of the intra-ocular tension.

In September, 1899, Jonnesco resected the superior ganglion of the cervical sympathetic for the cure of glaucoma, and in May, 1900, he reported eight cases. Very marked improvement was reported in all but two cases. Abadie,[9] who regards glaucoma as a disease due to derangement of the sympathetic, resorted to section of the cervical sympathetic in 1898 for the cure of glaucoma. It has been found that the immediate effect of resection of the superior ganglion of the cervical sympathetic is miosis followed in a few hours by reduction in tension, deepening of the anterior chamber in many cases, improvement in acuity of vision, and increase in size of the visual fields. In a large percentage of the cases the tension returns in a few days and fluctuates for some weeks. It may then remain approximately uniform, usually above the normal. Acute glaucoma on the side operated upon follows in some days or weeks in about 10 per cent. of the cases. An acute attack in the fellow eye may follow this operation. In a few cases of simple

[1] Brit. Med. Jour., October 10, 1885.
[2] Badal's operation, Arch. d'Ophth., xxi, p. 433.
[3] Deutsch. med. Woch., No. 21, 1905.
[4] Klin. Monatsb. 1873.
[5] Wiener klin.Wochenschrift, May 4, 1899.
[6] Soc. de Biologie de Paris, November 24, 1900.
[7] Graefe's Archiv, xlix, 2, p. 430.
[8] Klin. Monatsbl. f. Augenheilk, xxxviii, p. 129.
[9] Arch. d'Ophth., July, 1898.

glaucoma relatively permanent results have followed sympathectomy, but in the greater number the relief is temporary. We are at present unable to tell what cases will be permanently benefited. Removal of the superior ganglion produces throbbing and a sensation of fulness in the head due to vasomotor disturbances, which are sometimes annoying and persist for a number of months. Sympathectomy may be tried in hemorrhagic glaucoma (it does not increase intra-ocular hemorrhage); in simple glaucoma, in the cases where the limit of the field of vision is near the fixation point; in absolute glaucoma and simple glaucoma after iridectomy and sclerotomy, if these do not suffice to arrest the disease; and in cases where iridectomy and sclerotomy are refused. It is probable that the results are better in cases in which the operation is performed early.

Hydrophthalmos (*Buphthalmos; Ox Eye*).—This is characterized by a uniform enlargement of the eyeball, which affects the cornea as well as sclera, occurring in childhood, either congenitally or developing very soon after birth. Both eyes are usually, but not always, affected to about the same degree. The cornea is seldom perfectly transparent; it may be uniformly or irregularly hazy. It is frequently quite thin, and its diameter is much increased. The sclera is thin and bluish in color, due to the pigment of the chorioid and ciliary body showing through. The anterior chamber becomes very deep. The lens, which remains of normal size, lies farther back than in the normal eye, and does not support the iris, which is tremulous in consequence. The enlargement of the globe increases the distance between lens and ciliary body, and draws upon the suspensory ligament, sometimes causing rupture of part of the fibers of the ligament, producing partial dislocation of the lens. Changes—due to the stretching of the membranes—take place in the retina and chorioid. The tension of the eyeball is increased; the distention of the globe is due to the increased tension. There is marked cupping of the optic disk. This condition constitutes what has aptly been termed "infantile glaucoma." The cause is unknown. It is thought to be due to intra-uterine inflammation of the uveal tract, in some cases at least (Kalt[1]). However, the products of inflammation are not very evident. Heredity plays an important role in the production of this condition.

Microscopic Examination.—Cron[2] reports three cases, in two of which the iris was adherent to the periphery of the cornea; in one there was evidence that this had been the condition.

Prognosis.—Buphthalmos may come to a standstill with preservation of a fair degree of vision. Vision of $\frac{20}{20}$ has been reported.[3] It may advance until the eye reaches a very large size and vision be entirely abolished. Generally speaking the prognosis is unfavorable.

Treatment.—Pilocarpine and, in suitable cases, eserine in weak solution may be employed. Authors differ regarding the advisability of per-

[1] Ann. d'Ocul., cv, 225.
[2] Soc. U. K., xvi, p. 340.
[3] Epinatjew, Wjestnik Ophth., 1896, No. 6.

forming iridectomy in these cases. On account of a weakened suspensory ligament, there is danger of escape of vitreous. If the aqueous is permitted to escape slowly, serious complications, except in a few cases, may be avoided. Favorable results are reported. Schroenemann[1] reports thirteen cases, all of which were successful. Angelucci[2] reports favorably regarding iridectomy. He reports ten cases. The writer does not doubt that iridectomy is beneficial in some cases of buphthalmos, namely, in those cases in which the globe is not very large, with plus tension not controlled by miotics. In operating, a good-sized conjunctival flap should be secured. The sclera is thin and should have the support of such a flap.

Secondary Glaucoma.—The term is employed to indicate increase of the tension of the globe consequent on some antecedent pathological condition of the eye. The increase of tension may be subject to exacerbations and may be attended by pain and inflammatory symptoms, as in acute glaucoma. There may be edematous haziness of the cornea, dilatation of the iris, and diminution in vision, with periods of intermission and partial recovery. In the greater number of cases the increase of tension is continuous, occasioning little or no pain. In all cases the vision eventually fails completely, cupping of the disk takes place, and the degeneration peculiar to increase of tension develops.

Secondary glaucoma presents, in almost all cases, the condition of increase of tension due to obstruction to outflow. The degree of tension may reach T + 3, but ordinarily does not go above T + 1.

Etiology.—Conditions Influencing Development.—1. *Cornea and Sclera.*—(*a*) Perforating wounds or ulcers of the cornea which lead to the formation of anterior synechiæ, particularly those which, by subsequent cicatricial contraction, draw the iris against the cornea so as to obliterate a part or the whole of the sinus of the anterior chamber and lead to the formation of ectasiæ. (*b*) Non-perforating diseases of the cornea, as parenchymatous keratitis, which involve the margin of the cornea and anterior segment of the sclera, scleritis and episcleritis; gumma and burns, thermal or chemical, which affect the sclera and cornea in such a manner as to close part or all of the lymph channels at the filtration angle.

(*c*) Wounds of the sclera, punctured, lacerated, or ruptured, which occur in or across the ciliary zone, particularly those extending into the cornea.

2. *Iris and Ciliary Body.*—Anterior uveitis, which also involves the cornea and sclera; gumma of the iris and ciliary body; plastic iritis, the increase in tension being due to the plugging of Fontana's spaces with fibrin, a condition that lasts only a few days; iridocyclitis rarely, except when the pupil is occluded. When the anterior chamber is shut off from the posterior chamber by annular posterior synechia, with the development of crater pupil (iris bombé).

3. *Lens.*—Dislocation of the lens into the anterior chamber; valve-like obstruction to the channels for outflow; dislocation in such a manner that

[1] Arch. f. Augenheilk., xlii, p. 174.

[2] Arch. d. Ottalm., iv, 11, 12, p. 343.

the iris is pushed forward so as to obstruct the filtration angle wholly or in part. Dislocation backward into the vitreous chamber so that the presence of the lens on the ciliary processes produces irritation that results in increased secretion. Traumatism to the lens with or without rupture of the capsule, which results in the swelling of the lens to such an extent and so rapidly that the filtration angle is obstructed and outflow does not compensate for increase of volume; operative procedures, as discission or the extraction of the nucleus of the lens, leaving a quantity of the cortical substance behind. The glaucoma that follows cataract extraction is due to obstruction of the filtration angle, either by the cicatrix following the incision, a subsequent plastic iridocyclitis, or to the inclusion of iris or lens capsule in the wound. In the secondary glaucoma after extraction the onset is not infrequently determined by the same form of irritation that determines the onset in primary glaucoma. Glaucoma following discission of secondary or capsular cataract is thought to be due to entrance of vitreous body into the anterior chamber, blocking the filtration angle.

4. *Chorioid.*—Injuries and diseases, other than neoplasms, of the chorioid seldom lead to secondary glaucoma. It may follow hemorrhage from the chorioid. Lippincott[1] mentions having observed a case after rupture of the chorioid.

5. *Retina.*—Hemorrhage from the retina, due to disease of the blood-vessels, is at times followed by glaucoma which has been termed *hemorrhagic glaucoma.* The hemorrhages accompanying obstructive arteritis appear to favor increase of tension to a much greater degree than do the hemorrhages that accompany pernicious anemia, diabetes, and acute parenchymatous nephritis. Albuminuric retinitis accompanying chronic interstitial nephritis also occasions increase of tension in some cases. This form of secondary glaucoma (namely, that due to retinal hemorrhage) is in many of the cases accompanied by inflammatory symptoms, as in acute glaucoma. The glaucoma accompanying albuminuric retinitis may be unilateral. Detachment of the retina is sometimes followed by increase of tension.

6. *Intra-ocular Neoplasms.*—The second stage of intra-ocular neoplasms, whether the neoplasms spring from the retina, chorioid, ciliary body, or iris, is frequently accompanied by increase of tension. The increase of tension may be sudden in onset and be accompanied by much pain, similar to an attack of acute glaucoma. As a rule, the increase of tension is gradual and the degree of tension reached is not high.

7. *Myopia.*—Myopia of high degree is not infrequently accompanied by increase of tension. It is probable that the normal degree of tension is sufficient to progressively enlarge the globe in many cases of high myopia, but, aside from this, a marked increase of tension in some cases, with cupping of the nerve head, is observed. The increase of tension in myopia is seldom accompanied by inflammatory symptoms. It belongs to the form known as simple glaucoma.

[1] An American Text-book on Diseases of the Eye.

Complicated Glaucoma.—Glaucoma occurs rarely in the course of certain conditions of the eye which apparently are in no way causative—senile cataract, retinitis pigmentosa, atrophy of the optic nerve. Glaucoma, under these conditions, is termed *complicated glaucoma.*

Treatment.—It is possible in some cases to tide over a temporary increase of tension by the use of miotics. Whether miotics should or should not be used must be determined by the individual case. Miotics are sometimes of value in cases of high myopia with increase of tension. The cause must be removed if possible. A swollen or dislocated lens must be extracted. Total posterior synechia, anterior synechia, total or partial, require free iridectomy. Iridectomy is also sometimes beneficial in glaucoma due to sclerosis of the anterior segment of the fibrous coat of the eye (cornea and sclera), following disease of these parts, also in aphakic eyes, with or without a previous iridectomy. Paracentesis of the anterior chamber will serve to *temporarily* decrease the tension. In cases of painful blind eyes without neoplasm, posterior sclerotomy may serve to render the eye painless and enable the patient to retain it. Globes with neoplasms and painful globes, not amenable to iridectomy and sclerotomy, should be removed.

Operative treatment in *hemorrhagic glaucoma* by iridectomy or sclerotomy is seldom satisfactory. Both are liable to be followed by hemorrhage which will result in destruction of the eye. Miotics may be of service. Sympathectomy, which is followed by reduction of tension—at least temporarily—may be tried. The results that have been obtained by this operation in these cases are not brilliant. They are, however, sufficiently encouraging to warrant its use. In some cases the progress of the disease has apparently been arrested.

Reduction of Intra-ocular Tension (*Hypotony*).—This condition is produced by a diminution in the volume of the contents of the globe. The escape of aqueous or vitreous from whatever cause, diminution of the volume of vitreous humor as a result of disease, and the shrinking of exudates, as after plastic chorioiditis, will cause a decrease in the tension of the globe. Inflammation of the cornea without perforation is often accompanied by slight decrease in tension. When a bandage is applied, the pressure on the eye increases the outflow of fluid; for a short time after the bandage has been removed—until the normal equilibrium can be established—the eye is soft. Detachment of the retina is accompanied by decrease of tension so frequently that it is regarded as a diagnostic symptom.

Essential Ophthalmomalacia.—Paralysis of the cervical sympathetic is accompanied by slight reduction in tension. To injury to the eye and to affections of the cervical sympathetic is ascribed the cause of the rare and peculiar affection known as *essential ophthalmomalacia.* This condition is characterized by a temporary hypotony of the globe accompanied by injection of the ocular conjunctiva, photophobia, flashes of light, neuralgic pains, and obscuration of vision. In a few days the normal tension is restored and the symptoms disappear.

CHAPTER XVI.

THE RETINA.

Function of the Retina.—It is the function of the retina to transform the impressions produced by the rays of light that impinge upon it into nervous impulses. The impulses pass from the layer of rods and cones (visual cells) to the ganglion cells, and from these to the optic nerve and to the brain, in the cortex of which they are received and interpreted. The conversion of the stimulus afforded by light-waves of different lengths takes place in the layer of rods and cones, and is attended by mechanical, electrical, and chemical changes.

The mechanical changes consist in the migration of the pigment granules in the cells of the retina (see page 75) and in the alteration in the form of the cones.

Electrical disturbances have been studied by Holmgren, Kuehne and Steiner, and others, and are fully described by Dr. Carl Mays.[1] Kuehne and Steiner's experiments go to show that the electrical fluctuations or vibrations originate in the rods and cones.

Physicochemical Changes.—The known chemical changes that take place in the retina affect the visual purple which is contained in the rods. This substance is changed by the action of light into a colorless substance, a photochemical disintegration or degeneration of the visual purple. When light is permitted to enter through a yellow screen or is partly or wholly excluded for a number of hours, the substance is again restored to the purple color; a photochemical restoration or regeneration takes place which is complete. This change may take place in the dead as well as in the living retina. "When light acts upon the visual purple (rhodopsin), it first produces visual yellow (xanthopsin) and then visual white (leukopsin)."

It has been proved that the presence of visual purple is not necessary to vision, as it has been observed that animals without visual purple see readily, and the fovea centralis, which is supplied with cones only, and is devoid of visual purple, is the part of most acute vision. It is probable that the photochemical changes that take place are stimulating or irritating processes, and that they aid in generating the visual impulse.

Of the impulses sent to the brain, those which emanate from the fovea centralis only are capable of inducing the interpretation of sharply defined images. It has been found that in order to determine detail in an object, the image of which falls on the retina, the rays of light from

[1] Norris and Oliver's System, vol. i, p. 645.

the adjacent visible points must subtend an angle of 60 seconds. This implies the formation of a retinal image of about 0.005 mm., about the diameter of a cone (a visual cell at the fovea). This carries out the idea that the excitation of a single cone produces the sensation of a point of light distinguishable from that produced by the stimulation of another cone. It will thus be seen that the destruction of a portion of the layer of rods and cones of whatever size produces a corresponding scotoma, or blind spot.

Effect of Various Colored Lights on the Retina.—Samuilow,[1] as a result of numerous experiments, concludes that red exhausts the retina most rapidly, green less, blue least. The limit of the visual spectrum at the violet end differs much in different individuals. It is greater in the young than in the old, and greater in the aphakic than in the normal eye (Widmark). Photometric experiments disclose the fact that the middle (yellow) portion of the visible spectrum is first perceived. The perception of colors varies within certain limits with the area of the color, the diminution in brightness with diminution in size affecting the more refrangible colors (violet end) most; with diminution in illumination the least refrangible (red) is first affected (Carpenter).

After-images.—After-images are the images of which an individual is conscious immediately after the object which originated the image ceases to be regarded.

If a brightly illuminated object be looked at intently for fifteen or twenty seconds and the eyelids closed or the direction of regard changed, as against a neutral tinted screen, the image of the illuminated object will persist for an appreciable length of time and will present more or less definitely the appearance of the object in color and form. This phenomenon is termed a *positive* after-image. It is best observed by looking at the sun or at any other bright source of light and then closing the eyes. In a few seconds the color of the positive image gradually changes and an image having the same form but with colors complementary to those of the first image appears. If the color of the original image is yellow, the color of this after-image will be blue. This phenomenon is termed *negative* after-image. The negative after-image is frequently more readily recognized than the positive after-image. The complementary color of the negative after-image is apparently due to retinal fatigue produced by the intense stimulus of the image of the luminous object on the retina.[2]

ANOMALIES OF THE RETINA.

Absence of Pigment.—This occurs in albinos almost exclusively. Partial absence of the retinal pigment is occasionally encountered. When this is the case the chorioidal vessels and the characteristic dis-

[1] Wjestnik Ophth., 1889, xi, p. 2.

[2] See Norris and Oliver's System, vol. i, p. 528, for a comprehensive discussion of this phenomenon

tribution of the pigment in the chorioid may be observed. The margins of the defect are usually sharply defined. When these defects occur near or at the macula, the patches are usually circular.

Opaque Nerve Fibers.—These are due to the presence of medullated nerve fibers in the nerve-fiber layer of the retina. Usually situated on and near the disk and connected with it, they may be found in isolated large or small patches remote from the disk. In the former position the patch may entirely surround the disk and extend two or more disk diameters above and below, or even reach almost to the macula. There may be only a very small patch. All degrees between these extremes are observed. The color is a glistening white at its densest part, which is commonly placed at the margin of the optic disk. The

Fig. 220

Opaque nerve fibers. (De Wecker and Masselon.)

patch terminates in an irregular feathery border with fine striations radiating from the disk. The blood-vessels at the centre of the disk are plainly visible, but where they pass through a patch of opaque nerve fibers they may be completely hidden. Occurring away from the disk, the patches are usually very thin, delicate, and feathery. Opaque nerve fibers may occur in one eye only, but are bilateral in the greater number of cases. The size and arrangement of the patches are seldom alike in both eyes. A scotoma exists in the field of vision corresponding with the retinal area occupied by the patch of opaque nerve fibers. In extreme cases the eye is amblyopic (Lang and Collins).

The condition is influenced by heredity. It is not uncommon to find two or more members of a family affected. The patches remain practically unchanged throughout life.

Retinal Pigmentation.—Peculiar arrangement of the retinal pigment is sometimes observed. Von Reuss[1] describes numerous confluent pigment dots, the result of congenital changes in the pigment epithelium. Small, symmetrical, pigmented, circular patches are sometimes observed at or near the macula. They remain unchanged throughout life. Small irregular pigment patches are also observed.

Vascular Anomalies.—In quite a large percentage of the cases (16.7 per cent., Long and Barrett;[2] 14 per cent., Veasey[3]) the retinal circulation is supplemented by a (rarely more than one) small arterial twig from the short ciliary arteries, usually derived from the circle of Haller, but which may spring from the vessels at the chorioidal margin. The branch usually occurs on the temporal half of the disk above the horizontal meridian and proceeds toward the macula, in some cases anastomosing with branches from the central retinal artery. Branches may occur at any part of the circle and pass in any direction from the disk. They are readily recognized as they disappear just at the margin of the disk (see Fig. 98). They are seldom binocular.

Peculiar Arrangement of Vessels on or about the Disk.—An arterial branch may project forward into the vitreous two or three millimeters, form a loop, and return to the normal level; it may be twisted upon itself. A vein may accompany an artery. Two venous branches may anastomose at or near the margin of the disk. A vein and artery may be coiled around each other, describing one or two turns.

DISEASES OF THE RETINA.

Hyperemia.—This is a condition in which there is an excessive amount of blood in the vessels of the retina. It may be classified as active or passive.

Active Hyperemia.—This exists when the entrance of arterial blood into the vessels of the retina is greater than normal. It affects both eyes, but is sometimes more pronounced in one than in the other.

Passive Hyperemia.—This is a result of venous stasis, and will be considered here in its mildest form only. (For the consideration of marked venous stasis, see page 427.) It is characterized by an increase in the size and tortuosity of the veins and a deepening in the color of the venous blood. The arteries are often slightly smaller than normal. This condition is much more often unilateral than is the case in active hyperemia, and, since the opportunity for comparison is present, can be more readily diagnosticated. The appearance of fine striations in the region of the disk is not present in this form of hyperemia, as a rule. Edema, when it occurs, is of a pronounced character and is classed as exudation. The condition is then termed venous stasis with exudation.

[1] Wiener med. Presse, vol. x, No. 9, S. 287.
[2] R. L. O. Hosp. Reports, vol. xii, p. 59.
[3] Ann. of Ophth. and Otol., July, 1893.

Etiology.—Active hyperemia is the first stage in all forms of true retinitis. It is common in those who suffer from eye strain due to errors of refraction or to muscular anomalies; in those who use their eyes excessively, especially by artificial light; in those exposed to excessive glare of light and excessive heat.

Passive hyperemia may be caused by anything that prevents the free return of blood to the veins of the orbit, such as partial stenosis of the central vein, conditions causing engorgement of the veins of the head, as convulsive seizures, violent cough, emphysema, mitral disease. A form of venous stasis is also observed in cases in which the flow of arterial blood is below the normal in amount. The venous blood becomes darker in color, the veins not so regular in contour, and, although just as broad, are not so full.

Diagnosis.—As the physiological range of the color of the fundus of the eye due to the presence of blood in the retinal and chorioidal vessels is considerable, and as mild cases of hyperemia are not accompanied by edema of the retinal tissue, it is difficult to diagnos the condition with certainty. If the hyperemia is accompanied by slight edema, the diagnosis is made with relative ease. There is but little increase in the size of the arteries, but an overfulness of the capillaries heightens the color of the retina. The color of the disk is much deepened, and may approach the color of the adjacent retina. This appearance of the disk is said to be due to excessive "capillarity." In active hyperemia the veins are slightly distended, but the color is not deepened; on the contrary, the color of the venous blood is lighter than in the normal retina. The transparency of the retina is not diminished, nor is the acuteness of vision impaired. When slight edema of the retina occurs in active hyperemia, it is confined to the disk, the nerve-fiber layer of the retina in the immediate vicinity of the disk, and along the arterial trunks. This is manifest as fine, pale striations radiating from the disk, particularly noticeable in the thick nerve-fiber layer at the upper and lower margin of the disk and as pale, diffuse lines accompanying the arteries. A very slight veiling of the tissue of the disk and vicinity results.

Symptoms.—In active hyperemia there is increased sensitiveness to light, inability to use the eyes for close work for any length of time, often some pain, and a sensation of fulness in the eye.

Passive hyperemia is not accompanied by symptoms, unless there be some impairment of vision.

Treatment.—This consists in ascertaining and removing the cause. Local treatment directed to the condition of the blood-vessels in the eye itself is not of value.

Venous Stasis.—A serious form of hyperemia of the retina is that occasioned by partial or complete closure of the caliber of the central vein of the retina or of one of its branches. In this condition the veins become much enlarged, very tortuous, and almost black in color. There is much exudation along the course of the veins. This is so intense that the disk is often entirely hidden. The exudation occurs in the nerve-fiber

and in the deeper layers as far back as the outer reticular layer, and is either diffuse or fairly well defined. Numerous hemorrhages are present in all parts of the retina, particularly throughout the posterior third of the fundus. The hemorrhages are diffuse, radiating from the disk, or are well defined and more or less circular in shape, according as they take place (*a*) in the nerve-fiber layer or (*b*) deeper in the retina. The condition is most frequently met with in individuals between fifty and seventy years of age and is ordinarily accompanied by arterial sclerosis. It is seldom bilateral. Males and females are affected in equal proportion. While vision is impaired, it is seldom entirely abolished. This is accounted for by the supposition that collateral venous circulation is established to some degree.

Fig. 221

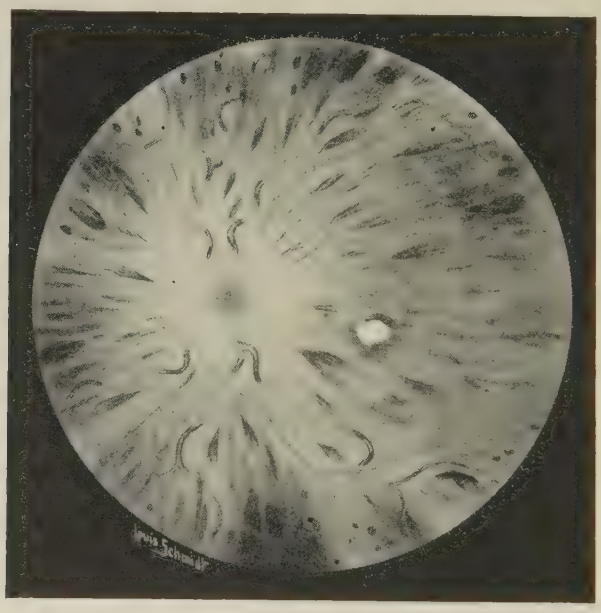

Venous stasis from obstruction of central artery of retina.

Etiology.—Disease of the vessel walls due to syphilis, albuminuria, diabetes, or atheroma; traumatism, the exanthematous fevers and sepsis, followed by the formation of a thrombus..

Symptoms.—More or less sudden diminution of vision, sometimes almost complete; no pain, as a rule, unless glaucoma develops, when pain may be intense.

Results.—Acute glaucoma occurs in a number of cases. In nine cases observed by the writer acute glaucoma occurred in one, producing absolute blindness in the affected eye, the fellow eye remaining normal. One writer reports four cases of glaucoma in eighteen cases of venous thrombosis. In the majority of the cases some degree of vision was recovered.

Treatment.—The iodide of potash and mercury in small, long-continued dose, with iron when the blood is deficient in hemoglobin, have appeared to be beneficial. The general health of the patient should be kept as good as possible. Little or nothing is gained by keeping the patient in a darkened room. Medium tint "London smoke" glasses may be worn if the light is annoying. Very moderate use of the eyes may be permitted. Iridectomy in cases in which glaucoma develops does not promise well, because of intra-ocular hemorrhage, which is prone to follow.

Dilatation of the Retinal Veins (*Phlebectasia Retinæ*).—The following varieties are recognized: cylindrical, fusiform, serpent, sacciform, varicose. Atrophy of the muscular and elastic walls of the veins and perverted vasomotor influences may account for some of the cases, but the greater number are due to thrombotic obstruction of the caliber of the vein at some point.

Anemia.—Anemia of the retina is a term applied to a condition of abnormal paleness of the retina.

Etiology.—It may be due either to (1) a reduction in the amount of blood that flows through the retinal vessels, or to (2) a change in the quality of the blood. To the first belong the anemias due to great systemic loss of blood, as in hemorrhage from the stomach, uterus, etc., and those due to obstruction to the arterial flow, as in spasm, obliterating arteritis, embolism, and thrombosis. This form is characterized by small, narrow, light-colored arteries, which may pulsate, and by dark-colored, tortuous veins. The most pronounced cases of acute permanent obstructive anemia are due to plugging of the central artery of the retina; of chronic obstructive anemia, those cases in which complete obliteration of the arteries occurs, as in obliterating arterial sclerosis and in atrophy of the retina.

Transient obstructive anemia may be produced by pressure on the eyeball, by increase in intra-ocular tension, and by spasm of the arteries of the retina. The latter condition is observed as a result of the giving of toxic doses of salicylic acid or quinine, in arterial sclerosis, and in true migraine. Transient anemia also occurs in cases of great loss of blood, as in hemorrhage from the lungs, intestinal tract, and genital organs, and has been observed by von Graefe during the stage of collapse in cholera. Anemia also accompanies atrophy of the retina and optic nerve. In all forms of obstructive anemia of the retina, vision is more or less impaired transiently or permanently.

To the second group belong the forms that accompany general anemia, pernicious and tapeworm anemia, and leukemia. In anemia due to these causes the blood-vessels are not changed in size, but the color of the blood flowing through them is lighter, due to a preponderance of the proportion of white blood corpuscles over the red.

Ischemia of Retina.—This term is used somewhat ambiguously. It means a holding back of the blood supply, and may be applied to any case of anemia of the retina due to obstruction to the flow of blood, as by compression, plugging, obliteration of lumen, or to spasm of the arteries

due to disease of their walls[1] (vasomotor ischemia). The term is usually applied to transient anemic conditions, as in epilepsy (Hughlings Jackson),[2] lightning stroke,[3] in which the obstruction is probably due to spasm of the arteries.

Prognosis.—In many of the reported cases the tendency to spasm passes off after a few weeks or years without impairment of vision. In some, partial or complete loss of vision results. The disease of the walls of the vessels, to which the spasm is due, may eventually cause obliteration of the lumen of the vessel, the amblyopia becoming permanent.

Treatment.—Dietary and medicinal measures directed to the improvement of the vascular system are the only measures that are of value.

Plugging of Central Artery of Retina.—This may be due to embolus, thrombus, or to obliterating or proliferating endarteritis. It is characterized by a more or less sudden loss of vision, almost complete collapse of the retinal arteries, slight collapse of the veins, the venous blood becoming darker in color; grayish, hazy, opaque appearance of the retina at and in the vicinity of the disk and macula, and the presence of a cherry-red spot at the fovea centralis.

Etiology.—While earlier writers have almost without exception attributed this picture to embolism, recent observers[4] are of the opinion that local disease of the central artery, resulting in the formation of a thrombus, or proliferating endarteritis, is the cause in many of the cases. If the obstruction occurs suddenly, and if the eye is examined shortly afterward and the arterial flow is completely stopped, the cause may be embolus or thrombus. If disease of the heart exists, or a suppurative process or a phlebitis is present in some part of the body, or there is aneurism in the arteries between the heart and the eye, the cause is, in all probability, embolism. Of 59 cases of supposed embolism, Galezowsky failed to find any disease of the heart or aorta in 13 cases. If it happens that a blood-stream, however small, still exists in the retinal artery, immediately after the attack, either thrombosis or obliterating arteritis is the probable cause. Both of these conditions may be preceded by prodromal symptoms. This is particularly the case in prolifer-

[1] Spasm occurs, as a rule, in elderly adults in whom there is evidence of arterial sclerosis. It is transient in character, lasting from three minutes to six or eight hours. It is monocular, seldom binocular. The spasm may affect the central artery, in which case the amblyopia is complete, or it may involve a branch of the central retinal artery only, in which case the amblyopia affects but a part of the field of vision. As a rule, the attacks are repeated at varying intervals. There is no pain at the time, nor are the attacks accompanied or followed by headache or cerebral disturbances. In some of the cases the attack is preceded by a "fluttering" of the vision in the eye affected. Ophthalmoscopic examination has been made in a number of cases (Zentmayer, Trans. Section on Ophth., A. M. A., 1906, p. 174) throughout an entire attack. At the onset there is diminution of vision, the arteries become small, the blood-column disappears in the arteries and sometimes in the veins, the vessels showing as pale lines. In the reëstablishment of the blood-current the vessels fill gradually. Eventually the veins become much distended (Wagenmann). In some cases the spasm affects a vessel in part of its course only (Benson). The affected vessel may be bloodless where it emerges from the disk and for a few disk diameters in its course, the blood-column being present beyond the constriction.

[2] Ophth. Hosp. Rep., iv, p. 14. Gowers has never seen ischemia of the retina in epileptiform convulsions.

[3] Uhle, Zeh. klin. Monatsblt. f. Augenheilk., xxiv, p. 379.

[4] Reinor, Arch. f. Augenheilk., March, 1899; Kern, Inaug. Dissert., Zürich, 1892.

PLATE XIX

Embolism of Central Artery.

ating endarteritis. In all cases in which thickenings of the walls of the arteries can be seen with the ophthalmoscope, whether uniform or not, the cause of the obstruction is probably proliferating endarteritis.

Plugging of the central artery is, as a rule, monocular. Rare cases of binocular embolism or thrombosis have been recorded.[1]

While plugging of the central artery of the retina is most frequently met with in individuals over forty years of age, it has been recorded as occurring at the age of fifteen.

Thrombosis is often the result of syphilis, which may also produce an obliterating arteritis. Atheroma, rheumatism, and gout are also given as causes of obliterating arteritis. Embolism, thrombosis, and obliterating arteritis may affect the artery before it branches, shutting off the blood-supply to the entire retina, or it may affect a retinal branch only.

Symptoms.—When embolism of the central artery takes place, blindness comes on almost immediately, but subjective sensations of moving forms may be experienced for some minutes at least, and perhaps for an hour or two, due to a disturbance of the retinal elements by the collapse of the vessels.

If a small column of blood remains in the vessels it almost invariably becomes broken, and if slight pressure is made upon the globe or even in some cases without appreciable pressure on the globe, the blood will flow from the branches into the central vessel. This is one of the symptoms which enable the observer to differentiate between embolism and thrombus or proliferating endarteritis.

In complete plugging the appearance of the fundus varies according to the time that has elapsed. After the closure of the vessel, the characteristic appearance as already described may be modified by the presence of a few small hemorrhages usually near the disk. The column of blood in the arteries when present may be broken up and may move in a jerky manner. Centripetal movement of the blood in the arteries has been described.[2]

The edema of the retina which occasions the grayish pallor of the posterior portion of the fundus slowly disappears, often leaving small, punctate or irregularly shaped whitish patches about the macula, somewhat like the patches observed in albuminuric retinitis.

These small patches are due to the presence of exudation in the deep layers of the retina, viz., in the inner nuclear, outer reticular, and outer nuclear layers. This exudation also gradually disappears. At the end of four to six weeks all the exudation will have been absorbed. The cherry-red spot is due to the blood in the choriocapillaris of the chorioid which shines through the retina at its thin portion, the fovea centralis.

[1] The writer observed one case in which embolism of the central artery of the right eye was followed by embolism of the central retinal artery of the left eye five days later, in a woman, aged sixty years, with endocarditis. Van Duyse (Bull. d. l. soc. belge d'opht., November 24, 1901) reports a case in which blindness in one eye was followed by blindness in the other eye within a few minutes, both from embolism.

[2] Hirschberg, Centralblt. f. Augenheilk., viii, p. 14; Baratz, Vratsch, No. 29, 1891.

The absence of blood-vessels and of the four inner layers of the retina at this point causes this portion of the retina to remain free from exudation and permits it to remain transparent. With the disappearance of the exudation from the retina the red spot at the fovea centralis loses its conspicuous character. The blood-stream in the arteries, which at the time of complete plugging is very small, is restored slowly. At the end of five to seven days it is often almost normal in volume. In some cases the arteries and veins remain abnormally small. The *optic disk* slowly becomes pale and assumes the appearance observed in simple atrophy of the optic nerve.

When the plugging is incomplete, as is sometimes the case when the interference with the blood-stream is due to thrombus or proliferating endarteritis, the exudation is very slight. The arterial vessels are not entirely emptied, and we may have a restoration of the arterial flow with disappearance of the exudation in a very few days.

When plugging of one of the branches of the central artery only takes place, the disturbance is confined to the area supplied by the affected branch.

Diagnosis.—The ophthalmoscopic picture just described is always the result of interference with the flow of arterial blood. It is often extremely difficult to say whether this interference is due to an embolus, to a thrombus, or to proliferating endarteritis.

Division or compression of the central artery back of the globe will produce a similar picture, but a history of traumatism under these circumstances will be obtained which will establish the diagnosis.

When in addition to division of the central artery there is also division of the ciliary arteries the appearance of the retina is the same, with the exception of the cherry-red spot, which is then absent, because of absence of circulating blood in the choriocapillaris.

Prognosis and Effect on Vision.—In sudden complete plugging of the central artery of the retina, vision is completely lost within a very few minutes. If the flow of arterial blood is shut off gradually, vision will also fade gradually. The degree of loss of vision depends directly on the degree of the interference with the nutrition of the nerve elements of the retina.

Vision begins to fail at the periphery, disappearing at the fixation point last.

In cases in which there is a cilioretinal branch (14 to 17 per cent.), the portion of the field of vision supplied by this branch remains unaffected.

In cases in which a branch of the central artery of the retina only is occluded, the loss of vision corresponds to the portion of the retina which depends on the affected branch for its nutrition. The permanent effect on vision depends to some extent on the duration of the anemia of the retina. Little if any return of vision can be expected if *profound anemia* has lasted longer than twelve or twenty-four hours, on account of the rapidity of the pathological changes that take place in the neurons of the retina.

Although anastomoses with arteries of the retina at the periphery have not been demonstrated, some cases have been reported in which there was complete plugging of the central artery of the retina and in which some vision in the nasal part of the field has been preserved. These cannot be explained in any other way than by assuming that some collateral circulation is established at the periphery of the retina.

Treatment.—As a rule, treatment is unsatisfactory. Some cases of recovery are on record. Hirschberg[1] reports one in which recovery took place in embolism affecting a branch of the central artery after vigorous massage of the eye had been employed. Würdemann[2] reports two cases. "Deep" massage was resorted to in the first case six days, in the second three weeks, after the embolism took place. Other cases are reported, but they are not numerous.

In embolism an attempt should be made to force the embolus onward into one of the branches in order that part of the field of vision may be restored. Dilatation of the peripheral blood-vessels and stimulation of the heart in connection with massage may accomplish this. Digitalis should be given as soon as the patient is seen, in quantity sufficient to stimulate but not to depress the heart. After twenty to thirty minutes have elapsed a vasomotor dilator, preferably nitrite of amyl, sufficient to cause quite marked dilatation of the peripheral vessels, may be given. Glonoin may be substituted for the nitrite of amyl if the latter cannot be readily obtained. A very few minutes after the giving of the nitrite of amyl, vigorous massage may be employed. The eyeball may be pressed backward into the orbit somewhat forcibly and then suddenly released. This may be repeated a number of times with the eyeball in the primary position, and also with the eyeball forcibly rotated in different directions. Massage as far back on the globe as it is possible to reach with the fingers may be employed, and, in addition, deep massage by means of a strabismus hook or other similar instrument, passing the hook as far back toward the posterior pole of the eye as possible. If improvement in vision does not follow the first, subsequent treatments may be given. If improvement does not take place after three treatments have been given, it is unnecessary to make further attempts to dislodge the embolus.

In cases due to thrombus or proliferating endarteritis, the systemic condition that has produced these changes must be attacked; potassium iodide and mercury may be resorted to for the purpose of influencing the local lesion. These remedies are employed in order that they may prevent plastic new formations and to arrest changes that are taking place in the walls of the vessels.

Anemia followed by More or Less Complete Blindness Due to Hemorrhage from Remote Parts of the Body.—**Etiology.**—This occurs after hemorrhage from the stomach, intestinal tract, lungs, genital tract, particularly the uterus, from the veins, as after venesection, and, extremely rarely, after injuries.

[1] Centralblt. f. Augenheilk., xii, p. 296.

[2] Arch. of Ophth., xxxi, 6, p. 611.

Kurtsinger[1] has collected 198 cases. The sex is given in 174, 79 males and 95 females. The youngest individual affected was two years of age, the oldest seventy-seven. The greater number of cases occurred between the fortieth and fiftieth years of life. Of 189 cases, 76 were from hemorrhage from the stomach and intestine, 62 from the uterus; 27 were due to artificial bleeding (23 followed venesection, 3 application of leeches, and 1 scarification of the scalp); 4 followed epistaxis; 5 followed wounds in various parts of the body; 2 were due to hemorrhage from the lungs, and 2 to bleeding from the urethra.

Number of Hemorrhages.—In the majority of cases loss of vision follows a number of hemorrhages. Blindness may supervene after one profound hemorrhage. In the cases in which hemorrhage was induced, as in venesection, the loss of vision followed a single escape of blood. In a number of cases blindness has supervened after the continuation of bleeding for some days. In a case observed by the author in a woman, hemorrhage from the uterus was more or less constant for fourteen days. In this case vision was reduced to counting fingers at two feet.

In regard to the amount of blood that must be lost in order to produce blindness nothing positive is known, as a physician ordinarily is not present when the hemorrhage takes place, and the statement of the patient is very indefinite.

In many of the cases reported the patient has been somewhat debilitated when the hemorrhage took place. It is possible that the condition of the system favors the affection of vision, but this cannot be said of all cases. In one case observed by the writer, blindness followed a single hemorrhage from the stomach occurring in a strong man, a laborer. It is a remarkable fact that affections of the vision seldom follow bleeding after operative procedure.

Pathology.—Ziegler[2] reports degeneration of ganglion cells and nerve-fiber layer; there was no small-cell infiltration. The only experiments with positive results have been made by Holden[3] on dogs and rabbits. It is today fully recognized that the blindness is due to degeneration of the ganglion cells primarily because of interference with their nutrition.

Symptoms.—*Ophthalmoscopic Picture.*—In some cases in which the loss of vision is great, there is nothing abnormal to be seen in the fundus. In others examined shortly after blindness came on, edema of the disk was observed. Edema of the retina, not so great as in embolism of the central artery, and small hemorrhages have been seen. In very many of the cases the arteries are small, the veins somewhat tortuous, quite wide, and filled with dark blood. Pulsation has been observed. The veins are smaller than normal in some cases. Paleness of the disk is sometimes seen very soon after blindness supervenes, but atrophy is frequently delayed, coming on some weeks or months afterward.

Vision and Prognosis.—In regard to the time of impairment of vision after the hemorrhage, of 120 cases reported by Singer, in 8.3 per cent.

[1] Beiträge zur Augenheilkunde, Heft 53, 1902.
[2] Beit. z. Path., Anat, u. Phys., ii, 1, 57 to 72.
[3] Arch. f. Augenheilk., xl, 351.

impairment of vision began during the hemorrhage; in 11.6 per cent., immediately after; in 14.2 per cent., within twelve hours; in 19.2 per cent, before the end of the second day; in 39.2 per cent., from three to ten days after the hemorrhage; in 7.5 per cent., after more than ten days. In 14 cases impairment of vision came on fourteen days after the hemorrhage; in 1 case, eighteen days; in 1 case, between fourteen and twenty-one days; in 1 case, three weeks, and in 1 case, sixty days after the hemorrhage.

Fig. 222

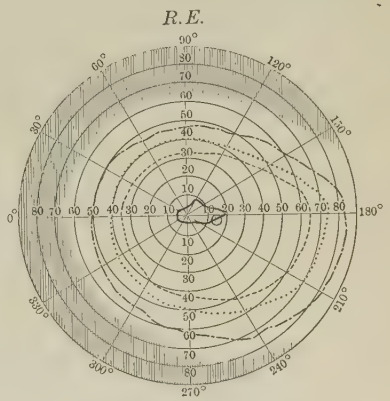

Visual field in a case of hemorrhage from the stomach. $V = \frac{20}{50}$. Left eye blind.

The degree of impairment of vision differs very much in various cases. Singer reports 58.8 per cent. of complete blindness, 32.4 per cent. of partial blindness; in 8.8 per cent. blindness was complete in one eye and partial in the other. In those rendered partially blind, the fields of vision presented many curious defects. In some cases a uniform concentric limitation is present, reducing the field in some but little, in some to a purely telescopic field —a field the extent of which is not more than 10 or 15 degrees. Sector-like defects, central and paracentral scotomata, have been observed.

The results differ much. Singer reports no improvement in 45.9 per cent., improvement in 39.1 per cent., complete recovery in 13.5 per cent., and subsequent failure in 1.5 per cent.

The effect on the pupil depends entirely on the degree of failure of vision. If perception of light is abolished the pupil remains dilated.

Treatment.—The treatment of blindness after hemorrhage is usually of little avail. The hemorrhage, of course, should be stopped as early as possible and supportive measures employed. Nourishing food in plentiful amounts should be taken and tonics containing iron administered. If the patient is seen very shortly after hemorrhage has occurred, it is possible that transfusion of salt solution intravenously may be of value.

Leukocythemic Retinitis.—**Etiology.**—Leukocythemic retinitis may occur in any of the forms of leukocythemia, being present in from 25 to 33 per cent. of the cases (Leber), but is most frequently seen in splenic leukocythemia.

Pathology.—Extravasation of blood takes place most frequently in the nerve-fiber layer, but it is often present in the inner reticular, inner nuclear, and outer reticular layers, and may penetrate into the layer of rods and cones. The small vessels are crowded with leukocytes which are always present in large numbers in all of the hemorrhagic foci. The pale appearance of the retina and of the margins of the vessels and the

white centres observed in the hemorrhagic spots are due to the presence of enormous numbers of white blood corpuscles. The optic disk is infiltrated with small cells and, in cases of long standing, newly formed connective tissue may be present. Leukocytes and red blood-corpuscles not infrequently pass through the membrana limitans interna into the vitreous body. The blood-vessels may present varicosities consequent on the accumulation of white blood-cells.

Fig. 223

Changes in the eye ground in leukemia. (After Haab.)

Symptoms.—Both eyes are involved, but one may be affected more profoundly than the other. The retinal disturbance may occur at any stage of the leukocythemia, and in some cases precedes the general symptoms of the disease. The fundus of the eye usually appears lighter in color than normal. A pale orange tint has been described by some writers, a lemon color by others. There are differences in the color due to difference in pigmentation. The arteries are pale, light orange-red, often somewhat reduced in caliber. The veins are dilated, broad and tortuous, and of a deep orange red. The central tract of the veins may be quite pale, and arteries and veins may be bordered by white stripes. The optic disk is usually somewhat swollen, its outlines obscured;

the retina, particularly in the vicinity of the posterior pole, often becomes hazy; numerous hemorrhages occur near the periphery of the retina and in the vicinity of the macula. Many striped or flame-shaped hemorrhages may occur on and in the vicinity of the disk. The centres of the larger hemorrhagic spots may be light yellow or almost white in color. Irregular white patches slightly raised and with a red border are present in many of the cases. In the vicinity of hemorrhagic spots the color of the retina may be influenced by the diffusion of the pigments of the blood before they have been entirely absorbed.

There is a milder type of retinal affection due to leukocythemia in which evidence of inflammation is wanting. In this mild form the hemorrhages are less numerous than in the severer form, but the distribution of the hemorrhages is the same. The pale color of the fundus, the tortuous and overfull veins are quite distinctive. The optic disk does not present a great departure from the normal, nor is the retina opaque.

Vision.—Vision may be but little disturbed, but when hemorrhage or exudation occurs in the region of the macula, vision is much diminished. Scotomata corresponding to the site of large hemorrhages or of plaques of exudation are present. The interference with central vision depends largely on the location of these lesions. Complete blindness may result relatively early in the severer cases.

Diagnosis.—It is often difficult to differentiate this condition from albuminuric retinitis, particularly when the yellow plaques occur at the macula. Albuminuria may complicate leukocythemia, in which case the appearance of the fundus leaves one in doubt.

Complications.—The complications that attend leukocythemic retinitis are chorioidal hemorrhages, hemorrhages into the vitreous, into the ciliary body, and iris. Hemorrhages also occur into the conjunctiva. Secondary (hemorrhagic) glaucoma develops in quite a large percentage of the graver cases. Exophthalmos from extravasation of blood into the orbital tissue and lymphomata of the eyelids have been observed.

Prognosis.—The prognosis in leukocythemic retinitis is bad. Slight improvement may take place, but this is usually followed by relapses and the ultimate result is unfavorable.

Treatment.—The treatment of leukocythemic retinitis consists in the treatment of the general condition. It is necessarily principally dietetic. Arsenic and quinine have been recommended.

Retinitis of Pernicious Anemia.—**Pathology.**—The walls of the blood-vessels are but little changed. The nerve-fiber layer of the retina is often edematous; the fibers are more or less swollen and show varicosities. In places the fibers are pushed apart by hemorrhages. The elements of the deeper layers of the retina are also separated by the constituents of the blood that have escaped from the blood-vessels. The escaped blood-corpuscles undergo degenerative changes. The tissues of the retina in the immediate vicinity of the clots are more or less colored by blood pigment. White corpuscles are found in the clots, and, in addition, small hyaline masses are present.

Symptoms.—This form of retinitis is characterized by a rather pale fundus. The arteries are somewhat tortuous, light in color, perhaps slightly enlarged, but not departing much from the normal in size. The veins are broad, tortuous, and slightly overfull, the venous blood being lighter in color than in the normal eye. The change in the blood-vessels is pronounced at and near the disk, but is scarcely recognizable at the periphery.

Uhthoff calls attention to a condition which may be observed in many cases, namely, that the color of the vessels on the disk, particularly the veins, is much lighter than on the adjacent retina.

In typical cases numerous hemorrhages occur. The hemorrhages take place at the papilla and in its vicinity principally, but may reach to some distance from the optic disk. Many of them are striped or

Fig. 224

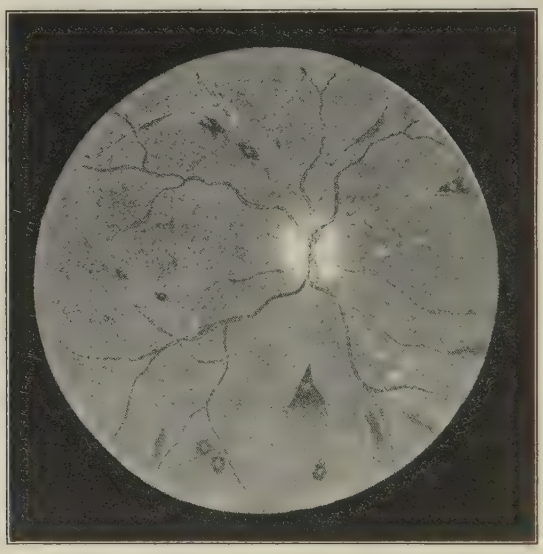

Retinitis in pernicious anemia. (Graefe and Saemisch.)

flame-shaped, occurring in the nerve-fiber layer, but the greater number are circular, occurring in the deeper layers of the retina. Frequently they present a pale yellow centre. It will be seen by this description that the retinitis of pernicious anemia resembles closely that of leukocythemia. The chief distinguishing characteristic is that the hemorrhages are not so numerous in the retina near the equator of the globe as they are in leukocythemic retinitis.

The affection of the retina in pernicious anemia is very marked in some, very slight in other cases.

Vision.—The disturbance of vision may be extremely slight or may be pronounced. Blindness is seldom produced, but relative and positive scotomata may be present in various parts of the field of vision.

Diagnosis.—In typical cases the appearance of the background of the eye, even without a knowledge of the history of the case, is sufficient to establish the diagnosis; but a history of the case, together with the results of an examination of the blood, will enable the surgeon to make the diagnosis with certainty.

Prognosis.—Pernicious anemia is a disease that is seldom recovered from. The retina may show but little change for years, but with the advance of the anemia the affection of the retina becomes more profound and visual disturbance more pronounced. As a rule, some degree of vision remains to the end.

Treatment.—The treatment, is of course, that directed toward the general condition.

Purpura Hemorrhagica.—Retinal hemorrhages occur in purpura hemorrhagica, but in what percentage of cases is not known, as sufficient ophthalmoscopic examinations are wanting. The hemorrhages are principally in the nerve-fiber layer and are at and in the vicinity of the disk.

Acquired Anomalies of the Retinal Blood-vessels; Preretinal Blood-vessels.—It is not unusual to see blood-vessels that spring from the primordial retinal vessels passing forward into the vitreous in newly formed connective-tissue structure, the result of hemorrhages. In retinitis proliferans they are frequently present (see page 458). They have also been observed in inflammatory processes, as in chorioretinitis circumscripta[1] and in syphilitic retinitis.[2] In one case of chronic glaucoma observed by the writer a cluster of minute vessels springing from the temporal side of the disk projected into the vitreous, a distance of about two millimeters, where they broke up into vascular tufts which swayed slightly on movement of the eye. A delicate film was present in the vitreous at this point. The retinal blood-vessels presented evidences of arterial sclerosis.

Pre-retinal vessels occur in old people as a result of arteriosclerosis. When they occur in the young, syphilis, retinitis proliferans, and injury are the causes with very few exceptions.

Aneurism of the Retinal Vessels.—The simple form of aneurism has been occasionally observed. Sous[3] was the first to describe it. An arterial branch at the disk was involved. The tumor was ovoid, dark red in color, and pulsated. A second class are the miliary aneurisms, but few cases are reported. These consist in dilatations of numerous small arterioles, and in the cases reported have accompanied atheroma of the arteries, contused injury to the eye, and general paresis.[4]

Two other rare forms of aneurism have been described, multiple anastomosing miliary aneurism and arteriovenous aneurism.

Perivasculitis Retinæ.—The term is applied indiscriminately to any condition of the retinal vessels which shows white borders to the vessels, but it is properly applied only to those cases in which the perivascular

[1] Krause, Centralbl. f. prak. Augenheilk., v, p. 48.
[2] Nettleship, Trans. Ophth. Soc. U. K., 1884, p. 15.
[3] Ann. d'oculistique, 1865, iii, p. 241.
[4] Litten, Berlin. klin. Woch., 1881.

lymph spaces are distended and occupied either by exudation or by small cells or by both, the caliber of the vessel being but little interfered with. In all cases of edema of the retina pearl white borders to the arteries and frequently to the veins at and near the disk may be seen, the perivascular spaces being distended. While it is generally a symptom accompanying some inflammatory disease of the retina or nerve, it may have the appearance of a more or less distinct disease.

Cases have been described by Nagel,[1] de Wecker[2] and others in which relatively wide white borders were present on the larger arteries and veins, and in some of the cases the smaller branches appeared like white threads. Some cases have been reported in which the larger arteries were entirely white. While some of the vessels may be affected less than the others, the condition is usually quite uniform in the individual vessels. The impairment of vision is very slight. The condition in the very marked cases is apt to continue for a long period of time. In edema of the perivascular space which accompanies acute inflammatory conditions, the so-called perivasculitis usually disappears on the subsidence of the inflammatory process.

Treatment.—In the common form of perivasculitis the treatment consists in correcting the condition upon which the perivasculitis depends. In the pronounced cases in which the perivasculitis appears to be the principal disturbance, it has been found that the iodides and mercury in moderate, long-continued dose give good results.

Arterial Sclerosis of the Retinal Vessels (*Endarteritis Deformans; Arteriocapillary Fibrosis*).—**Etiology.**—The conditions present in the aged favor degeneration of the walls of the blood-vessels, but exciting causes determine the changes. Syphilis, gout, rheumatism, and acute nephritis are the affections that most frequently induce arteriosclerosis. Overfeeding, drinking, and excessive prolonged muscular exertion are etiological factors. Interstitial nephritis is undoubtedly a contributing cause, but the nephritis itself is often secondary and due to the primary general arteriosclerosis. The changes in the walls of the blood-vessels of the retina may be apparent before there is any discoverable evidence of pathological changes in the kidneys.

Pathology.—Although all of the coats of the vessels are involved to a greater or less degree, the intima is the most affected. The first stage is that of cellular infiltration, which greatly increases the thickness of the intima. The new-formed cells may develop into connective tissue. All of the cellular elements, except the endothelial cells, may undergo hyaline degeneration. A cellular infiltration of the muscular coat may occur with subsequent hyaline degeneration. The adventitia is least affected, but does not entirely escape. The hyaline degeneration which not infrequently causes obliteration of the capillaries can be studied advantageously in the choriocapillaris of the chorioid. Nodular thickenings produced by foci of granular detritus in which minute fat globules, cholesterin crystals, and lime salts are found within the lamina

[1] Klin. Monatsbl. f. Augenheilk., 1864, S. 394.

[2] Etudes Ophtalmiques, tome ii, p. 224 *b*.

PLATE XX

Retinal Hemorrhages, Arteriosclerosis, Venous Obliteration.

elastica of the intima, are met with in the advanced stage. The inner surface of these patches may become roughened by partial loss of endothelial cells and thrombi may form. The portion of the contents of the vessels which escapes into the retinal tissue may or may not contain the corpuscular elements (hemorrhages, exudation); both coagulate. Hemorrhages may occur in any of the layers of the retina to which retinal vessels penetrate, and may pass beyond these limits. It is not very unusual to find blood in the layer of rods and cones. Rarely it breaks through the membrana limitans interna and invades the vitreous. The exudations are chiefly confined to the inner layers of the retina. A narrowing of the lumen of the vessel in some part of its course, at least, occurs in all cases, and complete obstruction is not infrequent. It is almost always an affection of advanced years, a manifestation of systemic vascular changes of a similar nature, usually an evidence of senility. The veins as well as the arteries are sometime affected. Both eyes are always involved. In 35 cases of general arteriosclerosis, Raehlmann[1] found a similar condition of the retinal blood-vessels in twenty.

Symptoms.—Arterial sclerosis is manifest by the appearance of very delicate white lines at the borders of the arteries in the greater number of cases. The veins may present the white lines, but to a less degree than the arteries. As a rule, the white lines are most pronounced in the larger trunks, namely, at and near the optic disk. However, since arterial sclerosis does not always affect the vessel walls uniformly, it may occur that the white lines are present only in some isolated branches or in one or more of the main branches. The affected arteries and veins become tortuous to some extent. With the appearance of the white lines the smaller vessels lose their transparency. This is particularly the case at the points where branches are given off, the blood-stream frequently being almost hidden. Underlying markings in the retina and chorioid are not so clearly seen as when the vessel walls are normal. When the vessel walls are thickened and consequently rigid, veins over which such arteries pass present the suggestion of an ampulliform dilatation on the distal side because of the obstruction to the venous flow; venous pulsation may be observed at these points. Arterial sclerosis may affect the walls of the vessels fairly uniformly (*arteriosclerosis diffusa*), but frequently it is not uniform, and in many cases it is quite irregular (*arteriosclerosis nodosa*).

In all cases there is narrowing of the lumen of the affected portion of the vessel except when aneurism develops, a condition in marked contrast to that observed in perivasculitis. As the disease advances, the lumen of the affected vessel is narrowed more and more. Complete obliteration may take place; the conditions and symptoms that accompany obstruction to the arterial circulation, namely, venous stasis from a loss of the *vis a tergo*, retinal edema, transudation of blood from capillaries and veins, develop. Hemorrhage and exudation increased

[1] Deutsch. med. Woch., 1888, No. 28.

by the high arterial tension, a constant accompaniment of general arterial sclerosis, take place from diseased arterial branches. Obliteration of the lumen and the conversion of many of the arteries into white lines which eventually become slightly smaller than the normal arteries, and the almost complete disappearance of the unaffected veins are observed. The optic disk presents the appearance of atrophy, the margins being often slightly obscured. In some cases arteriosclerosis affects the vessels at and about the macula most profoundly, under which circumstances the small macular hemorrhages and exudations not infrequently seen in the aged develop.

With the obliteration of the arteries, vision is entirely lost throughout the area affected. Sudden blindness through the formation of a thrombus may occur and may affect both eyes. The defects in the visual field may be of the most varied nature, consisting of concentric limitation, sector-like defects, isolated scotomata. In some of the cases, as anemia advances, torpidity of the retina develops and vision is very imperfect except by bright illumination.

Treatment.—It is of much importance to recognize arterial sclerosis at an early date in order that measures may be taken to retard its advance. The diet should be carefully regulated, excesses of all kinds should be avoided, severe physical tasks and anything that might increase arterial tension should also be avoided. Examinations of the blood and urine should be made from time to time, and any irregularity which such examinations may disclose should be corrected. Diseases that may stand in a causative relation should be combated with appropriate remedies. In a general sense, remedies that decrease blood-pressure, as nitroglycerin and nitrate of soda, may be employed. Also remedies that promote absorption of exudate and blood-clots, as the iodides and mercury.

Atrophy of Retinal Blood-vessels.—This is characterized by a uniform diminution of the size of the vessel, with partial or complete obliteration of the lumen. Retinitis pigmentosa and simple optic-nerve atrophy of the hereditary type present conditions that approach the nearest to primary atrophy of retinal arteries, but in these conditions the affection of the vessels is probably secondary. Atrophy of the vessels follows plugging of the central artery, primary optic-nerve atrophy, and injury causing destruction of the nerve immediately back of the globe.

Hemorrhagic Retinitis (*Retinal Apoplexy*).—Hemorrhage into the retina accompanies many forms of retinal disease, and in the majority of cases is a symptom of disease conditions that can be properly classified. It sometimes occurs that hemorrhage is the predominating feature, and when this is the case the term hemorrhagic retinitis is often employed. In a typical case numerous hemorrhages are scattered throughout the retina. Those that occur in the nerve-fiber layer are flame-shaped, as they follow the course of the nerve fibers. Those in the deeper layers are circular or oval. Those occurring between retina and vitreous or in the layer of rods and cones between the membrana limitans externa

and the pigment layer may present the shape of a shallow U from gravitation. The hemorrhages may be very numerous, covering a greater part of the entire fundus, or they may be few in number and confined to certain areas. They are usually accompanied by more or less haziness of the retina; in severe cases the optic papilla is swollen. Glaucoma may follow hemorrhage into the retina. Schweiger observed it ten times in 450 cases of retinal hemorrhage.

Etiology.—The causes are very numerous and may be divided into (1) obstructive, (2) toxic, (3) traumatic.

To the first belong embolism; thrombosis, arterial and venous; arteriosclerosis, phlebitis of retinal veins, cicatricial processes affecting the retina, as retinitis striata, retinitis proliferans, glaucoma, neoplasms.

To the second belong albuminuria, pernicious anemia,[1] tapeworm anemia, malaria,[2] purpura, scurvy, intestinal toxemia, after extensive burns,[3] diabetes.

To the third, blows of various kinds on the eyeball or on the head adjacent to the eye.

There are cases of hemorrhagic retinitis, as those occurring in individuals at adolescence. Also accompanying menstruation[4] (vicarious menstruation), the cause of which is obscure.

Symptoms.—Hemorrhages from arteries are bright red in color, from veins much darker. As the hemorrhage becomes absorbed, it becomes darker in color. The retina adjoining may be stained a yellowish tone from the spread of blood pigment. Every trace of the hemorrhage may vanish or a white patch may remain.

The absorption of escaped blood progresses rapidly in the young, especially if the tension of the eyeball is not increased above the normal, requiring from one to six weeks. In the aged, absorption progresses very slowly.

Treatment.—The cause should be ascertained, if possible, and appropriate treatment for its removal instituted. In addition to the remedies administered directed to the specific cause, general tonic remedies are indicated. The diet should be carefully regulated and the excretory functions of the body should be rendered active if they are not already so.

Albuminuric Retinitis.—This is characterized by the occurrence of white patches of exudation in the retina, either diffuse (occurring in the nerve-fiber layer) or well-defined, often arranged in a stellate form about the fovea centralis (in the deep layers of the retina) and by hemorrhages occurring on the disk and in the retina.

Albuminuric retinitis may be conveniently divided into two great classes, namely, (1) those cases *not preceded* by thickening of vessel walls,

[1] Mackenzie (Ophth. Soc. Great Britain, p. 132) reported six cases of retinal hemorrhage associated with anemia, and concludes that "when the corpuscular richness falls below 50 per cent., or below one-half the normal quantity, the tendency to hemorrhage is developed.

[2] Bruns, N. Y. Med. Jour., July, 14, 1888.

[3] Wagenmann, Graefe's Archiv, xxxiv, 2, p. 181

[4] Cohn, Uterus und Auge, 1890, p. 110; Fridenberg, P., Trans. Amer. Ophth. Soc., x, 116.

and (2) those cases in which the hemorrhage and exudation are *preceded* by changes in the walls of the vessels (arteriosclerosis).

If we exclude the retinitis of pregnancy, males are affected much more frequently than females, the proportion being about 2 to 1.[1]

All of the cases occurring as a result of acute parenchymatous nephritis belong in the first class. They occur as a result of the albuminuria of pregnancy, scarlet fever, diphtheria, mumps, exposure, and all forms of acute nephritis accompanied by general anasarca. The changes in the kidneys precede those that occur in the retina.

In the second class are those cases accompanying chronic interstitial nephritis. The retinal manifestations are the result of a general arteriosclerosis. The changes in the retina may precede the appearance of albumin in the urine.

Transient blindness sometimes accompanies uremia without fundus changes. This is a toxic amblyopia and is central in origin.

It is remarkable that in a disturbance of the retina so profound there is almost no small-cell infiltration or manifestation that accompanies true inflammation. The phenomena are those due to transudation, a leakage from weakened vessels.

Hypertrophy of the left ventricle of the heart, with increased arterial tension, is a condition accompanying all cases of chronic interstitial nephritis. This condition also occurs to some degree in the albuminuria of pregnancy.

Pathology.—A general edematous condition of the nerve-fiber, the nuclear, and the anterior reticular layers exists in all cases in which the retinitis is marked, the edema being most pronounced near the disk, gradually diminishing toward the ora serrata. The entire thickness of the retina is edematous in severe cases. A number of cases have been observed in which almost total detachment of the retina has taken place within a very few hours. In these cases shrinkage of the vitreous body must have preceded the detachment. Aside from the escape of serum from the vessels, the plasma of the blood escapes, coagulates, and forms the white patches. The appearance of the patch seems to depend on coagulation of albuminous plastic lymph and not on the presence of fat. Corpuscular elements may or may not be present in the *white plaques*. When fresh, the white plaques, whether in the nerve-fiber layer or deeper in the retina, consist of a network of fibrin fibrils interlaced. As the patch grows old the fibrin contracts. Fatty changes may occur and, rarely, rosettes of fat crystals may form. The masses of fibrinous exudation may be found in the nerve-fiber layer. A few white and red blood corpuscles may be present in the masses of fibrin.

Dimmer[2] and others attribute the stellate arrangement of the white plaques at the macula as being due to the radiating arrangement of the cone fibers in the outer nuclear and reticular layers. Koppen[3] attributes

[1] Nettleship, R. L. Ophth. Hosp. Reports, xv, 327.
[2] Präger med. Woch., 1894, No. 42.
[3] Zeitschr. f. Augenheilk., December, 1902.

the arrangement to the disposition of the capillaries and other minute blood-vessels at the macula, which penetrate to the outer reticular layer and converge toward the fovea centralis, but never encroach upon it. The changes in the walls of the vessels often affect these at an early stage and transudation of the plasma of the blood from these radiating vessels occurs. The researches of the writer lead him to believe that the explanation of Koppen is the correct one, particularly since the radiations of the cone fibers do not extend beyond the macula lutea, while the rays of the stellate figure extend much farther.

Fig. 225

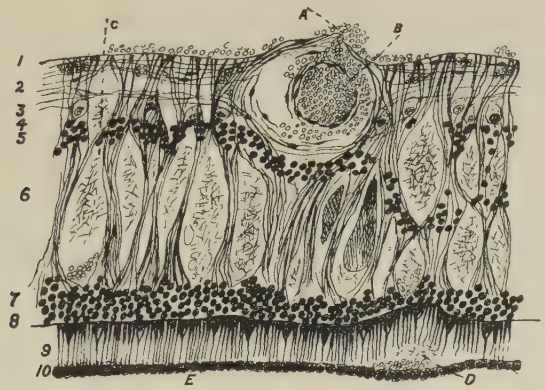

Retinal changes in albuminuric retinitis: 1 to 10, the various layers of the retina; *A*, escape of blood into the vitreous chamber; *B*, rupture in the wall of a vein; *C*, exudation into retinal tissue; *D*, hemorrhage into layer of rods and cones; *E*, pigment layer of retina.

The hemorrhages present nothing unusual. When fresh, the corpuscles are well formed; when old, disintegration of white and red blood-corpuscles takes place, and there may be much granular detritus mixed with cells that are more or less perfect..

Nerve Fibers.—These are swollen, often varicose. Occasionally small nodules are observed in the nerve-fiber layer, which appear to consist of degenerated ganglion cells. The cells are irregularly circular and appear to possess one or two processes. They are found among the approximately normal nerve fibers. A well-defined cell body and nucleus are present, but no nucleolus. What corresponds to the portoplasmic body is granular (reticular), and so is the nucleus. The nucleus stains very slightly darker than the protoplasm, possibly not quite so dark as the nucleus of the cells of the ganglion layer. The growth is always confined to the nerve-fiber layer. It may occur on the papilla. Some difference of opinion has been expressed regarding the nature of these cell-like bodies. Virchow[1] described them as sclerosed ganglion cells; Müller,[2] changes in the nerve fibers themselves, and Greeff[3] regards them as greatly swollen mononuclear leukocytes, the

[1] Virchow's Arch., Band x, S. 171.
[2] Graefe's Arch., Band iv, 2, S. 42.
[3] Orths, Lehrbuch. d. Path. Anat., x, S. 364.

form, which is often quite elongated, being due to pressure. The writer who described this condition[1] as ganglionic neuroma of the retina is now of the opinion that the view of Greeff is correct, in so far as the condition is due to enlargement of a group of adventitious cells. This condition was thought by Müller to be characteristic of albuminuric retinitis, but a similar condition has been observed in other forms of retinitis (traumatic and septic retinitis in severe anemias and papillitis, Parsons).

Ganglion-cell Layer.—Except in the older cases of albuminuric retinitis in which decided interference with the circulation has taken place there is no evidence of actual degeneration in the ganglion nerve cells, but in all cases in which edema is marked the ganglion cells become much enlarged, apparently from imbibition. If the nutrition is interfered with the ganglion cells degenerate and disappear.

Inner Reticular, Inner Nuclear, Outer Reticular, and Outer Nuclear Layers.—Aside from edema and the occurrence of spaces in which are found coagulated masses, either with or without red and white corpuscles, but little change is noted in these layers, except in advanced cases in which the nutrition has become seriously impaired. In these cases degenerative changes, leading to atrophy and accompanied by the formation of fat globules to a greater or less degree, occur.

Rods and Cones.—Degeneration of these elements takes place only when the nutrition is interfered with, when a fatty and granular degeneration causes them to disappear, portions of the inner members disappearing last. Serum, plastic exudation, and hemorrhages are not infrequently found between the membrana limitans externa and the pigment-cell layer.

Pigment-cell Layer.—The pigment-cell layer undergoes but little change. In some cases of long-standing, hyperplasia of the cells of the retinal pigment layer may occur.[2]

Müller's Fibers.—These are much elongated near the disk, often swollen, and sometimes undergo degeneration with the formation of minute fat globules.

Optic Disk.—The tissues of the disk are edematous. Hemorrhages, plastic exudation, and nodules composed of bodies resembling ganglion cells may occur in the tissues of the disk. In old cases, new-formed capillaries and small blood-vessels may be present.

Blood-vessels.—The perivascular spaces are distended by serum, fibrinous exudation, or by blood corpuscles in almost all cases. In the retinitis of acute parenchymatous nephritis no structural change in the walls of the vessels can be detected except in the parts where hemorrhages occur where a small break in the wall of a venule may be demonstrated. In the cases of retinitis accompanying interstitial nephritis and in the cases in which parenchymatous nephritis passes over into chronic interstitial nephritis with retinitis, changes of the most varying

[1] New York Eye and Ear Infirmary Reports, 1902.
[2] Weeks, Arch. of Ophth., 1888, xvii, No. 3.

degree take place in the walls of the arteries, capillaries, and veins. The chief change is in the intima of the vessels, and consists in a hyaline thickening at the expense of the lumen of the vessel. This does not appear to involve any increase of the endothelium. In the vessels in which this change is far advanced, the endothelial cells may be found crowded together in the axis of the vessel. The media of the vessel wall may be involved to some extent. In old cases foci of deposits of lime may be found in the thickened walls. This change affects arteries and capillaries most, but may also affect the veins. So constant are these changes in retinitis accompanying chronic interstitial nephritis that Michel regards all of the retinal changes to be due primarily to obstruction of the retinal circulation brought about by a primary arterio-capillaro-phlebosclerosis.

It is not unusual to find small new-formed blood-vessels in the retina at or near the disk.

Fig. 226

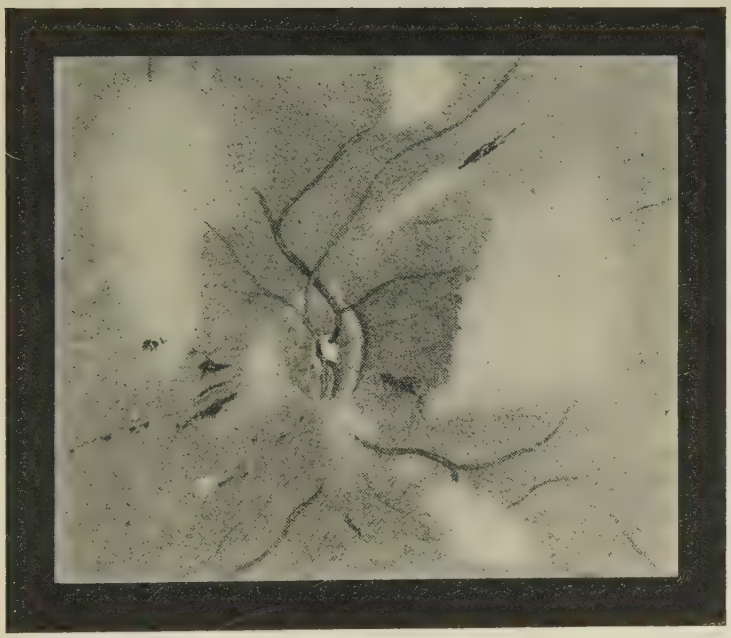

Albuminuric retinitis in a case of acute nephritis, showing areas of soft-edged, edematous-looking exudation into the retina, with hemorrhages. (Posey and Wright.)

The vascular changes affect the vessels of the chorioid, ciliary body and iris, as well as those of the retina. It is not uncommon to find complete obliteration of many of the capillaries of the choriocapillaris.

Symptoms.—The retinitis accompanying parenchymatous nephritis and the retinitis accompanying chronic diffuse nephritis differ somewhat in appearance and in prognosis. The first may be regarded as a *toxemic*

retinitis, as the exudation and hemorrhages that occur are not the result of obstruction in the vessels, but of a weakening of their walls by the presence of poisonous substances in the blood. The ophthalmoscopic examination discloses the presence of white patches in the retina, some of which are sharply defined, often arranged radially from the fovea centralis, partly surrounding, but not encroaching upon it; the sharply defined patches are small. Patches not very well-defined occurring in other parts of the retina may be larger, approaching the size of the disk. While in the vicinity of the macula the white patches are grouped together, in other parts of the retina they may be widely scattered. The sharply defined white patches are located in the deep layers of the retina. Diffuse white patches occur chiefly near the disk and along the course of the larger vessels. They are flame-shaped fusiform or in irregular patches. These

Fig. 227

Albuminuric retinitis. Granular kidney. Note hard-edged "asterisk" exudation at *y s*, the silver-wire condition of the arteries, and the punctate and linear hemorrhages. (Posey and Wright.)

are situated in the nerve-fiber layer and partly or completely hide the vessels that may pass through them. Edema of the retina is apparent at the margin and in the vicinity of the disk, giving a grayish striated appearance to the parts of the retina where the nerve-fiber layer is thickest. The margins of the disk are obscured principally by the edema. The blood-vessels are only slightly altered in size, the veins overfull and slightly tortuous, the arteries almost unchanged. Hemorrhages are not so numerous in this form, but they occur in the greater number of cases.

The hemorrhages take place from the capillaries and veins almost exclusively.

The type of the second form presents more hemorrhages than the first. The earliest manifestations may be a few small hemorrhages located at the macula or near the disk. Since, in addition to the presence of deleterious substances in the blood due to insufficient elimination through the kidneys, there is disease of the walls of the retinal vessels, hemorrhages may occur from arteries, veins, or capillaries. The patches of white exudation are not, as a rule, so numerous as in the first variety, but have much the same arrangement. Evidence of disease of the vessel walls may be obtained by use of the ophthalmoscope. The lumen of the vessels is not uniform, and white lines accompany the arteries especially. The appearance of a very marked neuroretinitis is much more apt to occur in this variety than in the former.

Diagnosis.—Without confirmatory evidence it is not possible to determine from the appearance of the retina alone that a case is one of albuminuric retinitis. The appearance of the retina is not always typical, and it is possible to have a picture closely resembling albuminuric retinitis due to other causes. Neuroretinitis accompanying cerebral lesions, due to diabetes, to syphilis, and obstructive lesions of the retinal arteries, may present a picture closely resembling albuminuric retinitis, the star-shaped figure at the macula, more or less perfect, being present. It is, therefore, wise to obtain the history of the patient and to examine the urine before giving a positive opinion regarding the character of the retinitis in any case.

Retinitis circinata may be mistaken for albuminuric retinitis in its very early stage, but the greater size of the white patches, their raised character, and their arrangement around the macula will suffice to make the diagnosis. Opaque nerve fibers present irregular, flame-shaped patches, which may resemble the diffuse patches of albuminuric retinitis. The retinitis of pernicious anemia and syphilitic retinitis may resemble albuminuric retinitis very closely.

Atrophic chorioidal patches are distinguishable by their pigmented borders. The small, light colored patches that occur in the region of the macula because of changes in the membrana vitrea of the chorioid (guttata chorioiditis of Gunn) may be distinguished from retinitis albuminurica by their yellowish color, circular shape, and non-interference with vision.

Effect on Vision.—In the cases accompanying parenchymatous nephritis, marked changes may be present in the retina with but little impairment of vision, or the vision may be greatly reduced and eventually entirely lost. Rarely the subsequent picture is that of complete atrophy of the optic nerve. In the greater number of cases the field of vision is not diminished in extent, but there is impairment in the central portion of the field. In the milder cases, with recovery from nephritis, the exudation in the retina becomes absorbed and vision is restored almost, if not quite, to the normal. In the type of albuminuric retinitis with arteriosclerosis the effect on vision may not be great in the early stage of the affection, but scotomata of all varieties of form may develop as a result of sectional interference with the retinal circulation, due to obliteration

of the lumen of the vessels. Complete blindness is not common; the patient usually succumbs before this point is reached. Retinal changes have been observed in cyclic albuminuria.[1]

Albuminuria in Pregnancy.—If retinitis develops as a result of albuminuria in pregnancy, it indicates a grave condition of the patient and the probability of eclampsia. The time of the onset of retinitis in relation to the pregnancy and the severity of the retinitis are factors that determine treatment. This raises the question as to the advisability of the induction of premature labor in cases of albuminuria in pregnancy. The induction of premature labor in these cases has a twofold object—first, the saving of the life of the patient, and second, the preservation of vision. Ahlstrom[2] and others report cases of complete blindness following the albuminuria of pregnancy in cases in which premature labor was induced, also in cases in which it was not induced, but experience has proved that the condition of the retina and of the kidneys is favorably influenced if pregnancy is terminated soon after the appearance of the retinitis, and that in many cases complete restoration of vision and recovery from the disease of the kidneys result. The following rules may be observed:

1. If albumin appears in the urine of a pregnant woman, the eyes should be examined from time to time with a view to determining the condition of the retina.

2. If retinitis occurs before the end of the sixth month, premature labor should be induced. If it does not occur until the eighth month, an attempt to tide the patient over to full term should be made.

3. The appearance of the retinitis between the sixth and the eighth month indicates the induction of premature labor only if the vision is impaired (to prevent blindness) or if the amount of albumin excreted is large and the quantity of urea excreted is small.

It is a well-known fact that chronic interstitial nephritis may follow the nephritis of pregnancy, and it is fair to assume that the more severe the nephritis accompanying pregnancy, the greater the probability of subsequent chronic nephritis.

Albuminuric retinitis may occur at any pregnancy; it may recur at subsequent pregnancies, but seldom does. The mortality after albuminuric retinitis in pregnancy is less than after any other form of nephritis. Nettleship[3] records 22 cases of retinitis during pregnancy, of which he knew but one that died within two years. Some of the cases were lost sight of, but two-fifths of the number were known to have lived more than two years.

The cases of albuminuric retinitis occurring after the acute exanthematous fevers give a less favorable prognosis. Many of the cases pass into chronic interstitial nephritis. Of the cases of albuminuric retinitis occurring with interstitial nephritis, nearly all die within two years, and one-half die within the first year. Of 103 cases analyzed by Bull,[4]

[1] Ostwalt, Wiener klin. Rundschau, 1897, No. 41.
[2] Hygiea, Stockholm, lxv, No. 8. [3] Royal Lond. Ophth. Hosp. Reports, xv, p. 320.
[4] Trans. American Ophthalmological Society, 1886.

the death of 86 was recorded; 57 of these died within the first year, 18 within the second, and the others before the end of the sixth year. Hahnle[1] found that death occurred in 82 per cent. of the cases, within two years.

Complications.—Detachment of the retina sometimes occurs in cases in which the edema is excessive. This takes place in the cases of parenchymatous nephritis accompanied by marked general anasarca.

Secondary glaucoma occurs in cases in which retinal hemorrhage is excessive. Iritis may complicate albuminuric retinitis, but is not common.

Fig. 228

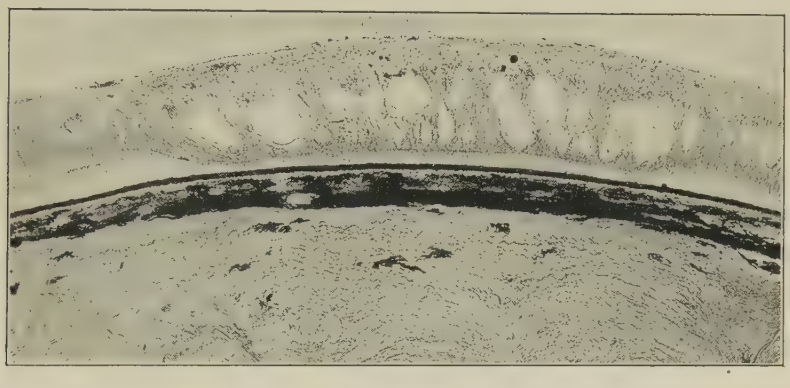

Changes occurring in the retina in albuminuric retinitis. (Photo by Dixon.)

Treatment.—Local measures are of no avail except perhaps when complications arise. These must be met as seems most advisable. The retinitis, if influenced at all, must be reached by treatment of the condition to which it is due, attention to diet, proper regulation of habits, etc. If arterial tension is high, glionin may be of value. In moderate dose it may be given a long period of time with benefit. Mercury and iron are often of service. The biniodide of mercury in $\frac{1}{30}$ to $\frac{1}{15}$ grain dose, t. i. d., and some form of iron that can be assimilated and will not constipate, in moderate, long-continued dose, will often be found to be beneficial.

Diabetic Retinitis.—A form of retinitis peculiar to diabetes mellitus is recognized by many writers. It is a very rare affection, so much so that its existence is questioned by some ophthalmologists. The retinal disease occurs in the later stages of diabetes. Both eyes are affected. There are two forms of retinitis which are fairly characteristic of diabetes, although albuminuria may complicate the cases in which these forms appear. The first is one characterized by the appearance of numerous small white or yellowish-white deposits in the retina in the vicinity of the posterior pole, irregular in shape, sometimes assuming irregular

[1] Inaug. Dissert., Tübingen, 1897.

groupings, but not forming the stellate figure of albuminuric retinitis. The white patches seldom attain to one-half the size of the optic disk. Small punctate or elongated hemorrhages occur on the margin of or between the white spots. The hemorrhages often extend farther toward the periphery of the retina than do the white spots. There is seldom any appreciable change in the appearance of the optic disk or in the large vessels, except in old cases in which the disk may present the appearance of mild neuritis and the veins become somewhat tortuous. This form is classed by Hirschberg as *retinitis centralis punctata diabetica.*

The second form, which is somewhat characteristic, presents large, irregular white patches, not very numerous, which are most plentiful near the posterior pole, but may extend well toward the periphery of the retina. In this form the hemorrhages are frequently larger than in

Fig. 229

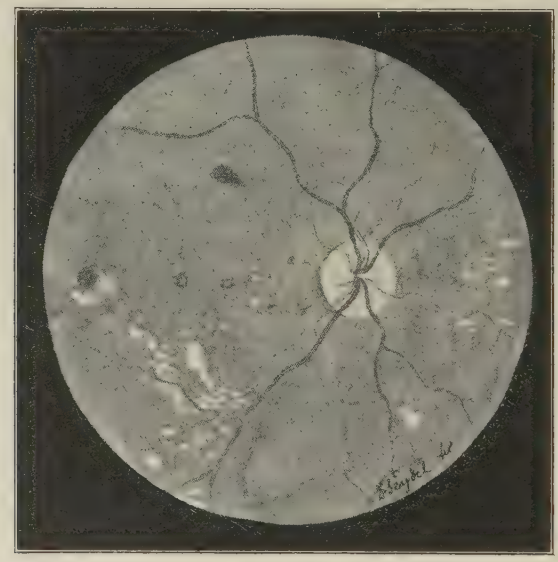

Diabetic retinitis. (Graefe and Saemisch.)

the preceding form. They occur frequently in the nerve-fiber layer, and sometimes break through into the vitreous body. Tortuosity of the retinal vessels and papillitis in a mild form are probably more frequent in cases of this general type than in those corresponding with the first type.

Mild cases of retinitis occurring with diabetes may show only white spots—*punctate diabetic retinitis.* Some cases present hemorrhages almost exclusively—*hemorrhagic diabetic retinitis.* The white spots in diabetic retinitis have little tendency to coalesce.

Many mixed forms of retinitis, not in any way characteristic, have been observed in diabetes, especially in those patients who have

albuminuria as well as glycosuria, the retinitis being influenced by both conditions. Retinitis pigmentosa in connection with diabetes has been observed by Hirschberg.

As *complications*, may be mentioned hemorrhage and opacities, circumscribed and diffuse, in the vitreous. These occurred in 7 of the 47 cases compiled by Dodd.[1]

Secondary glaucoma occurs in cases of marked retinal hemorrhage, and atrophy of the optic nerve may develop as a late complication of the condition, not preceded by a visible neuritis.

Pathology.—The number of microscopic examinations of retinæ showing diabetic retinitis, recorded, is only four or five. Nettleship[2] reports two, Michel[3] one, and Galezowski[4] one. None have been reported recently. The changes that take place in the retina affect the blood-vessels principally, the arteries and capillaries in particular, and consist in a fibrohyaline thickening of the intima, which causes partial or complete occlusion of some of the capillaries and also of the smaller arteries. Capillary aneurisms were observed in the two cases reported by Nettleship, the aneurism, which was always spherical, being due to a distention of the wall of a capillary as a consequence of occlusion, partial or complete. The minute character of the hemorrhages was attributable to the fact that the escape of blood was principally from the capillaries. The white spots are not well described in any of the reports.

Nettleship describes small round spaces in the intergranular (reticular) and molecular (nuclear) layers filled with faintly refracting globules.

Edema of the anterior layers of the retina and varicose swellings of the nerve fibers have been described.

Changes in the blood-vessels of a nature similar to those in the retina take place in various parts of the body. They have been studied in brain tissue, in the kidneys, liver, and other parts. They resemble the changes found with chronic interstitial nephritis, but since they differ somewhat, are, in all probability, due to a toxic substance of a slightly different character circulating in the blood. The blood-vessels of the chorioid, ciliary body, and iris are also involved.

Subjective Symptoms and Effect on Vision.—These are very slight in cases in which the hemorrhages are not large and numerous. When opacities in the vitreous occur, when the hemorrhages are large, and when atrophy of the optic nerve occurs, the vision is, of course, greatly reduced. Flickering is often noticed in the early stage of the retinitis, due to disturbance of the perceptive elements of the retina by the exudation and hemorrhages. Photopsia, metamorphopsia, and chromopsia develop from the same cause. Reading may be rendered difficult even before gross changes in the retina are discoverable.

Diagnosis.—The typical form of diabetic retinitis presents but little difficulty in diagnosis with the ophthalmoscope, but the ophthalmoscopic

[1] Arch. f. Ophth., xxiv, No. 3, p. 206.
[2] Trans. Ophth. Soc. U. K., 1882, 1886.
[3] Deutsch. Arch. f. klin. Med., 1876.
[4] Ann. d'oculistique 1863.

findings should always be supplemented by repeated examinations of the urine. If sugar and albumin are found in the urine, the retinitis must be considered as being due to both.

Retinitis punctata albescens differs from the retinitis in diabetes by the regularity in size of the spots, difference in color (the former being of a yellowish hue), in being more widely distributed, and in lying beneath the blood-vessels. Chorioretinitis is accompanied by pigment changes which do not occur in diabetic retinitis.

Prognosis.—Diabetic retinitis appears after diabetes has lasted for a long time. It indicates changes in the walls of the blood-vessels from which recovery cannot be expected. The affection may remain virtually stationary for a long time, and in favorable cases the vascular changes may become arrested and the exudation and small hemorrhages may disappear in part and good vision be preserved for some years, but relapses occur and, although diabetic retinitis seldom causes complete blindness except in those cases in which acute glaucoma or atrophy of the optic nerve develops, the vision may be greatly diminished without much limitation of the field of vision.

Treatment.—Remedies employed locally are, of course, of no benefit. The condition of the retina can only be influenced favorably by treatment of the general condition. The very moderate use of the eyes should be enjoined, and, if bright light is annoying, dark glasses may be worn. It is not necessary to confine the patient to darkened rooms.

Angeioid Streaks in Retina.—A condition characterized by the appearance of narrow, pigmented, branching stripes or lines in the retina beneath the blood-vessels. They may run across any part of the retina, frequently radiate from the optic disk, pursue a generally straight direction, but may be curved, are jagged, and may be accompanied by light streaks. They are about the size of the retinal vessels, but are not of uniform width. They do not correspond with the course of the vessels either of the retina or of the chorioid. The color of the streak may vary from a very dark brown to a light, reddish brown.

Etiology.—No direct connection between these streaks and retinal or chorioidal vessels can be traced. The condition develops most frequently in young adults, but has been observed in the aged. Vision is always impaired, sometimes to a very slight degree, sometimes profoundly.

Both eyes are always affected. The appearance of the stripe is always preceded by retinal hemorrhages. In some of the cases collected by Frost,[1] the transition from hemorrhage to brown streak was observed; also in the cases of de Schweinitz[2] and Holden.[3]

Prognosis.—The condition may remain stationary for years. There may be recurrent retinal hemorrhages with further loss of vision, but complete blindness has not been observed. The condition cannot be confounded with anything else.

Treatment.—Therapeutic measures have not proved to be of any value.

[1] The Fundus Oculi, London, p. 209.
[2] Ophth. Record, July, 1897.
[3] Arch. f. Ophth., 1895, xxiv, p. 147.

Retinitis Striata.—This term was apparently first applied by Nagel, and is now recognized as indicating a condition characterized by narrow, long, glistening, white or yellowish-white bands which often radiate from the disk, but may be independent of the disk, may branch, anastomose, and run in various directions. While often straight, they may curve and may vary much in width. They may be numerous, traversing the entire fundus, or they may be small and few in number. The bands are situated beneath the retinal vessels and apparently in front of the chorioid. Some of the bands may be bordered by a narrow, broken band of pigment, which would seem to sustain Jervey's opinion[1] that the condition has its origin in the chorioid. Very fine striations may be seen in the retina by close examination by good light in some of the cases. Small white dots may be scattered about the fundus, particularly in the vicinity of the macula. The acuity of vision is often much reduced, but the fields of vision for form and color are seldom contracted. The affection is usually monolateral, but cases of bilateral retinitis striata have been reported.

Etiology.—Little is known of the etiology of this affection. The condition is usually fully developed before the patient presents himself to the oculist. Holden[2] is of the opinion that the striations have their origin in retinal hemorrhages, while L. Caspar,[3] Natanson, Praun, Goerlitz, and others believe that they follow detachment of the retina, and that they represent residua of this condition, the striations being situated between retina and chorioid and being formed by coagulated fibrin. Caspar believes that the stripes of coagulated fibrin are transformed into thin bands of connective tissue by proliferation from the chorioid, and terms the condition chorioretinitis striata.

Pathology.—None of the cases have come to section, consequently nothing is known of the pathology.

Course and Prognosis.—The condition occurs between the ages of fifteen and fifty-three. It is often associated with small opacities of the vitreous. In many cases the condition remains unchanged for years. There is seldom any change in the course of the retinal vessels, indicating that the tendency to cicatricial contraction is not great. In a considerable percentage of the cases, detachment of the retina apparently results. Complete blindness seldom occurs.

Diagnosis.—The condition cannot readily be confounded with anything but retinitis proliferans. If it be remembered that in retinitis striata the changes are back of the retinal vessels and in retinitis proliferans in front of the retinal vessels, an error in diagnosis cannot be made.

Treatment.—Treatment is of no avail.

Retinitis Circinata.—This is a rare condition, first described by Hutchinson[4] under the title "Symmetrical, Central Chorioidoretinal Disease Occurring in Senile Persons." The term retinitis circinata was

[1] Ophth. Record, October, 1901.
[2] Arch. of Ophth., xxiv, 153.
[3] Arch. of Ophth., January, 1897, p. 80.
[4] R. L. Ophthal. Hosp. Reports, 1876, viii, p. 23.

applied to the condition by Fuchs,[1] who described the condition very fully. It occurs in old individuals and depends on changes in the blood-vessels.

Pathology.—As yet only one case has been examined microscopically. It is doubtful that this case was typically circinate. Amman, who made the examination, found much fat present in the white patches. From the ophthalmoscopic examination of cases seen by the writer, he is of the opinion that the white plaques are due to the coagulation of fibrinous exudates which occur in the retina beneath the nerve-fiber layer as a

Fig. 230

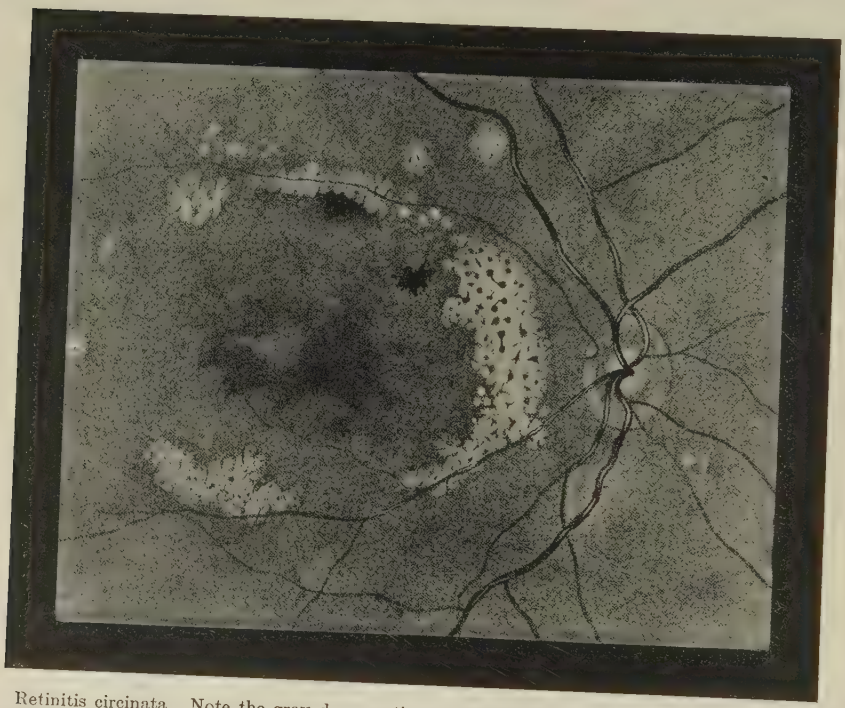

Retinitis circinata. Note the gray degeneration of the retina at the yellow spot, and the white exudation concentric with the yellow spot, having the appearance of Passover bread. (Posey and Wright.)

result of disease of the small vessels in the affected zone. Fatty degeneration may occur to some extent in the plaques, increasing their brilliancy. This view corresponds quite closely with that of Fuchs and Nuel. The spots do not, in all probability, originate from hemorrhages, but hemorrhages and fibrinous exudate are probably dependent on the same condition, namely, degeneration of the walls of the blood-vessels.

Symptoms.—Its principal feature is the appearance of a zone of numerous glistening white spots, which may approximately follow the

[1] Arch. f. Ophth., 1893, Band xxxix.

macular borders of the superior and inferior temporal vessels. The spots coalesce, forming broad, slightly raised, irregular, broken bands with lobulated edges which partly surround the macula. The bands seldom reach the disk. The circle formed is usually, but not always, open at the temporal side. The zone may vary much in width in different parts, and may be quite broken. The larger retinal vessels pass over the patches. Minute branches may be seen passing into them. In very nearly all cases there are changes at the macula, consisting in many instances in a yellowish-white opacification. Often small hemorrhages and slight pigment changes are observed. A zone of varying width of approximately normal retina is often present between the macula and the masses of white spots. Outside the zone of clustered and coalesced white spots there may be some diffuse pale yellow patches, but there is rarely any change of moment. Hemorrhages in the macular region at the margins of and in the white patches have been observed, and Fridenberg has noted the development of new-formed blood-vessels in the retina. As a rule, the spots develop slowly, reaching the maximum in a few weeks or months. Small hemorrhages and more white spots may appear much later. There is no pain. The development is so gradual that it is seldom appreciated by the patient until it is well advanced.

The condition occurs almost exclusively in the aged. In 12 cases reported by Fuchs the ages ranged from thirty-five to seventy-five years, the average being sixty. Of 9 cases observed by the writer the youngest patient was fifty-four years old. Women suffer more frequently than men. The central vision is always reduced, frequently very much so. The field of vision is seldom limited in extent. The affection is unilateral in approximately three-fifths of the cases.

Prognosis.—The affection is essentially chronic in nature. Fuchs observed one case for seven years and found but little change. De Wecker reports a case of twenty years' duration. Some of the cases are slowly progressive. De Schweinitz quotes Schöbl as follows: "In some cases the exudation does not disappear, and gradually the retina becomes enormously thickened. The macular spot and zone of white spots are changed into dirty, yellowish-white, protruding connective-tissue-like masses." Opacities of the vitreous and retinal detachment have been reported.

In approximately 8 per cent. of the cases the white masses of exudate disappear, often leaving a few crystals of cholesterin. Fuchs reports one case in which the white patches disappeared in four years. De Schweinitz[1] writes: "I have seen beginning disintegration of the ring in five months in one case and its complete disappearance in a little more than a year in another." The writer observed the disappearance of the patches in a year in one case. A few cholesterin crystals remained.

The damage sustained in the macular region is not entirely recovered from. The temporal portion of the optic disk becomes atrophic in pro-

[1] Ophthal. Record, Chicago, Feburary, 1903, p. 15.

portion to the loss of central vision. The peripheral vision remains good.

A prognosis of possible loss of vision should not be made in any case of circinate retinitis; nor should a prognosis of an unfavorable outcome be given before efforts to relieve the patient by means of appropriate treatment have been made. The cases are not all hopeless. No definite statement can be made regarding the length of time that will be required for the absorption of the exudate which forms the white patches.

Treatment.—The experience of de Schweinitz, Fuchs, and others, coupled with that of the writer, leads the latter to believe that something may be done by appropriate treatment. The iodides and mercury with iron may serve in some of the cases to cause the white plaques to cease forming, and become absorbed in part or wholly. The medication must be continued for a very long period of time. De Schweinitz suggests subconjunctival saline injections and pilocarpine diaphoresis.

Fig. 231

Fig. 232

Retinitis proliferans.

Hyperplastic Hemorrhagic Retinitis[1] (*Retinitis Proliferans*, Manz).—This affection is characterized by the appearance of white or bluish-white bands or membranes of new-formed connective tissue which spring from the retina and extend into the vitreous, being accompanied in many of the cases by new-formed blood-vessels. The first mention of this condition was probably made by Mackenzie in 1864. Quite exhaustive papers have since been written by Manz,[2] Leber,[3] and others. The writer reported four cases, two of which came to section, together with a resumé of cases already reported, in the *Transactions of the American Ophthalmological Society*, 1897.

The disease is a very rare one. Of 179,057 patients seen by Schöbl, but five patients with this affection were observed. In the writer's private practice of 24,000 patients this condition occurred but twice. Hyperplastic hemorrhagic retinitis may be classified under three heads: (1) idiopathic, (2) syphilitic, (3) traumatic.

[1] In the opinion of the writer, this name, given by Schöbl to the condition described, is the most fully descriptive and appropriate.

[2] Graefe's Arch., xxii, 3, p. 229.

[3] Graefe u. Saemisch, Band v, S. 665.

Etiology.—The fact is now quite generally recognized that the formation of the membranous structures is always preceded by the presence of a fibrinous coagulum, with or without blood corpuscles, extending into the vitreous and resting at some point on the retina, due to leakage from retinal vessels. Disease or injury to the blood-vessels of the retina must antedate the escape of their contents. In idiopathic hyperplastic hemorrhage retinitis the cause is not known.

Of the patients observed by the writer, none were robust, all were rather under size. Although apparently subjects of inherited physical defects, positive stigmata of inherited syphilis were not present. In many of the cases reported by others, mention of the absence of syphilis is made.

In the cases collected by the writer, the ages of the patients ranged from eight to thirty-three years. By this it will be seen that idiopathic hyperplastic hemorrhagic retinitis is a disease of early life. Both eyes are almost invariably affected. The affection occurs in males much more frequently than in females, the proportion being approximately four to one.

Syphilitic hyperplastic hemorrhagic retinitis depends on vasculitis, and may occur in patients with acquired syphilis. Both eyes are usually affected.

Traumatic hyperplastic hemorrhagic retinitis may occur after injury to the eye that results in hemorrhage from the retinal vessels. The injured eye only is affected.

Pathology.—The change in the retina in the idiopathic form is an increase in the connective-tissue elements of the nerve-fiber layer and in the walls of the blood-vessels. In pronounced cases the arteries are reduced in size and in some the lumen is obliterated. The veins are not so much affected as the arteries. The increase in connective tissue affects the muscularis and adventitia, not involving the intima. An apparent elongation of Müller's fibers, resulting in a bulging forward of the membrana limitans interna at points usually near the papilla, occurs. Hyperplasia of the connective-tissue elements of the papilla also takes place where the new-formed membranes are attached to the papilla.

The membrana limitans interna is defective. The connective-tissue fibers continue uninterruptedly from the nerve-fiber layer into the new-formed membrane. If the new-formed membrane is of considerable volume, blood-vessels pass from the retina into it. The walls of the new blood-vessels are quite well formed in the older parts of the membrane, but may consist of a single layer of endothelial cells in the newer parts of the membrane. The growth of the membranes found in the vitreous chamber takes place on the surface of a fibrinous clot. Formative cells appear, some oval, others fusiform, and others possessing a number of processes. These develop into a very thin connective-tissue membrane which becomes reinforced by blood-vessels and increases in thickness. Hemorrhages may, and not infrequently do, occur from the new-formed blood-vessels. In the parts not hyperplastic the retina becomes thinner;

the ganglion cells disappear. Hemorrhages may occur in the retinal tissue. There is but little small-cell infiltration in the retina in idiopathic cases and nothing to indicate an inflammatory process. In syphilitic cases a perivasculitis with small-cell infiltration is present at the onset of the affection.

Cicatricial contraction of the new-formed membranes causes detachment of the retina. The vitreous shrinks; the chorioid is affected by connective-tissue hyperplasia, the vessels, large and small, suffering. The choriocapillaris disappears. The ciliary body and iris are involved in a similar change.

Course and Prognosis.—In all the cases reported, with one exception, both eyes were affected in those not syphilitic or traumatic. The changes may be very slight and the progress of the disease may become arrested, but in almost all of the idiopathic cases the ultimate result is blindness. This is produced most commonly by detachment of the retina.

Secondary glaucoma develops in some of the cases, the eye becoming painful. In the greater number of the cases the eyeball becomes soft and atrophic. Cataract may develop. The prognosis is, as a rule, unfavorable.

Treatment.—The iodides of sodium and potassium, mercury and iron appear to be of some value, but it is probable that they are capable of arresting the progress of the disease only in the cases in which syphilis is the cause. Many of the idiopathic cases go on to the destruction of vision in spite of all remedies.

Retinitis Pigmentosa.—Retinitis pigmentosa is characterized by the appearance in the retina of stellate (bone corpuscle) pigment patches which are not very large, are scattered over the fundus, often accompany the blood-vessels, and are most numerous in the equatorial region. The retinal blood-vessels are reduced in size, there are concentric narrowing of the field of vision and night blindness.

Atypical Forms.—In a very few cases the formation of the pigment patches occurs at the posterior part of the fundus exclusively (retinitis pigmentosa centralis). In such cases the central vision is abolished, the periphery of the field of vision remaining intact. In rare cases the pigment patches are general over the entire fundus. Sometimes the patches are large and irregular. At times the pigmentation is accompanied by the appearance of small, round, light-colored spots deep in the retinal tissue. These are, as a rule, more numerous at and in the vicinity of the yellow spot. Certain other cases present the appearance and symptoms of gradual atrophy of the retina without pigmentation. A few cases are on record of a zone of pigmentation encircling the macula at some distance from it. The cases last mentioned present paracentral, or ring scotomata.

Etiology.—Heredity is at present accorded the first place in the list of causes, the inherited cases following the Mendelian law very closely.[1]

[1] For a full consideration of this phase of the subject, see Nettleship's Bowman lecture, Trans. Ophth. Soc. United Kingdom, 1909.

Consanguinity is next in frequency. Ayres[1] reports 25 cases occurring in 19 families, 18 males and 7 females. The parents were related in 28 per cent., not related in 24 per cent., relationship not known in 48 per cent. Of 11 cases reported by Trousseau, only two had parents who were related. Recent investigations prove that consanguinity may be regarded as a cause in about 25 per cent. to 30 per cent. of the cases. Males are more frequently affected than females. According to Schobl, the disease is more common with the Semitic than with the Aryan race.

Fig. 233

Typical retinitis pigmentosa. (Jaeger.)

Pathology.—The process is essentially an atrophy not preceded by inflammation. The atrophic process affects simultaneously the vessels of the choroid and of the retina. Gonin,[2] as a result of the histological study of a case, is of the opinion that the immediate cause of the degeneration is a slow atrophy of the choriocapillaris.

Atrophy of the sensory elements of the retina in the outer retinal layers is a result of destruction of the choriocapillaris, atrophy of the sensory elements of the inner layers, a result of sclerosis of the retinal vessels. The former precedes the latter.

[1] Amer. Jour. of Ophth., April, 1886.

[2] Ann, d'oculistique, January, 1903.

The pigmentation of the retina is greatest over the equatorial zone, the portion corresponding with the area supplied by the terminal branches of the ciliary arteries. In rare cases the degeneration of chorioidal vessels first affects the choriocapillaris in the region of the yellow spot. The pigment is derived from the pigment layer of the retina, the pigment penetrating into the atrophic retina and forming along the course of the vessels, the perivascular spaces favoring its extension. Processes extend from the small masses of pigment and apparently anastomose with those from neighboring masses. Although advancing from the pigment layer of the retina, the development of pigment in the inner layers is greater than in the middle layers, and the microscopic appearance is often that of small areas of pigment spread out in the inner layers of the retina, joined to the pigment layer proper by columns of pigment. The retina gradually loses its characteristic structure; the various layers disappear; the membrane becomes thinner and is converted into connective tissue.

Blood-vessels.—Arteries and veins become much smaller and apparently less numerous. White lines accompany the arteries. In the later stage of the disease almost all vessels disappear or are represented by a few very narrow arteries and veins or by extremely fine white lines.

Optic Nerve.—In the early stage of the disease the optic nerve is but little changed; later its vascular supply is reduced by atrophy of the smaller vessels. Eventually the nervous elements disappear in great part, the nerve becomes shrunken, and connective-tissue elements are increased.

The atrophic changes in the chorioid keep pace with those in the retina. The sclerosis of blood-vessels extends to the ciliary body and iris, reducing the volume of these tissues.

The lens often presents evidences of loss of nutrition by the formation of posterior polar, posterior cortical, or complete cataract.

The vitreous humor may also present numerous small opacities as a result of impaired nutrition.

Symptoms.—One of the most distressing symptoms is hemeralopia (night-blindness). On a dull day, at twilight, or on going into a room that is dimly lighted, the patient with retinitis pigmentosa is virtually blind. He can see nothing. The retina is torpid, requiring the stimulus of intense light to excite the recognition of images.

Clinical History.—Retinitis pigmentosa of the typical variety is thought to be congenital in its inception. As a rule, no intimation of the condition is given by the patient until the defect of vision is noticed. This may be before the age of ten years or may not occur until the age of fifteen or twenty years; then one of two things happens—either the great loss of vision by subdued illumination (night-blindness, hemeralopia) or the contraction of the field of vision is noticed. The affection advances very gradually, but, as a rule, constantly. The pigmented figures become more numerous and encroach upon the retina at the posterior pole of the globe. The retinal blood-vessels become greatly reduced in size. The

optic disk assumes a dirty, pale-yellow color with hazy edges, the disk itself apparently becoming smaller. The vision gradually fails. At the age of forty-five to sixty the patient sees but little and only throughout a greatly narrowed field.

Fields of Vision.—The nature of the affection makes it evident that the fields of vision may vary much in form. The form depends on the areas of degeneration. As a rule, the degeneration advances from the periphery. In these cases the fields of vision are narrowed concentrically. The degeneration may advance irregularly, may occur in a zone about the macula, may first develop at the posterior pole of the eye. The fields of vision will correspond in form.

Diagnosis.—Typical retinitis pigmentosa cannot be mistaken for any other condition. Atypical forms may be confounded with some forms of chorioiditis, as the atypical forms of desseminate chorioiditis of syphilitic origin.

Prognosis.—This is invariably bad. In some cases retardation of the development of the affection may be obtained.

Treatment.—The progress of the disease may be delayed by improving the general nutrition. Strychnine in full dose has been advised. Anti-syphilitic remedies should be employed, if there is any suspicion of syphilis. Benefit has been claimed from the use of galvanism.[1] This may be tried. If any measure serves to retard the advance of the affection, it is all that can be expected. Recovery of much of what is lost is impossible because of the anatomical changes.

Fig. 234

Retinitis punctata albescens. (Morax.)

Retinitis Punctata Albescens.—This condition is characterized by the appearance of numerous discrete, round, pale spots in the retina unaccompanied by pigmentation. The entire fundus may be studded with the spots, or they may be absent at the posterior pole and at the periphery.

Pathology.—The author is not aware that a histological examination of this condition has been made. It is probable that the capillaries of the retina or the choriocapillaris of the chorioid is at fault.

Symptoms.—The condition was first described by Mooren. It is rare, the writer having seen but four cases in twenty years. Judging from the relatively few cases reported and by the cases seen, the ophthalmoscopic picture varies only very slightly. The affection is bilateral and is probably congenital. A number of the members of the same family may present

[1] Standish, Trans. Amer. Ophth. Soc., 1887.

the condition.[1] Heredity is probably a factor. Consanguinity has been traced in some of the cases. On examining the fundus with the ophthalmoscope, it is found to be studded with numerous small, round, discrete, white or yellowish-white spots, which vary in size from those just distinguishable to spots about the diameter of a retinal blood-vessel of the first dimension. These spots are situated beneath the retinal blood-vessels. They do not appear to change with lapse of time. The retinal blood-vessels are of normal size or, in some cases, very slightly reduced; the disk may be paler than normal and its borders slightly blurred. There is no evidence of interference with nutrition in other tissues of the eye. Vision, as a rule, is below normal in acuity. In some cases the reduction is considerable; in some cases normal vision has been observed. The extent of the field of vision for form is not reduced, but the color fields are smaller in many cases and in some there is a relative central scotoma. Night-blindness occurs in perhaps two-thirds of the cases. Sex apparently does not influence the condition.

Prognosis.—Almost all writers are of the opinion that there is no tendency to progression.

Treatment.—Treatment is of no avail.

Gunn's Dots.—Marcus Gunn[2] has called attention to the presence of a number of small white or yellowish-white dots that are sometimes found at the macula. The dots are clustered. They are found in both eyes, do not affect vision and do not change readily. They occur mostly in young individuals.

Gyrate Atrophy of Chorioid and Retina.—Fuchs[3] describes a peculiar form of chorioidal and subsequent retinal atrophy, of which he has observed a few cases. The disease is characterized by the development of a broad zone of atrophy, apparently corresponding to the capillaries terminating the short ciliary arteries. The affection begins by the appearance of circular atrophic spots in the chorioid which slowly extend, coalesce, and eventually form an atrophic zone with irregular margins, encircling macula and disk. During the development of the affection, which progresses extremely slowly, the atrophic spots may assume various shapes and bands of more or less normal chorioidal and retinal tissue may extend between them. Both eyes are affected symmetrically. In one case reported by Fuchs the patient was night-blind from early childhood. The retinal vessels and disk had the same appearance as in typical retinitis pigmentosa, and there was present the stellate opacity—posterior cortical cataract—which is so often met with in the last-mentioned disease. The vision was greatly reduced, corresponding to the changes in the fundus just described.

Syphilitic Retinitis.—Syphilis affecting the retina is primarily an affection of the vessels; it is, therefore, not difficult to understand that the retina is seldom affected alone, but that, although the system of vessels in the retina is largely an independent one, the vessels of the chorioid may and often do participate.

[1] Griffith, J., Trans. Ophth. Soc. United Kingdom, xvii, p. 48.
[2] Trans. Ophth. Soc., iii, p. 110.
[3] Arch. of Ophth., xxvii, No. 5, p. 480.

Syphilitic affections of the retina may be classified as follows:

1. *Syphilitic retinitis*, syphilitic inflammation of the retina, which does not present any visible affection of the chorioid. This may be subdivided into (*a*) macular, (*b*) diffuse retinal, (*c*) neuroretinal, (*d*) syphilitic hemorrhagic retinitis.

2. *Syphilitic chorioretinitis.* Subdivisions: (*a*) Macular chorioretinitis, (*b*) diffuse chorioretinitis, (*c*) circumscribed chorioretinitis.

1. **Syphilitic Retinitis without Visible Affection of Chorioid.**—(*a*) MACULAR SYPHILITIC RETINITIS.—This develops slowly, becoming pronounced in acute cases in from two to five days after its inception. In some cases the development is much slower. The symptoms are dimness of vision due to a relative central scotoma, distortion of images (metamorphopsia). There is no pain. Ophthalmoscopically there may be a slight edema of the retina at the macula evidenced by a loss of clearness of retinal detail and a slight paling of the reflex at this point, with very little haziness of the overlying vitreous body; also a few minute white patches indicating the presence of minute isolated masses of plastic exudate, rarely a very few minute hemorrhages, and, in addition, dilatation and perhaps some tortuosity of one or more vessels at the macula. The affection is frequently monocular. When both eyes are involved it may be symmetrical, but is apt to be more diffuse in one eye than in the other. This type of syphilitic retinitis is relatively mild; it seldom extends to other parts of the retina. The optic disk may be hyperemic and its borders hazy, but the disturbance is slight.[1]

Diagnosis.—Macular syphilitic retinitis should be differentiated from incipient albuminuric retinitis, from exudation and hemorrhage occurring in advanced adult life due to degeneration of the blood-vessels, and from tubercle of the chorioid occurring at the macula. The history of the case supplemented by the physical examination and the examination of the urine will suffice to make the differential diagnosis.

(*b*) DIFFUSE SYPHILITIC RETINITIS.[2]—In this affection the details of the retina are altered and often obscured by a grayish exudation into the retina irregularly disposed. Edema of the retina and a haziness of the vitreous overlying the affected area develop, hemorrhages may occur. As a rule the hemorrhages are small, occur in the nerve-fiber layers consequent on the partial or complete obstruction of a blood-vessel. They may take place in the deep layers of the retina or may be large and become subhyaloid. The grayish exudation varies in intensity in the different parts of the affected area and is due not only to the amount of plastic or fibrinous exudation, but to the extent of the

[1] The writer observed a case in the person of an artist, forty-three years of age, who, one morning, noticed that horizontal lines when looked at with the left eye presented a curve with the convexity upward, and that the vision with that eye was not quite as good as with the right eye. The disturbance increased slightly. Thirty-six hours later a similar defect of the right eye developed. This incapacitated him for work. The ophthalmoscope revealed a very slight haziness at the macula of each eye, no plaques, no hemorrhages. Under vigorous antisyphilitic treatment recovery without a trace of the defect took place in two months. The primary sore occurred eleven years previously.

[2] Jacobson, Koenigsberger med. Jahrb., Band i, S. 283.

small-cell infiltration. The vessels may be hidden by the exudation. The intensity of the obscuration of the vessels varies greatly in different cases and in the various parts of the retina. An area of the retina quite removed from the optic disk may be affected and the tissue of the disk escape almost, if not entirely; but in the cases in which the area involved is large or in which the entire retina is affected the tissue of the disk is also involved and the case becomes one of neuroretinitis. In pronounced cases the iris and ciliary body are very apt to participate in the process.

Symptoms.—Dazzling, sometimes persistent, is often complained of. There is diminution of the light sense corresponding to the affected area, and at times hemeralopia. Diminution of vision is always present and is greatest in those parts of the visual field corresponding to the part of the retina in which the exudation is densest or in which the circulation is most interfered with. Total blindness during the acute stage probably never occurs. Distortion of images and flashes of light may be observed by the patient. Externally there may be an overfilling of the deep vessels of the ocular conjunctiva.

Diagnosis.—There is no danger of confounding this form of retinitis with any but albuminuric retinitis, which it may closely resemble. Even the stellate arrangement of white patches about the fovea centralis, which at one time was thought to be pathognomonic of albuminuric retinitis, is faithfully reproduced in some cases of syphilitic retinitis.

(*d*) Syphilitic Hemorrhagic Retinitis.—This term is employed by Schöbl[1] to designate a class of cases, of which he reports five, characterized by small retinal arteries, large tortuous veins, red nerve heads, numerous small and large hemorrhages scattered all over the fundus, and dust-like opacity of the vitreous. Severe headache and dizziness accompany the condition. There was a pronounced history of syphilis in every case. Improvement followed vigorous antisyphilitic treatment in all but one case. Schöbl states that a slow syphilitic endarteritis must have preceded the attack. These cases are closely allied to the cases of hemorrhagic retinitis with endarteritis obliterans in which no history of syphilis is obtainable.

2. **Syphilitic Chorioretinitis.**—(*a*) Macular Chorioretinitis.—Macular chorioretinitis (syphilitic) develops slowly and is marked by a diffuse haziness of the retina in the macular region, with slight paleness. The symptoms are dimness of central vision, photopsia, metamorphopsia. The lesion may be monocular, may be binocular and nearly symmetrical. The initial change probably takes place in the choriocapillaris and consists in a small-cell infiltration, an interference with the circulation at this point in this layer, and a serous or serofibrinous exudation, the disturbance of the bacillary layer of the retina producing the metamorphopsia. Recovery may take place without leaving a trace, but it may be followed by all degrees of damage to retina and chorioid.

(*b*) Diffuse Chorioretinitis.—This presents very varied appearances and results in disturbances of the retinal pigment layer and in

[1] Norris and Oliver's System, iii, p. 484.

permanent lesions of the chorioid of greater or less extent. The inflammation may begin in retina and chorioid simultaneously, may affect one first and subsequently develop in the other. Disturbance of the retina by extension of exudation and small-cell infiltration from the chorioid may readily occur. When the chorioid is extensively involved the process extends beyond the border of the choriocapillaris, often implicating the ciliary body and iris. The dust-like clouding of the vitreous humor is more pronounced than it is when the retina is the chief seat of the affection. Fibrinous deposits may occur on the posterior surface of the cornea as in uveitis. The cloudiness of the vitreous humor is seldom due to the presence of large masses, but to very numerous minute particles of fibrin which may eventually disappear entirely.

Symptoms.—Impairment of vision, sometimes very pronounced. Pain, if the ciliary body or iris is involved. Congestion of the vessels of the sclera and deep, ocular conjunctival vessels.

Relative and positive scotomata of all forms are produced; irregular peripheral defects, paracentral and ring scotomata. Small islets of normal retina only may be preserved. Photopsia, chromopsia, micropsia, and metamorphopsia occur.

Diagnosis.—A differential diagnosis must be made between this affection, albuminuric retinitis and a mild metastatic chorioiditis. The onset of the albuminuric retinitis is less rapid. An examination of the urine is often of value, although a syphilitic affection may be associated with albuminuria. Careful observation for a few days, in addition to the history, may be necessary to differentiate it from mild metastatic chorioiditis.

Results.—The results of this form of syphilitic chorioretinitis differ from those of any other form in the character and variety of the permanent lesion. The retinal pigment may be much disturbed with little chorioidal atrophy. Proliferation of the retinal pigment cells may take place and closely resemble the changes found in retinitis pigmentosa, but in such cases careful examination will rarely fail to disclose small spots of chorioidal atrophy, and there is often an indefinite, circular arrangement of the pigment which does not obtain in typical retinitis pigmentosa. As a rule, the atrophic spots in the chorioid are more or less regularly circular in shape, and there is often a grouping of the spots.

(*c*) Circumscribed Chorioretinitis.—This is characterized by the appearance of large isolated patches, which may represent the site of a single large lesion or of two or more which have coalesced. The vessel around which the inflammatory focus has formed may often be seen to enter the mass. Disease of the vessel walls may be apparent. As a rule, a number of these foci are scattered throughout the fundus, sometimes near or at the posterior pole, sometimes well at the periphery. The patches may be quite small, but are often two or even three disk diameters in size and elevated. They are white or yellowish-white in color, often present plaques of more intense white at some part, and may show some hemorrhages at the periphery. The hemorrhages occur most often on the border toward the disk. The outline may be quite sharply marked

at some part of the border, but it is always in part obscured and may be entirely so by the exudation into the superficial layers of the retina and by the haziness of the superimposed vitreous. In these cases the fundus, aside from the areas of inflammation, may be almost free from evidence of disease, the disk unchanged, but in many cases haziness of the margin of the disk, hyperemia of the disk, and dilatation of the veins accompany the process. Opacities of the vitreous, often quite large and freely movable, are present.

On subsidence of the process large circular or lobulated atrophic patches are left, often bluish-white in color, which appearance is due to the formation of connective tissue. The contraction of this tissue may, according to Fuchs, lead to detachment of the retina. The writer has never seen such a result.

Diagnosis.—The process may be mistaken for tubercular chorioiditis or for a subretinal entozoon —cysticercus. A careful study of the condition will suffice to make a differential diagnosis.

Etiology.—*Acquired syphilis* may produce all of the forms of retinitis except, perhaps, circumscribed chorioretinitis. It is by far the most common cause of the forms of syphilitic retinitis, in which the process is almost wholly confined to the retina. Retinitis may follow the initial lesion of syphilis at any time after the lapse of four to six months. Diffuse chorioretinitis due to syphilis is a later manifestation occurring seldom before the third year.[1]

Inherited syphilis affects the retina, as a rule, during the early years of life, seldom producing a retinitis after the age of eighteen years. The types of hereditary syphilitic chorioretinitis are the diffuse and circumscribed, particularly the latter. Diffuse chorioretinitis due to inherited syphilis is seldom unaccompanied by disease of the ciliary body and iris, and is not infrequently accompanied by parenchymatous keratitis. Although it may be present at birth or develop very shortly after birth, it develops most frequently between the ages of five and twelve years.

Pathology.—All cases of syphilitic affections of the retina have their origin in focal lesions which are in the nature of a vasculitis. The capillaries, or the vasa vasorum of the arteries, are the vessels that are first attacked. A small-cell infiltration first occurs, which in the case of the capillaries may eventuate in their obliteration throughout the area involved. If the point of departure is in the wall (the vasa vasorum) of a vessel, the adventitia, intima, and muscularis are soon affected, and its lumen may be much compromised. Where the aggregations of small cells occur the ophthalmic picture is that of white or slightly yellowish-white spots (usually small). These may appear in clusters along the vessels. The lesions correspond to those described by Heuber[2] as occurring in the vessels of the brain in brain syphilis. In circumscribed syphilitic chorioretinitis the aggregation of small cells takes place at a few points only, but the mass may be quite enormous. In a specimen examined by

[1] Hirschberg, Centralbl. f. Augenheilk, xii, p. 369.
[2] Die lueteschen Erkrank, d. Hirnarterien, Leipzig, 1874.

Schöbl[1] the mass of small cells in one plaque produced an elevation of 1.3 mm.

It has been demonstrated by Bach[2] that the changes in the vessels may be confined to the retina in diffuse syphilitic retinitis, but it is well known that in the greater number of the cases in which the retina is affected by syphilis the chorioid participates.

Results.—If recognized early and proper treatment is vigorously carried out, recovery with good vision almost invariably follows. Without treatment, blindness due to destruction of the perceptive elements of the retina and subsequent atrophy of the optic nerve may follow. Laxity in treatment is followed by relapse.

Hemorrhages into the vitreous as well as into the retina may occur. These may favor the formation of pseudomembranes, the subsequent contraction of which may cause detachment of the retina. The development of syphilitic retinitis proliferans may result from the hemorrhages into the vitreous.

Impairment of the retinal vessels may be very slight or very extensive. In mild cases recovery is apparently complete. In severe cases complete destruction of the vessels, the arteries and capillaries in particular, may occur. In cases of this kind the larger arteries present the appearance of narrow white lines. They are few in number, and cannot be traced very far from the disk. The retina becomes atrophic, the disk pale, yellowish white, with hazy outlines. Chorioidal patches also occur. The pigmentary and atrophic changes in the chorioid assume the most bizarre forms.

Treatment in General.—The administration of mercury and the iodides should be begun as early as possible and should be continued until the active process has entirely subsided, and thereafter less vigorously for from six to eighteen months. The diet should be carefully regulated and proper tonic remedies employed. Examinations of the urine and of the blood should be made at sufficiently frequent intervals to afford reliable indications regarding the proper remedies required. The writer has obtained the greatest benefit from the use of mercury. The method of administration has been by inunction, particularly during the acute stage. The biniodide, when mercury has been administered internally, has been very satisfactory. The mercurial should be carried to the point of saturation, that is, until there is some sensitiveness of the gums, and the system should be kept thus under the influence of the drug for two to four weeks. Lesser doses may then be given. Calomel may be the form of mercury employed, given in small (gr. $\frac{1}{10}$) dose, frequently repeated; or the salicylate of mercury in an oily menstruum may be given by deep gluteal injections. Of the iodides the potassium or the sodium iodide may be given in sufficient dose to produce a mild physiological effect.

Purulent Retinitis.—Classification.—The forms of purulent retinitis may be classified as follows: (1) *Traumatic purulent retinitis.* (2) *Secondary purulent retinitis.* (3) *Metastatic or embolic purulent retintits.*

[1] Norris and Oliver's System, iii, p. 479.

[2] Arch. f. Augenheilk, 1893, Band xviii, S. 67.

1. Traumatic Purulent Retinitis.—In the examination of eyeballs that become infected by the entrance of foreign bodies through the cornea and lens without wounding the uveal tract in any of its parts, it will be found, in some cases at least, that the retina has taken on a high degree of inflammation of a purulent type which is continued into the vitreous and gives by transmitted light a yellowish reflex. The uveal tract participates secondarily. In the early stage of the affection the iris shows little evidence of inflammation. On microscopic examination the retina is found to be greatly thickened and practically filled with small cells. The inflammatory products often find their way between the retina and chorioid. The condition resembles panophthalmitis of the milder type. Schöbl[1] mentions having observed cases of this nature following the entrance of pieces of percussion caps into the vitreous humor. Here the inflammatory process is undoubtedly set up by the chemical irritation produced by the decomposition of the brass of the cap and the fulminate of mercury which may adhere to it.

Symptoms.—See Panophthalmitis.

Results.—Disorganization of the globe results.

2. Secondary Purulent Retinitis.—This may, according to Schöbl, result after perforation of a corneal ulcer with injury to or loss of the crystalline lens of the eye. However, the process terminates in panophthalmitis with loss of the eye, and can only be diagnosticated anatomically in cases in which the globe has been removed early; consequently it is of no clinical importance.

3. Metastatic Purulent Retinitis (*Embolic Metastatic Retinitis*).—Septic embolism of the retinal vessels may occur as a result of systemic or local septic or pus-producing processes of whatever nature—accompanying acute diseases, as cerebrospinal meningitis, variola, scarlatina, typhoid fever, the various forms of pyemia and septicemia, endocarditis, phlegmon, etc.[2] Although originating in the retina, the process soon affects the uveal tract, which is involved to a greater or less degree. A panophthalmitis is established, which may not be so acute as when the chorioid is primarily the seat of the metastasis, but is equally destructive to vision.

Etiology.—The microörganisms concerned are the same as those that produce metastatic chorioiditis (see page 367).

Symptoms.—The symptoms are those of metastatic panophthalmitis, as described on page 368.

Diagnosis.—Schöbl states that in the early stages the diagnosis can be made ophthalmoscopically. The yellow, partly filled-in, cup-shaped fundus is thought to be pathognomonic.

Treatment.—If the process is not very acute and the pain occasioned not great, the eyeball may be permitted to remain; otherwise enucleation should be resorted to at an early stage. The process may be modified

[1] Norris and Oliver's System, iii, p. 489.

[2] A case of metastasis into the retina of miliary actinomycosis is reported by L. Müller (Klin. Monatsbl. f. Augenheilk, 1903, p. 236) which, however, did not become purulent.

by the internal administration of small, frequently repeated doses of calomel (gr. $\frac{1}{10}$), care being taken not to cause salivation, the remedy to be continued until the acute stage is passed.

Septic Retinitis of Roth.—Under the term septic retinitis, Roth[1] has described a retinal process which occurs in pyemic and septicemic conditions. There is no active inflammatory manifestation externally. The ocular conjunctiva may become slightly edematous and a few small hemorrhages may occur. Ophthalmoscopically, the optic disk may be very slightly hazy. The vessels are not changed in size or materially so in color. A number of small flame-like or circular hemorrhages may occur about the disk and macula. Vision is not interfered with except at the site of the hemorrhages. The process does not appear to be embolic, but to be due to an effect on the walls of the vessels, permitting the escape of red blood-corpuscles at certain points. Recovery follows slowly. Blood pigment may be detected in the retina for a long period of time. The vision is restored. There is no tendency to relapse.

Gouty Retinitis.—Few recognize the existence of a class of cases of retinitis to which the term "gouty" can be applied, but some writers[2] are of the opinion that certain cases of retinal hemorrhage are caused by changes in the retinal vessels due to gout. Hutchinson, quoted by Gowers, believes that many of the cases of hemorrhagic retinitis occurring in young people are due to inherited gout, and suggests that they may be caused by thrombi and partial obstruction of the central retinal vein. Acute retinitis resembling the so-called gouty explosions never occurs, but a slowly developing retinal disturbance characterized by small, usually flame-shaped hemorrhages, numerous irregularly circular, pale patches of exudation at the posterior pole of the eye, and some impairment of vision, occurs in elderly people who are sufferers from gout, and has been termed "gouty retinitis."[3]

Macular Retinitis.—Changes of a pathological nature taking place at the macula are not uncommon. They are of various forms: (*a*) Edema, (*b*) minute spots of exudation, (*c*) hemorrhages, (*d*) the development of pigment patches, etc. Changes in the chorioid immediately back of the fovea centralis and macula are so intimately connected with the retinal changes that they will be considered here.

Edema (*Serous Exudation*).—This presents itself in the form of a grayish haze obscuring the details of the retina in this portion, the cloud often extending into the vitreous. It may occur as the faintest possible haze, or it may be quite dense, presenting a grayish-white circular patch at the macula, shading gradually into normal retina. In all cases in which the choriocapillaris back of the fovea centralis is normal, the fovea presents as a more or less intense red spot. The disk and other parts of the fundus are unaffected. Edema may be symmetrical, but it is unilateral in a large percentage of the cases. It occurs most frequently in adults.

[1] Deutsch. Zeitschr. f. Chirurgie, 1872, Band i, S. 441.
[2] Gowers, Medical Ophthalmoscopy, 3d ed., p. 267.
[3] Bull, Trans. Amer. Ophth. Soc., 1893.

Etiology.—Syphilis is the cause in many of the cases. It may be due to traumatism or to undue use of the eyes by a very bright light.

Prognosis.—The prognosis is favorable.

Treatment.—In addition to improving the general physical condition of the patient, absorbent remedies, such as the iodides and mercury, are indicated.

Exudation (*Plastic*).—This appears at the macula either in the form of small white spots occurring in the deeper layers of the retina or in large white plaques which cover the macular region to a greater or less

Fig. 235

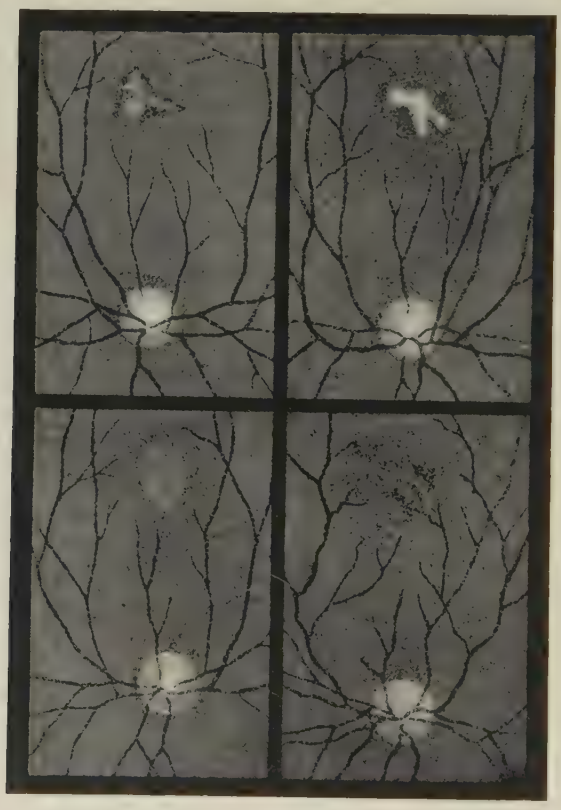

Disease of the macula lutea of the retina resulting from a severe blow on the eye (traumatic macular disease). (After Haab.)

degree. The small white spots have a stellate arrangement, owing to the deposition of the minute blood-vessels from which the exudation takes place.

Etiology.—The exudation is due to an affection of the walls of the vessels. This may be caused by traumatism as in commotio retinæ, a weakening of the walls of the blood-vessels as in acute nephritis, a

localized arteriocapillary fibrosis (an appearance most common in advanced life), or a syphilitic perivasculitis localized at the macula. The deposit takes place in the inner and outer reticular layers of the retina and in the inner nuclear layer.

Prognosis.—Good so far as a disappearance of the punctate deposits are concerned. The plaques may also disappear, but much permanent injury may have been done to the perceptive elements of the part of the retina affected.

Treatment.—This consists in correcting any causative constitutional defect and in the use of absorbents continued over a long period of time.

Hemorrhage.—Macular hemorrhages are not uncommon, particularly in the aged.

Etiology.—They may develop as a result of (*a*) thrombus or embolism of a macular vessel; (*b*) arterial sclerosis or arteriocapillary fibrosis; (*c*) syphilitic perivasculitis; (*d*) traumatism; (*e*) stretching of the retina in high degrees of progressive myopia.[1]

Prognosis.—More or less permanent injury and impairment of vision result.

Treatment.—The treatment is the same as for retinal hemorrhage affecting other parts.

Changes Marked by a Disturbance of Pigment.—It is undoubtedly true that obstructive capillary fibrosis occurring at any part of the choriocapillaris soon causes changes in the pigment layer of the retina. The obstruction may take place very slowly and not be accompanied by any appreciable edema. A central scotoma develops. This may remain small and be relative only; it may extend and become absolute. The changes at the macula are visible with the ophthalmoscope as irregular broken lines of retinal pigment, appearing much like small ridges between which the fundus is usually slightly paler than normal. There may be a number of small patches from which the pigment has entirely disappeared. The defect at the macula may remain unchanged for years, but the tendency is to slowly increase.

Etiology.—This form of change at the macula is most frequently observed in the aged and is an expression of senile changes in the choriocapillaris. It may be monolateral, but is usually bilateral.

Symptoms.—The patient complains of an inability to see clearly objects that he looks at directly. In some cases macropsia, micropsia, or photopsia is present.

Diagnosis.—This is easily made with the ophthalmoscope.

Treatment.—It is possible that the advancement of the affection can be averted by the internal administration of the iodide of potash and of mercury in some form, long-continued, but changes that have already occurred cannot be recovered from.

[1] The writer has observed a case in which a fissure in the retina involving all but the internal layers developed. The fissure was in the horizontal meridian extending through the fovea centralis to a short distance from the optic disk; a clot of blood filled the outer two-thirds of this fissure.

Changes of the Nature of an Arteriocapillary Fibrosis.—Changes at the macula involving the choriocapillaris and the macular retinal vessels occurring in the aged, of the nature of an arteriocapillary fibrosis, result in the development of relatively large areas of retinal atrophy at the posterior pole, with irregular distribution of pigment and the disappearance of pigment over areas of greater or less size. These processes seldom exhibit any sign of inflammation, but may be accompanied in the early stage by edema, due to obstruction. Irregular relative and absolute scotomata develop. Islets of comparatively normal retina may persist for months or years, but, as a rule, the central vision is virtually abolished.

Treatment.—An attempt may be made to limit the progress of the condition. The remedies of greatest value are the iodide of potash, mercury and iron, in small, long-continued dose.

Injuries to the Retina.—These may be classified as traumatic anesthesia, commotio retinæ, hemorrhage, perforation, rupture, and detachment.

Traumatic Anesthesia.—This term has been employed by Leber to designate impairment of vision with contraction of the field of vision following injury, without discoverable ophthalmoscopic changes in the retina. According to Leber, the impairment of vision may last a few weeks or may remain indefinitely. The cases are extremely rare.

Treatment.—Improvement of the general condition, rest, atropine, tinted glasses in the early stage, and strychnine.

Traumatic Edema of Retina (*Commotio Retinæ; Traumatic Amblyopia*).—*Etiology.*—The term "commotio retinæ" has been long used to designate an edema of the retina the result of trauma.

Symptoms.—Concussion, if severe, produces pain and immediate impairment of vision which may amount to total blindness. The immediate great impairment of vision passes off rapidly, some impairment remaining. The eye may be painful for some hours or days. The pupil, which is at first dilated, may soon become small from engorgement of the vessels of the iris following the trauma. Miosis may not develop or it may soon give way to dilatation due to traumatic paralysis of the sphincter pupillæ. If an ophthalmoscopic examination is made early, a pale gray, patchy, diffuse haziness of the retina at the posterior part of the fundus will be seen, with overfull veins, and arteries reduced in size. The diffuse patches coalesce and at the end of from eighteen to twenty-four hours present a uniform whitish, translucent appearance of the fundus, differing much in degree of intensity in different cases, sometimes approaching the appearance seen in embolism of the central artery of the retina. The whitish area passes imperceptibly into normal fundus toward the periphery. The appearance is due to edema, principally of the nerve-fiber layer of the retina. It may be accompanied by a few small hemorrhages. Central vision is impaired to a greater or less degree. The field of vision is usually normal in extent.

Prognosis.—The prognosis is favorable. The edema disappears in from five to ten days, leaving in severe cases, small, sharply defined white patches radiating from the fovea centralis, resembling the patches seen in albuminuric retinitis. These patches, which represent exudation from minute vessels situated in the deeper layers of the retina, disappear after some weeks. Vision is completely restored, as a rule. In some cases pigmentary changes ultimately develop in the retina as a result of disturbance in the circulation of the choriocapillaris.

Treatment.—Atropine to put the ciliary muscle at rest; dark glasses, saline laxatives, rest.

Hemorrhage.—A contused blow on the eyeball may be followed by hemorrhage from retinal vessels. The hemorrhages are usually small, situated on or near the disk. The hemorrhage may be large and blood may pass into the vitreous body.

Treatment.—Atropine; rest; non-use of the eyes.

Traumatic Perforation at the Macula Lutea (*Holes at the Macula*).—Concussion injuries to the eye sometimes cause a minute rupture at the macula which appears as a circular hole in the retina.

Symptoms.—The bottom of the defect is of a deeper red color than the normal fundus; the retinal pigment remains attached to the chorioid. The edge of the retina at the defect is very slightly raised or thickened and is paler than the surrounding retina. In four cases observed by the writer the depth of the defect did not exceed $\frac{2}{3}$ mm. The smallest opening was about 0.4 mm.; the largest 0.8 mm. There is a small central or paracentral scotoma. In old cases the retina at the margin of the defect is thickened. Other ruptures of the retina as well as rupture of the chorioid may accompany this condition.

Treatment.—Treatment is of no value.

Rupture of Retina.—Without rupture of the chorioid this is rare. One such case which resulted from the impaction of a missile from a blowgun was seen by the writer. The rupture occurred near the periphery of the retina below. The irregular edges of the defect could be seen. The retina was detached in the vicinity of the rupture. There were a little blood and some patches of exudate in the vitreous chamber near the site of the rupture.

Prognosis.—The prognosis in these cases must always be guarded. Recovery may take place. Total detachment of the retina sometimes follows.

Treatment.—Rest in bed; atropine; non-use of the eyes. Violent exertion of all kinds should be avoided. The bowels should be kept free.

Laceration of Retina.—This, in connection with laceration of the other tunics of the globe, will be considered in connection with injuries to the globe.

Effects of Various Lights on Retina.—**Sunlight** (*Solar Retinitis*).—*Symptoms.*—Exposure to intense sunlight may produce transient or temporary impairment of vision with or without permanent changes in the retina. Usually a permanent positive scotoma appears (Widmark).

The visual acuity is reduced and there are changes at the macula. Widmark[1] has experimented on animals and concludes that the changes in the retina caused by exposure to intense sunlight consist of an edema with death of nervous elements. A number of cases have been reported, due to watching an eclipse.

In an exhaustive article by Mackay[2] the literature to date is reviewed. He reports seven new cases. In four of the cases a positive scotoma was not noticed until one or two hours after the eclipse had been watched. The scotomata varied in size from 3 to 20 mm. at a distance of one meter. It was described as a "gray spot," a "luminous disk," a "revolving star." A peculiar "revolving movement or oscillation" is sometimes observed affecting the scotoma, which may persist for months or years. Metamorphopsia, macropsia, and micropsia may be observed. These phenomena may persist. Ophthalmoscopic changes are very slight. When they can be seen they consist in a slight edema at the macula, which disappears slowly and fine pigmentary changes develop.

Prognosis.—The prognosis for complete recovery is not good, but improvement over the immediate diminution of vision almost always occurs.

Treatment.—This is the same as in non-syphilitic retinal exudation. Prophylaxis: suitably tinted glasses, yellow or amber tint; several layers of ruby glass or a combination of green and red (Maklakoff).

Electric Light.—Exposure to intense electric light with the eye relatively close to the source of light, arc light, or a flash due to a "short circuit," may produce temporary blindness with temporary changes at the macula. Würdemann and Murray report a case of a man temporarily blinded by a short circuit; the blindness lasted ten minutes. The macular region was hazy and the inferior retinal veins congested. Recovery to the normal in two weeks. Uhthoff discovered a number of yellowish-red points scattered about the macular region after a similar exposure. In a case reported by Ryerson, instantaneous blindness followed a stroke by lightning. The optic nerve and retina were edematous; retinal veins engorged. Recovery complete in eight weeks.

Röntgen Rays.—The Röntgen rays are visible to the eye adapted to the dark (Crzellitzer). The phenomenon observed is in the form of a diffuse bright disk or of a pale ring with a paler included field. "Since the brightest spot does not lie in the middle of the field of vision, the region of the macula can possess no particular sensibility to the Röntgen rays as it does in ordinary vision."

Birch-Hirschfeld[3] is of the opinion that great care should be exercised in employing the x-rays about the eye, as he has found changes in the retina and optic nerve due to prolonged exposure.

The experience of the writer leads him to believe that ordinary exposures of the eye, as in the treatment of neoplasms of lids or globe, do not injuriously affect the retina.

[1] Hygiea, 1892, No. 6, Stockholm.
[2] Ophth. Rev., 1883, xiii, p. 1.
[3] Graefe's Arch., lix, 2, p. 229.

PLATE XXI

Glioma Retinæ.

Radium.—Radium rays in a darkened room impart a general sensation of light. They are not refracted, reflected, or absorbed to any appreciable degree by the refractive media of the eye. If too long-continued, radium rays may cause retinitis or even atrophy of the globe.[1] The phenomenon excited in blind eyes is a fluorescence of the media (Greeff).

Ultra-violet or Chemical Rays.—According to Ströbl,[2] it is possible for these rays to induce a circumscribed retinitis.

Senile Circular Defects at the Macula.—Circular defects closely resembling the traumatic "holes" at the macula occur in elderly individuals, apparently as a result of atrophic processes. The defect is symmetrical, but may develop earlier in one eye than in the other; it is usually larger than the traumatic defect and does not present the radiating lines sometimes seen in traumatic defects. The latter occur in children or young individuals and are never symmetrical. Kuhnt, Harms, de Schweinitz and others have described the senile condition. De Schweinitz describes the ophthalmoscopic appearance as follows: "Exactly in the centre of the right macular region was an oval, red-brown area, about one-third the size of the papilla, containing in its centre two yellowish-white dots and a few fine white stipplings. This spot was surrounded by a greenish-white ring, somewhat raised, so that the red portion appeared as if at the bottom of a small pit." The depression appears to be about 0.50 mm. deep. Central vision becomes much reduced.

Harms[3] made a microscopic examination of such an eye. The retina at the defect was one-fifth of the normal thickness. There was no sharp wall as indicated by the ophthalmoscope. The thinning was chiefly due to atrophy of the rods and cones and their associated nuclei. The pigment layer of the retina was much changed, the cells being heaped up in places. The chorioid was not much changed.

Tumors of the Retina.—The tumors of the retina that have been recorded to the present time are perithelioma, angioma, tubercle, malignant epithelial melanoma, and glioma.

Perithelioma and Angioma.—There are elements in the retina of mesoblastic origin from which neoplasms may develop. Collins[4] has described perithelioma and angioma which if they developed from the retina had this origin.

Tubercle.—A few cases of tuberculosis of the retina have been reported, all of which, with one exception, were secondary to tubercular formations in the chorioid or optic nerve head.

Malignant Epithelial Melanoma.—Under this name a growth which apparently sprang from the retinal epithelial cells near the ciliary region was reported by Mr. John Griffith.

All tumors of the retina other than glioma are extremely rare.

Glioma Retinæ[1] (*Neuroepithelioma*, Flexner).—This is a neoplasm that appears in infancy. It produces enlargement of the globe (rarely

[1] London, Graefe's Arch., lvii, 2, p. 195.
[2] Klin. ther. Wochen, x, No. 45.
[3] Klin. Monatsbl. f. Augenheilk., May, 1904.
[4] Trans. Ophth. Soc., 1892, xii.
[5] For an exhaustive description of the growth, see Parsons, The Pathology of the Eye, vol. ii, p. 626.

iridocyclitis and subsequent temporary shrinking), pierces the sclera, extends to the orbital tissues and contents, and causes the death of the individual in two or three years' time.

Occurrence.—Glioma occurs during fetal life and up to the age of twelve years. It is most frequently observed between the first and third years of life. In regard to frequency, it occurs, according to Arlt, von Graefe, Schöbl, and others, in about $\frac{1}{20}$ of 1 per cent. of the cases of affections of the eyes. Of 204.612 cases of eye disease occurring at the New York Eye and Ear Infirmary in ten years, 0.017 per cent. were glioma retinæ. When observed at birth both eyes are generally affected. In cases that occur after birth about 10 per cent. are bilateral. No positive etiological factor is known, but it is certain that heredity exerts a strong influence. Newton[1] reports a family of 16 children, 10 of whom had glioma; Maher, a family of 4 children, glioma in 3; Wilson, a family of 8 children, glioma in all. (Of 60 cases collected by Lawford and Collins no example of heredity was recorded.)

Fig. 236

Glioma of retina. (Hunter.)

Development.—It is said that glioma develops most frequently from the inner nuclear layer. Schöbl has seen it developing from a number of foci. Opportunity to confirm this statement is sometimes afforded in cases of binocular glioma. When a diagnosis of glioma of one eye has been made, the fundus of the fellow eye should always be carefully examined. Commencing glioma appears as a yellow spot, slightly raised and supplied with its individual system of blood-vessels. There may be a number of these spots situated near each other in the posterior half of the retina. The tumor may be circumscribed or diffuse. The former is much the more common. It may push the retina in front of it, developing in large part between the retina and chorioid (exophytum), or it may push forward into the vitreous chamber (endophytum). As a rule, the tumor grows steadily, in some cases much more slowly than in others, in some cases there are apparent periods of arrest. A mild iridocyclitis may develop, followed by partial shrinking of the globe.

The growth of the tumor may be divided into four stages:

1. *Quiescent Stage.*—The quiescent stage in which the patient experiences no pain. The eyeball retains its normal size and shape. There is little or no injection of the external ocular vessels. In the early part of this stage the diagnosis can be made by means of the ophthalmoscope

[1] Australasian Med. Gaz., May, 1901.

only, but in the latter part the characteristic light yellow reflex is present. When the reflex begins to be appreciable the yellow has a tinge of red. Later it is light yellow, and when the growth has almost filled the eyeball the reflex is whitish yellow. The reflex is readily seen and progressively more readily, because the fundus of the eye is pushed forward and the refraction becomes highly hyperopic. While on casual examination the reflex appears to be uniform, closer examination will disclose areas of greater paleness, due to degenerative changes, hemorrhagic spots, and a lobulated surface. The vision may be abolished, but perception of light in some part of the field is preserved until the growth is well advanced. The tension of the globe is not diminished; it may be slightly increased. The anterior chamber tends to become gradually more shallow. Consensual reaction of the iris, which is preserved, keeps the pupil about of normal size until pressure from the advanced lens interferes with the motility of the iris.

2. *Painful Stage.*—The eye, which heretofore has been free from pain or evidence of inflammation, now becomes painful from the onset of glaucoma or, rarely, iridocyclitis. If glaucoma develops, all of the symptoms of this condition *plus* the yellowish reflex from the pupil are present. Iridocyclitis presents the symptoms of this affection with reduced tension. Iridocyclitis may be followed by partial atrophy of the globe before the growth again advances.

3. *Ectatic Stage.*—The eyeball now becomes ectatic. On account of the plastic condition of the sclera in infants the globe may be greatly enlarged before perforation takes place. The enlargement may be fairly uniform, producing megalophthalmos and keratoglobus, eventually scleral staphylomata (intercalary, ciliary, equatorial) develop and the growth extends beyond the fibrous coat of the eye. There are three methods by which the growth passes from the interior of the eye: (*a*) By extension along the optic nerve, in which case exophthalmos develops; (*b*) by growing between the fibers of the sclera or cornea, dissociating these and gradually passing through the fibrous coat; (*c*) by extension along the minute canals through the sclera which give passage to arteries, veins, and nerves. At this stage the patient acquires the cachexia so common to malignant disease.

4. *Metastatic Stage.*—The stage of metastasis during which the growth appears in other parts of the body. Metastasis is frequent in the parotid and submaxillary glands, but may occur in the lymphatic glands, the liver, kidneys, ovaries, brain, bones of the skull, ribs, etc. It is thought that metastasis occurs through the medium of the blood-vessels. Bizzozero (1871) reports having found glioma cells in the blood-vessels.

In cases of glioma which are complicated by iridocyclitis and temporary shrinkage of the globe the condition is made possible, according to von Graefe and Virchow, by an inflammatory process set up by the glioma together with a high grade of retrogressive metamorphosis of the tumor tissue and absorption of the fluid elements. So far as is known the glioma eventually again advances.

Pathology.—*Structure.*—The tumor before hardening is soft and gelatinous, of a white or yellowish-white color. On section reddish spots or streaks are seen which mark the site of degeneration. In these, calcareous deposits are sometimes found. Old hemorrhages may produce spots of pigmentation. Microscopically it is found that in stained sections the better-nourished cells, which are those surrounding the blood-vessels, to the depth of twelve or fourteen layers, are much more deeply colored by nuclear stains and more sharply defined than are the cells outside of these zones. This produces a peculiar figure of tortuous lines and dots. The remaining masses of cells present evidences of degeneration. The cells possess large nuclei, round or oval, 6 to 7 μ in diameter (Parsons), granular, containing a single small nucleolus. The cystoplasm is extremely scant; more in young than in mature cells. The cell is quite regular in contour in its early stage, 8 to 9 μ in diameter, but soon presents numerous minute processes approaching a crenate appearance. The cells are fairly uniform in size; where they are rapidly increasing in number they are larger; they are also larger in metastatic growths.

Forms of Cells.—Cells of various forms are met with: (*a*) Cylindrical cells, developing at the edge of nutrient canals; (*b*) giant cells, very uncommon; (*c*) ganglion cells, possibly remnants of the ganglion-cell layer; (*d*) neuroglia cells; (*e*) spindle cells, shape due to pressure.

Arrangement of Cells.—The cells are usually massed together without well-defined system; however, in approximately two-fifths of the cases a circular arrangement of cells about a small lumen, the lumen being sharply limited by a fairly well-defined membrane, is found. These forms are known as *rosettes* (Flexner) and are thought to represent the rod and cone cells. Processes are found extending into the lumen of the rosettes.

Stroma.—This is very inconspicuous. It consists in numerous delicate fibrils which, according to Greeff, are the minute processes of cells resembling neuroglia cells. The blood-vessels are small, usually not very numerous.

Diagnosis.—Transillumination of the globe is of as much value in the diagnosis of glioma as in the diagnosis of all obscure intra-ocular conditions with detachment of the retina or hazy vitreous. (For technique, see page 118.)

Differential Diagnosis.—Glioma may be confounded with diffuse tubercle of the chorioid, optic-nerve head, and ciliary body; with metastatic chorioiditis, rare cases of plastic chorioiditis not metastatic, and with some forms of cyclitis.

Prognosis.—Glioma causes the death of the patient probably without exception, if the affected eye is not removed during the first or early part of the second stage. It is generally conceded that a cure may be recorded if recurrence does not take place in three years after enucleation. In 143 cases collected from various sources (Lawford and Collins, Hirschberg, Holmes, Noyes, Owen) permanent recovery is recorded in 42—about 30 per cent. Eight cases of recovery after removal

of both eyes for double glioma have also been reported. It is probable that recovery may be as frequent in binocular as in uniocular glioma. Glioma may appear in the fellow eye after enucleation of the first eye.

TREATMENT.—The only treatment that is of any avail is enucleation at as early a stage as possible. If glioma occurs in both eyes and is in a very early stage, an attempt to save the life of the individual by enucleating both eyes may be made. If when both eyes are involved the growth is well advanced in one or both, enucleation is of little value. If recurrence in the tissues of the orbit or metastasis takes place, operation is not indicated, as it will not prevent the onward march of the affection.

DIFFERENTIAL DIAGNOSIS.

	Glioma.	Tubercle.	Plastic chorioiditis.	Pseudo-glioma. Cyclitic membrane.
History	Slow development; non-inflammatory.	Slow development; tuberculosis in some other part of body.	Onset inflammatory; injection of ocular conjunctiva. In metastatic history of meningitis or some other affection capable of producing metastasis.	Onset inflammatory; history or evidence of injury to eye.
Size of globe	Normal in first stage; enlarged in second stage.	Normal except late in development, when it may be enlarged.	Slightly enlarged in inflammatory stage; shrunken later.	Of normal size or smaller.
Tension	Normal or increased.	Normal.	Decreased.	Decreased.
Reflex	Pale yellow.	Dirty white.	Often pale yellow; ordinarily more intense yellow.	Dirty white.
Anterior chamber	No inflammatory products except when complicated by cyclitis, which is rare.	Not changed from the normal.	Papillary zone of iris conforms to shape of anterior surface of crystalline lens on which it lies. Sinus of anterior chamber deeper than when the anterior chamber is shallow under other conditions. May contain inflammatory products.	Usually deeper than normal; may contain inflammatory products.

Pseudoglioma.—This term is applied to conditions not gliomatous which have been diagnosticated glioma, or between which and glioma a differential diagnosis without dissection is extremely difficult or impossible. The conditions most frequently confounded with glioma are plastic chorioiditis and cyclitis or choriocyclitis; cysticercus subretinæ, tubercle, and detachment with degeneration of the retina. The principal points of difference have been referred to in the paragraph on the diagnosis of glioma. Transillumination will aid much in clearing up the diagnosis. In cases in which a doubt regarding the true diagnosis exists, enucleation is almost without exception desirable, even if the condition is not glioma. While in former years such mistakes in diagnosis were not infrequent, with present methods and better knowledge of symptomatology, pseudogliomata are rare.

Detachment of Retina.—Etiology.—Detachment of the retina may be due (1) to subretinal exudation, with diminution in the size of the vitreous body; (2) to subretinal hemorrhage; (3) to overdistention of the globe, with changes in the size of the vitreous chamber; (4) to shrinkage of the vitreous body from any cause; (5) to traumatism with or without loss of vitreous.

Subretinal Exudation.—To this class belong detachment accompanying albuminuric retinitis, subretinal entozoa (cysticercus), and chorioidal tumors, particularly sarcoma. The detachment in albuminuric retinitis may develop very rapidly and become complete.[1] Detachment may occur in the albuminuria of pregnancy[2] as well as in albuminuria

Fig. 237

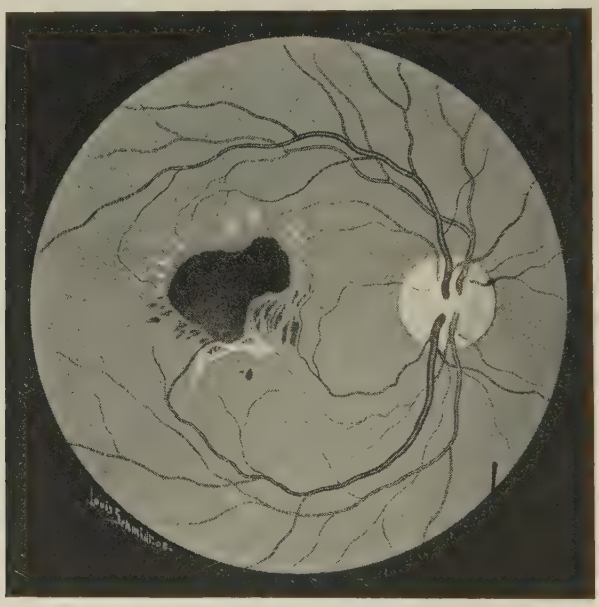

Subretinal hemorrhage.

from any cause accompanied by more or less general anasarca. The subretinal exudation which accompanies the growth of subretinal entozoa and chorioidal tumors is slow in development; consequently the detachment of the retina is slight and localized at first; it may eventually become complete.

Subretinal Hemorrhage.—In hemorrhagic retinitis it sometimes occurs that the blood finds its way into the layer of rods and cones and produces small areas of detachment of the retina. Hemorrhage from

[1] The writer observed a case occurring in a man with uremic coma in which complete detachment of the retina of both eyes occurred in twenty-four hours. Postmortem examination of the eyes made by the writer disclosed the presence of a sero-albuminous fluid beneath the retinæ. There was no appreciable change in the vitreous humor.

[2] Wadsworth, Trans. Amer. Ophth. Soc., 1887.

the chorioid, either spontaneous or as a result of traumatism, is apt to cause a greater degree of detachment than occurs from hemorrhage from the retina.

Overdistention with Changes in Size of the Vitreous Chamber.—The most common example of detachment from overdistention is the detachment accompanying myopia. It was pointed out by Iwanoff that in the distention of the eyeball in acquired high myopia, the vitreous body did not increase in volume in proportion to the increase in the size of the vitreous chamber—that is, it became detached from the retina in part, and that the additional space was occupied by serum. It has been held that the serum surrounding the vitreous body may filter through the tense retina and cause detachment, but de Wecker and Schweiger[1] are of the opinion that a rupture of the retina, which may occur from slight traumatism (possibly spontaneously) under the conditions present, always precedes the detachment.

Shrinkage of Vitreous Body.—If from any cause the vitreous body becomes the seat of new-formed connective-tissue elements, as after hemorrhage from retinal, ciliary, or chorioidal vessels, as a result of cyclitis, exudative chorioiditis, retinitis proliferans, the presence of a foreign body, or is filled with a fibrinous exudation, as in certain cases of diffuse chorioiditis or uveitis, or if, from malnutrition, as in certain cases of atheroma of the blood-vessels, the vitreous shrinks, detachment of the retina may result.

Traumatism.—Contusion of the eyeball, mild or severe, violent massage, penetrating wounds may all cause detachment of the retina, partial or complete.

By far the greater number of cases of detachment of the retina are preceded by changes in the vitreous body which render it partly fluid or reduce its volume. Detachment after traumatism is most frequently preceded by loss of vitreous humor.

Immediate Determining Causes.—These are direct injury, sneezing, vomiting, coughing, lifting heavy loads, riding horseback, jumping, jolting the body in any way, venereal and alcoholic excesses, violent exercise, forcibly rubbing the eyes, etc.

Symptoms.—The symptom of greatest importance is loss of vision. This occurs in that portion of the field of vision corresponding to the area of detachment. Vision throughout this area is often entirely abolished, but light-perception is retained in many cases. In cases of slow detachment the visual acuity of the attached portion of the retina is but little disturbed at first, but the area of diminished vision often extends to parts of the retina other than those apparently detached. In sudden detachment the loss of vision extends much beyond the actual detachment. Vision is most profoundly affected when the detachment is at or near the macula. In the remaining attached portion the light sense is reduced. Patients see best by strong illumination. Color sense is impaired. There are distortion of images (metamorphopsia), due to the

[1] Trans. Twentieth Meeting, Heidelberg Ophthalmological Society.

unevenness of the retina, and flashes of light (photopsia), due to dragging on the retina, the latter being constant in developing detachment. Chromatopsia is also often experienced.

If from any cause the retina becomes re-attached the vision is restored to a great degree, but not quite to the normal. After rest in the recumbent position, particularly after lying on the back, the vision is frequently temporarily improved. Often on rising in the morning the vision will be greatly improved. This improvement may be held until the day is well advanced, but, as a rule, it recedes half an hour to three hours after rising. Photopsia is probably always experienced when the redetachment takes place. The tension of the eyeball is diminished in perhaps 95 per cent. of the cases. The exceptions are those in which the detachment is the result of intra-ocular growths, of entozoa, and in some cases of detachment attending albuminuric retinitis. When almost complete

Fig. 238



Detachment of retina. (Nettleship.)

blindness is present, the pupil is large and the iris sluggish. In cases of extensive detachment in which the retina comes well forward in the vitreous chamber, a pearly gray reflex may be obtained from the pupil by simple inspection, if the light is favorable.

There is a group of cases in which the detachment is flat, the elevation from the chorioid seldom extending more than 3 or 4 mm., in which the red reflex is preserved, due either to a transparent retina or to the character of the subretinal fluid. The detachment is partial more frequently than complete, and is often difficult of diagnosis. Such a detachment may accompany a flat chorioidal neoplasm, and may be due to a hemorrhage or chorioidal exudate. Ophthalmoscopic examination gives a reddish reflex with areas or striæ of a slightly grayish tone in some cases,

The blood-vessels, as they come onto the raised area are bent and may pursue an uneven course. The veins are often darker in color than in the normal eye. If the elevation is partial and slight, the difference in the refraction over the detached area as compared with the undetached area is a valuable diagnostic sign. The phenomenon of parallactic displacement of the vessels is also of value.

In ordinary cases the retina is thrown into folds. The folds are usually multiple and often lie meridionally. Detachment of this character can be readily examined by reflected light, using the ophthalmoscopic mirror. The retina appears as pearly gray undulations over which the retinal vessels, not greatly changed in character, pass. The difference in level of the different parts of the vessels can be easily determined. In complete detachment the retina is often irregularly funnel-shaped, the base of the funnel being at the ora serrata, the apex at the optic disk. The detachment usually presents a dirty grayish- or bluish-white appearance. In old detachment, pigment spots the result of hemorrhage, calcareous plaques, and cholesterin crystals develop in portions of the retina. The detachment due to subretinal cysticercus is globular in form during the early stages of development. It increases slowly, keeping pace with the development of the entozoon. The retina may be sufficiently transparent to enable the observer to see the entozoon, but is often irregularly discolored, whitish-yellow plaques appearing. Detachment accompanying lobulated neoplasms of the chorioid corresponds in shape to the neoplasm in the early stages of its development; later complete detachment of the retina takes place. (In the *very* early stage of the neoplasm the detachment is either not present or is so very slight that it cannot be readily diagnosed.) The retina and subretinal fluid, if transparent, permit a view of the underlying neoplasm. The direct method of ophthalmoscopic examination is of much value, particularly in the very early stage of detachment when but little of the retina is involved.

Detachment of the retina occurs at all ages, but is most common in adult life, since the causes for its production are then most prevalent. Males suffer twice as frequently as females. One eye only is usually affected, but in albuminuric detachment and in high myopia it is not unusual for both eyes to be involved. Of 204,612 patients presenting themselves at the New York Eye and Ear Infirmary in ten years with disease of the eyes, 256, or 0.125 per cent. had detachment of the retina.

The detachment frequently begins above and changes by gravitation to the lower part. In total detachment the retina remains attached at the optic disk and ora serrata. It often happens that undulations of the retina can be seen on movement of the eye.

The blood-vessels appear smaller the nearer they are to the cornea because they are seen under reduced magnifying power. The veins may become very dark, not because of actual changes in the blood, but because they absorb more light by transillumination.[1]

[1] Schöbl, Norris and Oliver's System, iii, p. 540.

If vision is retained by a detached retina, the refraction is hyperopic as compared with the previous condition. This acquired hyperopia may entirely disappear on reattachment of the retina.

Course and Prognosis.—Spontaneous recovery takes place only in a very small percentage of cases. This is most apt to occur in detachment following traumatism not associated with high myopia, detachment with albuminuria, detachment due to inflammatory chorioidal exudation, to disturbed circulation and to diseases of the orbit, rarely in detachment accompanying myopia. Muglich[1] collected 136 cases of spontaneous replacement of the retina. The causes of detachment in these cases were myopia, albuminuria, traumatism, phlegmon of the orbit, loss of vitreous humor after operation, and chorioiditis.

Temporary spontaneous readjustment, partial or complete, is not uncommon in recent cases. The detachment is very apt to recur and to gradually increase in extent. If a reattachment remains for six weeks or two months, it may be considered permanent, as relapses after this period of time has passed are uncommon. The detachment may remain partial, but the ordinary course is to the development of a more or less complete detachment with blindness of the affected eye. Degenerative changes develop in all of the tissues of the eye after detachment of the retina. In some cases hyperplastic changes take place in the retina. The blood-vessels may become reduced in size, their lumen reduced by thickening of their walls; aneurismal dilatations in arteries or veins may develop. The nerve elements, particularly the ganglion cells, may disappear; the layer of rods and cones may become lost or changed in character. Hemorrhages into the retinal tissue; calcareous deposits; the development of opacities in the vitreous, cholesterin crystals (synchysis), and, in very rare cases, of osseous tissue may take place. In cases of total detachment, cysts of the retina are not uncommon.

Accompanying Changes in Other Tissues.—The chorioid may become atrophic. Mild iritis and cyclitis may occur as complications. Cataract frequently develops. In old cases ribbon-shaped keratitis and not very infrequently atrophy of the globe results. Atrophy of the optic nerve is always a result when the detachment becomes complete. The fellow eye is never sympathetically affected except possibly in some rare cases in which atrophy of the globe with the formation of osseous tissue in the primarily affected eye may produce a painful inflamed globe and subsequent sympathetic inflammation. Glaucoma sometimes follows detachment.

Treatment.—The results of treatment in detachment of the retina are most discouraging. A very small percentage of recoveries only have been observed. The patient should be seen at the earliest possible moment after the detachment has occurred. He can then be placed under conditions most favorable for reattachment. Rest in bed in the dorsal position should be enjoined. Movements of the head or eyes should be slow and as few as possible. If the patient leaves the bed, his movements should be

[1] Inaug. Dissert., Marburg, 1891.

slow and deliberate. Straining at stool, coughing, sneezing, etc., should be avoided. The confinement in bed should continue for a period of six weeks to two months. Use of the eyes during this period should be prohibited. A compress bandage for two weeks is thought to be of value. Atropine should be instilled to prevent contraction of the ciliary muscle. Diaphoretics may be employed at the same time. Of the diaphoretics, pilocarpine is the most serviceable. This may be administered by the stomach or hypodermically, in sufficient dose to produce free diaphoresis;[1] the latter method is the one to be preferred. The injections should be made daily for five to ten days. An interval of a week should be allowed and another course of injections, similar to the first, should be given. When perspiring, the patient should be between flannel sheets or blankets, be well covered and kept warm. These measures, in connection with the internal administration of the iodide of potassium and mercury in cases in which there is plastic chorioidal exudation or hemorrhage, will accomplish all that can be expected from postural and medicinal treatment. When the patient leaves the bed all of the "immediate determining causes" of detachment should be avoided for a long period of time. If the detachment has lasted some weeks or months before treatment is commenced, postural measures will be of no avail.

A multitude of procedures, surgical and medical, have been advocated —leeches to the temple, sinapisms, vesicants, cupping, venesection, hot and irritating foot baths, Turkish baths, etc.

Sichel, in 1859, in the hope of causing reattachment of the retina, punctured the sclera and permitted the subretinal fluid to flow out. Multiple scleral puncture has been practised by many. Others have advocated operation for the purpose of establishing an inflammatory exudative process between the retina and chorioid. Von Graefe (1863) recommended discission of the retina, accomplished by introducing a needle from in front and lacerating the retina. De Wecker (1877) introduced a fine gold wire through sclerotic and chorioid and fixed it in position so as to allow of continuous filtration of subretinal fluid. Galezowski (1872) advised iridectomy in these cases. In the same year he proposed the injection of the tincture of iodine into the subretinal space, subsequently employing Lugol's solution because of too violent reaction from the tincture of iodine. Schoeler revived and revised this method in 1889 or 1890. Numerous successful results were reported, but the experiences of others were not satisfactory and the method was abandoned. Galezowski (1890) sutured the retina to the chorioid by means of catgut. De Wecker and Messelon (1892) employed galvanopuncture, and Gillet de Grandmont advocated electrolysis for detachment. In 1895 Deutschman advocated discission of the retina and the cutting of fibrous bands in the vitreous in the hope of causing reattachment of the retina by pressure of preretinal fluid. He subsequently advocated preretinal injections of the prepared vitreous of the rabbit.

[1] The dose by stomach is gr. $\frac{1}{8}$ to $\frac{1}{2}$; hypodermically, gr. $\frac{1}{12}$ to $\frac{1}{2}$.

De Wecker[1] advocated the injection of saline solutions into the lymph space of Tenon's capsule. He has employed solutions of various strengths, having used as high as 30 per cent. He did not explain the therapeutic action, but claimed to be satisfied with the results. Many others have employed intracapsular and subconjunctival injections of saline solution and report unsatisfactory results.

L. Müller[2] proposes an operation for the cure of detachment, as follows: (1) Expose the contents of the orbit by the Krönlein operation. (2) Expose the outer posterior portion of the globe by cutting the externus and inferior oblique muscles. (3) Resect an equatorial, fusiform piece of sclera lying between the equator and the insertion of the external rectus muscle, piece measuring 8 to 10 mm. wide, 16 to 20 mm. long. (4) Puncture the chorioid at the lower part of the opening in the sclera and permit the subretinal fluid to escape. (5) Suture the edges of the sclera; restore the muscles by suturing the cut ends; close the orbital wound. This operation, which has for its object a reduction in the volume of the globe, is as yet *sub judice*.

Of the operations that may be of some value, iridectomy as preventive, and multiple scleral puncture as curative, may be mentioned. Iridectomy is for the purpose of preventing detachment in cases in which detachment has occurred in one eye and the conditions in the other eye favor detachment, as in cases of progressive myopia with increased tension and opacities of the vitreous.

Multiple scleral puncture has for its purpose the escape of subretinal fluid and the permanent reapposition of the retina by a plastic exudative process. This should not be employed in very recent cases. After rest and diaphoretics have been thoroughly tried, multiple scleral puncture may be resorted to, this to be followed by rest, compress bandages, and atropine. The puncture should be made in such a way that the subretinal fluid may be evacuated. A Graefe knife may be employed, the point being carried through the retina.

Subretinal Cysticercus.—See chapter on Entozoa.

Amaurotic Family Idiocy.—This condition was first described by Warren Tay (1881) under the title "Symmetrical Changes in the Region of the Yellow Spot in Each Eye of an Infant." The condition depends on extensive disease of the nervous system, consisting in large part in a degeneration or atrophy of the gray matter of the cortex of the brain, the basal ganglia, the cord and spinal ganglia, and of the retina. The patients are Hebrew infants without exception so far as is at present known. Both sexes are attacked alike.

Etiology.—No definite cause is known. The changes that occur in the ganglion cells point to a toxic degeneration.

Pathology.—The retina has been examined microscopically in these cases by Collins, Holden, Shumway, Poynton and Parsons, Stock and others. Holden[3] was the first to furnish a correct explanation of the

[1] Annal. d'ocul., August, 1902.
[2] Münch. med. Woch., 1903, No. 23.
[3] Journal of Nervous and Mental Disease, July, 1898.

changes that produce the peculiar ophthalmoscopic appearance. The pathological change occurs in the ganglion cells of the retina and consists

Fig. 239



Section through fovea in a case of amaurotic family idiocy. (From a photomicrograph by Geo. S. Dixon. × 100.)

mainly in a condition of chromatolysis and other degenerative processes of the protoplasm, with considerable edema of the cell body. The thick

Fig. 240

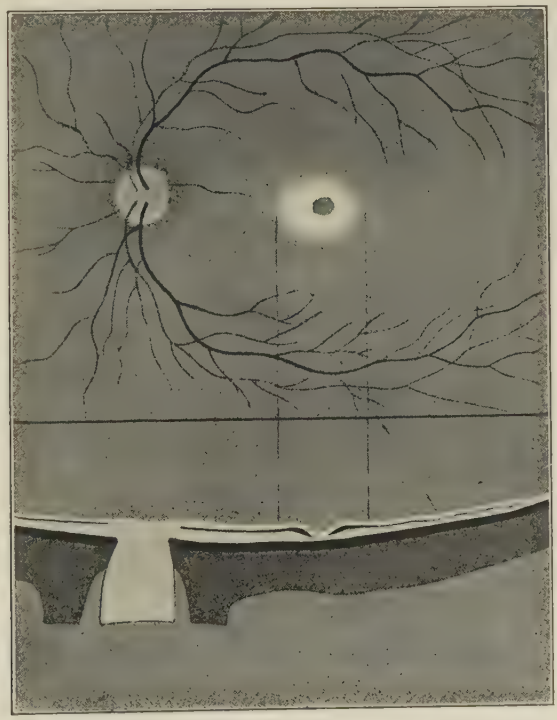

The upper diagram represents the fundus picture. The lower diagram represents a corresponding section of the eyeball. The dark line in the retina indicates the layer of ganglion cells. (Holden.)

layer of ganglion cells at the macula (Fig. 239), six to nine cells deep, produces the white appearance; the pit in the centre of this patch marks the absence of ganglion cells at the fovea centralis.

Symptoms.—The clinical symptoms are uniform in all cases and are principally as follows: Parents healthy; no syphilis or tuberculosis. Children healthy and remain so to the age of three to six months. The muscles of the neck and back then become weak and flabby; the child is unable to sit erect. The weakness gradually extends to all the muscles and the palsy deepens. The child becomes listless, apathetic, and develops absolute idiocy. Unusual sensitiveness to sight and sound (hyperacusis) is present in some cases.

Convulsions may occur. The functions of the body are in a low state of activity. Intestinal disturbances and attacks of bronchitis are common. The child usually dies of marasmus before or shortly after the end of the second year. Blindness comes on fairly early in the disease.

The early ophthalmoscopic appearances are a large, nearly circular, white patch at the macula of each eye, one and a half to two disk diameters in size, shading gradually into normal fundus at the periphery. The centre of the patch presents a cherry-red spot, the choriocapillaris showing through the thin retina at the fovea centralis, similar to the appearance in sudden obstruction to the central artery of the retina. Optic disk normal. Atrophy of the optic nerve develops. The appearance at the macula persists until death.

Treatment.—Treatment is unsatisfactory.

CHAPTER XVII.

THE OPTIC NERVE AND OPTIC CHIASM.

Function of Optic Nerve.—The function of the optic nerve is to conduct the impulses originating in the retina by the stimulus of light, from the retina to the brain. The number of optic-nerve fibers is approximately 1,000,000, making it impossible for each rod and cone to have its individual fiber, as the rods and cones number many millions. It is possible, however, that this relation may exist at the fovea centralis, as Cajal has shown to be probable in reptiles and birds.

The rule that the nerve fibers associated with that portion of the retina the visual field of which is common to the visual field of the fellow eye conduct impulses to the same side of the brain finds its most perfect exemplification in man, since the extent of the visual fields common to both eyes is greater in man than in any other animal. Pathological data obtained in cases of disease destroying the cortex of the brain at, and in the region of, the calcarian fissure, on one side, and experimental data on the monkey in which corresponding parts have been destroyed, have abundantly proved this rule. In man the visual impulses received on the temporal half of the right retina and the nasal half of the left retina pass to the cortical centre of the right cerebral hemisphere, and contrariwise. The visual impressions at the fovea centralis throughout an arc of 10 to 14 degrees are conducted to both cortical centres, because, as has already been described, this portion of the retina is supplied by fibers from both sides of the brain.

Impulses which serve to regulate the movements of the iris and ciliary muscles and the extrinsic muscles of the eye are also carried through the optic nerve along the fibers that connect with the nuclei of these muscles.

In addition to afferent impulses, of which two kinds have been described, there are efferent pathways and efferent impulses.

ANOMALIES OF THE OPTIC NERVE.

Coloboma.—Coloboma of the sheath of the optic nerve is one of the most frequent anomalies met with. Among 1655 eyes with anomalies of refraction, Vosius[1] found 75 (4.53 per cent.) with coni downward. The greater number of these represented coloboma of the optic nerve and sheath of some degree. Coloboma of the sheath is due to faulty closure of the retinal fissure (fetal retinal cleft). It occurs downward or downward and inward.

[1] Zeh. klin. Monatsbl. f. Augenheilk., xxii, 137.

Etiology.—Heredity as a cause is not questioned. Wagenmann cites the case of a woman with coloboma whose three children had coloboma, although they were the offspring of three fathers.

Ophthalmoscopic Appearance.—The optic disk may appear nearly normal, the blood-vessels emerging below the centre of the disk, but being surrounded by normal nerve tissue. The disk may appear oval, the long diameter horizontal. It may be kidney-shaped, the notch being below. Only the upper rim of the nerve may be observable or the normal appearance of the papilla may be entirely wanting, its place being occupied by a bluish-white circular depression in the sclera out of which retinal blood-vessels proceed, their trunks being dimly visible in the bottom of the depression. The defect often resembles the myopic conus, except that it occupies the lower part of the disk and its retinal margin is always sharply defined. Its margins may or may not be pigmented. The lower margin of the optic nerve fades into the conus and is ill-defined. The oval shape of the nerve and the amount of the disk visible is in inverse proportion to the depth of the depression. The blood-vessels may be

Fig. 241

Coloboma of the optic-nerve sheath: *R*, right papilla; *L*, left papilla. At *a*, the small retinal vein leaves the cone. (De Wecker.)

surrounded by the tissue of the nerve itself, or they may lie in a groove in the under part of the nerve or may be found entirely outside of the nerve proper. On emerging they may take their usual course; ordinarily the greater number of the vessels do not cross the defect, but some of the principal arteries and veins pass over the area, following its contour. In many cases no depression of the vessels is noted.

Coloboma of the optic nerve may, and not infrequently does, occur in connection with coloboma of the chorioid and iris.

Vision.—This is defective in many cases.

Anatomical Peculiarities.—Elschnig[1] has studied the tissues of the eyes in six cases of coloboma of the optic nerve. In all of these cases a sac-shaped deposit of rudimentary retinal tissue was found either between chorioid and sclera or between optic nerve and sclera. The chorioid and sclera were thinner at the site of the coloboma and in all marked cases, the subvaginal space was dilated at the lower part.

Opaque Optic-nerve Fibers.—See Retina, page 425.

[1] Graefe's Arch., li, 3, p. 391.

Pigmentation of Disk.—This occurs rarely and is supposed to be due to incomplete absorption of the fetal optic-nerve pigment, which is excessively developed. Pick[1] reports a case in a girl of seven years. The optic disk was surrounded by opaque nerve fibers. Its centre was intensely pigmented, being almost black. Pick collected six cases. The pigmentation is usually monocular, but may be binocular.

Aplasia of Optic Nerve.—Defective formation or development of the optic nerve is met with rarely. In microphthalmos, hydrocephalia, and anencephalia the optic nerve may be replaced by a fibrous cord, the nerve and retina being destitute of nerve fibers or elements.[2]

In some cases, a portion of the ganglion cells of the retina remains. Duane[3] reports a case in which aplasia of both optic nerves was present in eyes that were of normal size and appearance. There was total blindness.

Fig. 242

Connective tissue on disk.

Connective-tissue Masses on Optic Papilla.—White, glistening masses of tissue, which may be small or may be large enough almost to cover the disk, of different degrees of density, are sometimes present. The tissue may project as shreds from the disk or may appear as a thin cyst wall, covering part of or the entire disk. These connective-tissue structures are remnants of the fetal hyaloid artery.

[1] Arch. f. Augenheilk., xli, p. 96.
[2] Rosenbaum, Zeit. f. Augenheilk., vii, 3.
[3] Arch. f. Ophth., xxxii, 4, p. 319.

DISEASES OF THE OPTIC NERVE.

Circulatory Disturbances.—As has already been shown the nutrition to the disk is supplied principally by the retinal vessels. This is augmented by arterial branches from the circle of Haller (see p. 65), which extend into the optic nerve at and near the lamina cribrosa. The vascular disturbances that can be determined are principally those of the retinal vessels as they present at the optic disk. These may be designated as follows: (1) Venous pulsation; (2) arterial pulsation; (3) anemia; (4) hyperemia; (5) hemorrhage.

The belief has been held that the condition of the circulation in the optic papilli and retinæ is an accurate indication of the condition of the circulation within the cranial cavity. This is not strictly true. The intra-ocular pressure so modifies the circulation in the eye that the relationship between the eye and the cranium is not a very intimate one.

1. **Venous Pulsation.**—The occurrence of venous pulsation in part or in all of the large venous trunks *at the papilla* occurs frequently in normal eyes, in the young and in the old. Lang-Barrett[1] examined 61 individuals, most of whom were young, and found venous pulsation in 45 (73 per cent.). Veasey examined 120 eyes and found venous pulsation in 58.3 per cent. of the cases. When existing normally, venous pulsation will be found to coincide with the diastole. It has been explained as follows: "Before the blood-wave in the retinal arteries passes through the capillaries to the veins, its influence has been exerted on the vitreous body and the intra-ocular pressure is thus momentarily increased so that the veins are most compressed at their exit where the blood-pressure is lowest. Therefore, the phenomenon is not an intrinsic venous pulse, but a rhythmic dilatation and contraction of the central vein dependent on the arterial pulse, although the latter is not visible. To quote Becker[2] the central vein is an index for the arterial pulse, and may be considered as a natural sphygmograph."[2]

Appearing as a result of disease of the heart, as in aortic insufficiency without compensatory hypertrophy, or in tricuspid insufficiency, venous pulsation may vary as to the time of its appearance. Venous pulsation may be induced by pressure on the eyeball, also in many cases by the inhalation of nitrite of amyl.

2. **Arterial Pulsation.**—This is always of pathological import. It is most frequently seen in one or two of the principal branches of the central artery, particularly in the branch or branches that bend most abruptly as they pass to the level of the retina, whatever the condition of the end of the nerve may be. The rhythmic reddening ("puls") of the whole of the papilla is seen sometimes, but very infrequently. Arterial pulsation may be present *whenever the general blood-pressure* falls below the intra-ocular tension. It may be present in low arterial tension, as in the

[1] Royal London Ophth. Hosp. Reports, xii, 1, 50.
[2] Arch. f. Augenheilk., 1872, Band xviii, S. 206.
[3] Norris and Oliver's System, vol. iii, p. 435.

diseases that produce this condition, namely, anemia, chlorosis, syncope, and after profuse hemorrhage.

The degree of the pulsation may vary in the two eyes, the variation being due to anatomical conditions existing in the nerve, in the vessels between the eye and the heart, or in the intra-ocular pressure. Arterial pulsation is seen most frequently as a result of *increased intra-ocular pressure,* and is regarded as an important diagnostic symptom of glaucoma. (See page 397.)

Arterial pulsation is also observed in aortic insufficiency and at times in aneurism of the aorta. It has also been seen in Basedow's disease. In cases of affections of the aortic valves, aneurism, and Basedow's disease the support to the blood-column immediately after systole is much less than normal and the blood rapidly recedes toward the heart; all the vessels of the upper part of the body are similarly affected.

3. **Anemia.**—The term anemia is applied to an undue paleness of the disk, due either to (*a*) the color or (*b*) the quantity of the blood. The first is always consequent on a general condition of the system, the so-called anemias. The size of the vessels is not greatly changed. The color of the blood in both arteries and veins is lighter than in the normal eye. In pernicious anemia, leukemia, and in chlorosis, pallor of the disk is observed; this is due largely to the abnormal proportion of the white blood-corpuscles in the blood. In these cases a slight haziness of the margin of the disk (papilla) may exist because of slight edema, and small hemorrhages into the tissue of the disk are not uncommon. The second form of anemia depends either on great loss of blood or on an obstruction to the circulation by spasm, thickening of the walls of the blood-vessels, thrombosis, or embolism. In cases of obstruction, the column of blood in the affected arteries may vary much in diameter, being greater just before the obstruction than it is at or beyond the obstruction, except in cases of spasm of the arteries, when, if the arterial spasm is general, the reduction in size will be uniform. The veins are not reduced in size and are sometimes tortuous. There is a marked difference between the color of the blood in arteries and veins, the latter being very dark.

Slight blanching of the optic nerve has been observed in syncope.

4. **Hyperemia.**—Hyperemia of the optic disk exists, but is of little diagnostic importance. It is in fact very difficult, because of the physiological variations, to determine whether a state of hyperemia does or does not exist, except in cases in which the disks can be compared and are found to differ decidedly, and in conditions of inflammation. In hyperemia the normal pink tone is deepened, the physiological cup assumes the color of the surroundings, parts of the disk and the outlines of the disk become less clearly defined, in part—because the color of the disk approaches that of the surrounding retina and in part because the congestion passes the border of the disk in the thick layer of nerve fibers. Cases which suggest *simple* hyperemia of the disk merit careful examination with the ophthalmoscope, both by the direct and indirect methods. When to congestion of the disk is added exudation, the condition is then termed inflammation. Simple hyperemia may be transient or it may be a chronic

condition attending a general hyperemia of the optic nerve, preceding atrophy.[1]

Etiology.—Hyperemia of the optic disk may exist (*a*) as a result of *general disease*, as in some cases of advanced diabetes mellitus, and in congenital cardiac malformation. The congestion accompanying these conditions is chiefly venous. In the acute stage of lobar pneumonia with high arterial pressure. (*b*) In *disorders of the nervous system*, as during acute mania; in cerebral embolism in some cases (Gowers); after the excessive ingestion of alcohol, after inhalations of the nitrite of amyl. (*c*) As a result of *functional disturbances*. Eye strain, due to errors of refraction, particularly to hyperopia and astigmia, occasionally in neurasthenia and asthenopia. Hyperemia of the disk as a result of these conditions is not frequent, and in itself is of no particular importance. (*d*) As a result of *traumatism*. Injuries of any kind to the eyeball or to the optic nerve itself, or blows on the head, may bring about congestion of the optic disk affecting all of its vessels. If congestion does not deepen into inflammation the condition subsides without permanently affecting the nerve. (*e*) As a forerunner of inflammation of the optic papilla and nerve. The hyperemia preceding inflammation may be very transient or it may be of long duration. Thus, in acute optic neuritis accompanying meningitis the hyperemia may last but a few hours, while in that preceding and accompanying retrobulbar neuritis it may be present for many days without evidence of exudation or other products of inflammation, finally disappearing, to be followed by the pallor of atrophy.

Treatment.—The treatment of hyperemia is the treatment of the cause which produces it.

Hemorrhage.—Hemorrhage into the tissues of the optic nerve back of the lamina cribrosa is apparently of very rare occurrence, but hemorrhage into the tissues of the optic disk or papilla is frequently seen. It may be due to any cause that affects the walls of the blood-vessels sufficiently to permit the escape of the red corpuscles of the blood. The causes may be classified as (*a*) general disease—chlorosis, syphilis, pernicious anemia, diabetes mellitus, nephritis, arteriosclerosis, grave cardiac disease, and profound malarial poisoning. (*b*) Local: embolism or thrombosis of the central artery, thrombosis of retinal veins. papillitis of all varieties, and traumatism.

Hemorrhage into the optic papilla occurs in the layers of nerve fibers. These radiate from the disk. The effusions of blood consequently assume a fan-, wedge-, or flame-like shape. The hemorrhages are frequently unilateral. Except in arterial sclerosis and traumatism the hemorrhage occurs from the veins.

Hemorrhage into Sheath.—Extravasation of blood into the sheath of the optic nerve may occur, but is by no means frequent. The hemorrhage may extend into and distend the sheath of the optic nerve from the cranial cavity, the blood coming from the meninges (Gowers), from rupture of an aneurism of the middle cerebral artery, and from hemorrhagic

[1] Gowers' Med. Ophthalmoscopy, 3d ed., p. 47.

pachymeningitis. Reported cases indicate that the condition is more frequently bilateral than unilateral.[1]

Results.—In regard to the effect on the optic nerve, the hemorrhage may be considerable and produce no other effect than a slight hyperemia of the disk (Elschnig). According to Knapp and Liebreich, a pigmentation of the outer peripheral part of the disk may result. The author has observed a case in which a relatively large deposit of black pigment occurred in the centre of each optic disk. The pigmentation appeared about seven weeks after the hemorrhage. Edema of the disk with whitish plaques of exudation (mild choked disk) was present for a few days after the hemorrhage.

Optic Neuritis.—The study of pathological conditions makes it evident that inflammation of, and degenerative changes in, the optic nerve may involve part or the whole of the visual tract from its ocular end to the basal ganglia Since the diagnosis is based on the clinical picture, a classification as follows is rational.

1. *Papillitis.*—Inflammation of the nerve in which the most prominent feature is due to changes in the nerve head.

2. *Retrobulbar Neuritis.*—Cases usually characterized by the development of central scotoma with or without papillitis, the papillitis when it occurs being of a mild variety.

3. *Optic-nerve Atrophy.*—Manifested only by loss of vision and ultimate paleness of the optic disk.

4. *Neuroretinitis.*—In this retina and nerve are both involved. (These have been described with diseases of the retina.)

Papillitis.—General Characteristics.—Papillitis from whatever cause presents certain appearances and conditions in common. The disk becomes hyperemic, the principal *arterial branches* are slightly changed in size. In the very early stage they may be enlarged, but they assume a normal size or are smaller than normal within a few days after the onset. With swelling of the tissue of the papilla they become *slightly* tortuous. On the disc the arteries are more obscured than the veins.

Veins.—The veins rapidly become enlarged and assume a darker color than normal, consequent on venous congestion, the congestion being due, in part at least, to obstruction to the outward flow of blood. They become tortuous, the tortuosity being very marked in the forms of papillitis in which the swelling is greatest. At the disk, the wavy distor-

[1] Priestley-Smith (Trans. Ophth. Soc. of United Kingdom, 1884, p. 271) reports the history of a man who had an epileptic attack the day after a fall. He died on the twelfth day. Autopsy revealed a large subdural hematoma with destruction of the inferior frontal gyrus. There was hemorrhage into the subdural space in the sheath of each nerve and the subarachnoid spaces of the sheaths were filled with a colorless fluid. Schnaudigel (Graefe's Arch., xlvii, p. 490) reports the case of a patient who suffered from epileptiform attacks. He finally passed into a somnolent condition and was taken to an asylum for the insane. Hemorrhages were found beneath the conjunctiva and skin of the lids. The left disk was hyperemic and swollen; arteries normal; veins reduced in size. There were many linear hemorrhages along the vessels. The patient died. On autopsy the orbital portion of both nerves was found enlarged, the enlargement being ampulliform immediately back of the globes. Hemorrhages were found in the nerve trunks and in the subvaginal space. The ampulliform swelling was due in part to hemorrhage and in part to the presence of serosanguinolent fluid.

tion of the veins is largely in the antero-posterior plane. The portions of the veins that approach the surface of the disk become plainly visible, while the parts that dip deeply into the tissue of the disk are obscure. The middle of the visible sections of the veins presents a purple appearance, while the ends of the sections which dip so abruptly that the axis of the vein presents toward the pupil often appear almost black, as the column of blood is seen in cross-section. The tortuosity of the veins is continued into the surrounding retina, but here the plane of the tortuosity corresponds to the surface of the retina.

Fig. 243



Acute optic neuritis. Note disk much swollen: estimated at × 7 D. Edge indistinct; vessels obscured at edge; large number of hemorrhages around the disk; patches of edema in the retina; veins very tortuous. (Posey and Wright.)

The margins of the disk are obscured by the edema and the swollen nerve fibers. The area of the disk appears to be much increased and somewhat irregular in outline, frequently gradually shading off into normal retina.

Color.—The color of the disk depends much upon the quantity and character of the exudation. If there is but little exudation, and that of a cellular nature, the color is a light red if arterial, or dark red, if venous congestion preponderates. If the exudation is serous or seroplastic, the color may be lighter as a whole than the surrounding retina; in those cases in which the exudation contains many leukocytes or is serosanguinolent the color of the disk will have a yellow tone. Light-colored spots, due to exudation, may appear on the papilla or in the adjoining retina. When hemorrhages occur, they are usually small and plainly visible.

Elevation.—The swollen tissues of the disk project above the level of the retina to a degree depending upon the amount of exudation and the thickening of the tissue elements of the papilla. The elevation seldom exceeds $1\frac{2}{3}$ mm. It is usually less than 1 mm. On the degree of elevation an arbitrary classification of papillitis has been based (Uhthoff). If the elevation does not exceed $\frac{2}{3}$ mm., it is termed optic neuritis; if more than $\frac{2}{3}$ mm., it is termed choked disk. Subsidence of papillitis may take place at any stage, either spontaneously or as a result of treatment. In all forms of papillitis the inflammatory disturbance is most pronounced in the portions of the disk over which the layer of nerve fibers is thickest, namely, the upper, lower, and nasal sides. Whitish radiating striæ can be seen passing from the disk onto the retina over these borders, in almost all cases, particularly in the early stage of the affection. This is due to the layer of nerve fibers which becomes visible because of the exudation around or edema of the fibers. The normal disk presents this appearance in small degree under favorable conditions. (See appearance of the normal fundus.)

Etiology.—The causes that produce papillitis may be classified as follows:

Classification of Causes.—*Local.*—Diseases of ethmoidal, frontal, and sphenoidal sinuses, nasopharnyx, posterior parts of nasal cavities, cellulitis of orbit, periostitis of orbit, wounds of orbit, tumors of orbit, thrombosis of orbital veins and their tributaries, wounds or tumors of the optic nerve and chiasm, wounds of the globe, erysipelas.

Intracranial.—(1) Meningitis: traumatic, tubercular, syphilitic, pyemic, epidemic cerebrospinal; (2) tumors; (3) abscess; (4) aneurism.

General Causes.—Heredity, acute febrile diseases, emphysema of lungs, albuminuria, uterine diseases, influenza, anemia, chlorosis, diabetes, malarial poisoning, inherited or acquired syphilis, poisoning from lead, leukocythemia, pyemia, acromegaly, lavage of stomach.

Heredity.—In some families optic neuritis, followed by partial or complete atrophy of the optic nerve, occurs. The neuritis may be of the acute retrobulbar variety, but it is more frequently of a chronic nature, progressing until eventually a marked degree of amblyopia results. Complete loss of vision may result. The affection occurs in individuals at the age of puberty and in young adults. Sonyo[1] reports retrobulbar neuritis in a male, aged nineteen years. The mother, two brothers, and two nephews suffered in the same way. Westhoff[2] traced the occurrence of retrobulbar neuritis through three generations. Hereditary optic neuritis affects males much more frequently than females. Both eyes are involved. The early ophthalmoscopic picture is that of mild papillitis, which gradually changes to that of partial or complete atrophy.

Treatment.—Treatment should be directed to the improvement of the general condition and to the correction of any dyscrasiæ that may be present. The iodides and mercury in small doses may be of service. Strychnine hypodermically should be employed.

[1] Zeh. klin. Monatssch., xxx, p. 256.

[2] Centralbl. f. Augenheilk., xix, p. 168.

Syphilis.—All degrees of papillitis may result from syphilis. The optic nerve may be affected throughout its entire course, or any part of the nerve may be the site of the inflammation. When the ocular end of the nerve is affected, the papillitis resulting is usually moderate in degree. Syphilitic neuritis is seldom confined to the papilla, but extends into the retina (neuroretinitis). The condition is accompanied by marked perivasculitis, exudation and hemorrhages, with perivascular infiltration of small cells. Inherited as well as acquired syphilis may produce optic neuritis.

Diagnosis.—If the papillitis is accompanied by evidence of perivasculitis, the exudation marked, and hemorrhages numerous; particularly if these changes tend to involve the retina, syphilis should be suspected. If there is a doubt regarding the cause, antisyphilitic remedies should be used energetically.

Erysipelas.—The affection of the optic nerve due to erysipelas is always a part of the general inflammation of the tissues of the orbit. The papillitis resulting is usually one of much severity. The arteries become reduced in size and the veins greatly engorged. Venous stenosis is very pronounced. Hemorrhages and exudation occur on the disk and extend into the retina. The condition is usually bilateral.

Results.—Atrophy of the optic nerve with complete loss of vision occurs in almost all of the cases; however Weiland[1] reports a case in which complete recovery took place in two weeks, transient total blindness having occurred. The diagnosis is easily made, as erysipelas of the face always accompanies or just precedes the affection of the optic nerve.

Treatment.—In addition to the treatment of the erysipelas, diaphoretic (Weiland) treatment is recommended.

Influenza.—The papillitis due to influenza is of the acute retrobulbar variety. The degree of *papillitis* is mild, amounting to little more than a very decided congestion. Both eyes are usually affected. The neuritis advances rapidly, coming on eight to twelve days after the onset of the influenza, and is preceded by severe orbital and frontal pain. The diminution in vision may take place in twenty-four hours. The scotoma, which is central, may be relative or absolute; may be very small and quite regular or large and irregular; partly or wholly paracentral. Ophthalmoscopically the picture is that of a mild papillitis in the early stage. Paleness of the lower outer segment of the disk, the place of entrance of the macular bundle of nerve fibers, appears as the acute stage passes.

Diagnosis.—The history of the case must be depended upon in making the diagnosis.

Prognosis.—This is favorable for improvement in the greater number of cases. The writer has observed two cases in which the central scotoma was absolute; in both cases the defect existed for about two years; both eyes were affected and vision, which was eccentric, was reduced to about $\frac{20}{200}$. Central vision of $\frac{20}{30}$ was eventually obtained in both cases. Optic atrophy with complete blindness may result from influenza.[2]

[1] Deutsch. med. Woch., 1886, No. 39.

[2] Macnamara, Brit. Med. Jour., 1891, p. 251.

Treatment.—General tonic treatment appears to be of most service.

Exposure (Rheumatic) Optic Neuritis.—The neuritis due to rheumatism is also of the retrobulbar variety. As a rule, one eye only is affected. The neuritis comes on after exposure to inclement weather or to severe cold, one side of the face being more exposed than the other. The optic neuritis is preceded by severe frontal and temporal pain for some hours and in some cases for several days. The character of the process is much like that developed in influenza, but the scotoma is seldom absolute.

Diagnosis.—From the history of the case.

Prognosis.—Favorable, but recurrences may take place.[1]

Treatment.—Antirheumatic. The iodides and mercury in small doses, in addition to the salicylates. The latter should be given in large dose.

Malaria.—The papillitis accompanying malaria is of a more general nature. Distinct central scotoma is seldom present. The vision does not fall below $\frac{20}{50}$, except in the rare cases which pass into complete atrophy. The tendency to hemorrhage is marked, small hemorrhages occurring on the disk and on the adjacent retina. The neuritis is of a mild degree, the engorgement of the veins being out of proportion to the other changes in the papilla.

Diagnosis.—This depends upon the history of the case.

Prognosis.—Generally favorable; in rare cases blindness results.

Treatment.—Antimalarial.

Chlorosis.—The papillitis due to this cause may be mild or it may be very intense. Gowers,[2] Ditsch,[3] and others report cases. The condition may be quickly corrected by the administration of iron, but in some cases partial atrophy follows. Gowers noted a recurrence in one of his cases on recurrence of the chlorosis.

Bright's Disease.—Papillitis varying in intensity from a slight hyperemia to choked disk may be due to Bright's disease. In exceptional cases the retinal disturbance may be almost *nil* until the papillitis is well developed, but it seldom occurs that changes in the retina cannot be discovered on careful examination. In neuritis from Bright's disease the conditions are much the same as in neuritis from other causes, except that exudation *en plaque* is more common and the marginal radiating striations are more pronounced. In this form of neuritis, hemorrhages may occur on the disk, and in the retina in the immediate vicinity they are often absent or very few in number. The neuritis is usually binocular, but may be monocular. Vision gradually declines, and though it may remain for some time without great impairment, eventually becomes greatly reduced and may be entirely lost.

Prognosis.—Neuritis is followed sooner or later by involvement of the retina, and a lethal issue is the result at the expiration of a few months or years.

Treatment.—See Bright's retinitis.

[1] Katz, Wjest. Ophth., 1895, Nos. 4 and 5.

[2] Med. Ophthalmoscopy, p. 244.

[3] Klin. Monatsbl., 1879, p. 144.

Toxemia.—Optic neuritis which results in diminution of vision with mild papillitis occurs in cases in which the history points decidedly to toxemia. An example of this particular form is the following. Male, aged eighteen years, apparently robust and healthy came for treatment, complaining of diminution of vision and flashes of light in the right eye, which had been noticed for three or four days. About one week previously the patient had suffered from severe gastro-intestinal irritation.

The disturbance of the intestinal tract subsided in three or four days. The ophthalmoscope revealed mild papillitis without hemorrhage. Vision, $\frac{20}{40}$. Central color perception not as good as in the paracentral zone, but not abolished. Field of vision normal in extent. Refraction virtually normal. No history of rheumatism or syphilis. Blood examination negative. Careful examination by a competent physician failed to discover any condition of the system that could be considered causative, except the ptomaine poisoning.

Typhoid Fever.—Papillitis, which does not reach the degree to which the term choked disk is applied, may occur in typhoid fever. The affection of the nerve comes on late in the disease, and is sometimes followed by partial or complete atrophy. Such cases are rare, but a sufficient number have been reported to establish the fact.[1]

Diphtheria.—Papillitis after diphtheria is rare, but has been observed by many. The papillitis is usually of a mild form and occurs in two to four weeks after the diphtheritic membrane has disappeared (as does the neuritis of other nerve trunks). It usually passes away without impairment of vision. It is, with few exceptions, bilateral. Gowers[2] has observed almost complete atrophy following optic neuritis after diphtheria.

Periostitis.—Cases of retrobulbar neuritis with papillitis of mild degree as a result of periostitis, particularly about the foramen opticum, have been described. Moll[3] mentioned a case of recurrent retrobulbar neuritis which he attributed to this cause, and which resulted in partial atrophy. Deutschmann[4] mentions some cases which he ascribes to this cause, of rheumatic origin.

Arteriosclerosis.—A form of chronic retrobulbar neuritis, with mild papillitis, is rarely produced by atheromatous or sclerotic changes in the walls of the central artery. The interference with nutrition and pressure occasioned by the increase in the size of the artery, caused gradual death of some of the apex fibers of the papillomacular bundle. Under such conditions the scotoma is absolute and is not strictly central.

Traumatism.—The papillitis due to traumatism and to orbital or intracranial disease may be of the form that presents but little elevation of the disk, or may reach the degree of swelling that entitles it to be termed choked disk.

[1] Gowers, Med. Ophthal., p. 280; Braen-Hartwell, Brit. Med. Jour., 1897, p. 1344.
[2] Med. Ophthal., p. 290.
[3] Centralbl. f. prakt. Augenheilk., xviii, p. 269.
[4] Beiträge zur Augenheilk., vi, 899.

Choked disk.—Excessive papillitis, Stauungspapille.

Etiology.—Excessive swelling of the intra-ocular end of the optic nerve is probably due in almost all cases to some degree of strangulation or interference with return circulation involving lymph or blood-streams. The results of actual inflammation are present only in those cases in which the process is due to infection of some kind. Quite a large percentage of the cases of choked disk are apparently cases of pure strangulation edema.

Fig. 244

Choked disk.

The causes of choked disk that are most likely to produce *inflammatory products* are traumatism, with infection, purulent processes occurring in and about the orbits, septic meningitis, brain abscess from whatever cause, and degenerating cerebral blood-clot.

Choked disk in which edema is the prominent feature is caused by orbital or intracranial neoplasms. The neoplasms may be glioma, sarcoma, rarely epithelioma, tubercle and gumma; other causes are pachymeningitis, basilar meningitis (Leszynsky), cysts due to the presence of entozoa.

Symptoms.—Choked disk of a decided inflammatory character is inclined to extend into the retina. The color of the disk is not so light as in the non-inflammatory form, and in the early stage it may be as dark (in rare cases darker) in color as the surrounding fundus.

The non-inflammatory variety extends but little into the adjacent retina, presents a "woolly," tuft-like appearance. The surrounding retina is apparently perfectly normal, except for the slight change in the vessels. Hemorrhage occurs only in a small percentage of the cases.

The color is usually a light grayish yellow. Radiating striations are present, particularly in the earlier stage.

Choked disk may occur at any age. It may affect one eye only (rarely), but in the great majority of cases it affects both eyes. Commonly one eye is affected more than the other. According to most writers, the eye first affected affords no evidence of the site of the lesion, but according to Victor Horsley[1] it almost invariably occurs on the side of the lesion.

Course.—The course of choked disk may be divided into three stages: (1) The acute; (2) the subacute stage, or stage of recession, and (3) the stage of atrophy.

Fig. 245



Choked disk in cerebellar tumor. Vertical section. Author's case. (Photograph by Geo. S. Dixon.)

Acute Stage.—The time required to develop choked disk varies from one to six weeks.[2] It is more rapid in the inflammatory form. Congestion, mild or intense, is first observed. The acute stage may last for some weeks, gradually passing into the subacute stage, in which the color changes, the disk becoming paler, the evidence of congestion being less.

The *Subacute Stage* (Stage of Recession).—This may last from one month to three years. During this time the *height* of the swollen disk may decrease but little, but in many cases it gradually diminishes.

Stage of Atrophy.—The disk is now pale, presenting a color which varies from a dirty, pale yellow to chalky white. The lamina cribrosa is not visible. (In the cases of atrophy without papillitis the lamina cribrosa is visible and the margin of the disk is apt to be slightly irregular.) The obscuration of the lamina cribrosa and the irregularity of

[1] Trans. Brit. Med. Assoc., 1906.

[2] The writer observed the development of choked disk in a case of rapidly developing gliosarcoma of the brain. The first symptoms were hyperemia of the disk and enlargement and tortuosity of the large retinal veins. At the end of ten days these symptoms were intensified. Typical choked disk was established at the end of five weeks.

the margin of the disk are due to the presence of newly formed connective tissue. The optic disk is said to be "filled in." In all except the mildest cases there is more or less disturbance of the margin of the chorioid and of the retina in the immediate vicinity of the disk. This is appreciable after the papillitis has subsided and is seen with the ophthalmoscope as an irregularity in the arrangement of the pigment of the retina and of the chorioid. It is due to the pressure of the swollen tissue of the disk (Fig. 245) on these membranes where they are in apposition with the optic nerve. The "filled-in" appearance of the disk and the irregular disposition of the pigment of the retina and chorioid around the disk, particularly on the nasal side, make it possible to diagnose optic-nerve atrophy *after papillitis* from atrophy *without papillitis.*

Effect on Vision.—The effect on vision varies greatly in different cases. A great reduction in vision may take place two or three days after the commencement of the papillitis and may rapidly pass to almost complete loss. This sudden effect on vision occurs in the cases of neuritis with papillitis due to infection—the cases in which the effect on vision is a consequence of the optic neuritis and not due to pressure on the nerve, chiasm or tract or to destruction of the visual centres. In cases of pure edema the vision may be retained with but slight impairment for many months.[1]

The progress of the failure of vision affects the *field of vision* differently in different cases, according to the degree of involvement of the different bundles of optic-nerve fibers and the effect on the nutrition of various parts of the retina. Central as well as peripheral vision suffers, as a rule. In cases of great loss of vision the contraction of the field of vision is from the periphery. Sector-like defects and paracentral scotomata may occur.

Mechanical Cause.—Authors are divided in regard to the influence of intracranial pressure in the production of choked disk. Schwalbe[2] demonstrated the fact that the subvaginal space of the optic nerve was continuous with the subarachnoid space; subsequently Schmidt and Manz[3] advanced the theory that increased intracranial pressure influenced the head of the optic nerve by the passage of subarachnoidal fluid into the subvaginal space, causing distention of the optic-nerve sheath. Experiments directed to the production of choked disk by increasing the intracranial pressure have been confirmatory with some investigators,[4] apparently negative with others.[5] The experiments of Mertz[6] remove all doubt of the influence of pressure in the production of choked disk. In experimenting on dogs, he showed conclusively that an increase of intracranial tension by 15 to 20 mm. of mercury brings about venous hyperemia

[1] The writer has observed a case in which the acute and subacute stages combined lasted two and one-half years. The vision in the right eye = $\frac{20}{40}$ at the end of the second year, when it gradually failed and was *nil* at the end of two and one-half years. The left eye = $\frac{20}{30}$ at the end of two years. At the present time, five years from the date of the onset of the papillitis, the vision of the left eye = $\frac{20}{40}$; disk pale. The case was one of cerebral syphilis.

[2] Centralbl. f. d. med. Wissensch., 1869.

[3] Deutsch. Arch. f. klin. Med., 1871, ix, p. 339.

[4] Manz, Shulten, Knapp (Intracranial Growths, 1861).

[5] Schmidt-Rimpler, Deutschmann, Adamkiewicz (Neurol. Centrabl., 1893, p, 802).

[6] Knapp's Arch., xxx, p. 349.

and arterial anemia in the retinal vessels in a few hours and edema of the disk soon follows. Postmortem examination disclosed distention of the subvaginal space and the presence there of granules of ink that were contained in the fluid that was introduced just beneath the dura through the opening made in the skull.

Some writers (Schmit-Rimpler, Leber, Parinaud) admit that distention of the optic-nerve sheath and consequent pressure on the optic nerve may exert some influence, but hold that this alone is not sufficient to produce choked disk. They insist on the presence of some irritating substance in the fluid that fills the subvaginal space. Gowers is of the opinion that "there is little evidence that a mechanical impediment to the return of blood from the eye, induced either by intracranial pressure, by distention of the optic sheath, or by pressure of the scleral ring, ever plays any considerable part in the production of optic neuritis." Gowers also states that "in cases of cerebral tumor evidence of ascending inflammation may be traced in sheath or nerve much more commonly than current statements suggest." This opinion is based on microscopical examination of the optic nerve in cases of papillitis.[1]

Elsching[2] reports the examination of 55 cases of choked disk. He found evidences of inflammation in all.

In all probability the truth regarding the production of papillitis warrants the acceptance of the predominating features of the two principal theories. In the pure cases of edema of the papilla the obstruction theory applies with the greater force, and in the cases in which inflammatory products are evident the infective theory must be given more weight.

Pathology.—At the beginning there is dilatation of the capillaries and veins, and in some cases of the arteries. In the cases due to the presence of microörganisms or their products, as in the neuritis accompanying influenza, syphilitic and tubercular meningitis, purulent processes in the orbit or brain (abscess) or affecting the meninges of the brain, and in those cases in which toxic substances are present (in cases of regressive cerebral hemorrhage, pachymeningitis, etc.), the products of inflammation, namely, small cells, plastic exudation, and hemorrhages, soon appear, with the exudation of serum. These products occupy enlarged spaces between the nerve fibers, anterior and posterior to the lamina cribrosa. Posterior to the lamina cribrosa the avenues for the escape of fluid products are not greatly obstructed, consequently the nerve itself is not

[1] Examination of the tissues in five cases of choked disk accompanying brain tumor made by the writer resulted as follows: Distension of the subvaginal space in all but one case. Infiltration of small cells in the sheath in one case, in the papilla—not very marked—in two cases. Arteries small at and anterior to the lamina cribrosa in all cases, posterior to the lamina cribrosa in one case. The veins are dilated anterior to and reduced in diameter posterior to the lamina cribrosa. There are hemorrhages from the capillaries in the papilla. The following conclusions were reached: (1) In many cases of papillitis there is little evidence of true inflammation, but the condition is that of an engorgement edema. (2) In a number of cases there is evidence of marked inflammation. To the former class belong the cases of greatest elevation of the papilla, the typical Stauungspapille—to the latter belong the cases of slight elevation, intensely injected disk, with a tendency to extension of the process into the retina, hemorrhages, plastic exudation, etc.—the true inflammatory papillitis.

[2] Trans. Soc. of Ger. Nat. and Phys., Vienna, 1894.

greatly enlarged, although some increase in its diameter occurs. On account of the unyielding nature of the lamina cribrosa, sudden increase in the tissues of the head of the nerve necessarily causes more or less constriction of lymph and blood-channels, and the result is a decided enlargement of the intra-ocular end of the optic nerve—the papilla, the enlargement extending anteriorly and laterally. The inflow of blood is reduced as evidenced by the diminution in size of the arteries, and the outflow is interfered with as evidenced by the enlargement and tortuosity of the veins. In the cases in which the bacterial and toxic influences are at a minimum the exudation is albuminous apparently, coagulating in the tissues.

The nerve fibers in the nerve and papilla become swollen and varicose and may eventually lose their function. In a large percentage of cases of choked disk the subvaginal lymph space becomes distended, presenting an

Fig. 246

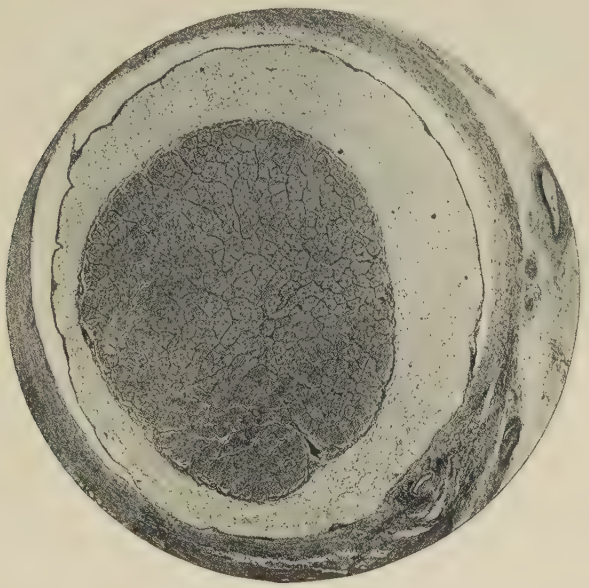

Cross-section of optic nerve in choked disk in a case of cerebellar tumor. The subarachoid space is filled with a fibrinous secretion.

ampulliform enlargement immediately back of the globe. This space is filled with a serous fluid resembling and probably identical with the cerebrospinal fluid. The enlargement gradually diminishes toward the optic foramen. The perivascular lymph spaces, particularly anterior to the lamina cribrosa, are distended.

When the atrophic stage is reached the optic nerve is reduced in size; the nerve head (papilla) is occupied by a thin layer of cicatricial tissue ("filled in"); the blood-vessels are reduced in size, the arteries often becoming very small, their walls being *thickened* as indicated by the white

lines that are seen on either side of the column of blood. In extreme cases the lumen of the arteries is obliterated, their remains being represented by small, white, thread-like cylinders of tissue.

In a case of cerebellar tubercle with blindness after choked disk, Rochon-Durigneaud found that the axis cylinders were the first to disappear, the myelin sheaths changing subsequently.

The Diagnostic Value of Choked Disk in Brain Disease.—The early stage of papillitis produced by any cause, unaccompanied by other pronounced symptoms, can not be distinguished from the early stage of the papillitis accompanying brain tumor, but after papillitis is established its appearance is sufficiently characteristic to enable the observer to eliminate many of the causes enumerated.

Frequency of Occurrence of Papillitis in Brain Tumor.—Oppenheim estimates that optic neuritis is present in 82 per cent. of the cases of brain tumor. Gowers is of the opinion that it is present in four-fifths of the cases. Knapp found 11 cases of neuritis and 2 of atrophy in 18 cases of intracranial tumor—72.2 per cent. Annuske and Reich found neuritis present in 95 per cent. of the cases examined. Dana estimates it at 80 per cent. In Bernhardt's table of 485 cases, an ophthalmoscopic examination was made in 154 cases, and choked disk found in 104, or 66.2 per cent. In 601 cases collected by Martin, the fundus was examined in 590 and optic neuritis or atrophy found in 77.3 per cent. In 27 cases described by Bramwell, 24 were examined ophthalmoscopically and 20 found to have, or to have had, optic neuritis, or 83 per cent. The average of those given would be 78.2 per cent., which is probably very near to the actual frequency.

Location.	No.	No optic neuritis.	Unilateral.	Double optic neuritis.	Per cent.
Frontal lobes	64	12	4	48	80.3
Temporosphenoidal	24	9	0	15	62.5
Motor area	113	46	3	64	59.2
Parietoöccipital	33	4	3	26	87.8
Brain surface	13	4	0	9	69.2
Centrum ovale	58	17	2	39	70.7
Corpora quadrigemina	19	0	0	19	100.0
Basal ganglia	36	14	0	22	61.1
Multiple	39	11	2	26	46.6
Corpus callosum	12	7	0	5	41.7
Pituitary body	18	9	0	9	50.0
Pineal gland	1	1	0	0	0.0
Crura	5	1	0	4	80.0
Pons	50	20	5	25	60.0
Cerebellum	164	21	4	139	87.2
Base of cranium	10	1	0	9	90.0
General	19	3	4	11	83.3
Totals	675	186	27	470	69.4

Relative Frequency in Tumor of Various Parts of the Brain.—From the cases collected, with the addition of cases observed by the writer, the above table, giving the percentage of choked disk or neuritis in the cases examined with the opthalmoscope, has been prepared. Cases tabulated as amblyopic or with optic atrophy, although many of the latter were probably postneuritic, have been omitted, except where it is stated that the atrophy was postneuritic.

Diagnostic Importance.—The following quotations from the writings of a number of prominent neurologists indicate the diagnostic value of optic neuritis from their point of view. Gowers says: "The most common causes of optic neuritis are encephalic diseases, and of these, tumor is incomparably the most frequent. Neither the nature, size, nor seat of the tumor appears to exercise much influence on the occurrence of neuritis." Otto Schwartz says: "The most important symptom in brain tumor is optic neuritis, double-sided, and not combined with retinitis." Dana's view is that, "Optic neuritis is one of the most frequent and important of all of the general symptoms of brain tumor," and Oppenheim, *Die Stauungspapille ist zweifellos das wichtigste Symptom des Hirntumors.* The view of Knies is: "Typical choked disk is almost the most important symptom in the diagnosis of brain tumor of whatever kind or wherever situated."

Location.	On side of lesion.	On opposite side.	Total.
Frontal	10	2	12
Temporosphenoidal	5	0	5
Motor	14	3	17
Parietoöccipital	2	4	6
Multiple	2	0	2
Basal ganglia	1	0	1
Centrum ovale	1	2	3
Corpora quadrigemina	1	0	1
Pituitary	0	1	1
Pons and medulla	4	2	6
Cerebellum	1	2	3
General	..	1	1
Total	41	17	58
Per cent.	70.7	29.3	..

Papillitis of the choked disk variety, with accompanying confirmatory symptoms, is of great diagnostic value in brain tumor, but when not associated with confirmatory symptoms it is of little value.

Localizing Value.—If we consider the localizing value of neuritis, whether unilateral or double, in cases of brain tumor, a glance at the first table will convince one that the papillitis alone is of no value whatever as a means of localizing the tumor. Tumor of the corpora quadrigemina gives the highest percentage, 100 per cent.; next comes tumor

of the parietoöccipital region, 87.8 per cent., with tumor of the cerebellum a close third, 87.2 per cent. Tumors of other parts of the brain follow so closely, however, that it would be folly to venture a guess as to location from this symptom alone.

In regard to the signification of unilateral papillitis, the foregoing table, which is that of Martin with some additions, indicates its diagnostic value.

The greater frequency of the occurrence of unilateral optic neuritis on the side of the tumor is conclusively shown by the table, but this fact is of no importance except in the frontal, temporosphenoidal, and motor portions of the cerebrum. In tumor occurring in these portions of the brain, the proportion is as 4 to 1 in favor of the tumor being on the side of the brain corresponding with the neuritis.

In regard to the kind of tumor, little can be determined by the papillitis. It is known that papillitis is most often absent in tubercular tumors, most frequent in glioma and cysts.

The size of the tumor appears to have no bearing on the development of papillitis.

Unilateral papillitis may be produced by direct implication of the nerve in the newgrowth, but this is only observed in a minority of the cases.

Prognosis.—In a very small percentage of the cases recovery takes place without impairment of vision; in the majority of cases the vision is more or less permanently impaired, and in quite a large percentage of the cases complete blindness results. Complete blindness may exist for a short time and subsequently a small degree of vision be restored. Dagilaiski[1] reports a case in which total blindness existed for three weeks; there was a history of syphilis. Antisyphilitic treatment caused a restoration of vision equalling 0.2. Reference is made to two similar cases reported by Uhthoff.

Recurrence.—It has been observed that choked disk may recur even when atrophy of the nerve has been produced (de Schweinitz and Thompson). Gowers reports the case of a "boy, aged twelve years, who had double optic atrophy, due to intracranial disease some years previously; distinct double papillitis occurred in the atrophied disks, associated with symptoms of intracranial tumor."

Treatment.—The cause of the papillitis should be carefully determined and removed if possible. With removal of the cause the papillitis ordinarily subsides. Thus it is found that the removal of a cerebral tumor[2] may cause the disappearance of papillitis and in some cases restore a certain degree of vision even when total blindness has existed for some days. Relief of intracranial pressure by trephining the skull and opening the dura mater without resection of the tumor[3] gives relief from the symptom of increased pressure, as headache and nausea, and causes the papillitis to subside. Horsley[4] advises making the opening in the skull in the

[1] Zeh. klin. Monats., xxxvi, p. 63.
[2] Sattler, Cincinnati Lancet-Clinic, December 26, 1896.
[3] Zeller, Berlin, 1895.
[4] Trans. Brit. Med. Assoc. 1906. Address in Surgery.

basal temporal region of the right side. Von Hippel[1] has collected 221 cases. He concludes that the prognosis for preservation of vision is good if the operation is not too long delayed. This effect is also obtained by drawing off cerebrospinal fluid by spinal puncture (Quincke's method), and subsidence of the edema of the disk with general improvement in the condition of the nerve is obtained after opening the sheath of the nerve as advocated by De Wecker and performed by him, Brudenell-Carter,[2] Bickerton,[3] and others. The improvement obtained by trephining, spinal puncture, and opening the sheath of the nerve may be only palliative, but the violence of the papillitis may be bridged over by these measures until curative treatment can be instituted. One or the other operation should be performed in all cases in which the papillitis causes diminution in vision.

Unless syphilis can be absolutely excluded, it is wise to give a course of antisyphilitic treatment.

If syphilis is the cause of choked disk, mercury and the iodide of potassium to the point of saturation should be given and continued until all symptoms have disappeared, and the system should be kept mildly under the influence of these remedies for some months longer. In case of annoyance from bright light, during affections of the optic nerve back of the eyeball, protective glasses may be worn.

Retrobulbar Neuritis.—This term is applied to a form of neuritis which has as a frequent feature the affection of the macular fasciculus of nerve fibers (see Fig. 260) and the production of a central scotoma. The scotoma is commonly relative, but may be absolute. Retrobulbar neuritis occurs as an acute and as a chronic affection.

Acute Retrobulbar Neuritis.—This is comparatively sudden in its onset. It occurs most frequently in individuals at the age of puberty and in early adult life. The central scotoma is not so marked or so constant a feature in this form as it is in the chronic form. Papillitis is observed to a greater or less degree in almost all of the cases. The degree varies from a mild hyperemia to a pronounced choked disk. One optic nerve only may be involved, but in the greater number of cases both are affected. Hemorrhages in the papilla seldom occur. When they do, they are small and seldom extend beyond the disk.

Bilateral hereditary retrobulbar neuritis (*Leber's disease*) occurs, and may affect a number of the members of a family. It affects young individuals, presents the usual symptoms of retrobulbar neuritis, and usually causes more or less permanent serious impairment of vision. Nettleship[4] reports a case occurring in a male, aged twenty-eight years, in which the vision was completely restored.

Chronic Retrobulbar Neuritis.—This occurs in two forms: *toxic,* due to the abuse of tobacco, alcohol, stramonium, etc. (see Toxic Amblyopia), and *retrobulbar neuritis proper,* which may be due to arterial sclerosis and hereditary influences and which will be discussed in considering the peculiarities of papillitis due to specific causes.

[1] Graefe's Arch., lxix, Heft 2.
[2] Ophth. Rev., viii, 304.
[3] Ophth. Rev., vii, 300.
[4] Trans. Oph. Soc. U. K., October 16, 1902.

Etiology.—Acute retrobulbar neuritis may be due to heredity, influenza, rheumatism, malaria, chlorosis, Bright's disease, ptomaine poisoning, metastatic infection, exposure to cold, erysipelas, typhoid fever, scarlet fever, measles, diphtheria, beriberi,[1] the puerperium, periostitis, disease of accessory sinuses, multiple sclerosis, and myelitis.[2]

Pathology.—There is an inflammatory condition of the sheath of the nerve and the interstitial connective tissue of the nerve, an increase in size and often in the number of the blood-vessels, serous or plastic exudation, and an infiltration of small cells. In many cases the other nerve trunks of the orbit are also apparently more or less involved. This is particularly so in retrobulbar neuritis due to rheumatism, influenza, exposure to cold and diphtheria.

Symptoms.—Acute retrobulbar neuritis is accompanied by painful symptoms in a large percentage of the cases. The painful symptoms frequently precede the intra-ocular changes and loss of vision. There is pain in and about the orbits; headache, frequently frontal and sometimes general, which varies in intensity and character. It may be of a neuralgic nature, but in the majority of cases it is quite constant and frequently severe. The period of pain is from two to ten days. The patient is not apt to have a relapse of pain. Movements of the eyeball and pressure on the globe often cause pain. Distress on attempts to use the eyes and photophobia are not uncommon. Retraction of the upper lids from tonic spasm of Müller's muscle is sometimes observed. Failure of vision may just precede the pain or may not become noticeable until the pain has existed for some days. Subjective visual disturbances are noticed as a rule soon after pain is experienced. These phenomena consist in flashes of light which are observable with the eye closed as well as open and changeable luminous forms sometimes sufficiently pronounced and persistent to be annoying, sometimes scarcely enough to be noticeable.

Fig. 247

Left

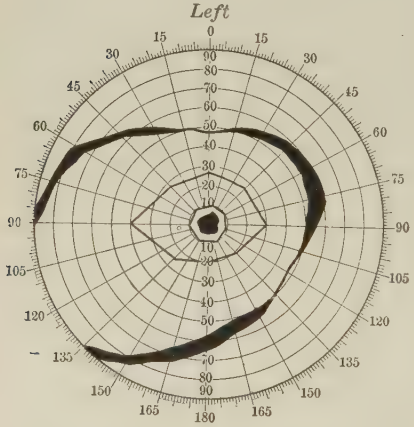

Field of vision from a case of retrobulbar neuritis. Very little contraction for form, but marked contraction for red and green, with an absolute central scotoma. From without inward the fields are white, red, and green.

Vision.—Failure of vision is seldom more than partial. Visual acuity may fall to $\frac{20}{200}$, but in the greater number of cases does not go below $\frac{20}{50}$. A central scotoma can usually be demonstrated. This may be relative, appreciable for colors only, and may be very small. It may

[1] Coppez, Bull. d. l. soc. belge d'opht., April 27, 1901.
[2] Scharz, Deutsch. med. Woch., 1893, p. 261.

be absolute and may be quite large. The form of the scotoma is usually approximately circular, the point of fixation at its centre, but, particularly when absolute, the outlines of the scotoma may be irregular, sector-like defects extending into the surrounding field. Partial paracentral scotomata may exist with the central defect. Absolute scotoma and irregular forms occur in the severer cases. Ordinarily there is no concentric limitation of the field of vision. However, in those cases which terminate in complete atrophy, loss of vision proceeds from the periphery. Loss of color perception exceeds loss of vision for form, in whatever part of the field of vision this may occur.

Prognosis.—In by far the greater number of cases the prognosis is favorable. The exceptionally severe cases only, as those resulting from erysipelas, beriberi, periostitis, and other diseases of the orbit and those accompanying multiple sclerosis and myelitis, result in complete blindness. In exceptional cases, permanent, relative, or absolute scotomata may be the result.

Treatment.—This must depend largely on the cause. The nature of the pathological changes makes it desirable in the majority of cases to administer remedies that tend to prevent the organization of plastic exudates and the development of new connective tissue. To this end the iodides and mercury, in small doses, long-continued, are of great service. Local treatment, except, perhaps, mercurial inunctions to the temples and forehead, is of little value.

Perineuritis.—This is an inflammation of the sheath of the nerve, resulting in exudation into the subvaginal space. One or both optic nerves may be involved.

Etiology.—Tubercular, syphilitic, or suppurative meningitis, periostitis of the orbit (Horner), gonorrhea, orbital abscess, erysipelas, traumatism affecting the orbit, and parotitis (Dor).

Pathology.—In all of the cases there is small-cell infiltration of the sheath of the nerve and exudation into the subvaginal space. This exudation differs in character according to the cause of the affection. In suppurative processes the exudation is purulent and granulation tissue may develop from the walls of the subvaginal space. In syphilis and in gonorrhea, the exudation is of a plastic nature, not purulent. In tuberculosis, tubercular masses, minute or large, may develop. Complete obstruction of the subvaginal space may follow. The process attacks the nerve by extension along the septa, and may be slight or profound. The trabeculæ become infiltrated with small cells, hyperplasia of connective tissue takes place, the blood-vessels are at first congested, new vessels forming in the granulation and in the hyperplastic tissues. In the late stage degeneration or cicatrization of the tissues involved takes place.

Symptoms.—Some degree of papillitis usually accompanies perineuritis; it may be absent. Slight congestion of the disk only may be present. Choked disk (Uhthoff) may be produced. Vision is affected in varying degree, according to the degree of involvement of the trunk of the nerve itself. The vision may vary with variations in the degree of the inflammatory process. Inflammation of the sheath commonly extends to other

tissues of the orbit, affecting other nerves and the ocular muscles. Pain, when it exists, is referred to the orbit back of the globe.

Diagnosis.—A positive diagnosis of optic perineuritis is seldom possible, but it may be inferred in those cases in which there is orbital periostitis, orbital abscess, or any of the causes in which diminution of vision and intra-ocular changes are present, with involvement of the ocular muscles. Gonorrheal perineuritis is associated with edema of the ocular conjunctiva, and may manifest no evidence of the involvement of other orbital structures.

Prognosis.—This depends on the severity of the perineuritis and of the condition from which it arises. Slight impairment of vision may result; the peripheral nerve bundles of the optic nerve only may perish uniformly or irregularly in the parts in which the inflammation is most severe. Total atrophy of the nerve may result.

Treatment.—This depends on the cause, for which careful search should be made. In tubercular perineuritis very little can be done other than to endeavor to influence favorably the system by change of air and proper tonic treatment to correct the tuberculosis. Injections of tuberculin may be beneficial. In syphilitic cases energetic antisyphilitic treatment should be instituted. In gonorrheal cases the urethritis should be corrected. Gonorrheal affections of the eye of the non-suppurative variety are favorably influenced by moderate, frequently repeated doses of the salicylates. The sodium or strontium salts may be employed. Surgical treatment may be necessary in suppurative cases. Liberation of pus and thorough drainage are to be sought.

Injury to the Optic Nerve.—Injuries to the optic nerve may be in the form of rupture, incision, laceration, compression.

Rupture.—This is an injury of considerable severity and is relatively rare. Hiem[1] reports a case in which a blow from a blunt nail caused a small lacerated wound of the upper lid and of the bulbar conjunctiva. There was no gross injury to the globe, but the optic nerve was torn across close behind the eyeball. Barck[2] reports a case of *avulsio bulbi.* A man was thrown from a wagon and struck on his face on some stones; he was not rendered unconscious. On rising it was found that his left eye was lying on his cheek attached to the orbit by the superior rectus muscle only. The optic nerve had been severed. The portion attached to the globe was 23 mm. long and was enclosed in its sheath.[3]

Incision.—This has been observed due to the entrance of a sharp instrument into the orbit.

Laceration.—By the passage of a foreign body, piece of steel or iron, *gunshot wounds,* etc., this injury may cause partial or complete destruction of the nerve.

Compression.—This may be brought about in a number of ways: (1) A blunt instrument, entering the orbit, may impinge upon the nerve at the apex of the orbit, wounds with the ferrule of an umbrella or

[1] Central. f. Augenheilk., xxi, p. 209. [2] Amer. Jour. of Ophth., December, 1898.

[3] Snell, Optic Atrophy and Allied Causes, Trans. Opth. Soc. of United Kingdom, xxii, p. 66, discusses the subject at length, and reports eighteen cases of injury.

walking-stick, the button of a fencing foil, etc., are of this character;[1] (2) pressure from a clot in the orbit, in the sheath of the nerve, or subperiosteal located at or near the optic foramen; (3) pressure from the bony wall of the orbit after fracture of the wall, or after fracture through the optic foramen. (See Fracture of Orbital Wall.)

Diagnosis.—The diagnosis of injury to the optic nerve is, of course, quite evident in cases of avulsio bulbi. Lacerating wounds of the optic nerve and injuries causing sudden and extensive compression of the nerve are followed by blindness which is sudden and complete. Compression of the optic nerve not very severe in character may cause partial loss of vision, the greatest loss being in the parts of the retina corresponding to the portion of the nerve most affected. In compression from subperiosteal clot the loss of vision comes on slowly, one to forty-eight hours, and may be partial or complete. This is also true of hemorrhage into the sheath of the nerve or into the orbit. If the traumatism affects the central vessels of the retina, the portion of the nerve near the globe, or if sudden traction on the globe is sufficient, marked intra-ocular changes may be present immediately after the injury. In severance of the vessels the condition is one of collapse of the retinal arteries, scarcely a trace of which can be seen; the blood remaining in the veins is dark in color. The blood column may be interrupted. The veins are small. A slight paleness of the retina about the disk and in the region of the macula, such as is found in embolism of the central artery of the retina, but of less degree, is present, due to slight serous effusion into the nerve-fiber layer of the retina; the "cherry red" spot observed in embolism of the central retinal artery is present only when the short ciliary arteries are uninjured. The optic disk is pale, but does not present the chalky whiteness of atrophy. In cases of sudden and violent traction on the optic nerve, congestion of the papilla with hemorrhages and exudation at and about the papilla may be present. In injury to the nerve affecting it at the apex of the orbit and in the cases of pressure from blood-clot affecting that part of the nerve, there may be no change in the fundus whatever until sufficient time (two to eight weeks) has elapsed to permit the descending atrophy to reach the papilla.

Prognosis.—As regards vision, the prognosis is bad in all cases except in those in which the injury is due to pressure from blood-clot Vision in these cases may be reduced to nothing, and as the clot shrinks or becomes absorbed, may be restored fully or in part. The chances for the restoration of vision are in inverse proportion to the duration of the suspension of the function of the optic nerve.

In cases of laceration of the nerve there is danger of the loss of whatever vision may remain by subsequent inflammation and degeneration.

Treatment.—The indications are to take measures to prevent subsequent inflammation in all cases of wounds and the prevention of the formation of cicatricial tissue of undue amount, organization of exudates and clot. The first may be met by properly cleansing the wound and render-

[1] Callan, Trans. Amer. Ophth. Soc., 1891.

ing it aseptic; the second by the administration of suitable remedies, of which the iodides and mercurials are the best.

Atrophy of Optic Nerve.—As a result of many morbid processes, the optic nerves waste away, the nerve fibers disappear, and the function of the nerve is abolished. Feilchenfeld[1] in analyzing 321 cases of optic-nerve atrophy found that 59 cases followed optic neuritis, 29 meningitis, 28 acute infectious diseases, 10 tabes, 3 multiple sclerosis, 4 nasal tumors, 5 hydrocephalus, 32 syphilis, 37 injury, 41 alcoholism, 7 exposure to cold, 31 were congenital, 3 due to cretinism, 7 pregnancy, 1 parturition, 7 cessation of menses, 4 embolism of central retinal artery, 4 diabetes, 4 apoplexy, 3 blindness from lightning, 2 arsenic intoxication.

Aside from loss of vision, there are changes in the intra-ocular end of the nerve which present appearances when viewed with the ophthalmoscope that vary according to the form of the atrophy.

Atrophy may be preceded by inflammation of the nerve manifest at the intra-ocular end of the nerve, papillitis, *consecutive* or *postneuritic* atrophy, or it may come on without visible inflammatory disturbance consequent on disease of the nerve back of the globe, of the chiasm, tracts, or basal ganglia, *simple* atrophy, *descending* atrophy. It may also follow certain diseases of the chorioid and retina, *secondary* or *ascending* atrophy.

Simple Atrophy.—Although visible inflammatory changes in the ocular end of the optic nerve are seldom seen in "simple" optic-nerve atrophy, it is undoubtedly a fact that slight congestion is present in the earliest stages in many cases, and in all probability a slow inflammatory condition exists in some part of the nerve. This is particularly true of hereditary optic-nerve atrophy, the atrophy of multiple sclerosis, and of general paralysis of the insane (Gowers). Simple atrophy occurs more frequently in males than in females and more frequently in adults than in children.

Simple atrophy may be classified as *primary* in those cases in which the loss of vision keeps pace with the changes in the disk, and *secondary* in those cases in which the "structural integrity of the nerve" is interfered with by trauma or some other cause, the atrophy being visible some time after vision has partly or wholly failed. The two forms cannot be differentiated by the ultimate appearance of the disk. The secondary atrophies are much more frequently unilateral.

Etiology.—Primary simple atrophy may be due to (1) tabes dorsalis, (2) lateral sclerosis, (3) disseminated sclerosis, (4) heredity, (5) general paralysis of the insane, (6) arterial sclerosis affecting the internal carotid, ophthalmic and anterior cerebral arteries, (7) parotitis, exposure to strong electric current, malformation of the skull, cerebral growths, syphilis associated with dropping fluid from the nose (cause unknown), diabetes, intermittent fever, toxic conditions, colds, sexual excesses, menstrual disturbance, gastro-intestinal affections.

Tabes Dorsalis.—In 100 cases of atrophy from all causes occurring in Schoeler's clinic,[2] 37 cases were in patients with spinal disease. Graefe[3]

[1] Inaug. Dissert., Kiel, 1896.

[2] Uhthoff, Graefe's Arch., xxvi, Ab. 1.

[3] Zeh. klin. Monatsbl., 1865, iii, p. 201.

PLATE XXII

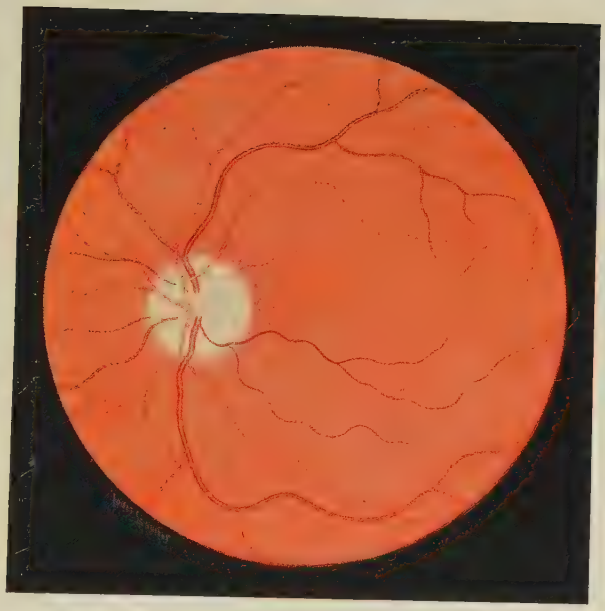

Simple Optic Atrophy.

estimates that 30 per cent. of all cases of atrophy of the optic nerve accompany tabes. The percentage of patients with tabes who suffer from impairment of vision from atrophy of the optic nerve is estimated by Gowers[1] as one in six. Of 178 cases of tabes reported by various observers collected by him, 14 per cent. had diminished vision. Atrophy of the optic nerve is an early symptom in tabes, usually preceding incoördination. In some cases atrophy precedes incoördination by many years. Gowers mentions one case in which the atrophy lasted twenty years "before the first symptoms of ataxy showed themselves." It seldom happens that some of the symptoms of ataxy are not present; either the lightning pains, the loss of knee-jerk, or the Argyll-Robertson pupil (see p. 122); one or all of these may exist with optic nerve atrophy for many years before other symptoms of ataxy can be detected. The atrophy advances with different degrees of rapidity in different cases; it may lead to blindness in six months or it may require many years. The progress of the atrophy may be arrested permanently, or for a time when it may again progress. Both eyes are affected almost without exception; it often happens that one eye is less affected than the other.

Diagnosis.—This is determined by the history and the presence of symptoms of tabes. The appearance of the disk is that of simple atrophy and the field of vision is one of concentric limitation. Central scotoma exists rarely, if ever.

Prognosis.—This form of atrophy, is as a rule, progressive, ultimately resulting in blindness. Not infrequently the progress is so slow that the patient does not perceive it, but perimetric measurements made at long intervals will show reduction in the extent of the field of vision. The history of the case and observation for a considerable length of time will enable the surgeon to form an opinion of the probable outcome.

Treatment.—Regulation of the patient's diet, habits, and mode of living must be the first consideration with a view to putting him in the best possible physical condition. Overwork, excessive mental strain, excessive sexual intercourse, etc., must be prohibited. It is generally admitted that syphilis is the cause of tabes in at least 95 per cent. of the cases. This gives an indication for treatment which is of value. Gowers is of the opinion that antisyphilitic treatment is of greatest value in those cases of tabes in which the length of time since the primary lesion has not been very great. Arsenic, iron, quinine, the iodides, mercury, nux vomica, nitrate of silver, calabar bean, belladonna have been advised. Aside from a general tonic treatment, the writer has obtained no benefit of moment in the attempt to arrest the progress of optic-nerve atrophy except by the use of the iodides and mercury. The treatment with mercury has been by inunction, keeping the patient at the point of saturation for from three to six weeks, then diminishing the dose. After six or eight weeks, the mercury is taken by the stomach or hypodermically, alternating with the inunctions, enough being taken to gently influence the system for one and a half to two years. The iodide of potash, in

[1] Med. Ophthal., p. 191.

moderate dose, taken at the same time appears to have a beneficial effect. The writer has found no special benefit in the use of strychnine.

Lateral Sclerosis.—Simple atrophy of the optic nerve having the same characteristics as that occurring in tabes occurs, but occurs rarely in lateral sclerosis. It does not require separate consideration.

Disseminated Sclerosis.—Burns and Stolling[1] examined 5500 cases of nervous disease in which there were 70 cases of multiple sclerosis; of these 21 or 30 per cent. had some affection of the optic nerve. The lesion in the nerve consists in patches of sclerosis similar to those which are present in the brain and cord. On account of the character of the lesion, the defects in the field of vision may be very varied. Central scotoma, sector-like defects, etc., may be present. The nerve fibers passing through the sclerosed patches may have their function only slightly impaired, causing a relative scotoma only. One optic nerve alone may be attacked, but there is usually some defect in both. The defect in vision may occur when there is no appreciable change in the optic disk. Sometimes a very slight neuritis is present in the early stage, particularly when a sclerosed patch affects the nerve immediately back of the eyeball. Secondary atrophy soon follows.[2]

Paralysis of the extra-ocular muscles may accompany the optic atrophy; nystagmus is frequently a concomitant symptom. The intrinsic muscles are seldom involved.

Etiology.—Heredity, family history of neuroses following acute illness, typhoid, scarlet fever, diphtheria.

Pathology.—The degeneration of nerve fibers appears to be secondary to a local subacute inflammatory process, the determining cause of which is unknown. The patch consists in an increase in connective-tissue elements and a degeneration of nerve fibers, the medullary substance suffering first.

Treatment.—Very little can be expected from treatment. Arsenic, iron, and quinine are advised. The system must be put in as good condition as possible.

Heredity.—The usual form of affection of the optic nerve from this cause is retrobulbar neuritis, but cases are on record[3] in which the atrophy was of the variety known as "simple" atrophy. The hereditary tendency is usually developed after an attack of acute illness, measles, scarlet fever, etc., or awakened at the stage of puberty. Consanguinity intensifies the tendency. A generation may be skipped.

Klopfer[4] has collected 214 cases of hereditary optic neuritis. Of these 87 per cent. occurred in males, 13 per cent. in females. It is well known that the affection is transmitted from one generation to the other, *through the mother* in the greater number of cases. The mother may have good vision, but belong to a family with hereditary tendencies. The time of onset ranges from the tenth to the fortieth year, but by far the greater

[1] Zeit. f. Augen., iii, Nos. 1 and 2.

[2] For an exhaustive consideration of affections of the eye in disseminated sclerosis, see Uhthoff, Untersuch. u. d. bei der multiplen Herdsklerose vorkomm. Augenstörung, Berlin, 1889.

[3] Heigier, Deutsch. Zeit. f. Nervenheilk., x.

[4] Inaug. Dissert., Tübingen, 1898.

number develop between the seventeenth and twenty-first year. The blindness occurs at about the same time in the same family. Hereditary syphilis (Higgins), tobacco (Hutchinson), alcohol (Keersmaecker), microbic infection (Boucheron), meningitis and perineuritis (Konig), and malformation of the skull have been given as causes, but nothing of sufficient constancy has been observed to make it probable that any one condition is accountable for all. The recent studies of Nettleship[1] tend to show that transmission from generation to generation follows the Mendelian law.

Treatment.—The general condition of the patient must be made as good as possible. In the way of remedies, mercury by inunction, iodide of potassium, and galvanization have been recommended. Injections of strychnine, the remedy being introduced into the temple daily for three weeks at a time, repeating the treatment every three months, have given temporary improvement in vision in the cases in which it was employed by Vossius.[2]

General Paralysis of the Insane.—Simple atrophy of the optic nerve occurs in 2 to 4 per cent. of the cases. Both eyes are usually affected, one often more than the other. As in tabes, the affection of the optic nerve occurs early in the disease. It has been known to precede general paralysis by four years (Magnus), but in the greater number of cases some symptoms of general paralysis are present when the amblyopia begins. In some of the cases reported, congestion of the papilla and papillitis have been observed.

Electric Current.—Atrophy of the optic nerve as the result of the passage of a strong electric current through the body has been recorded.[3]

Serous Discharge from Nose.—Atrophy of the optic nerve accompanying a serous discharge from the nose has been observed. In the case reported by Emrys-Jones, dropping of serous fluid from the left nostril had existed for twelve years. The fluid resembled cerebrospinal fluid. There was little or no pain in this case. Almost total blindness of the left eye, due to partial atrophy of the optic nerve, was present, and there were evidences of an atrophic condition of the right optic nerve. This condition had not been preceded by optic neuritis. St. Clair Thomson[4] has collected 21 cases. The discharge from the nose was persistent, coming usually from the left nostril. Optic neuritis or secondary atrophy occurred in eight of the cases. Violent headache, nausea and vomiting, epileptiform attacks, drowsiness, unconsciousness, delirium, and weakness of the lower extremities were the symptoms recorded. The symptoms varied widely in the different cases. When the fluid ceased to flow the symptoms became more violent. Leber regards the fluid as coming from the third ventricle and gaining the subdural space, passing into the nose either through a small opening in the cribriform plate of the ethmoid or by way of the lymph space surrounding the olfactory nerve. The

[1] Bowman Lecture, Ophth. Soc. of United Kingdom, 1909.
[2] Neuritis Optica. Infol. V. Hereditat u. Cong. Anlage, Halle, 1900, p. 18.
[3] Ulbrich, Correspondenzbl. d. ver. deutsch. Aerzte in Reichenberg u. Ung., 8, 1900.
[4] The Cerebrospinal Fluid; its Escape from the Nose, London, 1899.

affection begins in early adult life. The flow may cease for a few hours to a few months and become reëstablished, or it may stop entirely. Some of the cases are recorded as having died of meningitis; but few cases have been kept under observation.

Arteriosclerosis.—Arteriosclerosis affecting the central artery of the retina is an occasional cause of atrophy of the optic nerve.[1] In these cases the retina also suffers.

Aneurism.—Unless it presses on the optic nerve (blindness in one eye), the chiasm or the optic tract (hemianopsia), aneurism of the ophthalmic or internal carotid or anterior cerebral arteries does not cause degenerative changes in the optic nerve. Michel[2] reports a case of double cirsoid aneurism, affecting the two internal carotids, which was accompanied by double optic neuritis. The aneurisms pressed upon the optic nerve, producing interstitial inflammation.

Atheroma.—Atheroma of the walls of the internal carotid as it passes the chiasm, of the anterior cerebral arteries where they lie in close proximity to the optic nerves, and of the ophthalmic arteries as they pass through the optic foramina, may cause partial loss of vision by the effects of pressure on the chiasm or optic nerves. Such pressure produces very varied defects in the fields of vision, sometimes symmetrical, sometimes irregular. In all cases of obscure partial defects in the fields of vision due to optic-nerve affections the possibility of pressure from sclerosed vessels should be borne in mind. A careful examination of the vascular system should be made in such cases for confirmatory evidence.

Internal Hydrocephalus.—Affection of the optic nerve may be absent throughout, even if the hydrocephalus is sufficient to cause enlargement of the cranium. In the early stage atrophy of the nerve seldom occurs, but it is frequently accompanied by atrophy after the hydrocephalus has lasted some time. The papilla usually presents the appearance of simple white atrophy, but in some cases choked disk is present.[3] The atrophy of the nerves is usually due to the pressure of the distended third ventricle on the optic chiasm.

Malformations of Skull.—*Affections of the Optic Nerve Due to Malformations of the Skull.*—Hirschberg[4] reports three cases due to congenital or acquired malformation of the skull in early life. One case was of "tower" skull. There were early synostosis of the frontal bones and atrophy of both optic nerves following neuritis. In the second case the skull was brachycephalous; the sagittal suture ossified early. There was partial atrophy of both optic nerves; vision was almost entirely lost. The third case was one of leptocephalus accompanied by optic-nerve atrophy. Patry,[5] who has collected 64 cases, writes of the optic-nerve lesions as atrophy following neuritis. Meningitis at the base is regarded as the cause of the "tower" skull and of the affection of the optic nerve.

Excessive Sexual Intercourse.—Atrophy after excessive sexual intercourse affects males only. Cases from this cause are extremely

[1] Humelschein and Leber, Graefe's Arch., lii, p. 336. [2] Arch. f. Ophth., xxxiii, 2, p. 225.
[3] Wilbrand and Binswanger, Centralbl. f. med. Wissen., 1879, p. 923.
[4] Centralbl. f. Aug., vii, p. 1. [5] Annal. d'oculistique, April, 1905, p. 165.

rare, having occurred but twice in the private practice of the writer in 24,000 cases. It seldom occurs before the age of twenty-five and only after the excesses have been indulged in for a number of years. In the cases observed by the writer the ophthalmoscopic appearances were those of simple atrophy.

Hemorrhage at a Distance.—Atrophy after hemorrhage from a distant part of the system. (See Retina.) The atrophy of the optic nerve may become apparent a few days after the hemorrhage and blindness have occurred, or it may not develop for some weeks later. The appearance is that of simple atrophy.

Symptoms—*Ophthalmoscopic Appearances.*—The pallor of the optic nerve which is seen in "simple atrophy" in its uncomplicated form is due to the disappearance of the capillaries in the ocular end of the nerve and the increased distinctness of the connective-tissue elements of the nerve head in the absence of the nerve fibers. In simple atrophy the pallor is not a pure white, but is of a grayish tone, the shade of gray[1] varying in different parts of the disk, approaching white in the upper, lower, and nasal portions, where the nerve fibers are most numerous, and darker, with a slight variation in tone (greenish to bluish), at the site of the physiological cup and in the lower nasal quadrant. The color of the disk and the details are best studied by the direct method of ophthalmoscopy and by faint illumination.

In beginning simple atrophy the pallor of the disk is greatest in the part in which the layer of nerve fibers is thinnest, namely, in the inner lower third. The disappearance of the capillaries is not complete, consequently the normal rosy hue is partly retained in that portion of the disk in which they are most numerous. Later all the capillaries disappear and the entire disk becomes pale, the outline of the disk is sharply cut in all parts, the chorioid and retina being clearly visible.

Lamina Cribrosa.—In simple atrophy the bars of the lamina cribrosa are clearly visible, particularly in the inner lower third of the disk. They appear as indistinct white bars or lines crossing the disk and forming a network. The spaces between the white bars are of a deeper gray, frequently presenting a bluish tone.

Excavation or Cupping.—The level of the nerve head sinks slightly below that of the retina, forming what is known as the cupping of optic-nerve atrophy. The cupping describes a gradual sloping from a very short distance beyond the margin of the disk to the centre of the physiological cup (see Fig. 399). De Wecker suggests that the normal intra-ocular pressure may, on account of the loss of substance in the nerve head, assist in producing the excavation. However this may be, microscopic examination fails to disclose any bulging outward of the lamina cribrosa, the expression of cupping from increased intra-ocular tension.

Blood-vessels.—In simple atrophy, the large central arterial and venous trunks may remain almost, if not quite, unchanged. In injury to

[1] The term "gray" atrophy should not be employed, because it is not sufficiently uniform to designate a type.

the nerve back of the entrance of the vessels this is usually the condition; however, in many cases the blood-vessels become slightly reduced in size.

Field of Vision.—The contraction of the field of vision is, as a rule, from the periphery, and is concentric. Central scotoma in this form of atrophy is extremely rare, but irregularities in the form of the field may assume almost any shape. The fields for color may diminish proportionally with that for white. They may diminish less rapidly, or, what is more common, they may diminish more rapidly. Diminution of central vision, as a rule, approximately coincides with the diminution in the field of vision, but it may occur that the field for form will be greatly diminished, while the central acuity of vision will be surprisingly good. A very small central field may be retained many years before blindness finally ensues.

Secondary Atrophy.—Atrophy due to disease of the retina and chorioid presents conditions at the disk which are sufficiently characteristic to distinguish it from the other two forms, except in cases following great loss of blood and in certain toxic conditions. The character of the atrophy due to retinitis pigmentosa, syphilitic retinitis, chorioidal atrophy, and in amaurotic family idiocy, will be described in the discussion of these conditions. Suffice it to state here that the disk usually presents a dirty gray or smoky appearance, margins hazy, blood-vessels small—in some cases obliterated.

Tumors of Optic Nerve.—These are of rare occurrence. Braunschweig[1] succeeded in collecting 64 cases. Parsons[2] collected 120 cases. Secondary growths of neoplastic tissue, particularly those due to glioma of the retina and sarcoma of the chorioid, are not very uncommon (see pages 380 and 479). Primary tumors of the optic nerve may develop in the optic-nerve sheath (dural portion)—extraneural—or they may develop in the nerve itself—intraneural. J. H. Parsons[3] has collected 18 of the first and 102 of the second variety. The following forms have been observed:

Aneurism, central artery of the retina.
Carcinoma (metastatic).
Cysts, hydatid.
Endothelioma.
Fibroma.
Fibroma, lymphangiectatic.
Glioma.
Gumma
Myxoma.
Myxofibroma.
Myxoglioma.
Psammoma.
Sarcoma.
Tubercular tumors.

- Angio-
- Alveolar
- Endothelial
- Fibro-
- Glio-
- Metastatic
- Myxo-

[1] Graefe's Arch., xxxix, 4, p. 1.
[2] Ophth. Record, xii, 3, 125, N. S.
[3] Pathology of the Eye, vol, ii, part ii, p. 693.

Of the various forms, myxosarcoma is the most common, 12 to 15 per cent. Sarcoma of all varieties occurs in 33 per cent.

Symptoms.—The disease commences before the tenth year in approximately 40 per cent. of the cases. Development after sixty years of age has been observed. Exophthalmos, the projection usually being directly forward, is a prominent symptom. Haziness of the cornea due to desiccation from exposure occurs when the exophthalmos is excessive. Pain is absent in the greater number of cases until the growth has attained to a considerable size. The movements of the eyeball are much limited in all directions as soon as exophthalmos is marked. Vision fails rapidly in many cases, but in some it is preserved for years. Wiegman[1] reports a fibroma of the optic nerve, springing from the perineurium in which vision was preserved to the last. Neuritis and choked disk develop in the majority of the cases, running the usual course. Extension of the growth into the eyeball is a rare occurrence. Finlay[2] reports one case and refers to four others. The tension of the eyeball is usually increased. Extension of the tumor into the cranial cavity is not uncommon.

Fig. 248

Myxosarcoma. (Graefe's Archiv.)

Diagnosis.—The peculiarity of the exophthalmos, the loss of sight, and the intra-ocular appearances are usually sufficient. The possibility of the presence of a slow-growing, encapsulated, intra-orbital neoplasm must be kept in mind.

Duration.—The extremes of the duration of tumors in 50 cases collected by Finlay were two months and twenty years. A fibroma in one case was present twenty years, a sarcoma eighteen years. The mean time for fibroma was 5.2 years; sarcoma, 3.47 years; glioma, 1.5 years; endothelioma, 5.83 years.

Results.—Of the cases reported by Finlay, mention of the subsequent course is made in 25 cases only. In 10 cases there was no recurrence; in 8 cases recurrences either in the orbit or in other parts of the system, and in 7 cases death followed the operation for removal in a few days. Sepsis undoubtedly was the cause of death in a number of the cases. It is very probable that the percentage of recoveries is much less than that indicated by the cases in which the subsequent history is reported. Of 11 cases operated on after the method proposed by Knapp, in which the eyeball was preserved at the time of operation, the eyeball retained its normal form in only 2. In 3 cases operated on by the Krönlein method, death occurred two months later by metastasis in the brain in 1 case; in the other 2 cases the form of the eyeball was perfectly preserved.[3]

[1] Zeh. klin. Monatsbl., xxxii, p. 272.
[2] Arch. of Ophth., xxiv, 2, p. 224.
[3] Axenfeld and Bush, Arch. f. Augenheilk., xxxix, 1, p. 1.

In point of malignancy the various growths will range as follows: Glioma, sarcoma (the various forms), and endothelioma.

Treatment.—Except in the case of gumma, the treatment is surgical. When a tumor is present, antisyphilitic remedies should be employed sufficiently long to exclude the possibility of a syphilitic growth.

Surgical Treatment.—This may be conducted (1) as complete *exenteration of the orbit*; (2) removal of the eyeball and tumor; (3) removal of the tumor preserving the eyeball. It is only necessary to write in detail of the last procedure. The operation as advised by Knapp[1] consists in approaching the tumor by an opening through the ocular conjunctiva or through the lid at a point situated so as to reach the tumor to the best advantage for dissecting out the mass, using scissors guided by a finger introduced into the wound, or by blunt dissection. Considerable displacement of the globe may be obtained without causing its death. In suitable cases this procedure is valuable.

The Krönlein operation, by affording an extensive exposure of the contents of the orbit, will be the desirable method in many cases.

The tumor should be removed as early as possible. A lethal issue is almost certain if the growth is permitted to remain. The probability of recurrence is in direct proportion to the length of time that the tumor has been developing.

Tumors of Intra-ocular End of Optic Nerve.—Tumors that have been observed, not extensions of neoplasms affecting the retrobulbar portion of the nerve, are gumma, tubercle, and hyaline bodies.

Gumma.—Scheidemann[2] reports a case of gumma of the papilla in a man, aged thirty-two years, which occurred ten months after the primary infection. A circumscribed, round, prominent, broad-based nodule of a yellowish-gray color was present on the disk; arteries thin, veins dilated; the retina about the disk was swollen; striped hemorrhages were present; vision, $\frac{1}{200}$. Under energetic treatment the tumor disappeared and vision reached $\frac{15}{200}$. A section of the optic papilla showing localized tuberculosis was presented at a meeting of the Section on Ophthalmology, New York Academy of Medicine, by A. Knapp, December 16, 1901. The patient was a colored child, aged two years. The child was well nourished; possibly there were some tubercular lesions at the apices of the lungs, but this was not certain. The adjacent retina and chorioid were involved to a slight extent.

Colloid Excrescences on Papilla.—Colloid masses are sometimes observed between the nerve fibers scattered throughout the nerve and extending backward in the chiasm and tracts. The author has such a specimen in his possession, and Berger[3] states that they are not uncommon. The function of the nerve may be but little affected.

Deposits of Calcareous Salts in Papilla.—The deposit of calcareous salts in the papilla in degenerate globes occurs, but is not common. It is seldom that these deposits are present posterior to the lamina cribrosa,

[1] Arch. of Ophth. and Otol., iv, p. 323 and v, p. 132.
[2] Graefe's Arch., xiv, p. 156.
[3] Anat. d. Auges, Wiesbaden, 1887, p. 131.

but von Graefe mentions a case in which the nerve was so infiltrated with lime that when the eye was enucleated it was very difficult to divide the optic nerve.

Hyaline Bodies in the Papilla.—These masses, which are sometimes described as colloid bodies, appear as small, rounded elevations of a pearly or yellowish-gray color, usually multiple, clustered together in mulberry form, and often protruding slightly beyond the margin of the disk. They may occur at any age, may accompany retinitis, chorioiditis, atrophy of the optic nerve, or appear in eyes otherwise perfectly healthy and with unimpaired vision. The condition is not a common one. Two views are held regarding the origin of these masses: (1) That they are

Fig. 249

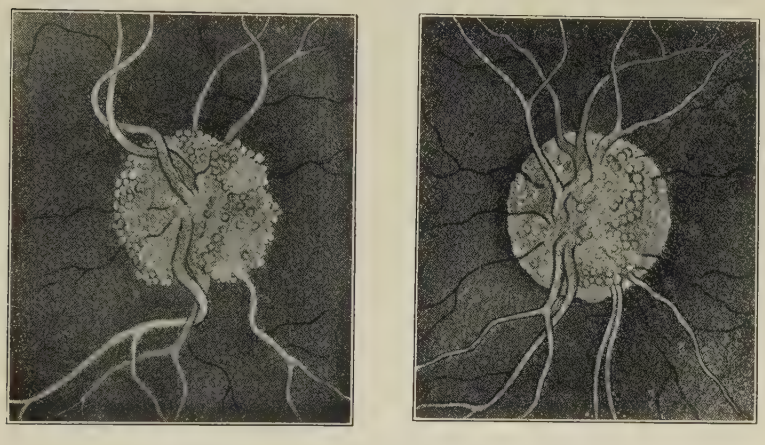

Colloid hyaline excrescences in the papilla. (Cirincione.)

identical with the hyaline excrescences of the lamina vitrea of the chorioid; (2) that they are an entirely distinct new formation. De Schweinitz[1] has studied these masses microscopically, and is of the opinion that the latter view is the correct one. "One investigation of Hirschberg and Cirincione indicates that the bodies are amorphous and organic and that their composition appeared most to resemble elastin. They may undergo calcification." Sachsalber[2] examined microscopically the eyes of a woman having colloid formations in the optic disk. $V = \frac{6}{9}$. He found the hyaline masses in the various layers of the retina near the disk, at the margin of and in the disk, and behind the lamina cribrosa. He does not think that they are in any way related to the colloid excrescences of the chorioid, but that they may be due to inflammatory conditions.

Treatment.—The treatment of gumma is evident. Tuberculosis of the papilla is best treated by removal of the globe. The hyaline bodies require no special treatment. They may disappear and reappear. More or less complete disappearance occurs after some weeks or months in the greater number of cases.

[1] Trans. Amer. Ophth. Soc., 1892. [2] Deutschmann's Beiträge zur Augenheilk., xxi.

DISEASE OF THE OPTIC CHIASM.

Disease beginning in the chiasm itself is extremely rare. One case of cyst developing in the anterior angle of the chiasm, producing bitemporal hemianopsia, has been reported. Disease of the chiasm is secondary to disease of adjacent structures, and in almost all the cases the disturbance of vision from lesion of the chiasm is the result of pressure. Gehrung[1] has collected 102 cases of disease of the optic chiasm. An analysis of these cases shows that the sexes are about equally affected. The age of the patients ranged from four to seventy-six years, the greater number of cases occurring in individuals in middle adult life.

Etiology.—Pressure from enlargement of the pituitary body (in acromegaly), hemorrhage, syphilis, multiple sclerosis, periostitis, tuberculosis, carcinoma, sarcoma, fibroid tumors, aneurism, cysts, fractures at the base, pressure from the third ventricle. "Of 174 cases of acromegaly collected by Hertel, 91 (53 per cent.) were found to have visual disturbances due to pressure on the chiasm."

Symptoms.—Headache referred to the apices of the orbits or temples, nausea and vomiting, sometimes periodic, failing vision, fluctuating in some cases; polyuria is present in at least 50 per cent. of the cases. Optic neuritis of all grades may exist, but in the greater number of cases the optic disks become paler than normal, and show signs of atrophy without previous inflammation. Choked disk seldom occurs. Why this is so is not positively known. It is probable that the process that affects the chiasm causes closure of the space connecting the subdural with the subvaginal spaces. Probably the most conspicuous symptom of chiasm disease is hemianopsia (see page 540). This develops slowly. The defect in the field is, as a rule, very irregular, but is of the hemianopic type.

Prognosis.—This depends on the cause. If syphilis is the cause much can be done to arrest progress and to recover a part of the fields of vision that have been lost. In some traumatic cases the prognosis for the retention of a part of the field of vision is good.

Treatment.—This consists in treating the cause of the chiasm disease.

[1] New York Eye and Ear Infirmary Reports, January, 1904.

CHAPTER XVIII.

AMBLYOPIA, AMAUROSIS, AND HEMIANOPSIA WITHOUT INTRA-OCULAR INFLAMMATORY MANIFESTATIONS.

THE term amblyopia indicates dimness of vision, usually without ophthalmoscopic changes, but it is also applied to dimness of vision, due to disease of the eyes. It may be congenital or acquired, temporary or permanent, monocular or binocular.

The term amaurosis indicates blindness.

NON-TOXIC AMBLYOPIA.

Congenital Amblyopia.—Congenital amblyopia without appreciable anatomical changes. Cases of this character are occasionally met with in squinting and in non-squinting eyes. It is monocular in the greater number of cases. The field of vision is usually normal in extent. There may be a relative central scotoma for form and for colors, an absolute scotoma for red and green, or for all colors. When occurring in squint the amblyopic or more amblyopic eye deviates. In pure congenital amblyopia the fusion faculty develops (Worth).

Etiology.—This is not discoverable in some cases. Quite a large percentage of the cases are associated with hyperopia and astigmia (astigmic amblyopia, Martin) or with some defect in the media which has always prevented the formation of perfect images on the retina, in consequence of which the proper stimulus for the development of normal vision has always been wanting. In many of the cases of binocular amblyopia and in some of the cases of monocular amblyopia in which the inability to form perfect images on the retina can be removed (correcting errors of refraction, removing cataracts, etc.), the vision will gradually improve, especially in young individuals.

Macular hemorrhages, diffuse retinitis, and some affections of the optic nerve may occur early in life and all discoverable traces disappear before the patient comes under observation.

Diagnosis.—It is often difficult to differentiate these cases from those of amblyopia from non-use. The distinguishing features are the history of amblyopia antedating the squint (if squint is present), the presence of the fusion faculty, and central or paracentral relative scotoma.

Color-amblyopia.—Color has no objective existence; it is purely a sensation excited by light-waves of different lengths, and depends on the normal integrity of the visual apparatus. With few exceptions, light emanating from any body is compound; that is, it is made up of luminous

waves of varying length; when passed through a strong prism the luminous ray is decomposed, the component parts being differently refracted according to their wave length forming a luminous band—a spectrum, which to the normal eye appears to be composed of many colors. The longest light-waves are refracted least, corresponding to the red end of the visible spectrum; the shortest waves are refracted most, corresponding to the ultra-violet end of the spectrum; the light wave for red is 0.00069 mm., for violet 0.00039 mm.; between these limits the eye receives the impression of orange, yellow, green, and blue, and innumerable shades consequent on their blending. Although the solar spectrum presents what may be regarded as seven primary colors, they can not be considered as *primary color sensations.* According to the Young-Helmholtz theory, there are but three primary color sensations, namely, red, green, and violet; these are termed fundamental colors. Hering concludes that there are four primary color sensations, namely, red, yellow, green, and blue; these he reduces to complementary pairs—1st, red and green; 2d, yellow and blue.

Fig. 250

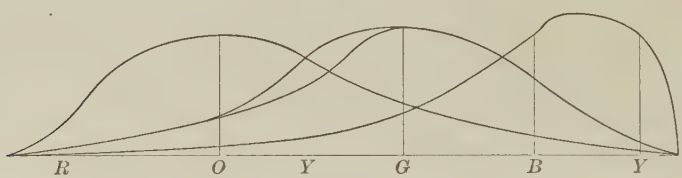

Jennings' color blends.

The inability to distinguish colors constitutes *color-blindness.* Color-blindness may be *congenital* or *acquired, total* or *partial,* and it may affect a part or the whole of the field of vision for colors. Congenital color-blindness is known as Daltonism,[1] after an English chemist, who was red-blind and who first accurately described color-blindness.

Individuals who are totally color-blind see the world as though it were tinted in different shades of gray from white to black. In cases of partial color-blindness, only certain groups of colors may be affected, as reds and greens, or blues and yellows. Again, the inability to distinguish colors may involve only certain ill-defined tints. Thus all grades of defective vision for colors may exist.

Etiology. The *classification* and *explanation* of the phenomena observed in the color-blind depend on which of the two theories of fundamental color perception we adopt.

Young-Helmholtz Theory.—In the early part of the nineteenth century Thomas Young devised a theory of three primitive colors or fundamental perceptions. This was modified by Helmholtz in 1850, and is known as the Young-Helmholtz theory. This theory supposes that the normal retina is supplied with three sets of perceptive elements,

[1] Mem. of the Literary and Philanthropical Society of Manchester, 1st series, v, p. 28, 1798.

or end-organs, of which one responds more actively to red, one to green, and one to violet. If one of these sets of perceptive end-organs is defective, the individual is "color-blind" for the corresponding color in proportion to the degree of the defect. The perception for red is most frequently affected, next that for green, and last that for violet.

According to this theory excitation of all the retinal elements is produced by any one of the three elementary or fundamental colors, but in the normal eye the *maxium* excitation of any one of the sets of retinal elements is produced by its corresponding fundamental color. Equal excitation by all the fundamental colors produces the sensation of white. The theory is graphically set forth in Fig. 251.

FIG. 251

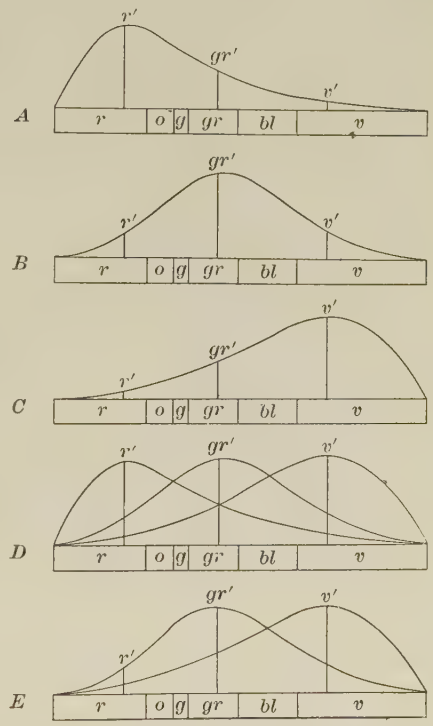

Representation of color perception according to the theory of Young and Helmholtz. The abscissa represents the spectrum, the colors of which are: red, *r;* orange, *v;* yellow, *y;* green, *gr.;* blue, *bl.;* violet, *v*. The curves which rise above the abscissa show graphically the sensitiveness of the three sorts of fibers in the retina toward rays of different wave lengths. The ordinates, (r', gr', and v') indicate the intensity of the stimulation of the fibers produced by red, green, and violet rays, respectively. *A*, gives the curve representing the sensitiveness of the fibers for the perception of red; *B*, that of the fibers for the perception of green; *C*, that of the fibers for the perception of violet. In *D*, all three curves are represented at the same time. *E*, shows the curves of sensitiveness of a red-blind eye in which the fibers for the perception of red are assumed to be wanting. (After Fuchs.)

The individual with red blindness is deficient in the retinal elements that respond to red; however, it does not follow because of this that he does not see red objects at all, or that they appear colorless. According to Fuchs: "If he looks at the spectrum it appears to him shortened at its red end, since he sees only blackness where others still perceive red. A red ray which falls upon this man's retina sets into action only the fibers for the perception of green and those for the perception of violet — and of these the former more markedly, so that the resultant effect will be green. If green light falls upon the retina, the fibers for the perception of green are again stimulated more strongly than those for the perception

of violet, and again the sensation of green is produced. Where, then, we have two different sets of sensations, viz., red and green, a person with red blindness has two that are similar—namely, both green. (The shade of green that appears to most persons with red blindness to have the same color as red is that hue of bluish green which is complementary to red.) A person with red-blindness, however, can distinguish these two sensations from each other, for, though similar indeed, they are not quite the same. They are distinguished from each other by their difference in brilliancy, for let us assume that the red and green rays selected as an example are of the same brilliancy to a normal eye. Such an eye can still distinguish them apart, owing to their difference in color. The case is otherwise with a red-blind man; in him the red ray, in spite of its luminous intensity, causes but slight stimulation of the fibers for the perception of green, simply because these fibers are in any case but slightly sensitive to red rays. The sensation produced by the red ray is hence a feeble one, and the color which is seen looks dark. The green ray, on the other hand, is perceived in its full brilliancy, because the fibers for the perception of green are stimulated by it in the normal fashion. In this way it is generally possible for the man with red blindness to distinguish red from green, not by the difference in color, but by the difference in brilliancy."

Hering's Theory.—In the analysis of color sensations it is found that there are four colors that give what may be termed pure sensations. If we look at orange we gain the impression of yellow mixed with red, if at purple, of blue mixed with red, but we shall find a red in which we cannot imagine the admixture of any other color; in like manner we shall find a yellow, a green, and a blue. These have been designated primary color sensations by Hering, and the colors as the four fundamental colors. These have been associated into two pairs, namely, red and green, yellow and blue, and are termed *contrary colors* because it is averred that we cannot conceive of one as occurring in the other. If light from the two members of a pair fall on the retina at the same time the resulting sensation will be in accordance with the one which predominates, but never of both together. If the light from both members of a pair affects the retina equally the result will be a sensation of white (gray), for which reason they are known as *complementary colors*. From these fundamental colors all colors are derived.

Hering assumes the presence in the retina of three substances, which are affected differently by different kinds of light; these are known as visual substances; they are white black, red green, and blue yellow. The sensations of light and color depend on the decomposition or *dissimilation* and reconstruction or *assimilation* of the visual substances. The white-black substance is dissimilated by white and reconstructed in the absence of white. Of the other two pairs, it is not known which dissimilates and which assimilates.

According to this theory the partial or complete absence of the red-green or blue-yellow visual substance constitutes amblyopia for the colors affected. Red-green color-amblyopia is by far the most common;

it corresponds with the red and the green color-amblyopias of the Young-Helmholtz theory. Blue-yellow color-amblyopia is rare.

Other Theories.—The theories of Preyer[1] and of Oliver[2] may be found as indicated.

All degrees of congenital color-blindness exist; the red-green color blindness is the most common.

Congenital Total Color-blindness.—This form is extremely rare. About forty cases have been reported, the proportion of men to women being approximately two to one.

Etiology.—Consanguinity in the parents was found in 12.5 per cent. The condition is always associated with defective vision for form consequent on opacities of the cornea, lens, or vitreous, or changes in retina and chorioid.

Fig. 252

Color-blindess. The totally color-blind have the eyes partly closed. (From a photograph of Uhthoff.)

Heredity is an important factor in the production of color-amblyopia. Horner is of the opinion that the transmission of color-amblyopia follows a certain law which he formulates as follows: "The sons of daughters whose fathers were color-blind are most likely to be the same."

Jennings[3] sums up as follows: (1) Color-blindness is hereditary and is attached to certain families; (2) it may not be found in one generation, but reappears in the next; (3) all children will not be affected, the girls especially escaping; (4) when several children are affected it is traceable to the mother; (5) the kind and degree will be the same for all the cases in a family. Congenital color-blindness apparently follows the Mendelian law of heredity.[4]

[1] Arch. of Ophth., 1881, x, p. 480.
[2] Amer. Jour. Med. Sciences, 1885.
[3] Color-vision and Color-blindness, Philadelphia, p. 41.
[4] Verh. naturf. ver. in Brunn Abhandlungen, 1865, iv.

Symptoms.—In many cases small defects at the macula are present. Photophobia is almost invariably present. The individual sees best by moderate illumination. The lids are partly closed and the head tilted forward, giving the total color-blind a distinctive appearance (Fig. 252). Strabismus and nystagmus may be present.[1]

Congenital color-amblyopia is almost always binocular, but a very few well-authenticated cases of uniocular color-amblyopia have been observed and carefully described.

Frequency.—The frequency of color-blindness is estimated differently by different observers: Seeback, 12.5 per cent.; Prevost, 5 per cent.; Wilson, 5.6 per cent.; Jennings, 4.25 per cent.

Males are much more frequently color-blind than females; the proportion is approximately 20 to 1.

Prognosis.—Congenital color-amblyopia is incurable.

The individual who is amblyopic for colors is unfitted for occupations in the arts which require him to mix pigment or to match colors; also for marine service, certain kinds of army and navy service, and for that part of railroad service in which he is required to recognize different colored signals. It often happens that neither the individual affected nor those with whom he comes in contact are aware of the defect, the existence of which can only be determined by the employment of certain tests.

Acquired Color-blindness.—*Etiology.*—Acquired defects in the color sense are always accompanied by some impairment in the form sense, and in almost every instance implies some defect in the visual tract, retina, nerve or its cerebral termination. Partial loss of the transparency of the cornea, lens, aqueous or vitreous humor does not impair the color sense. Affections of the optic nerve are the most frequent cause of acquired impairment of the color sense. In low grades of atrophy with but slight concentric contraction of the field for white the color sense may be greatly impaired. It may be difficult to determine a loss in the extent of the field for white when examination of the color sense will disclose a marked diminution.

Retrobulbar neuritis, particularly that due to the immoderate use of alcohol and tobacco, produces a central color defect. The color sense due to disease departs gradually, green and red first being extinguished, then yellow, and last blue.

Loss of the color sense in half of the field of vision with preservation of the form sense is found in some cases of hemianopsia (see page 540); the condition is known as *hemiachromatopsia.* Cases of loss of color sense as a result of traumatism are recorded (Jennings).

The special forms of color defects in diseases of the eye are discussed in the chapter devoted to these affections.

(For the tests for the detection of color-blindness, see chapter on Examination).

Prognosis. In all cases of acquired color-amblyopia recovery follows the recovery of the form sense except in the cases of achromatopsia.

[1] Uhthoff (Trans. Heidelberg Ophth. Gesell., 1898, and other papers) and Grunert (Graefe's Arch., lvi, No. 1) have presented the subject very fully.

Congenital Word-blindness (*Developmental Alexia,* Jackson).—**Etiology.**—This condition is a developmental defect of the visual memory centre for the graphic symbols of language in the cortex of the brain. There is no disease of the brain itself. Heredity and family exert a strong influence in the production of this condition. The developmental defect is in the angular gyrus of the left cerebral hemisphere.

Symptoms.—The condition is manifested by an inability of the child to learn to read within the time required by children of ordinary mental powers. The child may be quick to learn by word of mouth and be mentally bright in every other respect. "In some cases numbers and music are read normally, drawing and needlework present no special difficulties," but years of endeavor are required before even simple words can be read. In some of the cases the child is mentally defective in other ways. In the schools under the control of the London County Council defective children at the age of seven years are reported to the medical officer. In this way a number of cases of word-blindness have come under observation. C. T. Thomas estimates that one child in two thousand is congenitally word-blind.

Prognosis.—Recovery may be expected in all cases in which there is ordinary mental capacity in other respects.

Treatment.—Errors of refraction should be corrected early. All other measures should be employed to assist the deficient memory. Learning to recognize the meaning of words without trying to memorize the letters, the "look-and-read" method is of value. Lip-reading will help in some cases.

Wray[1] suggests special tables and cards for treating these cases. Block letters, in order that the sense of touch may aid in overcoming the defect, may be employed. Spoken language is of great value.

Amblyopia from Non-use (*Amblyopia Exanopsia*).—**Etiology.**—This is met with in cases in which there is obstruction to the proper access of light to the retina in childhood, as in congenital or early acquired cataract and in pupillary obstruction; in cases of high anisometropia, in which the ametropia of one eye is very considerable, and the effort to properly focus is abandoned; also in strabismus.[2]

Symptoms.—The degree of amblyopia varies from a very little impairment of vision to the ability to count fingers at one or two feet. The degree of amblyopia in squinting eyes appears to depend on the time when the deviation of the eye begins. If the squint develops very early in life (six months to eighteen months) and treatment is not instituted, a very high degree of amblyopia is attained. With squint developing later, the degree of amblyopia is much less.

The field of vision is not contracted, nor is there any central scotoma. Central fixation (the fusion sense) in squinting eyes is lost rapidly in early life, that is, before six years of age; it is seldom lost after that age Loss of fusion power is sometimes very rapid—"it is often lost within eight or ten weeks" (Worth).

[1] Lancet, September 23, 1905.

[2] For a comprehensive discussion of amblyopia exanopsia, see Worth, Squint, London, 1903.

Treatment.—Amblyopia from non-use admits of correction in a large number of cases if treatment (see Squint) is instituted early. If not, it is impossible to effect much improvement except in a very small percentage of the cases. Coleman[1] reports 17 cases of internal squint with subnormal vision in the squinting eyes on first examination. After operation vision improved 25 per cent. in three, 50 per cent. in five, 100 per cent. in four, and 300 per cent. in one. The others remained unchanged.

Psychical Amblyopia.—This form of amblyopia is met with in hysterical, asthenopic, and neurasthenic individuals, and is sufficiently discussed in the description of these conditions.

"Suppression of Images."—In some cases of all varieties of strabismus the vision of the squinting eye as well as that of the "fixing eye" is normal. Since the visual axes of the two eyes, under these conditions, are not directed toward the same point, the images of objects do not fall on "corresponding points" on the retina, and the individual would ordinarily see double. In squint that develops early in life double vision does not obtain; the image which is formed on the retina of the deviating eye is ignored or "suppressed" by the perceptive centre in the brain. The "suppression" may alternately affect either eye. No injury to vision follows.

Examples of the suppression of images in one or other eye in non-squinting individuals are observed in artisans who work largely with one eye, but keep both eyes open, as watchmakers, jewelers, microscopists, and physicians who use the ophthalmoscope. The image formed on the retina of the eye not in use is ignored.

The ability to suppress the image of one eye may be acquired by persistent endeavor at any age, but requires much more time with some individuals than with others. Those suffering from paralytic strabismus acquired late in life are greatly annoyed by double vision at first, but in the greater number of cases the individual learns to ignore (suppress) the image formed on the retina of the deviating eye.

Traumatic Amblyopia.—After injury to the brain or fracture of the skull it sometimes occurs that amblyopia is produced without ophthalmoscopic changes and without a readily discoverable cause. The amblyopia may be due to intracranial hemorrhage, injury to both tracts, pressure on the optic nerve, or hemorrhage into the sheath of the nerve. These are all sufficiently discussed under their appropriate headings. Persons who have been injured on railroads or other public carriers are apt to exaggerate the degree of amblyopia from which they appear to suffer. The methods of malingerers are of course easily recognized by the ophthalmic surgeon.

Loss of vision has followed injections of paraffin for the correction of "saddle-nose." A number of cases have been reported. In Mintz's[2] case there was pain in the left eye three minutes after the injection followed by complete blindness. Symptoms of orbital venous congestion, paralysis of ocular muscles, and exophthalmos developed during the next few days.

[1] Ann. of Ophth. and Otol., April, 1893.

[2] Centralbl. f. Chir., January 14, 1909.

Reflex Amblyopias.—These are said to be due to uterine or ovarian irritation, to intestinal irritation consequent on the presence of intestinal parasites, to irritation of the fifth nerve from a furuncle on the ala of the nose, to defective and painful teeth. As a rule, some cause other than those mentioned can be found; however, in obscure cases it is advisable to inquire into the condition of the reproductive organs, the intestines, and the teeth as a possible source of the trouble. Dunn[1] reports two cases in which affections of the teeth caused transient amblyopia.

Amblyopia Associated with Agoraphobia.—Fear of being alone in any place (agoraphobia) is sometimes accompanied by amblyopia. Nieden[2] reports a case in which agraphobia was accompanied by a fear that the space in which the patient found himself was too small to contain him. During the attack his surroundings became dark and indistinct; however, objects looked at would be seen; the patient regained his composure by remaining in a darkened room and closing his eyes.

Simulation Amblyopia.—Simulation defects in the fields of vision are almost entirely confined to concentric limitations and hemiopic defects. Malingerers know nothing of central, ring, or sector-like defects. In all cases of pure malingering the objective conditions are of course perfectly normal. Proof of malingering may be adduced by employing the following plan:

The statements of the subject throughout the examination must be carefully noted in order that they may be compared. They will undoubtedly be at variance as the examination proceeds.

The examination of the fields of vision must not be too protracted at one sitting, as fatigue contraction of the fields may be induced.

The patient should be kept under close observation by the examiner, the results being dictated to an assistant to be recorded.

Tests.—The tests employed may be:

1. The ordinary perimetric measurements, the charts for form and color obtained by two or more sittings should be compared.

2. The size of the fields at different distances from the eye may be compared. This may be obtained by the device of Wilbrand,[3] which consists in the attachment of a black thread to the chin-rest of a perimeter at a point where the axis of the perimeter cuts the eye-rod (see Fig. 100). The thread may be three times the length of the radius of the perimeter. A white ball, fifteen millimeters in diameter, on a black rod, is attached to the end of the thread. The patient is directed to "fix" a point on the axis of the perimeter (the point may be at the centre of the arc of the perimeter or at a greater distance), and the ball is brought into the field of vision from the periphery. The arc of the perimeter should lie at about right angles with the place of entrance of the white ball into the field of vision, and the background should be black so that there is nothing to distract the attention of the patient or to interfere with the test. When the ball is perceived by the patient, the arc of the

[1] Amer. Jour. Ophth., October, 1891.

[2] Deutsch. med. Woch., 1891, p. 465.

[3] Norris and Oliver, vol. ii, p. 313.

perimeter is rotated so that the angle in that meridian can be determined in degrees. The field so obtained is compared with the field obtained when the examination is made on the ordinary perimeter. Wilbrand states that the field of vision obtained by means of the thread is usually more extensive than that obtained in the ordinary way.

3. Schmidt-Rimpler's plan: "The examining object is made fast at the utmost limit of its recognition and a prism of 30 degrees is placed before the eye. The patient is made to open the other eye and fix with it as well. The base of the prism is held in such a manner that the image of the examining object falls on the part which is said to be blind. As the fixation point is seen double, the simulator is tempted to give a correct answer as to the examining object at the periphery also."

Some evidence of simulation may be obtained by observing the patient's powers of orientation. Patients with very much contracted visual fields have very limited powers of orientation. They cannot move about a room readily because of inability to differentiate the various articles of furniture, etc. If the simulator moves about readily with the supposed defective eye, or eyes free, a very close estimation of the extent of the visual field can be made.

Lunar Amblyopia (*Moon-blindness*).—There is a popular belief that sleeping exposed to moonlight may cause a dimness of vision which may last some hours or months. This has been observed most frequently among sailors. The condition is apparently due to torpidity of the retina, causing night-blindness; but changes in the crystalline lenses apparently due to exposure to moonlight have been reported (Ole Bull). The patient was a sailor, twenty-six years of age, who slept with two companions on the deck of a ship in the bright moonlight. On waking all had great difficulty in seeing, which condition lasted two months. Small opacities were scattered throughout the crystalline lenses of the patient examined by Bull. It is very probable that this form of amblyopia is largely dependent on impaired nutrition and that the influence of exposure to moonlight is exaggerated.

Snow-blindness.—This is not of very uncommon occurrence. It is characterized by partial loss of vision without ophthalmoscopic changes and is recovered from slowly when the glaring, intense light from the snow is excluded. Those who live in polar regions or in mining camps during the winter months, exposed to glare of light from the snow, whose diet is not sufficiently varied, are most apt to be affected. Torpidity of the retina is induced, which is in part at least due to the restricted diet. The wearing of veils or of properly tinted glasses goes far to prevent this form of amblyopia, but in many of the cases removal from exposure and a decided change and improvement in diet are necessary to bring about recovery.

Colored Vision.—Colored vision is in many cases a contrast phenomenon. There are a number of varieties.

Erythropsia (*Red Vision*).—This may be induced by exposure to glare of light, especially to light from the snow, and by traumatism. After exposure for some hours to snow some individuals on entering a moder-

ately darkened room will have red vision throughout a small area of the visual field extending 10 to 20 degrees from the fixation-point, for a few minutes. After cataract extraction in some cases the patient will see everything in a reddish or purple color. This may last some days or months (Van Duyse), gradually disappearing. The phenomenon is distressing to some, scarcely noticed by other patients.

Berger[1] reports the occurrence of erythropsia after severe injury over the left zygomatic bone without contusion of the eyeball. He regards it as a symptom of retinal irritation.

Xanthopsia (*Yellow Vision*).—This may result from the taking of certain drugs, of which santonin is the best known (see Toxic Amblyopia), from injury, or as the result of illness. Niemetachck reports the case of a man who was shot in the face without injuring the eye. The right eye was amblyopic for three weeks. Then followed monocular diplopia and xanthopsia which lasted three or four weeks. Kesteren reports a case which occurred after heat prostration. The exanthopsia lasted three months. Yellow vision has been observed during convalescence from typhoid fever (Purtscher) and in epilepsy preceding a seizure. In all of these cases the fundus oculi was normal. The disturbance appears to be due to an affection of the cerebral color centre.

Cyanopsia (*Blue-seeing*).—This may be occasioned as a contrast phenomenon or as a result of disturbance of the cerebral color centre. The contrast phenomenon is often observed in patients who have had an extraction of an amber-colored cataract. For a long time the light that has entered the eye has had a brownish-amber tint. On removal of the cataract the light that enters the eye appears abnormally blue. The light that enters the unoperated eye still possesses the amber tint and serves to perpetuate the impression. The "blue-seeing" gradually passes away, particularly if the fellow-eye is relieved of its cataract. Pergious[2] reports a case of blue-seeing in a patient after a debauch. The phenomenon lasted three days; eyes normal. Helbert reports a case in a patient suffering from influenza. The blue-seeing was preceded by attacks of vertigo. The two last cases were probably of central origin.

Amblyopia from Exposure to Cold.—A number of cases have been reported. Nettleship[3] reports two cases. The blindness occurred in adults, came on after exposure to cold and high wind, and passed off in from one-half to twelve hours. The phenomenon was attributed to retardation of the circulation in the chorioidal and retinal vessels as a result of local and general depression occasioned by the cold, possibly associated with spasm of the blood-vessels.

Night-blindness (*Hemeralopia*).—**Etiology.**—The condition may accompany and be due to disease of the retina and chorioid that presents definite ophthalmoscopic changes, as retinitis pigmentosa, syphilitic chorioretinitis, etc. This form is termed "chronic night-blindness." It persists and tends to increase (see pages 361 and 460.)

[1] Centralbl. f. Aug., ix, p. 140.
[2] Ann. d'ocul., cxx, p. 114.
[3] Royal London Ophth. Hosp. Rep., May, 1902.

Symptoms.—Night-blindness is a symptom of a number of conditions and consists in an inability to distinguish objects when the illumination is moderately reduced. The affected individual is virtually blind at night and has great difficulty in going about as soon as the "sun goes down."

Night-blindness may come on suddenly, last for a longer or shorter time, and disappear under suitable conditions. This form is termed "essential" or acute night-blindness. It may occur in individuals of all ages; it affects both sexes. Those afflicted have invariably suffered from malnutrition due to insufficient food or to a diet devoid of sufficient fresh meat or vegetables. Long exposure to strong light is thought to contribute to its production.

Acute night-blindness occurs most frequently in the spring and early summer. It is met with in soldiers, farm and plantation "hands," especially in tropical climates, railroad laborers, glassblowers, furnace-workers, sailors on tropical seas; prison, almshouse, and asylum inmates; children in residential schools. In some of the cases there is scurvy. Xerosis epithelialis or triangularis (see page 242) is present in about 50 per cent. of the cases. There is no essential connection between the two, but the condition of the system that induces the night-blindness permits the development of the xerosis. Xerosis epithelialis may exist without night-blindness; it may continue after the night-blindness has been recovered from. Those who hold to the Hering theory believe that there is a loss of normal balance between the "dissimilation" and "assimilation" processes in the retina. There may be photophobia. The pupils are abnormally wide, particularly in the dark. Erythropsia and xanthopsia may be experienced. The condition is one of torpidity of the retina due to transient or permanent impairment of the walls of the vessels of the retina and chorioid with consequent disturbance of the nutrition of the retina.[1] The field of vision may be normal in extent for white by good illumination. It may be narrowed concentrically. The sensitiveness of the retina for blue is diminished.

Prognosis.—Decided improvement in vision follows appropriate treatment. Restoration to the normal occurs in a large percentage of the cases.

Treatment.—Improvement in diet (fresh meats and vegetables) and protection from too bright light suffice to bring about a cure in the greater number of cases in a few weeks. Pilocarpine, strychnine, nitrite of amyl inhalations and electricity have been employed with reported good results. Cod-liver oil has been strongly recommended (Dumas). F. Santos[2] recommends subcutaneous injections of the serum of the horse. Two to four injections of 20 c.c. are given at intervals of forty-eight hours. Recovery in a few days is reported.

Day-blindness (*Nyctalopia*)—This is a symptom or condition in which the individual affected sees better by subdued light than by bright illumination. The condition may be congenital, as in some cases of

[1] Kriene's Hemeralopia, Wiesbaden, 1898.

[2] Rev. gén. d'oph., No. 2, p. 49.

aniridia, coloboma of the iris, total color-blindness, axial, congenital, and zonular cataract, and albinism. It may be due to acquired conditions, as in individuals who have been long removed from the light, those suffering from eye strain, sometimes in those who have been exposed to bright light, as from snow, patients with retrobulbar neuritis, also with incipient nuclear cataract.

Treatment.—This consists in removing the cause as far as possible.

Amblyopic Defects of the Visual Fields not Dependent on Appreciable Disease of the Media, Retina, or Optic Nerve.—Scotoma and hemianopsia; transitory scotoma (spectral scotoma or migraine).

Etiology.—Fatigue, long use of the eyes, and hunger are exciting causes. There is apparently an inherited tendency in some cases. The phenomenon is due in all probability to disturbance in the cerebral cortical circulation affecting the side opposite that to which the scotoma is referred. If the scotoma affects both sides, both cortical visual areas are involved.

Symptoms.—Transitory symmetrical defects in the field of vision occur not infrequently in intellectually active individuals and in those engaged in vocations requiring the close use of the eyes. The attack is characterized by the development of a blind area usually to one side of the centre of the field of vision. The area is irregular in shape, its outline being often defective or broken on one side. The borders of the defect or the line may be broad and composed of changing prismatic colors (*scintillating* or *spectrum* scotoma). The limiting border is often zig-zag. It may assume the shape of the angles of a redoubt (*fortification* scotoma). This limiting border of the scotoma is convex outward. It may remain quite small, but usually gradually extends upward and toward the side on which it (the "*expanding angled spectrum*") started, sometimes assuming the hemianopic type. The dimness of vision extends throughout the area surrounded by the limiting border lines, but is most intense just within the border, fading out at the defective side of the area. The play of colors (spectrum) may assume various shapes and invade the field differently. The spectrum may be progressive (*progressive spectrum*) rather than expansive, may travel throughout part of the periphery of the field, usually only on one side. The blind area may be outside of the spectrum. The spectrum may be stellate in form and gradually work across the field much like a comet. It may be zig-zag and progress radially. It may form an arch. While the blind area is more often to the

Fig. 253

Scintillating scotoma in migraine. (Reute.)

side of the fixation point it may involve the centre of the field and expand to include almost the entire field. In some cases a scintillating spectrum border at the periphery of the field only remains.

Fig. 254



Homonymous hemianopsia.

Fig. 255

Bitemporal hemianopsia.

Fig. 256



Binasal hemianopsia.

Fig. 257



Horizontal hemianopsia.

Duration.—The scotoma passes off gradually in from five to thirty minutes, fading first from the part of the field first affected, with perfect restoration of vision. In the greater number of cases the phenomenon is followed by severe headache, often with nausea and vomiting, but in a small percentage of cases there are no disturbing sequelæ. The headache may be general, but is usually more severe on the side opposite the scotoma.

Occurrence.—The attacks are periodical in some individuals; in others the attacks are very irregular. Often there is a marked difference in degree of severity in the different attacks in the same individual.

Treatment.—The correction of errors of refraction, heterophoria, errors of diet and digestion, and less arduous use of the eyes are measures of considerable value. Out-of-door life is often beneficial.[1]

Hemianopsia (*Hemiopia*)—Loss of one-half of the field of vision. The term *vertical hemianopsia* is employed if the dividing line is vertical; *horizontal hemianopsia* if the dividing line is horizontal. The nasal half of one field and the temporal half of the other field of vision may be lost—*homonymous hemianopsia* (Fig. 254); the lateral halves of both fields may be lost—*bitemporal hemianopsia* (Fig. 255); the nasal halves of both fields may be lost—*binasal hemianopsia* (Fig. 256); the lower

[1] For an exhaustive discussion of the subject, see Gowers, Subjective Sensations of Sight and Sound, J. & A. Churchill, London, 1904.

or upper halves of the visual fields may be lost—*horizontal* (*altitudinal*) *hemianopsia* (Fig. 257).

(For a description of the visual tract, see page 85.

Etiology.—Hemianopsia is the result of (1) disease of the optic nerve and chiasm; (2) lesion of the optic tracts; (3) lesion of the primary optic centres; (4) lesion of the fibers that proceed from the basal ganglia to the cortical visual area; (5) lesion of the cortical visual area. The course of the visual fibers from the globe to the cortex is represented in Fig. 50, and lesions placed as represented would produce the various kinds of vertical hemianopsia. (For transient hemianopsia, see Asthenopia.)

Lesions of the chiasm producing vertical hemianopsia may be caused by (*a*) injury dividing the chiasm sagitally; (*b*) the pressure of a growth of any character in the anterior angle or in the posterior angle of the chiasm, involving only the decussating fibers (bitemporal hemianopsia), enlargement of the hypophysis cerebri as in acromegaly; (*c*) a double lesion affecting the non-decussating fibers at the lateral angle of the chiasm, as in atheroma of the internal carotids.

Since the lesion affecting the chiasm may readily extend to other fibers in the chiasm than the decussating or non-decussating fibers, the character of the hemianopsia is seldom typical—that is, the scotoma is seldom confined to just one-half of each retina. The defect in the field may stop short of or may extend into the other half. The half character of the field is approximate only.

Fig. 258

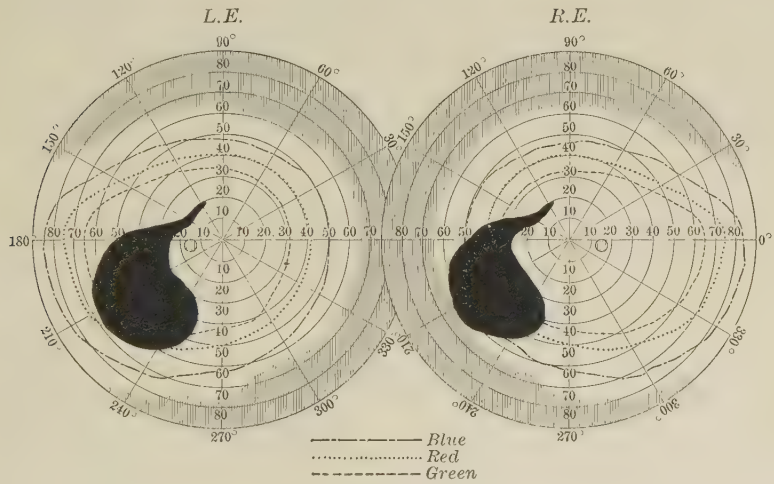

Visual Field Chart

Partial hemianopsia occurring in the writer's practice. Complete recovery.

The hemianopsia produced by lesions cerebral from the chiasm is homonymous; it is designated *right lateral homonymous hemianopsia* when it affects the right half of the field of vision, *left lateral homonymous hemianopsia* when it affects the left half of the field of vision. Hemianopsia is said to be *complete* when there is loss of vision in the

entire affected half of the field of vision, *incomplete* when a part of the half field is preserved. Lesions affecting both visual paths cerebral from the chiasm at any point produce *double homonymous hemianopsia.* This may be, and not very infrequently is, *relative* on one or both sides. When relative the central vision is usually much better than the peripheral vision. Hemianopsia is said to be *absolute* when vision is completely lost, *relative* when perception of light and the form sense are preserved. In some cases the color sense only is lost—*homonymous hemi-achromatopsia.* This usually represents a cortical lesion, but it may be produced by non-cortical lesions (de Schweinitz).

Bitemporal and binasal hemianopsia are due to lesions of the chiasm.

Homonymous hemianopsia, presenting the Wernicke (pupil inactive) symptom and accompanied by evidence of a lesion at the base of the brain, is dependent on a lesion of the tractus or anterior principal optic (basal) ganglia. The above often causes changes in the appearance of the optic disks. If associated with right hemiplegia, aphasia, and word-blindness. the lesion is due to disease of the area supplied by the middle cerebral artery on the left side. If associated with hemiplegia and hemi-anesthesia the lesion "is probably situated in the posterior part of the internal capsule."

Incomplete hemianopsia, relative hemianopsia, hemi-achromatopsia, are, as a rule, due to lesions in the cortical visual area [1]

Fig. 259

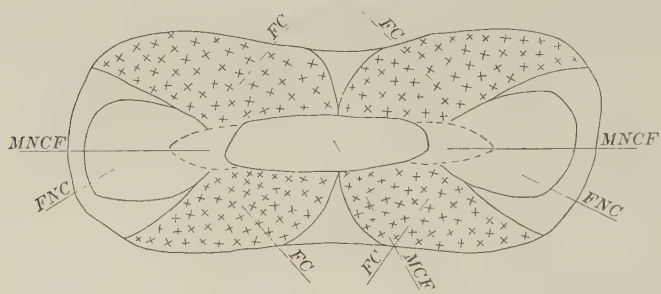

Schematic section of optic chiasm, showing arrangement of bundles of nerve fibers. (Henschen and Barker.) *FC*, crossed fasciculus; *FNC*, uncrossed fasciculus; *MNCF*, macular non-crossing fibers; *MCF*, macular crossing fibers.

The Dividing Line.—In hemianopsia due to lesions of the chiasm or optic nerve the borderline between the blind and the seeing halves is irregular and will not be well-defined unless the lesion is a simple sagittal division. Reference to Fig. 259 will make clear the reason for this statement. There may be a transition zone of relative blindness between the area of absolute blindness and normal field. This in fact is one of the points in differential diagnosis. In hemianopsia from a lesion cerebral from the chiasm the dividing line is sharply cut except, perhaps, at the fixation point; here, as has been described in the chapter on Anatomy, the retina is supplied by neurons whose fibers are connected with both cortical centres. This causes the dividing line to be less sharply defined at the

[1] For an exhaustive discussion of hemianopsia, see Wilbrand-Saenger, Neurologie d. Auges, Band ii, Heft 2.

fixation point and to recede into the amblyopic half. The deviation of the dividing line begins, as a rule, about 10 degrees above and below the point of fixation and extends about 5 degrees into the amblyopic half (Fig. 254). The dividing line may be exactly vertical; it may be somewhat oblique or it may extend around the periphery of the seeing half for a short distance above or below. These peculiarities are explained by supposing an irregularity in the decussation of the centripetal fibers.

Pupil in Hemianopsia.—In hemianopsia due to lesions anterior to the point where the fibers of the reflex pupillary arc are given off from the optic tracts, the pupillary rigidity of Wernicke[1] is present because the lesion has interfered with the conduction of the centripetal fibers of this reflex arc (see page 121). When the lesion is posterior to this point the pupil reacts to the stimulus of light whether the light falls on the blind or seeing side of the retina. This differential point in diagnosis is often difficult to determine, particularly in cases of partial destruction of the chiasm. The method of examination is described on page 122.

Significance of Various Forms of Hemianopsia.—If the hemianopsia is horizontal and is monocular it is due to a lesion of the upper or lower half of one optic nerve near the chiasm; if binocular, to a lesion of the upper or lower half of the chiasm (these forms are accompanied by changes in the optic disks); if homonymous, affecting an upper or lower quadrant of the field of vision, it may be due either to a lesion affecting the upper or lower half of a tractus or the cortical area above or below the calcarian fissure in the occipital lobe. Cases of the latter kind have been reported.[2]

Development.—The development of hemianopsia dependent on disease affecting the optic nerves, chiasm, tracts, and primary visual ganglia is slow, as a rule, and is unattended by symptoms other than those of basal cerebral disease. If due to tumor or cyst posterior to the basal ganglia, the development may be slow, encroaching on the visual field gradually. In the greater number of the cases due to lesions posterior to the basal ganglia, the onset is sudden and the hemianopsia is complete, the lesion being due to hemorrhage, embolism, or thrombosis of the vessels supplying this portion of the brain.

If the cells of the visual memory centre (see p. 87) are excited, as not infrequently occurs in hemianopsia due to cortical or subcortical lesions, phantom vision (visual hallucinations) is produced, the figures being referred to the amaurotic half of the visual fields. Phantom vision may last for some weeks, but, as a rule, subsides in a short time. Faulty orientation is present in some of the cases due to involvement of the cortical memory centre for form.

Prognosis.—In hemianopsia due to hemorrhage or to thrombosis partial or complete recovery of vision may be expected in a small percentage of the cases. If recovery is to take place, it begins almost without exception before the end of the sixth week.

Treatment.—This consists in treating the cause of the hemianopsia.

[1] The Wernicke pupillary sign is the negative sign; that is, the iris does not react when light is thrown on the amaurotic side of the retina.

[2] Buvor and Collies, Brain, 1904, xxvii, p. 153.

CHAPTER XIX.

TOXIC AMBLYOPIA AND AMAUROSIS.

UNDER this heading are included all of the cases of impairment or loss of vision due to the entrance into the system of poisonous substances not produced by the action of bacteria within the body. The terms amblyopia and amaurosis are here given their generally accepted significance.

Classification.—The classification proposed by Dr. Casey A. Wood[1] appears to be the most useful.

Class I.—Poisons that directly affect the optic nerve. These may be divided into (*a*) poisons that produce a chronic retrobulbar neuritis. This includes amyl alcohol, tobacco, carbon sulphide, hasheesh, iodoform, nitrobenzol, dinitrobenzol, stramonium, lead, atoxyl; (*b*) poisons producing other forms of optic-nerve and retinal disease. To this class belong methyl alcohol, lead, quinine, salicylic acid, arsenic, sodium salicylate, ergot, nitrous-oxide gas, male fern, pomegranate, nitrite of amyl, phosphorus, osmic acid fumes, scammonium, colocynth, and toxins.

Class II.—Poisons whose amblyopic symptoms are unaccompanied by retinal or optic-nerve lesions. (*a*) Agents producing mydriasis—belladonna and stramonium and their products, hyoscyamus niger, sulphuretted hydrogen, cocaine, carbolic acid. (*b*) Agents producing miosis—opium and its products, chloral hydrate, jaborandi and calabar bean and their alkaloids, pilocarpine, and eserine. (*c*) Agents producing various irregular eye symptoms—osmic acid, picric acid, santonin, digitalis, gelsemium.

Class I.—Poisons Directly Affecting the Optic Nerve.—Agents Producing a Chronic Retrobulbar Neuritis.—Alcohol.—It seldom happens that retrobulbar neuritis from alcohol alone, or tobacco alone, is observed, as the use of one is almost always accompanied by the use of the other. However, well-authenticated cases have been reported by Uhthoff[2] and others. Microscopic examinations of the optic nerve, chiasm, and tractus have been made in such cases. In the examination of 1000 cases of alcoholism Uhthoff found that 6 per cent. were amblyopic and that 11.8 per cent. presented pathological changes in the optic nerve or optic nerve and retina. Uhthoff collected 135 cases of retrobulbar neuritis due to toxic drugs. The causes were divided as follows: Alcohol in excess of tobacco, 64; alcohol and tobacco, 45; tobacco in excess of alcohol, 23;

[1] Toxic Amblyopiæ, p. 3.

[2] Graefe's Arch., xxxii, 4, 95 to 108, and xxxiii, 1, 257 to 318.

FIG. 260

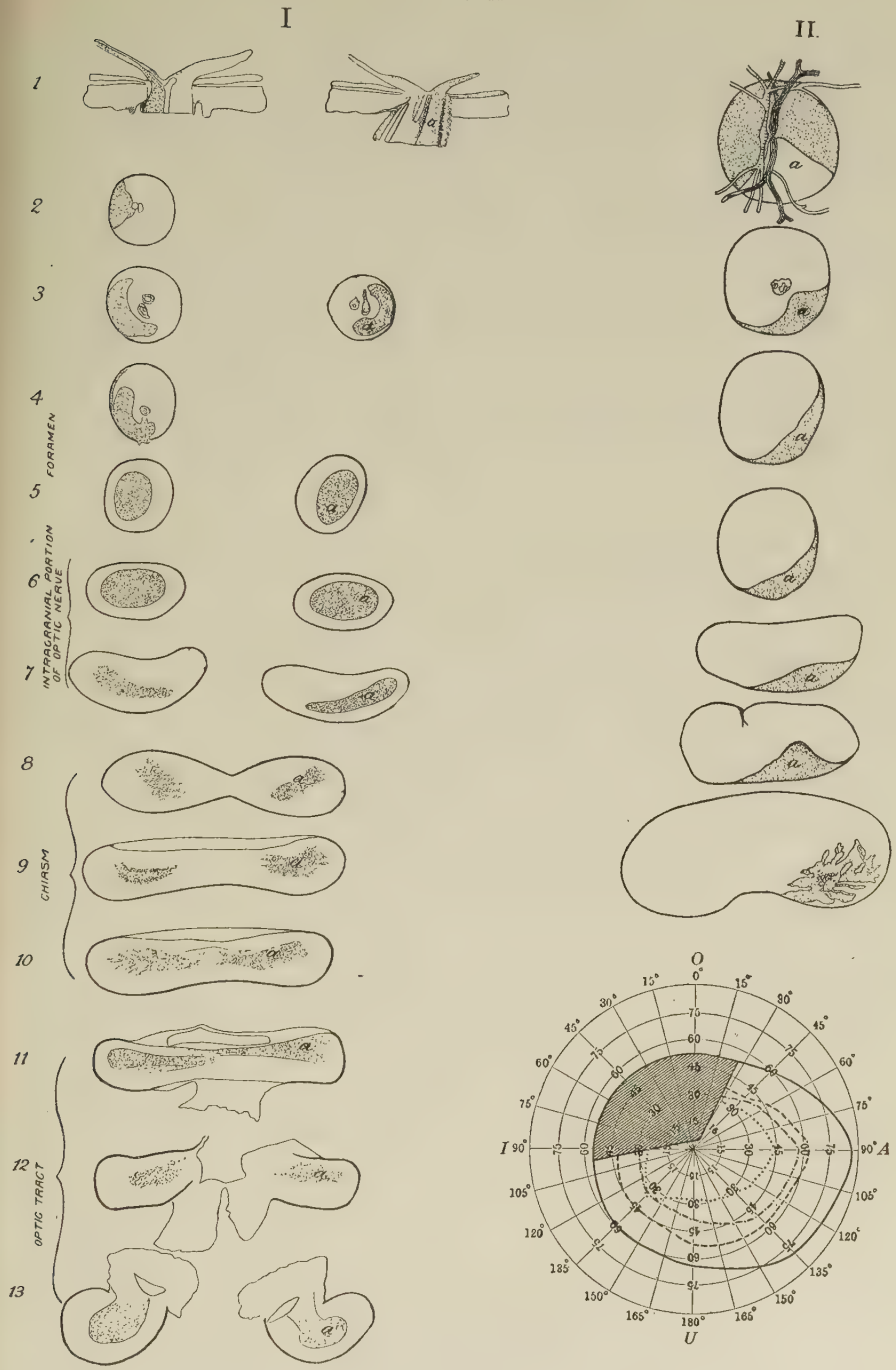

I. Schematic representation of the degenerated papillomacular bundle in the optic nerve, chiasm, and optic tracts (dark areas represent degenerated portions according to Case I of Uhthoff's series).

II. Schematic representation of the course of the nerve fibers in the optic stem, which comprise its lower and outer portion, and which when degenerated produce a quadrant defect in the visual field, upward and inward—tabes dorsalis. Case VII of the series. (Uhthoff.)

lead, 1; bisulphide of carbon, 2. In this series of cases almost 50 per cent. occurred in those who used alcohol, with some tobacco. It has been found that the steady use of alcohol in moderate amounts is far more likely to produce retrobulbar neuritis than excessive use for a short period of time (debauches). The disease is rare before the thirty-fifth year of life. Bär,[1] in a study of 100 cases, observed it in one case at the age of seventeen years; the oldest individual was seventy years old.

Symptoms.—The general symptoms are those of chronic alcoholism—tremor, insomnia, gastro-intestinal disturbances, etc. Ocular symptoms: Gradual loss of central vision. The field of vision is usually normal in extent. In the centre of the field a scotoma, usually oval, its long axis horizontal, is found. This is a relative scotoma for white and for all colors but red and green. In rare cases the central portion of this scotoma becomes absolute. The color scotoma may vary in shape, may be paracentral or sector-shaped. Nyctalopia is frequently present.

Fig. 261

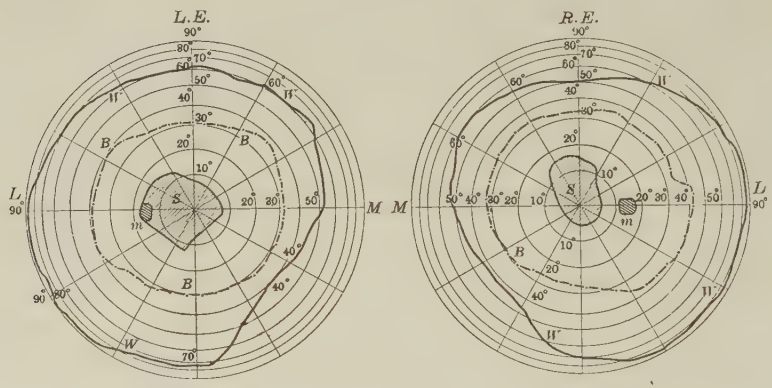

Typical pericentral scotoma in alcoholic amblyopia. (Hirschberg.)

Optic Disk.—In the early stage of the affection the optic disk may present a hazy appearance and the retina be slightly veiled, but this is not of common occurrence. Paleness of the infratemporal quadrant or third of the optic disk develops in about 75 per cent. of the cases, and becomes very pronounced in from one to three months. The vision is seldom reduced below $\frac{20}{100}$; the writer has observed cases in which the vision was reduced to $\frac{10}{200}$.

Alcohol tobacco amblyopia does not differ in any essential point from that of pure alcoholic amblyopia. Rarely is complete blindness produced.

Tobacco.—Disturbance of vision from the use of tobacco may be acute or chronic. *Acute tobacco poisoning* produces sudden and complete blindness; it is extremely rare. A case is reported by Wilkinson[2] following a tobacco enema. The pathological condition produced has not been determined.

[1] Arch. f. Augenheilk., liv, p. 391.

[2] Med. Chronicle, 1888–89, p. 472.

Chronic Tobacco Amblyopia.—This is acquired after a number of years most commonly by those who smoke regularly and to excess. It has been reported as occurring in those who are in the habit of "dipping"[1] and "chewing," and in workers in tobacco factories who inhale the dust. Dowling examined 153 men and 50 women workers in tobacco manufactories. He found 23 cases among the men and two among the women. The women neither drank nor smoked; they had handled moist tobacco for a number of years. Wood[2] is of the opinion that "it is the nicotine that causes loss of vision," but other writers are of the opinion that other toxic agents are in part responsible.

Frequency.—Various observers estimate the frequency of tobacco amblyopia from 1 to 0.1 per cent. of eye patients. In 10,000 cases in the author's private practice tobacco amblyopia has occurred but four times. Judging from statistics, tobacco amblyopia is more common in England and Germany than in the United States. In certain countries, Spain, Turkey and Cuba, the inhabitants appear to be exempt. The time required to produce tobacco amblyopia in those who use tobacco somewhat excessively and constantly averages about fifteen years Nettleship[3] reports one case at the end of three years. The condition is seldom seen in individuals under the age of thirty-five years. Groenouw[4] records the time of development in 178 cases as from twenty-five to twenty-nine years in 6 cases; thirty to thirty-nine years in 53 cases; forty to forty-nine years in 71 cases; fifty to fifty-nine years in 33 cases; sixty to sixty-eight years in 15 cases.

Men and women are equally susceptible, but many more cases are seen in men. Only a very small percentage of those who drink alcohol and those who use tobacco have any defect of vision as a result. "The method of smoking tobacco appears to have a decided influence, the patient being more susceptible if much tobacco comes in contact with the mouth or if the saliva becomes impregnated with it and is swallowed." Both eyes are always affected, but the degree may be greater in one than in the other.

Symptoms.—These are general and local. Digestion may be impaired. A condition of nervous irritability may exist and "tobacco heart" may be present. There may be failure of memory, also diminution of sexual function.

Local Symptoms.—The patient complains that he sees objects as through a fog. Intense illumination is distressing. The patient sees better relatively by moderate illumination. The central vision is defective, the peripheral portion of the field not being impaired, as a rule. Vision ordinarily varies from $\frac{5}{200}$ to $\frac{20}{30}$. Complete blindness has been observed (Widmark, Gifford).

There is nothing characteristic in the size of the pupils or the movements of the irides. The optic disk usually presents the sector-shaped paleness of the lower outer quadrant or third, but no appreciable change

[1] Blitz, Jour. Amer. Med. Assoc., February 15, 1890.
[2] Loc. cit.
[3] Trans. Ophth. Soc. United Kingdom, 1887, vii. p. 43.
[4] Graefe's Arch., xxxviii, 1. p. 1.

may be present. Actual neuritis has been described. Nettleship and Morton have described occasional small retinal hemorrhages.

Visual Field.—The extent of the visual fields is normal. In the vast majority of the cases there is a central scotoma for red and green. Before mapping out this scotoma it is necessary to determine the non-existence of non-toxic red-green color-blindness. In all events, it is best to use yellow and blue also in making the tests. The scotoma (relative scotoma for white) is usually oval, its long axis nearly horizontal, extending from the fixation point, or a short distance to the temporal side of this point, to the normal blind spot. The field for red is larger than that for green. In some cases the field for green and sometimes for red are abolished to the temporal side, the so-called "breaking through" of the color scotoma.

Fig. 262

Typical paracentral scotoma in alcoholic amblyopia. (Hirschberg.)

The scotoma is usually symmetrical, but the scotoma in one eye is more advanced than in the other in some instances, and cases are on record in which the scotoma developed in one eye some months before the fellow eye showed any sign of involvement. In rare cases a scotoma for yellow and blue also exists. The light sense in cases of tobacco amblyopia is greatly reduced, being in some cases one-twentieth that of the normal.

Diagnosis.—The diagnosis of tobacco amblyopia is determined by a history of excessive use of the drug, and the presence of a central relative color scotoma for red and green. A paleness of the outer lower quadrant of the disk makes the diagnosis more probable. To be sure of a diagnosis of tobacco amblyopia, intoxication from alcohol, bisulphide of carbon, nitrobenzol, iodoform, stramonium, cannabis indica, and certain diseases must be excluded.

Prognosis.—This is usually good if the use of tobacco is discontinued. Even if the vision has sunken to $\frac{20}{100}$, almost complete recovery may be expected. Relapses may occur if the use of tobacco is resumed, although this is rare. In the analysis of 64 cases of tobacco amblyopia, Hutchinson[1] reports recovery in 48 cases, no change in vision in 4 cases, diminu-

[1] R. L. Ophth. Hosp. Reports, viii, p. 356.

tion in vision in 7 cases. In 5 cases the patients were blind when first seen and remained so. No relapses.

Pathology.—The lesion in toxic amblyopia of the chronic type is, according to many writers, a low form of interstitial inflammation affecting the macular bundle of nerve fibers in the optic nerve, chiasm, and tracts. Late researches (Nuel) indicate that in all probability the primary lesion is a parenchymatous neuritis—an affection of the nerve fibers themselves. The increase in neuroglia and interstitial connective tissue is secondary. Nuel is of the opinion that retrobulbar neuritis always affects retina and nerve conjointly, but that the primary lesion is in the nerve. The investigations of J. H. Fisher with nicotine indicate a probable primary affection of the neurons of the retina. The first anatomical demonstration of the location of the macular bundle of nerve fibers in the optic nerve, chiasm, and tract was made by Samelson[1] in 1882.

Section of the optic nerve discloses an increase in neuroglia cells and in the connective tissue of the trabeculæ, a slight infiltration of leukocytes and a marked decrease of nerve fibers. Except in the rarer cases some nerve fibers remain intact, accounting for the absence of absolute scotomata.

Treatment.—The use of alcohol and tobacco should be completely discontinued. The diet should be carefully regulated. The general condition of the patient should be improved as much as possible by careful attention to the diet, the use of local remedies, and out-of-door life. Strychnine, because of its effects on the nervous system and on the heart action, is particularly valuable. It may be given by the stomach or by hypodermic injection, using the nitrate or sulphate in the dose of $\frac{1}{60}$ of a grain once daily, gradually increasing the dose until clonic contractions of the leg muscles are produced, decreasing the dose subsequently. Pilocarpine sweats are highly thought of by some surgeons. Digitalis may be required to stimulate the heart action.

Bisulphide of Carbon and Chloride of Sulphur.—De Schweinitz collected 48 cases, none of which occurred in the United States. All of the patients worked in rubber factories in which the bisulphide of carbon mixed with the chloride of sulphur was employed. The ages of the patients ranged from fifteen to sixty-five years. All but five were males. In 1885 the Ophthalmological Society of the United Kingdom[2] appointed a committee to investigate the amblyopia due to poisoning by carbon bisulphide. This committee concluded that the pathway of the entrance of the poison is through the lungs, the poisoning being in direct proportion to the inhalation of the fumes. If suitable apparatus is employed to prevent the inhalation of the vapor, amblyopia is prevented no matter how frequently and how long the hands may be immersed in the fluid.

Pathology.—Autopsies are wanting.

Symptoms.—These are divided into two stages by Delpech: (1) The stage of exaltation, in which there is vertigo, variable spirits, hilarity, and

[1] Graefe's Arch., xxviii, Abl. 1, p. 1,

[2] Trans. Ophth. Soc. United Kingdom, v, p. 157.

depression, increased appetite, sexual excitability, cutaneous excitability; (2) the stage of depression, in which there is anesthesia of the skin, cramps, muscular weakness, loss of sexual desire, mental impairment, emaciation and wasting of muscles. According to de Schweinitz, 40 per cent. of the cases of chronic bisulphide of carbon poisoning are amblyopic.

Ocular Symptoms.—A "fog appears before the eyes," most noticeable at the end of the day. Pupils dilated. Vision much reduced. The fields of vision are normal in extent, but central negative (sometimes positive) scotomata are almost invariably present. Heath[1] reports a case in which the fields of vision were contracted for form and for colors without central scotoma. Pallor of the disk is noted. These symptoms deepen if exposure to the fumes is continued.

Diagnosis.—The patient will always give a history of the stages of exhilaration and depression, more or less marked, in connection with that of having worked in the presence of the fumes of bisulphide of carbon.

Prognosis.—If the patient can be removed from the presence of the noxious fumes the prognosis is good. Of the reported cases recovery or improvement occurred in about 60 per cent., no improvement in 20 per cent.; the remaining 20 per cent. were not reported on.

Treatment.—The prophylactic treatment consists in the use of suitable apparatus to prevent the inhalation of the fumes. The medicinal treatment consists in the building up of the general system by the use of suitable tonic remedies, including iron, strychnine, phosphorus, and the iodide of potash; and massage and forced feeding if the stage of the wasting of muscles is reached. Electricity may be of value.

Iodoform.—Amblyopia from iodoform has been observed in a very few instances. The first case was reported by Hirschberg in 1882.[2] The drug is absorbed either from large denuded areas on which it has been sprinkled[3] or from the stomach.[4] The denuded area must be large and the iodoform be used for some days before amblyopia is produced. If taken by the stomach the period of treatment must be long and the amount taken be large before the toxic effect is experienced (1000 grains in Priestley-Smith's case).

Ioduret and thiuret[5] are said to produce amblyopia resembling that produced by iodoform.

Symptoms.—Constitutional symptoms consisting of diarrhea, faintness, drowsiness, may be experienced.

Local Symptoms.—A mild neuroretinitis develops in the early stage of the amblyopia in many cases (Mohr, Snyder). In one case reported the appearance of the disk was normal; in one there was haziness of the disk; in three partial atrophy. The fields of vision are normal in extent, but there is a central scotoma for red and green resembling that in tobacco amblyopia. The central scotoma may be absolute for white

[1] Annals of Ophth., January, 1902.
[2] Centralbl. f. prakt. Augenheilk., 1882, p. 92.
[3] Hirschberg, Valude, Terrier, Arch. d'opht., 1897, xvii, 10.
[4] Priestley-Smith, Ophth. Review, 1893; E. Hutchinson, New York Med. Jour., January 2, 1886
[5] Karl Baar, Das Gesichtsfeld, Stuttgart, 1896, S. 173.

(Priestley-Smith). Vision seldom sinks below $\frac{1}{100}$. The pupils may be dilated and sluggish.

Prognosis.—The prognosis is good. In the recorded cases recovery to almost normal vision occurred in eight days in one, in six months in one.

Treatment.—The use of iodoform must be discontinued. Strychnine has been found of the greatest service in restoring vision. Suitable remedies for the purpose of improving the general condition should be employed.

Cannabis Indica, Hasheesh.—Cases of typical central scotoma resembling that in tobacco-alcohol amblyopia have been described by Ali.[1] Some of the cases are unilateral. These cases occurred in the Orient, where the using of hasheesh is more common than in other parts of the world.

Nitrobenzol and Dinitrobenzol.—Nitrobenzol is produced by the action of fuming nitric acid on benzol. The odor resembles that of the oil of bitter almonds; it is used for scenting soaps and in the manufacture of aniline. Dinitrobenzol, made by boiling benzol in the presence of fuming nitric acid, is used in the manufacture of "roburite," a high explosive. The cases of amblyopia due to poisoning by these substances are similar. The cases are rare. White[2] reports six cases and Snell[3] describes five cases of amblyopia from poisoning with dinitrobenzol. The entrance of the poison is by absorption through the skin or the mucous membranes of the respiratory tract.

Pathology.—The central scotoma and the concentric limitation of the field evidently place the change in the category of the amblyopias due to nutritional disturbances.

Symptoms.—These are general, as well as referable to the eye. The eye symptoms consist in a diminution of central vision and some narrowing of the field. There may or may not be a central scotoma for red and green. The amblyopia is bilateral and symmetrical. Ophthalmoscopic changes consist in a cyanosis of the retina. The dark appearance of the fundus is due to the fact that these substances have the effect to cause the blood to lose its power of absorbing oxygen, changing the blood to a deep chocolate color. Vision sinks to $\frac{10}{200}$ or less.

Prognosis.—Vision usually returns to approximately the normal if the patient is removed from contact with the substances.

Lead or Saturnine.—The amblyopia produced by lead may be due to retrobulbar neuritis with or without fundus changes. Both eyes are affected and the lesions are approximately symmetrical.

Method of Entrance.—The lead may enter the system (1) by the stomach by eating articles of food that are contaminated with lead, or by drinking water or other fluids that contain lead, fluids that have passed through lead pipes or have been retained in lead receptacles; (2) by the skin, either from handling lead in some form or by the use of cosmetics.

[1] Rec. d'opht., 1876, p. 258.
[2] Provincial Med. Jour., 1892, ii: p. 462.
[3] Brit. Med. Jour., 1894, xiii, p. 340.

Cases of lead poisoning occur in tailors and seamstresses who are in the habit of biting thread that may be "weighted" with sugar of lead. Those who work with the carbonate of lead, painters, and those who work in the manufacture of white lead furnish the greater number of patients. Individuals at all ages may be affected, males more frequently than females because more commonly exposed.

Length of Time Required.—This varies with the susceptibility of the individual and the amount of lead taken into the system. An exposure of twelve days has sufficed. In many cases years may elapse before the amblyopia is established.

Pathology.—It is probable from a study of the defects of the field of vision that the optic neuritis may be general or localized. In some cases the papillomacular bundle only is apparently affected. The exact changes in the nerve are not known, since reliable microscopic examinations are wanting.

Symptoms.—Disturbances of the general system almost always precede disturbances of vision—colic, headache, drop-wrist, etc. The ocular symptoms have been well enumerated and classified by de Schweinitz.[1] Slightly modified they are as follows:

1. Sudden transient amblyopia without ophthalmoscopic changes, "not unlike amaurosis from uremia without fundus lesions."
2. Amblyopia usually permanent either without distinct fundus changes or with slight hyperemia of the disk, a condition similar to retrobulbar neuritis due to other causes.
3. Fundus changes due to optic neuritis or to neuroretinitis of moderate type, depending on the direct effect of the lead, or secondary to changes in the brain or kidneys.
4. Optic atrophy, primary or secondary to papillitis.
5. Retinitis, "often due to lead nephritis," but also primary retinitis with vasculitis and perivasculitis.

The inaction of the iris to the stimulus of light and the condition of the pupil depend on the condition of the optic nerve.

The fields of vision are impaired in various ways, depending on the affection of nerve and retina: (1) Concentric limitation for form and color in cases of general optic-nerve atrophy, sometimes associated with peripheral relative or absolute scotomata. (2) Typical central scotoma, relative or absolute.

Vision.—All degrees of diminution in vision are noted.

Diagnosis.—This can only be made by exclusion, a history of lead poisoning without other discoverable cause for the lesions present. Lead may be recovered from the urine in some cases. The blue line on the gums is present in many cases of chronic lead poisoning.

Prognosis.—In 58 cases reported by de Schweinitz, recovery occurred in 33, no improvement in 25. Of 114 cases reported by Lewin,[2] recovery occurred in 40 only; atrophy of the optic nerve was noted 36 times. The

[1] Toxic Amblyopiæ, p. 156.

[2] Berl. klin. Woch., December 12 and 19, 1904.

probabilities of the recovery of vision in postneuritic and in simple atrophy are not good. Absolute central scotomata may remain permanent or may pass into complete atrophy. In the cases of sudden amaurosis, recovery is usually complete.

Treatment.—Early vigorous treatment is desirable. The first indication is to prevent the ingestion of more lead, If work is continued, the shop should be well ventilated, respirators should be used, gloves worn. The mouth should be washed frequently and it may be advisable to take baths of the sulphuret of potassium twice a week. The second indication is to eliminate the poison from the system. This may be accomplished by means of the iodide of potassium internally, ten to fifteen grains three times daily, and baths of the sulphuret of potassium every forty-eight hours, six or seven ounces of the salt to the bath, the water to be warm and the bath continued for half an hour, with frequent rubbings of the skin with a coarse towel. The third indication is to relieve symptoms and to restore lost function. For the relief of colic, cathartics are indicated. Alum is of great value. It may be given as alum curd, the patient partaking freely of it four or five times daily.

If optic-nerve atrophy threatens, pilocarpine, to produce copious sweating, and strychnine may be employed. Nephritis or other diseases may require special attention.

Stramonium.—The smoking of stramonium leaves in large quantity may produce a toxic amblyopia, with affection of the papillomacular bundle resembling that produced by tobacco.[1] Improvement in vision generally follows discontinuation of the habit. Cerillo[2] reports the case of an asthmatic patient who smoked stramonium leaves four years. Amblyopia resembling that from tobacco developed. Recovery two months after discontinuing the use of the drug.

Coffee.—The excessive use of strong coffee may produce a narrowing of the fields of vision and relative central scotoma. Bulson[3] reports a number of cases. Recovery takes place on discontinuing the use of the coffee.

Thyroid.—Coppez[4] reports the observation of five patients, between the ages of thirty and forty years, who had taken thyroidin for many months for the reduction of fat. They developed symptoms of retrobulbar neuritis, with central scotoma. The condition increased rapidly after it began. In six to eight weeks, $V = \frac{1}{10}$. After discontinuing the thyroidin, improvement in vision began, but was not complete until many months had elapsed.

Pathology.—Experimental investigation on dogs[5] shows the anatomical changes to be a degeneration of the ganglion cells of the retina, with secondary degeneration of the optic-nerve fibers.

Copper.—A case of supposed amblyopia from the absorption of copper, in which vision was reduced to $\frac{1}{10}$ in the right eye, and an absolute central scotoma existed in the left eye, was reported by Galezowski.[6]

[1] Fuchs, Text-book of Ophth., New York, 1899, p. 491.
[2] Rec. d'opht., 1895, p. 403.
[3] Am. Jour. of Ophth., February, 1905.
[4] Arch. d'opht., 1900, p. 656.
[5] Birch-Hirschfeld and Inouye, Graefe's Arch., lxi, p. 3.
[6] Ophth. Review, March, 1906.

Poisons Producing Other Forms of Optic-nerve and Retinal Disease.—**Methyl Alcohol** (*Wood Naphtha; Wood Spirit*).—This is a deadly poison if taken in quantity. Moulton[1] reports death in two men who drank each about half a pint; three others who drank a similar quantity were rendered very ill. Amblyopia is induced in quite a high percentage of the individuals into whose systems methyl alcohol enters. Males and females are alike susceptible.

Method of Entrance.—The most frequent method is by the stomach. One ounce so taken has produced blindness (Bogue). A number of cases are on record in which the alcohol entered by the lungs; also by the cutaneous surface. In one case (Schapringer) the patient was engaged in shellacking the interior of large beer vats and inhaled the fumes. In another case (Colburn) the patient used methyl alcohol for cleansing clothing. Methyl alcohol may also be taken into the system in the form of Jamaica ginger, essence of peppermint, essence of cinnamon, eau de cologne, bay rum, colombian spirits, by the stomach. Amblyopia comes on in from eighteen to thirty-six hours, often being present when the patient recovers consciousness after a debauch. If exposed to the fumes, the alcohol entering the system by the lungs may produce amblyopia in from eight to twenty-four hours, or a number of months may elapse before blindness is induced.[2]

Pathology.—The changes in the organ of vision following the ingestion of methyl alcohol occur in the ganglion cells of the retina. At first a toxic effect on the cells occurs, causing a pronounced loss of function. This primary toxemia disappears in part in a few days or weeks and is followed by a secondary degenerative process which again reduces vision. The degeneration consists, first, in chromatolysis. The cells become somewhat edematous, vacuolated, the nuclei disintegrate, further degenerative changes take place, and the cells disappear. Secondary degeneration of the axis cylinders occurs and optic-nerve atrophy develops.

Blood-vessels.—The arteries become narrow; the veins remain approximately of normal size.

When the atrophy is advanced the arteries are sometimes reduced to mere threads.

The first experimental study was made by Ward Holden.[3] His conclusion was that the primary effect was on the ganglion cells of the retina. These results were confirmed by Birch-Hirschfeld.[4]

Symptoms.—The general symptoms are those of intoxication—dizziness, nausea and vomiting, headache. The local symptoms are: (*a*) neuroretinitis of moderate degree present during the first two to five days; (*b*) disturbance of vision, which may amount to total blindness at once, or the impairment of vision may be partial and may seriously affect parts of the retina only. The irides are responsive to light in proportion to the degree of vision remaining. When blindness is com-

[1] Ophth. Record, July, 1899.
[2] De Schweinitz, Ophth. Record, June, 1901.
[3] Arch. of Ophth., xxviii, 2, p. 125.
[4] Graefe's Arch., lii, p. 358, and liv, p. 68.

plete the pupils are widely dilated. Lateral movements of the globe produce pain in some of the cases.

Fields of Vision.—The effect on the field of vision is general, as a rule, but in some cases concentric limitation or scotomata of various shapes may be present. Scotomata may be relative or absolute, and may affect any part of the field.

Prognosis.—Permanent recovery of a degree of vision much above the maximum primary diminution may, but seldom does, occur. Following the primary diminution, there may be an improvement lasting some

Fig. 263

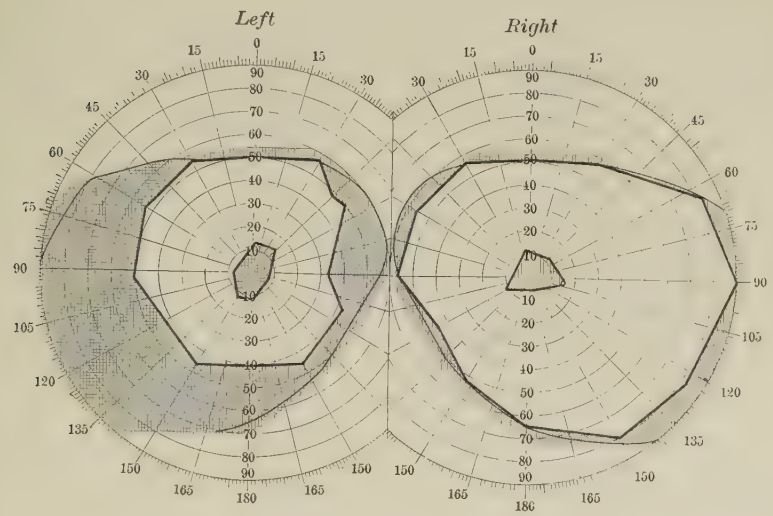

Concentric limitation of visual fields. Absolute central acotoma, left eye; relative central scotoma right eye. (Author's case.)

days or weeks; then the vision again fails. The secondary decrease in vision may exceed the primary impairment. Gifford reported a case in which vision improved slightly after the degenerative process was complete, a very rare result.

Treatment.—This appears to be of but little avail if we except the use of strychnine in large doses long-continued. In a case narrated by Ring,[1] large doses of strychnine sufficed to improve the vision from $\frac{2}{200}$ to $\frac{6}{200}$ in one eye and from $\frac{4}{200}$ to $\frac{10}{200}$ in the other eye.

If seen early an attempt may be made to remove the poison from the stomach by means of the stomach pump and by high rectal injections. Pilocarpine and the iodide of potash have been recommended.

Quinine.—Amblyopia develops in a very small proportion of the individuals who take large doses of quinine and continue the dose for a long period of time. The blindness comes on in from twenty-four to seventy-two hours, is often complete, but is transitory. Individuals at

[1] Trans. Amer. Ophth. Soc., 1902, p. 529.

all ages are affected, except the extremely young and the extremely old. Males and females are alike susceptible. The quantity of quinine required to produce amblyopia varies greatly in different individuals. Dr. H. C. Wood[1] has observed amblyopia in a woman after taking twelve grains of quinine. It is thought by de Schweinitz that the poison of malaria neutralizes to some extent the effect of quinine on the eye. Both eyes are affected equally and simultaneously, as a rule; there are rare exceptions.

Pathology.—It has been clearly proved experimentally that the first change in the tissues of the eye is in the neurons of the retina,[2] chromatolysis followed by vacuolation, edema, and eventual disappearance. Secondary atrophy of the optic nerve follows. It is now held that the effect is a direct one on the nerve cells, not due to the anemia, although much contraction of the retinal vessels and a paleness of the entire fundus have been observed in the early as well as in the later stages of the amblyopia.

Symptoms.—The symptoms are general as well as local, and consist in dizziness, headache, delirium, stupor, deafness, tinnitus aurium. The affection of vision may be very slight. When this is the case, slight haziness develops. The pupils may be dilated or of normal size, and the irides may react sluggishly or normally. Accommodation is temporarily impaired. In the severe cases the blindness is total, often coming on suddenly, as by the dropping of a veil; sometimes a day, sometimes several days are required to produce the maxium diminution of vision. During the stage of complete blindness the pupils are widely dilated, do not respond to the stimulus of light, but respond slightly to convergence (Gruening). Anesthesia of the cornea, proptosis, increased tension, nystagmus, and divergence have been observed.

Ophthalmoscopic Appearance.—The disk is pale, arteries and veins contracted. There is sometimes edema of the retina posteriorly, with a red spot at the macula, as in plugging of the central artery of the retina. Paleness of the entire fundus is often seen. In some cases observed very early there has been no apparent change in the optic disk. After some days the disks become quite pale, and the blood-vessels more reduced in size.

Visual Field.—In almost every case the visual field is contracted concentrically in the early stage (if not completely abolished), the long axis of the preserved field being horizontal. After complete blindness the central portion of the field is restored first. When in process of recovery absolute scotomata may be scattered over the fields. Absolute central scotoma has been observed in a few cases.

In almost all cases there is permanent loss of a portion of the periphery of the fields of vision, and in a majority of the cases there is slight general impairment of the entire field. The fields for colors

[1] De Schweinitz, "Toxic Amblyopiæ," p. 181.

[2] Holden, Arch. of Ophth., November, 1898; Drusault, Arch. d'opht., 1900, and others.

are reduced concentrically to a greater degree than the fields for form.

Diagnosis.—The history of the taking of large doses of quinine, together with the symptoms, constitutional and local, will enable the observer to make the diagnosis without question.

Prognosis.—Complete blindness from quinine has not been recorded, although one or two cases in which vision was permanently reduced to perception of light have been observed. De Schweinitz states that "complete restoration of the visual field when once contracted does not occur in grave forms of quinine amaurosis." It may be stated that the prognosis for the restoration of good central vision in quinine amaurosis is, as a rule, excellent.

Treatment.—The administration of strychnine, preferably hypodermically, is the only treatment that appears to be of value. The general health of the patient must be made as good as possible.

Aspidium (*Male Fern; Filix-mas*).—The rhizome of dryopteris filix-mas, when given in large dose, may cause blindness which may be recovered from or may become complete and remain so. The remedy is always taken as an anthelmintic. The cases of blindness from this cause are very rare. The size of the dose necessary to cause amblyopia varies greatly. The smallest dose known to have produced amblyopia is 7.3 grams, taken by a woman, aged twenty-two years. Lethal doses have been taken without producing amblyopia. In 78 cases of poisoning, permanent blindness in one or both eyes occurred in 33. Amblyopia in 5 cases.

Pathology.—It has been determined experimentally by Miel[2] that the most pronounced effect is upon the optic nerve, which, according to this author becomes swollen and stiffened, pushing the globe forward. The swelling and stiffness gradually diminish and at the end of two months the nerve may have become very small, and completely atrophic. In cases in which the attack is severe, Miel states that all of the nerve fibers in the optic nerve just behind the eye may entirely disappear by the end of the third day. The axis cylinders disappear and the neuroglia sheath becomes much distended by the presence of a watery fluid. The process is one of interstitial edema of the optic nerve without distention of the subvaginal space, probably preceded by a primary affection of the nerve fibers themselves. There is very little small-cell infiltration.

It has been found that changes take place in the neurons of the retina, almost if not quite as early as in the optic-nerve fibers, and it is very difficult to decide which are first affected. Miel holds that the optic neuritis precedes; Birch-Hirschfeld that the retinal neurons suffer first.

Symptoms.—General symptoms due to this disturbance are marked; the remedy is an active gastro-intestinal irritant.

Eye Symptoms.—The amblyopia is the first disturbance noticed. This comes on in from twenty-four to seventy-two hours if it originates

[1] Sidler-Huguenin, Corresbl. f. Schweiz. Aerzte, 1898, No. 17.
[2] Miel, trans. by Marlow, Annals of Ophth., April, 1902.

from a single large dose. If due to repeated small doses ten days may elapse before amblyopia is produced. The pupils are dilated, and if the blindness is not complete, the irides react sluggishly to light. In the early stage of the amblyopia the retina may be extensively edematous (Stuelp) or the fundus of the eye may not present any change. If the amblyopia is not recovered from, the optic disk becomes pale, the retinal vessels extremely small, and atrophy is gradually established.

Prognosis.—The prognosis should be guarded. Complete recovery has been recorded.

Treatment.—General tonic treatment and the administration of remedies that stimulate nerve-tissue and increase the circulation, as strychnine and amyl nitrite, are indicated.

Salicylic Acid.—Transient bilateral amaurosis, which may amount to complete blindness, followed in from twenty-four to thirty-six hours by complete restoration of vision, may follow the administration of large doses of salicylic acid. The amaurosis resembles very closely that produced by quinine. It is accompanied by tinnitus and vertigo. Aside from a slight overfilling of the retinal veins, no fundus changes have been observed. The salicylate of sodium is thought to have a similar effect in rare cases.

The amblyopia is evidently due to the direct effect of the drug on the neurons of the retina.

Oil of Wintergreen.—Baum[1] has recorded a case of temporary amblyopia after taking about 24 c.c. of the oil of wintergreen, in divided doses, in forty-eight hours.

Prognosis.—Favorable.

Treatment.—If the administration of the drug is discontinued, recovery follows rapidly.

Ergot.—In large dose by the stomach[2] ergot may produce temporary blindness with dilated pupils. The cases are extremely rare; the four on record are not carefully reported. In Hume's case, vision became greatly diminished a few hours after taking a small teaspoonful of Squibb's fluid extract. The vision was fully restored in forty-eight hours. There is no report of an ophthalmoscopic examination. By far the greater number of cases of impairment of vision from ergot occur in chronic ergot poisoning, as by the use of ergotized bread. It results in the formation of cataract. (See Cataract.)

Pomegranate.—Pelletierine (the active principle of pomegranate) is employed as a sulphate for the expulsion of tapeworm. When large doses are taken it is said to produce some impairment of vision and enlargement of the retinal veins.

Arsenic.—It is questionable whether arsenic produces amblyopia, but a number of cases of amblyopia in which arsenic appears to have been the cause have been reported. Derby[3] reports optic neuritis and amblyopia as possibly having been caused by arsenic.

[1] Ophthalmic Record, January, 1903.
[2] Hume, Med. News, November 5, 1887, p. 53.
[3] Boston Med. and Surg. Jour., 1891, i, p. 603.

Atoxyl (*Meta-arsen-anilid*).—This, when taken by the stomach or hypodermically, may produce amblyopia and blindness. The quantity necessary to produce amblyopia varies greatly in different individuals. Amblyopia from the subcutaneous injection of 10 grains, given over a considerable period of time, has been reported by Lesser and Greef.[1] Fifty grams taken by the stomach over a period of seven months[2] produced blindness.

The drug has been employed in the treatment of syphilis, pemphigus, and sleeping sickness. In all of these conditions amblyopia or blindness has been reported as a result.[3]

Symptoms.—The impairment of vision progresses rapidly and attains its height in a few days. There is contraction of the fields of vision, particularly the nasal half, followed by partial or total blindness. The amblyopia or blindness may remain stationary or partial recovery may take place. The affection assumes the character of atrophy of the optic nerve and neurons of the retina. Retinal hemorrhages may occur.[4]

Birch-Hirschfeld and Koster,[5] as the result of experiments on dogs and rabbits by the daily administration of small doses of atoxyl, describe the lesion as a destructive process affecting the optic nerve, retina, and central nervous system.

Prognosis.—Uncertain. Some degree of vision is recovered in some cases; in others the process goes on to complete blindness.

Treatment.—This consists in the withdrawal of the drug and general tonic measures.

Nitrite of Amyl.—This has much the same effect on the optic nerve and retina as nitrous oxide gas. Chromatopsia and hallucinations of vision have been observed.

Phosphorus.—Hyperemia of the retina has been observed in acute and chronic phosphorus poisoning (Jeffrie). Retinal hemorrhages were followed by "fatty degeneration of the retinal tissue and an ophthalmoscopic picture not unlike retinitis albuminurica" (de Schweinitz).

Mercury, Silver.—The production of amblyopia is credited to the use of mercury and its salts and to the use of the nitrate of silver, but the cases are not authentic. (For a discussion of reported cases, see de Schweinitz, *Toxic Amblyopiæ.*)

Coal-tar Products.—Workers in aniline dyes sometimes suffer from amblyopia. Veasey reports the case of a dyeworker who presented slight optic neuritis and negative central scotomata, the dye principally employed being aniline.

Antifebrin and Acetanilid.—These are reported to have caused complete blindness with a condition of the optic nerve and retina and contraction of the visual field closely resembling that produced by quinine.[6]

[1] Fehr, Deutsch. med. Woch., December, 1907.
[2] Krüdener Festsch. v. H. Kuhnt, Ztschr. f. Augenheil., 1906.
[3] See Verderame and Hoppe, Klin. monatsbl. f. Augenh., April, 1908, for a review of the subject.
[4] Herford, Annal. d'oculistique, October, 1908.
[5] Fortschrit. d. Medizin, xxvi, 22, p. 673.
[6] Hilbert, Therapeutische Woch., 1897, Band iv, S. 728.

Osmic Acid.—A few cases of profound but transient amblyopia from the action of osmic acid on the retina have been reported,[1] accompanied by severe irritation of the conjunctiva.

Scammonium and Colocynth.—Taken together, these have, according to Sirni,[2] produced amblyopia with choked disk, tortuous veins, small arteries, and edema of the retina.

Potassium Chlorate.—Roselli[3] reports a case of amblyopia following poisoning from potassium chlorate; the ophthalmoscopic examination revealed a pale fundus. Recovery complete in one week.

Ptomaine-poisoning.—"Ptomaines and leukomaines affect the eye in much the same way as the mydriatic poisons." Cases are most frequently seen in those who eat "high" game and uncooked or partly cooked food. In rare cases a mild neuroretinitis is produced.

Cachexia Amblyopia.—Cachexia amblyopia accompanying the later stages of carcinoma has been described.[4]

Class II.—Poisons Whose Amblyopic Symptoms are Unaccompanied by Retinal or Optic-nerve Changes.—(*a*) **Agents Producing Mydriasis.**—Belladonna, hyoscine, daturine, duboisine, homatropine, scopolamine. (See Mydriatics.)

Cocaine.—In *acute cocaine poisoning* the amblyopia is due to the syncope; the pupils are dilated and sluggish. Vision returns to the normal after the effect of the cocaine passes. In *chronic cocaine poisoning* transient amblyopia, hallucinations of vision, diplopia, hemianopsia, and chromatopsia may be experienced.

Sulphuretted Hydrogen.—This is mentioned by Casey Wood[5] as having produced temporary amblyopia, mydriasis, exophthalmos, loss of pupillary reflex, and anesthesia of the cornea.

Carbolic Acid.—This chemical when absorbed into the system may produce a temporary profound amblyopia which will be recovered from in from twelve to forty-eight hours. The pupils will be dilated and not responsive to ordinary stimuli.

(*b*) **Agents Producing Miosis.**—**Opium.**—Visual disturbances from the use of opium, aside from the slight diminution of vision in reduced illumination, due to the small pupil, are so unusual that they may be disregarded.

Chloral Hydrate.—A few rare cases of amblyopia from the use of chloral hydrate have been observed. Mittendorf records a case of amblyopia which occurred after six months' use of the drug; from forty to sixty grains were taken daily. The amblyopia disappeared after the use of the drug was discontinued. Miosis is one of the symptoms of poisoning.

Jaborandi and Calabar Bean.—See Miotics.

Muscarine and Curare.—Active poisons and also miotics. They produce amblyopia by miotic action.

(*c*) **Agents Producing Irregular Eye Symptoms.**—**Toxic Chromatopsia.**—Certain drugs when given in sufficient dose produce colored

[1] Noyes, Amer. Ophth. Soc., 1866, p. 34.
[2] Bull. d'ocul., September 1, 1884.
[3] Bull. d. Ospedale Ottal., April, 1903.
[4] Tojoda, Klin. Monatsbl. f. Augenhl., February, 1907.
[5] Toxic Amblyopia, p. 10.

vision of which xanthopsia, or "yellow-seeing," is the most common. Of these drugs *santonin* is best known. The dose required is 0.3 gram to 0.6 gram. The "yellow-seeing" sets in from thirty to forty minutes after the dose has been taken, and, according to Knies, is preceded by a short period of violet-seeing. The color may change, red and green vision having also been observed after poisoning with santonin. It is thought that the effect is produced by cerebral irritation rather than from any effect on the retina or staining of the media. The chromatopsia lasts from two to four hours. No changes in the retina or optic nerve have been observed.

Other drugs that have been known to produce chromatopsia are nitrite of amyl, chromic acid, digitalis, carbonic oxide, tobacco, cannabis indica, and picric acid. Hilbert's[1] experiments on himself with the latter drug produced symptoms similar to those of santonin poisoning; slight yellow vision followed two hours after the taking of 0.3 gram. Cannabis indica may cause violet vision; coffee, red vision.

[1] Centralbl. f. prakt. Augenheilk., March, 1885, S. 70.

CHAPTER XX.

ASTHENOPIA (WEAK SIGHT) AND HYSTERIA.

ASTHENOPIA.

The term asthenopia in its literal meaning would have but a limited application in reference to the eye, but, as Risley states, the word has come to signify painful sight as well as weak vision.

Asthenopia is classified as (1) accommodative, (2) muscular, (3) neurasthenic or nervous, (4) retinal, (5) tarsal, (6) reflex.

Asthenopia occurs most frequently in neurasthenics, in the physically weak, in those who suffer from indigestion, and in those who follow vocations that require more or less constant use of the eyes. The use of the eyes for distance or near vision soon produces unpleasant symptoms; as increased lachrymation, inability to maintain single monocular vision, headache, dizziness, nausea and vomiting, orbital and peri-orbital pain, redness of the eyes with itching and burning of the eyelids; somnolence in some individuals, insomnia in others. There are visual hallucinations; phantom figures are seen. Fatigue contraction of the field of vision occurs in some subjects. There may be scintillating scotoma, and transient hemianopsia, usually homonymous, at times affecting the upper or lower halves of the fields of vision, in some cases monocular. Large central scotomata are sometimes present. The defects in the fields of vision last for a few seconds in some patients, for a few minutes or hours in others. Phantom vision, micropsia, and macropsia are also described. Brief total blindness is sometimes experienced. The visual phenomena are undoubtedly due to transient disturbances in the cortical visual areas of the brain, and their associated memory centres for visual impressions. It is probable that these disturbances are of vasomotor origin. Twitching of the eyelids is met with; also excessive nictitation. Remote disturbances, often not recognized as being caused by use of the eyes, are also produced. The effect upon the mind is often most pronounced in asthenopia, loss of mental balance and an approach to melancholia sometimes being the result.

The different forms of asthenopia present certain inherent peculiarities.

Accommodative Asthenopia.—This, caused by fatigue of the ciliary muscle, is accompanied by inability to use the eyes for close work, whether one or both eyes are employed, and in many cases inability to fix the gaze on distant objects for any length of time without discomfort. In these cases an error of refraction or an undue limitation of the range of accommodation is at fault. The correction of these errors gives relief.

The use of a cyclopegic causes the symptoms to disappear while the cyclopegic controls the ciliary muscle. Monocular diplopia is not an infrequent accompaniment of this form of asthenopia.

Muscular Asthenopia.—This is a condition in which the common train of symptoms is set up by use of the eyes for any distance after the error of refraction is corrected, due to fatigue of the extrinsic muscles of the eyes. A symptom more constant in this than in any other form of asthenopia is binocular diplopia. The attempt to maintain binocular single vision in heterophoria soon produces fatigue and a deviation of the visual axes takes place. Asthenopia due to this cause would be relieved by the correction of the muscular imbalance. In many cases covering one eye brings about relief from the symptoms.

Neurasthenic Asthenopia.—Neurasthenia, which, as Dana puts it, "is a morbid condition of the nervous system of which the underlying characteristics are weakness and excessive irritability," is mentioned here because it is a frequent accompaniment of inability to use the eyes. It is the underlying cause of asthenopia in many cases, and, although it may be joined to the other causes of asthenopia, is quite capable of originating painful vision.

Neurasthenia, frequently referred to as "the American ailment," seldom develops before the age of sixteen years or after the age of fifty years. It is most common between the ages of eighteen and thirty. It affects males and females with almost equal frequency.

One of the symptoms of neurasthenia is an inability to close the eyes completely when standing with the legs close together, accompanied by fibrillary twitchings of the orbicularis palpebrarum muscle (Rosenbach's phenomenon). Kneis[1] states that the "voluntary motor innervation is enfeebled, the sympathetic reflexes are increased. The former corresponds to the weakness, the latter to the irritability."

The so-called "*morning ptosis*" of Gowers is regarded by some as a symptom of neurasthenia and may occur in hysteria. In reality it is much more frequently a consequence of eye strain due to the want of proper glasses and disappears when such want is supplied. The symptom occurs most frequently in elderly, nervous individuals, and consists in an inability to open the eyes during the night or in the morning on waking. There is no secretion, but the eyelids seem to stick to the eyeball and cannot be parted except with difficulty. Patients state that the "lids appear to be dried to the eyeball." There is a sense of lack of lubrication. After the upper lid has been raised by the fingers the function of the levator palpebræ superioris returns. A number of such cases have occurred in the practice of the writer in patients whose nervous force has depreciated as a result of senility. If the term neurasthenia can be applied to these individuals it is applicable only in a limited sense. The symptoms can in no way be considered as an hysterical manifestation.

The symptoms referable to the eyes in neurasthenic asthenopia are much the same as those common to asthenopia from other causes, except that the psychical manifestations predominate. Double vision, dizziness,

[1] Relation of Diseases of the Eye to General Diseases, Noyes, 1895, p. 232.

nausea, nervous dyspepsia, phantom images, hemianopsia, transient blindness, persistent after-images, variable heterophoria, deficient power of the external muscles of the eye, twitching eyelids are not uncommon. When glasses are worn the reflexes from surfaces and edges of the glasses or from parts of the frames are very disturbing. The "fatigue field" of vision develops in neurasthenia more readily than in any other condition and is the result of "nerve exhaustion." The retina shows no change on examination with the ophthalmoscope.

Types of Fatigue Fields.—Certain types of fatigue fields are recognized.

1. *Concentric Contraction.*—This consists in a general contraction of the visual field similar to that seen in hysteria, except that in neurasthenia it constantly changes, while in hysteria it remains fairly constant in size and form until recovery takes place. As a rule, the field of vision for form grows smaller and smaller as the examination proceeds. If the examination commences at one meridian and is carried around the circle the extent of the field when the meridian of starting is reached will be found to have diminished. The form of field developed by testing the various meridians in rotation describes an irregular spiral and has been termed the *exhaustion spiral* (Fig. 264) (von Reuss).

Fig. 264

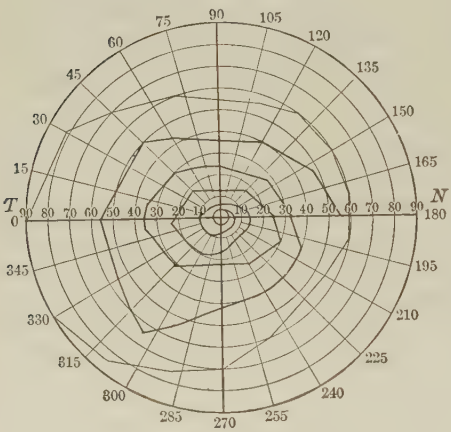

Fatigue spiral field. (Von Reuss.)

2. *Unsymmetrical Concentric Contraction.*—Shifting or displacement type (Fig. 265). To obtain this field the patient is placed at the perimeter and the test object is advanced into the field of vision from the temporal side and continued through to the nasal side where it leaves the visual field. This is done in all meridians. It has been found that the extent of the field is greater to the side of the entrance of the test object and less at the side of exit, as the latter is more fatigued. After the eyes have had time to recover the test is repeated, passing the test object from the nasal side. It will now be seen that the field is greater on the nasal side from the same cause. Wilbrand arrives at the same conclusions more rapidly by making continuous measurements along the horizontal meridian, passing alternately from temporal to nasal and from nasal to temporal sides at about the same velocity. One may determine the variation of the field and also determine whether the fatigue may reach such a degree that the field is entirely lost. The portion of the field that resists has been termed by Wilbrand the "minimal visual field." It is held by some observers that the fatigue fields for color maintain a constant relation to the fatigue fields for white, but this view is opposed by others.

3. *Oscillating Visual Field.*—A type of fatigue field in which the test object, if carried throughout the extent of a meridian of the field, appears, disappears, and appears again, has been described by Wilbrand and called by him the "oscillating visual field." The field behaves the same for colors as for white (Fig. 266).

Fatigue phenomena in the form of central scotomata of the visual fields more frequently manifest for small colored objects than for white have been described.

Fig. 265

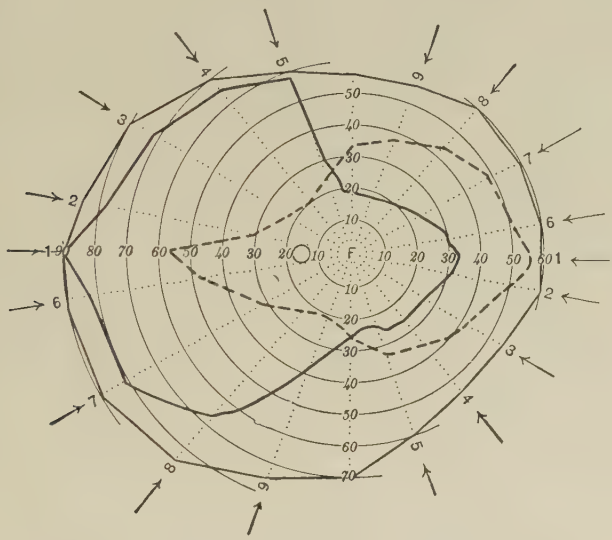

Förster's shifting or displacement type of the visual field. (Wilbrand.)

4. *Mixed Form of Visual Field.*—It is held by von Reuss that all fixed forms of contracted visual field not due to pathological changes are hysterical and that all variable forms are neurasthenic. It has been found that fixed (hysterical) contracted fields may show fatigue and change in form. Such fields are known as mixed forms, and show a condition of neurasthenia mixed with hysteria.

Diagnostic Value of Fatigue Fields.—It cannot be said that fatigue fields are diagnostic of neurasthenia, since they occur in those who are not neurasthenic, in epilepsy, in Basedow's disease, in trifacial neuralgia, in heart disease, in chlorosis, in alcoholism, etc. Nevertheless, the determination of fatigue fields affords information that is of much value in leading to an accurate diagnosis. For an able exposition of this subject, see the article of de Schweinitz.[1]

Treatment.—While it is very probable that ocular defects (eye strain) may be one of the causes of neurasthenia, there can be little doubt that there are other equally as potent causes.

[1] Posey and Spiller, p. 672.

In the treatment of these cases all errors of refraction and of the ocular muscles should be corrected and explicit directions regarding the use of the eyes, the wearing of tinted glasses, and the general hygiene of the eyes should be given.

Often relief in such cases comes only by correction of the disordered nervous system. The further treatment devolves upon the neurologist, to whom cases of this nature should be sent.

Fig. 266

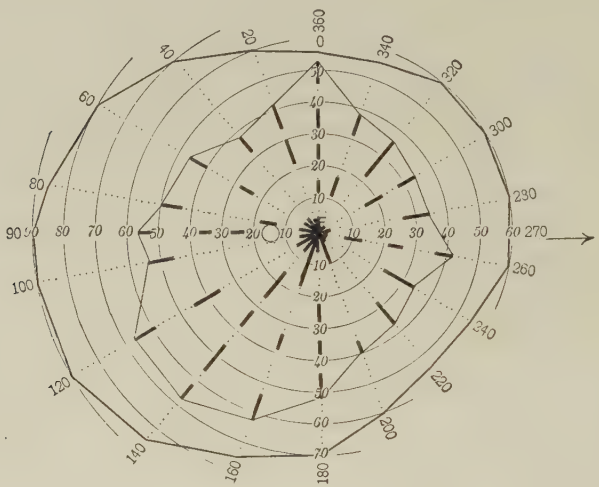

Left field. Oscillating field. (Wilbrand.)

Retinal Asthenopia.—This is really a condition of hyperesthesia of the retina. It is a condition in which a prominent symptom is that of dazzling and pain, due more to the excitation of the retinal elements by bright light than to the use of the eyes when the light is modified. Use of the eyes for reading or for regarding distant objects is painful, but much more so when the light is strong. This condition is met with more frequently in students at about the age of puberty than in any other class or at any other age. On examining the retina it will be found to be hyperemic, and there may be a slight edema of the tissue of the disk and of the adjacent retina. The condition disappears slowly under proper treatment, complete recovery taking place.

Treatment.—Glasses of light neutral or amber tint, which correct the error of refraction, should be worn. All close work with the eyes should be abandoned. The patient should take a proper amount of exercise, and live out-of-doors. The diet should be plain and nutritious, and proper medication for correcting any error of the system that may exist should be employed.

Tarsal Asthenopia.—The weight of the upper eyelids, increased by thickening of the tissue of the lids from whatever cause, produces symptoms of asthenopia in some patients. The cause of the distress is the

slight change in the curvature of the cornea and a consequent change in the refraction which the weight of the lid induces. Relief follows return of the lid to its normal condition and the final adjustment of suitable glasses.

Reflex Asthenopia.—This form of asthenopia is commonly due to an inflamed condition of the nasal mucous membrane, but is also observed in ethmoiditis, frontal-sinus disease, and dental caries. In acute coryza, in ulcerative processes affecting the nasal mucous membrane, and in pustular affections of the nasal mucous membrane, attempts to use the eyes are frequently accompanied by photophobia, increased lachrymation, smarting of the eyelids, and headache. These symptoms are accompanied by a diminution of the range of accommodation in some cases. It is wise in all cases of asthenopia to examine the nasal mucous membrane and to have all possible cause of irritation from this source removed.

Facial Expression Due to Eye Strain.—In many individuals the attempt to overcome the effect of errors of refraction or to compensate for muscular imbalance produces certain facial expressions, deformities, or positions of the head. These are brought about often without the consciousness of the individual and are frequently regarded as indications of traits of character. Thus, the myope and the individual with astigmatic axes at or near the horizontal meridian endeavor by narrowing the palpebral fissure to increase their distance vision. The astigmic with oblique axes develops wrinkles ("crow's feet") at the outer angle of the eyes. Hyperopes and those with muscle imbalance develop wrinkles in the forehead, either vertical or horizontal. Eye strain may cause a convulsive contraction of the orbicularis palpebrarum and some associated facial muscles on one or the other side of the face (tic), and in cases of diplopia, as in paralysis of the abducens or motor oculi nerve on one side, the diverging eye is usually shut off by tonic contraction of the orbicularis palpebrarum muscle. The development of wrinkles in the forehead and upper part of the face, regarded by many as evidence of senility, can often be obviated to a great degree by preventing eye strain, namely, by the wearing of proper glasses.

Head-tilting.—The habit of tilting the head to one side or the other is a very common one. It occurs in the private practice of the writer in about 25 per cent. of the patients who consult him for errors of refraction or of the extrinsic ocular muscles. Gould[1] has drawn attention to the fact that astigmia may cause head-tilting when the axis of the astigmia in both eyes inclines from the vertical or horizontal, a few degrees "in the dominant eye alone, in the same direction for both eyes." The object of this tilting of the head is to render the axes vertical or nearly so in the interest of better vision. Head-tilting has other causes, one of which is hyperphoria. The head in these cases tilts toward the side of the lower visual plane. In one case observed by the writer, a male, aged forty-one years, the refraction was R. $+ 1.0 \bigcirc + 0.50$ axis 60°, V $= \frac{20}{20}$; L. $+ 1.25 \bigcirc + 0.50$ axis 113°, V $= \frac{20}{20}$. Left hyperphoria

[1] American Medicine, 1904.

7°; head tilts to the right 7 to 8 degrees. Adjustment of proper prism corrects the tilting of the head. The prisms have now been worn nine years; the head remains straight. A number of recorded cases in the histories of private patients confirm the results in this case. A mixture of the two conditions may occur. Whatever the influence of astigmia with slightly oblique axes and hyperphoria may have in producing head-tilting, there are other causes to which the greater number of the cases are due, in which the eyes are not a factor.

HYSTERICAL OCULAR DISTURBANCES.

Forms.—The disturbances of vision which may be due to hysteria are (1) amaurosis, (2) amblyopia, (3) monocular diplopia, (4) contraction of the visual fields, (5) reversal of color fields. Other disturbances of the eyes are (1) anesthesia of lids, conjunctiva, and cornea, (2) hippus, (3) conjugate deviation of the eyes, (4) ptosis, (5) clonic blepharospasm. The manifestations of hysteria occur between the ages of six and thirty. Females are affected more commonly than males in the proportion of 4 to 1.

Amaurosis.—Hysterical amaurosis (blindness) may be monocular or binocular; more frequently it is the former. It is met with most frequently between the ages of twelve and twenty-five years. The individual appears to be completely blind in the affected eye. The pupils are slightly larger than normal, as a rule. If but one eye is affected, there may be a slight difference in the size of the pupils, that of the affected eye being larger. The fundus is normal. In the greater number of the cases it is possible to prove, by means of the tests to detect simulated blindness, that the amaurotic eye really sees.

Amblyopia.—Diminution in the acuity of vision may affect one or both eyes and may be moderate ($\frac{20}{40}$ to $\frac{20}{70}$), or it may amount to almost complete blindness. In nearly all cases it is accompanied by contraction of the visual fields.

Monocular Diplopia.—Monocular diplopia is sometimes observed. Knies, referring to Charcot and Parinaud, is of the opinion that it is due to irregular contraction of the ciliary muscle. In some astigmic subjects monocular diplopia occurs without any trace of hysteria.

Other Disturbances of Eyes.—Anesthesia of lids and conjunctiva is usually unilateral and accompanied by amblyopia or contraction of the visual field on that side. It persists for a varying length of time. Hippus need not be associated with any other ocular manifestation. It is more marked if the patient is under excitement. Conjugate deviation of the eyes occurs in the crises of hystero-epilepsy, but is rare at other times. The eye may deviate to either side. Paresis of the abducens or spasm of convergence has been reported. Ptosis, which Knies is inclined to believe is due to spasm of the orbicularis, has been seen by many observers. It may be clonic or tonic. Clonic blepharospasm is not uncommon.

Symptoms.—Contraction of Visual Fields.—This is fairly characteristic of hysteria. The contraction is always concentric. It may reduce the field one-third or one-half, but, as a rule, the field is very small—not more

Fig. 267

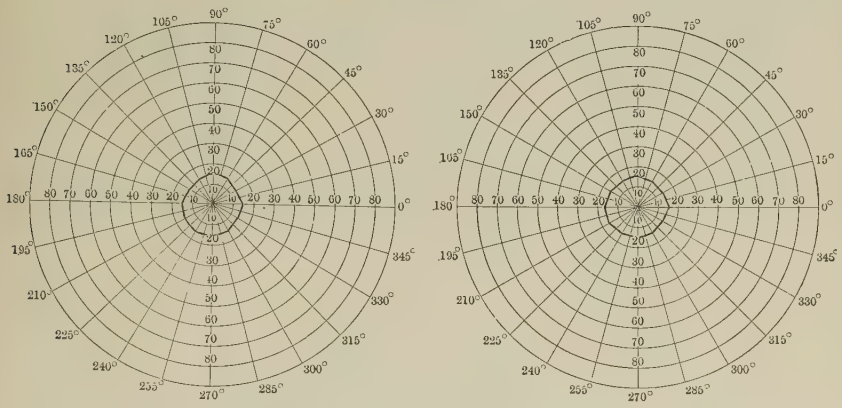

Marked contraction of both visual fields in hysteria. (Gilles de la Tourette.)

than five degrees about the line of fixation (*the telescopic field*). Slight variations in the size of the field may be noted when examined at different times, but it does not present the conditions of the typical "fatigue" field and should not be confounded with it, although neurasthenia and hysteria may exist coincidently when the visual field may show the peculiarities of both conditions. In some cases the field of vision remains the same size when tested at any distance from the eye (*tubular field*).

Fig. 268

Left

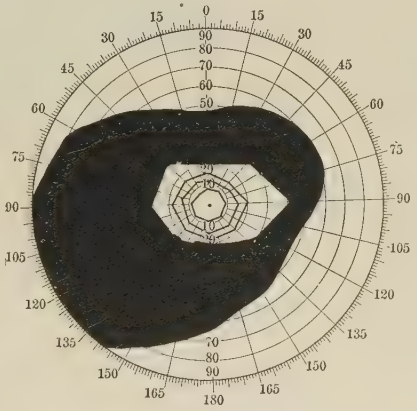

Field of vision from a case of hysterical amblyopia. Marked concentric contraction, with complete reversal of the red and blue fields. From without inward the fields are for white, red, blue, and green.

The color field for red in some cases closely corresponds with that for white. It may exceed the field for blue, and green may disappear. At times the field for red may exceed that for white. This has been termed *inversion of the color field.* Entire absence of color sense (achromatopsia) or a perversion of color sense (dischromatopsia) have been observed. Central scotoma is a rare manifestation of hysteria. Hemianopsia does occur, but is rare. In all the visual disturbances the fundus oculi is normal, and the reaction of the iris to the ordinary stimuli is normal, with the exceptions noted above. The visual disturbances are, as a

rule, accompanied by other manifestations of hysteria hemianesthesia, complete, segmental, or disseminated, affecting not only skin, but also mucous membrane; the buccal and faucial mucous membranes, and the side of the tongue to the median line, corresponding to the side of the amblyopic eye may be anesthetic. Hysterical deafness on the same side may be present. Patches of hyperesthesia (hysterogenic zones) may be present. They are situated along the spine, over the epigastrium, in the lower abdominal region. Globus hystericus and other symptoms, photopsia, macropsia, and micropsia hystericus, are occasionally observed.

Duration.—This varies greatly. The visual disturbance may last but a very short time or it may persist for years. The writer has seen a case of hysterical contraction of the visual fields in a young man, of eight to ten years' duration. The anomalies of vision appear suddenly and usually disappear suddenly.

Diagnosis.—This is arrived at (*a*) by exclusion; there is no evidence of disease of the eyes; the pupils react almost if not quite normally. (*b*) By determining the fact that the individual sees with the affected eye or eyes. Often the use of any glass, plane, or weak sphere will enable the patient to see. Tests with the stereoscope will demonstrate binocular vision in some cases. The tests for simulation are useful. The hysteric subject with contracted fields has no difficulty in orientation—moves about alone without running against objects, which is impossible for those whose peripheral field of vision is gone. (*c*) By finding other stigmata of hysteria, such as hysterogenic zones, hemianesthesia, globus, etc.

PLATE XXIII

Dislocation of Lens beneath the Conjunctiva.

CHAPTER XXI.

DISEASES OF THE CRYSTALLINE LENS.

Position.—In almost all cases the position of the axis of the lens coincides with the visual line.[1] A rotation on its vertical axis of 3 degrees to 7 degrees has been observed, and more rarely, a rotation on its horizontal axis. This, of course, has more or less influence on the refraction of the eye.

Congenital Dislocation of Lens (*Ectopia Lentis*).—In some cases of imperfect development of the eye, it occurs that the remains of the hyaloid artery and its branches by traction on the lens prevent it from remaining in its proper place as the eye develops, the lens being found in the vitreous chamber. In these cases there is usually coloboma of the chorioid, ciliary body, and iris, and the eye is microphthalmic. In the greater number of cases congenital dislocation of the lens is due[2] to a defect in the suspensory ligament. Knapp observed this condition five times in 50,000 patients with eye affections. The defect occurs in the vicinity of the retinal fissure permitting of a displacement upward and inward, upward, or upward and outward, rarely downward. It is often associated with coloboma of the chorioid and iris, rarely aniridia, and sometimes with coloboma of the ciliary body. The degree of the dislocation varies considerably; from one- to two-thirds of the pupillary area may be occupied by the lens.

Fig. 269

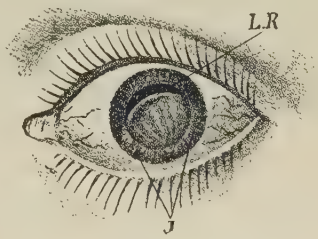

Dislocation of lens. (Michel.)

Mobility.—In the greater number of cases the lens is stationary, but in some the zonula is so relaxed that it is possible to cause dislocation of the lens into the anterior chamber. The lens is often smaller than the normal, and may present irregularities in shape (*coloboma lentis*) with opacification of the portion of the lens contiguous to the defect. The entire lens may be cataractous. About 20 per cent. show more or less opacification.[3]

Etiology.—The direct cause, namely, deficient suspensory ligament, has been mentioned. It has been shown that heredity strongly influences the production of the condition. Parker, who gives a résumé of the

[1] Tscherning, Union méd., 1888, No. 57.
[2] First described by Sichel, Oppenheim's Zeitschr. f. d. g. Medizin, 1846.
[3] D'Oench, Inaug. Dissert., Strassburg, 1879.

literature,[1] mentions five examples in three generations which came under his observation.

Symptoms and Diagnosis.—If the lens occupies the entire pupillary area the symptoms are those of myopic astigmia. There is often a slight bulging forward of the iris in the upper half (corresponding to the location of the intact portion of the zonula) and recession in the lower part with tremulous iris. On dilating the pupil and examining the eye by transmitted light, a black, curved, narrow zone which marks the visible portion of the margin of the lens will be seen. This zone, which is sharply marked at its outer border and shades rather rapidly into the illuminated area at the inner margin, is due to the deflection of light reflected from the interior of the eye. Viewed by oblique illumination, a curved light zone, with neither border sharply marked, may be seen, due to direct reflection of light from the posterior surface of the lens at its border. If the lens occupies but part of the pupil the patient may be greatly annoyed by diplopia, the image through the lens differing in form and distinctness from that through the aphakic part of the pupillary area. On examining the eye with the ophthalmoscope, using the indirect method, two images of the fundus will be obtained, one through the lens and one through the aphakic space.

Fig. 270

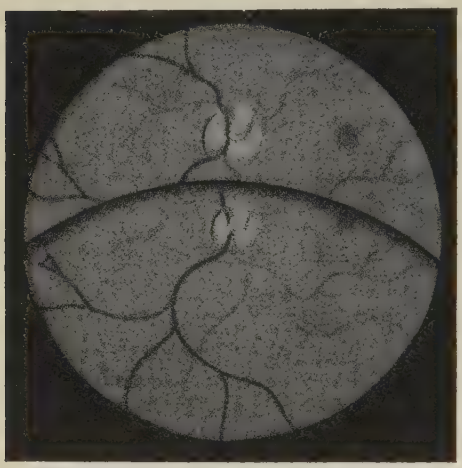

Eye ground in downward subluxature of the lens. (Axenfeld.)

Results.—Subsequent spontaneous complete dislocation of the lens has been observed in a few cases. Glaucoma has been observed apparently as a result of the malposition of the lens.[2]

Treatment.—If vision sufficient for the ordinary vocations of life can be obtained by the adjustment of glasses, nothing further is required. When diplopia is very annoying and when vision is greatly reduced (below $\frac{20}{40}$) removal of the lens (preferably early in life and by discission) should be resorted to.

Absence of Lens.—This condition is extremely rare. The writer has observed it once in a microphthalmic eye. It is only possible as a result of an arrest of development.

Microphakia.—Lenses that are smaller than the normal are met with in microphthalmic eyes, also rarely in eyes of normal size. The condi-

[1] Trans. Section on Ophth., A. M. A., 1898, p. 99.
[2] D'Oench, Arch. f. Ophth., x, p. 89.

tion is due to an arrest of development, either before or after birth. Evidences of changes in the vascular coat of the eye are usually present. The writer has observed this condition in a case of congenital syphilis. It was bilateral. In addition to microphakia there were small opacities scattered throughout the lenses. On dilating the pupil in these cases, the border of the lens can be seen throughout its entire extent. Such eyes are usually myopic.

Coloboma of Lens.—This defect is present usually as a flattening of a portion of the margin (seldom a notching) of the lens. It may be unilateral, or bilateral. The portion of the border affected is, as a rule, downward and slightly inward, corresponding to the site of the retinal fissure. Christian[1] mentions a case in which the coloboma was upward and outward. A large proportion of the cases are associated with coloboma of the iris or of the chorioid, or both, rarely with coloboma of the ciliary body. Only a small portion of the volume of the lens is absent, but more or less distortion of the lens is occasioned, the refraction usually being myopic and astigmic. This condition may be associated with ectopia lentis. Not infrequently the lens is cataractous in the vicinity of the coloboma, and fine opacities may sometimes be present throughout the body of the lens. Zonular cataract has also been observed.

Boas[2] describes an interesting case of kidney-shaped lens, the defect directed inward.

There may be two notches in the lens (Meyer).

Etiology.—The cause of coloboma of the lens is not fully understood. A number of theories have been advanced. Heyl and Hess are of the opinion that the defect is due to an anomalous condition of the fetal vascular capsule of the lens, but they are not in accord as to the precise manner in which the lens is influenced by this anomaly.

Lenticonus.—This condition of the lens is of rare occurrence. In 1891 the writer could find but four cases reported. Since then a number have been recorded. It consists in a conical protrusion of the lens, either at the anterior (*anterior lenticonus*) or at the posterior (*posterior lenticonus*) pole of the lens, having a circular base measuring from two to four millimeters in diameter.

Etiology.—The cause of *anterior lenticonus* is not known. It is probable that in some cases the lens capsule at its anterior pole remains attached to the cornea to a late period, and that undue traction is exerted in its separation in the development of the anterior chamber. In the case of Veunemann[3] there was an inherent weakness of the capsule at its anterior pole which permitted of the development of a curve at the age of puberty.

In the light of recent observation and research it is obvious that posterior lenticonus is due to traction on the capsule at its posterior pole, either with or without rupture, by the remains of the hyaloid artery and its branches.

With the exception of the case of Pergens,[4] no microscopic examina-

[1] Arch. of Augenheilk., xxix, p. 233.
[2] Klinisch. Monatsbl. f. Augenheilk., 1893, S. 297.
[3] Ann. d'oculistique, v, p. 158.
[4] Arch. f. Augenheilk., xxxv, 1, S. 1.

tion of a *human* lens with lenticonus has been made. The investigations of Becker,[1] Hess,[2] Baeck[3] on the eyes of pigs and rabbits show that the capsule at the posterior pole is complete in some, deficient at the apex in others, reduced in thickness in all cases. Bach[4] reports three cases in the eyes of rabbits in which he found a connective-tissue band, which represented the thickened sheath of the hyaloid artery. A displacement of the nucleus of the lens backward to the capsule of the lens, causing a posterior bulging apparently due to a small rupture of the capsule at the posterior pole, was seen by Hess in the eye of a pig, producing lenticonus posterior. It is possible that this condition obtains in man in some cases of lenticonus posterior.

Symptoms.—*Lenticonus Anterior.*—This occurs more rarely than lenticonus posterior. In the cases so far recorded (two) the affection was binocular. In Webster's[5] case, the first reported, the patient was a male, twenty-four years of age. Illumination with the ophthalmoscopic mirror gave the appearance of keratoconus. "At a distance of twelve inches two images of retinal vessels could be seen, one in the centre of the pupillary reflex and one at the periphery. On movement of the observer's head from side to side the images were seen to move in opposite directions. Examination by oblique illumination revealed a conical protrusion of the centre of the anterior part of each lens into the anterior chamber. The whole surface of the posterior capsule was dotted over with minute opacities, and there was a small posterior polar cataract. The vision in either eye was $\frac{15}{100}$ increased to $\frac{20}{100}$ with glasses."

Fig. 271

Lenticonus anterior. (Webster.)

Lenticonus Posterior.—This is always monocular. Strabismus, either convergent[6] or divergent,[7] may exist, the affected eye being the squinting eye. On looking into the eye with the ophthalmoscope, using the mirror only, a bright circular patch is seen, located between the iris and the fundus in the antero-posterior axis of the globe. About the margins of this disk light and dark crescentic figures play on changes in the direction of the light. When viewing the interior at about twelve inches from the eye, images of the vessels are seen through the periphery and through the centre of the lens.

In some of the cases of lenticonus, opacities in the lens have been observed. In many of the cases of posterior lenticonus, opacities on the capsule, representing remains of the fetal blood-vessels, are present.

The vision of eyes with lenticonus is always poor. The refraction at the apex of the lens is greater than at the periphery in the direction of myopia by 10 D. and upward, depending on the height of the cone.

[1] Anat. d. g. u. kranken Lens, S. 125.
[2] Arch. f. Ophth., xiii, 3, S. 234.
[3] Arch. f. Aug., xxxvi, 2, p. 160.
[4] Arch. f. Ophth., xiv, 1, S. 59, 60.
[5] Arch. of Ophth., 1875.
[6] Weeks, Arch. of Ophth., 1891, vol. xx, No. 2.
[7] Meyer, Centralblt. f. p. Augenheilk., Band xii, p. 41.

Cataract.—The term *cataract* is applied to opacities of the lens or its capsule. Opacities affecting the lens substance are known as *lenticular cataract*; those affecting the capsule, *capsular cataract*, and those affecting both lens and capsule, *capsulo-lenticular cataract.*

Cataract occurring in youth is spoken of as *juvenile cataract;* occurring in the aged, as *senile cataract.*

Cataract is said to be (1) *primary*, when occurring without other gross changes in the eye or disease of the general system; (2) *secondary*, when the result of disease in other portions of the eye; (3) *symptomatic*, when due to a general malady; (4) *traumatic*, the result of injury.

In regard to their consistence, cataracts are classified as *hard, soft* or *fluid.* In regard to color, as *gray, amber, black, yellow*, etc.

Classification.—A convenient classification is the following:

- Lenticular
  - Hard
  - Soft
  - Fluid
    - Gray
    - Amber
    - Black
    - Yellow
      - Juvenile (congenital)
        - Lamellar (zonular).
        - Diffuse.
        - Total.
        - Axial.
        - Complicated.
        - Anterior polar.
        - Posterior polar.
        - Cortical
          - anterior
          - posterior
      - Senile (acquired)
        - Nuclear
        - Morgagnian.
        - Anterior polar.
        - Posterior polar.
        - Complicated.

- Capsular juvenile
  - Anterior.
  - Posterior.
- Capsular after the removal of lenticular cataract (after-cataract).
- Capsulo-lenticular
  - Anterior polar (pyramidal).
  - Axial.
- Traumatic
  - Partial.
  - Complete.
- Symptomatic
  - Diabetic.
  - Nephritic.

Lamellar (Zonular) Cataract.—This is a form of cataract which develops just before or shortly after birth. It consists in opacification, more or less complete, of two or more contiguous lamellæ of lens fibers, enclosing a clear or partly opaque nuclear portion of lens substance, the cataractous zone being nearer or farther from the centre of the lens, according as the process which determined the development of the cataract occurred very early or relatively late in the life of the infant. Sometimes two or more *cataractous zones* are present in the same lens. Zonular cataract is binocular in almost all cases, but may be monocular, Wintersteiner[1] reports such a case. The degree of opacification varies from that in which the opaque zone at its equator can just be distinguished, the transparency of the axial portion being slightly affected, to a density through which no red reflex from the fundus can be seen.

Etiology.—Interference with the nutrition of the lens at an early period of life is accountable for the condition. The opaque lamellæ

[1] Klinisch, Monatsbl. f. Augenheilk., xxxi, p. 300.

are apparently the lamellæ that occupied the periphery of the lens at the time of the grave general disturbance of the nutrition.

Shrinkage of the nucleus is considered to be the first change, producing cleavage of the peripheral lamellæ, also small clefts and cavities in the nucleus itself (Peters).

Heredity is a potent factor in the development of this form of cataract. Derby[1] reports eight cases in members of one family. Fromeget[2] observed the inheritance of lamellar cataract through six generations; there was no consanguinity; cataract occurred in the females only. Malformed "terraced" teeth are often found in individuals with zonular

Fig. 272



Scheme of opacification in cataract formation. (Axenfeld.)

cataracts, thought to be evidence of rickets, which is recognized as a cause. Max von Air[3] collected 189 cases; in 66.07 per cent. the patients possessed rachitic teeth. Schliep[4] reported 178 cases of zonular cataract; 59 per cent. showed undoubted signs of rickets. A history of convulsions may be elicited in many cases.

Pathology.—The lamellæ in the affected zone are separated by small clefts which are filled with an emulsion, composed of fluid and granular material obtained from the lens fibers. The nucleus of the lens appears to be slightly shrunken and often presents minute clefts containing clear fluid with sometimes a few granules. The lens fibers in the peripheral parts of the lens appear to be normal.

Appearance.—By oblique illumination with the pupil dilated a more or less dense, grayish reflex will be obtained from the central portion of the lens, which is limited by a well-defined border situated between the centre and the equator of the lens. The grayish reflex is most pronounced at the equator of the opaque zone. A clearer portion of the lens is included between the partly opaque lamellæ. The red reflex from the fundus will be less pronounced throughout the affected area, the interference being greatest at the border of the cataractous area, except in cases in which the nucleus of the lens is more or less opaque, which rarely occurs. In some cases the border of the opaque lamellæ is not regular, fine opaque

[1] Trans. Amer. Ophth. Soc., 1891.
[2] Ann. d'oculistique, cx, 200.
[3] Zur Path. d. Schicht-Staars, 1883.
[4] Inaug. Dissert., Tübingen, 1902.

spiculæ ("*outriders*") extending into the transparent zone at the periphery of the lens.

Course.—All lamellar cataracts tend to become more dense with age. Calcareous deposits may develop in the nucleus of the lens. The entire lens may become cataractous. This is most apt to occur in the cases which possess "outriders." The changes that take place advance extremely slowly—so slowly that zonular cataract is said by some authors to be stationary.

Fig. 273

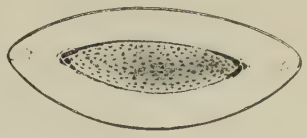

Lamellar cataract. (After Axenfeld.)

Treatment.—If vision is reduced to $\frac{20}{40}$ it is better to remove the lens. This is more satisfactory, if done early in life, by discission and absorption, than if done later in life when extraction must be resorted to. Iridectomy is only a temporary expedient.

Diffuse (Punctate) Cataract.—In this form, small, irregular opacities are present throughout the lens, frequently not in sufficient number to greatly interfere with vision.

Total or Complete Cataract.—Complete congenital cataract is sometimes met with. It occurs in both eyes, as a rule. The cataract is white in color and is ordinarily soft in consistence. It may contain small deposits of lime salts and cholesterin crystals, and may be considerably shrunken and hard.

Anterior Capsular Cataract.—This form is sometimes occasioned by partial retention of the congenital pupillary membrane (see Iris, p. 322), with attachment to the capsule of the lens. In many of these cases there is merely a small area of connective tissue on the lens capsule at the site of the attachment; in some cases the area is large and dense enough to materially interfere with vision, and in some cases the lens substance immediately beneath the attachment is opaque; this opacity does not tend to increase. *Treatment* is not indicated.

Anterior Polar Capsular Cataract (Pyramidal).—This form of cataract appears as a small, circular, white eminence at the anterior pole of the lens; it seldom exceeds 2 mm. in diameter at its base, and may measure not more than $\frac{1}{2}$ mm. in diameter. It projects slightly into the anterior chamber in the form of a cone, and because of the projection has been termed pyramidal. Anterior polar cataract is frequently associated with partial opacification of the lens, which is situated immediately beneath the opacity in the capsule.

Etiology.—Following loss of aqueous and abolition of the anterior chamber, due in almost all cases to a perforating ulceration of the cornea, the pupillary portion of the lens capsule comes in contact with the posterior surface of the cornea, and with the secretion from the ulcer becomes more or less adherent to the cornea. Local softening of the capsule (Müller) may occur. The reformation of aqueous causes more or less traction on the capsule, disturbing its normal relation to the lens fibers at this point. Disturbance of the lining cells and destruction of lens fibers in the adjacient lamellæ take place with possible detachment of

the capsule over a small area, and infiltration of fluid. Hyperplasia of the cells follows.

Pathology.—In recent cases (six to ten weeks' formation) the proliferating tissue is rich in nuclei and rests directly on the underlying lens

Fig. 274

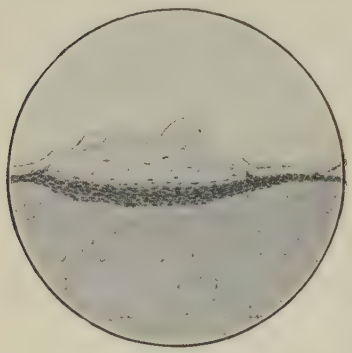

Fig. 275

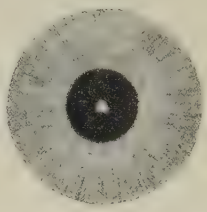

Fig. 276



Anterior polar cataract. (Axenfeld.)

fibers. Older cases (one to two years) present a mass of large homogeneous fibers or lamellæ irregularly disposed, with few nuclei; between the white mass and the lens substance proper a layer of epithelial cells

Fig. 277

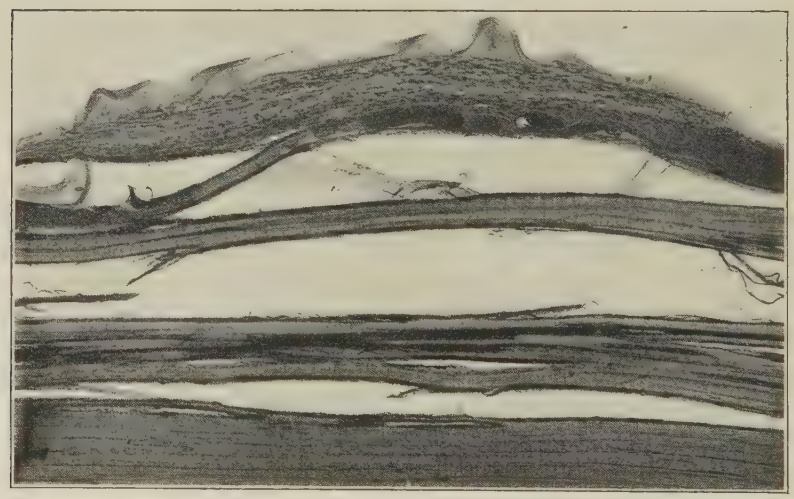

Anterior polar cataract.

continuous with the epithelial cells of the unaffected capsule, evidently a proliferation from the normal capsule cells, is found. In still older cases the nuclei have almost entirely disappeared from the opaque mass

and between it and the layer of epithelial cells just described is a layer of basement membrane exactly like the capsule of the lens and continuous with it. The appearance is as though a split in the capsule had occurred, and the opaque mass constituting the cataract had formed in the cleft. The newly formed basement layer is undoubtedly a product of the epithelial cells. Calcareous deposits are found in old pyramidal cataracts.

A deposition of clear lens fibers subsequent to the development of pyramidal cataract may cover an opacity of the lens, occasioned by death of superficial lamellæ at the site of the cataract, and cause the opacity to occupy a position deeper in the lens substance.

Symptoms.—In very many cases inspection of the cornea will reveal opacities which mark the site of former ulceration, but not in all. The writer observed double anterior polar cataract in an infant of three weeks in which the corneæ were absolutely clear. Nuel[1] observed two cases in which there was corneal ulcer without perforation. He assumes that irritating substances pass from the cornea into the anterior chamber and excite proliferation of the capsular epithelium. Mules[2] examined an eye with pyramidal cataract that was removed with staphyloma; threads of lymph, three in number, extended from the pyramidal structure, two being attached to the cornea and one to the iris. Mules thinks that traction on the capsule produced the cone.

In six cases observed by Collins,[3] corneal ulceration had been present in all.

Anterior polar cataract is stationary.

Treatment.—Not indicated unless the opacity is so large that it obstructs the pupillary space, in which case iridectomy for visual purposes may be performed.

Posterior Polar Capsular Cataract.—In the development of the eye it sometimes happens that the hyaloid artery and its branches do not entirely disappear. A mass of connective tissue, usually circular, remains at the posterior pole of the lens and constitutes posterior polar capsular cataract. Various degrees of persistence of the hyaloid artery and its branches have been observed.[4] The opacity on the posterior capsule may show radiating striæ and a number of independent deposits may be present. This form of cataract is stationary.

Diagnosis.—This form of cataract may be confounded with the posterior polar (lenticular) cataract which accompanies retinitis pigmentosa, congenital axial cataract, and some forms of traumatic cataract. Its chief distinguishing feature is the bright, smooth, reflecting surface which it presents when viewed by reflected light. Further, the presence of fine radiating branches and of prolongations into the vitreous aids in making the diagnosis. One lens only may be affected.

Vision is seldom seriously impaired.

Treatment.—This is not indicated.

[1] Arch. d'opht., xix, 1, p. 6.
[2] Trans. Ophth. Soc. United Kingdom, xiii, p. 70.
[3] Trans. Ophth. Soc. United Kingdom, xii, p. 89.
[4] See Stryker, "The Crystalline Lens System," p. 144.

Axial Lenticular Cataract.—It occurs at times that an axial opacity of the lens is present as a congenital defect. The opacity may be most marked in the anterior, central, or posterior portion of the axis of the lens or may extend fairly evenly throughout the entire length of the axis. It presents a white appearance. If at all progressive it is only very slightly so.

Treatment.—This is not indicated except in cases in which vision is seriously interfered with, in which case iridectomy for visual purposes may be performed.

Complicated Cataract.—This occurs as a juvenile or congenital cataract, but it is much more frequently met with in adults, and is described on page 584.

Acquired Cataract, Primary, Senile, or Simple Cataract.—This form begins either in the periphery of the lens, *cortical cataract*, or in the centre of the lens, *nuclear cataract*.

Cortical Cataract.—This begins, as a rule, near the equator of the lens, in the lamellæ slightly removed from the capsule, the lower, inner portion of the cortex first becoming opaque in the greater number of cases. Opacities gradually appear in other parts of the periphery, opaque radiations, striæ, or sectors extending toward the poles of the lens. In some cases the opacification affects the posterior lamellæ of the lens almost to the exclusion of other parts (*posterior cortical cataract*, *chorioidal cataract*); sometimes the anterior portion of the cortex alone is affected (*anterior cortical cataract*). Posterior cortical cataract is apt to develop extremely slowly, many years elapsing before the cataract becomes mature.

Nuclear Cataract.—The opacity, usually diffuse, begins at the centre of the lens, and gradually extends toward the periphery.

Stages of Development.—The development of simple senile cataract presents four stages clinically.

1. *Stage of Incipiency.*—This begins with the earliest evidence of cataract and may be said to continue until vision is considerably impaired. It may last a few months only; it may last many years.

2. *Stage of Immaturity* (*Cataracta Immatura Maturescens*, *Stage of Intumescence*, Fuchs).—In this stage vision is much impaired, but much of the lens substance is still transparent; the condition most favorable for extraction has not been reached. Many cataracts, particularly those that begin as cortical cataracts, are swollen during this stage from imbibition of aqueous, the anterior chamber shallow. In many cataracts which are nuclear in origin, increase in the volume of the lens from imbibition does not occur. When intumescence occurs, the second stage lasts from a few months to a few years; in other cases this stage may be greatly prolonged.

3. *Stage of Maturity.*—In this stage the lens substance is completely opaque, except perhaps in some cases of nuclear senile cataract in which maturity may have been reached before the entire lens substance is opaque. The swelling of the lens has subsided and diminution in the size of the lens is progressing; the vision in this stage is reduced to perception

of light or the ability to count fingers at a few feet from the eye. The duration of this stage is from six months to a number of years.

4. *Stage of Hypermaturity.*—In this stage the lens substance undergoes degenerative changes. It may liquefy (formation of liquor Morgagni); deposits of cholesterin crystals in the liquor Morgagni or of lime salts in the lens substance may take place. The lens substance may become greatly shrunken and assume the shape of a thin disk (disciform cataract); the capsule sometimes becomes thickened by proliferation of the lining epithelial cells and deposits of lime salts may be found in this hyperplastic tissue.

Etiology.—All cataracts develop because of a change in the nutrition of the lens; the quantity is not sufficient, or the channels through which it should pass are closed, or the quality is not favorable for the maintenance of transparency.

Senile cataract is in all probability preceded by changes in the blood-vessels in the ciliary processes or in the secreting cells of these processes which bring about the change in the nutrient fluid. Heredity is a strong predisposing cause, the cataract usually occurring earlier in life when inherited predisposition is marked. Berry[1] observed a family of fifty-five members, running through five generations, in which cataract occurred in thirteen, eight males and five females. Many reports of cases are on record to this effect.

Pathology.—Defects and pathological changes in the capsular epithelium are seldom, if ever, absent. In all senile cataracts the nucleus of the lens becomes more or less shrunken and condensed by loss of water and diminution of the nutrient fluids. Minute clefts may appear between the fibers in the nucleus which fill with granular detritus derived from the lens fibers, consituting nuclear senile cataract, or large clefts may appear between the lamellæ near the periphery of the lens, constituting cortical cataract. These clefts occur near the equator of the lens in the incipient stage; they become filled with fluid in which granules and myelin globules are found; degeneration of the lens fibers contributes to the mixture, which constitutes the opaque white emulsion termed the *liquor Morgagni.* The degeneration goes on, involving all of the cortical portion of the lens, and, while this is progressing, the cortical fibers become swollen by imbibition of liquid, which undoubtedly passes through the capsule, and the period of intumescence is entered upon. The lens substance becomes separated from the capsule by a thin layer of liquor Morgagni at about the time that the swelling of the lens fibers begins to subside, and the lens is in condition to be removed—is mature. The development of liquor Morgagni at the expense of the lens fibers (principally of the cortical fibers) may continue, the nucleus remaining or entirely disappearing (Morgagnian cataract).

Fig. 278



Incipient cortical cataract. (Axenfeld.)

[1] Ophth. Rev., 1899, vol, xii.

Symptoms.—Simple senile cataract develops without pain, the subjective symptoms being those of disturbed vision only. In quite a large percentage of the cases of nuclear cataract the centre of the lens becomes quite hard (sclerosed) previous to the opacification, the refraction is increased and a condition of lenticular myopia develops. The refraction of the axis of the lens may be so much greater than that of its periphery that the image formed by rays of light passing through the nucleus may be distinct from that formed by the rays of light passing through the periphery of the lens, a bifocal lens being developed. Usually the patient first notices a diminution of vision. This may be preceded by photophobia or a sensation of dazzling from diffraction or dispersion of rays of light that impinge on the opaque parts of the lens. Monocular diplopia may result from a division of the lens by opaque striæ; distortion of images also occurs. In cases in which the axial portion of the lens remains relatively transparent the vision may be best when the illumination is intense, the consequent contraction of the pupil shutting off the opaque portion. In cataract beginning at the nucleus the vision is better by diminished illumination, as at twilight, the dilatation of the pupil permitting the light to enter the eye around the opaque portion of the lens. The acuity of vision gradually decreases until the patient is only able to distinguish light from dark (V = perception of light). This condition seldom changes until the cataract is removed. Spontaneous absorption has occurred in a few cases.

Course.—The cataract now gradually passes into the hypermature stage, in which it may present a number of conditions:

1. It may become completely absorbed (*a*) without rupture of the lens capsule. Kipp[1] reports the case of a man, aged fifty-five years, who had a cataract successfully removed from the left eye. There was a nearly mature cataract in the right eye. Eleven years later the patient reported that he could see better with the unoperated eye with the cataract glass than he could with the operated eye. On examining the unoperated eye, it was found that the lens was entirely absent, that the capsule was transparent and apparently intact, and that there was no disease of the fundus; the field of vision was normal in extent and vision with correction equalled $\frac{18}{30}$. Mitralski[2] reported 20 cases, in some of which complete, in some partial, absorption had taken place with restoration of useful vision. In some of the cases there was no history of disease or of injury to the eye preceding the disappearance of the cataract, nor does it appear that liquor Morgagni was present in any large amount. A number of cases have been reported in which the spontaneous disappearance of cataract has been preceded by disease. Baquis[3] reports the case of a man aged thirty-eight years, with cataract of twenty years' standing. During an attack of episcleritis, lasting forty days, the cataract became absorbed.[4] (*b*) With spontaneous rupture of the capsule. Many of the reported cases coming under this heading are complicated with intra-ocular disease or

[1] Amer. Jour. Ophth., 1887, iv, p. 157.
[2] Centralbl. f. prakt. Augenheilk., xvi, 289.
[3] Ann. di ottalm., xxxvi, 1-2, p. 76.
[4] For further report of cases, see Pyle, Phila. Med. Jour., March 17, 1900.

have a history of traumatism. Marlow[1] reports a case of hypermature cataract in a patient, aged eighty years, in which rupture of the zonula and capsule occurred. Vision of $\frac{6}{36}$ was obtained. In many of these cases rupture of the capsule is followed by symptoms of glaucoma induced by the escape of swollen lens fibers from the capsule. Pain and tenderness may be present for some weeks. Eventually absorption of the lens substance in whole or in part occurs and some degree of vision is obtained.

2. It may become partly absorbed, the cortical portion disappearing and the nucleus sinking below the pupillary margin. This result is most apt to occur in Morgagnian cataract, absorption of the liquor Morgagni taking place.

3. The cataract may be partly or wholly converted into liquor Morgagni.

4. The cataract may show but little change aside from a slight loss in volume.

5. The cataract may become greatly shrunken, forming a thin opaque disk.

6. Spontaneous dislocation of the cataractous lens may take place. The dislocation may be partial or complete. The author observed a patient forty-seven years of age, who had cataract of three years' standing in both eyes, with spontaneous subluxation of both lenses. There was no history of injury; the zonula was defective above in both eyes. There was evidence of peripheral chorioiditis of a mild character. The lenses did not sink below the pupillary area. Complete dislocation occurs. Desgranges reports a case of sudden spontaneous dislocation of a cataractous lens with immediate restoration of vision in a man, aged fifty-six years, and Sichel a case in a myope in whom the dislocation was gradual, extending over a period of five years, at the end of which time vision was restored.[2] It sometimes occurs that spontaneous dislocation of cataract leads to secondary glaucoma necessitating removal of the globe.

Black Cataract (*Cataracta Nigra*).—The term is at present applied to two forms of cataract. In the first form the sclerosing process includes all of the lens substance. The lens has a dark amber color, is somewhat reduced in size and is usually sufficiently clear to admit of vision for form at a distance of one to four feet. It is not necessarily connected with disease of any part of the eye. In the *second form* the lens is of a dark chocolate color. Gillet de Grandmont[3] reports a spectroscopic examination of a black cataract in which he found that the pigmentation was due to an infiltration of altered blood-coloring matter. The lens was sclerosed and contained many hemin crystals which were scattered throughout the entire lens. The author has removed two lenses of this nature, in one of which the color was deepest in the nucleus and in a broad zone separated from the nucleus by a zone of lighter pigmented lens tissue.

The latter variety of black cataract owes its dark color to the presence

[1] N. Y. Med. Jour., January 14, 1899. [2] Quoted by Pyle, Phila. Med. Jour., March 17, 1900.
[3] Arch. d'opht., xiii, 5, 273.

of blood pigment, and is always indicative of deep-seated lesions of the eye. In the cases observed by the writer there were chorioidal changes, most extensive near the periphery.

Moauro, referred to by Norris[1] "has examined ten black cataracts and believes that the coloring matter is always derived from the blood. In his cases it consisted either of hematin, hematoidin, or melanin."

Diagnosis.—The diagnosis of black cataract is sometimes difficult on simple inspection, as the pupil is black. Oblique examination will disclose a deep amber or chocolate color. Viewed by transmitted light, the red reflex is wanting. The vision is greatly reduced; the third image, Purkinje's figure, is absent.

Prognosis.—This must be guarded in the second form, as the vision after extraction is often poor.

Consecutive Cataract.—This term applies to all forms of cataract that are due to disease of the eye, or to disease of other parts of the body. Consecutive cataract may be subdivided into (*a*) complicated or secondary, those due to disease of the eye, and symptomatic; (*b*) those due to disease of the system or to certain diatheses.

Secondary or Complicated Cataract.—Cataract may be due to violent inflammation of the anterior parts of the eye, as suppuration of the cornea, particularly infected ulcer, gummatous iritis, iridocyclitis with posterior synechiæ (cataracta acreta), inflammation of the entire vascular tunic (uveitis), plastic chorioiditis, metastatic chorioiditis, retinitis proliferans, retinitis pigmentosa, hemorrhagic retinitis, detachment of the retina, absolute glaucoma, intra-ocular tumor, cysticercus, etc. In complicated cataract the color is frequently different from that of the uncomplicated form. It may be very white, due to hyperplasia of the lining capsular cells and deposits of lime salts; yellow, because of plastic or suppurative process in the interior of the eye, or very dark in color from the absorption of blood pigment.

Diagnosis.—This is made by the appearance, position, size, and color of the cataract and the presence of adhesions; also by the appearance of the tissues of the globe, size of globe, tension, and the condition of the eye regarding vision.

Some of the forms of secondary cataract present peculiarities in development that should be noted. The cataract which is complicated with a subacute anterior chorioiditis in which the ciliary body is involved to some extent (a slow process which leads to obliteration of many of the small vessels) develops very slowly, the posterior cortex of the lens becoming first involved. Typical posterior cortical cataract should always awaken a suspicion of disease of the anterior portion of the chorioid. Cataract due to chorioidal disease may be monocular.

The cataract which develops as an accompaniment of *retinitis pigmentosa* is of the lenticular, posterior polar variety. The atrophy of the retina and chorioid characteristic of this disease appears to affect the nutrition of the lens at its posterior pole most profoundly. A diffuse

[1] System of Diseases of the Eye, Norris and Oliver, vol. iv, p. 316.

opacity of the posterior pole of the lens, at first very minute, develops. This extends along the axis of the lens and concentrically into the peripheral portions, proceeding very slowly until eventually the entire lens is involved. A posterior polar lenticular cataract may extend to and develop rapidly from the nucleus, soon affecting the entire lens.

Fig. 279



Incipient nuclear cataract. (Axenfeld.)

Fig. 280



Crescentric shadow from margin of iris in incipient cataract. (Axenfeld.)

Prognosis.—Always less favorable than in simple uncomplicated cataract.

Symptomatic Cataract.—Certain chronic diseases of the system which are unaccompanied by marked increase in temperature, and, also, the convalescent stage of some acute, systemic diseases are prone to cause the development of cataract; to the first belong diabetes, chronic nephritis, arteriosclerosis, hook-worm disease, pellagra; to the second, typhoid fever, etc.

Diabetic Cataract.—The frequency of cataract in diabetic patients is variously estimated. Taconneau-Dufresne found cataract in 0.6 per cent. of the patients with diabetes; J. Meyer in 3 per cent.; Seegin in 4 per cent.[1] Of patients with cataract, Hirschberg found 4 per cent. with sugar in the urine. This corresponds with the experience of the writer.

Etiology.—While sugar has been found in the lens, vitreous body,[2] and aqueous, Knies[3] states that it has been detected in only two-thirds of the cases. The clear as well as the opaque lens may contain sugar in diabetes (Leber), "and cataract in one eye may contain sugar while the other does not" (Becker). It is possible that excess of sugar in the lens may in rare cases, by influencing osmosis, produce cataract; but in the majority of cases the cause of the cataract is undoubtedly an altered condition of the blood, lymph, and aqueous of a toxic nature which leads to degeneration of the blood-vessels of the uveal tract, particularly of those of the ciliary processes, with consequent impairment of the nutrition of the lens. Degeneration of the capsular epithelium, followed by opacification of the lens, develops. Evidence of vascular changes in the eye due to diabetes is noted in the hemorrhagic retinitis, iritis, cyclitis, and chorioiditis, which often accompany the disease.

The urine should be examined in all cases of cataract, but if sugar is

[1] Stricker, "The Crystalline Lens System," p. 219.
[2] Kamocki, Arch. of Ophth., xvii, p. 247.
[3] The Eye in General Diseases.

found it is not conclusive that the cataract is due to the diabetes. Individuals with cataract may develop diabetes.

Pathology.—In the development of this form of cataract in young individuals the imbibition of water is excessive. The formation of the globules of Morgagni and the disintegration of lens fibers are apparently more rapid than is the case in cataract due to other causes. It is very probable that defects in the capsular epithelium may be among the first pathological changes.

Symptoms.—Cataract in diabetes may be said to be characteristic when it occurs in the young, and then only when it develops rapidly and there is abundant sugar in the urine. Seegin[1] reports one patient, aged twelve years; Frey[2] a case in a girl of nine years, one year after the beginning of the diabetes. In diabetic cataract in young individuals the cortical portion of the lens, close beneath the capsule, assumes a bluish-white appearance, both lenses being similarly affected. The nuclear portion of the lens is not at first greatly involved, but gradually takes on the same change, resulting in a uniform bluish-white mass, the process being complete in a few months. In individuals from twenty-five to thirty-five years of age the "asbestos" stripes occur early in the development of the cataract and complete opacification is rapidly attained; the lens becomes markedly swollen. In older individuals the development of cataract in diabetics cannot be differentiated from the ordinary senile forms.

Prognosis.—The healing after extraction of diabetic cataract is a little less favorable than in non-diabetic individuals. On account of the changes that take place in the walls of the blood-vessels in some diabetics, hemorrhage from the vascular tunic or from the retina must be expected to occur somewhat more frequently than in the non-diabetic, and iritis may develop in a higher percentage of the cases. In the extraction of a number of diabetic cataracts the writer has had nothing but uneventful recoveries, so far as the healing of the wound was concerned, but in one case death from diabetic coma occurred ten days after the extraction.

Such a possibility should be considered, and the fact brought to the notice of the relatives before the operation is performed. Before operaing for cataract in a diabetic patient, the amount of sugar should be reduced as far as possible by a judicious diet and by medication. If acetone, diacetic or oxybutyric acid are present these should be eliminated before operation is attempted, as diabetic coma is apt to develop in such cases. The spontaneous partial clearing up of the opacity of the lens in diabetic patients has been reported,[3] but this termination is extremely rare.

Albuminuric Cataract.—Albumin appears in the urine in quite a high percentage of individuals with cataract. Rothziegel[4] found small quantities of albumin in 26.5 of the 102 patients with cataract which he examined and large quantities in 2 per cent. Ewitzky,[5] with a view of

[1] Der Diabetes Mellitus, Leipzig, 1870.
[2] Lond. Med. Rec., May, 1887.
[3] Nettleship, Trans. Ophth. Soc. United Kingdom, vol. v, p. 107.
[4] Allg. Wiener med. Ztg., 1886, No. 30.
[5] Wjest. Ophth., No. 2, 1887.

determining the influence of albuminuria in the production of cataract, examined the urine of 200 patients with cataract and found albumin in 19 per cent. He then examined the eyes of 90 patients suffering from nephritis. Of those less than fifty years of age (67 patients), he found one with unilateral posterior polar cataract (evidently not due to nephritis). Of the patients above fifty years of age, six had cataract. Ewitzky then examined 586 inmates of an asylum whose ages were between fifty and ninety years, and found opacities of the lens in 45 per cent. He also examined the urine and found albumin in approximately 10.5 per cent. Ewitzky concludes that albuminuria does not play an important part in the production of cataract. It appears that the change in the kidneys that determines albuminuria and the change in the eye that produces cataract are part of a general degenerative change affecting the blood-vessels of the system at large—arteriosclerosis.

Cataract as a Result of Sea-sickness.—In rare cases cataract develops as a result of severe sea-sickness; the writer observed a case in a female, aged thirty-four years. The patient was at sea two weeks, and was ill during the entire time. On boarding the steamer at Hamburg the vision was excellent; when she reached New York vision was greatly reduced. Examination of the eyes disclosed almost complete opacity with swelling of both lenses (soft cataract). The lenses were extracted and good vision obtained.

Cataract Accompanying Skin Disease.—Cataract as an accompaniment of certain forms of skin disease has been observed. Rothmund, quoted by Knies, reports having observed seven children who were affected with a peculiar disease of the skin which he describes as a fatty degeneration of the stratum Malpighii and of the papillæ with secondary atrophy. Of the seven children thus affected, five had cataract; the skin became affected during the third to sixth month of life; the cataracts appeared at the age of three to six years.

Cataract occurring in syphilitic patients is always secondary to changes in the globe itself.

Cataract as a Result of Systemic Poisoning (*Toxic Cataract*).—**Cataract from Ergotism** (*Raphanic Cataract*).—A number of observers have reported the frequent occurrence of cataract during or shortly following epidemics of ergot poisoning. Kortner[1] observed 500 cases of poisoning; 37 of these patients, ranging from six to fifty-four years of age, had cataract. The opacity of the lens began in the nucleus and spread to the periphery. The cataracts that occurred in young individuals matured in from two to three months; in adults, from eight to twelve months. Extraction was not attended with complications. In spasmodic and in gangrenous ergotism there are violent spasms and cramps, with subsequent contracture which affects non-striated muscular tissue especially. During the spasms the fundus of the eye becomes pallid. In the interval it may be hyperemic. Many writers attribute the formation of cataract to interference with the nutrition due to spasm of

[1] Wjest. Ophth., 1892, No. 3.

intra-ocular blood-vessels. Cataract of this form is almost unknown in the United States.

Naphthaline Cataract.—The ingestion of naphthaline (a product of the distillation of coal tar), as pointed out by Bouchard[1] and later by Dor,[2] may produce cataract. Dor gave naphthaline to rabbits and observed the first traces of cataract on the fifth day, preceded by retinal exudation. If the naphthaline was discontinued as soon as the retinal exudation appeared, the cataract did not develop.

Lezinius[3] reports the case of a pharmacist, aged thirty-six years, who took 5 grams of unpurified naphthaline in 200 grams of castor oil. Disturbances of vision were noticed within thirteen hours. Some hours later vision was greatly reduced, retina pale and cloudy, vessel walls and temporal half of disk pale. Visual fields contracted. One year later there was zonular cataract, with vision reduced to counting fingers at one meter. According to Bouchard, Dor, Lezpinius, and others, the development of naphthaline cataract is preceded by changes in ciliary and retinal blood-vessels. Hess[4] does not find these changes constant, but does find degeneration of the capsular epithelial cells of the lens. Naphthaline does not produce cataract when injected subcutaneously.

Occupation Cataract.—Glassblowers who are exposed to intense heat and light, develop cataract more often and at an earlier age than do those who are not so exposed. Meyhofer[5] examined 506 glassblowers, and found opacities of the lens in 59, 42 of whom were less than forty years of age. The left eye was nearer the furnace and suffered more often. A posterior stellate opacity, which is quite characterstic, develops; the opacity shows little tendency to advance; the workman may possess the cataract for a long period of time without being aware of it, as the interference with vision is often slight. This form of cataract begins at the posterior pole of the eye at the site of the posterior nodal point. Robinson[6] is of the opinion that the cataract begins at this point because the principal rays of the various cones of rays cross here and subject this part of the lens to the greatest amount of heat and light. The contraction of the pupil shields the periphery of the lens. Robinson states that the disease can be prevented if the workmen will wear blue glasses.

Traumatic Cataract.—Without Laceration of the Capsule and without a Perforating Wound of the Eyeball.—Blows on the eye from any blunt object result in a small proportion of the cases in the production of opacity of the crystalline lens. The opacity may be partial and become stationary, or it may progress and become complete. It is not necessary that the blow should fall on the eyeball directly. A blow on the orbit or side of the head may be followed by opacity of the lens. A patient at the age of twenty-five years was thrown from a carriage, striking on the right side of the head. Some months later the vision of the right eye became slightly impaired. Examination disclosed the presence of minute opaque

[1] Receuil d'opht., 1887, p. 91.
[2] Rev. générale, 1887, No. 1.
[3] Klin. Monatsbl. f. Augenheilk., xi, p. 129.
[4] Graefe-Saemisch, 2 aufl., Band vi, ix Kap.
[5] Zeh. Klin. Monatsbl., February, 1886, p. 49.
[6] Brit. Med. Jour., January 24, 1903.

spiculæ at the periphery of the lens, extending from the equator toward either pole. The axis of the lens remained free. Fifteen years later the opaque striæ had not materially changed, but they were covered by a number of lamellæ of transparent lens fibers, and resembled zonular cataract with very little opacification. *Stellate cataracts* evidently the result of traumatism are sometimes seen. Such a case came under the author's observation in which the clear-cut, leaf-like opacity had remained unchanged for more than forty years. Fuchs[1] reports the clearing up of four traumatic cataracts. They were stellate and leaf-like in shape, and were evidently due to turbid fluid between the fibers or lamellæ, as, after clearing, no loss of substance could be demonstrated, which would have been the case if degeneration of lens substance had occurred.

After Laceration of Lens Capsule.—This may occur either with or without perforation of the fibrous coat of the globe, puncture, incised, or lacerating wounds. After a punctured or incised wound, if the opening is very small, even if the lens substance is involved, the opening in the capsule may close and the resulting opacity may be very slight and be confined to the margins of the wound canal. The lens substance may become cloudy for some distance adjacent to the wound, and the cloudiness may clear up except at the margins of the wound. A minute foreign body may pass entirely through the lens, causing only very slight opacification along the track of passage. Opacification of the wounded lens may advance to a certain degree short of complete opacification, and then become stationary, so remaining throughout life. As a rule, penetrating wounds of the lens result in complete opacification, the cataract thus formed being of a grayish-white color, and belonging to the class "soft" cataracts. The lens substance in all traumatic cataracts from whatever cause becomes swollen from imbibition of water. In cases of laceration of the capsule, the swollen lens substance may escape from the wound, cause increase of tension (secondary glaucoma), and require immediate removal.

Absorption of the lens substance after rupture of the anterior portion of the capsule progresses rapidly in the young, much less rapidly in adults. Absorption of lens substance after rupture of the posterior capsule takes place very slowly. The vitreous humor possesses little absorbent power.

Inflammatory Cataract.—Cataract which forms during the course of an iritis, cyclitis, chorioiditis, or which accompanies intra-ocular neoplasm, not infrequently presents a swollen appearance, a thickened capsule and a multiplication of epithelial cells. The epithelial cells form in masses on the posterior surface of the anterior capsule, produce cystoid cells masses at or near the equator of the lens, and sometimes, more or less completely cover the anterior surface of the posterior half of the capsule. This form of cataract is sometimes spoken of as inflammatory. To designate these cataracts as inflammatory is plainly a misnomer, since their development is due to perverted nutrition only. In traumatic

[1] Wiener klin. Woch., 1888, Nos. 3 and 4.

cataract, with infection of the lens substance, a multiplication of germs takes place in the lens substance accompanied by an infiltration of small cells and a disintegration of lens fibers; this form may be termed inflammatory cataract. In no other condition will we find a true phakitis.

Morgagnian Cataract (*Cataract Lactea, Cataracta Fluida*).—Develops primarily as a cortical cataract, the stage of tumescence being marked. There is an unusual amount of fluid within the capsule; the cortical lens fibers break down, forming a granular detritus and the globular bodies known as myelin globules (H. Müller), or the globules of Morgagni. The cortical fibers also undergo some degree of fatty degeneration. The fluid, with its mixture of granular detritus, Morgagnian and fat globules, is white in color, about the consistency of thin cream, and is pasty. As the quantity of fluid increases, calcareous granules and crystals of cholesterin may appear in it. If the cataract develops in a young adult, or in one in whom the centre of the lens has not become sclerosed, entire liquefaction of the lens substance may take place. In the greater number of cases a nuclear mass of lens substance remains unchanged, the size of the nuclear mass depending on the degree of the sclerosis of the nuclear portion. In elderly individuals four-fifths of the nuclear portion of the lens may remain comparatively unaffected by the cataractous process. What is left of the nuclear portion of the lens gravitates to the lowest portion of the capsule.

If the head is thrown backward the lens presents a uniform grayish-white appearance, a few small areas of more intense white being present if calcareous granules have been deposited in the tissues adherent to the capsule. If the head is tipped forward and so held for a few minutes the sclerosed nucleus will gravitate forward and become visible. The equatorial capsular cells become vesicular, greatly enlarged, and break down.

Capsular Cataract.—True capsular cataract is the form of cataract due to hyperplasia of the epithelial cells lining the anterior portion of the capsule. Anterior polar or pyramidal cataract (see page 577) is of this variety. Hyperplastic changes in the capsule occur not infrequently in hypermature senile cataract. The hyperplasia is most frequently confined to an area corresponding in some degree to the area of the pupil. Its margins may be irregularly serrated. The patches of hyperplastic cells may occupy any part of the anterior portion of the capsule. They may extend over the posterior portion of the capsule. Capsular cataract, although usually preceded by opacification of the lens substance, may form before the lens proper has become opaque. In some cases, as in anterior polar cataract, the lens may remain clear indefinitely.

Secondary Capsular Cataract.—This term can properly be applied to the *after-cataract* that forms subsequent to cataract extraction. The density of this structure and its shape depend on a number of factors.

1. All of the lens substance may have been expelled from the capsule of the lens, leaving the entire capsule (with perhaps a lacerated opening through the anterior portion), the anterior and posterior portions lying in apposition.

2. A large part of the anterior portion of the capsule may be absent.
3. More or less lens substance may remain within the capsule.
4. Inflammatory processes may occasion the deposition of new-formed tissue on the capsule or hyperplasia of the lining epithelial cells may occur, or both processes may be combined.

The importance of the secondary capsular cataract lies in its effect on vision by obstructing the pupillary area.

In cases where the lens substance has been expelled the capsule may be transparent in the pupillary area and remain so; this is more liable to happen if the anterior portion of the capsule is wanting. In both cases the transparency may be abolished either by the hyperplasia of the lining endothelial cells, the formation of pseudomembrane or wrinkling of the capsule. Wrinkling of perfectly transparent capsule may reduce vision to a very considerable degree.

Fig. 281

Secondary capsular cataract. (Morax.)

Where the lens substance remains, that more exposed to the aqueous humor becomes absorbed; that included between layers of capsule, as at the equator (crystalline pearl or wurst of Sommering), may remain many years. In a number of cases the operation or injury that has resulted in the removal of the lens substance causes considerable irritation of the eye, and a plastic exudation is thrown out from the vessels of the iris and ciliary body. This exudation results in the formation of a thin or thick layer of lymph or pseudomembrane on the capsule of the lens. If a cyclitis is present a membrane may be found posterior to the capsule. The *capsule proper* does not undergo any change in thickness. When the term "thickened capsule" is employed, it should not convey the idea that the homogeneous basement membrane—the capsule proper—is thickened, but that accretions of various kinds have taken place.

Diagnosis.—When opacities of the cornea do not exist and the pupil is clear the diagnosis of cataract is relatively easy, if one bears in mind the fact that the term has reference to opacities of the lens and lens capsule only. This definition makes it at once apparent that the opacity must lie back of the plane of the iris, except in rare cases, in which the lens is dislocated into the anterior chamber.

Incipient and Partial Cataract.—The pupil should be well dilated. If the lens is partly transparent, so that a red reflex may be obtained through part of it, by transmitted light, the opacities that it may contain appear black against a red field—the reflex from the fundus. Cortical cataract frequently begins by a few opaque striæ in the inner lower quadrant of the lens, and if the pupil is not very widely dilated, it may escape detection unless the patient is directed to look downward and inward, when the striations will come into view. In cases in which the opacity of the lens is small and situated in the middle or posterior portion of the lens, it may be difficult to determine whether it is in the lens or

in the vitreous. However, if the relation of the opacity to the corneal reflex (see page 146) is studied, the exact location of the opacity can be readily determined. The examination by transmitted light should not be terminated without having employed a strong plus glass (+ 20 D.) for minute inspection of the cataractous lens. When the opacity in the lens is so dense that a red reflex from the fundus cannot be obtained, provided the fundus is normal, the incipient stage has passed.

Oblique Illumination.—When viewed by oblique illumination (see page 117) the opaque parts of the lens ordinarily present a gray or grayish-white appearance. There are a few exceptions. The nuclear senile cataract associated with more or less sclerosis of the lens presents a grayish periphery, but the nucleus is amber-hued within a grayish haze. In "black cataract" the lens has a deep amber or a dark chocolate color, depending upon the variety of black cataract. In complicated cataract the color may be yellow, chalky white, or some departure from the gray. In the examination of incipient cataract the opaque portion is seen through more or less clear tissue.

When the cataract has reached the "immature" stage, if the opacity is a nuclear one, examination with the oblique illumination will present a crescentic shadow (penumbra) at the margin of the pupil toward the source of illumination (see Fig. 280). This is due to the fact that the opaque nucleus which reflects the light is separated from the capsule of the lens, on which the free margin of the pupil rests, by a layer of clear lens substance of greater or less thickness; the width of the shadow depends on the thickness of this layer, provided the angle of the incident rays of light remains the same. The term "immature" does not always apply to cataractous lenses that present this phenomenon (see page 280). In many cortical cataracts this appearance will not be obtained because the opacification affects the cortical lamellæ lying very near the capsule. The cortex may be opaque and the nucleus transparent. If the stage of tumescence has passed and the lens cortex is opaque the cataract may be said to be mature. The characteristics of mature and hypermature cataract have been sufficiently described (see p. 580) to render their diagnosis easy.

Treatment.—The treatment of cataract may be divided into *medicinal* and *surgical.*

Medicinal.—It may safely be stated that the complete clearing up of opacities that have already formed in the lens by medicinal means (except perhaps in some rare cases of traumatic and toxic cataract) is not obtained. Spontaneous absorption of cataractous lenses occurs, but this process has not the slightest relation to medicinal treatment, and cannot be prognosticated in any given case.

Medicinal treatment may be applied in symptomatic, toxic, secondary and progressive cataract for the purpose of preventing, arresting, or retarding development.

Symptomatic Cataract.—In diabetic cataract the cataractous process may be favorably influenced in a few cases and an arrest of development, partial or complete, may be obtained by diet and treatment that will

decrease the amount of sugar excreted and bring about improvement of the general health. Existing opacities have been known to disappear in a few cases (see page 586).

Toxic Cataract.—In toxic cataract the treatment is obvious. Discontinue the ingestion of the toxic agent and have the diet as nutritious and supporting as possible.

Secondary Cataract.—The treatment must be directed against the condition which has led to or may lead to cataract. In syphilitic affection of the sclera, vascular coat or retina, the treatment, local and systemic, should be pushed vigorously. In retinitis proliferans and in retinitis pigmentosa, small and long-continued doses of the iodide of sodium or of potassium and of mercury, combined with a generous, wholesome diet, may retard and in some cases apparently arrest the development of cataract.

Progressive Cataract.—Improvement in the general condition by the use of suitable tonics and improved diet and the correction of any diathesis that may be present will do much to retard the development of senile cataract. A collyrium that will cause transient hyperemia of the anterior ciliary vessels put into the eyes sufficiently frequently, the application of moist heat to the eye and lids by bathing the eyes for fifteen or twenty minutes, twice or three times daily, with hot normal saline solution or boric acid solution, will assist in producing the desired increase in the circulation in the anterior segment of the globe and apparently exert a favorable influence in many cases.

"It is generally known that changes in the refraction of the lens frequently occur during the development of cataract and that the adjustment of glasses in the earlier stages may improve the vision. In a case recently observed, myopia of 3 D. developed. In all cases where vision can be improved, glasses should be given not with the expectation of producing any effect on the development of the cataract, but for the improvement of vision.

"In cases of nuclear, zonular, polar, or axial cataract, either in youth or in age, if the tension of the globe is normal and vision is improved thereby, a weak solution of atropine, sufficiently strong to produce a moderate dilatation of the pupil, may be employed often enough to maintain maximum vision.

"Miotics are seldom required, but in certain rare cases in which the axis of the lens is comparatively transparent and the apices of the opaque sectors, from the equator of the lens, enter the normal pupillary area and disturb vision, and in those cases where the development of cataract is accompanied by increase in tension, as when the lens is swollen, a miotic may be employed. Pilocarpine is usually sufficient, but eserine may be required in some cases."

Massage.—From the knowledge afforded by a study of the various methods of ripening cataract the influence of traumatism on the lens and the results of massage as applied by others, the author is of the opinion that this method is not of much value in the prevention of cataract.

Electricity.—Electricity, in various forms, has been and is being employed by ophthalmologists for the purpose of stimulating the circu-

lation of the eye to cause arrest of development of cataract. The author has no personal experience with this method.

SURGICAL.—See chapter on Operations.

Spontaneous Dislocation of the Lens.—Spontaneous dislocation of the lens is seldom complete; as a rule, a portion of the suspensory ligament only ruptures and the lens tilts backward or forward out of position. Spontaneous dislocation occurs most frequently in buphthalmos and highly myopic eyes, eyes in which there have been distention of the fibrous coat and a consequent stretching of the suspensory ligament. It also occurs in eyes in which the vitreous body shrinks because of the presence of inflammatory or fibrous exudation, the lens being carried backward with the recession of the fovea patellaris. Unless the nutrition of the lens is interfered with, it remains transparent after spontaneous dislocation.

Treatment.—If the lens becomes opaque, or occasions distressing symptoms by pressure on the ciliary processes or iris, it may be removed; otherwise treatment is not indicated.

Injuries to and Affecting the Crystalline Lens.—**Dislocation of Lens.**—Dislocation of the lens may be caused by contused wounds or blows upon the head without rupture of the eyeball. The dislocation may be partial or complete. In many cases the lens will be tilted backward into the vitreous and will lie in the lower anterior portion of the vitreous chamber, being held by part of the suspensory ligament at its lower border. The lens may be totally dislocated, may occupy any part of the vitreous,[1] or may pass into the anterior chamber (Fig. 282).

FIG. 282

Dislocation of the lens into the anterior chamber.

After incised wounds in the cornea or anterior segment of the sclera, as in iridectomy for glaucoma, the lens may be dislocated into the wound by pressure of the vitreous body. In operating for cataract pressure made by the patient may dislocate and extrude the lens as soon as the section is complete. Rupture of the sclera near the cornea may cause dislocation of the lens and its extrusion through the wound beneath the conjunctiva.

Diagnosis.—Dislocation of the lens is accompanied by increase in the depth of the anterior chamber if the dislocation is backward and the lens

[1] The writer has seen a dislocated lens lying next to the optic disk that had been driven entirely through the vitreous body. The fibrous coat had not been ruptured.

does not press on the iris. If a portion of the iris is pressed upon the depth of the anterior chamber will not be uniform. If the lens is dislocated into the anterior chamber the iris will be pressed backward and will not be tremulous. If the lens is opaque the diagnosis is relatively easy, but if the lens is transparent the diagnosis may be difficult. If a free border of the lens can be seen the portion tangential to the observer will be indicated by a dark band by transillumination, due to diffraction of the rays of light that impinge upon it. The border will appear as an annular shadow. This holds good whether the dislocation is in front or behind the iris (Fig. 270).

Treatment.—As a rule, lenses that are dislocated into the anterior chamber should be removed. Those in the posterior chamber should be removed if they produce pain or inflammatory disturbances.

Foreign Bodies.—Foreign bodies of various kinds may become embedded in the lens. They are usually visible, but may be hidden by cataractous lens substance, when their location may be determined either by skiagraphy or by transillumination. As a rule, foreign bodies are well tolerated by the lens substance, but traumatic cataract usually develops, making it desirable to remove the lens. The foreign body may come away with the lens substance or it may be removed independently. This is particularly feasible if the foreign body is magnetic, in which case the magnet is employed.

Ossification of Lens.—Ossification of the lens occurs rarely.[1]

Parasites in Lens.—Entozoa have been found in the lens as a cause of cataract in rare cases. Round- and flat-worms described as Filaria oculi humani, Monostoma lentis, Distoma oculi humani (Nordmann, Gescheidt, von Ammon[2]), and cysticercus have been found in the crystalline lens (Graefe).

Regeneration of Lens.—This has never been observed in man, but apparently does occur in some animals. Randolph observed it in newts.

[1] Dunn and Holden, Arch. of Ophth., xxvii, No. 5.
[2] Zeitschrift f. d. Ophthal., Dresden, 1833, iii, pp. 75 and 405.

CHAPTER XXII.

THE VITREOUS.

ANOMALIES OF THE VITREOUS.

Coloboma.—This is a rare condition. It is characterized by a cleft in the lower inner aspect of the vitreous body, extending from the optic nerve entrance to the lens in extreme cases. The cleft is produced by the presence of connective-tissue bands, usually bearing blood-vessels, which occupy the position of the fetal retinal fissure. In one case (Hess[1]) the coloboma was produced by a fold of retina.

Persistent Hyaloid Artery.—In 1856 H. Müller described a shred of connective tissue which he met with quite constantly as a projection into the vitreous body from the optic disk in the eye of the ox. In calves the shred of connective tissue often bore a blood-vessel and extended forward to the lens. This Müller described as a remnant of the hyaloid artery. Very soon afterward the same condition was observed in man by von Saemisch, Zehender, and others. Remnants of the hyaloid artery in man present very varied appearances. The remnant is usually attached to the optic disk, frequently to the temporal side, and extends forward either in the axis of the vitreous or eccentrically. In a few cases the attachment is to the posterior capsule of the lens, only the shred of connective tissue extending backward. The remnant of the hyaloid artery may extend but a very short distance from the disk or go well into the vitreous, terminating in a free end which sways on movements of the eye. The remnant may traverse the vitreous and be attached to the posterior lens capsule. At the optic disk there is frequently an ampulliform dilatation. In some cases almost, if not quite, the entire disk may be

Fig. 283

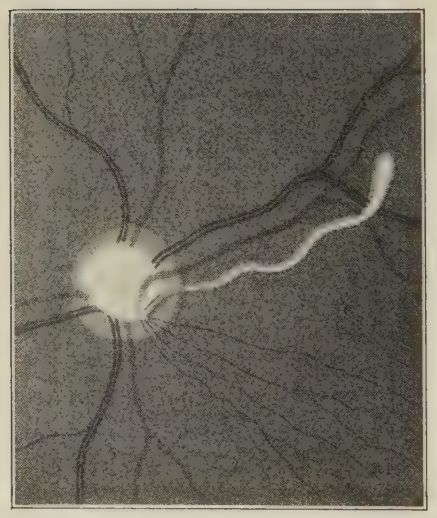

Persistent hyaloid artery and cyst of the nerve head. (After De Beck.)

[1] Graefe's Archiv, xxxviii, 3, p. 93.

covered by a delicate membrane which projects forward into the vitreous, forming the so-called *cyst of the nerve head.* At the lens the shred may break up into a number of branches. In some cases remnants of these branches are present in the form of small white spots on the capsule of the lens; in other cases short shreds of connective tissue extend backward into the vitreous body.

Although, as a rule, consisting of a non-vascular connective-tissue band or cord, the remains of the hyaloid artery may bear a small vessel containing blood which may extend from the optic disk to the lens. The vessel is connected with the central artery of the retina or one of its principal branches.

Eccentric Hyaloid Artery.—Observations of persistent hyaloid artery starting from a branch of the central retinal vessels situated some distance from the optic disk have been made.[1] The appearance differs in no essential particular from that of the artery starting from the optic disk

By transmitted light, remains of the hyaloid artery appear dark in color; by reflected light they appear white.

Pseudohyaloid Artery.—Remnants of the hyaloid artery must not be mistaken for connective-tissue shreds due to inflammatory processes, which not infrequently spring from the optic disk and sometimes bear blood-vessels. These inflammatory products are not, as a rule, so regular in form. There are usually other evidences of inflammation, but in some cases it is very difficult to differentiate between the two conditions.

Hemorrhage and inflammatory exudation may find their way into a patent hyaloid canal, and the organized shred of tissue which may result may closely resemble the persistent hyaloid artery.

Persistent remnants of the hyaloid artery do not, as a rule, interfere with vision, and the condition is not progressive.

Remnants of the network of fetal blood-vessels that occur at the periphery of the vitreous have been reported by Hirschberg.

Arterial loops originating from the central artery of the retina, either the main trunk or one of its branches, projecting into the vitreous for a greater or less distance have been reported by a number of observers.

Wiegels[2] reports a case of congenital microphthalmos in which the entire vitreous body was replaced by typical fatty tissue. A persistent hyaloid artery was present.

Persistent Canal of Cloquet.—This condition may be combined with persistent hyaloid artery, or the artery may be wanting. The appearance is that of a delicate gray, diaphanous tube, somewhat ampulliform at the optic disk, which extends into the vitreous, sometimes as far forward as the crystalline lens. At the optic disk the thin envelope covers the physiological excavation, seldom or never including the entire disk. It is claimed by some writers that the canal of Cloquet is present in all eyes as a central lymph space of the vitreous, but that the walls of the canal are seldom visible.

[1] Schöbl, Norris and Oliver's System, iii, p. 423.

[2] Graefe's Archiv, i, p. 368.

DISEASES OF THE VITREOUS.

Inflammation of the Vitreous (*Hyalitis*).—Primary inflammation of the vitreous probably never occurs. Inflammatory processes taking place in this body are *secondary* to the introduction of pathogenic or pyogenic germs.

Purulent Hyalitis.—When pyogenic microörganisms capable of multiplying in the vitreous are introduced into that body, the irritation and destruction that their growth produces by the development of toxins or otherwise call forth an invasion of leukocytes derived from the vessels and tissues of neighboring structures. The cells of the vitreous are so few that they exercise no influence on the process. On account of the absence of blood-vessels and the secluded position of the vitreous, microörganisms can only reach it after traversing other structures of the eye.

A penetrating wound of the globe may serve to introduce into the vitreous the staphylococcus, streptococcus, pneumococcus, or some other virulent microörganism which may develop an acute inflammation of the nature described. A septic chorioiditis, retinitis, or cyclitis, or a perforating ulcer of the cornea may supply the microörganisms which may invade the vitreous. In this way what is termed a hyalitis may be produced. The condition possesses no features peculiar to the vitreous alone. Purulent inflammation involving the vitreous becomes panophthalmitis, as a rule, and results in loss of vision with atrophy of the globe or phthisis bulbi.

Hyalitis Punctata.—By this term Benson[1] designates an appearance similar to keratitis punctata which he observed as situated just back of the crystalline lens. The patient had syphilis and was suffering from keratitis punctata and a mild iritis. The writer has seen a similar condition, the spots apparently occurring on the capsule of the lens in the patellar fossa, in a patient suffering from a mild cyclitis.

Muscæ Volitantes.—Visual sensations generated within the eye (entoptic) are produced by a number of conditions—opacities in the anterior chamber, in the crystalline lens, and in the vitreous. Entoptic images are also created by variations in the refractive index of the clear media of the eye and by phenomena of circulation in retinal vessels. Opacities of the fluid media of the eye produce entoptic images which are movable; opacities of the crystalline lens, images that are virtually stationary. The vitreous body is frequently the seat of changes which are not visible by use of the ophthalmoscope or by any method of objective examination; what appear to be small floating bodies in the vitreous result; these are termed *muscæ volitantes*, or *myiodesopsia*. When the vision is directed against a white screen, page, cloud, or clear sky, small brownish, diaphanous objects of fantastic form, small bodies with irregular processes float into the field of vision, being thrown

[1] Ophth. Rev., vii, p. 304.

upward on rapid movement of the eye upward, moving downward when the eye is held stationary.

Etiology.—It is very probable that these phenomena are due to shadows, cast on the retina by elements in the vitreous body whose behavior to light is different from that of the rest of the vitreous. Judging from their forms these elements are cellular, possibly remnants of embryonic cells of the vitreous which have produced the phenomena since the birth of the individual or have subsequently acquired that property. The permanency of the form of the image may be accounted for on this supposition. Disturbances of digestion are thought to stand in a causative relation.

The movements described correspond with the movements of the interior of a gelatinous mass on rapid rotation. The shadows observed do not interfere with vision, nor is there any danger of muscæ volitantes degenerating into a condition of an injurious nature, although there is abundant evidence to prove that they may increase under certain conditions of depression of the general health. The presence of the shadows is annoying, especially to neurasthenics who frequently become alarmed at what to them appears to be impending blindness.

Prognosis.—The shadows persist indefinitely.

Treatment.—There is no treatment known that will cause these phenomena to entirely disappear, but the correction of errors of refraction, the wearing of light, neutral-tint glasses, and the improvement of the general health will reduce the annoyance to a minimum.

Opacities of Vitreous.—These vary greatly in size and number. They originate from pathological processes outside of the vitreous itself —disease of the uveal tract and retina and from traumatism.

They may occur as dust-like opacities, flakes, dots, strings, bands, membranes, large, regular, or irregular masses. The color varies with the nature of the opacity. The opacity may be fixed or movable.

Dust-like opacities of the vitreous are due to the presence of fibrin (minute coagula) throughout the affected part, rather than to the migration of cellular elements. The color is usually of a grayish tone and the vitreous is diaphanous, while in cases in which a large number of cells are present the opacity is of a yellowish color and is dense.

Dust-like opacities may be general, as in some cases of uveitis; partial, as in some cases of localized chorioiditis and syphilitic retinitis. The density varies greatly from that sufficient to slightly cloud the fundus picture to complete obscuration and almost if not quite complete abolition of the fundus reflex.

Coagulated masses occurring in minute islets produce larger opacities, varying greatly in number, size, and shape.

Numerous diffuse opacities are derived from general inflammatory processes affecting the uveal tract and retina, while isolated opacities are common in high myopia and in focal vascular changes, as in atheroma of the vessels of the ciliary processes.

Symptoms.—Obscuration of vision is the principal symptom when diffuse opacities of the vitreous are present. Isolated opacities throw

shadows on the retina and are noticed as obscuration islets. The tension of the globe is usually below the normal. Pain is present only as a result of the inflammation that has produced the vitreous opacities.

Diagnosis.—See page 145.

Prognosis.—Opacities of this nature may disappear entirely if the cause can be corrected. The smaller opacities disappear much more readily and completely than the larger ones.

Membranous Opacities.—Membranous opacities are fixed either at one or both ends, usually at both ends, either to the retina or to the retina and ciliary body or to the lens. They occur as bands, cords, membranous or cobweb-like structures, sometimes extremely thin, sometimes extremely dense. They may bear blood-vessels. The denser bands are met with most frequently in the anterior portion of the vitreous and result from cyclitic inflammatory processes. Membranous opacities develop on the periphery of coagula that form in the vitreous as a result of the escape of the fluid portion of the blood or of the fluid and corpuscular elements of the blood combined. The formative corpuscular elements are derived from the retina or from the chorioid and ciliary body. (See Retinitis Proliferans, p. 458.)

Results.—The result of the formation of membranous opacities is as a rule great impairment of vision, not only by obstruction to light, but also because of detachment of the retina which follows the cicatricial contraction to which these membranes are subject.

Prognosis.—The membranes are usually permanent. They do not tend to disappear.

Hemorrhage into the Vitreous.—Hemorrhage into the vitreous occurs from the vessels of the ciliary body, chorioid, and retina as a result of traumatism or of disease. Hemorrhages are of all degrees of severity from a minute escape of blood to a hemorrhage that extends throughout the greater part of the vitreous body. Recurrences are not uncommon.

Etiology.—Hemorrhages that occur between the retina and the vitreous are known as subhyaloid hemorrhages. They come from the retinal vessels (rarely the chorioidal vessels), usually the veins, the blood passing through the membrana limitans interna of the retina. The blood may be confined to this space or it may break through the outer condensed layer of the vitreous and enter that body deeply.

Hemorrhage into the vitreous, often without assignable cause, is met with in young persons ("juvenile hemorrhage into the vitreous") between the age of fifteen and twenty-two years. It occurs in males more frequently than in females and appears to bear some relation to the establishment of the sexual function. Anemia is frequently present. Epistaxis sometimes precedes the intra-ocular hemorrhage (Abadie). Engorgement of the retinal veins has been observed (Friedenwald). Constipation, irregularities of the circulation and gout (Hutchinson) are thought to be causes. While one eye only may be affected, both eyes are sometimes involved.

Hemorrhage into the vitreous due to menstrual disturbances (vicarious

menstruation) has been observed. In these cases the hemorrhage may be monolateral or bilateral, and may recur with each menstrual period.

Symptoms.—Small hemorrhages are unaccompanied by pain. If the hemorrhage is large the tension of the eyeball may be increased and the increase in tension may produce severe pain. The pain is referred to the eyeball and to the neighboring parts of the head. When the intraocular tension becomes normal the pain disappears.

In the early stage of hemorrhage into the vitreous the patient often describes the obscuration of vision as of a veil or shower of opacities or dark clouds, often having a reddish hue, dropping before the eye. Dense masses are seen as dark clouds having crimson edges. When the hemorrhage is very large and dense almost complete blindness is induced. If the layer of blood is very thin the sensation is like that produced by looking through a crimson veil.

Results.—Hemorrhage, if small, may be absorbed without leaving a trace. Frequently some remnant remains in the form of cicatricial tissue, the result of organization of a part of the clot. Bands of cicatricial tissue or new-formed membranes, shrinking of the vitreous, and detachment of the retina, with complete loss of vision and shrinkage of the globe, may follow.

Treatment.—The internal administration of gallic acid, ergot, and iron, and the use of purgatives in the cases of recurrent hemorrhage into the vitreous may be of some value in limiting or preventing the flow. Subcutaneous injections of gelatinized serum in the dose of 50 to 150 c.c. into the tissues of the abdomen, repeated after three days, have been employed by Fromaget[1] with good results. Fromaget also suggests the use of calcium chloride in dose of 5 to 6 grams daily per mouth. After the hemorrhage has taken place absorbents should be employed.

Fibrinous and some cellular opacities of the vitreous and hemorrhage may be caused to disappear in great part. Treatment must be directed to correcting the disease which permitted the development of the opacities. In addition absorptive treatment and absorbents should be employed—thermal diaphoresis by use of cabinet or Turkish bath, medicinal diaphoresis by use of jaborandi and pilocarpine by the stomach or pilocarpine hypodermically, cholagogue laxatives, etc., are useful. Probably the greatest dependence is to be placed on the iodide of potassium, sodium, or strontium, on mercury and iron, the last in cases of low hemoglobin percentage, all in small dose, but regularly administered and continued over a long period of time. The diet should be appropriately regulated. When the vision is sufficiently good to induce the patient to attempt to use the eyes for close work, accommodative effort should be abolished by use of atropine, particularly if the ciliary body is involved in the process.

Subconjunctival injections have been advocated. Ligature of the common carotid for recurrent hemorrhages into the vitreous has been performed in a number of cases (Mayweg, Axenfeld, Duby,[2] Vasquez-

[1] Ann. d'ocul., September, 1903.

[2] Trans. Sec. on Oph., A. M. A., 1907.

Barriere[1]). Duby's case was not benefited; in the others some degree of vision was preserved. The operation is indicated only in those cases in which blindness is imminent from recurrent hemorrhages.

Fluidity of the Vitreous (*Synchysis*).—In high degrees of myopia with opacities in the vitreous, in old people who suffer from vascular degeneration affecting the vessels of the uveal tract and retina and in some patients who have suffered from uveitis, the opacities in the vitreous may be seen to float about, describing quite extensive excursions on movements of the eyes. In these cases the vitreous is said to be "fluid." In all probability this is true in those cases in which the movement of the opacity is very free, but in other cases the vitreous is simply softened or less firm than normal. All gelatinous masses, when quickly rotated, undergo a torsion movement within themselves whereby the motion of the periphery does not correspond with the motion of the interior of the mass. The less firm the mass the greater the difference in the extent of the opposed movements or oscillations. In cases of fluidity of the vitreous the tension of the eye may be reduced, but it is not always so nor can we say it is the rule. Such cases present complications when operative procedures necessitating the opening of the globe are undertaken.

Fluidity of the vitreous is associated with impaired vision in almost all cases.

Treatment.—Treatment is of no avail.

Asteroid Hyalitis (Benson).[2]—This consists in the appearance in the vitreous of minute, highly refractive globular masses. These bodies, which are fixed in the vitreous, appear cream-colored by oblique illumination. In the case reported by Benson, they remained unchanged during the nine months that the patient was under observation.

Synchysis Scintillans.—This condition is characterized by the presence in the vitreous of crystals of cholesterin, tyrosin, and the phosphates. According to Sgrosso,[3] who examined two eyes presenting this condition, margarin salts, fat crystals, and calcium salts are also found. When the eye is examined with the ophthalmoscope the light is reflected from the surfaces of the crystals, producing a beautiful, rapidly changing, sparkling or scintillating effect, as of showers of silver or golden spangles, rapidly changing on movements of the eye. In some cases the crystals are very numerous; in others, relatively few. They are located throughout the vitreous, often clustered more thickly in some parts than in others. The crystals appear to float, but in all probability are held in suspension in the vitreous, the scintillations being caused by oscillation of the vitreous. One or both eyes may be involved. The condition is seldom observed in youth, but occurs in individuals past middle age. Cholesterin crystals are sometimes present in the crystalline lens and in the aqueous humor.

Etiology.—The cause is not well understood. The condition is seen in eyes with old chorioiditis and in some cases after cyclitis. Alcoholism

[1] Klin. monatsbl. f. Augenh., January, 1908.

[2] Trans. Ophth. Soc. United Kingdom, xiv, p. 10.

[3] Ann. di ottalm., xxii, 1-55.

and gout are thought to be causative. The condition is at times present in eyes which otherwise appear to be normal. The writer has observed it in eyes with normal vision and apparently normal fundi. Age is apparently a strong causative factor.

Symptoms.—The patient is often ignorant of any change in the eyes. The sparkling and scintillations are not always observed subjectively. In a patient with normal vision whose vitreous bodies were quite full of crystals nothing but a few small floating opacities were observed by him. The vision may be obscured, but this in apparently due to chorioiditis or retinitis, not to the presence of the cholesterin and other crystals. There is no external sign of disturbance.

Treatment.—No remedies have as yet been found that exert a beneficial effect in these cases.

Entozoa in the Vitreous.—Etiology.—Three kinds of parasites have been found in the vitreous, namely, cysticercus, hydatid cyst (Hill-Griffith), and filaria. The cysticercus found in the eye is the cysticercus cellulosæ, the larval form of the tenia soleum. The adult parasite is found only in man, the intermediary host being the pig, where the parasite occurs in the muscles and other tissues in the form of the cysticercus cellulosæ. In order to produce cysticerci the ova of the tenia must enter the stomach. There the embryos are set free; they penetrate the walls of the stomach and enter the blood-stream, developing into the cyst or bladder form wherever they may lodge. The host of the tenia soleum may infect himself by causing the ova to pass from the intestine into the stomach. The ova may be carried into the stomach by drinking-water, food, etc. Tenia soleum develops in the host from the cysticercus injested by eating raw or undercooked pork infected by cysticercus. Cysticercus in the human body is met with most frequently in the inhabitants of countries where the practice of eating uncooked pork is most prevalent. North Germany furnishes the greater number of cases. It requires about three months for development from the ovum to the cystic stage. The cysticercus may live in man twenty years (Stiles). It may live in the eye two or three years at least.

The parasite appears most frequently between the chorioid and retina. It frequently perforates the retina and appears in the vitreous, but it may develop primarily in the vitreous, being carried to this body by the blood-vessels of the retina and ciliary processes. The parasite may develop in individuals at all ages.

Symptoms.—The development of cysticercus in the vitreous is accompanied by impairment of vision which may progress to complete loss of vision. Opacities of the vitreous appear at an early stage and increase in number as the time of the presence of the parasite increases.

Diagnosis.—The appearance is well described by Hill-Griffith.[1] "The ophthalmoscope showed a large, spherical, bluish-white cyst, and, springing from this, the neck of the animal like an alabaster pillar, surmounted by the head and suckers, which, with its slow, regular and

[1] Norris and Oliver's System, iii, p. 392.

graceful movements, reminded one of an elephant's trunk." When the parasite is alive the diagnosis is easy even when it is situated beneath the retina, although in the latter position it may be confounded with sarcoma of the chorioid or glioma retinæ. Careful and long study will enable one to detect the movements. When the parasite is dead the diagnosis is difficult because of the changes in the wall of the cyst and of the exudation that forms about it.

Prognosis.—This is always grave if the development is permitted to progress. If the character of the affection is recognized early, before the secondary lesions are very far advanced and the cyst removed, the prognosis is somewhat better. Morax[1] has collected 104 cases in which operation was performed (60 cases of cysticercus in the vitreous, 44 cases subretinal). The cyst was extracted in 79 cases. In 31 cases the result was cosmetic only; in 13 cases the degree of vision present at the time of operation was apparently preserved; in 28 cases there was some improvement in vision. Subacute iridocyclitis and suppurative chorioiditis may develop, followed by atrophy of the globe.

Prophylaxis.—Thorough cooking of meats destroys the entozoa. The inspection of meats with the rejection of all containing cysticerci has reduced the number of cases of cysticercus occurring in eyes in Germany, as well as elsewhere.

Treatment.—Medicinal treatment is of no avail. The surgical procedure consists in making a meridional incision through the sclera and chorioid over the site of the parasite after having exposed the sclera by dissecting away the conjunctiva and subconjunctival tissue. The incision should be from 7 to 10 mm. long. Frequently the cysticercus will present as soon as the incision is completed. If this does not occur, it is necessary to introduce fine-tooth forceps, seize the cyst and remove it. When well attached to retina or chorioid the removal is greatly complicated.

Echinococcus (*Hydatid Cyst*).—Two cases of echinococcus within the eye have been reported, one by Hill-Griffith[2] and one by Werner.[3] Hill-Griffith's case occurred in a girl, aged three years and eight months. The cyst was in the vitreous chamber, presenting as a dense, white, non-vascular opacity back of the crystalline lens. Tension normal. Atropine was employed, causing the development of glaucoma. The eye was blind. Enucleation was performed. On section a cyst was found occupying almost the entire vitreous chamber; retina and chorioid practically normal. "The cyst wall was composed of numerous superimposed structureless lamellæ."

In Werner's case the cyst occurred between retina and chorioid. It was a typical echinococcus cyst, containing brood-capsules. The capsules contained many heads or scolices.

Filariæ in the Vitreous.—Filariæ have been observed in the vitreous by Schoeler and by Eversbusch ophthalmoscopically. Kuhnt[4] observed

[1] Precis d'ophtalmologie, Paris, 1907, p. 356.
[2] Norris and Oliver's System, iii, p. 393.
[3] Trans. Ophth. Soc., xxiii, 1903.
[4] Arch. f. Augenheilk., xxiv, 1892.

the parasite ophthalmoscopically and afterward verified the observation microscopically.

Blood-vessel Formation in the Vitreous.—New-formed blood-vessels in the vitreous are probably always preceded by the formation of a coagulum due to the escape of plasma from the blood-vessels, as in retinitis proliferans (see p. 458). The development may take place from the optic disk or from any vascularized portion of the retina. Formations from the disk are most common. In a case described by Marple[1] there was an interlacing system of blood-vessels projected forward into the vitreous, coming from the upper, lower, and nasal borders of the disk. Congeries of vessels or only a few small vessels may be present.

Etiology.—The causes of the formation of blood-vessels in the vitreous are similar to those that cause retinitis proliferans, namely, congenital dyscrasiæ, syphilis, traumatism, and diabetes (Nettleship and Lawson). Non-traumatic cases are usually preceded by retinitis or neuroretinitis.

Prognosis.—The condition may go on to the full development of retinitis proliferans, with the resulting disastrous effect on vision. Some cases are apparently self-limited, recovery taking place with retention of good vision. If syphilis is the cause, vigorous antisyphilitic treatment will bring about a favorable issue with retention of good vision.

Treatment.—This should be directed to the improvement of the general condition of the patient. All specific disease conditions should be appropriately treated. Should glaucoma develop, an iridectomy may be performed. Other local treatment is of no avail.

Fig. 284

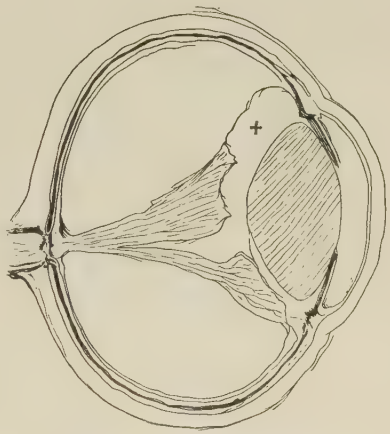

Detachment of the vitreous three weeks after a perforating wound of the sclera with a fork. Area of suppuration in the detached vitreous.

Detachment of the Vitreous.—Either because of a lessening of its volume as a result of disease or because of an inability to fill a constantly expanding sclera, as in progressive myopia, detachment of the vitreous occurs. The deleterious results would be slight if it were not that detachment of the retina accompanies detachment of the vitreous in a large percentage of the cases. Anterolateral detachment has been observed.

Etiology.—Chorioiditis, hemorrhage (subhyaloid), traumatism, high myopia, intra-ocular growths. According to Parsons,[2] "the detached vitreous always contains foreign inflammatory elements," the contraction of which tends to reduce the volume of the vitreous.

Treatment.—Treatment is of no value.

[1] Trans. Amer. Ophth. Soc., 1901.

[2] The Pathology of the Eye, ii, p. 429.

Tumors.—In some cases of glioma and rarely in melanotic sarcoma (Ewitzky) tumor cells may be carried into the vitreous and develop a metastatic tumor in that body. The form of glioma in which this is most common is glioma endophytum (Parsons).

Fungus Growths.—Cultivations of the Aspergillus fumigatus have been found in the vitreous[1] as a result of a penetrating wound of the eye. Some pain was experienced and hypopyon was present on the thirteenth day. Examination after enucleation on the fourteenth day disclosed the presence of the fungus in the vitreous. Leber, Noble, and others have reported similar cases.

Ossification.—Cases of primary ossification of the vitreous occurring in man in degenerated eyes have been described by Antonelli[2] and by Ruger.[3]

Foreign Bodies in the Vitreous.—See Foreign Bodies in the Globe.

[1] Römer, Klin. monatsbl. f. Augen., April, 1902, p. 331.
[2] Lagrange, Tumeurs de l'Oeil, Paris, 1901, i.
[3] Ann. di ott., xx, 1891.

CHAPTER XXIII.

THE EYEBALL.

Anophthalmos.—This condition, strictly speaking, is one in which there is complete absence of the eyeball. It is bilateral more frequently than unilateral. The sexes are affected about equally. As a rule, the lids are well-formed, but they may be adherent. The palpebral fissure is narrow and the conjunctival area much reduced. The lachrymal apparatus is usually normally developed; some defects may exist. As a rule, the child is well-formed, but occasionally harelip, cleft palate, supernumerary digits, etc., are met with. A number of cases have come to section. It is found that the orbits are smaller than normal. Anteriorly the orbit is closed by the tarsoörbital ligament covered by conjunctiva, with a small depression where the globe should be. The extrinsic ocular muscles are partly developed, extend forward, and are inserted into the tarsoörbital ligament at the depression. In some of the cases a rudimentary optic nerve terminates at the optic foramen. In a case described by Van Duyse,[1] the optic nerves, chiasm, optic tracts, and anterior geniculate bodies were wanting. The corpora quadrigemina were scarcely indicated. A rudimentary sclera and chorioid were present in the case. In some of the cases the olfactory bulbs are wanting; in one case one of the cerebral hemispheres was wanting. It is evident that in these cases there is failure to develop the necessary primary cerebral vesicles for the formation of the eyes and in case of absence of the olfactory nerves for these structures also. The formation of the mesoblastic parts of the eye apparently go on to some extent, rudimentary sclera and chorioid, muscles, etc., even in the absence of the nervous framework.

Fig. 285

Congenital anophthalmos. (Van Duyse.)

[1] Arch. d'opht., xix, p. 142.

Cryptophthalmos.—In the very rare cases in which there is absence of conjunctival sac and lids, the term cryptophthalmos is used to designate the condition. The eyeball may be present beneath the skin and its movements may be appreciable by inspection. In some of the cases the orbicularis palpebrabrum muscle is present.[1]

Microphthalmos.[2]—Microphthalmic eyes may be divided into two classes, (1) those in which the eyes are simply abnormally small, and (2) those which present some other congenital abnormality.

There is no well-defined dividing line between the perfectly formed microphthalmic eye and the normal eye. The highly hyperopic eye may be regarded as a microphthalmic eye. In the microphthalmic eye the diameter and the radius of curvature[3] of the cornea are less than in the normal eye. The more acute curvature of the cornea would render an eye with a normal antero-posterior diameter highly myopic. Since these eyes are highly hyperopic, the antero-posterior diameter is much shorter than the departure from the normal in the refraction would indicate. Not only is the antero-posterior diameter shorter, but all diameters are shorter.

Second, the congenital abnormalities other than diminution in size are with few exceptions consequent on imperfect closure of the retinal fissure. In the milder cases there is shallow posterior staphyloma, coloboma of the optic-nerve sheath, coloboma of the chorioid, iris, and possibly of the ciliary body. These have been considered under their appropriate headings. There are all degrees of developmental defect, from those above mentioned to the production of large cystic swellings, with almost complete absence of a globe proper. Both eyes are usually involved, although the abnormality may be greater in one than in the other.

Development of Cysts.—The cysts that develop are single, as a rule, but may be double.[4] They are always attached to the rudimentary globe at the posterior part, below and to the inner side of the optic nerve. As a rule, they present symmetrical swellings of the lower lids, but in some cases the bulging is above.[5]

Etiology.—The origin of microphthalmos with cystic formation has been ascribed by Arlt[6] to increased intra-ocular pressure with stretching of the tissues at the site of the fetal cleft.

Kundrat[7] ascribes it to a projection of a fold of retinal tissue through the fetal cleft into the mesoblastic tissue and the subsequent development of the cyst with its lining of rudimentary retina.

Symptoms.—The eyeballs to which such cysts are attached have presented the following conditions: Cornea small, cloudy, vascular.

[1] Van Duyse, Annal. d'oculist., 1889.

[2] For a comprehensive review of this subject, see Natanson, Graefe's Arch., lxvii, Heft 2.

[3] There is a difference of opinion in regard to the radius of curvature in highly hyperopic eyes Leber, Schneideman, Hertel and Best have found a radius of curvature shorter than the normal. Sattler and Fleicher have found high degrees of flattening of the cornea.

[4] Collins, Trans. Ophth. Soc., xiii; Zentmayer and Goldberg, Ann. of Ophth., January, 1904.

[5] Rogeman, Ann. d'oculist., January, 1904.

[6] Anzeiger du K. K. Gesell. d. Aerzte, Wien, 1885, No. 17.

[7] Wien. med. Blätter, 1885, Nos. 51–52; 1886, 53.

PLATE XXIV

Microphthalmos.

Sclera often thickened, continuous, with the cyst posteriorly. Iris, often with coloboma, may be wanting (irideremia). Lens defective, attached to remains of the hyaloid artery *in situ* or drawn backward into the vitreous chamber. The lens fibers may be very irregularly disposed. Lens cataractous, with calcareous deposits. Vitreous body absent or partly formed. Vitreous chamber communicates with the cavity of the cyst. Chorioid deficient at the point of the attachment of the cyst and often throughout the space corresponding to the fetal retinal fissure. The retina is thrown into folds in the globe, where it is often approximately normal; it dips into the cyst cavity and is generally found in a rudimentary form, covering almost if not quite the entire inner surface of the cyst wall.

The tension of these cysts is below the normal tension of the eyeball. The orbits in cases of this nature are of normal size.

Treatment.—Excision.

Fig. 286

Cysts of the globe.

Buphthalmos, Hydrophthalmos, Megalophthalmos.—See chapters on Cornea and Glaucoma.

Rudimentary Ocular Vesicles.—These, in the form of monocular cysts lined with pigmented, hexagonal epithelium like that of the retina, have been described occurring in ovarian tumors (Kummell), in tumor of the testicle (Verneuil and Guersant), in a tumor removed from the coccyx from a patient three years of age.[1]

Exophthalmos.—Exophthalmos may be monocular or binocular. In this condition the palpebral fissure is abnormally wide and often appears to be abnormally long. The unusual exposure of the sclera produces a striking appearance. When the lids are closed a profile view shows well the unusual prominence of the globe. In marked cases the lids cannot be closed over the eyeball and the desiccation of the cornea adds to the repulsiveness of the picture.

[1] Van Duyse and De Bersaques, Ann. de la Soc. belg. de Chir., October, 1895.

Etiology.—The prominence of the globe may be due (1) to the condition of the globe itself, as in (*a*) marked myopia and in (*b*) buphthalmos; (2) to malformation of the orbital walls, as in (*a*) oxycephalus, (*b*) osteoporosis, (*c*) displacement by the development of processes in neighboring sinuses causing a displacement of the orbital wall, (*d*) encephalocele; (3) to changes in the contents of the orbit itself, as (*a*) vascular tumors, (*b*) solid tumors, (*c*) abscess, (*d*) hemorrhage, (*e*) edema of tissues as in erysipelas, (*f*) emphysema, (*g*) cysts of various kinds, (*h*) orbital phlebitis; (4) to conditions affecting parts of the orbital contents secondarily, as (*a*) exophthalmic goitre, (*b*) hemiplegia externa of intra-orbital origin, (*c*) arteriovenous aneurism, this condition giving a pulsating exophthalmos; (5) to affections of the recti muscles, (*a*) to total paralysis, the loss of muscular tone permitting the eyeball to advance, (*b*) to extensive tenotomies of the ocular muscles.

Intermittent Exophthalmos.—This occurs (*a*) as a result of disease of posterior ethmoid cells, in rare cases, in which the escape of secretions is temporarily interfered with. When ethmoiditis affects cells that pass well under the floor of the orbit posteriorly this may occur (the writer has observed two cases). The exophthalmos is usually accompanied by symptoms of retention of secretion. When the contents of the cells are evacuated, which sometimes takes place spontaneously, the exophthalmos disappears to again reappear when secretion is again retained. (*b*) Association with menstruation. Teilais[1] reports two cases. The exophthalmos was not affected by pressure on the common carotid.

Pulsating Exophthalmos.—This may be due to (1) arteriovenous communication (aneurismal varix), traumatic (68.3 per cent.),[1] or spontaneous (31.7 per cent.), occurring between the internal carotid and the cavernous sinus; when spontaneous the rupture follows aneurismal dilatation or disease of the wall, as in atheroma. (2) Aneurism of the ophthalmic artery in or outside of the orbit. (3) The development of angiocavernoma. (4) Varicose dilatation of veins. (5) Thrombosis of the cavernous and adjacent sinuses. (6) In the development of malignant tumors. (7) Pulsating aneurismal sacs in the orbit.[2] (8) Orbital encephalocele. Women are more frequently affected than men, the left eye more frequently than the right.

Rupture of the wall of the internal carotid establishing communication with the cavernous sinus may be caused by fracture at the base by a crushing force applied to the head,[3] apparently by contrecoup,[4] by entrance of foreign bodies,[5] by pregnancy.

Symptoms.—Proptosis, edema of tissues of disk, engorgement and frequently pulsation of retinal veins, venous retinal hemorrhages; small retinal arteries; diplopia due to displacement of globe; vertigo; deafness; tinnitus; humming sounds due to the rush of blood into the cavernous

[1] Ann. d'oculist., cxix, p. 423.
[2] Sattler, H., Klin. Monatsbl. f. Augenh., July, 1904, p. 188.
[3] Sattler, New York Med. Record, June 13 and 20, 1885.
[4] Usher, Ophth. Rev., November, 1904, p. 179.
[5] Brounschweig, Monatsbl. f. Augenh., March, 1904.

sinus. Livid appearance of the conjunctiva and a dusky red appearance of the integument of the palpebral area. As a rule, the tumor pulsates. This is appreciable on palpation and on inspection. Rhythmic symptoms, bruit and pulsation cease on compression of the internal carotid on the affected side. Swelling may invade the frontal and temporal region. On auscultation a bruit is heard over temporal and parietal regions, margin of orbit above and below; also when the stethoscope is placed over the closed upper lid. The bruit varies much in different cases. It may be a rhythmic blowing sound synchronous with systole. It may be an irregularly interrupted sound, as of air passing through the bronchial tubes. The noises may be augmented by physical exertion or mental excitement.

Pain is not a prominent symptom; it is frequently absent. Hemorrhage from the nose is not uncommon.

Vision is impaired in about 50 per cent. of the cases. Movements of the eye are limited only when proptosis is extreme.

The proptosis may often be reduced by pressure; it becomes more marked on lowering the head, crying, coughing, etc.

Of 175 cases of pulsating exophthalmos in which there was arteriovenous communication or aneurism of the ophthalmic artery, spontaneous recovery occurred in 20. Compression of the common carotid healed 8 of 53 so treated. Ligation of the common carotid was successful in 54 per cent. of the cases so treated; mortality following this operation, 10 per cent. Prognosis regarding vision is not good.[1]

Diagnosis.—Whether or not a case can be classed as one of pulsating exophthalmos depends entirely on the pulsation. To determine this is an easy matter. It is not so easy to determine the source of the pulsation. The history of the case will aid materially. If the tumor appears a few days after some traumatism to the head, or if it develops even without a history of traumatism if not preceded by inflammation, it will almost invariably be due to rupture of the carotid in the cavernous sinus. If the development is slow and there is little or no engorgement of conjunctival and palpebral veins, an aneurism of the ophthalmic artery or angiocavernoma may be suspected. If the pulsation has been preceded by inflammation, such as erysipelas, otitis media purulenta, etc., orbital venous thrombosis should be considered.

Prognosis.—A few cases of spontaneous recovery are recorded. In other cases the prognosis is favorable if operative procedure is instituted. The operation that promises most is ligation of the common carotid on the affected side.

Treatment.—The treatment depends on the character of the case. If there is venous thrombosis the treatment must be sustaining and expectant. If due to vascular tumors, as aneurismal sacs, they must be excised. The Krönlein operation may be resorted to to expose the contents of the orbit. If due to aneurism of the ophthalmic artery, proximal ligation should be practised if feasible.

[1] Stormann, Pulsating Exophthalmos, Copenhagen, 1898.

Should this not be possible, ligation of the internal carotid on the corresponding side should be resorted to. In cases due to aneurismal varix ligation of the common carotid has been most often performed and has given the best results. This may be followed by the administration of iodide of potassium. Constant digital and mechanical pressure of the common carotid have been practised with success in a few cases. Intermittent pressure has also been employed. If intermittent pressure is employed the pulsation and bruit must be caused to disappear for some minutes at each sitting (Sattler).

Enophthalmos.—Recession of the eyeball into the orbit may occur spontaneously or as a result of traumatism. Spontaneous recession is usually of low degree and is bilateral.

Etiology.—It occurs as a result of wasting disease, cholera, typhoid fever, etc., and senility, and is due to a diminution in the volume of orbital fat. It comes on slowly without symptoms, is accompanied by narrowing of the palpebral fissure, and is complicated in some cases by spasmodic entropion of the lower lids.

Traumatic Enophthalmos.—This is seldom bilateral. The recession of the eyeball may be considerable. Burnett[1] reports a case in which the recession was one centimeter. The recession may follow the injury immediately or may develop some days or weeks after the injury. The injury usually does, but may not directly affect the walls or contents of the orbit. Lederer[2] reports 2 cases and has collected 52 from the literature. Enophthalmos is supposed to be due to (*a*) fracture of orbital walls and escape of orbital fatty tissue, thus drawing the eyeball backward (Franke); when this is the case the floor of the orbit is usually broken through and the tissue of the orbit sags into the antrum; the eyeball has been found in the antrum (Langenbeck); (*b*) to paralysis of Müller's orbital muscle; (*c*) to injury to or disease of the "check" ligament (Schoemaker); (*d*) to trophic disturbances of the orbital tissues from injury to the nerves (Purtscher); (*e*) to cicatricial contraction due to changes in the retrobulbar tissue; (*f*) to varicocele of the orbit (Van Lint); (*g*) to paralysis of the sympathetic (see page 194).

Symptoms.—The eyeball is retracted and usually lower than its fellow. Its mobility is limited in some or all directions. Its position in many cases changes with a change in the position of the head, coming forward when the head is thrown forward. In some cases the enophthalmos may be converted into exophthalmos by (*a*) compression of the jugular (Pasetti), (*b*) by throwing the head forward and sometimes by throwing the head backward (Sattler). Vision in almost invariably impaired; there is diplopia in many cases. There is no pain except as a result of the traumatism.

Injuries of the Globe.—Injuries of the globe may be classified as (*a*) contused, (*b*) penetrating, with or without retention of foreign body, (*c*) by combustion.

[1] Amer. Jour. of Ophth., July, 1899.

[2] Arch. f. Ophth., liii, 2, p. 241.

Contused Wounds.—Contused wounds may result in abrasion of the cornea, rupture of the cornea or sclera, hemorrhage into the interior of the eye from the vascular or nerve-tissue tunics, injuries to the iris, ciliary body, chorioid, retina, optic nerve, crystalline lens, and vitreous, all of which have been described in the chapters bearing on these individual parts. Endogenous infection may follow.

Endogenous Infection.—As has been shown by the experiments of Selmskowsky and Woizichowsky,[1] and others, injury to an eye by contusion lessens the resistance of the tissues to the invasion of microorganisms. Endogenous infection, which otherwise would not occur, takes place under these conditions, and panophthalmitis may be established.

Dislocation of Globe.—Dislocation of the globe external to the lids, into the antrum of Highmore, or into the nasal cavity has been observed; also total ablation of the eye.

Paralysis of Ocular Muscles.—This sometimes follows contused wounds of the globe. The abducens suffers most frequently. The prognosis in these cases depends on the extent of the injury.

Penetrating Wounds.—These are produced in every conceivable way and endanger the eye (*a*) in some degree in proportion to the extent of the wound, (*b*) depending on location, (*c*) in regard to the infection introduced, (*d*) depending on the chemical nature of the substance inflicting the wound.

If the wound is incised, clean, and free from infection, it may be quite extensive in cornea or sclera and not greatly endanger the integrity of the globe. If the contents of the globe have largely escaped, if the ciliary body is partly or wholly cut across and a portion of the ciliary body is prolapsed or incarcerated, the globe will require removal either at once or eventually.

If the wound is infected by pathogenic or pyogenic microörganisms, the probabilities are that the eye will be lost; however, if the wound is not large and the infection not severe, proper treatment may bring about recovery.[2] The inflammation that results is usually one affecting the entire contents of the globe (panophthalmitis).

This manner of infection is *exogenous* in contradistinction to that form in which the microörganism is contained in the blood and enters by means of the blood-vessels.

Exogenous Infection.—The microörganisms that have been recognized as producing panophthalmitis are the Pneumococcus lanceolatus,

[1] Arch. of Ophth., September, 1903.

[2] A patient whose eyeglass was struck and broken by a small stone from the street, carrying more or less dirt, came to the writer. The cornea was cut in three places by the fragments of glass. Two of the wounds were perforating wounds. A shred of vitreous hung from one of the wounds. Some particles of earth were present in the corneal tissue at the wound, and two or three very small particles could be seen in the vitreous just beyond the equator of the lens. The prolapsing vitreous was excised, the wound and incarcerated iris thoroughly cleansed, and the iris returned to the anterior chamber. A very violent inflammation followed, affecting iris, ciliary body, and anterior portion of the chorioid, but eventually the inflammation subsided, the exudation in the vitreous body and anterior chamber was absorbed, and vision of $\frac{20}{40}$ + was obtained and retained.

Streptococcus pyogenes, Bacillus subtilis, Bacillus coli communis, Bacillus perfringens, Bacillus pyocyaneus, influenza bacillus.

The wound that receives the infection need not necessarily be a perforating one; an ulcer which may result subsequently perforates and permits infection of the contents of the globe. Systemic infection sometimes follows infected wounds of the eyeball. Fromagat[1] reports a case of tetanus and death following a wound of the eyeball and its adnexa.

Burns of the Eyeball.—The effect of *burns* from quick-lime and acids have been considered in the chapters on Conjunctiva and Cornea.

Masses of molten metal, glowing brands or heated metal rods may cause entire destruction of the globe, leaving only charred remnants.

Penetrating Injuries with Retention of Foreign Bodies.—When the eyeball is injured by explosions of dynamite, its tissues are apt to be filled with chemically injurious substances (nitroglycerin and silicious earth, particles of stone, etc.), and vision is destroyed not so much by suppuration, as infection does not often occur, as by destruction of tissue and opacification of the transparent media. Of twenty persons injured by dynamite,[2] eight became totally blind in both, seven in one eye, and only two had sufficient vision to resume their occupation.

Foreign bodies of all descriptions enter the eye—metal, glass, wood, scales of dry paint, bone, ivory, stone, coal, etc. The point of entrance is usually through the cornea or the sclera near the sclerocorneal junction. Entrance through the sclera may occur at any point. The progress of the foreign body may be arrested at any point. It may just penetrate the cornea or sclera, may pass entirely through the eyeball. The size of the object, of course, varies greatly. The writer has seen a cube of steel measuring 12 mm. entirely concealed within the sclera. He has removed a piece of steel $\frac{1}{4}$ mm. in diameter from the vitreous body.

Fig. 287

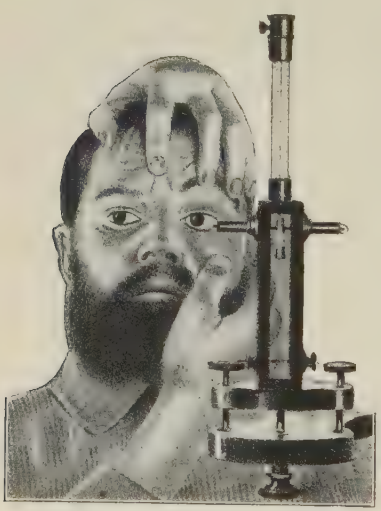

Sideroscope. (Axenfeld.)

Symptoms.—When a foreign body enters the eye there is usually more or less shock followed by pain. Disturbance of vision depends on the size of the foreign body, point of entrance and course, and amount of hemorrhage.

Diagnosis.—The history of the case is of some value, but the impressions of the patient are of but little value. Not infrequently the patient thinks that something has struck the eye, but has not entered. If the foreign body can be seen by simple inspection or by means of the ophthalmoscope, the diagnosis is positive. If it

[1] Arch. d'opht., xiv, 77, p. 657.

[2] Von Hippel, Graefe's Arch., xxxiii, 30, 205.

cannot be so seen other methods must be employed. Other methods available are the sideroscope, magnet, and the *x*-ray.

Sideroscope.—The sideroscope, if properly constructed and properly mounted, is of value in indicating the presence of a magnetic body in the eye *or its vicinity.* However, when it is used care must be taken to exclude any other magnetic body from the "field" of the needle of the sideroscope, otherwise the results are unreliable. The impossibility of determining the location of the magnetic body within one-half to three centimeters, and the fact that the method is applicable to magnetic bodies only, detract greatly from the value of the sideroscope as a means of locating foreign bodies in the eye.

Magnets.—The only magnets that are of much diagnostic importance are the powerful magnets—those that are usually termed "giant magnets." The diagnosis of a magnetic body in the eyeball or in the tissues in the anterior portion of the orbit or in the lids can be made with the giant magnet ordinarily, provided the magnetic body is of suitable size; but if the magnetic body is very minute or is lodged in the posterior segment of the globe, or if it is bound down by adhesions or is deeply situated in the tissues of the orbit, the magnet often fails as a means of diagnosis. It is, of course, of no value in determining the presence of non-magnetic foreign bodies.

TRANSPARENCY OF VARIOUS SUBSTANCES FOR RÖNTGEN RAYS.[1]

Material.	Sp. gr.	Transparency.	Material.	Sp. gr.	Transparency
Pinewood	0.56	2.21	Tin	7.28	0.118
Walnut	0.66	1.50	Zinc	7.20	0.116
Paraffin	0.874	1.12	Iron	7.87	0.101
Rubber	0.93	1.10	Nickel	8.67	0.095
Wax	0.97	1.10	Brass	8.70	0.093
Stearine	0.97	0.94	Cadmium	8.69	0.90
Cardboard	....	0.80	Copper	8.96	0.084
Ebonite	1.14	0.80	Bismuth	9.82	0.075
Woolcloth	....	0.76	Silver	10.5	0.070
Celluloid	....	0.76	Lead	11.38	0.055
Whalebone	....	0.74	Palladium	11.3	0.053
Silk	....	0.74	Mercury	13.56	0.044
Cotton	....	0.70	Gold	19.36	0.030
Charcoal	....	0.63	Platinum	22.07	0.020
Starch	....	0.60	Ether	0.713	1.37
Sugar	1.61	0.60	Petroleum	0.836	1.28
Bones	1.9	0.56	Alcohol	0.793	1.22
Magnesium	1.74	0.50	Amylalcohol	.....	1.20
Coke	....	0.48	Olive Oil	0.915	1.12
Glue	....	0.48	Benzol	0.868	1.00
Sulphur	1.98	0.47	Water	1.00	1.00
Lead Ointment	....	0.40	Hydrochloric acid	1.260	0.86
Aluminum	2.67	0.38	Glycerin	1.240	0.76
Talcum	2.6	0.35	Bisulphide of carbon	1.293	0.74
Glass	2.6	0.34	Nitric acid	1.420	0.70
Chalk	2.7	0.34	Chloroform	1.525	0.60
Antimony	6.7	0.126	Sulphuric acid	1.841	0.50

[1] The above table for the relative transparency of equal thickness of various substances (water = 1) is due to Batelli and Garbasso.

There is more or less danger attending the diagnosis of magnetic foreign bodies in the eye by the use of this instrument because of injury that may be inflicted by the application of too much force in a direction not the most favorable for the removal of the foreign body. Traumatism to retina, ciliary body, lens, and iris may result which might be avoided if the operator was aware of the exact location of the foreign body.

X-rays.—The *x*-rays are applicable to all foreign bodies that are opaque to the rays (see table on page 615). The degree of opacity varies with the density of the metal and glass.

Toleration.[1]—This depends on a number of things: (1) Nature of foreign body; (2) size; (3) position; (4) condition, whether septic or not; (5) chemical composition; (6) whether it becomes encapsulated or remains free.

Lead and glass are tolerated best. Copper is the most dangerous. It has been shown (Leber) that copper may produce suppuration by the irritation to the tissues alone without the presence of microörganisms. If the foreign body is small, non-infectious and non-irritating, if it is situated in the lens, vitreous or retina (sometimes in the iris), it may remain many years without grave disturbance to the eye or to the vision, particularly if it becomes encapsulated. Noyes reports having seen a small piece of iron in the iris where it had remained without reaction for nineteen years. Ranlin[2] narrates a case of a man whose eye had retained a chip of copper for twenty years without inconvenience. At the end of this time the copper was extruded spontaneously through the cornea. Spontaneous extrusion of foreign bodies is not very uncommon. Particles of copper (percussion cap), glass, and stone have been observed to escape in this way.

If the irritation following the entrance of the foreign body subsides it may be followed by insidious inflammatory processes, as cyclitis, chorioidal and retinal exudation, or chemical changes seriously affecting the tissues of the eye (siderosis[3] from iron, changes affecting lead and copper the exact nature of which is not fully understood). Many cases have been observed in which the foreign body has been tolerated for a time, but gradual loss of vision has eventually developed and complete blindness supervened. In the light of these observations it is best to remove foreign bodies from the eye in all recent cases, unless the body be small, aseptic, and non-metallic, and in all cases in which there is the least evidence of inflammatory or degenerative reaction.

Treatment.—Removal.

[1] Wirtz, Inaug. Dissert., Strassburg, 1904.

[2] Ann. d'oculist., cxviii, p. 287.

[3] Eisenberg, Arch. of Ophth., xxxi., No. 2, reports that among 53 cases of injury with splinters of iron observed in the Geissen Clinic, evidences of siderosis were manifest in 14. The foreign body lay almost always in the vitreous. In all the vision was seriously damaged. In 4 cases a brownish discoloration of the cornea appeared, but never before the lapse of nine months. The iris was discolored in all cases, greenish or brownish. The lense was cloudy in all with one exception, but only in 7 cases was a yellowish or brownish discoloration observed. In 3 cases the vitreous contained opacities; in 5 there were chorioretinitic changes; in 5 hemeralopia, and in 3 detachment of the retina.

Epibulbar Growths.—Of the neoplasms that develop on the exterior of the globe, the principal ones are sarcoma and epithelioma. These have been described in the chapter on Conjunctiva, Cornea, and Sclera.

Intra-ocular Entozoa.—Cysticercus and hydatid cysts are the most common. (See Retina and Vitreous.) Filaria sanguinis hominis and Tenia trichinosis have been observed, the former in the anterior chamber, the latter beneath the retina and in the vitreous. J. Hirschberg[1] reports 32 cases of trichinosis. He succeeded in obtaining lasting results.

The parasites that have been observed in epibulbar tissue are cysticercus, echinococcus, and Filaria loa. They do not seriously affect the globe. Their removal has been discussed in the chapter on the Orbit.

[1] Berlin. klin. Woch., 1892, 325.

CHAPTER XXIV.

THE ORBIT.

ANOMALIES OF THE ORBIT.

Congenital Anomalies.—The orbits may be congenitally increased or decreased in number, under which conditions they are usually malformed.

Congenital Defects.—Congenital defects of all degrees in the formation of the orbits are met with, due (1) to the shape of the skull, as in oxycephalus or acephalus. In oxycephalus the orbits are more shallow than normal because of a more oblique position of the greater wing of the sphenoid and a shortening of the roof of the orbit. In acephalus the roof of the orbit is shortened, the lower margin occupying a plane anterior to the upper margin. (2) Due to intracranial pressure, as in congenital hydrocephalus interna and externa. In these cases the orbit is more shallow than normal. (3) Due to defects in the orbital walls and the prolapse of cerebral tissues into the orbit, meningocele and encephalocele; these may be bilateral. In the first the meninges of the brain prolapse into the orbit, the sac being filled with cerebrospinal fluid; in the second the sac contains brain tissue. The tumor may occur at a defect in the roof of the orbit between the ethmoid and frontal bones, when the tumor pushes the globe forward, downward, and outward, and may present above the inner canthus, or the tumor may occur at the apex of the orbit, coming through an enlarged sphenoidal fissure or an opening between the lesser wing of the sphenoid and the orbital plate of the frontal bone. These tumors may be reduced, and when reduced the edge of the bony aperture through which they came may be felt. Pulsation may be felt, and in some cases a faint bruit may be heard on auscultation. These characteristics serve to differentiate this form of tumor from dermoid tumors, sebaceous cysts, and nevi for which they might be mistaken. (4) Due to a diminution in the volume of the contents of the orbit, as in microphthalmos and in anophthalmos. In these conditions the base of the orbits is usually smaller than normal, the vertical diameter being less than the horizontal diameter. (5) Due to an increase in the volume of the contents of the orbit, as in congenital buphthalmos or megalophthalmos, in which conditions the anterior third of the orbits is somewhat enlarged.

In the development of monstrosities the orbits may be increased or decreased in number. Double-headed monsters present four orbits. A double-faced monster may possess four, or, if the duplicature is not perfect, the two median orbits may be forced into one in which case the

middle orbit is elongated laterally. In cyclopia there is but one orbit and one eye. The orbit is quadrangular, usually shallow, and is situated at the root of the nose. It is in some cases overhung by a proboscis.[1] The eyeball may be perfect or may show various degrees of doubling.[2]

Acquired Anomalies.—There are a number of conditions which cause a change in the form of the orbit after birth, not due to disease of the walls. In disease of the ethmoid producing ectasia of the laminæ papyraceæ, as excessive development of polypi, malignant tumors, or osteomata, the orbits may be narrowed laterally. In hydrops or pyemia of the frontal sinuses the orbits may be compressed from above. Malignant growths developing in the antrum may displace the floor of the orbit upward and cause displacement of the globe upward and outward. The sphenoid sinus seldom compresses the orbital cavity. With the growth of the skull after birth the orbits expand, not in direct proportion to the increase in the size of the globe, but in a slightly greater proportion. If the eyeball is destroyed or removed in early childhood the orbit does not develop to quite the extent of its fellow, but the difference in the size is not great, nor is the asymmetry of the face because of a reduction in size of the orbit marked; the influence on the orbit from loss of an eye in early childhood has been overestimated by many writers. If enucleation is desirable in a very young child it should not be delayed because of fear of arrest in the development of the orbit; the growth of the orbits is dependent on the growth of the bones of the orbit, and this is not greatly influenced by loss of a part of the contents of the orbit some months or years after birth.

In a patient aged twenty-three years that came under the writer's observation, the left eye was lost at the age of two months; the difference in the diameters of the orbital openings was 1.5 mm.

DISEASES OF THE ORBITS.

Diseases of the Bony Walls.—Periostitis.—Inflammation of the periosteum should be classified according to the microbic cause. There can be no true ostitis without the presence of microörganisms. The hyperplastic reparative processes following injury to the periosteum should not be classed as inflammation.

Etiology.—The causes are the presence of a pyogenic germ, staphylococcus or streptococcus, or a pyogenic bacillus, syphilis, tubercle bacillus, or actinomyces. Periostitis may be general or may be localized.

Periostitis Due to the Presence of Pyogenic Bacteria.—Pyogenic germs may reach the periosteum through the blood current from a primary focus, as an osteomyelitis or phlegmon in some other part of the body and under favorable conditions produce a suppurative periostitis, or the germs may be carried directly into the periosteum by traumatism. The inflammatory process affects the periosteum and superficial layers of the underlying bone, frequently producing superficial or deep necrosis.

[1] Van Duyse, Arch. d'ophtal., xviii, 8, 9, p. 451, 581.

[2] Bullot, Ann. d'ocul., cxx, p. 43.

Symptoms.—Localized periostitis due to pus germs, if acute, is accompanied by pain referable to the part affected and the area of distribution of the branch of the fifth nerve involved, swelling and chemosis of the conjunctiva near the site of the disease, and swelling of the lids. Pressure on the eyeball backward into the orbit and pressure on nerve trunks emerging from the orbit will, in many cases, elicit pain.

In general orbital periostitis the symptoms enumerated are more intense, and it may be difficult to make a differential diagnosis between this affection and orbital abscess or orbital phlebitis. General orbital periostitis due to pus germs may produce extensive orbital abscess.

Systemic Symptoms.—There is generally a rise of temperature and the pulse rate may increase to some extent; but, as a rule, the systemic disturbance is not great.

Syphilitic Periostitis.—Periostitis from this cause may be a manifestation of the second stage of syphilis when it appears as periosteal nodes affecting the margin of the orbits, or a very slight thickening of the periosteum with rheumatoid pains more severe at night, with a tendency to disappear, as do the so-called secondary manifestations of syphilis; but much more frequently it appears as gumma and as tubercular nodules. Gummatous periostitis may present soft swellings which apparently fluctuate on palpation, but really do not contain fluid. Gummatous syphilitic periostitis may affect the orbital walls at any point, but is apparently more frequent at and near the apex and at the inner margin of the orbit, involving the lachrymonasal canal. Fistulæ may form; these leave scars less indrawn than those due to tuberculosis. Gummatous periostitis occurring in the apices of the orbits may impair the vision by pressure on the optic nerves. Paralysis of ocular muscles with consequent diplopia may be produced. Although frequently unilateral, it may be bilateral and almost, if not quite, symmetrical.

Fig. 288

Periostitis of orbital margin. (Posey and Wright.)

Diagnosis.—This is made largely by exclusion and by the presence of other manifestations of syphilis.

Tubercular Periostitis.—This affects the malar margin of the orbit most frequently. The presence of the tubercle bacilli is followed by the invasion of leukocytes and the development of a mass of cells which are denser in some parts than in others, and a composite conglomerate tubercular mass is the result. The bone as well as the periosteum is involved, leading to a honeycomb appearance of the bone with more or less extensive death. The periosteum breaks down and the adjacent tissues become tuberculous. Ultimately a tubercular abscess develops, followed by a spontaneous opening through the skin and the establishment of a fistulous tract. The process is attended by relatively little pain, and is slow in development. It may be secondary to tubercular disease in other parts of the body. The orbital bones may be affected at more than one point.

Diagnosis.—This may be made (1) by the very slow development of the condition; (2) by the absence of much pain; (3) by the production of a "cold" abscess, and (4), most important, by the presence of the tubercle bacillus.

Results.—Periostitis attended by destruction of periosteum or bone is always followed by extensive cicatrices which may produce pronounced deformities of the lids or, involving ocular muscles, limit the movements of the globe.

Fig. 289

Tubercular periostitis with cicatricial contraction.

Treatment.—In acute periostitis the treatment consists in making free openings, curetting away the necrotic tissues, cleansing thoroughly with an antiseptic solution, then establishing free drainage.

In syphilitic periostitis the conditions will rapidly disappear under vigorous antisyphilitic treatment, systemic and local, when local treatment can be applied, that is, when the manifestation is sufficiently near the surface.

Tubercular periostitis is best treated by thoroughly removing the tubercular tissues when practicable. Much can be done by a full, nourishing diet, and by keeping the parts, if suppurating and discharging, scrupulously clean. Injections of tuberculin (T. R.) will be of great value in the greater number of cases.

Leontiasis Osseous.—This rare affection sometimes involves the bones of the orbits, converting the margins of the orbits into a greatly enlarged, spongy mass, and greatly narrowing the base of the orbits.

Caries and Necrosis.—These conditions, which are rare, usually develop as a result of periostitis, but an osteomyelitis may develop in the thick, bony margin of the orbit primarily, the periosteum being involved secondarily. Injury to the margin of the orbit, often in the form of bruises, which under normal conditions would be of no consequence, is the predisposing cause in some of the cases at least. The microörganism which determines the disease is carried to the bruised part by the blood current from some distant focus and the process is established. In these cases the sequestra are not large, the bone usually breaking up into a granular mass and coming away with the purulent discharge. One or more sinuses form. If left to themselves these cases pursue a very protracted course, extending over years, and finally heal, producing indrawn cicatrices with retraction and sometimes eversion of the eyelid.

Syphilitic Necrosis.—Syphilitic necrosis of bone may extend from the nose to the orbital plate of the ethmoid and to adjacent bony structures

and cause extensive death of the osseous tissue. Quite large sequestra may develop. Death of the bone develops very slowly, is attended with some swelling of the soft tissues and the maintenance of a purulent discharge which may pass into the nose, or escape by fistulous tracts opening on the cutaneous surface of the lids near the inner canthus.

Treatment.—The treatment consists in thoroughly removing all carious bone after free incision, and the establishment of free drainage.

The dyscrasiæ responsible should be ascertained and appropriate systemic treatment instituted.

Hyperostosis.—This consists in an increase of the thickness of bone, and rarely affects the bones of the orbit. Asymmetrical development of the bones of the orbit may produce a marked difference in the position of the orbits, leading to quite a marked deformity, but this does not, as a rule, affect the movements of the eye and does not require corrective treatment.

Cellulitis (*Phlegmon of the Orbit*).—Inflammation of the cellulo-adipose tissue of the orbit varies very greatly in intensity. It may be chronic, subacute or acute, subsiding without a trace or resulting in profuse suppuration. The process may be unilateral or bilateral.

Etiology.—The direct introduction of pathogenic or pyogenic micro-organisms by penetrating wounds; invasion of orbital tissue from a suppurating periostitis, a purulent frontal, ethmoidal or sphenoidal sinusitis; extension from a pustule of the lid or mucous membrane of the nose, from a dacryocystitis or facial erysipelas; a metastatic process originating from a general pyemia or from some focus of purulent inflammation in a remote part of the body. Alveolar abscess has been regarded as the cause in some cases; suppurating inguinal glands (bubo) (Würdemann) may produce it. Scarlet fever as a cause has been reported.[1] The principal microörganisms found are the staphylococcus pyogenes and the streptococcus. The anthrax bacillus (Boucher) may be a cause, as may also the Bacterium coli communis (Lösser).

Symptoms.—In the mild cases the phlegmon may develop slowly. There may be but little constitutional disturbance. The eyelids are puffy, the ocular conjunctiva swollen, and there is exophthalmos. Movements of the eyeball may be limited. Vision is usually reduced. The retinal vessels are reduced in size and there may be optic neuritis. Pressure on the globe elicits pain.

In the *acute* form the constitutional symptoms are marked. The cellulitis may be ushered in with a chill, accompanied and followed by fever and headache. The eyelids, tissue about the lids, and the conjunctiva become much swollen. The eyeball protrudes and soon becomes fixed. The pupil, at first small, becomes moderately dilated. Vision is rapidly reduced and may be entirely abolished. A greater or less degree of optic neuritis develops, with diminution in the size of the central artery of the retina apparently due to pressure. There are tortuosity and enlargement of the veins and often retinal hemorrhages

[1] Antonelli, Rec. d'opht., May, 1905.

more or less diffuse. The pain is a prominent feature at the beginning, becoming more severe as the inflammation proceeds until the pressure from retained exudation is relieved. At the end of three to six days the tissues, usually at the upper inner angle of the orbit, bulge and fluctuation can be detected. If the process is permitted to take its course a spontaneous opening at the bulging part occurs and pus is evacuated. Gradual recovery follows. The pain subsides in great part as soon as a free opening is made and the pus is permitted to escape.

Fig. 290

Orbital cellulitis resulting in abscess.

Diagnosis.—The condition may be confounded with an extensive orbital periostitis, orbital thrombophlebitis, tenonitis and panophthalmitis. In periostitis a tender elevation as of a thickened orbital wall can sometimes be determined by digital examination. Movements of the eyeball are not apt to be so limited as in orbital cellulitis. The affection is ordinarily not so acute. Orbital thrombophlebitis is accompanied by very marked venous stasis manifest in the veins of the ocular conjunctiva particularly. If the retinal veins can be seen, they will be found much enlarged and tortuous, and there will be numerous retinal hemorrhages. In tenonitis the swelling of the lids is very slight. Movements of the globe are painful, but are not so limited as in well-developed cellulitis. In panophthalmitis the suppurative process is limited to the globe ordinarily. The nose and accessory sinuses should be examined in all cases.

Complications.—The process may extend to the tissues of the brow and cheek. Perforation of the globe may occur and panophthalmitis result. Extension by way of the lymphatics and sheath of the optic nerve to the meninges of the brain may produce a fatal meningitis. Abscess of the frontal lobe may develop. An opening into the ethmoid cells may be formed and the pus evacuated into the nose. An orbital phlebitis, with extension to the cavernous sinus may result, causing death.

Prognosis.—In the milder non-purulent forms, as in erysipelatous orbital cellulitis, recovery may take place without leaving a trace and without impairment of vision. In limited purulent periostitis this may also occur, but in all severe cases, whether suppurative or not, great impairment of vision and often total loss of vision results. In three cases of double orbital cellulitis observed by the writer, total blindness occurred in two and there was marked impairment of the vision of the left eye in the third. Death by extension to the brain occurs in quite a large percentage of the cases.

Treatment.—Supportive measures in the form of improved nutrition, the administration of iron strychnine and quinine, should be employed.

If there is any evidence of pus by palpation or by fluctuation of temperature, deep incisions should be made. These can be made with little risk to important structures in the inner third of the orbit and the lower outer half If pus is found it should be thoroughly evacuated, the cavity irrigated with normal saline solution or some non-injurious germicidal solution, and free drainage should be established. Injections of ten to thirty minims of a solution of the bichloride of mercury, 1 to 1000, deep into the tissues of the orbit in one to three places, may be made with advantage (Bull) in cases of orbital cellulitis whether pus has appeared or not. The writer has practised this procedure with good results in a few cases. In erysipelatous orbital cellulitis it is only necessary to support the system and treat the erysipelas. In cases of involvement of the accessory cavities of the nose, it frequently occurs that the disease originates from the involved cavities, and in the treatment competent operative measures must be employed to eradicate the source of infection.

Orbital Abscess.—This is very closely allied to orbital cellulitis, but differs in that the abscess may develop without much inflammatory reaction and without great involvement of the adjacent orbital tissues. The process is more circumscribed than cellulitis. Borthern[1] reports the case of a girl, aged fourteen years, who suffered from influenza. On the sixth day the lids of the right eye became swollen; the swelling disappeared in a few days. The right eye protruded, diverged, and its mobility was limited. A fluctuating tumor developed near the ligamentum palpebrarum internum; this was incised, pus was evacuated, and recovery followed rapidly.

Orbital Thrombophlebitis.—This is usually a septic condition primarily affecting the veins of the orbit in some cases. It may extend to the cavernous sinus and affect other sinuses of the brain. Thrombophlebitis may begin in the cavernous sinus and extend to the veins of the orbit on one or both sides. Traumatic non-infectious orbital thrombosis affecting the cavernous sinus on one side and extending to the other side has been reported by Knapp.

Etiology.—Intracranial suppurative processes; purulent otitis; any infected lesion in the area drained by the ophthalmic vein or its branches, as pustules on the eyelids, face or nose (de Schweinitz), traumatism, erysipelas.

Symptoms.—If the phlebitis originates from a previous orbital cellulitis the symptoms of the cellulitis (see p. 622) are deepened and in addition those of thrombosis of cerebral sinuses are added. When the process extends from the cavernous sinus the symptoms of sinus infection precede the orbital symptoms. There are chills, marked fluctuations in the temperature, severe cephalalgia, often delirium, with coma preceding death. The heart action is depressed. The frequency of the pulse is diminished if there is great meningeal involvement.

The orbital symptoms in cases of secondary involvement are, first, those of very marked venous thrombosis, marked swelling of the lids and

[1] Zeh. klin. Monatsbl. f. Augen., xxix.

conjunctiva, exophthalmos, increasing as the affection advances, fulness and tortuosity of all visible veins; increase in lachrymation at first, followed by decrease and comparative dryness of the conjunctiva. If the fundus can be seen, the veins will be found engorged and tortuous, the arteries small; numerous dark hemorrhagic spots scattered over the retina. The cornea becomes hazy and anesthetic, the iris dilated, sluggish or immovable. Vision is soon abolished. There is swelling of the tissues of the temple and about the ear.

Diagnosis.—It is difficult to differentiate orbital thrombophlebitis from orbital cellulitis, but a careful review of the history of the case in connection with the symptoms of cerebral involvement will usually give sufficient data to make a diagnosis.

Prognosis.—This is very grave, except in cases due to erysipelas. In these cases the thrombosis of the veins is frequently confined to the orbit and recovery without impairment of vision takes place. Orbital thrombophlebitis due to other causes is fatal in almost all cases.

Treatment.—Supportive measures may be employed. But little can be expected from treatment.

Tenonitis.—Inflammation of Tenon's capsule is a rare affection.

Etiology.—Infectious diseases, chronic gonorrhea, influenza, diphtheria, typhoid fever, traumatism, as after tenotomies or other operations on the ocular muscles, rheumatism and gout.

Symptoms.—It is characterized by an annular swelling and some injection of the ocular conjunctiva with chemosis which may not be uniform. The bulging of the ocular conjunctiva is usually less over the insertion of the recti muscles. The eyelids are also slightly edematous. Pressure on the globe and movements of the eyeball are painful. There is perhaps a very little exophthalmos. The vision is but little, if at all, affected. Lachrymation is increased. Cornea clear. The affection is confined to one eye as a rule.

The symptoms develop relatively rapidly, reach their height in from three to five days, then decline, recovery taking place without a trace in from two to three weeks.

Diagnosis.—In the early stage it is easy to confound this condition with commencing orbital cellulitis. In tenonitis the edema about the eyeball is more marked and the exophthalmos not so marked as in orbital cellulitis. The systemic and local symptoms are not so severe. Vision as a rule is not disturbed. As the disease progresses the diagnosis becomes easier. It will scarcely be confounded with panophthalmitis, as in the latter condition the interior of the eye is profoundly involved. Tenonitis may complicate panophthalmitis.

Treatment.—Hot applications. The treatment of any systemic condition that may stand in a causative relation and the use of absorbents, as potassium iodide and mercury, the latter in small quantities. If pus should form it should be liberated. Injections of antiseptic solutions into Tenon's capsule for controlling the inflammation are of doubtful value, since the process is usually self-limited, and healing without adhesions to the globe is the rule.

Hemorrhage.—**Etiology.**—Spontaneous hemorrhage into the orbital tissue is rare, but it may occur in conditions of hemophilia, purpura hemorrhagica, scurvy, as a result of violent coughing or sneezing, deterioration of blood-vessels, or from rapidly developing orbital tumors. Traumatism is the principal cause of hemorrhage into orbital tissue. This may result from direct injury, from tearing of periosteum or from injury to other than periosteal blood-vessels accompanying fracture of orbital walls from blows on the orbital margins or other parts of the skull.

Symptoms.—The escape of blood may take place beneath the periosteum as well as into the orbital tissues. The blood finds its way along avenues of least resistance to the anterior part of the orbit and usually appears beneath the conjunctiva at the outer inferior angle. In cases of subperiosteal hemorrhage no appearance externally may occur, evidence of hemorrhage manifesting itself only by pressure on the optic or some other orbital nerve, interfering with its function. The quantity of blood is usually not sufficient to interfere with the movements of the globe, but may be so great that the orbit will be much distended, very pronounced exophthalmos being produced. Great pain may accompany the presence of such hemorrhage. Hemorrhage if due to hemophilia or purpura, and hemorrhage from injury may recur, but recurrence after injury is rare after the first forty-eight hours.

Diagnosis.—As an aid to diagnosis of fracture of the walls of the orbit it is of value, but is not infallible, as a number of autopsies after injury have demonstrated intra-orbital hemorrhage without fracture (Shoemaker).

Course.—The course of intra-orbital hemorrhage is to complete absorption in from four to six weeks in the greater number of cases. In a very few instances a large clot becomes encysted and forms the so-called blood tumor.

Results.—The results of intra-orbital hemorrhage are, as a rule, benign. If the function of a motor nerve is impaired, full recovery usually occurs in about six weeks. If the function of the optic nerve is impaired it may be permanent, but in many cases full recovery takes place.

Treatment.—Nothing is required unless the pressure is so great that pain is occasioned and the integrity of the optic nerve and globe is threatened. A free incision in the lower outer angle of the orbit may then be made, entering through the skin of the lid or the conjunctiva. Such an opening should be kept free for twenty-four to forty-eight hours. If the cornea is exposed by excessive exophthalmos it should be protected.

Emphysema of Orbit.—See Lids, page 185.

Injuries to Walls of Orbit and to Contents of Orbit Other than Globe.—**Fracture of Walls of Orbit.**—There are three types of fracture of the walls of the orbit.

1. Fracture of the margin of the orbit which is caused by direct blows or by direct pressure on the margin of the orbit. The diagnosis is made by the deformity occasioned, by the mobility of the fragments, ascertained by digital examination, and by pain on pressure.

2. Fracture of the walls of the orbit followed by emphysema. This implies an opening into one of the adjacent pneumatic cavities, antrum, ethmoid, or sphenoid cells or frontal sinus (see page 185). This may be produced by a penetrating wound entering by the skin, conjunctiva or by the mouth or nasal cavity, or by a blow or pressure on the upper part of the face. The diagnosis is, of course, apparent on the production of the phenomenon of air in the orbital itssue.

3. Fracture through the apex of the orbit, diagnosed by the history of a blow or fall on the head, resulting in interference with the function of the optic nerve or some other orbital nerve, with or without subsequent visible evidence of hemorrhage into the orbit. Fracture at the apex of the orbit involves the optic foramen in a majority of the cases. In 88 cases of fracture at the base of the skull in which autopsies were made,[1] 80 involved the roof of the orbit. In 54 cases (60 per cent.) the fracture extended into the foramen opticum. Blows on the frontal bone are most apt to produce fracture into the foramen opticum on the side on which the blow is received. The fracture may affect the ethmoid and sphenoid bones, producing hemorrhage into the nasal cavity. It may extend into the temporal bone with rupture of the membrana tympani, causing hemorrhage from the ear. When this fracture occurs the optic nerve is usually compressed or torn across, producing blindness. In case of laceration or profound pressure on the optic nerve the blindness is immediate and permanent. In case of gradual pressure by escaped blood the blindness is not immediate but is produced in a few minutes or hours, may be partial or complete, and may be recovered from to a great extent. If the injury to the optic nerve is confined to the nerve at the apex of the orbit or if the ophthalmic artery is not lacerated or obliterated by pressure, there is no change in the ophthalmoscopic appearance for the first few days after the injury, but pallor of the optic disk is usually discoverable in two weeks, often in a shorter time.

Symptoms.—The symptoms briefly are a dazed or unconscious condition for some minutes after the receipt of the blow, immediate blindness on the affected side, bleeding from nose or ears or both, and in some cases the dripping of a colorless fluid from nose or ears, evidence of intra-orbital hemorrhage in some but not in all cases.

Impinging blows on the superior maxilla, as from the button of a foil, end of a cane, etc., may cause paralysis of the abducens, one or more of the muscles supplied by the third nerve, and hemorrhage in the tissues at the apex of the orbit, apparently by fracture near the apex. In a case observed by the writer, a young man while fencing received a blow from a foil, the button of which impinged on the lower margin of the orbit just above the exit of the inferior orbital nerve. A few hours later he experienced diplopia from paralysis of the abducens on that side, which on examination sixteen hours afterward was found to be almost complete.

Full recovery ensued in six weeks. Except a shallow skin wound, there

[1] Van Holder, referred to by Callan, N. Y. Eye and Ear Inf. Reports, vol. i, p. 2.

was no other visible effect of the blow. Cheney[1] reports a case of a similar wound which resulted in complete ptosis. This was recovered from in a few weeks. In the writer's case the lesion was apparently a hemorrhage, possibly subperiosteal, which exerted pressure on the trunk of the sixth nerve as it passes the sphenoidal fissure. Cheney attributes the ptosis in his case to pressure on the branch of the third nerve supplying the levator at or near the sphenoidal fissure.

Fracture of the walls of the orbit by the passage of bullets or by puncture may produce lesions of varied character. Thrust wounds that cause fracture of the roof, upper inner angle and apex of the orbit are particularly dangerous to life on account of the cerebral inflammatory processes that they are very liable to set up.

Treatment.—Little can be done so far as the orbit itself is concerned to remedy defects caused by fracture of the orbital walls. A displaced portion of the orbital margin would be replaced by restoration of the soft parts to their natural position, maintaining them in position by means of adhesive straps. Necrosis of bone seldom occurs.

Wounds to Contents of Orbit.—These are met with of all degrees of severity. There is danger of infection by the introduction of pyogenic or pathogenic germs at the time of the injury or by their entrance afterward. The infection may be followed by inflammation which may extend to the brain.

If the optic nerve is cut across or crushed back of the entrance of the central retinal vessels, there may not be any immediate intra-ocular changes, but if the central retinal vessels are injured or if there has been very violent traction on the globe at the time of injury, exudation into the retina, hemorrhages and engorgement of veins may be present immediately after the injury.

Gunshot wounds of the orbit are not very uncommon. Distressing cases, of which the writer has seen two, are those in which the ball enters the orbit at the temple, rupturing or severely injuring one or both optic nerves.[2]

Treatment.—Wounds of the orbital tissue should be thoroughly cleansed, the opening being enlarged if necessary. Antiseptics, of which the most serviceable is the bichloride of mercury, should be freely used. If an ocular muscle is torn from its attachment to the globe (cut across), it should be caught up, if possible, and reunited by sutures.

Foreign Bodies in Orbit.—Foreign bodies that enter the orbit may produce serious effects, endangering life or impairing vision, or, if small

[1] Boston Med. and Surg. Jour., August 11, 1898.

[2] In one of the writer's cases a young man attempted suicide by shooting. The ball entered the right temple at about the middle of the orbit, emerging from the left temple near the roof of the orbit just behind the globe. The *right* optic nerve had apparently been severed and the *left* optic nerve injured with destruction of the central artery. The result was blindness in both eyes. Three days later the ophthalmoscope showed but little change in the fundus of the *right eye*. There were numerous retinal hemorrhages, diffuse exudation at the posterior pole, absence of arterial flow, tortuous and dark retinal veins in the *left eye*. In the second case a shot entered the left temple and lodged in the right antrum, cutting the optic nerve on the left side, and producing rupture of the chorioid below and to the inner side in the right eye.

and aseptic, may remain in the orbit many years without giving the least trouble. The *immediate* effects of the entrance of foreign bodies are as follows: (1) They may bruise, rupture or pass through the eyeball; (2) they may injure or sever the optic nerve; (3) they may penetrate the walls of the orbit; (4) the hemorrhage produced may be excessive. The *secondary* effects are (1) inflammation following infection which may extend to the brain; (2) suppuration about the foreign body resulting in the production of fistulous openings. The toleration of foreign bodies in the orbit in some cases is quite remarkable. Lawson[1] narrates a case in which a piece of a twig 47 mm. long remained in the orbit of a child seven weeks. Holmes[2] reports a case in which a knife blade 38 mm. long and 8 mm. wide remained unsuspected in the tissues of the orbit thirty-two years.

Treatment.—The track through which a foreign body enters the orbit is often sinuous, as pointed out by Noyes. When the foreign body enters it strikes the tissues attached to the globe and rotates the globe in the direction of its passage. Afterward the globe and attached tissues return to their natural position, distorting the canal of entrance. This makes it difficult to follow the foreign body with a probe. As a rule, probing is unnecessary and may do harm. It is permissible only in the cases in which the foreign body is a piece of wood or other substance that offers no obstruction to the passage of the Röntgen rays. All metallic substances, also stone and glass, may be skiagraphed and their exact location and approximate size ascertained. This should be done in all cases before any attempt at removal is made, unless the foreign body can be seen. After locating the foreign body it may be cut down upon along the best possible route and removed, if it is thought advisable. Small pieces of iron, lead, stone, or glass, if deeply embedded and not producing symptoms, may be permitted to remain. Pieces of wood that have entered the orbit should be removed if possible. If not found, the piece of wood may become encapsulated in the tissues and give no trouble, but not infrequently such a foreign body causes some suppuration and the development of one or more sinuses. If these form, the site of the foreign body can be quite readily determined. The removal of magnetic foreign bodies may be facilitated by use of the magnet. The giant magnet is particularly serviceable.

Luxation or Dislocation of Eyeball.—These terms are used to designate the protrusion of the globe beyond the eyelids without serious injury to the tissues attached to the globe. The muscles and optic nerve are stretched, but not necessarily torn or detached from the globe. The lids close spasmodically behind the globe and a condition resembling paraphimosis results. This accident occurs spontaneously in excessive exophthalmos, as in some cases of exophthalmic goiter, in persons with shallow orbits and prominent eyeballs. It may be produced by the insertion of a lid speculum, by blows on the margin of the orbit, and in instrumental deliveries.

[1] Disease and Injuries of the Eye, sixth ed., p. 508.

[2] Am. Jour. of Ophth., May, 1900.

Treatment.—The eyeball should be gently replaced. In cases of *spontaneous* luxation the palpebral fissure should be shortened by performing tarsorrhaphy. In cases of *forcible* luxation, after returning the eye to its normal position, it should be bandaged until the stretched tissues can resume their normal tone. It may sometimes occur that on account of swelling or intense spasm of the lids, reduction of the luxation becomes very difficult. Lid retractors may be employed in such cases and canthotomy may be necessary. If the injury is recent, cold compresses may be employed after the dislocation is reduced.

Avulsion of Globe.—This term is employed to indicate the removal of the globe from the orbit by force with severance of the optic nerve and all, or almost all, of the extrinsic muscles. The globe is not infrequently ruptured at the same time. "Gouging," as indulged in by the insane and by fighters, is the most frequent cause. It has been produced by falling forward on a blunt object, by a blow from a cow's horn, etc.

Treatment.—When seen very early, provided the wound is not infected, the globe, when not entirely detached from the tissues of the orbit, may be restored to its normal position and the torn parts sutured in the hope of obtaining a good cosmetic effect. The wound should, of course, be thoroughly cleansed and rendered aseptic. In the greater number of cases complete removal of the globe is necessary.

Tumors of Orbit.—In this connection the primary tumors of the orbit and those that encroach on and invade the orbit from all sources except the eyeball, optic nerve, lachrymal gland, and the eyelids will be considered.

Primary tumors of the orbit are not common. Of 100,000 cases of eye disease treated at the New York Eye and Ear Infirmary during the years 1897 to 1900 inclusive there were 24 cases of tumor of the orbit.

The tumors met with in the orbit may be (*a*) *primary*, springing from the contents of the orbit, from the walls of the orbit, or (*b*) *secondary*, invading the orbit from neighboring structures, or (*c*) *metastatic*, namely, secondary to similar growths in other parts of the body. The growth may be malignant or benign. Malignant growths[1] develop more rapidly than benign growths. They infiltrate surrounding tissues and may produce metastases. Benign tumors grow slowly, are encapsulated, do not invade surrounding tissues, and produce abnormal conditions by pressure.

Symptoms.—Exophthalmos is the most constant and conspicuous symptom. The direction of the protrusion depends on the location of the growth. If the eyeball is pushed directly forward the growth is probably situated within the muscle cone. The motility of the eye is interfered with in some or all directions. Diplopia is a fairly early symptom, depending on the interference with the muscles and on the exophthalmos in some cases. Diminution in vision develops slowly,

[1] The term "malignant" is also employed to indicate those growths which have a tendency to recur if any vestige of the growth is left after attempts at removal, as in angioma or angiocarcinoma, even when there is no recurrence when the growth is completely removed.

except in those cases in which the central retinal vessels or the optic nerve are early involved. Ophthalmoscopically the fundus may be normal, or optic neuritis with retinal hemorrhage and exudation may be present. Lachrymation increases in the early stage of the exophthalmos. In cases which involve the branches of the fifth nerve, severe neuralgic pain may develop. After the tumor has developed sufficiently, its anterior aspect may be felt at the margin of the orbit on digital examination. Eventually the eyeball is forced outside of the lids if the tumor is allowed to grow and the changes in cornea and conjunctiva incident to desiccation take place.

Fig. 291

Sarcoma of orbit. Eyeball pushed forward on apex of tumor.

Prognosis.—This must be guarded in all cases of malignant growths. As a rule, it may be said to be unfavorable. In non-malignant growths the prognosis is favorable in all cases in which little damage has been done by the pressure of the growth and in which removal can be accomplished without additional injury.

Treatment.—In all cases of tumor of the orbit in which the character of the growth is not determined, a short but efficient course of antisyphilitic treatment should be employed for the purpose of eliminating syphilis. If this does not cause the growth to diminish in size and the symptoms to abate, it should be discontinued and surgical measures resorted to. If there is doubt regarding the character of the growth, whether solid or cystic, an aspirating needle may be introduced to determine the question. If, when the tumor is exposed, it is found to be contained in a well-defined capsule, the dissection need not include tissues outside of the encapsulated tissue, as with few exceptions the neoplastic tissue is entirely contained within the capsule, and if the entire encapsulated mass is removed the growth will not recur. In cases in which the neoplasm invades other tissues it is necessary to remove the entire contents of the orbit, even to the periosteum. After the removal of a malignant growth, if there is any indication that neoplastic cells still remain, or if the wound is slow in healing, or if suspicious areas appear in the cicatrix, a course of *x*-ray

treatment may be employed. Radium may be of value in some of the cases.

Angioma.—A number of forms are recognized: (*a*) Hemangioma (capillary angioma and cavernous angioma). (*b*) Lymphangioma. All are probably congenital. Capillary angioma (telangiectasia) is not common in the orbit. Cavernous angioma is met with not very infrequently. It occurs as a mass of dilated anastomosing vessels, usually with a thin capsule, probably originating in an extensive development of capillaries which causes a retardation of blood flow. Gradual dilatation follows which may be greatest on the arterial side, but usually affects the venous side most. The walls give way in places, forming large spaces or blood-channels (Parsons). The growth is of a bright red color when the dilatation affects arterioles most and is of a dark bluish red when the venules are most involved.

Hemangioma in the orbit causes proptosis. This will be increased if the individual assumes a prone position or does anything to increase arterial flow to the orbit or to impede venous flow from the orbit, such as crying, coughing, straining at stool, pressure on the internal jugular. Pressure on the eyeball or on the tumor will cause the proptosis to greatly diminish. In angiocavernoma a bruit can usually be heard by use of the stethoscope placed over the globe or at the temple. Hemangioma of the orbit may be associated with the same affection of the conjunctiva or skin of the lids. Hemangioma is seen most frequently in children. The growth may become quite fibrous, forming angiofibroma, or may develop lipomatous tissue producing angiolipoma. It is doubtful whether these tumors ever develop into malignancy. The angiofibromata are surrounded by a fibrous capsule. Hemangiomata tend to increase in size.

Lymphangioma is very rare as a tumor of the orbit. It consists of dilated lymph vessels. The tumor increases very slowly in size. All that have been observed have occurred within the cone of extrinsic ocular muscles.[1]

Treatment.—Telangiectatic growths occurring in the orbit are probably best treated by electrolysis. Needles attached to both poles are employed. Both needles are plunged into the growth, not close enough to touch each other and a current of from 4 to 7 milliampères is permitted to pass for one-half to two minutes. The process is repeated until the tumor has been pierced in all directions. From one to three sittings are necessary. Cavernous hemangioma may be dissected out without serious injury to other parts of the orbital tissue if the growth is situated well forward and is small. If large and deep the orbital contents may have to be sacrificed. Quite profuse hemorrhage is apt to ensue if the capsule is cut or ruptured. Tumors of this nature recur if any part of the growth is permitted to remain. The treatment of lymphangioma is excision.

Fibroma.—This form of tumor may spring from the periosteum, dural sheath of the optic nerve, or possibly from the tendons of the muscles.

[1] Wintersteiner, Graefe's Arch., xlv, p. 613.

Simple fibroma of the orbit is most rare. Benign tumors, which are made up largely of fibrous tissue but contain other tissue such as angiofibroma, lipofibroma, and implantation cysts with thick fibrous walls,[1] are more frequently seen. The case described by Mackenzie[2] approaches the simple fibroma as closely as any reported, but this tumor presented some small cystic cavities and contained some calcareous masses. Fibrous thickening of the periosteum following traumatism, nodular hyperplasia of the tendons of the ocular muscles, and thickening of the dural sheath of the optic nerve, producing a mass of considerable size, have been reported.

Fibrochondroma.—Tumors of this kind are very rare. Fromaget[3] describes a case. The tumor developed between the muscle funnel and roof of the orbit and reached the size of a large chestnut in eight months. Removal through the conjunctiva after splitting the outer commissure, with preservation of vision.

Lipoma.—Pure lipoma of the orbit is very rare. Lipomatous masses projecting into the tissues of the lid due to hyperplasia and hernia of orbital fat are more common. The tumors that have been reported as lipoma are congenital dermofibroma, angiolipoma, fibrolipoma. In these tumors the fatty tissue is usually secondary and adventitious (Parsons). Some cases have been reported in which the tumor was encapsulated and the fatty tissue was so greatly in excess of all other elements that the term lipoma was justified. Such a tumor was the one reported by Gruening.[4] In the discussion of this case encapsulated tumors of a similar nature were described by Holden and Knapp.

Symptoms.—Lipomata occur in adults, develop slowly without pain. They appear in the outer two-thirds of the orbit, produce soft elastic masses and cause displacement of the globe in proportion to the pressure exerted. They are not malignant.

Diagnosis.—This is made by means of the microscope.

Treatment.—Excision.

Lymphoma.—These neoplasms consist of a dense aggregation of leukocytes contained in a distinct capsule and traversed by scant, delicate connective-tissue trabeculæ. They are often symmetrical. A typical case is that of Arnold and Becker.[5] A number of apparently separate masses may occur in the same orbit (Axenfeld). They may be associated with lymphoid enlargements or tumors in other parts of the body, the neck in particular. Disturbances in the position of the globe may be occasioned. The tumor is benign.

Treatment.—Masses of this nature have been observed to become much reduced in size and to disappear on the administration of arsenic, mercury, and the iodides. If medicine has no appreciable effect, surgical measures must be employed.

These tumors must not be confounded with the symmetrical enlargement of the lachrymal glands that accompany Mikulicz's disease. (See chapter on Lachrymal Diseases.)

[1] Schiess-Gemuss, Graefe's Arch., 1868, xiv, 1.
[2] Diseases of the Eye, 1855, p. 336.
[3] Arch. d'opht., xxii, 6, p. 380.
[4] Trans. Amer. Ophthal. Soc., 1898.
[5] Arnold und Becker, Graefe's Arch., xviii, 2, p. 56.

Chloroma.—Chloroma is defined by Cabot[1] as "an atypical form of leukemia in which green-tinted leukoblastic marrow growths penetrate their bony shell, especially the skull bones, and invade surrounding tissue." Occurring in the orbit, a diffuse tumor results. It is usually primarily located in the upper part of the orbit, but grows quite rapidly and may involve the entire orbit. It does not tend to become adherent to the bony walls. The tumor is quite firm and elastic. About 50 cases have been reported. The average age at which it appears is eighteen years. The growth may be bilateral. It develops only in leukemic individuals and invariably terminates fatally in a short time, five and one-half months being the average duration of life, eighteen months the longest.

Etiology.—These tumors are local manifestations of a general disease in which the recently described Spirochæta lymphatica may play a prominent part.[2]

Pathology.—The mass consists of densely packed aggregations of myeloid and lymphoid cells, with but little connective-tissue reticulum. The color, usually a yellowish green, is probably derived from the blood.

Symptoms.—Exophthalmos, bluish discoloration of lids, optic neuritis with retinal hemorrhages, pain more or less severe referable to the head. Deafness often occurs. Constitutional symptoms are anemia, emaciation, hemorrhage, weakness; splenic, hepatic and glandular enlargements.

Treatment.—Treatment is unavailing in the present state of medical knowledge.

Rhabdomyoma.—Tumors of this nature are extremely rare in the orbit. Jennings[3] describes a case occurring in an infant of fourteen months. The tumor was congenital, first observed six weeks before. It was loosely attached to the surrounding tissue. On section it was found to be composed of connective tissue and striated muscle fibers.

Neuroma.—Simple neuroma is extremely rare in the orbit. The tumors are small, and, as a rule, involve the ophthalmic branches of the fifth nerve. Bietti has described amputation neuromata of the ciliary nerves after opticociliary neurectomy (Parsons).

Neuroma Plexiform (*Cirsoid Neuroma*).—Occurs very infrequently in the orbit. Extension from the upper lid to the tissues of the orbit is more common (see p. 178). They may occur in a number of members of a family and may develop in the children of parents who are so afflicted. The growth develops apparently from branches of the fifth, the supra-orbital branch being most frequently the principal one involved. It presents as a firm, elastic mass at the upper margin of the orbit, extends backward, may cause displacement of the globe and erosion of the wall of the orbit against which it impinges. Neuromatoses of other branches in and outside of the orbit may be present. The orbit may be entirely filled with the mass[4] and the sensory nerves of the *eyeball* may participate

[1] Osler's Modern Medicine, iv, p. 676.
[2] Proescher and White, Jour. Amer. Med. Assoc., December 14, 1907.
[3] Amer. Jour. of Ophth., July, 1895
[4] Rockliffe and Parsons, Trans. Path. Soc., iv.

in the change. Secondary hydrophthalmos has been reported in a number of cases.

Symptoms.—The neoplasm develops slowly. It is almost devoid of pain, but is sensitive on pressure.

Structure.—The mass consists of "coils of enlarged and varicose" nerve trunks in a mass of scant connective tissue and soft, yellowish, fat-like material (Beard). Some of the growths are firmer than others. Some are encapsulated. The greater number are not sharply circumscribed.

Results.—Sarcomatous degeneration occurs in a small percentage of cases.

Treatment.—Surgical; the removal must be complete.

Osteoma.—Bony tumors of the orbit are not of frequent occurrence. Lagrange[1] succeeded in collecting 148 reported cases dating back to 1506. They occur in males and females in about equal proportion. The greater number of the growths are extremely hard (ebonated). Some are spongy and a few are cystic. They may develop from any part of the bony wall, but the inner upper angle is the most frequent site (40 per cent., Lagrange). The inner wall is next in frequency (30 per cent.). They may originate from the neighboring cavities and grow into the orbit (probably the greater number originate in the frontal sinus, the ethmoidal cells coming next in order of frequency), or they may originate in the bony walls of the orbit and grow into the neighboring sinuses and into the cranial cavity. The tumors may be single or multiple, may affect one or both orbits. When bilateral the tumor may be due to extension of a single growth or to separate growths. The growths commence in early life and develop very slowly. The mass is commonly irregular, spheroidal, lobulated, presenting a smooth convex surface. Usually sessile, they may be pedunculated. They are covered by a layer of periosteum, over which is found the normal tissue of the cavity in which the growth is developing. Spontaneous detachment from the site of the growth sometimes occurs and the growth becomes a sequestrum, which may be discharged through a spontaneously formed fistula. Osteomata vary much in size. One of the largest on record is that of Weinlecher,[2] which measured 24 cm. in circumference and weighed 281 grams.

Fig. 292

Osteoma of frontal sinus projecting into the orbit. (Axenfeld.)

[1] Tumeurs de l'oeil, Paris, 1904, ii.

[2] Wien. med. Blätter, 1883.

Etiology.—Traumatism, sinus disease, and an embryonical abnormal condition of the bone cells are accredited causes. Systemic dyscrasiæ have been assigned as causes, but our knowledge is as yet too meagre on this point to warrant the acceptance of this assumption. A nucleus in the form of a foreign body is found in some cases.[1]

Symptoms.—The eyeball and other contents of the orbit are displaced in proportion to the encroachment of the growth in the cavity of the orbit. The mass is hard and inelastic on pressure, but not painful except that pain may be elicited on firm pressure in some cases. If the growth extends to the brain, cerebral symptoms may develop and pain will be present if inflammation occurs. The vision is often much impaired by pressure.

Diagnosis.—The hardness of the tumor on palpation, its immobility and apparent direct connection with the bone are usually sufficient. If doubtful a needle may be introduced. In cases of obscure orbital conditions accompanied by brain or sinus symptoms, the *x*-ray is at times of great value in diagnosis. It is always desirable to determine the extent of the growth by skiagraphy before attempting its removal.

Prognosis.—If the growth is confined to the orbital walls the prognosis is generally favorable. The eyeball and the vision as it existed immediately before removal can usually be preserved. When the growth extends into the cranial cavity meningitis may follow removal (Knapp) and death result. Of the cases collected by Berlin 16 were attached to the roof of the orbit; death followed removal in 6 cases (38 per cent.). It is probable that the present methods of procedure will yield a much lower percentage of fatal results. Relapses do not occur.

Treatment.—Surgical measures only are of avail. The tumor should be exposed, the periosteum stripped off from the tumor and raised from the bone at the base of the tumor. After the periosteum is stripped off it may be found that the tumor can be loosened by gentle traction. If this is not the case the orbital bony tissue at the base of the tumor should be grooved or the outer table cut through by means of a sharp chisel, when the tumor can be quite easily separated from the underlying bony tissue. If attached to the thin plate of the orbital roof, great care should be exercised not to injure the meninges of the brain. After removal the periosteum may be replaced and the wound closed.

Sarcoma.—Sarcoma of the orbit may be primary or secondary, pigmented or non-pigmented.

Primary Sarcoma.—Various forms of sarcoma develop in the orbit.

Classification.—They may be classified as (*a*) leukosarcoma, round or spindle cell, (*b*) pigmented sarcoma, (*c*) fibrosarcoma, (*d*) angiosarcoma, (*e*) myxosarcoma, (*f*) chondrosarcoma, (*g*) myosarcoma, (*h*) osteosarcoma, (*i*) cystic sarcoma, (*j*) cylindroma, (*k*) endothelioma, (*l*) chloroma, (*m*) gliosarcoma.

Sarcoma occurs in the proportion of about 1 to 10,000 cases of eye affection (Hartridge), 1 to 1500 (Langrange). In 204,572 cases of eye

[1] Fryer, Trans. Amer. Ophth. Soc., 1883.

disease observed at the New York Eye and Ear Infirmary sarcoma of the orbit was present in 34, or about 1 in 6000.

Sarcoma of the orbit develops at all ages, but is more frequent before the age of twenty years than subsequently. Of 29 cases reported by Stirling[1] 9 occurred before the age of nine years. In some cases the development is very rapid, three weeks (round cell) to eight years (osteosarcoma), according to Parsons.

The tumors arise from the connective tissue of the orbit, from the blood-vessels and connective tissue (angiosarcoma), from the endothelial cells of blood- and lymph-vessels (endothelioma), from the periosteum (osteo- and chondrosarcoma). The rapidly growing sarcomata are not, as a rule, encapsulated. They are not sharply circumscribed. The more slowly growing sarcomata (cylindroma, endothelioma, etc.) are often contained in a more or less delicate capsule.

Gliosarcoma.—Gliosarcoma, primary in the retina, has been reported.

Cylindroma.—This form of sarcoma is usually encapsulated. It may present the characteristic hyaline cylindroids in parts (see p. 184), much connective tissue, and round and spindle-shaped sarcoma cells in parts. It may attain to a large size.

Endothelioma (Alveolar Sarcoma).—These growths develop quite slowly, are encapsulated, nodular, and firm. They consist of alveoli with delicate connective-tissue trabeculæ, the alveoli being filled by round or oval cells containing a fair amount of protoplasm, a large oval nucleus, and a nucleolus.

Etiology.—Not much is known of the etiology of sarcoma of the orbit. Traumatism is reported as a cause in a number of the cases. Heredity is not traced.

Symptoms.—Exophthalmos is the most prominent symptom. The eyeball will be pushed forward and away from the direction of the advance of the tumor. The effect on vision depends on the involvement of the optic nerve, interference with the blood supply to the eyeball and pressure exerted. As a rule, pain is not a prominent symptom in the development of orbital neoplasm. There is bruit and pulsation in some of the vascular tumors and in some vascular rapidly growing sarcomata.

Prognosis.—This depends on the character of the growth and the time of removal. It may be broadly stated that all encapsulated growths afford a much more favorable prognosis than do the tumors that are not encapsulated. Recurrence took place in 17 of the 29 cases reported by Stirling. Parsons records 9 recurrences in 10 cases in which the tumor was removed from the orbit and 9 of 16 cases in which exenteration of the orbit was performed. Metastasis is of most frequent occurrence earlier in the round-cell sarcomata, later in the spindle-cell growths. Metastasis takes place by way of the blood stream.

Treatment.—In all forms of sarcoma in which the tumor is not encapsulated, exenteration of the orbit should be performed at the earliest

[1] R. L. O. H. Reports, 1893, xiii.

possible moment. It is entirely useless to endeavor to eradicate the disease by removal of the growth without removing all tissue from the orbit, as it is sure to return rapidly.

Secondary Sarcoma is due to extension from the eyeball, lachrymal gland, optic nerve, and tissues adjacent to the orbit. It calls for complete removal.

Carcinoma.—Tumors of the epithelial type are probably without exception secondary to growths in conjunctiva, lids, eyeball, or other adjacent skin or mucous membrane structures. When orbital tissue is invaded by such growths, complete exenteration of the orbit is indicated.

Cysts of Orbit.—These may be divided into *congenital* and *acquired.*

Congenital cysts include (*a*) dermoid and teratoid cysts, (*b*) inclusion cysts, meningocele, encephalocele, hydro-encephalocele.

Acquired cysts include (*a*) implantation cysts, (*b*) serous cysts, (*c*) parasitic cysts.

Dermoid Cysts.—These are always congenital and are due in all probability to invaginations of dermal tissues during fetal life, as propounded by Verneuil (1852). Dermoid cysts are found in all parts of the orbit, but are most frequent in the temporal angles and in the lower inferior angle. They are rounded masses, often adherent to the periosteum. They may have prevented the ossification or have caused absorption of the bone on which they rest, so that portions of the cyst may be outside of the orbit, in the antrum (Lediard), temporal tissues (Krönlein). The cyst wall is composed of more or less perfectly formed skin, containing hair follicles, sebaceous and sweat glands, and covered by stratified epithelium. Distention of the cyst produces marked degeneration in these structures. Inflammatory changes may take place in the cyst itself, causing the formation of granulation tissue and other products of inflammation. The glands of the skin become atrophied and displaced. Epithelium thinned or lost. The contents are degenerated epithelial cells, hairs, sebum, fatty granules, cholesterin. In some of the cysts the contents consist so largely of squamous epithelial cells that the growths are classed as cholesteatomata. Dermoid cysts differ from sebaceous cysts by the structure of the wall, contents of cyst, and relation to the skin. A dermoid cyst may have a sebaceous cyst as a development in its wall.

Teratoid Cysts.—They have all the characters of dermoid cysts plus the inclusion of mesodermic tissues as cartilage, bone, muscle tissue. Teeth have been found in these cysts. Such cysts are extremely rare.

Treatment.—The cyst should be dissected out without breaking through the wall if possible; in any event the wall of the cyst should be completely removed.

Inclusion Cysts.—These cysts are due to the protrusion of intracranial tissues through defects in the osseous walls of the orbit. If the tumor consists of the membranes of the brain only they are termed meningocele; if brain substance is included, encephalocele; if cerebrospinal fluid is also present, hydro-encephalocele. Inclusion cysts are found at the upper inner angle of the orbit, at the apex and at the outer angle of the orbit.

In all locations the defects occur at the site of normal sutures, the ossification not having advanced sufficiently far to effect the necessary closure.

Symptoms.—The eyeball is pushed forward and deviated in the direction of least resistance. The cyst may envelop the eyeball. Pulsation may occur. The tumor is soft, elastic, and sometimes reducible. Its reduction may produce convulsions or coma, and may be painful.

Implantation Cysts.—As a result of the entrance of a foreign body into the orbital tissue or the introduction of epithelium as a result of a punctured wound, implantation cysts may develop. They are extremely rare. The contents of the cyst are usually serous or serosanguinolent fluid with cell debris. The wall of the cyst is lined with flat epithelial cells.

Serous Cysts.—These are of rare occurrence. They may develop from the lymph space of Tenon's capsule, the synovial cavity of the trochlearis (Parsons), the sheath of the optic nerve, or from blood-clots (Lagrange, quoted by Parsons). The tumor is firm, elastic, usually bluish in color, and translucent. The contents may be serous or serosanguinolent.

Treatment.—Removal by surgical means.

Parasitic Cysts.—Echinococcus cyst (hydatid) of the orbit is an occasional occurrence. Blaschek[1] has collected 59 cases. The cysts may be small, the size of a pea, or they may reach the size of an orange. They may develop from any part of the orbital tissue, may be attached to the bony wall, may extend from the orbit into neighboring cavities or from neighboring cavities into the orbit. Primarily spherical, they assume any shape that may be necessary to conform to the pressure exerted on them. The cysts occur most frequently in young individuals. They affect the sexes approximately equally. The growth is slow, as a rule, but may be quite rapid—two weeks to six years.

Symptoms.—The symptoms are those of the development of orbital tumor except that the cyst is more yielding. Unless inflammation supervenes there is little or no pain. "Hydatid buzzing," elicited by closing the lids tightly, is sometimes experienced.[2] If the mass is sufficiently large and can be reached, fluctuation can be felt.

Structure.—The cyst wall has the laminated structure of all hydatid cysts, often contains hooklets, blood-corpuscles, and daughter cysts. The contained fluid is clear if the parasite is living, often turbid or milky if dead. The fluid is rich in sodium chloride, neutral in reaction; specific gravity 1009 to 1015; remains clear on boiling; contains little or no albumin (Parsons). It contains few cells, but may contain cholesterin crystals.

Cysticercus Cysts.—These are very rare, are seldom deep in the orbital tissue. They are apt to cause considerable inflammatory reaction (Parsons). The cysts are small in size. They may become adherent to adjoining structures by inflammatory reaction.

On opening the cyst the head, showing the four suckers and the double

[1] Wiener klin. Woch., 1899, No. 6.

[2] Wernicke, Centralbl. f. prakt. Augen., xxiii, p. 304.

ring of hooklets, can usually be made out even if the entozoon has been dead for some time.

Treatment.—The treatment of parasitic cysts is their removal by dissection when this is possible. In the case of the echinococcus the cyst wall can usually be stripped off quite easily, but this is not always so. If portions of the wall are of necessity permitted to remain the inner surface should be cauterized, preferably with carbolic acid, and the wound kept open. Healing by granulation will take place.

Filariæ Loa in Orbit.—These are sometimes found in the orbit. They do not cause disastrous changes.

Actinomycosis of Orbit.—A case of this kind is reported by Coppez and Depage[1] occurring in a man aged fifty-six years. Neuralgic pains in the region of the molar teeth on right side, in August, 1902. Carious teeth extracted. Abscess of the temporal fossa January 3, 1903; again in February, followed by exophthalmos and swelling of the entire right half of the face. A fistulous tract developed at the outer canthus. The fistula was curetted and actinomyces were found. Patient experienced severe pain in the head July 11, 1903, and died August 24, 1903, presenting the appearance of typhoid. No autopsy could be obtained.

Hernia of Orbital Fat.—A sac-like protrusion of the skin of the lid, usually the lower, at the orbital margin, resembling edema, is not infrequently seen in senile individuals. This is due to relaxation of the tarsoörbital fascia, partial atrophy of the orbicularis palpebrarum muscle, and an abundance of orbital fat (De Wecker). If the margin of the lid is pressed down to the margin of the orbit, the fat recedes into the orbit, affording a means of differentiating this condition from edema. Occurring in the upper lid it constitutes senile fatty ptosis.

[1] Jour. med. de Bruxelles, December 3, 1903.

CHAPTER XXV.

RELATION OF DISEASES OF THE THROAT, THE NOSE, AND THE ACCESSORY SINUSES TO THE EYE.

Throat.—Diseases of the throat affect the eyes only indirectly.

Adenoids.—The influence of adenoids in the production of epiphora by preventing the proper evaporation of fluids from the nose as a result of the abolition of nasal breathing is well known. Adenoids also appear to favor the development of phlyctenular keratitis and conjunctivitis, as these conditions often rapidly improve on the removal of the growths.

Faucial Diphtheria.—This, as well as nasal diphtheria, may be primary to a secondary diphtheria of the conjunctiva (see page 238). Post-diphtheritic paralyses affecting the muscles of the eye and post-diphtheritic optic neuritis occur not infrequently after pharyngeal as well as nasal diphtheria.

Nasal Cavities.—Disturbances of the eye and its adnexa due to disease of the nose are quite common. Perhaps the most frequent is disturbance of the lachrymal conducting apparatus by obstruction of the lachrymal duct. Probably 95 per cent. of the cases of dacryocystitis originate as a result of disease of the nasal mucous membrane. Acute coryza causes epiphora almost invariably. Subacute rhinitis often causes partial or complete blocking of the lachrymal duct by the extension of hypertrophy of the nasal mucous membrane to the mucous membrane of this duct. When to this is added some form of infection, acute dacryocystitis may develop. Atrophic rhinitis by extension to the lachrymal duct not infrequently causes the development of chronic purulent dacryocystitis. Syphilis affecting the nasal mucous membrane may by extension to the mucous membrane of the lachrymal duct and sac produce obstruction of the duct and dacryocystitis. Tuberculosis (lupus vulgaris) of the nasal mucous membrane may extend to the lachrymal duct and sac and by way of the lachrymal canaliculi may invade the conjunctiva. The writer has observed this in two cases. Pemphigus of the conjunctiva is associated with pemphigus of the nasal and faucial mucous membrane in many of the cases. An examination of the last-named membrane often affords valuable data in making a diagnosis.

Influenza extending from the nasal mucous membrane may occasion an acute conjunctivitis apparently by the passage of the bacillus of Pfeiffer through the lachrymal passages to the conjunctiva. Diphtheria of the nasal mucous membrane may also extend through the lachrymal passages and involve the conjunctiva. This has occurred in about 33 per cent. of the cases of diphtheria of the conjunctiva observed by the writer.

Obstruction to the lachrymal duct may be due to pressure from an

hypertrophied inferior turbinate, to the presence of polypi, to a greatly deviated septum, or to foreign bodies in the inferior meatus. A congenital imperforate lower extremity of the lachrymal duct may exist.

Reflex ocular symptoms not infrequently develop from affections of the nose. A patient, a physician, suffered from furunculosis affecting the mucous membrane of the right ala of the nose which gave him considerable pain for three to five days. During this period the lachrymation of the right eye was increased and attempts to read were difficult and painful. On inquiring the cause of the inability to read it was found that the power of accommodation of that eye was abolished. The disability vanished as soon as the acute symptoms of the furunculosis had passed.

Reflex spasm of the orbicularis palpebrarum may be caused by irritation of fibers of the fifth nerve occasioned by disease of the nose.

Antrum.—Acute catarrhal or purulent inflammation of the antrum may produce pain in and about the orbit and reflex ocular disturbance of the nature of increased lachrymation, hyperemia of the conjunctiva, and disturbance of vision by reflex interference with the action of the ciliary muscle. The case reported by Johnston[1] raises the question of the influence on vision of the absorption of septic material from retained pus in the antrum. In this case vision in the right eye was reduced to $\frac{20}{40}$ and use of the eye was very annoying. The evacuation of pus from the right antrum and the establishment of suitable drainage restored vision to the normal. There were no fundus changes.

Ziem[2] treated a case in which in addition to empyema of the antrum there was abscess in the orbit and a fistula of the lachrymal sac. The affection began in the antrum. Cases in whch empyema of the antrum has caused orbital abscess by perforating the floor of the orbit are not uncommon. Disease of the optic nerve and extension to the brain take place in some of the cases.

Caldwell[3] from his observations and experience concludes that "disease of the antrum is more especially manifested in intra-ocular and conjunctival circulatory disturbances and in the production of asthenopic symptoms, while disease of the sphenoid is more likely to affect the optic nerve and the motor nerves of the eyeball."

Ethmoid Cells.—Acute or chronic purulent ethmoiditis may extend to the orbit. This is more apt to occur after injury in which the os planum of the ethmoid is broken and the orbital periosteum is torn. Polypoid masses developing in the ethmoidal cells may cause the os planum of the ethmoid to bulge into the orbit and develop a mass which may be mistaken for a malignant growth. Exostoses having their origin in the ethmoid cells not infrequently protrude into the orbit (see page 635). The communication of the anterior ethmoid cell or cells with the nasal cavity is prone to become obliterated, converting the isolated cells into cysts, which fill with a mucoid (mucocele) or mucopurulent secretion, expand and appear at the inner margin of the orbit, slightly above the medium horizontal plane, as a tumor, tense and elastic, with imperfect

[1] Ophthalmology, July, 1907, p. 636.
[2] Allg. med. Central., 1887, Nos. 37 and 39.
[3] Med. Record, April 8, 1893.

bony walls. The cystic condition may be apparent at or just above the caruncle. The eyeball may be displaced outward and slightly downward. Bulging may also occur in the nasal cavity. It is often difficult to differentiate these cystic masses from malignant growths and from osteomata. The osseous wall is formed by the bulging of the posterior half of the lachrymal bone, the anterior part of the os planum of the ethmoid, and to hyperplasia of these walls. A cyst so situated may rupture either through the skin or mucous membrane at or near the inner canthus and produce a fistula that may discharge for years (de Schweinitz), may fill and empty and refill (Adelheim). Choked cells may become distended and rupture into the antrum.[1] Occurring well posteriorly they may open into the orbit and cause disturbances of the mobility of the eyeball or disease of the optic nerve.

In disease of the ethmoid cells the granulation tissue which almost always forms together with polypoid masses may add to the volume of the tumor that encroaches on the orbital cavity. The pressure exerted by the accumulating contents of such diseased cells causes discharge into the nose in the greater number of cases. If the cell simply continues to expand the symptoms are those of an intra-orbital neoplasm. If the cell or cells fill and empty into other cavities (nose or antrum) the effect on the contents of the orbit is intermittent and transitory. Among the symptoms of ethmoid disease affecting the contents of the orbit are edematous ptosis, venous engorgement, chemosis of ocular conjunctiva, diplopia, and interference with the action of the extrinsic ocular muscles.

Malignant growths extending from the ethmoid cells into the orbit are not common, but they do occur.

The posterior ethmoid cell lies in close proximity to the optic nerve, and in some skulls partly surrounds the bony canal which contains the nerve. Chronic inflammatory processes which affect these sinuses, necrosis and exostoses of the walls, malignant and syphilitic growths may all produce obscure affections of the optic nerve, resulting in disturbances of vision, amounting to complete blindness in some cases. It is not at all improbable that many cases of obscure optic-nerve atrophy and the so-called retrobulbar neuritides have their origin in disease of these sinuses. In all cases of obscure eye disease the nasal and accessory sinuses should be carefully examined.

Examination of the ethmoidal cells through the nose is often sufficient to clear the diagnosis, but some cases do not present intranasal changes of sufficient prominence to permit the making of a differential diagnosis. In such cases transillumination and *x*-ray skiagraphy must be resorted to.

Frontal Sinuses.—Acute frontal sinusitis causes severe pain referred to the upper part of the orbit, accompanied by tenderness of the supraorbital and supra- and infratrochlear nerves, swelling and tenderness of the tissues over the frontal sinuses. Chronic inflammation causing erosion of the floor of the sinus eventually results in bulging of the periosteum and the formation of a tense elastic tumor projecting into some part of the

[1] Sattler, Trans. Sec. on Ophth., A. M. A., 1899, p. 331.

orbit from the portion of the orbital roof forming the floor of the sinus. The bulging into the orbit most frequently occurs at the inner upper angle. It may occur in the outer third of the orbit, following extension of the sinus outward due to pressure from secretion retained in the sinus. Such a case came under the writer's observation. A spherical tumor, measuring 2.5 cm. in diameter, was present in the outer third of the right orbit, displacing the globe downward and inward. The tumor was of a brownish color, tense, and very slightly elastic. A diagnosis of melanosarcoma of the orbit had been made. The mass had been apparent to the patient about three and a half years. It was gradually increasing in size. There was no pain of moment. The mass was found to be attached to the roof of the orbit. When the pedicle was incised it was found that the mass was a cyst, containing a thick, brown, viscid fluid. The frontal sinus on that side was greatly distended and shut off from the opposite side and from the nasal cavity. Bulging may occur well back in the orbit under similar conditions. Spontaneous rupture on the cutaneous surface just beneath the margin of the orbit and the formation of a sinus sometimes take place.

Fig. 293

Acute frontal sinusitis.

The secretion resulting from an inflammation of a frontal sinus may escape (*a*) through the nose by forcing its way through its own infundibulum or by passing through the septum separating the two sinuses and escaping from the infundibulum on the other side; (*b*) onto the integument by spontaneous rupture, usually at the inner upper angle of the orbit just beneath the brow; (*c*) by rupture into the orbit where it may set up orbital cellulitis; (*d*) rarely into the cranial cavity.

Of 11 cases of frontal sinus disease seen by Wiedermann,[1] 6 perforated into the orbit, 2 into the cranial cavity, and 3 anteriorly onto the skin.

Emphysema of the tissues of the eyelids and of the orbit is not rare as a consequence of fracture of the floor of the orbit into the antrum or of fracture of the lachrymal bone, or the os planum of the ethmoid or the orbital margin into the frontal sinus. If pathogenic germs have been carried into the tissues at the time of the injury in sufficient number a pathogenic process may be set up.

Sphenoidal Sinus.[2]—The sphenoidal sinuses or cells are in closer relation to the optic nerve than the ethmoidal and differ widely in different individuals. In some skulls the sphenoidal sinuses surround the

[1] Inaug. Dissert., Berlin, 1893.

[2] For an extensive review of this subject, see the work by Berger and Tyrman, The Diseases of the Sphenoid Cavity and of the Labyrinth of the Ethmoid Bone and their Relations to Affections of the Eye, Wiesbaden, 1886, J. F. Bergmann.

optic nerve at the optic foramen, being separated from the nerve by a very thin osseous wall.

Inflammatory processes affecting the sinuses may readily affect the optic nerve by extension of the inflammation or by pressure exerted by inflammatory products that accumulate in the tissues surrounding the optic nerve. It is possible that hyperplasia of osseous tissue excited by inflammation in the sinuses may exert undue pressure on the optic nerves. It is also possible that toxins originating in the sinuses may affect the optic nerves. Retrobulbar neuritis, papillitis, concentric contraction of the fields of vision from peripheral optic neuritis at or near the foramen, sudden amblyopia without ophthalmoscopic changes, etc., may occur. The nerve trunks supplying the extrinsic muscles of the eye may be affected in sphenoidal sinusitis. Byron[1] reports a case in which bilateral abducens paralysis occurred.

Neoplasms of various kinds and necrotic processes affecting the walls of the sphenoid cavity occur and may affect the optic nerve and tissues of the orbit.

Neoplastic and inflammatory processes originating in any one of the accessory sinuses may extend to all of the others. In chronic suppurative processes this is not at all uncommon.

In all cases of orbital abscess, cellulitis, or phlebitis in which the etiology is obscure, the condition of the adjacent sinuses should be carefully ascertained. Transillumination, oral, nasal, and postpharyngeal inspection, exploratory incision, and *x*-ray skiagraphy, if necessary, should be employed.

[1] Jour. Amer. Med. Assoc., November 11, 1899.

CHAPTER XXVI.

REFRACTION.

HYPEROPIA, ASTIGMIA, AND MYOPIA.

THE refraction of the eye is determined by:

A. The length of the antero-posterior diameter. If the antero-posterior diameter is too short, the eye is hyperopic; if too long, myopic (see page 101). The conditions are termed *axial hyperopia* and *axial myopia*, respectively.

B. To peculiarities in the curvature of the surface of the cornea or lens: (1) The curvature may be regular and alike in all meridians: (*a*) curvature hyperopia (cornea or lens, or both, too flat); (*b*) curvature myopia (cornea or lens, or both, too acutely curved). (2) The curvature may be regular, but vary in various meridians—*regular astigmia.* (3) The curvature (usually of the cornea) may be irregular—*irregular astigmia.*

C. Abnormal refractive index of the media: (1) *Index hyperopia*—

(*a*) Index of the cornea or aqueous, too low.
(*b*) Index of the lens, too low.
(*c*) Index of the vitreous, too high.

(2) *Index myopia*—

(*a*) Index of the cornea or aqueous, too high.
(*b*) Index of the lens (usually the nucleus), too high.
(*c*) Index of the vitreous body, too low.

D. Abnormal position of the lens. (1) Displacement backward—*hyperopia*; (2) displacement forward—*myopia*; (3) tilted—*astigmia.*

E. Absence of lens (aphakia)—hyperopia.

F. Combinations of the above. (Modified from Parson's *Pathology of the Eye,* part iii.)

Axial Peculiarities.—These are determined by (*a*) conditions external to the eyeball; (*b*) conditions inherent to the eyeball.

External Conditions.—*Heredity.*—Those familiar with the facts cannot question the statement that the shape of the eye is greatly influenced by heredity. Thus in certain families the father or mother, or both, may be highly hyperopic, with relatively small but not decidedly microphthalmic eyes; the children of these parents, particularly those who resemble the parent so affected, will, as a rule, have similar eyes. This holds good with regard to all phases of refraction except those due to pathological changes. While the condition known as progressive myopia (including malignant myopia), which is axial, is not hereditary, judging from the

observation of Fleischer,[1] Botwinnik,[2] and others, the tendency to these forms is influenced by heredity to a considerable degree. Thus progressive myopia is more common in children the parents of whom have been so afflicted and in Hebrews than in others. Wilfur[3] was able to determine that heredity exerted an influence in 376 cases of 1352 myopes examined. Schnabel and Herrnheiser[4] contend that in all myopic eyes the resistance of the sclera about the optic nerve is slight and that this constitutes the inherited and congenital predisposition to myopia.

Congenital Influences.—The antero-posterior axis of the eye at birth is of such a length that nearly all infants are hyperopic. Ivanoff[5] examined 1000 eyes of infants at birth by means of the retinoscope and found 92 per cent. hyperopic, 7.2 per cent. emmetropic, and 0.6 myopic. Herrnheiser[6] found all eyes hyperopic in 1918 newborn children examined.

Influence of Shape of Orbit.—Although it has been held that those with dolichocephalous skulls are prone to axial elongation of the eyeballs, and those with brachycephalous skulls are prone to hyperopia, the studies of Schmidt-Rimpler,[7] Pymsza,[8] and others have not substantiated this view. After birth the antero-posterior axis tends to lengthen (*a*) as a result of normal growth; (*b*) as a result of influences that produce a pathological condition, as in progressive myopia. As the result of normal growth, the hyperopia present at birth diminishes, as a rule. Emmetropia may pass into myopia and myopia may increase slightly—all without pathological changes.

Hyperopia.—As a rule, the hyperopic eye does not present pathological changes; however, the myopic crescent, conus, and sclerochorioidal ectasiæ may be present in eyes still hyperopic, in which the hyperopia has been greatly reduced from the degree present in early youth. The process is the same as that found in progressive myopia, occurring in a previously highly hyperopic eye.

Removal of the lens from any cause (aphakia) makes a difference in the refraction varying from 10 to 26 dioptres, in direct proportion to the length of the antero-posterior diameter of the globe. Certain systemic conditions, as diabetes mellitus, sometimes produce transient hyperopia.

The cause of the development of hyperopia in the aged, which occurs in a small percentage of cases, is not constant. It is probably due to the relaxation of ciliary spasm in some cases, to a flattening or a lowered index of refraction affecting the lens in others, and to an increase in the index of the vitreous body in still other cases. It is doubtful that a lowering in the curvature of the cornea or a shortening of the axis of the globe plays a part.

[1] Trans. Oph. Cong., Heidelberg, xxxiv.
[2] Vratsch, 1899, No. 42.
[3] Inaug. Dissert., Kiel, 1896.
[4] Zeits. f. Heilkunde, 1895, V, xvi.
[5] Inaug. Dissert., Petersburg, 1898.
[6] Präger med. Woch., 1892.
[7] Graefe's Archiv, xxxv, 1, 76.
[8] Inaug. Dissert., Dorpat, 1892.

TABLE SHOWING DECREASE IN THE AXIAL LINE IN HYPEROPIA. (HARTRIDGE.)

For 0.5 D.	of	H.	there is	a diminution in the axial line of	0.16	mm.
1	"	"	"	"	.31	"
2	"	"	"	"	.62	"
3	"	"	"	"	.92	"
4	"	"	"	"	1.22	"
6	"	"	"	"	1.9	"
10	"	"	"	"	3.2	"

Astigmia.—This condition of refraction is corneal in a high percentage of the cases.

Regular Astigmia.—Regular astigmia must be considered congenital, as a rule. The curvature of the cornea is influenced by the pressure of the lids, a fact that is easily demonstrable in conditions of thickening of the lids. The weight of a lid in which hordeolum or chalazion has developed may change the astigmia from 1 to 2 dioptres, but it does not always so affect the cornea. Inflammatory processes affecting the sclera near the cornea and the margin of the cornea may produce transient astigmia. The writer observed a case of subacute lymphangiectasia affecting the superficial layers of the sclera near the sclerocorneal margin in which the corneal astigmia (regular) increased from 0.33 to 3 dioptres within a period of two weeks. At certain stages in the development of pterygium, corneal astigmia is produced. High degrees of regular astigmia result from operative procedures affecting the cornea, after iridectomy, extraction of cataract, etc. Postoperative astigmia always decreases as the cicatrix contracts. Corneal astigmia in which the curvature of the cornea is regular in every meridian presents the principal axes at right angles in almost all cases; however, in a small percentage of cases the principal axes are not at right angles. Not infrequently increase of astigmia and a departure from the right angle placement of the principal axes is the first objective sign of the development of conical cornea.

Irregular Astigmia.—This is almost invariably corneal and is acquired. It is due to inflammatory processes, largely ulcerative, which result in the formation of irregularities in the curvature of the external surface of the cornea. These irregularities are accompanied by corneal opacities of greater or less density. Although vision can be much improved in many cases by the application of glasses, it can never be brought up to the normal.

Lenticular Astigmia.—On examining the refraction of the eye, it will be found that the corneal astigmia does not always correspond with the total astigmia. It may be more or less, and the principal meridians may differ. These variations may be due in a small percentage of the cases to the peculiarities in the curvature of the posterior surface of the cornea, but in the greater number it is due to the shape or position of the crystalline lens. The astigmia of the lens may be passive, not being changed by acts of accommodation (*static astigmia*); or the astigmia may change on accommodation (*dynamic astigmia*). In some cases the lenticular closely corresponds with the corneal astigmia, under which condition the total is greater than the corneal astigmia. In other cases the lenticular is

opposed to the corneal astigmia, causing the total to be less than the corneal astigmia (Donders, 1864). The latter form of lenticular astigmia was held by Dobrowolsky[1] to be due in many cases to unequal contraction of the ciliary muscle (dynamic astigmia). This view has many supporters.[2] That this is anatomically possible is apparent from the fact that the ciliary muscle and sphincter pupillæ muscles are innervated by a number of separate nerve twigs, each of which passes to different segments of these muscles, and that irritation of separate twigs causes segmental contraction of the muscles (Hensen and Vœlckers). Clinical conditions which must come under the observation of every ophthalmologist support this view. It not infrequently occurs that individuals with 0.5 to 1 dioptre of astigmia, whose accommodation is normal, will show this degree on skiascopic and subjective examination one moment, and a moment later the astigmia will be annulled—in some cases reversed. It is difficult to account for this change in any other way than by the assumption of a dynamic astigmia. In some cases dynamic astigmia is so persistent that but part of the astigmia is manifest at first, the latent portion becoming manifest only after the patient has worn the correction of the manifest astigmia for some time.

In low degrees of ectopia lentis and of traumatic subluxation of the lens, lenticular astigmia exists.

The amount and often the axis of astigmia change with age. It is a rule, subject to exceptions, that astigmia "with the rule" tends to decrease; astigmia "against the rule" tends to increase. Changes in the curvature of the cornea, clearly demonstrated by recorded measurements with the ophthalmometer taken at intervals of years, take place. The well-known changes in the lens which always accompany age must affect its curvatures. Dynamic astigmia disappears with the loss of the power of accommodation.

Astigmia has nothing to do with the length of the sagittal diameter of the globe. It relates simply to the relative differences in the refraction in the different meridians of the eye, the maximum difference being between the "principal" meridians. Astigmia may accompany any length of the sagittal diameter of the globe.

Myopia.—Axial Myopia.—This embraces by far the greater number of cases of myopia. It may be divided into (1) *physiological;* (2) *progressive*—(*a*) self-limited, (*b*) continous; (3) *malignant.*

Physiological Myopia.—In this form the condition of the refraction is myopic without pathological changes in the tissues of the eye. Such eyes are normal eyes in the sense that they have undergone no form of degeneration. With correction of the error of refraction, vision is usually normal.

Progressive Myopia.—(*a*) Temporarily progressive; the type of this form of myopia begins at the age of eight to twelve years, progresses to the age of eighteen to twenty-three years, and then becomes practically stationary. (*b*) Continuously progressive; this form continues to be

[1] Arch. f. Ophthal., 1868, xix, iii, p 51.

[2] Mauthner, Javal, Landolt, etc.

slowly progressive, with periods of comparative arrest, throughout life.

Anatomical Changes.—Elongation of the sagittal diameter of the globe is accompanied by certain changes in the coats of the eye. The changes may begin with any condition of the refraction. In the early stage, a narrow, white, crescentic patch appears at the margin of the optic disk, usually extending half-way around the circumference of the disk on its outer lower aspect, indicating a separation of the chorioid and outer layers of the retina from the internal margin of the papilla. (The nasal margin of the opening in the chorioid for the passage of the optic nerve encroaches on the papilla as though the chorioid had shifted toward the temporal side.) The crescent may appear in any other position in relation to the disk. The margins of the crescent may be clear cut, or the convex outer margin may be irregularly pigmented. This patch, when it shows no depression and does not exceed $\frac{1}{5}$ or $\frac{1}{4}$ the diameter of the disk in width, is termed *myopic crescent.* It is often impossible without a history of progressive change in the refraction in the direction of myopia to differ-

Fig. 294

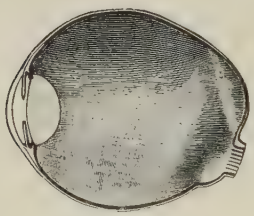

Section of a highly myopic eyeball; the retina has been removed. (Nettleship.)

Fig. 295

Myopic crescent of a small posterior staphyloma. (De Wecker and Jaeger.)

entiate the very narrow myopic crescent from the congenital scleral crescent (see page 134) of normal eyes. With the progression of the myopia the crescent increases in width. The outer border may become very irregular and crescentic zones of pigmentation, increasing slightly in intensity from within outward, may occupy the outer part of the patch. These patches usually become slightly depressed, constituting *myopic coni.* These must not be confounded with the coni present in coloboma of the optic-nerve sheath (see page 491, Fig. 241). They may greatly exceed the diameter of the disk in width, in which case they may extend almost or quite around the disk. As a rule, the greatest width is downward and outward, but this is subject to exceptions. In many cases, when conus is marked, changes in the macula affecting all of the membranes of the eye develop. As the axial elongation progresses the conus extends in the direction of the posterior pole, as a rule, and in the advanced cases may extend over a very large area. The development of the myopic conus is the result of an ectatic condition of the sclera (see page 317), a *posterior staphyloma* with corresponding stretching of the chorioid and retina. The ectasia which is more

or less regular usually affects the sclera to the temporal side of the optic-nerve entrance, but it may include the optic-nerve entrance and extend also to the nasal side. The outer border of the atrophic defect in retina and chorioid becomes very irregular. White, yellowish, and imperfectly pigmented patches may appear.

Disk.—The appearance of the disk may change markedly, due primarily to its position in relation to the sagittal axis of the globe. With the development of the ectasia, the disk presents at an angle to his axis, and when viewed with the ophthalmoscope appears to be oval in shape. In some cases, section shows that the optic disk (ocular end of the nerve) is dragged to the temporal side.[1] The blood-vessels dip into the depression at the temporal side. In some cases this feature is quite prominent; in some the color of the disk so closely approaches the color of the surrounding fundus that it is difficult to determine its limit.

Nerve.—The subvaginal space at the ocular end is much enlarged, the cleft extending farther on the sclera at the temporal than on the nasal side.

Retina.—The retina is dragged over the nasal side of the optic disk (*supertraction*) in a number of the cases, as pointed out by Jaeger. In high degrees of myopia the supertraction may reach almost to the centre of the disk (Nagel); often the outline of the disk may be seen through the supertracted retina. In a small percentage of the cases of high myopia a crescentic shadow, concentric to the disk, may be seen marking the border of the posterior staphyloma (*staphyloma verum*). Otto[2] has made a careful study of the condition. Although appearing, as a rule, on the nasal side, it may surround the disk. The nasal portion of the retina occupies a higher plane than the portion of the temporal side of the shadow. Blood-vessels passing over the shadow describe a decided curve, in some cases being lost under the shadow, indicating an actual overhanging of the retina. The retina and chorioid lying below the shadow are paler than the portion to the nasal side, and present evidence of stretching by their greater rarefaction (Fig. 296).

At the periphery the retina is approximately normal in appearance. Weiss[3] has described a crescentic "reflex streak" at the inner margin of the disk, which he considers one of the earliest ophthalmoscopic evidences of commencing myopia. He attributes it to a slight detachment of the vitreous with a collection of fluid beneath.

Apparently largely on account of a disturbance of nutrition, due to partial atrophy or disappearance of the capillaries of the choriocapillaris, the posterior layers of the retina suffer most. The changes in the pigment layer are pronounced. The pigment cells are wanting in some places, heaped up in others. The pigment is deficient in some of the cells. The bacillary lyyer suffers in connection with the pigment layer; the cones and rods degenerate, their outer members, particularly, clump together to some extent, and disappear. The inner layers, although stretched, suffer less since their nutrition is obtained from a different system of

[1] Heine, A. f. O., xxx, viii. [2] A. f. O., xliii, 3, 1897. [3] Graefe's Arch., xxxi, 3, 239.

vessels and is not greatly disturbed. When the lamina vitrea is defective, union between chorioid and retina takes place. *Detachment* of the retina occurs relatively frequently (according to Hertelin, 0.96 per cent.; Scleich, 2.3 per cent. of myopic eyes). Detachment seldom occurs before the age of thirty years, becoming more frequent as age advances. It occurs in women more frequently than in men, and in higher grades of myopia much more frequently than in the lower grades. Hertel estimates the proportion between detachment in non-myopic eyes and in axial myopia as one to four. The complications impairing vision are more frequent after the age of forty years.

Fig. 296

Retinal supertraction. (Graefe's Archiv.)

The stretching of the retina is apparently sufficient to produce detachment in some cases, the addition of a traumatism being necessary in others. In cases of chorioretinal adhesions, detachment is much less apt to occur, and if it does occur does not involve the region of the adhesion. An actual break or hole in the retina may result from the stretching (Coats referred to by Parsons).

Macula.—Very varied changes take place at the macula—rarefaction of retinal and chorioidal pigment in the early stages; atrophic spots forming irregular patches; white, branching lines frequently having a general horizontal direction; small hemorrhages, and in some cases capillary tufts (Parsons). Irregular pigment changes occur. A change frequently met with, usually symmetrical, is a circular pigment spot, rarely two, situated in or near the macula, first described by Förster (1862), studied anatomically by Lehmus,[1] who found that the spot is due to hyperplasia of retinal pigment, which may attain a thickness almost equal to that of the retina. The circular patch is preceded by a fibrinous

[1] Inaug. Dissert., Zurich, 1875.

exudate, yellowish white in appearance, with a narrow incomplete pigmented border. The exudate slowly gives way to a patch which may be entirely pigmented or may show a white centre with a defective pigmented border on one side (Figs. 297, 298, 299, 300). Fuchs has recently described these spots, and they have been termed "Fuchs' pigment spots." The patches are permanent, occur in high myopia, and are always associated with greatly impaired vision.

Fig. 297



Fig. 298

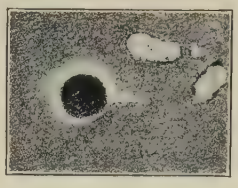

Etiology.—The influences of heredity and of congenital condition on the sagittal axis of the globe has been discussed (see page 647). The additional or determining causes necessary to the development of axial myopia remain to be considered. Up to the age of eight years, myopia is rare (3 to 5 per cent). It develops during the formative stage of the individual, that is, any time previous to the twentieth year of life. Pro-

Fig. 299

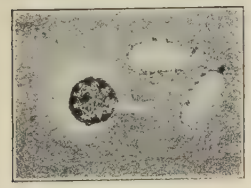

Fig. 300



Fuchs' pigment spots. (Zeitschrift f. Augenheilkunde.)

gressive myopia rarely, if ever, begins after this age. In by far the greater number of cases the progression ceases at about this time of life. It is evident that the final form of the eye is attained at about the age of twenty years, and that in the normal eye the *static* refraction changes but little subsequently.

Occupation.—Myopia is rare among all peoples whose occupations do not require prolonged use of the eyes for close work. It is generally admitted that the greatest percentage of myopia is found in the learned professions, and in those vocations demanding close vision. This is well shown in the statistics of Tscherning.[1]

[1] Arch. f. Oph., xxiii, 1, p. 201.

TSCHERNING'S STATISTICS.[1]

	Total.	Myopes.	Per cent.
Day laborers, peasants, and sailors	2326	57	2.45
Mechanics of various kinds	2861	150	5.24
Mechanics engaged in near work	566	66	11.66
Artists, engineers, and architects	270	36	13.33
Merchants	1009	159	15.76
Professional men	491	159	32.38

The increase in myopia in school children has been studied, and abundant statistics have been collected to show that the increase in myopia is constant during student life. The following table is taken from the statistics collected by Landolt:[2]

Age.	8	9	10	11	12	13	14	15	16	17	18	19	20	21
Erismann, St. Petersburg, Arch. f. Ophth., xvii, 1, 1871.	10.2	14	13	20.6	21.2	28.6	32.6	43.2	40.4	47.2	47.2	40	50	
Pflüger, Luzerne, Switz., Arch. f. Ophth., 1876, xxii, page 63.	2.0	3	6	6.5	6.0	10.0	14.5	26.0	30.0	43.0	55.0	56	40	61.5
Conrad, Leipzig, Germany, 1875.	11.1	..	15	20.0	..	..	25.0	..	40.0	45.0	50.0	55	60	62.2
Loring and Derby, New York, Int. Med. Cong., Phila., 1876.	3.55	..	5	..	10.0	..	..	15.0	..	..	20.0	25		26.8

Percentage of myopia at different years of student life.

The increase in static refraction affects hyperopic, ammetropic, and myopic eyes in common. Thorner[3] draws attention to the peculiar kind of ocular movements in near work, and distinguishes between continuous and discontinuous movements. He shows that discontinuous movements are of necessity employed in reading, as only six letters can be distinctly seen at one stop of the eye. Seven movements are required each second. Much more traction is exerted on the sclera by these constant movements than is exerted by regarding an object at the same distance without change in position. Thus reading, writing, and similar shifting near work are more injurious in progressive myopia than are other forms of near work. This is not prevented by monocular fixation, since the fixing eye undergoes the same movements when performing similar work. It is possible that this in part explains the rarity of progressive myopia in watchmakers and in cutters of precious stones, and its comparative prevalence in those who do much reading and writing.

Myopia is more common in females than in males. In those congenitally predisposed to the development of myopia, conditions impairing the vitality or vigor of the tissues would favor its production. Such conditions are indoor life, a restricted diet, and occupation favoring compression of the eyeball by the extrinsic muscles, such

[1] Landolt, page 448.
[2] Refraction and Accommodation of the Eye, Landolt, English ed., page 441.
[3] Klin. Monatsbl. f. Augen., xlvi, 1, p. 10.

as obtains in long-continued convergence necessary in students and those doing close work during the formative stage of life. In regard to compression by external muscles, it can readily be seen that strong convergence causes a closer application of the external rectus and the oblique muscles to the globe, and that the traction on the sclera must be greater than when the optical axes are parallel, or nearly so. This tension is increased with lengthening of the sagittal axis of the eyeballs as the myopia increases. Since the angle "a" decreases and may become minus, *greater convergence* is necessary. The extra-ocular muscular tension is also increased with increase in the length of the *base line* (see p. 667). The theory of Stilling,[1] who attributes elongation of the sagittal axis of the globe to pressure of the pulley of the superior oblique in orbits of lowered orbital index (brachycephalous individuals), has not been established. Although it has been demonstrated by Hess and Heine[2] that efforts of accommodation do not increase intra-ocular tension, it is a well-known clinical fact that myopia that has continued to increase will become stationary in many cases on correction of an error of refraction, particularly of astigmia. It is very probable that the endeavor to overcome any departure from the normal, either in the condition of the extra-ocular muscles, particularly hyperphoria and exophoria, or errors of refraction, particularly astigmia, will contribute to the development of axial myopia.

Injury as a cause has been reported by Lans.[3] It must be extremely rare.

Position.—The position of the individual while using the eyes for close work undoubtedly exerts some influence in the production of myopia. The sitting posture with the head bent forward may in some cases cause moderate venous congestion. Long hours in school and employment at close work necessitating the sitting posture encourage the development of axial myopia. The theory of Horner, supported by Emmet, Paulsen, and Weiss, that a short optic nerve by traction on the posterior segment of the globe in rotation contributes to axial elongation of the globe is of doubtful value. In 200 postmortems made by Stilling the condition of traction was found bût seldom. Schnabel and Hess do not accept the theory.

Degree of myopia.	Distance of the punctum remotum in centimeters.	Increase in length of myopic eye in millimeters in axial myopia.
0.5	200.0	0.16
1.0	100.0	.32
2.0	50.0	.66
3.0	33.33	1.00
4.0	25.0	1.37
5.0	20.0	1.74
6.0	16.66	2.13
7.0	14.28	2.52
8.0	12.5	2.93
9.0	11.11	3.35
10.0	10.0	3.80

(Hartridge.)

[1] Unter. u. d. Entsteh. d. Kurzsichtigkeit., Weisbaden, 1887.

[2] Arch. f. Ophth., xlvi, 1898.

[3] Ophth. Rev., xvi, p. 204.

Axial elongation of the anterior segment of the eyeball, as by annular scleritis, occurs rarely. In some cases the lens as well as the cornea is advanced. In almost if not quite all cases opacities of the cornea or of the lens, or both, develop in connection with the scleritis. Vision is impaired in proportion to the obstruction to the passage of rays of light.

Chorioid.—The lamina vitrea presents defects in high myopia consequent on the stretching which it undergoes. The choriocapillaris, the small veins and arteries disappear in part or wholly, and but few of the larger vessels remain in the area of the staphyloma.

Sclera.—The changes in this membrane may present a sharply defined ectasia; as a rule, the enlargement of the globe is not confined to the posterior pole of the eye, but extends to the insertion of the recti muscles. The enlargement is not necessarily uniform. The sclera is thinnest posteriorly.

Ciliary Muscles.—In high axial myopia the ciliary muscle is longer but not so thick as the normal. It consists largely of meridional fibers (Brücke's muscle), the circular fibers (Müller's muscle) being reduced in number.

Vitreous.—Opacities appear in the vitreous in almost all cases of high axial myopia, being more numerous in advanced life. They are said to originate from the chorioid as a result of its deterioration. It is indisputable that they may also originate from the vessels of the ciliary processes. Posterior detachment of the vitreous is the rule. Cavities which are occupied by fluid may form in the vitreous body.

Cornea.—The cornea is often flatter than in emmetropia. Rupture of Descemet's membrane has been reported.[1] The writer has observed a similar case.

Malignant Myopia.—Malignant myopia is a condition of progressive myopia in which the axial enlargement progresses rapidly and reaches an extreme degree. The changes previously described affecting all of the tissues of the eye are excessive and impairment of central vision profound. Malignant myopia is probably accompanied by low-grade inflammatory changes affecting all of the tissues at the posterior pole of the eye in the greater number of cases. Foci of exudation and haziness of the vitreous are not infrequently seen. It is difficult to determine whether this is a result or a cause of the rapid development of the axial elongation. The term "sclerochorioiditis posterior," which has been indiscriminately applied to the changes accompanying progressive myopia, should be used only in the cases in which there is indisputable evidence of inflammatory changes.[2] In all cases of high axial myopia of the progressive form, vision is defective largely on account of the injury to the percipient layer of the retina by stretching, as previously mentioned. In some cases the

[1] Fleischer, Klin. Monatsbl. f. Augenheilk. January, 1906.

[2] In by far the greater number of cases of progressive myopia, the changes noted in chorioid, retina, and optic nerve are simple atrophic changes due to the stretching of the fibrous membrane, the sclera. There is, with few exceptions, no exudation, no infiltration of small cells; in short, no evidence of inflammation.

opacities of the vitreous contribute to the impairment of vision. Contraction of the fields of vision, various forms of relative and complete scotomata, and irregular enlargement of the blind spot occur.

Tension.—In progressive myopia the tension is seldom minus. It is often normal, but in many cases, particularly in the higher degrees of myopia, is slightly plus. The writer has examined many myopic eyes with a view to determining this point, and has been struck with the relative frequency of slight increase of tension over the normal. Pronounced glaucoma with axial myopia is not very rare, but is of course very much less frequent than in axial hyperopia.

Curvature Myopia.—Increased curvature of the cornea or of one or both surfaces of the crystalline lens may produce myopia. Variations in the radius of curvature of the cornea from 7 to 8.5 mm. occur in emmetropic eyes (Mauthner). This implies a variation in sagittal axes from 22.25 mm. to 26.24 mm. The length of the radius of curvature in myopia is, on the whole, slightly shorter than in emmetropia or hyperopia (Mauthner, Nordensen, Stilling, Valk), but in many cases the radius is as long, and in some, especially in high degrees of axial myopia, the radius may be longer (cornea flatter) than in the emmetropic eye.

Myopia from corneal curvature is in the greater number of cases due to conical cornea (see page 303).

Myopia is sometimes due to lenticular curvature. It accompanies lenticonus anterior and posterior (see page 574) and ectopia lentis; in the last case the lens is more nearly spherical than in the normal eye. An approach to the spherical in the shape of the lens also occurs in young individuals with relaxation of the zonula, which sometimes obtains after injury, and, rarely, during iridocyclitis.

Index Myopia.—Increase in the refractive index of the cornea, aqueous, or lens, or decrease in the index of the vitreous. Increase in the index of refraction of the cornea has not been determined. A myopia of 1 to 2 D. as an accompaniment of iritis has been recorded by a number of observers. It is attributed to an increase in the index of the aqueous (Schapringer), but the calculations of Hess, who has shown that the index of the aqueous would have to be raised to equal that of the cornea to produce a myopia of 1.5 D., render this improbable. Myopia due to increase in the index of the aqueous in jaundice and in diabetes has also been reported. These cases are also open to the same criticism.

Lenticular index myopia is not uncommon in advanced life on account of sclerosis of the lens, particularly of the nucleus. The myopia is of all degrees up to 10 D. (Landesberg). The most extreme case observed by the writer was 6 D. in an individual of sixty-two years. Incipient cataract was present. Heine (referred to by Parsons) "found the total index of the lens in an old myope to be 1.451 in one and 1.47 in the other eye." There was no axial elongation of the eyes. The myopia in diabetes is due to increase in the refractive index of the lens (Hirschberg, Risley, and others). It is transient in nature, appearing in some cases of diabetes on marked increase of sugar in the urine, disappearing when the amount of sugar decreases. Judging from the

number of reported cases the development of myopia in diabetes is very infrequent.

Vitreous index myopia has not been determined.

Treatment of Ametropia.—In all ametropic conditions the error of refraction should be corrected. (See Refraction.) In hyperopia and astigmia little more can be done. Operations on the cornea designed to produce a cicatrix to neutralize an existing high astigmia have been undertaken,[1] but the necessity for such procedures is not great and the result not sufficiently constant to warrant their employment. In the treatment of non-progressive axial curvature and index myopia the correction of the ametropia and the treatment of any general condition that may stand in a causative relation (as diabetes) are all that is required. An eye with progressive myopia is a diseased eye and should always be so regarded. It requires first the careful correction of the ametropia. The influence of such correction on the course of the myopia is always beneficial, not only because of the improvement in vision but also because of its effect on the axial elongation. The astigmia, if any, should be fully and accurately corrected. Much discussion has been indulged in regarding the advisability of a full or partial correction of the myopia. The decision of the question depends on a number of conditions, which will be considered later.

The condition of the extra-ocular muscles should be determined. In a large percentage of myopes divergence appreciable on inspection or on examination by the phorometer or Maddox rod is apparent. Any departure from the normal should be carefully studied and corrected, either by use of prisms or by operative procedure if indicated.

In all cases of progressive myopia it is desirable that the general condition of the patient should be made and be kept as good as possible. The diet should be proper, nutritious, and abundant. Sufficient suitable exercise out-of-doors should be insisted upon. In short, everything should de done to insure a vigorous healthy condition of the tissues of the body. Examinations of the blood and urine should be made in the search for indications for treatment. The use of the eyes should be carefully regulated. If necessary, all close work should be interdicted and use of the eyes by artificial light forbidden. With students the number of hours in school or at close work should be regulated. In not a few cases it is advisable to insist on an exclusively out-of-door life away from the city. Progressive myopes should, as a rule, be advised to avoid the learned professions and vocations that require much reading and writing.

Operative Treatment.—In myopia above 9 D. the vision is seldom normal. Tenotomy of the external rectus has been suggested for the arrest of progressive myopia. Harlan[2] divided the external rectus in a boy of sixteen years with progressive myopia. Seven years later there had been no increase in the myopia. Velpeau operated by tenotomy of the recti and oblique muscles to prevent the progress of myopia by

[1] Lucciola, Archiv. d'opht., xvi, 10, page 360.

[2] Am. Ophth. Soc., 1885.

relieving pressure of these muscles on the globe. The operation was abandoned for obvious reasons.

Removal of Crystalline Lens in High Myopia.[1]—*Indications.*—The object of the operation is the improvement of vision, and it should not be practised unless the vision of the eyes to be operated upon, with the refraction corrected, is less than that required for the ordinary vocations of life ($\frac{20}{40}$ and less).

Degree of Myopia.—Fukala would operate if the myopia was progressive and equalled 10 D. at the age of ten years; otherwise he would not operate unless the myopia equalled 12 D. or more. The greater number of operators require a myopia of 12 to 15 D.

Age of Patient.—The most conservative put the age limit at thirty-five years. Fukala,[2] who had then operated 162 times, writes that the operation may be done at the age of sixty to sixty-five years.

Condition of Eye.—Many operators hold that marked changes at the macula contraindicate operative procedure, particularly if the changes are progressive. Opinions are divided regarding the effect of the operation on intra-ocular changes. Fukala does not think that they are greatly influenced. Sattler has operated for the prevention of progression. In 114 cases operated on by von Hipple, many had chorioidal lesions. The result of the operation was favorable in these cases. He believes that the progress of the myopia is limited, but that the development of the chorioiditis and detachment of the retina are not prevented. Chorioidal affections do not contraindicate the operation.[3] If one eye is blind, operation should not be performed. Both eyes should be operated on only when binocular vision is possible, or when confusion from unequal images is very marked. If opacities exist in both lenses, operation may be undertaken.

Operation.—Discission in the young, and subsequent removal of the lens substance by linear extraction after the age of twelve to sixteen years without iridectomy, are the operations that give the best results up to the time when the lens substance can be readily broken up (thirty to forty years). After this age, extraction should be employed.

Results.—The permanent increase in vision in favorable cases is one to fivefold.[4] Sidler-Huguenin[5] reviewed 100 cases in which the operation

[1] According to Dujardin, this operation was first practised by the Abbé Desmorceaux in France in 1776, but did not come into general use. It was suggested by Beer in 1817, and in 1858 was practised by Weber to some extent. At the session of the Heidelberg Congress, 1858, Mooren urged the operation in high degress of myopia, being actuated to do so by the favorable results obtained by the removal of cataract in a case of myopia of high degree. Pflüger quotes Mauthner as saying in 1876: "Wuste ich eine Staar Operation, die ungefährlich ist so wurde ich dieselbe allen hoch gradigen myopen anrathen." Von Graefe and Donders advised against the operation—Von Graefe because he feared that the operation would make the intra-ocular conditions worse, and Donders because of the necessary loss of accommodation. The operation was practised but little until it was revived by Fukala. In 1887 Fukala removed the lenses in two cases of high myopia and presented the patients at a meeting of the Vienna Medical Society in 1889. The vision of the patients had been greatly improved and the changes in the eyeballs had not progressed. The advantages of the operation in suitable cases are now fully recognized.

[2] Trans. Sec. on Oph., XII Internat. Med. Cong., Moscow, 1897.

[3] Vossius, Beitr. z. Augenheilk., xxix, p. 1.

[4] Panse, Zeit. f. Augenheilk., February and March, 1906,

[5] Ophthalmoscope, September, 1906.

was performed by Prof. Haab during the ten years—1892 to 1902. Of these, all but 15 per cent. had been benefited. Of 75 cases examined two to twelve years after operation, the vision in 57 was increased; in 2 there was no change; in 8 the vision was worse; and in 8 the vision was nil. The fundus lesions had increased 10.5 per cent. Vitreous opacities and retinal hemorrhages had increased. Detachment of the retina occurred in 5 per cent. of the cases. As far as can be judged by statistics derived from various sources, detachment of the retina after operation is slightly more frequent than in high myopia without operation. The highest proportion estimated is as 1 to 4 (Frost).

Refraction.—The effect on the refraction varies from 10 to 26 D. It is greater in the cases with greater axial myopia.

Accidents.—The accidents attending operation are the same as obtain in discission and in linear extraction for other purposes—infection, iritis and cyclitis, formation of pupillary membrane, and incarceration or prolapse of iris may occur.

The operation has not fulfilled the expectations of those who closely followed Fukala, but it is nevertheless an important and valuable aid in the therapy of myopia. It should be employed only in carefully selected cases. The sole purpose is to improve vision. The operation does not materially modify the progress of the myopia or its pathological changes, and is not without danger.

Polyopia.—Multiple vision, usually due to a slight difference in the refraction of the principal segments of the lens, which gives rise to the formation of separate retinal images, is sometimes encountered. When the ametropia is uncorrected these images are more widely separated and are distinguishable. When the ametropia is corrected the images are so nearly superimposed that they are not recognized.

ACCOMMODATION.

The ability that the eye possesses of changing its refraction so that rays of light coming from different distances can be focused on the retina is termed the *power of accommodation*. The normal emmetropic eye is capable of forming distinct images on the retina of objects at "infinity" (nominally at twenty feet and beyond), and, at will, to form distinct images of objects much nearer by changing the point of regard (*point of fixation*). This power is limited. The distance between the farthest point, *punctum remotum*, or p. r., and nearest point, *punctum proximum*, or p. p., at which objects can be seen distinctly, is termed the *range* or *amplitude* of accommodation.

Mechanism of Accommodation.—Various optical instruments possess the possibility of a change in focus (telescope, opera glasses, etc.). With these the length of the instrument is changed to accommodate it to the position of the posterior conjugate focus (see page 93) of the "objective." The length of the eyeball is fixed; consequently some other mechanism must be accountable for its power to change

the focus. This power resides in the ciliary muscle (see page 62), which, by its contraction and relaxation, so changes the shape of the crystalline lens that its *refractive* power is changed and rays of light that pass through it from whatever distance within the range of accommodation are brought to a focus on the retina at the will

Fig. 301

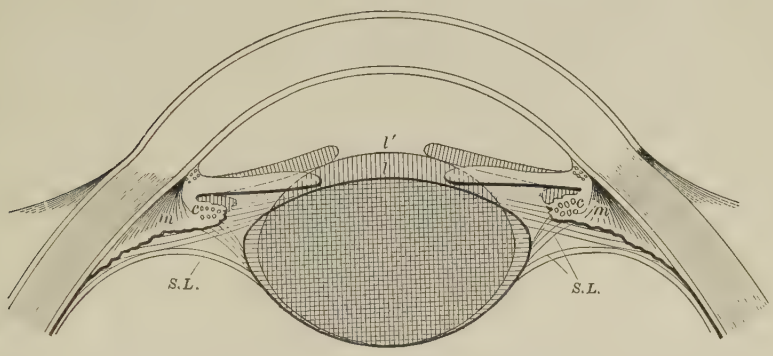

Showing the mechanism of accommodation. The horizontally shaded lens and the unshaded ris show the position of the parts when at rest; the vertically shaded lens and iris show the position during accommodation for a near-point: *m*, meridional muscle; *c*, circular muscle; *S. L.*, suspensory ligament. (After Landolt.)

of the individual (Helmholtz's theory,[1] confirmed by Donders, Hess and Grossmann). The changes that the crystalline lens undergoes in acts of accommodation have been graphically depicted by Landolt (Fig. 301). When the ciliary body is at rest the point of inser-

Fig. 302

Fig. 303

Catoptric images in accommodation. (Helmholtz.)

Fig. 302.—Position of the images in accommodation for distant objects. Fig. 303.—Position of the images in accommodation for near objects: *a*, corneal image; *b*, image from anterior surface of lens; *c*, image from posterior surface of lens.

tion of the suspensory ligament in the ciliary body, ciliary processes, pars ciliaris retinæ, and points of the ora serrata are further removed from the crystalline lens than at any other time. The removal of these parts causes a tightening of the suspensory ligament which produces traction on the lens capsule at the equator of the lens. The lens sub-

[1] Tscherning is of the opinion that ciliary *contraction* produces *traction* on the suspensory ligament, increases rather than diminishes the equatorial diameter of the lens, and increases the refraction by converting the anterior and posterior surfaces of the lens into the form of paraboloids.

stance in young individuals is elastic and the result of traction at the equator is to increase the equatorial diameter of the lens at the expense of the diameter at the poles of the lens, decreasing the acuity of curvature of the anterior and posterior surfaces. Since the refraction of a lens is in direct proportion to the acuity of the curvature of its surfaces, the refraction of the crystalline lens when the ciliary muscle is at rest is at a minimum. When the ciliary muscle contracts, the tissues of the ciliary body and the anterior zone of the chorioid, bearing with them the attachments of the suspensory ligament as far back as the ciliary body, are brought slightly forward toward the attachment of the ciliary body to the sclera (the annular ligament). The ciliary body is thickened and the suspensory ligament consequently relaxed; the natural elasticity of the lens, together with the physical property of gelatinous and fluid bodies, causes the lens to assume a more nearly spherical shape, to increase the acuity of the curvature of its anterior and posterior surfaces and, consequently, to increase its power of refraction. The degree of change in the crystalline lens is regulated, within certain limits, by the will of the individual. The change in the curvature of the lens affects the anterior surface (the surface lying in the aqueous humor) much more than it does the posterior surface (the surface lying against the vitreous body).

The eye may adapt itself to see objects distinctly at any point within the range of accommodation, but it cannot adapt itself to two points at the same time.

The degree of accommodation exerted to see distinctly at any distance is equal to a lens the principal focal length of which equals the distance from the nodal point of the eye to the point of regard (fixation). Thus if the emmetropic eye is accommodated for a distance of one meter the increase in the refraction of the eye corresponds to a lens whose principal focal distance is one meter, equivalent to a lens of 1 D. It is therefore possible, and convenient many times, to express the degree and also the range (amplitude) of accommodation in *lens dioptres.*

The range of accommodation diminishes with increase in the age of the individual, being fairly constant in individuals of the same age. The range of accommodation at various ages is shown in Fig. 304. The punctum proximum is added at the side.

The power of accommodation is approximately the same in ametropia as in emmetropia. In myopia it is sometimes *less,* in hyperopia sometimes *more* than in emmetropia. If with the ciliary body at rest[1] objects at a distance of twenty feet or more are in focus the punctum remotum (p. r.) is said to be at infinity, the eye emmetropic. If with the ciliary muscle at rest the punctum remotum is at a point less than twenty feet—at a finite distance (objects beyond this point blurred)—the p. r. is said to be positive or plus, the amount of plus accommodation corresponding with a lens whose principal focal distance equals the

[1] It is often necessary to paralyze the ciliary muscle by means of a cycloplegic in order to put it in a state of rest.

distance from the nodal point of the eye to the p. r. This is the condition in myopia. If with the ciliary body at rest objects at a distance

Fig. 304

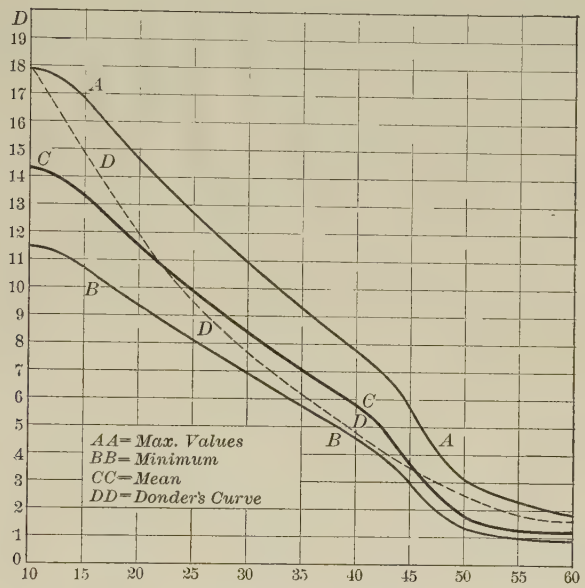

Range of accommodation in *D*, at different ages as determined by Duane, near-point being measured from anterior focus of eyes=13 mm. in front of cornea. *A A*, maximum limit in normal cases; *B B*, minimum limit; *C C*, mean values; *D D*, mean as found by Donders.

Age.	Mean.	Minimum.	Maximum.	Age.	Mean.	Minimum.	Maximum.
10	14.2	11.5	18.0	36	6.9	5.5	9.0
11	14.1	11.5	17.5	37	6.7	5.4	8.7
12	14.0	11.0	17.5	38	6.5	5.2	8.4
13	13.7	11.0	17.0	39	6.2	5.0	8.2
14	13.4	10.5	17.0	40	6.0	4.8	7.8
15	13.1	10.4	16.5	41	5.6	4.5	7.4
16	12.8	10.2	16.0	42	5.2	4.2	6.9
17	12.5	10.0	15.5	43	4.8	3.9	6.4
18	12.2	9.7	15.5	44	4.3	3.5	6.0
19	11.9	9.5	15.0	45	3.8	3.0	5.4
20	11.6	9.2	14.5	46	3.4	2.7	4.9
21	11.3	9.0	14.0	47	3.0	2.4	4.4
22	11.0	8.8	13.5	48	2.5	2.0	4.1
23	10.7	8.6	13.5	49	2.2	1.7	3.4
24	10.4	8.3	13.0	50	1.9	1.5	3.0
25	10.1	8.1	12.5	51	1.7	1.3	2.5
26	9.8	7.8	12.5	52	1.5	1.2	2.3
27	9.5	7.6	12.0	53	1.4	1.1	2.0
28	9.2	7.4	11.5	54			
29	8.9	7.1	11.1	to	1.3	1.0	1.9
30	8.6	6.9	11.0	57			
31	8.3	6.7	10.5	58			
32	8.0	6.4	10.1	to	1.2	0.9	1.8
33	7.7	6.2	9.8	62			
34	7.4	5.9	9.5	63			
35	7.2	5.7	9.3	to	1.1	0.9	1.5
				70			

can be seen distinctly only when plus glasses are placed before the eyes the p. r. is said to be at a negative distance, or minus, the degree of minus accommodation corresponding to the value of the lens required to bring the focus up to infinity.

In determining the range of accommodation it is convenient to place the punctum remotum at infinity. This is done by rendering the vision (with the ciliary muscle at rest) normal at a distance of twenty feet (6 m.). The large test letters used in determining acuity of vision are suitable test objects for this purpose.

The near-point may be determined by means of the smallest Snellen or Jager test type or by means of the rod optometer.

Since the range of accommodation varies but slightly in ametropia and emmetropia, it follows that in myopia with a plus p. r. the p. p. is closer to the eye than in emmetropia, and in hyperopia with a minus p. r. the p. p. is farther from the eye than in emmetropia. It is therefore possible to judge roughly the refraction of the eye by the position of the p. p.

The amplitude of accommodation exerted by one eye alone, the other eye being excluded, is termed *absolute accommodation;* that exerted by both eyes together, *binocular accommodation.* The amplitude of accommodation in the former is slightly less than in the latter.

Since the amplitude of accommodation is virtually the same in emmetropia and in ametropia, it follows that the range of accommodation is *placed differently* in relation to the eye in the different states of refraction. The position of the range of accommodation of any eye is termed the *region of accommodation* of that eye.

The *region* of accommodation in ametropes is often so placed that accommodation cannot be exercised to the advantage of the individual. This occurs in high degrees of hyperopia and myopia and in presbyopia. In such cases the position of the region of accommodation must be changed. This is accomplished by the application of suitable lenses.

Angles Gamma and Alpha.—In regarding an object the eye is held in such a position that the image of the object falls on the macula lutea. The eye is thus said to "fix" the object. The portion of the object "fixed," the image of which falls on the fovea centralis, is termed the *point of fixation.* A line drawn from the point of fixation through the nodal points (Fig. 305) to the fovea centralis is termed the *line of vision.* A line drawn from the point of fixation to the centre of rotation of the eyeball is termed the *line of fixation.* A line drawn from the centre of the cornea through the centre of rotation of the globe to the posterior pole of the eye is termed the *optical axis.* On this line all the cardinal points of the dioptic system of the eye are located. The apex of the *corneal ellipsoid* does not usually correspond to the centre of the cornea. The long axis of the ellipsoid forms an angle with the line of fixation, the line of vision, and the optical axis (Fig. 305). The angle formed between the line of fixation and the optical axis is termed the *angle gamma.* The angle formed between the line of vision and the long axis of the corneal ellipsoid is termed

the *angle alpha.* In hyperopic eyes both of these angles are increased because of the shortening of the eyeball. In the hyperopic eye the increased temporal position of the apex of the corneal ellipsoid in binocular fixation frequently gives the impression of a divergent squint. In *myopic* eyes the fovea centralis approaches the posterior pole of the eye and may pass to the nasal side of this point. When the angles

Fig. 305

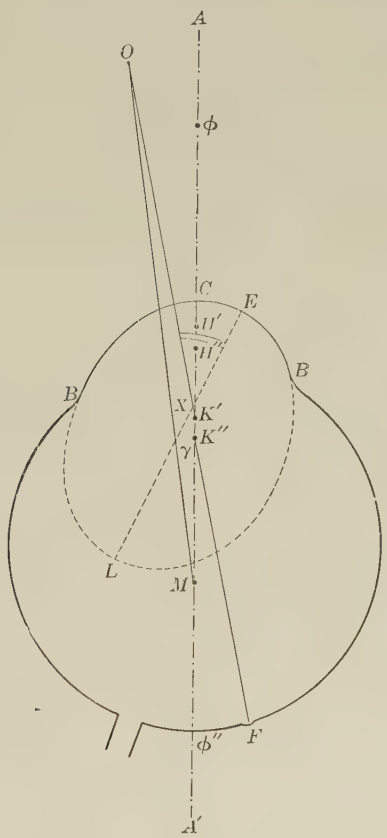

The figure is made very schematic in order that the angles α (alpha) and γ (gamma) may be rendered more apparent. $A\ A'$, optic axis ; ϕ, anterior focus; ϕ'', posterior focus; $H'\ H''$, principal points; $K'\ K''$, nodal points; M, centre of rotation; C, centre of cornea; $B\ B$, base of the cornea; $E\ L$, major axis of the corneal ellipsoid; F, fovea centralis; O, point of fixation; $K'\ O$, line of vision; $M\ O$, line of fixation; $O\ X\ E$, angle α; $O\ M\ A$, angle γ. (Landolt.)

gamma and alpha are on the nasal side of the optic axis and the long axis of the corneal ellipse, respectively, they are said to be *plus* angles; if to the temporal side, *minus* angles. In high myopia the angles gamma and alpha are greatly reduced and may even become minus. When this occurs the appearance of the globe of the myopic eye is that of convergent squint in binocular fixation.

Convergence.—When an object is seen with both eyes at once and the impression of a single object is conveyed to the brain, the image falls on corresponding points of each retina and the individual is said to have *binocular single vision* and *binocular fixation.*[1] If the object so regarded is 6 m. distance or beyond, it is said to be at infinity (see above), so far as the accommodation is concerned. (This is not quite true of convergence. The term infinity as applied to convergence means *parallelism* of the visual lines.) In all cases of binocular single vision the visual lines of the eyes must cut each other at the point of fixation in order that the various points of the image may fall on corresponding points of each retina. Since the distance between the *centres of rotation* of the eyeball is about 64 mm., it follows that in order to have the visual lines cross at the point of fixation the eyeballs must rotate inward to the necessary degree, depending on the distance of the object from the eyeball. This function is known as *convergence.* Since the power of accommodation must be exerted for viewing all objects distinctly inside of infinity (6 m. 20 ft.) and a corresponding crossing of the visual lines must be brought about to maintain binocular single vision, it will be seen that the exercise of these two functions is closely related. However, they are not interdependent. Accommodation may remain unimpaired if convergence is abolished. If one eye is removed the accommodation of the other eye need not suffer. The power of convergence may also be unimpaired when accommodation is abolished. As a matter of fact, a given act of accommodation is almost always associated with a corresponding act of convergence, and vice versa. However, under certain conditions the accommodation can be employed without change in convergence, without loss of binocular single vision. Thus it is found that if an object is fixed with both eyes and seen distinctly a minus lens may be interposed, increasing the accommodation without impairing the distinctness of the image and without a change of convergence; or, if the object is within infinity, a plus lens may be interposed, decreasing the accommodation with the same result. The accommodation thus exerted is termed *relative accommodation.* The increase in accommodation occasioned by the interposition of a minus (concave) lens is termed *positive relative accommodation.* The diminution in accommodation occasioned by the interposition of a plus (convex) lens is termed *negative relative accommodation.* The amount of positive and negative relative accommodation is measured by the highest minus and highest plus lenses that can be interposed without impairing the distinctness of the image. It is found that the relation of convergence to accommodation may also be much disturbed without impairing accommodation. Thus if when an object is properly *accommodated* for a weak prism with base out or in is interposed the eyeball will immediately turn out or in, as the case may be, to correct the deviation

[1] When an object is so regarded that a distinct image is formed on the retina of an eye the object is said to be "fixed" by the eye; also, the object is said to be at the point of fixation, or *point of regard.* If the object is "fixed" by both eyes, the individual is said to have "binocular fixation."

occasioned by the prism. At the same time the object is properly focused, the accommodation remaining unchanged.

The *amplitude* of convergence is the entire convergence that can be put in force. The *range* of convergence is the distance between the far- and the near-points of convergence. If with the convergence at a minimum (the eye at rest) the visual lines are parallel the *far-point* of convergence is at *infinity*. A minimum of convergence may place the far-point within infinity, at a finite distance (visual lines convergent as in convergent strabismus), or beyond infinity (as in divergent strabismus). All amplitude of convergence within infinity is termed *positive convergence*, all beyond infinity *negative convergence*. In all degrees of negative convergence the visual lines, if continued backward, would cross behind the eyeballs. The degree of convergence is expressed in units of convergence, the *meter angle*. The unit of convergence is the angle through which the visual line must pass to reach a point 1 meter from

Fig. 306

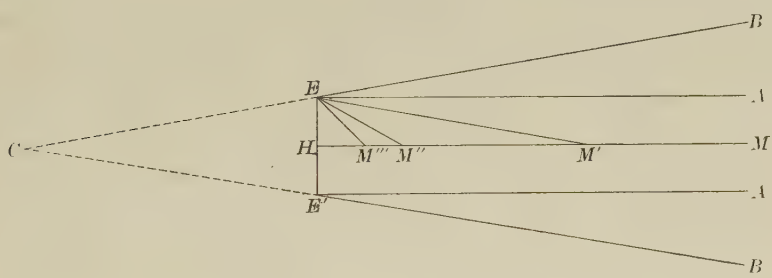

Meter angle in convergence. (After Hartridge.)

the base line on a perpendicular from the middle of the base line (the average length of the base line is 64 mm.; one-half of this, 32 mm., represents the sine of the meter angle in the average individual). If the eye converges to a point $\frac{1}{10}$ meter from the base line it is said to converge 10 meter angles. The deviation in meter angles increases inversely with the distance of the near-point of convergence. The *meter angle* of convergence corresponds to the *dioptre* of accommodation. In emmetropic eyes the expressed action of one implies a similar action of the other. This relation is disturbed in ametropia.

The measurement of the degree of convergence may be made by means of prisms and the deviation of the visual line expressed in the nomenclature of prisms (see page 90).

Acts of accommodation and of convergence are accompanied by contraction of the sphincter pupillæ muscle, causing a diminution in the size of the pupil under normal conditions. This pupillary phenomenon apparently depends more on convergence than on accommodation (see page 123).

CLINICAL VARIETIES OF AMETROPIA.

Hyperopia.—Varieties.—The clinical varieties depend on the relation of hyperopia to accommodation. They are *total hyperopia*—disclosed by the use of a cycloplegic; *manifest hyperopia*—represented by the strongest plus glass that will give distinct vision at infinity (twenty feet and beyond); *latent hyperopia*—the difference between the *total* and the *manifest* hyperopia, due to tonic spasm of the ciliary muscle. The *latent* hyperopia gradually becomes *manifest* as age advances and the range of accommodation decreases, so that at sixty years all is manifest. *Manifest* hyperopia is divided into *facultative* and *absolute*. *Facultative hyperopia* is that part of the manifest that the individual can correct by accommodative effort. *Absolute hyperopia* is that part of the manifest that the patient cannot correct by accommodative effort. In youth the entire manifest hyperopia may be facultative. However, in high degrees of hyperopia the individual may not be able to correct enough of the manifest hyperopia by accommodative effort to focus parallel rays,

Fig. 307

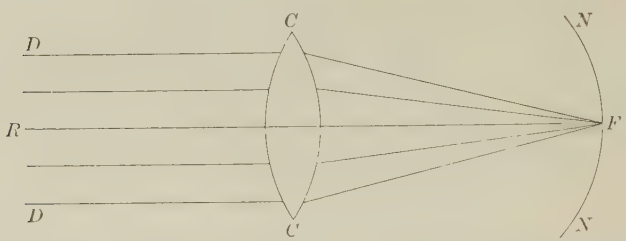

The emmetropic eye. *C C* is a lens representing the cornea and the crystalline lens collectively; *N N* is the retina lying at the principal focus, *F* of *C C* (*F* = posterior focus of the eye). Rays coming from a very distant object, *R*, will be sensibly parallel to one another (thus taking the direction *D C*, *D C*) when they strike the eye, and will hence be sharply focused at *F*, so as to form a distinct inverted image of *R* upon the retina *N N*. The emmetropic eye is, therefore, like a camera which is accurately focused for distance.

If the point *F* on the fundus is illuminated so that it sends out rays in the reverse direction, *F C*, *F C*, these rays will emerge from the eye parallel to one another, taking thus the direction *C D*, *CD*, after passing back again through the crystalline lens and cornea. (Posey and Wright.)

in which case all objects are indistinct. As age advances the facultative passes gradually into the absolute,[1] becoming totally absolute at the fifty-fifth to sixtieth year. The hyperope's p. p. is farther from this eye than the emmetrope's, requiring greater effort of accommodation for vision at all distances. In low degrees of simple hyperopia, if the individual is in fairly good health, this extra effort gives him no inconvenience until the reserve power of accommodation falls below that required for easy vision, usually until the p. p. approaches 8 inches.

[1] Donders makes a third division of the manifest, namely, relative, which the hyperope corrects by an effort of accommodation assisted markedly by convergence; the eyes squint inward.

The *amplitude* of accommodation (see p. 660) in the hyperope is often slightly in excess of the emmetrope, possibly because the demand on the ciliary muscle for more work has increased its power, but the law governing the decrease in amplitude of accommodation operates on all eyes approximately alike, consequently the distance of the p. p. rendering close work difficult without aid is reached earlier in the hyperope than in the emmetrope.

Fig. 308

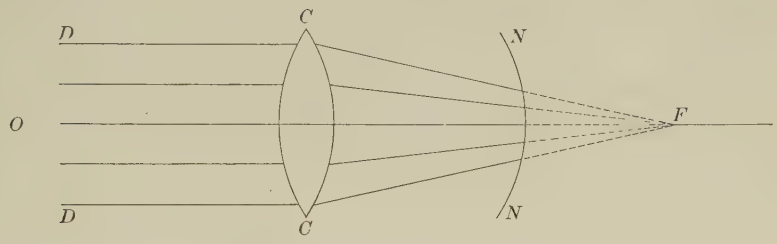

The hyperopic eye. *C C*, lens representing the cornea and crystalline lens collectively. *F*, the principal focus of *C C*, or of the eye, behind the retina *N N*. Rays emanating from a distant object, *O*, and hence parallel to one another before striking the eye (taking, therefore, the course *D C*, *D C*), will, after refraction through *C C*, be converged toward *F*. They will hence strike the retina before they come to a focus. The eye is, therefore, not adjusted for *O*. The amount by which it is out of focus—*i. e.*, the amount of its hyperopia—is measured by the distance between *N N* and *F*. (Posey and Wright.)

Symptoms.—Asthenopic symptoms develop early in the hyperope. He first complains of nervous disturbances, headaches—usually fronto-temporal, often developing after reading or doing close work. Reading and study become distasteful; the patient feels much better when out of doors and free from the necessity of using the eyes for close work. These symptoms are excited more readily and become more pronounced if for any reason the health is impaired. The acuity of vision is excellent, except in absolute hyperopia, occurring in early life, in which condition the patient has never been able to form distinct images on his retinæ, and in consequence of a failure of stimulus for the proper development of vision—namely, distinct images—vision remains below the normal. Ordinarily, in reading, the hyperope, to reduce accommodative effort, holds his page at a greater distance from the eye than the emmetrope, but in the case of absolute hyperopia in the young it not infrequently happens that reading is accomplished, usually with difficulty, by holding the page close to the eye. In this instance the patient more than compensates for the blurring by the increase in the size of the image.

Treatment.—In all cases of hyperopia except the very lowest degrees, the necessary increase in accommodation effort over the normal is accompanied by increase in convergence effort, which in some cases leads to the development of strabismus. In many cases the convergence near-point is closer to the eyes than the accommodation near-point (relative hyperopia). Whether *glasses* correcting the *total* hyperopia are prescribed or not must depend on the judgment of the examiner. In young individuals it not infrequently happens that they

do not readily tolerate a correction of the *total* hyperopia. The habit of ciliary spasm is not readily lost, and in consequence the images which before were sharply cut and intense are now slightly blurred a part if not all of the time, and present a pale or less intense appearance which the patient becomes accustomed to with difficulty. It is, therefore, often better in moderate degrees of hyperopia, if there is no tendency to squint, to give a correction 0.25 to 0.75 D. less than the total. In all cases of marked esophoria and strabismus, either periodic or confirmed, a full correction should be given and its constant use insisted upon, in order to remove the necessity for excess of convergence to aid accommodation effort.

The suggestion regarding slight undercorrection holds good in all cases of hyperopia, whether combined with astigmia or not, in which there is no *static excess of convergence.*

In correcting the higher degrees of hyperopia, 3 D. and above, it not infrequently happens that the patient is annoyed by the prismatic effect of the lenses. The difference in the length between the visual lines, as they cut the spectacle lenses in distance vision (visual lines parallel) and in reading (visual lines convergent to 13 to 15 inches) is 3 to 4.5 mm., depending on the distance of the spectacle lens from the eye, the distance of the point of fixation from the base line, and the length of the base line.[1] The degree of prismatic effort so produced is indicated in the following table, abbreviated from Jackson's table:[2]

Decentring Equivalent in Millimeters to a Given Refracting Angle (Index of Refraction 1.54).

Lens.	1°	2°	3°	4°	5°	6°	8°	10°
1 D.	9.4	18.8	28.3	37.7	47.2	56.5	75.8	95.2
2 D.	4.7	9.4	14.1	18.8	23.6	28.2	37.9	47.6
3 D.	3.1	6.3	9.4	12.6	15.7	18.8	25.3	31.7
4 D.	2.3	4.7	7.1	9.4	11.8	14.1	18.9	23.8
5 D.	1.9	3.8	5.7	7.5	9.4	11.3	15.2	19.0
6 D.	1.6	3.1	4.7	6.3	7.9	9.4	12.6	15.9
7 D.	1.3	2.7	4.0	5.4	6.7	8.1	10.8	13.5
8 D.	1.2	2.3	3.5	4.7	5.9	7.1	9.5	11.9
9 D.	1.0	2.1	3.1	4.2	8.2	6.3	8.4	10.5
10 D.	0.9	1.9	2.8	3.8	4.7	5.6	7.6	9.5
15 D.	0.6	1.3	1.9	2.5	3.1	3.8	5.1	6.3
20 D.	0.5	0.9	1.4	1.9	2.4	2.8	3.8	4.8

If the lenses are perfectly adjusted to the eye for distance vision the prismatic effect with lenses of +3 D. for the reading distance would be approximately 2°, of +4 D. 3° with the base out—a condition calling for considerable extra effort of convergence, enough to produce decided asthenopic symptoms in some individuals. This can be readily adjusted in presbyopes, as the distance between the optical centres in the lenses for distance vision can be of proper length for the passage of parallel

[1] The angle formed between parallel lines and the lines that converge to the point of fixation is computed from the points of rotation of the globes. The length of the arc is measured at the point where the visual line cuts "the spectacle line." This is approximately 27 mm. from the centre of rotation of the eyeballs. (See diagram 309).

[2] Trans. Am. Ophthal. Soc., 1889.

rays, and in the glasses for reading of proper length for rays as they diverge from the reading distance. In those who are not presbyopes the problem is not so easy of solution. A satisfactory compromise can sometimes be effected by dividing the difference between what may be termed the *spectacle base line* for distance and near vision in the glasses that are worn continuously; but in some cases either a "paster" (see page 706) containing a prism of sufficient refractive power must be added to the lower part of the lens, base in, to correct the prismatic effect of the part of the lens through which the patient must look when reading, or a pair of glasses properly constructed for reading and close work must be obtained in addition to those for distance. The matter of the proper centring of lenses in the correction of high degrees of hyperopia is of much importance.

Fig. 309

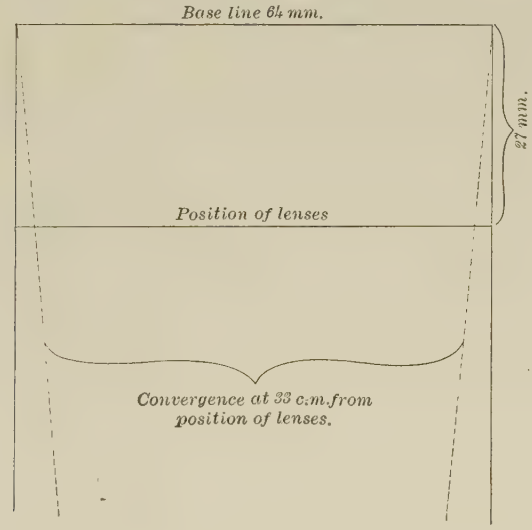

With a "base line" of 64 mm., the distance between the optical centres of lenses for distance vision should be 63 mm.; for a reading distance of 33 to 45 cm., 59 mm.

Myopia.—Simple myopia presents conditions more favorable for easy vision. If the myopia does not exceed 3 D. the patient seldom suffers from eye strain. The only inconvenience experienced, as a rule, if the extrinsic eye muscles are normal, is indistinct distance vision. The rule in myopia of moderate degree is to prescribe the weakest minus glass that will give maximum distance vision, and to *advise its constant use.* It must be remembered that in myopia the angle α (alpha) decreases in proportion to the degree of axial myopia, and that in high degrees of axial myopia it may become "minus." This necessitates a greater convergence of the optic axes and a consequent greater effort on the part of the internal recti muscles than obtains in other states of the refraction.

The necessity for increased convergence increases with increase in the degree of myopia. In axial myopia a number of influences operate to make the conditions unfavorable and eventually impossible for the continuation of *binocular fixation* (equivalent to binocular single vision). (1) The impulse, in the interest of distinct distance vision, is to abolish the effort of accommodation for any distance beyond the punctum remotum. This means in a myope of 1 D., beyond one meter; in a myope of 10 D., beyond 10 cm. The result is that the influence of accommodation on convergence is not in the direction of increased but of decreased convergence. (2) The elongation of the eyeball renders marked convergence much more difficult than it is in emmetropia, because of the necessary greater disturbance of the tissues immediately surrounding the eyeball. (3) The diminution in the angle "a" also makes a greater degree of convergence necessary than would obtain if this angle was not affected. In almost all cases of axial myopia insufficient action of the interni obtains either for distance and near

Fig. 310

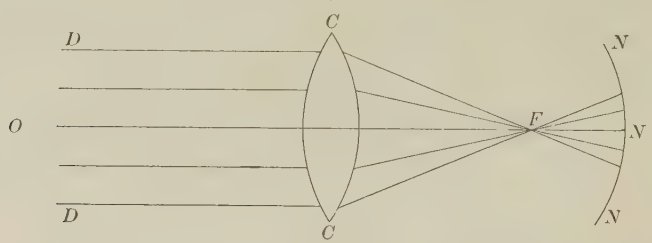

The myopic eye. *C C*, lens representing the cornea and crystalline lens of the eye collectively. *F*, the principal focus of *C C*, or of the eye, lying in front of the retina *N N*. Rays emanating from a distant object, *O*, and hence parallel to one another (taking the course *D C*, *D C*) when they reach the eye, are focused by *C C* at *F* in front of the retina. The eye is, therefore, not adjusted for *O*. The amount by which it is out of focus—*i. e.*, the distance between *F* and *N*—measures the amount of myopia. (Posey and Wright.)

vision or for near vision, and binocular fixation is proportionately less frequent as the axial myopia increases in degree. Fortunately, the loss of binocular fixation in these cases does not often produce diplopia.

In myopia lenses that are perfectly centred for distance vision have the effect of prisms with bases in when the eyes are used for near work (point of fixation is at the reading distance). The effort of the interni is assisted by this position of the lenses, which is, of course, salutary in all cases in which the interni are deficient in convergence power. Much has been written regarding the *full correction* of myopia. Many writers urge full correction in every case in which it is possible to maintain it, on account of its supposed favorable influence on progressive myopia. The consensus of opinion is in favor of the early full correction of myopia, even in cases of 10 D. or more if the glasses are well borne. Myopes with undercorrection are prone to look obliquely through their lenses in order to increase the refraction of the lens. At the same time, as

pointed out by Jackson,[1] the astigmic effect of the lens is also increased, causing increase of ciliary contraction. It is probable that undercorrection, under these conditions, is conducive to increase in the myopia.[2]

The writer is in full accord with those who advocate *early* full correction. However, not every case of myopia will tolerate full correction. In regard to the use of glasses, myopes may be divided into three classes: (1) Those to whom full correction may be given for all purposes. These are the cases in which not more than two-thirds of the power of accommodation will be employed in doing close work when the glasses are worn; the use of glasses obviates the necessity for undue convergence, thus lessening pressure of the external muscles, which pressure is presumably one of the causes of the progression of myopia. (2) Cases in which a full correction for distance can be used with comfort, but whose reserve of power of accommodation in doing close work would be less than one-third. These could not do close work comfortably with full correction. Patients in this class must of necessity have glasses for close work that correct less of the myopia than do those for distance vision. (3) Cases in which the glasses for near vision only can be worn with comfort. These are the cases of high myopia in which the p. r. is extremely close to the eyes. In these cases the full correction so reduces the size of the image *over that to which the patient has been accustomed*[3] that the benefits of clear distance vision are more than outweighed by the annoyance occasioned. Glasses that will remove the p. r. to the ordinary reading distance, namely, 33 to 40 cm., will often be worn with perfect comfort, and will be preferred for all distances. If clear distance vision is required at times, a glass may be provided in any form desired for that purpose. In most cases a bifocal lens in which the segment for distance vision is placed above and is small is very serviceable.

Astigmia.—Varieties.—1. Simple: (*a*) *Hyperopic,* in which one of the *principal meridians* is emmetropic, the other hyperopic; (*b*) *myopic,* in which one of the meridians is emmetropic, the other myopic.

2. *Mixed astigmia,* in which one of the principal meridians is myopic, the other hyperopic.

3. *Compound hyperopic astigmia,* in which both principal meridians are hyperopic, one to a greater extent than the other.

4. *Compound myopic astigmia,* in which both principal meridians are myopic.

5. *Irregular astigmia.*

The proportion of astigmia in ametropia, occurring in the writer's

[1] Trans. Sec. on Oph. A. M. C., 1877.

[2] Statistics confirming the beneficial effect of full correction are increasing Roscher (Klin. Monat. f. Augen., xl, 191) reports 40 cases observed by Ruckert, which were fully or very slightly undercorrected. Of these, 28 remained stationary. Of 18 similar cases undercorrected, only 2 remained stationary. Seggel (Graefe's Arch. lvi., 3) records an experience in correcting myopia in school children extending over a period of twenty-two years. During the last six years full correction was given, 2070 myopes were prescribed for. Of those given full correction, 43.4 per cent. remained stationary. Of those with undercorrection, 22.5 per cent. remained stationary. The beneficial influence was most pronounced between the ages of ten and fourteen years.

[3] As is well known the actual size of the image is not less than in the emmetropic eye.

practice, is approximately 85 per cent. Marlow[1] reported 86 per cent. in 1977 eyes examined by him.

In prescribing glasses for the correction of astigmia the total astigmia, as determined at a distance of 20 feet (6 m.) should be corrected. This is a rule to which but few exceptions should be made. All degrees of astigmia impair the distinctness of the retinal image. Astigmia is the most frequent cause of headaches and general asthenopia. In sensitive individuals even 0.12 D. may produce asthenopic symptoms. It is therefore necessary to be exact in the correction of this error of refraction. Not only is it necessary to exactly correct the amount of astigmia, but it is also very necessary to have the axis of the correcting lens in the proper meridian.

Axis of Astigmia.—In regular astigmia (see page 648) the meridian of least refraction—the meridian in which the axis of a minus cylinder should be placed—is usually horizontal or nearly so, "*astigmia with the rule.*" This term may be applied conventionally to astigmia in which the variation of this meridian is not more than 20 degrees from the horizontal. The meridian of least refraction when vertical or nearly so (conventionally, 20 degrees from the vertical) is said to be astigmia "*against the rule.*"

When the meridians are neither with nor against the rule (conventionally between 20 and 70 degrees to these meridians) they are said to be *oblique—temporally oblique,* if the upper end of the meridian points to the temple; *nasally oblique,* if the upper end of the meridian points toward the nose (median line). The direction of these meridians changes somewhat with age, as previously mentioned (see page 689). The following table, compiled by Bennett and Clemesha,[2] indicates very clearly the percentage of direction and tendency of change in the axis of astigmia at different ages:

TABLE SHOWING DIRECTION OF MERIDIANS OF GREATEST CURVATURE.

Age.	Total. eyes.	Vertical.	Horizontal.	Temporal. Oblique.	Nasal. Oblique.
1–10	233	87.98	5.93	3.8	4.29
10–20	1329	77.3	10.23	4.74	7.22
20–30	2508	75.71	11.08	4.94	8.26
30–40	1808	71.34	13.27	5.47	9.90
40–50	1091	54.81	26.03	6.69	12.46
50–60	479	37.78	39.04	10.85	12.31
60–70	163	30.67	42.33	15.95	11.04
70	54	29.63	62.96	0.	7.40

Symmetrical Axes.[3]—The principal axes in astigmia are said to be symmetrical when they lie in corresponding meridians in both eyes.

[1] New York Med. Jour., July 13, 1895.

[2] American Medicine, August 1, 1903.

[3] Symmetrical axes. The axes of the astigmia are said to be symmetrical if when the scale recommended (see page 695) is used the sum of the rotation in degrees of the meridians of greatest (or least) refraction equals 180. Examples: If the meridian of greatest refraction in each eye is vertical (=90 degrees), the sum of the rotation would be 180 degrees. If the meridian in one eye was placed at 120 degrees, in the other at 60 degrees, the sum would be 180 degrees. Axes in any meridians the sum of the degrees of which is not 180 degrees are asymmetrical.

When the axes are in the directly horizontal and vertical meridians in both eyes they are symmetrical. Also when they are inclined from the vertical or the horizontal, as in Fig. 311). The symmetric scale of Knapp (see page 695) is based on the assumption that symmetry obtains in astigmia in a high percentage of the cases. Marlow[1] found the symmetry less than 34 per cent. in 452 cases examined. In the practice of the writer the symmetry of astigmic axes is about 23 per cent.

When the meridians of greatest refraction incline, one temporally the other nasally, to the same degree, the axes are said to be asymmetrical but *homologous*. When the meridians are neither symmetrical nor homologous, they are said to be *heterologous*. This term is applied particularly to those cases in which the meridians of greatest refraction are in opposite quadrants of the circle. This condition is not common.

Fig. 311

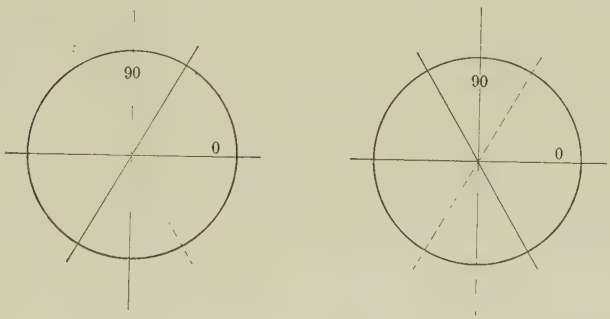

Right eye. Left eye.

Symmetrical axes: Oblique continuous lines, nasally symmetrical astigmia; oblique dotted lines, temporally symmetrical astigmia.

In prescribing cylindrical lenses the axis should always be placed in the meridian of corresponding refraction without regard to any supposed law (?) regulating the relation of the axes of the astigmia to each other in the two eyes.

Position of Lenses in Relation to Eye.—It is found that the periscopic (toric in astigmia) form of plus lens gives a larger arc for visual purposes without obliquity (see page 705) than any other form of plus lens.[2] For this reason it is better to employ periscopic or toric lenses, if they can be obtained, properly centred, in the correction of the higher degrees of hyperopia and compound or simple hyperopic astigmia, and to write the prescription so that the effect will approach the periscopic or toric in other forms of ametropia.

In *compound* hyperopic astigmia in which the hyperopia is of greater degree than the astigmia, the cylinder should be placed on the side next

[1] New York Med. Jour., July 13, 1895.
[2] Pergens, Klin, Monatsbl. f. Augen., June 21, 1904.

to the eye. If the cylinder is of the greater refractive power it should be placed on the side away from the eye.

In mixed astigmia a plus cylinder representing the total astigmia should be combined with a minus sphere of the same degree as the myopic astigmia, the sphere being placed on the side next to the eye.[1]

In simple myopic astigmia the cylinder is placed on the side of the lens next to the eye.

In compound myopic astigmia the more refracting element is placed on the side next to the eye.

Anisometropia.—In anisometropia of low and moderate degree the vision of either eye can, in the greater number of cases, be brought up to the normal in correcting the ametropia; but in the higher degrees it is not unusual to find the vision below normal in the eye with the greater degree of ametropia. In some of the cases the ametropia is so great in one eye that the possessor has never been able to form distinct images on the retina, and vision has never been acute in the affected eye. The image formed on the retina in quite a large proportion of these cases has been disregarded (suppressed) and amblyopia from non-use has developed. Such an eye is very apt to lose parallelism with its fellow and to deviate in some direction.

Muscular Anomalies.—Phorias and tropias are *not* more frequently met with in the low degrees of anisometropia than in other forms of ametropia. In fact, anisometropia of low degree is extremely common, but in moderate and high degrees muscular anomalies are of frequent occurrence. Astigmic anisometropia up to the point of the disassociation of images produces a higher percentage of asthenopia than any other form of ametropia, largely because of the dissimilarity in the size and distinctness of the images formed.

Application of Glasses.—The great majority of cases should receive a full correction of the ametropia. It must be remembered that apparent muscular anomalies often disappear when the error of refraction is corrected, whether there is anisometropia or not. In all suitable cases the *muscular error* should be kept under observation until the effect of the correction of the ametropia on the anomaly can be determined, before other measures for its correction are instituted.

The exceptions to the full correction of both eyes are: (1) Those cases in which one eye is emmetropic, or nearly so, and the other myopic −2 to 3 D., in which the individual has employed one eye for distance vision and the other eye for close work, for years. In these cases there is, as a rule, some muscular anomaly, usually divergence excess. It seldom happens that the myopic eye can satisfactorily regain the habit of accommodation which it has so long neglected; in addition, the muscular error, which previously had not produced symptoms because of the absence of binocular single vision, would become a source of annoyance if the myopic eye were given normal distance vision and

[1] Crossed cylinders possess no value over spherocylinders, are more difficult to make accurately, and are more expensive.

binocular single vision were restored. In cases of this kind, if glasses are required, it is best to make the vision of the eye that is used for distance vision emmetropic, and the eye that is used for reading as perfect for that purpose as possible and not attempt to establish binocular single vision. (2) Cases in which the vision of one eye is excellent, the vision of the other even with correction is defective, and in which binocular single vision causes a reduction in the distinctness of the image of the better eye, and produces asthenopic symptoms which do not disappear after careful correction and sufficiently thorough trial. (3) Those cases in which the vision of one eye is excellent for all purposes, the vision of the other eye of low degree and incapable of sufficient improvement to render binocular vision possible. In this case it is immaterial whether a correcting glass is prescribed or not.

The use of correcting glasses will not be assumed without much difficulty in some cases and success will be possible only after persistent effort on the part of the patient, and in many cases more or less changing of lenses. Some of the difficulties to be overcome are enumerated below.

1. In many cases temporary discomfort will be occasioned simply because of a change in the habit of vision. If the patient will *wear the glasses constantly* this discomfort will disappear in the course of a few hours, days, or weeks. The patient must be assured that the ultimate result will be satisfactory, and be encouraged to persevere.

2. The endeavor to overcome muscular anomalies which before the correction of the ametropia have not annoyed, but which when the acuity of vision is brought up to the normal are made appreciable by the overlapping of images and consequent confusion of vision. In some cases the condition of the muscles will require special treatment.

3. The difference in the prismatic action of the periphery of the lenses for each eye. Thus a highly hyperopic or myopic eye on one side with slight ametropia on the other would cause a prismatic effect of 1 degree to 3 degrees when the patient looked through the periphery of the lens. A hyperphoria of this degree may be extremely disturbing. It can be obviated to some extent by (*a*) wearing the glass as close to the eye as possible; (*b*) wearing periscopic or toric lenses; (*c*) adding a prism "paster" properly applied to counteract the prismatic effect of the stronger lens.

The statement that annoyance is occasioned by a difference in the retinal images produced by the correcting lenses possesses but little value. As a matter of fact, the images correspond more nearly in size when the ametropia is corrected than when it is not.

Some statistics apparently show that the right eye is more frequently the more ametropic. In the writer's experience there is no particular difference between the eyes in this respect.

The degree of anisometropia that may be corrected with the result of giving satisfactory binocular vision varies greatly. In one of the writer's cases the error of refraction was $+9$ D. $\bigcirc -12$ D. axis 88 degrees for the right eye, V. $= \frac{20}{30}$, and $+0.5$ D. $\bigcirc +0.5$ D. axis 163 degrees for the left eye, V. $= \frac{20}{20}$. These glasses permit binocular single vision; they

have been worn for years with perfect satisfaction. Without this correction the asthenopic symptoms are very pronounced.

It is of much importance to correct the anisometropia in cases of progressive axial elongation of the globe, also in cases of developing heterotropia or heterophoria. The careful observation of these cases and the intelligent correction of the anomalies of refraction and of muscles may often suffice to greatly improve vision.

Presbyopia (*Old Sight*).—The range of accommodation, as has been previously stated, decreases gradually with age. This is principally due to a gradual loss of the elasticity of the crystalline lens—a gradual sclerosing of the nucleus of the lens, preventing it from undergoing the change in curvature necessary to increase its refraction when the suspensory ligament is relaxed on contraction of the ciliary muscle (muscle of accommodation). It is very probable that the gradual loss of the range of accommodation is also *in part* due to a diminution in the vigor of the ciliary muscle.

The effect of time on the accommodation is determined by a study of the range of accommodation at different periods of life in emmetropic eyes of normal vigor. The results arrived at by different observers by such a study differ to some degree (see Fig. 305), but the difference is not very essential, since every case is more or less a law unto itself.

It has been found by observation that when the nearest point at which distinct vision is possible (the p. p.) is less than 22 cm. (8 inches) ordinary reading becomes difficult; that is, when the amplitude (range) of accommodation becomes less than 4.5 D. As a matter of fact, the ordinary distance at which print is held from the eye in reading is 33 to 38 cm., which is the principal focal distance of a plus lens of 3 D. and 2.75 D., respectively. As pointed out by Landot, it is necessary that there should be a reserve power of accommodation of one-third of the total in order that the ordinary use of the eyes for near work can be sustained with comfort. At the age of forty-five years the power or range of accommodation has fallen to about 4 D., which is not sufficient to enable the possessor to read comfortably for a long period of time at 33 cm. He would have less than one-third of the power of accommodation in reserve. In calculating the glass *theoretically* to prescribe in any case, two-thirds of the power of accommodation, expressed in dioptres, may be subtracted from the strength of the plus lens in dioptres whose principal focal distance equals the distance at which the desired work is to be done, and the result will be the designation of the lens to be employed. For example, for reading at the age of sixty-five years, the power (range) of accommodation is 0.75 D., one-third of which is 0.25 D., this subtracted from +3 D., the principal focal distance of which lens is the distance at which the reading should be done (33 cm. +), would give 2.75 D., the glass usually prescribed.

The physiological law governing the reduction in the range of accommodation is subject to some variation. The loss of accommodation may be prematurely rapid. This is found not very infrequently in individuals of weak physique—students, those in the learned professions, indi-

viduals confined to close work during long hours, individuals weakened by chronic disease. Not infrequently in these cases more than one-third reserve accommodation is required to enable them to maintain a continued effort at reading. This possibility must be borne in mind in prescribing glasses and the prescription varied accordingly.

Rarely the range of accommodation exceeds the ordinary. Thus the writer has seen an individual of fifty-six years whose p. p. was 18 cm. (=power of accommodation 5.5 D.), and an individual of fifty-two years with a p. p. of 20 cm. (=5.0 D.).

Another factor governing the prescribing of glasses to supplement those that correct the ametropia is the work to be accomplished. Thus painters, musicians, writers frequently, speakers in reading manuscript or notes when delivering addresses, artisans who do "bench work," etc., require glasses of less refractive power than those necessary for reading alone. Not infrequently two or more pairs of glasses designed for use at different distances ("intermediate," "piano," "card" glasses) are given in addition to the glasses for reading. The object is to give the patient glasses that will enable him to do the necessary work without discomfort. Rules or theories that conflict must be disregarded.

Variations between the Two Eyes.—Variations in the degree of loss of accommodation in the two eyes are seldom met with in cases that are not paretic. However, it is always advisable when determining the glass to test the p. p. of each eye separately; also to ascertain whether the test type can be seen with one eye as distinctly as with the other. If a discrepancy is found it should be remedied if possible. The condition of the action of the *extrinsic muscles* for the reading distance as well as for infinity should be determined and recorded in all cases.

It often happens that exophoria for the reading distance, of a degree that may cause distress in the use of the eyes, exists when exophoria for distance vision is not present. These conditions must be taken into consideration and corrected if necessary.

A proper distance between the optical centres of the lenses should be determined and indicated in the prescription.

Paralysis of Accommodation.—**Etiology.**—(*a*) Traumatism: A blow on the eye, without rupture or laceration of any of the tissues, may occasion a paresis of accommodation. (*b*) Disease: General disease, as diphtheria, diabetes, gout, measles, etc., and syphilis. Local disease, as brain tumor, tabes, general sclerosis, and diseases of the ciliary ganglion. (*c*) Toxic: As poisoning from alcohol and tobacco. Paralysis of accommodation is usually associated with paralysis of the sphincter pupillæ, but it may occur without implication of the sphincter—without mydriasis, and also without involvement of the extrinsic muscles. The paralysis accompanying diphtheria, diabetes, gout, and general acute diseases, and as a result of alcohol poisoning, is binocular. When the result of other causes, it may be monocular. Monocular paralysis or paresis of accommodation without a previous history of injury, or with-

out pronounced symptoms, is, with few exceptions, due to syphilis. The prognosis regarding recovery of the function of the ciliary muscle is unfavorable when due to syphilis.

The paresis of accommodation accompanying glaucoma has been referred to (see page 401).

Symptoms.—If the paralysis comes on relatively suddenly it may be accompanied by dizziness and nausea. It is frequently accompanied by dazzling when mydriasis is present. The inability to read is often the most prominent symptom.

Treatment.—The cause of the paralysis must be ascertained if possible and appropriate treatment instituted. In paralysis of accommodation due to diphtheria, measles, and other acute diseases the paresis is recovered from spontaneously on restoration of the general health. When due to gout, it may persist for a long period of time. The treatment should be directed against the diathesis.

Local Treatment.—This consists in the use of a miotic when there is mydriasis and dazzling if the miotic will reduce the size of the pupil. Pilocarpine should be tried first; if not efficient, eserine may be resorted to. Tinted glasses may be employed to reduce dazzling.

In the adjustment of glasses for reading, careful judgment must be exercised to place the focus of the glasses employed at the distance most convenient for the patient, and to have the images of both eyes as nearly alike in size and distinctness as possible. In monocular paresis, or paralysis of accommodation, it often requires very careful work to arrive at a satisfactory result.

Aphakia.—The term literally means "without a lens." Although an eye with a lens may be aphakic, so far as its refraction is concerned, it is not aphakic in the true sense of the term.

Etiology.—Aphakia is usually the result of operative procedure for the removal of cataract. Other causes are injury, or any process that brings about removal of the crystalline lens.

Diagnosis.—In aphakia the anterior chamber is deep, the iris—unless rendered stationary by adhesions—is tremulous (iridodonesis), and hangs in a single plane from its insertion, not being supported by the lens; the upright corneal image is present, but the crystalline lens reflexes (see page 661), the entoptic images of Purkinje, are absent. Accommodation is entirely abolished.

The aphakic eye, by the absence of the lens, is reduced to the simplest form of a dioptric system, of which the refracting surfaces are the corneal surfaces. The index of refraction of the aqueous and vitreous bodies are almost identical; these can be regarded as a single medium. The ametropia of an aphakic eye is quite strictly a *curvature ametropia.*

Treatment.—The ametropia in a previously emmetropic eye is approximately +11 D. This is subject to great variation (*a*) because of the previous refraction of the eye; (*b*) on account of changes in the curvature of the cornea consequent on the cause of the aphakia. If the eye was hyperopic before the aphakia the refraction would be +11 D., plus the degree of previous hyperopia, approximately; if myopic, +11 D.,

plus the degree of myopia within certain limits. (See Treatment of High Myopia.)

The nodal point of the aphakic eye is found at the centre of curvature of the cornea. When a strong plus lens is employed for the correction of the ametropia, the nodal point is displaced toward the cornea, making the distance between nodal point and retina greater than in the normal eye and greater than in axial hyperopia of the same degree. This increases the retinal image, since the size of the retinal image increases with increase in the distance of the nodal point from the retina.

In cases of aphakia affecting one eye, the vision of the other eye remaining good, although the anisometropia may not be very great, the eyes cannot be used together comfortably, largely on account of the disparity in the size of the images. The vision of one eye with correction may be as good as the vision of the other and the glasses may be so adjusted that the images are superimposed; but the difference in size will prevent the images from "registering" (perfectly coinciding) and the result will be a blurring that will not be tolerated by the patient. One eye will be used to the exclusion of the other. In these cases the refraction of the aphakic eye may be left uncorrected (which amounts to exclusion) or the refraction of the aphakic eye may be corrected and the other eye excluded. The course to be pursued must be decided by the demands of the individual case.

METHODS OF DETERMINING ERROR OF REFRACTION.

The student should be apprised at the outstart that applied refraction is one of the most important branches of ophthalmology, that it is fully worthy of his best efforts, and that its successful practice requires a comprehensive knowledge of the subject and the most discriminating judgment.

The optical principles involved have been given in Chapter III.

Use of Mydriatics and Cycloplegics.—A mydriatic is a drug that will *temporarily* dilate the pupil. A cycloplegic is a drug that will *temporarily* paralyze the ciliary muscles (muscle of accommodation).

In many cases the condition of the interior of the eye cannot be satisfactorily determined without the use of a mydriatic. In the writer's opinion it is best to make the employment of a mydriatic a rule at the first examination, and to permit of but few exceptions.

Increased tension of the eyeball is a contra-indication to the use of either a mydriatic or cycloplegic, because of the danger of exciting an attack of acute glaucoma. Cycloplegics should not be used in the eyes of nursing women on account of the tendency to decrease the mammary secretion.

If a complete cycloplegic effect is not desired, cocaine (4 per cent. solution), or cocaine and homatropine (homatropine, 0.1 per cent. solution), each dropped into the eye once, will suffice ordinarily. The mydriasis will last twenty to forty minutes. If a cycloplegic is to be used, one of the drugs enumerated in the following table may be employed:

	Solution per cent.	Dropped into eye.	Cycloplegia	Duration.	Passes off.	
Atropine sulph.	1.0	2 to 3 times at intervals of 10 to 15 m.	In 1 hour, begins in 10 to 15 min.	2 to 4 days	7 to 12 days	Full cycloplegia assured.
Daturia sulph.	0.5	"	"	2 to 4 days	6 to 10 days	
Hyoscyamine sulph. . . .	0.5	"	"	"	5 to 8 days	
Duboisine sulph.	0.5	"	"	1 to 3 days	5 to 8 days	
Scopolamine hydrochlorate .	0.5	"	"	12 to 36 hours.	4 to 6 days	
Homatropine hydrobrom. . . .	2.0	3 to 6 times at intervals of 15 min.	In 1 hour, begins in 15 to 25 min.	12 to 18 hours.	2 days.	In exceptional cases, cycloplegia is not complete.

These drugs are less liable to deterioration if put up in a sterile 3 per cent. solution of boric acid.

It should be remembered that all of the drugs enumerated above are capable of producing symptoms of poisoning in susceptible individuals, homatropine less so than any of the others. Very young children are particularly susceptible; when used for them, the strength of the solution should be reduced one-half or more.

The writer is accustomed to use mydriatics and cycloplegics for refraction work at the office, under his direct supervision. If for any reason the cycloplegic is prescribed for use at the patient's home, explicit directions are given.

In the selection of a cycloplegic, the convenience of the patient as well as the efficiency of the drug are to be considered. If the patient is young, or is myopic, atropine may be employed without entailing undue discomfort; the inability to use the eye for near work is not a serious disadvantage in the first, and if the myope is one of 2 D. or more this inconvenience is not experienced. In other cases, scopolamine or homatropine should be employed. The discomfort of the patient will be less if tinted glasses are worn during the continuation of the mydriasis. Neutral tinted glass, known as "London smoke," is excellent; it occurs in tints A, B, C, and D. Tint C or D are best suited. The "coquille" form may be used if it can be obtained without refractive quality, which is seldom the case. The plane glass is safe to prescribe.

The use of cocaine in connection with the cycloplegic apparently increases the cycloplegic effect. An experience of more than twenty years has confirmed the writer in the combined use of cocaine (4 per cent. solution) and homatropine (1 to 2 per cent. solution) in his private practice. The tension of the eyeball is ascertained, and if there is no symptom of glaucoma a drop of cocaine solution is instilled, followed

in five to ten minutes by the homatropine solution. The homatropine is instilled one to three times. The examination of the refraction can be proceeded with in one-half to one hour. Atropine sulphate (1 per cent. solution) is employed in exceptional cases of spasm of the ciliary muscle.

In all cases in which a mydriatic or a cycloplegic has been employed, a solution of pilocarpine (1 to 2 per cent.) or of eserine salicylate (0.3 per cent.) is instilled into the eye before the patient leaves the office—once or a number of times as may be thought advisable. At least two examinations—one with the eye under the influence of the mydriatic or cycloplegic, and one after the effect of the drug has passed —should be made. In many cases it will be necessary to see the patient a greater number of times in order to reach a satisfactory result. If the glasses prescribed are worn as directed, it is not necessary to repeat the *cycloplegic* in after years.

General Remarks.—Should the patient, because of lack of time or for any reason, require the completion of the examination at one visit, the probability of his receiving an imperfect correction should be explained to him.

For recording the results of the various steps in the examination of the eye, a suitable blank is convenient, especially if so arranged that it can be filed away and readily obtained when wanted (as by the card index system). The following serves the purpose very well:

No..... Name..... Age.....

Date..... Diag.....

Vision .....

Javal. { R. .....
L. .....

Without Accom. (Hom.) { Skiascopy .....
Ophthalmoscopy.....
Trial glasses { R. .....
L. .....

With Accom. { Trial glasses { R. .....
L. .....

Distance.....

Es..... Add.....

Ex..... Abd.....

V. D.....

Prescribed { R. .....
L. .....

REMARKS:

A routine method sufficiently comprehensive to make it impossible for any departure from the normal in the condition of the eye to escape the observation of the examiner should be adopted. The degree of vision of each eye at the distance of twenty feet (6 m.) should first be determined and recorded. For the determination of the refraction the writer employs the objective tests of ophthalmometry, skiascopy, ophthalmoscopy, and the subjective tests with the trial lenses. Before proceeding with, or during the progress of, the objective tests the condition of the cornea and of the interior of the eye is determined by means of oblique illumination and ophthalmoscopy. Unless there is a good reason for not doing so, the vision of the patient should be brought up to the normal before the examiner is satisfied with his efforts.

Fig. 312



Javal-Schiötz ophthalmometer.

Ophthalmometry.—Any good ophthalmometer may be employed. The writer uses the instrument of Javal and Schiötz.

Method of Using.—In order to obtain a clearly reflected image from the cornea, the mires should be strongly illuminated either by daylight, some form of artificial light, or by transmitted light. The patient should be comfortably placed at the instrument. The head should be placed in the head rest with the forehead against the frame, the eyes should be on the same level. If the patient's head is tilted, the principal meridians are tilted and a correct reading of the position of the axes cannot be obtained. While examining one eye, the other should be covered with the obturator. The patient is directed to look into the

end[1] of the telescope which is placed by the surgeon so that its axis corresponds to the visual line of the eye examined.

The ocular should be focused for the cross-hairs where a sharp image of the mires will be found, if the cross-hairs are properly placed. The entire tube should now be drawn as far away from the eye as possible and not impair the sharpness of the images. Flakes of mucus on the cornea or irregularities of the corneal surface distort the image. Double images of the mires will now be seen, Fig. 313, *A A′*, *B B′*. The outside images should be disregarded; the inside images should be sharply focused, and the stepped mire should be shifted so that the inner edge of its image just touches the inner edge of the other mire (Fig. 313, *A′ B*). (In all of the mires used, some device is employed by means of which the principal meridians of the cornea can be determined. A black guide line, passing through the centre of the mires in

Fig. 313

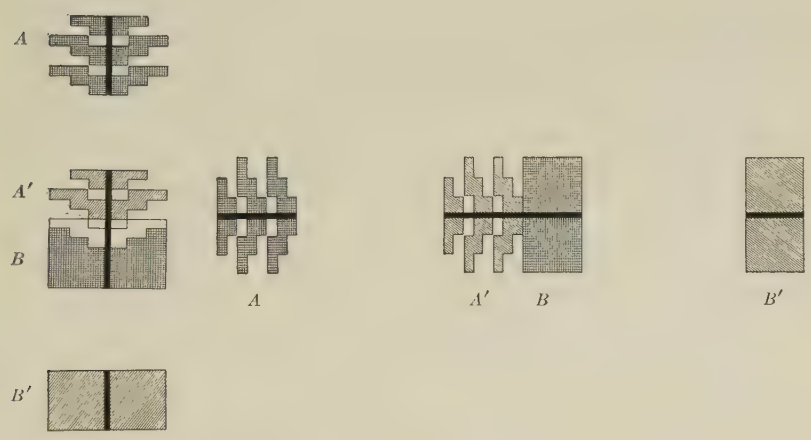

Mires in position, representing principal meridians. Astigmia = 3 D. "with the rule."

a plane cutting the axis of the telescope, is most common.) The black guide line of both mires will be continuous (their union forming a straight line) in all meridians of the cornea if all meridians have the same radius of curvature; if not (surface astigmic), the black guide line will be continuous only when the images of the mires lie in the principal meridians of the cornea. It is best to begin the measurement with the images of the mires in the meridian of least curvature (longest radius). This is determined by rotating the mires into the meridian in which their images are most widely separated. The mires are then approximated until the inner margin of their images

[1] In cases of partial amblyopia and in aphakia it is sometimes difficult for the patient to see the end of the telescope tube. This may be obviated to a great extent by slipping a piece of white cardboard over the end of the tube, after having cut out a circle to admit the end of the tube. The contrast of color makes it possible for the patient to fix the centre of the tube.

just touch. The position of the axis, which should be recorded, will be shown by the indicator. The length of radius of curvature in this meridian can now be read from the scale on the arm of the arc on which the movable mire is placed, if desired, and recorded. The other principal meridian (meridian of greatest curvature) into which the mire should now be rotated is usually found at right angles with the first. The images of the mires will now overlap (Fig. 313, vertical mires *A′ B*), the amount of overlapping depending on the difference in the degree of curvature of the two meridians. The refractive value of this difference is indicated by the number of steps of overlapping of the images. This should be recorded. The second axis should be recorded if it is not at right angles with the axis first determined. The radius of curvature of the second meridian may also be recorded if desired.

It *must always* be remembered that the astigmia indicated by the ophthalmometer is corneal astigmia only, and that this may be decidedly changed by the position and shape of the lens and by the position of the retina. As a matter of fact, the corneal astigmia seldom corresponds to the total astigmia—the rule being (there are numerous exceptions) that the total is 0.5 D. less (Javal estimates it as 0.75 D. less) than the corneal astigmia when the meridian of least curvature is horizontal ("astigmia with the rule"), or nearly so, and 0.5 D. more than the corneal astigmia when the meridian of least curvature is vertical, or nearly so ("astigmia against the rule"). When at an angle of 45 degrees the corneal corresponds closely to the total astigmia. This is thought to be due to a "compensating" position of the crystalline lens, or to an inverse astigmia of the posterior surface of the cornea, or both. In the higher degrees of astigmia *with the rule*, 3 D. and over, the total astigmia often exceeds the corneal astigmia. The axis of the corneal astigmia corresponds with the axis of the total astigmia[1] in 35 to 40 per cent. of the cases.

Skiascopy.—The examiner's refraction should be properly corrected while conducting the examination. Skiascopy (for the optical principles involved see page 106) is conducted in a darkened room. The light employed should be on a movable bracket or attached to the skiascope. The source of light may be electricity, acetylene gas, illuminating gas with a Welsbach, Argand, or other burner—named in the order of excellence—or any other light of sufficient intensity. The area of the source of illumination should be sharply defined. To effect this, and to control the area of illumination, a screen fitted with a changeable diaphragm is serviceable. The asbestos chimney of Thorington, with an iris diaphragm (Fig. 314), is very good. It is suited for use with an Argand burner. The light may be placed slightly back of the patient's head, or to the side. If the *concave* mirror is used, the source of light must be beyond the principal focal point of the mirror, preferably as indicated. If the *plane* mirror is used, the light may be brought within

[1] The ophthalmophakometer of Tscherning is employed to measure the posterior corneal surface as well as to observe the images of Purkinje.

six inches of the mirror. The distance between the light and the plane mirror will not materially change the direction of the rays of light that are reflected from the patient's eye (Thorington). Many observers prefer to have the light come through a 10 mm. diaphragm from a lamp six inches distant, to the right and in front. When the light is placed near the patient's head, the aperture in the diaphragm must be 2 to 3.5 cm. in diameter. A plane or concave mirror may be employed. The writer prefers a plane mirror. The mirror should be 2 to 3 cm. in diameter, and have a sight hole 2 to 3 mm. in diameter. If the sight hole is cut out, the glass from which the mirror is made should be thin and the edge of the opening should be blackened to prevent reflexes. The silver may be removed to form a sight hole without cutting the glass, but it is difficult to keep it clean. Skiascopes that are made of amber-tinted glass appear to cause less irritation because of a partial cutting out of actinic rays.

Fig. 314



Asbestos chimney.

Position.—The patient should be comfortably seated, preferably so that the head is approximately on a level with the head of the examiner.

Since skiascopy is the determining of the *point of reversal* of the movement of a shadow following an illuminated area on the retina, and since the point of reversal corresponds to the anterior focus (punctum remotum) of the conjugate foci of a myopic eye (naturally or artificially myopic, the latter produced by the interposition of lenses), which focus must be placed approximately at the nodal point of the observer's eye in order to enable him to see the reversal, it is convenient for purposes of easy computation to have the distance between the patient's and the observer's eye one meter—equivalent to 1 D. If the rays of light that enter the patient's eye are parallel,[1] or nearly so, it is then necessary to subtract 1 D. from the refraction indicated when the point of reversal is found to obtain the total amount of ametropia in the particular meridian examined. If the examiner should place himself at two meters from the patient, the difference between the total refraction and that determined by skiascopy would be 0.5 D. If at one-half meter, the difference would be 2 D. It will thus be seen that

[1] Rays of light reflected from a plane mirror from a source of illumination at some distance from the mirror (1 to 2 meters) are virtually parallel, but not actually so. They diverge, and the divergence increases as the apparent source of light approaches the patient's eye. This introduces a very slight error into the computation, which may be eliminated in large degree by following the suggestion of Jackson where parallel rays of light are not employed; when using the plane mirror, consider that the point of reversal is found when the strongest convex or the weakest concave lens is placed before the patient's eye, with which the movement of the shadow *with the mirror* (the "erect" movement) can be seen in the visual zone of the pupil. When using the concave mirror, the weakest convex and the strongest concave lens with which the movement of the shadow *against the mirror* can be seen in the same zone.

the difference between the total refraction and the refraction determined by skiascopy increases much more rapidly as the observer approaches the patient, and, since the recognition of the exact point of reversal is difficult and subject to some error when determined at any distance, the error is apt to be less if the observer is beyond one meter than if he is closer than one meter.

The patient's eye should be under the influence of a cycloplegic. If it is not, the results of skiascopy are influenced by ciliary spasm.

Fig. 315

Gruening's set of hand lenses for skiascopy, four in set.

It is better to occlude one eye while the other is being examined, but this is not necessary if there is binocular fixation. To hold the lenses before the patient's eye, a trial frame or an apparatus containing a series of lenses to be placed in position by the patient, as those designed by Gruening (Fig. 315), or a series designed to be manipulated by the examiner, as the apparatus of Lambert,[1] may be employed. After one has acquired proficiency in the practice of skiascopy, the

[1] Trans. Am. Ophthal. Soc., 1894.

changes of lenses necessary will not be many. The trial frame possesses advantages over banks of lenses in various forms of holders, in that the lenses can be kept in proper relation to the patient's eye whatever his movements may be. If *rapidity* of work is essential and *approximation* in result is sufficient, the banks of lenses, as described by Würdemann, may be used to advantage. Where accuracy is desired, the trial frame is superior. (The writer uses a trial frame and the ordinary trial lenses in office practice.)

The patient is directed to look into the sight hole of the skiascope, or, if the light annoys or the iris is not under the influence of a mydriatic, at the upper edge of the mirror or the forehead above the mirror. When

Fig. 316

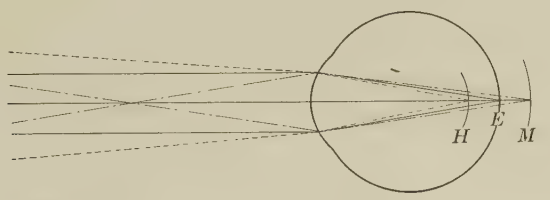

Dispersion of rays of light emerging from the ametropic eye.

the light is reflected into the patient's eye a red reflex will be observed, which will vary in intensity (*a*) in proportion to the intensity of the light that enters the patient's eye, and (*b*) in inverse proportion to the *degree of ametropia*. The reason for the former is apparent; the latter is due to the dispersion of the emergent rays of light in high degrees of ametropia (Fig. 316). If simple hyperopia or myopia, or emmetropia, is the refractive condition, the reflex will be approximately uniform throughout the pupil. If there is astigmia, the pupillary zone, or band of least ametropia will appear brightest (Fig. 319).

Fig. 317

Fig. 318

Fig. 319

Fig. 317.—Showing the form of the shadow in hyperopia, emmetropia, or myopia.

Fig. 318.—Showing the rectilinear shadow in astigmia when the examiner, being near the point of reversal of one principal meridian, tilts the mirror to one side.

Fig. 319.—Showing the central band of light in astigmia. (Souter.)

On tilting the mirror the red pupillary reflex will move across the pupillary area in the *direction of the movement of the mirror* if the refraction is *hyperopic*, or *myopic* less than 1 D. and disappear if a *plane* mirror is used and the examiner is at 1 m. distance. The movement of the red reflex will be *opposite* to the movement of the mirror if the *myopia* exceeds 1 D. The movement of the light reflex will be *opposite* to that just described, under the same conditions, if a *concave* mirror is used. When the point of reversal is found in any meridian a very *slight* move-

ment of the mirror *in the same meridian* may not cause an appreciable change in the reflex which now crosses the entire pupil in that meridian; a further movement will cause the reflex to disappear totally from all parts of that meridian of the pupil at the same moment.

In determining the refraction of the eye by skiascopy lenses should be placed before the patient's eye until the lens that causes a reversal in the direction of the movement of the pupillary reflex (or shadow) is found, and the result recorded. This should be obtained in both of the *principal* meridians (page 102) if astigmia is present. When simple hyperopia or myopia are present the error of refraction equals that found by skiascopy plus 1 D. If astigmia is present the amount corresponds with the difference between the meridians as found by skiascopy. If it is desired to obtain a more nearly accurate result, the point of reversal may be determined at a distance of 2 or more meters from the eye, after obtaining an approximate result at 1 meter.

Difficulties.—Opacities of the clear media and irregular astigmia render skiascopy difficult and may make it impossible. While skiascopy is the most nearly accurate objective method that we possess for the determination of refraction, it is subject to error (1) on the part of the observer, whose judgment of the position of the point of reversal may be at fault—the error is very small but is of importance; (2) on the part of the patient, (*a*) because of ciliary spasm in patients without a cycloplegic (this can be obviated by using a reliable cycloplegic); (*b*) by confusion in the movement of the light reflex area, due to irregular refraction of the media in the various parts of the pupillary area in consequence of (*a'*) asymmetrical curvature of the cornea external to the visual area, (*b'*) variation in the refractive index of the lens in its various parts; (3) slight tilting of the lens. These difficulties may be minimized by the use of a diaphragm to cut down the area of the dilated pupil to, or nearly to, the normal.[1]

Scissors Movement.—From what has preceded the movement of the light reflex and the following shadow and their interpretation can be readily understood by a little practice, but the so-called "scissors" movement is confusing and requires further mention. It is thus described by Jackson:[2] "In it one portion of the pupil, as an upper or lower half, is more myopic in a certain meridian than is the other part of the pupil. This causes an inverted movement of light in the one portion of the pupil, while there is an erect movement in the other. These two areas are distinct and separated by an intermediate zone of feeble illumination. As the light is made to move back and forth in the proper direction, the two areas of light in the pupil are seen alternately to approach and separate, narrowing or widening the intermediate zone. As the areas, under these circumstances, are generally band-like, or have comparatively straight margins, the effect is similar to that of opening and closing a pair of scissors." "The scissors-like movement may be pro-

[1] If a concave mirror is used it should have a principal focal distance of not less than 25 cm.
[2] Skiascopy, p. 66.

duced in an artificial eye by placing the lens which represents the dioptric surfaces so that the light passes through it obliquely." "Its presence in the eye indicates obliquity or imperfect centring of one or more of the dioptric surfaces." The skiascopic findings should be recorded.

Ophthalmoscopy.—In determining the refraction with the ophthalmoscope, the examination will be facilitated by the use of a cycloplegic. The examination should be made by the direct method (see p. 131), the right eye with the right, the left eye with the left eye of the examiner. A tilting mirror on the ophthalmoscope is convenient. The observer should approach close to the patient's eye when making the examination, endeavoring to have his eye as nearly as possible in the position that will be occupied by the spectacle lens. The examiner's error of refraction should be corrected and his accommodation perfectly relaxed. If the pupil is dilated the refraction may be determined by focusing the very small blood-vessels at the macula, which radiate irregularly in all meridians. If the pupil is not dilated the small blood-vessels that cross the margin of the disk must usually be chosen.[1] The refraction in the various meridians, as indicated by the strongest convex or the weakest concave lens in the ophthalmoscope through which the fine blood-vessels mentioned can be distinctly seen, must be determined—the difference in the value of the lenses required in the principal meridians if the refraction is astigmic represents the degree of astigmia. To approximately determine the refraction by means of the ophthalmoscope requires much practice. *Accurate* determination of the refraction by this method is possible in but few cases.

At the time of determining the refraction, or at this stage of the examination of the eye, the condition of the blood-vessels and of the fundus should be ascertained and recorded.

Possible Errors.—(1) On the part of the examiner: (*a*) The examiner's accommodation may not be under perfect control. (*b*) The point of greatest distinctness of the image of the fundus object may not be recognized (an error of 0.25 D. may readily obtain). (2) On the part of the patient: (*a*) The level of the object from which the refraction is measured may not be the same as the principal layer of the retina at the fovea centralis this may cause a large or small error; (*b*) the part of the cornea or dioptric media through which the refraction is determined may not correspond with the part traversed by the patient's visual line in cases in which a cycloplegic is employed, or if a cycloplegic is not employed, ciliary spasm may cause error. The possibilities of error are so great that the writer employs the ophthalmoscope for the final determination of the refraction only very rarely.

Subjective Examination.—After recording the ophthalmoscopic findings and the result of the examination of the cornea and anterior segment of the globe by oblique illumination, the examination with the lenses of the trial case (the objective examination) is proceeded with.

[1] By some observers the fine stippling at the macula is taken as the object from which to determine the refraction.

This is the most practical test extant for patients of sufficient intelligence and sufficient visual acuity—the test from the results of which we must prescribe the glasses required. The objective tests are valuable aids, but because of the possible error that all possess are not final in those cases in which the patient can aid the examiner.[1]

The patient should be seated at a distance of twenty feet (6 meters) from the test cards.[2] The test cards should be approximately at right angles with the horizontal plane of the patient's eyes.

Test Cards.—For the determination of the degree of simple hyperopia or myopia the ordinary test card bearing the test letters of Snellen (page 147) is sufficient. The cards should have lines of letters designed to be read at ten and fifteen feet, as well as for greater distances. A number of sets of type should be at command, so that they may be changed from time to time in order that the patient may not aid his vision by his memory. Test cards with groupings of dots, figures of various kinds, and pictures in black may be used for the illiterate and for children. Test cards must also be had for the testing of astigmia. The variety of these cards may be judged by Figs. 320 to 331. The

Fig. 320

Thomas' astigmatic chart.

Fig. 321



Green's wheel

writer prefers the clock dial (Green's wheel) with each group of lines made to subtend an angle of 5″ at twenty feet, and a clock dial with lines that subtend the same angle at fifteen feet; two sunbursts, the black lines of which should mark meridians at 10-degree intervals, beginning with the horizontal meridian, the width of each line to subtend an angle of 1″ at twenty feet; and two sets of groups of three black lines, each

[1] The cases in which the objective examination may be utilized as superior to the subjective are principally as follows: Ophthalmometry for the determination of astigmia in some cases in which the condition of the media does not permit of satisfactory skiascopy, in some cases of conical cornea and of irregular astigmia and in aphakic eyes, particularly those in which the acuity of vision is much below normal; *skiascopy* in young children, in the unintelligent and in the illiterate.

[2] If mirrors are used to reflect the test object, the apparent position should be twenty feet; if this plan is used, the letters of the test card must be reversed. A distance less than twenty feet does not give a punctum remotum at infinity in practice. This has been abundantly demonstrated by the writer in his office work.

Fig. 322



Fig. 323



Sunburst.

Fig. 324



Fig. 325



Pray's letters.

Fig. 326

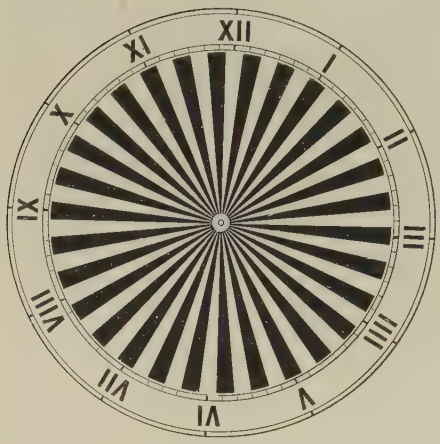

Fig. 327

Fig. 328

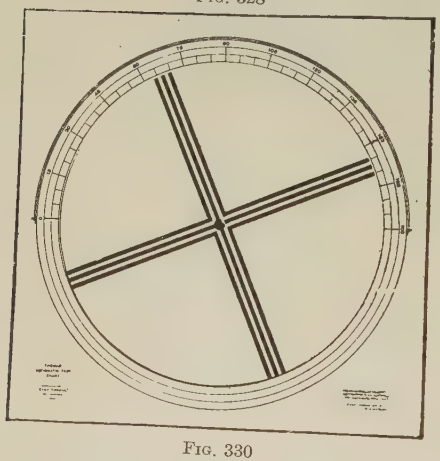

Fig. 329

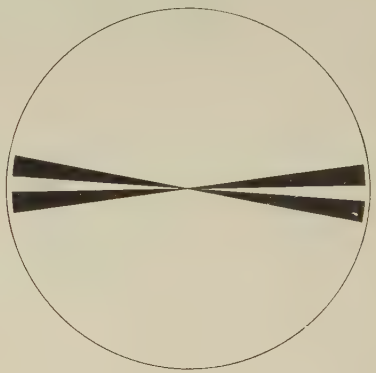

Fig. 330

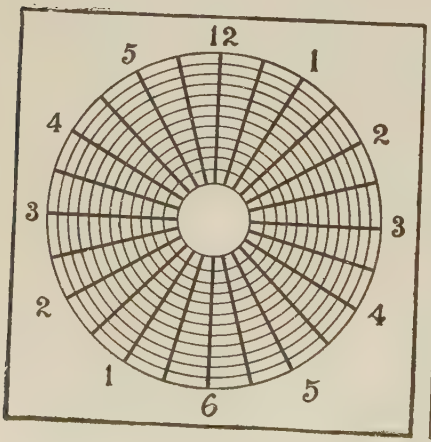

Fig. 331

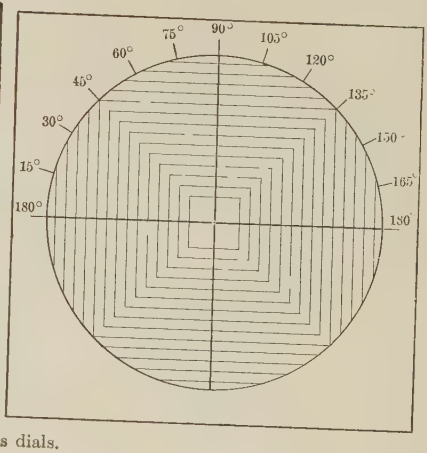

Verhoeff's dials.

10 cm. long, one of which subtends an angle of 5″ at twenty feet, the other 5″ at fifteen feet.

The test objects may be black on a white field or white on a black field. The cards may be illuminated by direct or by transmitted light. There is a degree of irradiation from white letters on a black ground and from transilluminated objects which is often trying to the patient. Black on a white field, if daylight or light that is not white is employed, will be found to be very satisfactory. If the Welsbach light is employed, the effect to the patient will be better if the rays pass through a very light amber-tinted glass before reaching the cards, or if the test cards (field) are of an *extremely light* straw or amber tint. The light should be uniform, constant, and sufficiently intense, but not glaring.

Trial Frame.—The trial frame should be made so that three (3) lenses may be placed in position in front of each eye, and the cells so arranged that the lenses will be very close to each other, their optical centres coinciding. The distance through the system of lenses should

Fig. 332

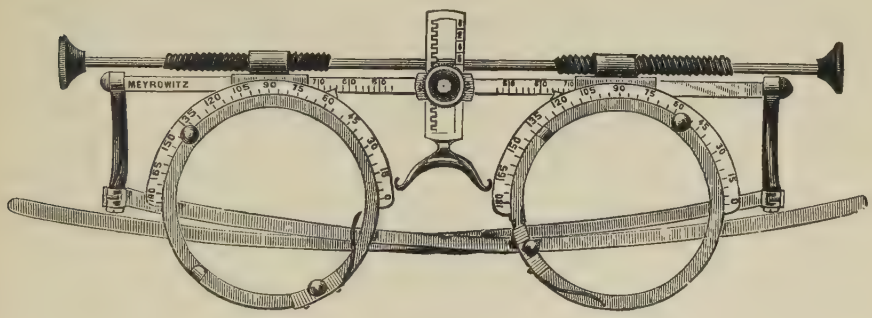

Trial frame.

be as short as possible. The examiner should be able to insert and remove the lenses easily. The revolving cells should be perfectly centred with the fixed cell and with the scale marking the degrees of the circle. The horizontal and the vertical meridians of the fixed and the revolving cells should be marked at the four points cut by these meridians, and the marks should be visible when the lenses are in position in order that the examiner may know *positively* the axis held by the cylinder when placed in the frame. The degrees of the circle should be marked by the scale, extending half-way around the cell at least (better to extend it entirely around), placed close to the periphery of the cell and perfectly centred. The meridians of the circle should be marked at 5-degree intervals on the scale, and the degrees numbered from right to left through the upper half of the circle, *as the observer looks at the frame when in position on the patient's face*[1] (Fig. 332).

[1] This corresponds with the method of indicating the meridians of a circle in other branches of science, and is understood throughout the civilized world. Another method, employed by some practitioners, is to call both ends of the horizontal meridan zero (0), scale the upper half of the circle only, and call the vertical meridian 90 degrees (Knapp). In writing a prescription, the axes of the

This method places the zero at the right of the horizontal meridian. The top of the vertical meridian on each side is at 90 degrees. The matter of determining the exact relation of the axis of the cylindrical lens to the astigmic eye is of much importance and is greatly facilitated by having a suitable trial frame. The frame should be capable of adjustment, so that the cells can be raised or lowered; the distance between their centres shortened to 48 mm. or lengthened to 72 mm.; the plane of the cells tilted backward below, and brought close to the eyes, so that the lenses in the posterior cells will just clear the eyelashes.

Trial Lenses.—The set of trial lenses to be sufficiently complete to enable the operator to do good work should contain pairs of "plus" and "minus" spherical lenses from 0.125 D. (D. = dioptres) to 20 D. inclusive. The "strength" of the lenses should increase by eighth dioptres up to 1.5 D.; by quarter dioptres from 1.5 to 3.5 D.; by half dioptres from 3.5 D. to 7 D.; by one dioptre from 7 D. to 14 D.; and by two dioptres from 14 D. to and including 20 D. It should contain pairs of cylindrical lenses from 0.125 D. to 6 D. inclusive, increasing by eighth dioptres to 1.25 D.: by quarter dioptres from 1.25 D. to 3.5 D.; and by half dioptres from 3.5 D. to and including 6 D. The set should contain pairs of prisms from $\frac{1}{2}$ degree (refracting angle) to 6 degrees inclusive, increasing by $\frac{1}{2}$ degree to and including 2 degrees; by 1 degree from 2 to 6 degrees inclusive. In addition there should be single prisms of 7, 8, 9, 10, 12, 14, 16, and 20 degrees. These prisms should correspond with the trial lenses in form, and fit in the trial frames. The accessories in the trial case should be: obturators, appropriate diaphragms, stenopeic disk, colored glasses, Maddox rod, plane and ground glass, all in disk form, to fit into the trial frames. Less complete sets are obtainable and permit of good work, but they are not as convenient.

Procedure.—The trial frame may be placed on the patient's face and properly adjusted. The centres of the cells should be opposite the centres of the patient's pupils when the patient is looking in the plane required. The plane of the cells should cut the visual line at right angles. The eyes are examined separately, the eye not under examination being excluded by means of an obturator. Both eyes should be kept open. The patient is now directed to look at the chart representing a clock dial (Fig. 321) and asked if he can see three lines in any of the bars. If he cannot, plus or minus glasses (those to be employed will have been indicated by skiascopy) may be placed before the eye until three lines can be distinguished in some or all of the bars. The "strength" of the lens is then increased in the direction of "plus" until the lines can barely be discerned in any meridian[1] (fogging method). This makes

cylinders, if in the vertical meridian, are indicated by the method recommended; if the meridian inclines to the median line above, 15 degrees for example, it is written 75 degrees nasally; if to the temporal side, 75 degrees temporally. Other methods also are employed, but they are unnecessary, and since not universally understood are confusing.

[1] This is known as the "fogging" method, so called because the vision in all meridians is at first rendered indistinct. When mastered it is an extremely valuable method for the correction of almost all forms of ametropia.

all the meridians of the eye slightly myopic. If the eye is simply hyperopic or myopic, all meridians will be equally indistinct, and it only remains to change the lens before the eye to the strongest plus (in hyperopia) or the weakest minus lens (in myopia) that will give *maximum* vision to determine the degree of the error of refraction. This test is not sufficient to positively exclude the lower degrees of astigmia in all cases. To do this proceed as follows:

The fogging at first produced by the lens in the trial frame may be reduced slightly so that the patient is not mistaken regarding his ability to see three lines in some, if not all, of the bars (all meridians being still rendered slightly myopic). The patient's attention is then called to the sunburst, and he is asked "if a line or a group of lines appears to him to be darker than the others." If the reply is negative, a bar of three lines made to subtend an angle of 5 minutes at fifteen feet is presented to the patient's view, and is carried to the greatest distance at which the lines can be differentiated. If the patient sees no difference in the relation of the lines to each other when they are placed in the various meridians the evidence so far has excluded astigmia. It now remains to check these findings by placing a weak cylinder (+0.25 D. or —0.25 D.) before the eye, changing its axis into different meridians. If astigmia is then developed corresponding in amount to the cylinder introduced the examiner may conclude that the eye is not *then* astigmic, *whatever the objective examination may have disclosed.* The examiner may now proceed to find the degree of hyperopia or myopia, *if any is present,* and record the findings.

If a bar on the clock dial (Green's wheel) appears to be darker than the others the refraction is astigmic. The *exact* meridian of most distinct vision is now ascertained. This cannot be done, as a rule, sufficiently accurately with the clock dial, in which the meridians indicated by the bars are 30 degrees apart. Recourse must be had to the sunburst in which the lines indicate meridians 10 degrees apart. In this, one line may be seen most distinctly (usually in high degrees of astigmia), in which case the axis of greatest curvature, one of the principal meridians, corresponds to the meridian marked by that line. If two lines appear to be of equal distinctness, those on either side shading off equally, the axis of greatest curvature lies between the two distinct lines. If the degree of astigmia is low, a *group* of lines will appear to be more distinct than the others, in which case the axis lies at the middle of the distinct group. In some "negative" patients it may be easier to determine the position of the most indistinct group of lines. Having determined the position of either axis the refraction of the meridian of greatest curvature is reduced by placing minus cylinders with their axes at right angles to it (if the meridian of greatest curvature is vertical, with the rule, the axis of the minus cylinder should be horizontal, and vice versa) until the refraction of both principal meridians is equalized. The findings are carefully confirmed by tests as described when excluding astigmia. The lens required to equalize the meridians is the measure of the astigmia. The vision is now made normal by the

addition of minus spherical glasses, if necessary. Having done this, the measure of the ametropia is indicated by the lenses in the trial frame. The result as determined for each eye is recorded. This method suffices for determining hyperopia, myopia, and all forms of regular astigmia.

If the vision in either eye is defective from any cause, the method described for determining astigmia may be employed at any distance short of twenty feet that may be thought best. In *exceptional* cases of moderate and low degrees of astigmia, the patient may mistake dispersion lines that appear in the meridian corresponding to that least nearly corrected, for the most distinct lines. When this occurs the examiner will find that placing minus cylinders with the axes as indicated by the testimony of the patient, accentuates the difference. If the axes of cylinders are placed at right angles to that indicated by the patient, the appearance of the various meridians will be equalized. The findings by the objective methods must be used as a check on the testimony of the patient, but such testimony must be most carefully weighed. Having determined the refraction, the lenses indicated are properly centred before each eye, and the *static* condition of the ocular muscles for twenty feet determined by means of the phorometer (Stevens, see p. 729) or Maddox rods. (The writer prefers the latter because of greater simplicity and rapidity of application.) A single rod may be employed, but it gives too short a line. A number of rods should be combined (Fig. 333), giving a long, straight, continuous line. The point of light used in this test should be small and bright. A minute incandescent light (a light seen through an aperture 1 cm. in diameter, a small candle or gas jet that does not flicker) at a distance of twenty feet may be employed. It is sometimes necessary to darken the room in order to enable the patient to readily distinguish *the line*, or the light may be made of a different color by the interposition of a tinted glass. If the vision of one eye is better than the other the rods should be placed before the better eye. Any error of the muscles should be recorded.

Fig. 333

Maddox rods.

If the examination has been conducted without the use of a mydriatic or cycloplegic, glasses are now prescribed. If a mydriatic or cycloplegic has been used, a miotic is now instilled and the patient is directed to return in twenty-four to forty-eight hours if a mydriatic has been employed, as soon as the pupil is of a normal size if a cycloplegic has been used. (It is not wise to prescribe glasses except in the case of young children or imbeciles, from the findings when the eye is *under the influence of a mydriatic*, on account of the possible error that may be occasioned by the refraction of the area outside of that included within the pupil when the pupil is of natural size. Furthermore, the ciliary muscle

may be sufficiently affected by the mydriatic to produce some degree of error.) The concluding examination should be made at a time when neither the patient nor the patient's eyes are fatigued, preferably in the morning. The patient should be cautioned not to use the eyes for close work on that morning until after the examination is completed.

The examination at the second visit is a repetition of the subjective examination of the first visit, and is confirmatory. It should be conducted rapidly (to avoid fatiguing the patient), and with much care. The refraction affecting all meridians will be found to be 0.5 to 1 D. less than when the eye is examined under a cycloplegic. This presumably represents the difference in contractile "tone" between the paralyzed and normal ciliary muscle. Spasm of the ciliary muscle may be entirely absent, which is apt to be the case if the eyes have not been used for close work since the cycloplegic was employed, or since the sleep of the preceding night. The method of examination ("fogging") tends to eliminate ciliary spasm. Spasm may be present, exhibiting itself if clonic by alternate blurring of the image; if tonic, by a great reduction in the hyperopia or increase in the myopia over the findings with a cycloplegic. In either case there is a tendency to relaxation of spasm when approximately correct lenses are put before the eyes and the exact correction can gradually be determined. If the spasm affects all meridians alike, it is often best to prescribe for the correction of as much of the hyperopia as is manifest and for all of the astigmia if astigmia is present, and to correct the remainder of the hyperopia after some days have elapsed, or, as it becomes manifest under the use of the glasses. In myopia, the error may be undercorrected. Ciliary spasm is not apt to occur in considerable degrees of myopia, but is sometimes observed. In some cases it is necessary to return to the cycloplegic, to prescribe glasses that are then indicated, and to gradually modify them as the cycloplegic effect passes. Other cases may require the long continuation of the cycloplegic, but these cases *are very rare.* The astigmia may be modified by the refraction in the reduced pupillary area, but, *as a rule,* it is but little changed. The *static condition* of the extrinsic muscles may be considerably altered when the effects of the cycloplegic or mydriatic have passed.

Aberration.—In very many eyes the refraction near the margin of a dilated pupil differs very much from that in the central area. The cornea is flatter at its periphery than at the centre, the lens flatter at its anterior and posterior poles than at its periphery. The conditions of the cornea and of the lens neutralize each other in the visual area sufficiently for practical purposes in the greater number of cases, but in some cases the flattening or increased curvature predominates at the periphery of the pupil, particularly when the pupil is large or dilated by means of a mydriatic. If the increased curvature predominates so that the eye is more myopic or less hyperopic at the edge of the pupil than at the centre it is called *positive aberration.* This resembles the aberration of a spherical lens. It is the more common form. If the flattening predominates at the edge of the pupil, making it less myopic

or more hyperopic than at the centre it is called *negative aberration* (Jackson). This condition, occurring as it does in various forms in spherical and astigmic ametropia, is a source of considerable annoyance in determining the correction best suited for the patient's use. A lens that may give maximum vision through one part of the visual area may differ considerably (0.25 D. to 1 D.) from that giving maximum vision through another part of the visual area. Monocular double vision is not infrequently present in these cases, one image being much more distinct than the other, the weaker often appearing as a shadow of the more distinct. This phenomenon accompanying conical cornea and sclerosis of the nucleus of the lens preceding cataract (negative) is most pronounced.[1]

Irregular Astigmia.—This exists to some extent at the periphery of the pupil of nearly if not quite all eyes, but is so small in degree in eyes that have not suffered from injury or from some form of ulcerative keratitis that it does not interfere materially with vision. Irregular astigmia the result of keratitis or of irregular refraction due to changes in the crystalline lens occasions marked disturbance of vision. Peculiar distortion of images, diplopia and polyopia, particularly when looking at distant objects, as the moon and artificial lights, are experienced, due to the formation of multiple images on the retina. Irregular astigmia cannot be perfectly corrected with lenses. In some cases a small space may be found in the visual area, the ametropia of which can be corrected and the vision much improved. This should be carefully sought for.

In the search for the best correction of the ametropia of conical cornea and irregular astigmia the stenopeic slit will be found of much service. The pupil should be of normal size. The approximate maximum vision of such eyes should first be determined. This can be done usually by having the patient look through a pin-hole aperature, 0.5 to 0.57 mm. in diameter, at the test object, which must be well illuminated. The degree of vision thus ascertained should be the standard to be reached by the correction with lenses. The stenopeic slit (0.5 to 0.75 mm. in width) is placed before the eye and rotated into various meridians until the meridian is found that permits of the best vision. Plus and minus glasses are then placed before the slit and the meridian of the slit slightly changed if found to increase vision, until the maximum vision in some meridian is obtained. The slit is then rotated into the meridian at right angles and the maximum vision obtained in that meridian in the same manner. If the combination of lenses so indicated is tried without the pin-hole aperture or stenopeic slit, the maximum vision of the eye under examination may be obtained, but in many cases it will fall much below. Other combinations of lenses may be found that will be better, but often the maximum vision cannot be obtained by any combination that is used when the pupil is of ordinary size. The pin-hole or the stenopeic slit may be used for reading and for *special*

[1] For a discussion of this subject, see Szily, Klin. Monat. f. Augen., July 23, 1903.

distance vision. The field of vision is too limited with these appliances to make them *generally* applicable for ordinary distance vision.

Anisometropia.—Anisometropia is the term employed to indicate a difference in the refraction of the two eyes. It is employed by some to indicate a difference in the same form of ametropia (myopia or hyperopia), while the term *antimetropia* is employed to indicate the difference in refraction when one eye is myopic and the other hyperopic. Used in its broad sense the term anisometropia is sufficient to indicate a difference in the refraction of the eye of whatever nature.

Other Methods of Determining Refraction.—There are numerous other ingenious methods of determining the refraction of the eye, nearly all of which are of scientific interest only, not being sufficiently accurate or requiring too much time to be of practical value. A few only will be mentioned.

Scheiner's Experiment.—When one looks at a luminous point through two or more minute openings in a thin diaphragm, which are placed within the area of the pupil, the luminous point will appear single if the conjugate focus is at the retina; in other words, if the luminous point is in focus. If the point is not in focus, the observer will receive the impression of as many luminous points as there are apertures in the diaphragm. Scheiner's experiment is usually practised with a thin disk with two pin-hole perforations situated near enough to each other so that they will be included within the area of the pupil (Fig. 334). The

Fig. 334

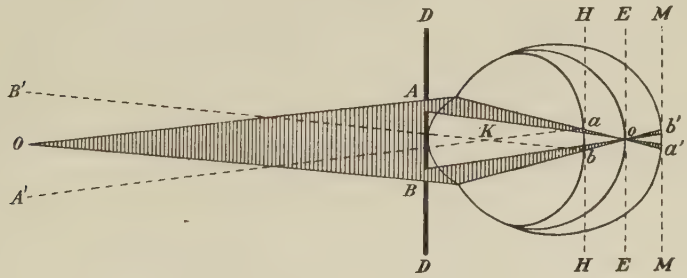

Scheiner's experiment. (From Landolt)

line cutting the pin-hole openings may be held in any meridian of the pupil. (It is better to have the pupil dilated and the accommodation paralyzed.) Let the point of light be at a distance of 6 m., so that the rays of light entering the eye are virtually parallel. It is well to have one of the apertures in the diaphragm covered by a colored glass so that the image formed by each opening can be recognized. If the *meridian* corresponding with the plane of the openings is emmetropic (the retina at the principal focal point of the dioptric system of the eye), the rays of light entering at each opening will fall together on the retina and will give the impression of one point of light (*E*). If the meridian is hyperopic the rays of light entering at each aperture will reach the retina at points separate from each other (*H*). The degree of separation is in

direct ratio to the degree of ametropia. Since images falling on one side of the fovea centralis are referred or projected to the opposite side, the images of the light will be crossed (heteronymous). If the aperture above is covered by the red glass the red image will be projected below. A plus glass that will cause the images to fall together placed before the perforated plate is the measure of the hyperopia in that meridian. If the meridian is myopic the rays of light entering the aperture will have crossed before reaching the retina and will fall on opposite sides of the fovea centralis (*M*). Following the same law as that which obtained in hyperopia, the images will be projected to the opposite sides and will be homonymous. The minus glass that will exactly superimpose the images is the measure of the myopia in that meridian. The diaphragm may be rotated into all meridians and the refraction of each meridian determined. The test is too difficult of application to be practical.

Chromatic Aberration Test.—The pupil should be dilated and the accommodation paralyzed. The eye to be tested is covered by a cobalt-blue glass which has the property of allowing only red and blue light to pass through it. The blue rays are more strongly refracted than the red and are brought to a focus sooner than the red. If when looking at a luminous point at 6 m. distance the blue rays are brought to a focus just in front of the retina and the red rays just back of the retina, they will exactly overlap each other and will be seen as a purple point. This is the condition in *emmetropia*. If the eye is highly hyperopic neither the red nor the blue rays will be focused. A diffusion circle will appear on the retina composed of red and blue rays. The blue rays, which are the more refracted, will be found in the centre only; hence the illuminated area will appear as a blue centre surrounded by a broad band of red. If the eye is myopic the opposite condition will obtain. If astigmia obtains, corresponding elongation of the chromatic figures will be pronounced. Glasses placed before the eye that will reduce the figure to that observed in emmetropia will give the measure of the ametropia.

Thompson's Ametrometer.—This is based on the principle of the measurement of the position of retinal diffusion circles. The instrument has two very small flames, one of which is stationary and one movable. The latter is attached to a metal arm which may be rotated into any meridian. The arm is marked with a scale which indicates in dioptres the position of the movable flame. A point of light situated at a distance and separated by an interval that will subtend an angle of about one minute as they enter the eye will be seen as two distinct points of light by the *emmetrope*. To the *ametrope* these points of light will produce diffuse, circular areas of light on the retina, which, if the lights are close together, will lap one onto the other. In using the ametrometer the flames are separated just far enough to permit the diffusion circles to touch and the result read from the scale on the bar. The separation is greater the greater the ametropia. The degree of astigmia is determined by moving the light into and testing the principal meridians.

PLATE XXV

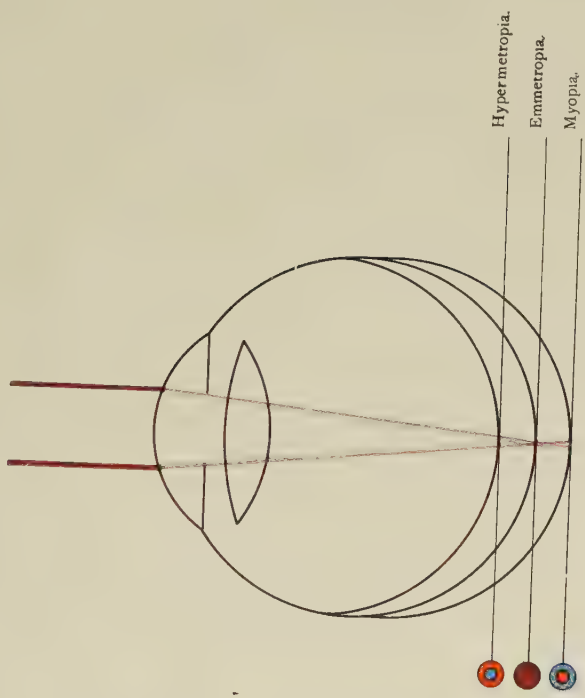

Diagram Illustrating Chromatic Aberration Test for Ametropia.
(Norris and Oliver.)

The Application of Prisms.—In conditions of heterophoria the question of the advisability of prescribing prisms for their correction presents itself. Before prescribing prisms it is advisable to know whether asthenopia or disturbances of any kind is due to the heterophoria. This implies a knowledge of the behavior of the eyes after sufficient use of glasses that perfectly correct the ametropia. It is no unusual experience to note the disappearance of heterophoria under the use of glasses that correct the ametropia. The writer has observed the disappearance of an esophoria of 16 degrees under these conditions. Exophoria and hyperphoria are influenced to some extent, but to a less degree than esophoria. Only moderate degrees of heterophoria can be corrected with prisms to advantage, as prisms of high degree produce so much confusion and chromatic aberration that they are not worn with comfort. Some patients cannot tolerate a prism of more than 1 or 2 degrees, while others are comfortable with 6 or 7 degrees before each eye. Although there are some exceptions, 6 degrees is about as strong a prism as will be tolerated by any patient. Generally speaking, prisms prescribed for the correction of esophoria will give relief from symptoms if they correct one-third to one-half of the error. In exophoria it will be necessary to correct almost if not quite the total error as measured at 6 m. In hyperphoria they should correct the total or to within one-fourth degree. Before prescribing prisms the condition of the muscle balance should be known for 6 m. (infinity) and for 33 to 37 cm. (the reading distance) for the mean plane of vision and for the planes 15 to 20 degrees above and below the mean plane, with the *correction for the ametropia in position* before the eyes. Great variations in the heterophoria will often be found at the different distances and in the different planes, variations which must influence the composition of the prescription. The correction required for the ametropia will in some cases produce a heterophoria in some plane requiring the interposition of a prism when the plane affected is in use. Thus with a myopic astigmia of high degree, axis horizontal, affecting one eye, the other being virtually emmetropic, a vertical deviation of the visual plane will be produced when the patient looks above or below the plane corresponding with the axis of the cylinder. This may require a compensating prism in the lower part of the lens before the less ametropic eye. A paresis of depressors or levators affecting one eye may require similar treatment.

The successful correction of troublesome low degrees of heterophoria by means of prisms requires a careful study of the individual case and may necessitate the occasional change of the prism. In many cases of esophoria and exophoria in which prisms are prescribed the degree of the phoria will appear to increase on use of the prisms. This is due many times to the relaxation of overstrained muscles, in which case the development of the phoria will cease when a *natural* balance has been reached. In hyperphoria this occurs, but to a much less degree, as a rule, than in the other deviations. In a small percentage of cases the correction of esophoria with prisms appears to lead to an actual increase in

the strength of the interni and the development of an appreciable convergent strabismus.

Patients to whom prisms are prescribed require to wear them continuously, as a rule. If the prisms are removed the asthenopia brought about by the muscular effort to avoid double images returns very quickly.

In the treatment of heterophoria by the constant wearing of prisms it is well to at first prescribe the prisms in separate frames, in many cases, in order that various degrees of prisms may be tried until those that will give the greatest satisfaction are determined.

In prescribing prisms the simplest way is to indicate the direction of the base as out or in, up or down, as the case may be.

If the base-apex line is placed obliquely the position of the base must be indicated in degrees of the circle at right angles with the base-apex line.[1]

Application of Glasses for Correction of Ametropia, Presbyopia, and Errors of Extra-ocular Muscles.—**Mounting of Glasses.**—The frame chosen should be sufficiently firm when applied to the face to hold the lenses in proper relation to the eyes, and be sufficiently rigid to avoid being easily bent out of shape. Spectacle frames are preferable for cylindrical lenses, as the position of the axes of the lenses must be maintained in proper relation to the eyes and to each other. They are also desirable for holding heavy lenses (high plus and minus lenses). The optical centre of the lens should correspond with the centre of the mounted lens unless otherwise ordered.

Position before Eye.—The lens, as a rule, should be placed before the eye so that the visual line will cut the optical centre of the lens, when the visual line is in the *mean visual plane.* The *mean plane* for distance vision is 10 to 15 degrees below the horizon; for near work (reading, etc.), approximately 35 degrees below the horizon. For determining this, the distance between the visual lines where they cut the spectacle lenses and the mean plane of vision for the work for which the lenses are to be used should be known. The first may be determined sufficiently accurately by measuring the interpupillary distance by means of a millimeter rule. It may be obtained more satisfactorily by use of the appliance shown in Fig. 335.[2] The error produced by wearing lenses not properly centred before the eyes is equivalent to decentring (see page 670) the lenses to a corresponding distance. The vertical plane of the glass should be tilted so that the visual line in the mean plane of vision will cut the surface of the lens at right angles.

[1] Prisms for constant use are of very great value in many cases; they are prescribed by the writer for approximately 15 per cent. of the patients seen by him for refractive anomalies in private practice.

[2] The "base line" (distance between centres of rotation of eyeballs) varies greatly. Of 8300 measurements recorded in the writer's private practice in adults the length was from 50 to 74 mm. The mean was 64 mm. The average difference between the length of the base line of males and females was 2 mm. less in females. The base line tends to increase in length up to the age of forty-five to fifty years, after which it tends to decrease in length, seldom decreasing more than 1.5 to 2 mm.

Obliquity of Lenses.—Lenses obliquely placed before the eyes produce an astigmic effect, with the axis of the astigmia corresponding to the meridian around which the lens is rotated to make it oblique, and in addition increases the refraction of the sphere. The amount of error in the obliquity affecting strong lenses is considerable, as will be seen by consulting the following table prepared by Jackson.[1] A lens of —10 D. rotated around its horizontal axis:

10 degrees = + 10.10 ◯ + 0.37 cy. ax. 180 degrees.
20 degrees = + 10.40 ◯ + 1.38 cy. ax. 180 degrees.
30 degrees = + 10.93 ◯ + 3.65 cy. ax. 180 degrees.

It will be seen that the increase in error is proportionately more rapid with the increase in degree of obliquity. As Jackson writes, "Patients sometimes look obliquely through the edge of their glasses in order to get the effect of a stronger lens than has been prescribed for them or a cylindrical effect that their lenses do not give." To prevent this, he advises the use of the periscopic form of lens.

Fig. 335

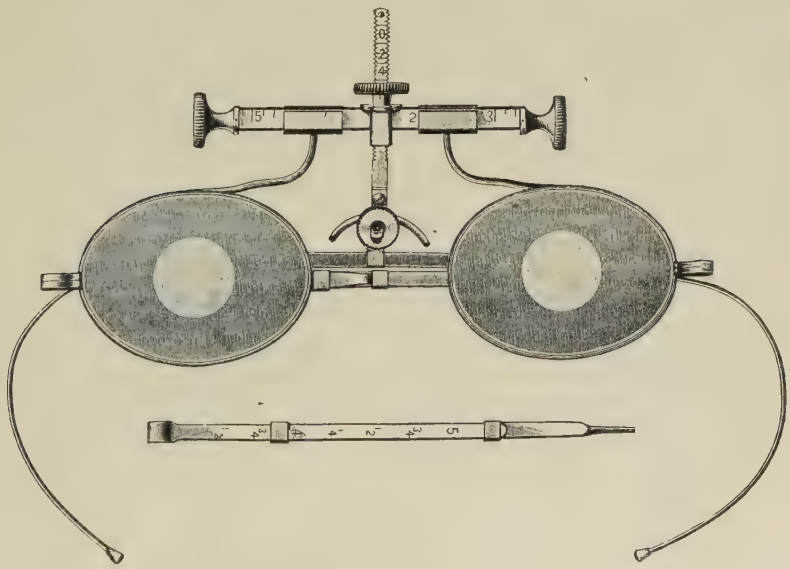

Adjustable trial frame for facial measurements, with readings for pupillary distance, height of bridge, depth of bridge, and length of temples.

Construction of Lenses.—Some of the different forms of single lenses are shown in the cut on page 95. There remain to be considered the *periscopic, toric,* and the *bifocal* lenses.

Periscopic Lenses.—The periscopic lens is the meniscus which may be a concavo-convex, in which the concave curve is less than the convex; or a concavo-convex, in which the concave curve exceeds the outer

[1] Diseases of the Eye, p. 189.

convex curve. Since both surfaces are spherical, these lenses cannot be used to correct astigmia. They give a wider flat field than the ordinary convex or concave lenses.

Toric or Twisted Lenses.—Toric or twisted lenses are those in which the inner surface is cylindro-concave, with the meridian of least curvature —3 D. or —6 D., or the outer surface cylinder convex—the meridian of least curvature +3 or +6 D., the other surface being spherical, making it possible to furnish a crossed or spherocylinder with a periscopic effect. A torus from which such a lens is made is a "curved solid generated by the revolution of a circle about any line other than its diameter" (Duane). The curved moulding at the base of a cylindrical column is a familiar example.

Fig. 336

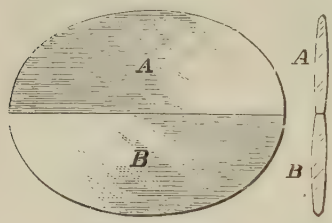

Franklin bifocal.

Fig. 337

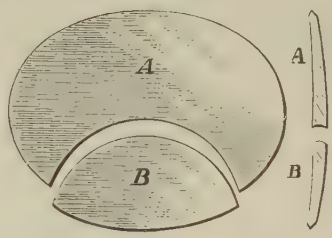

Bifocal with a curved lower segment cut to fit into a suitable curved effect in the upper segment.

Fig. 338

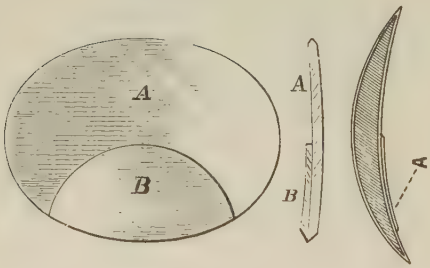

Toric

Fig. 339

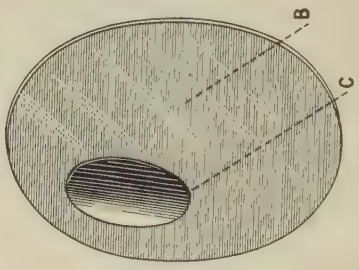

"Paster" bifocals.

Bifocal Lenses.—Bifocal lenses are variously constructed.

Franklin Bifocal.—The Franklin[1] bifocal consists in an upper half lens for distance and a lower half lens of proper strength for reading, properly centred and joined in the middle.

Bifocal (Morck's perfection bifocals), in which a suitable segment of a small periscopic sphere, known as a "paster," is cemented to the lower part of the lens, for distance vision, by means of Canada balsam.

[1] Invented by Benjamin Franklin some time between the years 1750 and 1785, and described in a letter addressed to George Whatley, London, dated Passy, May 23, 1785.

The segment may be of any shape and be placed at any part of the large lens. It may be placed on the upper part of a lens suitable for reading, converting the part on which it is cemented into a glass for distance vision.

Fig. 340

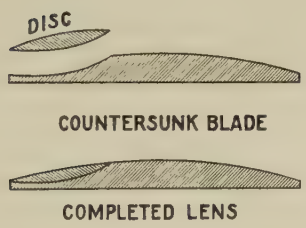

Achromatic bifocal.

Fig. 341

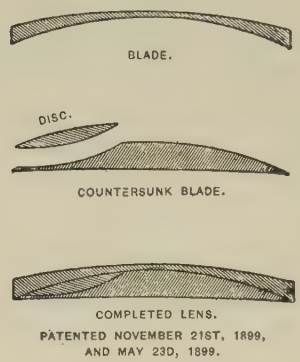

Achromatic bifocal.

Achromatic Bifocals (Borsch patent).—These consist in the combination of two qualities of glass with different indices of refraction, namely, crown and flint glass. The crown glass forms the lens for distance vision. A suitable concavity is ground out of its lower half and a small plus lens of flint glass of suitable shape to give the desired refraction is cemented into the concavity. The outer surface of the flint glass lens is made to correspond with that of the lens into which it is cemented. A process of fusing the flint and crown glass together is now employed, virtually converting the lens into a solid piece.

Another form of construction is shown in Fig. 341.

Fig. 342



Solid bifocal.

Solid Bifocals.—Lenses of this character are ground in one piece, the upper part for distance, the lower part for reading.

In all bifocal glasses the line of division between the distance and the reading parts annoys the wearer. In the Franklin and the "paster" bifocals the annoyance is greater than in the others because the line is more decidedly visible. This is particularly so when the edge of the "paster" is not made to blend into the surface of the lens to which it is cemented—in other words, is thicker than need be. Annoyance is also experienced, especially by beginners, in becoming accustomed to the use of such lenses, difficulty being experienced in changing from one to the other part of the lens in walking, etc.; these difficulties are soon mastered.

For those requiring glasses for reading only, the upper part of the glass is frequently cut away, permitting the wearer to look over the top when regarding distance objects. This shape is termed the clerical lens.

Prisms.—When prisms are required they may be cut in the lens prescribed, forming a part of the lens. If prisms are prescribed for the reading part of bifocals differing from the distance part they cannot be readily constructed in the Borsch patent or in the fused bifocal; the "paster" bifocal is ordinarily employed in the construction of this combination.

CHAPTER XXVII.

MOVEMENTS OF THE EYEBALLS AND THEIR ANOMALIES.

By ALEXANDER DUANE, M.D.

Monocular Fixation.—When we look at an object directly, so that it appears more distinct than any of the objects surrounding it, we are said to "*fix*" or *fixate*" it.

As the fovea is normally the most sensitive part of the retina and affords by far the most distinct vision, fixation, in the great majority of cases, is so performed that the image of the object that is fixated falls upon the fovea of the eye that is fixing. This is called *central* or *macular fixation.*

When, however, central vision is absent, as, for example, occurs when there is disease in the region of the macula, the patient has to see with a portion of the retina outside of the fovea, and he then so directs his eye that the image of the object he wishes to see falls on this outlying portion of the retina (*eccentric fixation*). Vision is then mostly very poor.

The ability to fix is apparently acquired in very early infancy by constant practice in looking. Any marked interference with vision, and particularly with central vision, present at or soon after birth, will tend to prevent the acquisition of this ability, and in extreme cases of the sort the eye does not learn to fix at all, but wanders aimlessly in all directions.

Binocular Fixation and its Anomalies.—We habitually use our two eyes together and fixate with both at once; that is, we direct the eyes in such a way that the image of the object looked at falls on the fovea in each eye.

This condition in which both eyes are accurately directed at the object at which one of the two is looking is called *binocular fixation*, *i. e.*, binocular fixation means that both eyes are straight.

The ability to produce and maintain binocular fixation—to keep both eyes directed straight—is acquired very early in life. The impulse to maintain it grows with exercise, and soon becomes so strong that after the age of infancy binocular fixation is present in the great majority of persons, and in most of them is present all the time. In some persons, however, binocular fixation is absent either all or part of the time. One

eye in that case deviates from the object which the other eye is fixing, *i. e.*, one of the eyes is no longer straight.

So far as binocular fixation is concerned, we must, in fact, distinguish three conditions that may obtain—orthophoria, heterophoria, and squint.

Orthophoria.—This is the condition in which both eyes look straight at the same object, whether both see it or not. There is not even a tendency to deviation.

Heterophoria.—This is the condition in which both eyes keep looking straight at the same object, so long as both see it, but in which as soon as one eye is excluded from vision (as by a screen) that eye deviates. There is then a tendency to deviation which is strong enough to become manifest when either eye is covered, but which is abolished or overcome by the compelling impulse to binocular fixation when both eyes are used for seeing.

A heterophoria thus produces a *superable* deviation. The deviation is also said to be *latent*, since it is absent under ordinary conditions, and is brought to light only by special maneuvers.

A common, though less proper, term for heterophoria is *insufficiency*.

Squint.—Squint is the condition in which there is so great a tendency to deviation that even when both eyes are uncovered one deviates, and only one fixes. It differs, therefore, from heterophoria in that the deviation it produces is obvious under ordinary conditions, *i. e.*, is a *manifest* deviation.

Squint is also called *strabismus* or *heterotropia*. In other words, in orthophoria there is binocular fixation all the time and under all conditions; in heterophoria it is present only when the two eyes are uncovered, so that both see the object looked at; and in squint it is not present at all.

Or, in plainer terms, in orthophoria both eyes are straight all the time; in heterophoria both are straight, but only so long as both are uncovered; and in squint only one eye is straight, no matter whether both eyes are uncovered or not.

In squint, while binocular fixation is absent altogether, the ability to *perform monocular fixation* is almost always preserved; that is, the squinting eye will fix at once if the other eye is covered. It is only when there is marked amblyopia, particularly as the result of a central scotoma, that the squinting eye loses its power to fix at all, and wanders uncertainly about, receiving impressions now on one, now on another portion of the retina.

The term *imbalance* is often used to denote the two conditions opposed to orthophoria, *i. e.*, to denote collectively heterophoria and squint.

Varieties of Heterophoria and Squint.—1. **Classification According to Direction of Deviating Eye.**—Heterophoria and squint may be classified according to the direction assumed by the deviating eye. Thus we have the following varieties of heterophoria:

HETEROPHORIA.

LATERAL DEVIATIONS.

Either eye when screened deviates	
In or toward the nose	ESOPHORIA.
Out or toward the temple	EXOPHORIA.

VERTICAL DEVIATIONS

The *right eye goes up* and the left eye down when screened	RIGHT HYPERPHORIA.
The *left eye goes up* and the right eye down when screened	LEFT HYPERPHORIA.[1]

So, too, we have the following varieties of squint:

SQUINT.

LATERAL SQUINT.

The deviating eye turns *in* or toward the nose	ESOTROPIA (Strabismus convergens, Convergent Squint).
The deviating eye turns *out* or toward the temple	EXOTROPIA (Strabismus divergens, Divergent Squint).

VERTICAL SQUINT.

The deviating eye turns *up* . . .	HYPERTROPIA (Strabismus sursumvergens) (Right or Left).
The deviating eye turns *down*. . .	HYPOTROPIA (Strabismus deorsumvergens) (Right or Left).

In addition to these lateral and vertical deviations, conditions are described in which the vertical meridian of one eye instead of maintaining its parallelism with the vertical meridian of the other either forms an angle with it (*cyclotropia*) or tends to do so, but is kept in place by muscular effort (*cyclophoria*).

[1] In some very rare cases of vertical heterophoria, each eye tends to go up (*anophoria*) or each to go down (*catophoria*) when screened. These cases must not be confounded with anotropia and catotropia (see p. 712). In anophoria and catophoria there is binocular fixation when both eyes are uncovered, while in anotropia one of the eyes squints.

Cyclotropia is usually due to paralysis of one of the ocular muscles, causing the vertical meridian of the affected eye to be tilted out or toward the temple (*extorsion*), or in toward the nose (*intorsion*). A tilting of the vertical meridian toward the right is also called *dextrotorsion* (or *positive declination*), and to the left *levotorsion* (or *negative declination*).

2. **Constant, Intermittent, and Periodic Deviations.**—A deviation, whether a squint or heterophoria, may be present all the time (*constant*), or be sometimes present and sometimes absent (*intermittent*). In this regard we may have heterophoria alternating with orthophoria, or heterophoria alternating with squint, or squint alternating with orthophoria; and, furthermore, a squint or heterophoria, while not actually intermittent, often shows marked variations in amount from one time to another.

Again, a deviation, whether squint or heterophoria, may be regularly present for near and regularly absent for distance, or, more rarely, present for distance and absent for near. In either case the deviation is said to be *periodic*. Here, again, we may have different varieties; as a squint for near and a heterophoria or orthophoria for distance, or a heterophoria for near and orthophoria for distance, or, a constant squint for near and an intermittent squint for distance, etc. Again, a deviation may be periodic, in that its amount for distance may greatly exceed that for near, or vice versa.

Opposed to a periodic deviation is one which is present, and in about equal amount, both for distance and near. Such a deviation, whether squint or heterophoria, is called *continuous*.

3. **Alternating and Uniocular Squint.**—An *alternating squint* is one in which, when both eyes are uncovered, so that both have a chance to fix, sometimes the right eye will deviate, sometimes the left. In *uniocular* (less properly *monocular*) squint, under the same conditions, one eye, either the right or the left, always fixes and the other always deviates. A uniocular squint is denoted as *right* or *left*, according as it is the right or left eye which deviates.

In an alternating lateral squint either an esotropia of one eye alternates with an esotropia of the other, or an exotropia of the one with an exotropia of the other. Very exceptionally it may happen, especially in anisometropia, that an esotropia of one eye alternates with an exotropia of the other. In the very uncommon alternating vertical squint, a hypertropia (strabismus sursumvergens) of one eye almost always alternates with a hypotropia (strabismus deorsumvergens) of the other. In exceedingly rare instances, however, a hypertropia of one eye alternates with a hypertropia of the other (a condition called *anotropia*), or a hypotropia of one eye with a hypotropia of the other (*catotropia*).

4. **Comitant and Non-comitant Deviations.**—In some varieties of heterophoria and squint the amount of deviation is the same in all directions of the gaze, so that the angle between the visual line of one eye and that of the other remains the same, no matter which way the eyes are turned. Such deviations are called *comitant*[1] or *concomitant*, because one eye

[1] This is the preferable term.

accompanies and keeps pace with the other in all its movements. In other cases the deviation changes as the eyes are moved in different directions, so that the angle between the two visual lines keeps varying. Such deviations are called *non-comitant*. Usually in a non-comitant squint the angle of deviation increases in a regular way as the eyes are moved in one direction, and decreases as they move in the direction opposite.

In some old squints, however, the squinting eye, particularly when very amblyopic, wanders in an uncertain way, and apparently quite without reference to the movements of the other eye.

Law of Projection.—The movements of the eye are designed primarily to effect fixation, that is, to bring upon the macula the image of the object that we wish to look at. When this has been accomplished we know, as a result of long experience, the direction of the object looked at and also the direction of other neighboring objects. This knowledge is doubtless afforded us in part by our muscle sense. Thus we know that an object, *A*, is straight in front of us because we can see it sharply without moving either the head or the eyes from the position of rest or equilibrium; and we know that an object, *B*, is on the right of us because to see it sharply we have to move either the head or the eyes to the right, thus altering the muscular condition from one of rest to one of tension. But we also, without moving either head or eye, know while we are still looking at *A*, that *B* is to the right, for the image of *B* is then formed on a portion of the retina situated to the left of the macula, and from long experience we know that an image so situated means an object placed on our right. Moreover, the farther to the left of the macula the image *B* is the farther to the right do we judge *B* itself to be.

Similarly, if *B* is so placed that its image falls below the macula, we know that *B* itself is really above *A*, which forms its image on the macula; and if the image of *B* is above the macula, we know that *B* itself is below *A*. In this way, as shown in Fig. 343, we *project* an image formed on the retina, *i. e.*, mentally refer it to a point in space situated diametrically opposite.

Corresponding Points: Binocular Single Vision.—An object, *A*, at which both eyes are looking forms retinal images, *M* and *M′* (Fig. 344), on each fovea; each eye then projects its own image outward to the same point in space, the point namely, where the object itself is situated. In this case the mind, although dealing with two retinal images, sees but one object in space (*binocular single vision*).

The act of thus compounding two retinal impressions so that but one mental concept is formed out of them is called *fusion;* the mental process by which this is effected is called the *fusion faculty*, and the cerebral centres by means of which the fusion faculty acts are called the *fusion centres.*

The mental image produced by fusion of the two retinal images is projected forward in the median line as though is were seen by a single eye set half-way between the two eyes (cyclopean eye).

A is not, however, the only object that will be seen singly by the two eyes.

If (Fig. 344) an object, B, is so situated as to form its retinal image, N, on the right eye, 5 degrees above and 10 degrees to the right of M, the eye

Fig. 343

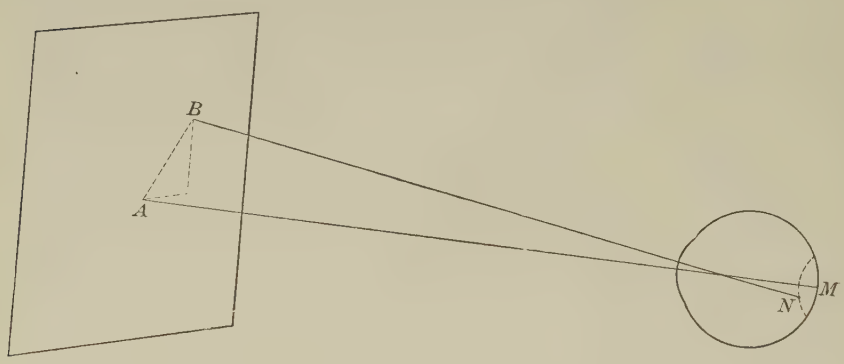

Projection.—An object, A, situated straight in front of the eye will form its image on the macula, M. Conversely, a retinal image situated on M will be mentally projected to A, *i. e.*, will be regarded by the mind as situated in space at A, straight in front of the eye. An object, B, above and to the right of the point A, at which the eye is directed, always forms its image on the retina below and to the left of M (at N). Conversely, an image formed on the retina 6 degrees below and 5 degrees to the left of M will be regarded by the mind as situated in space at B, 6 degrees above and 5 degrees to the right of A; that is, the retinal image N will be projected out to B.

Fig. 344

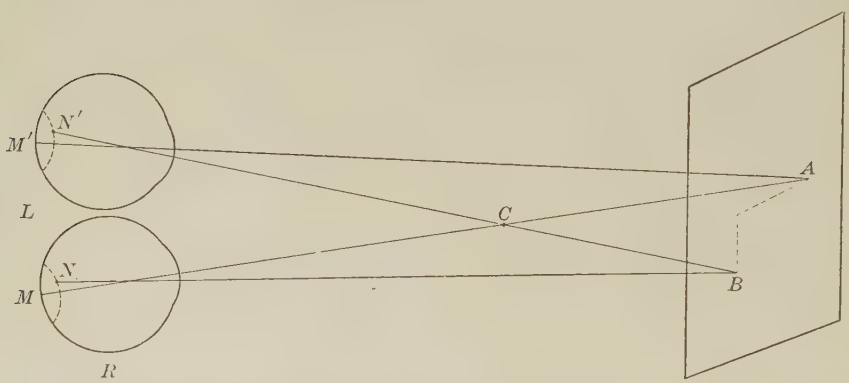

Corresponding Points.—Physiological Diplopia.—A, an object at which both eyes R and L are directed, so that it forms a retinal image on the macula (M and M') in each. These two retinal images are fused by the mind, which projects them both into space as a single image, situated straight in front of both eyes, *i. e.*, at A. B, an object so situated that it forms its retinal images at N and N', 5 degrees above and 10 degrees to the right of the macula in each eye. These two images will likewise be fused by the mind, which will project them into out space as one image, located at B, 5 degrees below and 10 degrees to the left of A. C, an object so situated as to form its retinal images at M in the right eye and at N' in the left. The former image will be projected out to A, the latter image to B, and the mind will get the impression of two objects, one situated 5 degrees below and 10 degrees to the left of the other. A and B will appear single, because they form their images on corresponding points (M and M', N and N'), while C will appear double because its images are formed on the non-corresponding points M and N'.

will project that image to a point 5 degrees below and 10 degrees to the left of A; and if B is also so placed that it will form in the left eye the

image of N', 5 degrees above and 10 degrees to the right of M', that image will be projected out to the same point in space to which it is projected by the right eye. In that case, also, B will appear single, the mind fusing the two images.

Any two points like N and N', one in the right eye, the other in the left, so situated that N bears precisely the same relation to its fovea M, that N' does to its fovea M', are called *corresponding points.* And any object which forms its retinal images on the corresponding points in the two eyes will always appear single (*law of binocular single vision*).

Diplopia.—The converse to this proposition is also true; that is, any object whose retinal images are not formed on corresponding points in the two eyes appears double (*binocular diplopia*). Thus if in Fig. 344 we imagine a third object, C, so situated as to form its retinal image in the right eye on the fovea N, and in the left eye on N', the right eye will project it in the direction $M\,A$, and the left eye in the direction $N\,B$, *i. e.*, to a point situated 10 degrees to the right and 5 degrees below A. Hence the mind gets the impression of two objects similar in appearance, one situated straight ahead, the other 10 degrees to the left of the other and 5 degrees below it. Under ordinary conditions the former image, being seen by the fovea, will be much more distinct and solid looking (*real image*), while the other seen by an outlying part of the retina will appear more or less vague and shadowy (*false image*).

When the two eyes are both fixing the same object that object and a large number of outlying objects, too, will appear single, because their respective images fall on corresponding points. All other objects, however, will appear double, and this will be particularly the case with objects either nearer or more remote than the object looked at. This *physiological diplopia* is regarded as one of the most important of the factors enabling us to appreciate depth and relief (*stereoscopic vision*). We are not, however, usually aware that these outlying objects are really double, so that, in general, when we use binocular vision everything is apparently single to us.

It is otherwise when binocular vision is disturbed in any way, so that the image of an object looked at falls on the fovea in one eye and away from the fovea in the other. Then, as we have seen, diplopia must ordinarily ensue. Such a dislocation of the image in the second eye may be due to some actual *deviation of that eye*, so that its fovea is pointing in the wrong direction. Thus if the right eye is looking at an object, A, and the left eye is deflected inward (Fig. 345, C) the image of A will fall on the left retina to the inner or right side of the fovea M, and hence will be projected, not in its proper direction, *i. e.*, out toward A, but to the left (or to B), since every object that forms its image on the right side of the retina is always conceived of as situated in space correspondingly far to the left. In this case the patient will see double, for, while the left eye locates the object at B, the right eye, which is properly directed, will locate it in its right place, A, and the mind will get the impression of there being two similar objects, one at A, the other at B. In this case the amount of the diplopia, *i. e.*,

the apparent distance between the two images, is directly proportional to the deviation of the non-fixing eye.

Diplopia then occurs if one eye looks straight and the other deviates.

The same thing will occur if both eyes are looking straight, but one has *before it a prism.* Thus suppose that the left eye has before it a prism with apex out (Fig. 346). The prism will deflect the rays of light toward its base so that they will impinge, not on the fovea M' but to the inner side of it, or N, and, as before, this image will be projected, not straight ahead but to the left hand of its proper position, *i. e.*, to B. The amount of the diplopia in this case, *i. e.*, the distance between A and B, will be proportionate to the strength of the prism.

Fig. 345

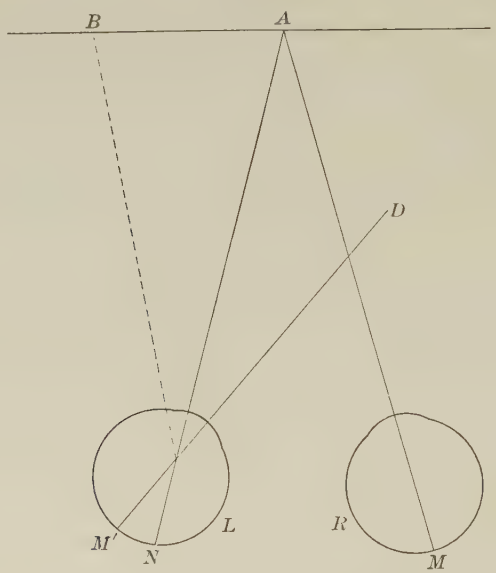

Diplopia Due to Deviation of the Eyes.—The right eye, R, is directed at A, but the left eye, L, is turned inward so as to point in the direction M' D. The image of A in the left eye hence falls on N instead of M', and is projected not toward A, as it is with the right eye, but to the left of A, *i. e.*, to B. The mind, therefore, perceives two images, a *real* one situated at A, and a more or less shadowy *false* image situated at B.

It can readily be seen that in the case shown in Fig. 346 the diplopia thus produced by the prism can be *abolished* or *overcome* by turning the left eye outward until its fovea M' coincides with N, *i. e.*, until it is looking in the direction N P.[1]

It is also plain that a diplopia, whether produced by an actual deflection of the eyes or by prisms, may be corrected by a prism placed before the eye with its apex properly directed. Thus the diplopia produced either by turning one eye in (Fig. 345) or by means of a prism placed apex out (Fig. 346) will be corrected by a prism with its apex in, for such a

[1] Really diverging both eyes equally, then turning both eyes quickly to the left.

prism will deflect the rays of light toward its base, *i. e.*, outward. The retinal image, which owing to the deviation is already situated too far to the nasal side, will then be carried by the prism outward toward the macula. The nearer it gets to the macula the less will the diplopia be, and if the prism is of such a strength that the retinal image is just brought upon the macula, binocular single vision will be restored. The *prism, in fact, that abolishes the diplopia is a precise measure of the amount of the deviation.* We may extend these considerations to all possible varieties of diplopia and present the results in the following table:

TABLE OF DIPLOPIA.[1]

	Name of diplopia.	Image of right eye as compared with that of left is	Caused		Corrected by	
			(1) By a natural deviation of	(2) Artificially by a prism placed, base	(1) Turning	(2) Prism placed with base
Lateral.	Homonymous.	On the right.	Either eye inward (esophoria, esotropia).	In before either eye.	Both eyes outward (divergence).	Out before either eye.
Lateral.	Heteronymous (or crossed).	On the left.	Either eye outward (exophoria, exotropia).	Out before either eye.	Both eyes inward (convergence).	In before either eye.
Vertical.	Right.	Below.	Right eye up or left eye down (right hyperphoria, right hypertropia, left hypotropia).	Up before right eye, down before left eye.	Right eye down and left eye up (left supravergence).	Down before right eye or up before left eye.
Vertical.	Left.	Above.	Right eye down or left eye up (left hyperphoria, left hypertropia, right hypotropia).	Down before right eye, up before left eye.	Right eye up and left eye down (right supravergence).	Up before right eye or down before left eye.

Exceptions to Law of Diplopia.—Vision in Squint.—It must be noted that while binocular fixation is regularly associated with binocular single vision, and absence of binocular fixation with diplopia, this association does not hold for all cases. A man may fix an object with both eyes and yet see it with but one (uniocular vision), either because the other is blind or covered, or because, as often happens in a cured squint, the image formed by that eye is mentally suppressed (see infra). In this case, then there is *binocular fixation, but not binocular single vision.*

Anomalous Diplopia.—In other rather rare cases there may be *binocular single vision, but not binocular fixation.* That is, one eye may deviate and yet both eyes see the object and see it singly. This is usually due to the fact that the deviating eye has learned to project its retinal images differently from the other eye. Such a *false projection* usually persists (often for a long time) after the deviation has been corrected, either by prisms or an operation, and then causes the patient to see double, although the eyes are straight (*anomalous diplopia*). The same anomalous diplopia, due to erroneous projection, we sometimes see when the deviation is still

[1] Modified from the author's article in de Schweinitz and Randall's American Text-book of the Eye, Ear, Nose, and Throat.

present, causing a patient with convergent squint to have crossed diplopia, and one with divergent squint to have homonymous diplopia. The double images in such cases of anomalous diplopia are said to be *incongruous.* Slighter degrees of incongruity, in which the amount of diplopia does not correspond absolutely to the amount of deviation, are not infrequent.

Fig. 346

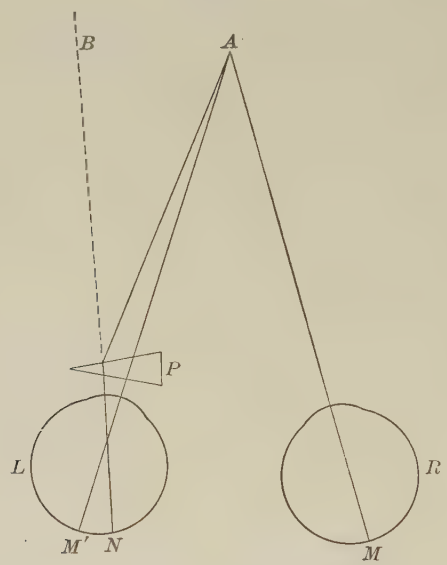

Diplopia Produced by a Prism.—Both eyes are looking at an object, *A*. A prism, *P*, with its base in, is placed before the left eye *L*. This deflects the rays of light so that the retinal image in this eye is found at *N* instead of *M′*. The retinal image in this eye is hence projected out to *B* as many degrees to the left of *A* as *N* is at the right of *M′*. The mind will therefore perceive two images of the same object, one a *real* image at *A*, seen by the right eye, the other a shadowy image at *B*, seen by the left eye.

Suppression of Image.—All deviations should be, and probably all are, primarily associated with diplopia. Yet in the great majority of cases of established squint, especially convergent squint, there is no double vision. This is due to the mental suppression of the image of the squinting eye. In such cases all attempts to evoke diplopia by our tests may be futile, the patient not appreciating the presence of double images even when they are widely separated by prisms. Moreover, this suppression usually persists after the squint is cured, so that even though there are two foveal images of the same object the mind perceives but one and ignores the other, just as though it were not present. In this case there is no true stereoscopic or solid vision.

Amblyopia in Squint.—Lastly, it must be stated that in a great many squinting eyes central vision is very poor and the field of vision often restricted. This amblyopia has been regarded by some as a condition antedating the squint and, in fact, causing it; by others, as due to the prolonged disuse of the squinting eye (*amblyopia ex anopsia*). Which view is correct is still undecided, although the latter seems the more probable.

Monocular Diplopia.—Binocular diplopia due to deviation of the eyes or to prisms must be distinguished from monocular diplopia or the condition in which the patient sees double with one eye alone. This occurs as the result of astigmatism, polycoria, and other conditions (occasionally in squint). It can readily be differentiated by the fact that binocular diplopia disappears when the patient shuts either eye, while monocular diplopia, of course, does not.

Movements of Each Eye Singly.—The movements of each eye individually are effected as follows:

The external rectus moves the eye directly outward; the *internal rectus*, directly inward.

The superior rectus raises the eye. Because of the way in which the muscle runs, obliquely from within outward, its lifting action increases when the eye is abducted, and diminishes to little or nothing when the eye is adducted.

The inferior rectus carries the eye down; and, here again, owing to the oblique direction of the muscle, its depressing action increases as the eye is abducted, and decreases to zero as the eye is adducted.

The inferior oblique is inserted back of the equator of the eye. It hence pulls the back part of the eye down, and consequently throws the front part up. It is thus an elevator of the eye, reinforcing the action of the superior rectus. Owing to the way in which it runs, from in front backward and outward, its elevating action is greatest when the eye is adducted, and diminishes to little or nothing when the eye is abducted.

The superior oblique so far as its action on the eyeball is concerned, may be regarded as arising from the trochlea. From this point it runs backward and outward, and is inserted back of the equator of the eye. It therefore pulls the back part of the eye up and consequently throws the front part down. It is thus a depressor, reinforcing the action of the inferior rectus. Owing to the oblique way in which it runs, its depressing action is greatest when the eye is adducted, and diminishes to little or nothing when the eye is abducted.

Besides these, which are to be regarded as the main actions of the ocular muscles, there are various *subsidiary actions*, due to the oblique way in which the superior and inferior recti and the two obliques run. Thus, both the superior and inferior recti adduct the eye, their action being most pronounced when the eye is already adducted. The two obliques, on the other hand, abduct the eye, and do so most effectively when the eye is already abducted.

The superior rectus and superior oblique rotate the top of the vertical meridian of the eye inward (*intorsion*), while the inferior oblique and inferior rectus rotate it outward (*extorsion*). The superior and inferior recti act thus on the vertical meridian mainly when the eye is adducted; the obliques, on the other hand, when the eye is abducted.

Hence, the eye is *adducted* by the internal rectus, assisted toward the end of its course by the superior and inferior recti. It is *abducted* by the external rectus, assisted toward the end of its course by the two obliques.

It is carried *straight up* by the superior rectus and inferior oblique;

up and out by the superior rectus and external rectus (the inferior oblique helping to carry it out, but not up); and *up and in* mainly by the inferior oblique and internal rectus (the superior rectus helping to carry it in, but hardly at all up).

It is carried *straight down* by the inferior rectus and the superior oblique; *down and out* by the inferior and external recti (the superior oblique helping to carry it out but not down); and *down and in* by the superior oblique and internal rectus (the inferior rectus helping to carry in, but scarcely at all down).

Field of Action of Muscles.—Each muscle, it will be seen, acts most energetically in some special direction of the gaze, which is called the *field of action* of that muscle; thus the external rectus acts most powerfully when the eye is directed outward, and acts little or not at all when the eye is directed inward, except by purely passive traction. So, also, the superior rectus acts mainly when the eyes are directed up, and but little, and that generally in a mechanical or passive way, when the eye is directed down. Furthermore, not only is its action limited mainly to the upper field, but, so far as its elevating power is concerned, it is limited to the upper and outer field, for in the upper and inner field elevation is performed chiefly by the inferior oblique.

The like is true of each of the other muscles.

We have, in fact, six *cardinal directions* of the gaze, each corresponding to the field of action of one of the six ocular muscles, as follows:

Cardinal Direction.	Muscles Specially Active.
Straight out.	External rectus.
Straight in.	Internal rectus.
Up and out.	Superior rectus (as an elevator).
Up and in.	Inferior oblique (as an elevator).
Down and out.	Inferior rectus (as a depressor).
Down and in.	Superior oblique (as a depressor).

It is to be noted that the action of each muscle does not stop absolutely at the middle line, but extends somewhat beyond it. Thus the action of the right externus extends not only throughout the whole right half of the field of vision, but also some 15 degrees to 20 degrees to the left of the median line, and that of the superior rectus extends not only above the horizontal plane, but also somewhat below it.

Primary Position.—Field of Fixation.—Under normal conditions, when the head is erect and the eye is directed straight forward[1] in the horizontal plane, the muscles are all balanced. This is called the position of equilibrium, or the *primary position.* It is the position that we should make the patient assume when conducting our tests for balance of the muscles.

From the primary position the eye may make excursions in every direction, so that without moving the head the patient can look at a whole series of objects in succession. The portion of space occupied by

[1] That is, when its line of sight is perpendicular to the line joining the centres of rotation of the two eyes.

all the objects that thus can be seen directly by moving the eye without moving the head is called the *field of fixation.* (See Section on Tests, page 722.)

Binocular Movements.—While either eye alone may move in all possible directions, it cannot move independently of the other eye. Under ordinary circumstances those movements only are possible which are regularly required to subserve binocular vision, and hence, also, binocular single vision. These movements are as follows:

1. **Parallel Movements.**—When one eye looks at a distant object the other is also directed at it, so that the lines of sight of the two eyes are parallel, and if the distant object is moved about, the lines remain parallel, one moving as fast and as far as the other. These parallel movements of the two eyes are executed with considerable freedom in all directions, either eye being able to move readily to the right, left, up, down, or obliquely, provided the other eye moves precisely with it.

In executing any one of the countless possible parallel movements, each eye is, generally speaking, acted upon by at least three and sometimes by as many as five muscles. But of these muscles two at most (and sometimes only one) produce any great movement of the eye, the others serving simply to steady it in its course. Thus when we look to the right, although there are five muscles really acting upon each eye, the right eye is moved mainly by the external rectus, and the left eye by the internal rectus. So also when we look up and to the right, although other muscles take part, the superior rectus is the chief muscle that moves the right eye up, and the external rectus the chief one that moves it to the right, while for the left eye the inferior oblique and the internal rectus are the efficient muscles. A careful study of the actions of the individual muscles as shown on page 720 will make it clear that these facts hold good for each of the cardinal directions of the gaze.

Furthermore, if we attentively consider the actions of the twelve muscles moving the two eyes, we see that they may be divided into three groups, viz., four lateral rotators, four elevators, and four depressors.

A. Lateral Rotators.

(a) *Right rotators.*	(b) *Left rotators.*
R. external rectus.	R. internal rectus.
L. internal rectus.	L. external rectus.

B. Elevators.

(a) *Right-handed elevators.*	(b) *Left-handed elevators.*
(Acting mainly when the eyes are directed to the right.)	(Acting mainly when the eyes are directed to the left.)
R. superior rectus.	R. inferior oblique.
L. inferior oblique.	L. superior rectus.

C. Depressors.

(a) *Right-handed depressors.*	(b) *Left-handed depressors.*
(Acting mainly when the eyes are directed to the right.)	(Acting mainly when the eyes are directed to the left.)
R. inferior rectus.	R. superior oblique.
L. superior oblique.	L. inferior rectus.

Each group, it will be seen, comprises two pairs of muscles, one pair acting solely or mainly when the eyes are directed to the right, the other when they are directed to the left. It will further be noted that of the two muscles constituting any one pair, one is situated in the right eye, the other in the left.

The muscles forming any one pair are called *associated antagonists*, or *associates*. Any two associates acting together will move their respective eyes in precisely the same direction and to the same extent. Thus the right superior rectus moves the eye up to the left and rotates its vertical meridian to the left; and its associate, the left inferior oblique, moves its eye up to the left and rotates its vertical meridian to the left. So, also, with each of the other five pairs of associates.

If one eye fails to keep pace with the other in executing parallel movements, diplopia ensues.

If we make the eyes move in all directions and note the points where the patient just begins to see double we delimit the *field of binocular single vision*.

Normally, however, the two eyes maintain parallelism up to the very limits of their excursion, so that diplopia occurs only at the extreme periphery of the field of vision, if at all. In fact, the field of binocular single vision usually extends not less than 40 degrees from the primary position in every direction.

Each of the various parallel movements of the eyes appears to be governed by a distinct nervous mechanism, there being one centre for movements to the right, one for movements to the left, one for movements up, etc.

2. **Movements of Convergence.**—In order to see an object near by, the eyes have to converge, a movement effected by a simultaneous and equal contraction of both internal recti. This movement may be combined with a vertical, lateral, or oblique parallel movement. Thus, when we wish to look at a near object situated 20 degrees to our right, we first turn both eyes 20 degrees to the right, then converge both equally, turning the left a little more to the right and the right a little back toward the left.

Convergence is governed by a distinct nervous mechanism, the site of which has not been determined.

3. **Movements of Divergence.**—In passing from a position of convergence to a position of parallelism the lines of sight separate or diverge. This movement of divergence is effected by a simultaneous equal relaxation of both interni, or a simultaneous equal contraction of both externi, or probably of both actions combined. The eyes may even diverge somewhat beyond parallelism, as in overcoming prisms, base in, when looking at a distant object.

4. **Vertical Divergence.**—The amount by which the lines of sight can separate in a vertical direction is very limited (1 degree or 2 degrees at most).

Tests.—1. **Tests for Movements of Each Eye Singly.**—The ability of each eye singly to move in the various directions, thus delimiting its field of fixation (see page 719), may be estimated roughly by ascertaining how

far the eye can follow the finger or a light. In movements outward the outer edge of the cornea should go to the external canthus, and in movements inward the inner edge of the cornea should reach at least as far as the caruncle. More accurately the field of fixation is taken with a *tropometer* (Fig. 347) or with a *perimeter*. With the latter the head is placed so that the eye when in the primary position is looking directly at the zero mark of the scale. The head should be kept rigidly fixed during the examination. An object (either a line of fine print, or, better, two dots set close together on a card) is then passed along the perimeter arm and the patient is directed to follow it with his eye, but not with his

Fig. 347



Stevens' tropometer consists essentially of a telescope in which the inverted image of the examined eye is found at the eye-piece, where its movements can be accurately observed. A graduated scale in the eye-piece permits every movement of rotation, in any direction, to be exactly measured. The patient's head is fixed immovably in a chin-rest.

head, until the object blurs, which in the case of the two dots will be known by their running into one. The perimeter arm being successively set in different directions the limit of the excursion in every direction will thus be defined.

The limits of the *field of fixation* as defined by the perimeter were found by the author[1] (37 measurements of 18 subjects) to be as follows:

Field of Fixation.

	Up. Degrees.	Up and out. Degrees.	Up and in. Degrees.	Out Degrees.	In Degrees.	Down. Degrees.	Down and in. Degrees.	Down and out. Degrees.
Average	43	46	49	51	53	63	54	61
Minimum	35	35	35	40	40	35	32	38

Such measurements will vary widely even in the same subject, and the

[1] Duane, Motor Anomalies of the Eye.

only way to obtain reliable data in any given case is to make a series of examinations on different days, and take the highest result of all as indicating the patient's maximum power of movement in any given direction.

Fig. 348

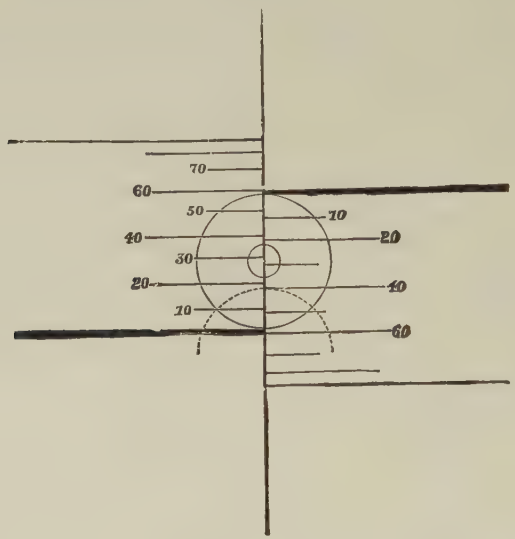

Scale of Stevens' Tropometer.—The long line between and at right angles to the shorter lines divides two similarly graduated scales running in different directions; the larger circle represents the outer border of the cornea, the edges of which are in contact with the two strong lines; the interval between each pair of short lines of the scale is ten degrees of arc, commencing at the strong line in each case. If now the head of the person examined is held firmly in the primary position and the eye caused to rotate strongly in a given direction, the arc through which the border of the cornea passes may be accurately read upon the scale. In the figure, *B*, the curved dotted line, represents a new position of the border of the cornea.

Suppose that the person examined has been directed to look strongly upward, then the cornea has moved down the scale and reaches the point in this example of 40 degrees, that being the measure of rotation. By means of the small lever the scale can be placed horizontally, vertically, or obliquely, and by means of the two graduations measurements in opposite directions can be made.

2. **Tests of Binocular Fixation.—Screen Test.**—This is made both for distance and for near. *For distance*, the best test object is a white disk, one-quarter of an inch in diameter, in the centre of a large black circle at least one foot wide. As the patient looks fixedly at this a card is placed before the right eye and then passed alternately and quickly from one eye to the other. If there is any deviation or tendency to deviation (squint or heterophoria) each eye will deviate when covered and will turn back into position when uncovered (movement of redress). Thus if there is an esophoria or strabismus convergens, and the screen is passed from the right eye to the left, the left will deviate in behind the screen, and the right eye, which when covered was deviated in, now on being uncovered turns into place; that is, out, in order to make fixation.

For near, the test is made in the same way, except that a fine black dot on a circular white card six inches in diameter is used as a test-object. This is usually held at about ten inches from the eyes.

The amount of *deviation is measured* by the prism that corrects it. Thus if the eye deviates in behind the screen we place one prism after another, base out, before the eye until the movement is just over-corrected, that is, turned into a movement out behind the screen. Then this prism less 2 degrees will represent quite closely the amount of the deviation.

In deviations of 2 degrees or under there is usually no perceptible screen movement, but in this case we determine the first prism that produces a movement one way, and then the first that produces a movement the other way; the mean will represent the true finding. Thus if it takes a 5 degree prism, base out, to cause a movement outward, and a 1 degree prism, base in, to produce a movement inward, the true condition would be one corrected by a prism of 2 degrees, base out, *i. e.*, 2 degrees of esophoria.

The screen test is also used in another way (called "*binocular uncovering*") to determine whether the deviation that is present is a squint or heterophoria. In the former case, when both eyes are uncovered but one eye fixes; in the latter case both eyes will fix. The test is made, then, by directing the patient to look at a test object with both eyes, and then suddenly covering one eye, say the right. If the case is one of heterophoria, the right eye, which before was fixing with its fellow, will now deviate, while the left will remain fixing; then, the cover being removed, the right eye will move back into place again, while the left still remains in its position of fixation. If, however, the case is one of strabismus of the right eye, this eye will be deviated already at the time the screen is put before it, will remain deviated while the screen is on, and will continue so, too, when the screen is taken off again. The left eye, which was fixing before the screen was put on the right eye, will remain fixing still, both when the cover is put over the right eye, and also when it is taken off again. Hence, neither eye moves. If, however, in the same case the screen had been placed before the left eye, the right eye, which was deviating, would now have to move into place in order to fix, and as it does this, the left, which is behind the screen, deviates. When the screen is taken off, and both eyes are again exposed, the left eye, which is the eye regularly used for fixing, moves back into place, and the right eye moves into its habitual condition of squint. Hence, if in the presence of a deviation of any amount the screen is suddenly placed before one eye and then taken off again, three things may occur:

A. But one eye moves, and that the one that is covered. There is *heterophoria*.

B. Neither eye moves. There is *squint* affecting the eye before which the cover is placed.

C. Both eyes move. There is *squint* affecting the eye which has been left uncovered.

By performing binocular uncovering several times with each eye in succession we can tell whether one eye, such as the right, squints all the time (*uniocular squint*) or whether sometimes one and sometimes the other squints (*alternating strabismus*.)

Another test for the presence or absence of binocular fixation and for

ascertaining the amount of deviation in the case of a squint is the *perimeter*. This test is made as follows:

The patient is placed with the squinting eye in the centre of the perimetric arc, which is set horizontally. The good eye is covered, and the patient is directed to gaze, with the squinting eye at a candle flame placed at the zero point of the arc. The observer standing behind the candle, notes the precise point on the cornea occupied by the image of the flame. The good eye is then uncovered and is directed at a distant object situated in the prolongation of a line connecting the squinting eye with the zero of the perimetric arc. The candle is then carried along the perimeter arc until the image of the flame, as seen by the observer standing directly behind the candle, occupies the same position on the cornea of the squinting eye that it did when that eye was fixing. The point of the arc at which the candle stands indicates the amount of squint in degrees.

In comparing results obtained with the screen test and the perimeter it must be remembered that the latter gives us the actual amount of the deviation, the former the refracting angle of the correcting prism. The relation between the two is shown in the following:

TABLE SHOWING RATIO BETWEEN REFRACTING ANGLE OF A PRISM AND THE DEVIATION PRODUCED BY THE PRISM.

Refracting angle of prism.	Corresponding deviation.	Refracting angle of prism.	Corresponding deviation.
1	0.5	21	11.7
2	1.1	22	12.3
3	1.6	23	12.9
4	2.1	24	13.5
5	2.6	25	14.1
6	3.2	26	14.8
7	3.8	27	15.4
8	4.4	28	16.0
9	4.9	29	16.7
10	5.4	30	17.3
11	6.0	31	18.0
12	6.5	32	18.7
13	7.1	33	19.4
14	7.6	34	20.1
15	8.2	35	20.8
16	8.8	36	21.5
17	9.4	37	22.3
18	10.0	38	23.1
19	10.5	39	23.9
20	11.1	40	24.7

This table can be used whenever there is a question of converting any measurements made with prisms into actual measurements of arc. Thus if we wish to find out what is the actual degree of divergence of the eyes corresponding to a crossed diplopia that is abolished by a prism of 11 degrees we see from the table that it must be 6 degrees; and if we ask through what angle the eyes actually converge when they overcome a prism of 31 degrees, base out, placed before one eye, the table shows us that it must be 18 degrees.

In making measurements with prisms in this way, no prism or aggregation of prisms amounting to more than 40 degrees should be placed before

one eye, as when higher prisms are used slight variations in the way in which they are held cause considerable variations in the deviation they produce, so that precise measurements would be impossible. When higher deviations are to be measured, prisms should be placed before each eye, and their combined effect computed. Thus a deviation corrected by a prism of 36 degrees before one eye and 19 degrees before the other would be 21.5 + 10.5 = 32 degrees' actual deviation.

3. **Diplopia Tests for Imbalance.**—All the remaining tests for imbalance are dependent in some way upon the projection of double images, and are, therefore, *tests of binocular vision*, and not, like those just mentioned, tests of monocular and binocular fixation. When, therefore, there is incongruity of the double images these tests will not agree with the screen and other tests just described.

The first of the diplopia tests is:

A. Parallax Test.—In making the screen test, if the test object appears to the patient to move to the right when the screen is transferred from the right eye to the left he is said to have a *homonymous* parallax. This corresponds really to a homonymous diplopia; that is, to an esophoria, the only difference from ordinary diplopia being that the images are seen alternately instead of simultaneously.

So, also, if the object seems to move to the left when the right eye is uncovered he has a *crossed* parallax (= exophoria); if it moves down he has a *right* parallax (= right hyperphoria); and if it moves up he has a *left* parallax (= left hyperphoria).

The amount of deviation is measured precisely by the prism, base out, base in, base down, or base up, respectively, that will just abolish the movement. This test is an extremely delicate one. It is conducted simultaneously with the screen test, and, like the latter, must be made for both distance and near.

B. Diplopia Test.—If there is a strong tendency to deviation the patient will often see double if simply a red glass is placed before one eye.

The diplopia, whether homonymous, crossed or vertical, can be corrected by prisms (see page 725), and the prism abolishing it furnishes a rough, usually insufficient estimate of its amount.

C. Stevens' Stenopeic Lens.—This consists of a +13 D. lens, covered, except at its optical centre, where an aperture 3 mm. in diameter is left. The patient placing this before his right eye, and looking through it at a light, sees a circular disk of light while the left eye sees the flame as it really is. If the eyes are absolutely balanced the light seen by the left eye occupies the centre of the luminous disk seen by the right eye; while in the case of lateral deviation the light will appear to one side of the centre, and if there is hyperphoria, will appear above or below it. The amount of deviation will be determined by the prism that brings the light just to the centre of the disk.

D. Maddox Rod.—This consists of a cylinder or a series of cylinders of glass set in a frame. The patient places this before the right eye in such a way that the rods run vertically, and looks at a light. To this

eye the light then appears as a long horizontal streak. If the two eyes are on the same level the streak will seem to run through the undistorted image of the flame seen by the left eye; if, however, there is right hyperphoria, the streak will fall below the light, and if there is left hyperphoria, above it.

Fig. 349



The Maddox rod.

Similarly, if the rod be placed horizontally the patient will see a vertical streak, which will be on the right of the light in esophoria, and to the left of the light in exophoria.

The amount of deviation may be measured by ascertaining the prism that overcomes it, or directly by measuring along a tangent scale placed just back of the light.

E. Phorometer.—The phorometer is a modification of *Graefe's prism test.* In this latter a prism is placed before the right eye with its base in, so as to produce an artificial homonymous diplopia. The two images, if the prism is accurately leveled, should be also level. If the right image is lower, there is right hyperphoria, if higher, there is left hyperphoria.

Again, if the prism is placed, base up, before the right eye the image of that eye is thrown below that of the left; if, then, there is esophoria this lower image will stand to the right of the upper. If there is exophoria it will stand to the left.

The amount of deviation may be determined by the additional prism, placed base in, base out, base up, or base down, that will put the two images precisely in line. Or the same thing may be effected by revolving the prism which was used to produce the diplopia in the first place until the images are in line, and from the angle through which the prism is turned deducing the amount of deviation.

In the *Stevens' phorometer* (Fig. 350) there are two prisms which are rotated simultaneously until the images are in line, the amount of deviation being indicated by an index which points to a graduated arc on either side.

The instrument is first levelled and then placed so that its right-hand index points to zero. If the images are level there is no hyperphoria; if not, the prisms are rotated until the images are level, when the index will indicate the amount and kind of hyperphoria.

Then the prisms are revolved until the left-hand index points to zero. If the images stand straight over each other there is no lateral deviation; but if this is not the case the prisms must be rotated until the images are just in a vertical line, when the index on the left-hand arc will show the amount of exophoria or esophoria, as the case may be.

4. **Tests of Parallel Movements.**—We may determine:

A. Field of Binocular Fixation.—This is the extent to which the two eyes can move and still both maintain fixation in following a moving object. This can be made out roughly by the *excursion test, i. e.,* carrying a pencil or some other object through the six cardinal direc-

tions—right, left, up and right, up and left, down and right, and down and left, and observing at what point either eye begins to lag behind the other or wander off from the fixing position. If such lagging takes place soon there must be insufficiency of the corresponding muscle. (See Section on Paralysis.)

The same may be determined by applying the *screen test* according to the principles outlined on page 724, but with the test object placed in the various outlying portions of the field instead of straight ahead.

In either test the patient's head must be immobilized, the eyes alone being allowed to follow the test object.

Fig. 350



Stevens' phorometer.

B. Field of Binocular Single Vision.—This is determined by covering the right eye with a red glass and carrying a candle held about three feet from the patient through the various cardinal directions, viz., right, left, up and right, up and left, down and right, and down and left. In each position it must be noted if there is diplopia, how much it is and of what kind, that is, whether homonymous, crossed, right, or left.

The amount of diplopia can be ascertained by the distance apart of the

double images ascertained on a tangent scale,[1] or, less precisely, by the prism which serves to overcome it.

5. **Tests of Convergence.**—The amount of convergence is determined by ascertaining:

A. Convergence Near-point.—This is done by carrying a card with a dot on it up to the eyes in the middle line until the dot doubles, or until one eye evidently diverges. The distance of the dot from the root of the nose should not be more than one and one-half or at most two inches (or should not be more than two and one-half inches from the cornea). If much more than this, the convergence is deficient.

Fig. 351

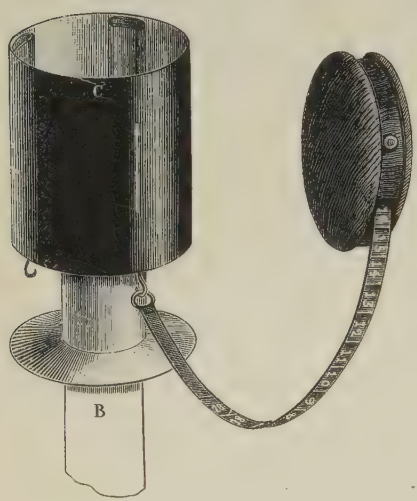

Landolt's ophthalmodynamometer.

The same test can be made with somewhat more precision by means of Landolt's ophthalmodynamometer.

B. Prism-convergence (*so-called Adduction*).—This is measured by the amount of prism, base out, which the eye can overcome—that is, see singly with—when looking at a distant object. This amount varies extremely in different persons and in the same person at different times, being much increased by practice, but can, in general, be brought up to 60 degrees to 90 degrees of prism, representing an absolute convergence of 40 degrees to 60 or 65 degrees. The mere fact that a patient does not, at first, overcome more than 12 degrees to 15 degrees of prism, base out, is no proof that his convergence is defective, and still less that his interni are weak. Only when a patient after repeated trials cannot overcome low prisms, base out, or if overcoming them he cannot hold the images together, can we infer that his convergence is really subnormal? Prism-convergence may be measured both for distance (20 feet) and for near.

6. **Tests of Divergence.**—Divergence is measured by determining the amount of prism, held base in, before the eyes, which the patient can overcome. The tests can be made both for distance and for near. Normally, the amount of prism so overcome (*prism-divergence*, or, less properly, *abduction*) is from 4 degrees to 8 degrees for distance, while for near it varies anywhere from 10 degrees to 25 degrees. A prism-divergence of less than 4 degrees for distance indicates subnormal, and one of over 9 degrees supernormal, diverging power.

[1] A very convenient appliance for this purpose is the tangent-plane described by the author, Duane, Trans. Am. Ophth. Soc., 1906.

It must be noted that there is no fixed normal ratio between the amount of prism-convergence (adduction) and that of prism-divergence (abduction); the former, as above stated, being a variable quantity, susceptible of almost indefinite increase by exercise.

Prism tests, particularly those for divergence and convergence, are best made with square prisms, which are either simply held before the eyes or are slipped into a trial frame having square cells. Special *prism piles*, or *prism batteries*, have been devised for the purpose but have no particular advantage over the single prisms.

7. **Tests of Vertical Divergence.**—The ability of the eyes to deviate in a vertical plane (*supravergence*) is ascertained by determining the amount of prism, base up or base down, that the eyes can still overcome when looking at a distant object. This amount does not usually exceed 2 degrees or 3 degrees of prism, representing 1 degree of actual divergence. In certain cases, especially where there is hyperphoria, or in persons who wear strong, ill-fitting glasses which act like prisms, the supravergence may be as high as 5 degrees to 10 degrees. If a person overcomes a prism of only 1 degree, base down, before the right eye (right supravergence or sursumduction), or base up before the left eye (left deorsumduction), and can overcome 2 degrees or 3 degrees prism held in the opposite direction he will usually be found to have left hyperphoria.

8. **Tests for Torsion.—Declination.**—When one eye is rotated so that its vertical meridian is no longer vertical, but tipped to one side, objects looked at will also appear tipped and in the opposite direction, *i. e.*, if the right eye is rotated inward (intorsion) a vertical line seen by that eye will appear tipped outward.

Both intorsion and extorsion may be detected and measured by the following means:

A. Tipping of Images.—If there is diplopia we can ascertain whether one of the double images appears tipped while the other is straight. If one image appears tipped to the right the corresponding eye is tilted to the left, and vice versa.

B. Maddox Rod.—If this is put in a trial frame before the affected eye and set accurately vertical the streak of light seen with it will appear tipped and the Maddox rod will have to be rotated through a certain angle before the streak becomes vertical. The amount of rotation indicates the amount of pathological torsion. Thus, if the rod placed before the right eye has to be turned so that its inner end stands at 10 degrees instead of at zero, the eye is extorted 10 degrees. The direction of the Maddox rod in this case indicates the direction of the horizontal meridian of the eye.

C. Maddox Double Prism.—This consists of two prisms with their bases together (Fig. 352). When this is held before one eye and the patient looks with both eyes at a horizontal line, he sees three lines, the lines above and below being seen by the eye armed with the double prism, and the middle one by the other eye. Theoretically, if this middle line is parallel with the others there is no torsion; if not (Fig. 353), there is. Practically, however, the instrument will often be found unreliable, indicating torsion where none exists, or vice versa.

Clinoscope.—More elaborate instruments, called clinoscopes or clinometers, have been devised for the same purpose, but the above, and particularly the Maddox rod, will be found sufficient for practical purposes.

When the eyes are converged, as in looking at an object which is pretty close to them, they regularly undergo a moderate torsion, which is, therefore, physiological. Tests for pathological torsion should, accordingly, be made with the object of fixation at a distance of several (preferably fifteen or twenty) feet.

Fig. 352

a *b*

Maddox double prism: *a*, front view; *b*, sectional view.

Fig. 353



Torsion demonstrated by Maddox double prism.

9. **Tests of Binocular Vision.**—We often wish to determine if a patient, whether he has binocular fixation or not, has or has not binocular vision, *i. e.*, we wish to know whether with both eyes open he actually sees with both or suppresses the image of one (see page 718).

The most usual tests are:

1. Red Glass.—This placed before one eye when the patient is looking at a candle flame will if he has binocular vision give him two images, one red and the other yellow. If he has not only binocular vision but also binocular single vision, the two images will be superimposed, giving a single particolored—yellow and red—flame. If he has only monocular vision he will see but one flame, which is either distinctly red or distinctly yellow.

2. Maddox Rod.—With this the patient in case he has binocular vision will see both the streak and the flame. If he has also binocular single vision the streak and the flame will be superimposed. If he has monocular vision he will see the flame alone or the streak alone.

3. Stereoscope.—Suppose a man looks through a stereoscope at a picture whose two halves are quite dissimilar. If he has monocular vision he will see but one-half, right or left, as the case may be. If he has binocular vision he will see both halves, and if in addition he has binocular single vision he will fuse the two into one.

This test can be made even better with the *amblyoscope*. (See under Treatment, page 752.)

4. Bar Reading.—In this the patient while reading holds a bar of wood, one-fifth inch wide, lengthwise between him and the page, and about two inches from the latter. If he then can still read every word,

he must be seeing with both eyes, and also have binocular single vision. For if he has only monocular vision the bar would hide some of the letters from the eye which alone is seeing; and if he had double vision, the deviating eye would see some letters indeed, but not the ones that are behind the bar.

5. HERING'S TEST.—The patient looks with both eyes through a large tube, across the further end of which a thread is stretched vertically. Balls are dropped alongside the thread, some forward and some back of it. If, then, he can tell with a good approach to accuracy when the balls fall in front of the plane of the thread and when behind it he has not only binocular vision but also perception of depth (stereoscopic vision).

Way in Which Tests are Made in Practice.—Tests of convergence, divergence, and the other movements of the eyes often act in a disturbing way upon the natural balance of the eyes; hence they should be made after the tests for imbalance.

In ordinary cases the following tests are sufficient. They should be made in the order given:

A. We determine the *deviation for distance* (twenty feet) by:

1. The *screen* and—

2. The *parallax* simultaneously, and at the same time by binocular uncovering (see page 725), ascertain whether we are dealing with a squint or a heterophoria.

3. The *Maddox rod* (first testing for hyperphoria, then for lateral deviation).

4. The *phorometer* (again first testing for hyperphoria and then for lateral deviation).

B. We determine the *deviation for near-points* (ten inches) by—

5. The *phorometer* (testing usually for lateral deviation only).

6. The *screen* and—

7. The *parallax* simultaneously, and here again we determine by binocular uncovering whether we are dealing with a squint or a heterophoria.

C. We next measure:

8. The *convergence near-point.*

9. The *prism-divergence* (abduction) with prisms, base in.

10. The *prism-convergence* (adduction) with prisms, base out. This test is scarcely necessary if the convergence near-point is normal.

11. The *field of binocular single vision* with the candle at three feet, noting at the same time whether each eye follows the candle in all its movements or whether one eye lags behind its fellow—thus ascertaining by—

12. The *excursion test* if the field of binocular fixation is normal or not.

D. In complicated cases we also determine:

13. The declination or torsion of each eye by means of the Maddox rod or the clinometer.

14. The *field of monocular fixation* for each eye with the tropometer or perimeter.

What the Tests Should Show.—In a case that is completely normal we should get from the tests above described the following results:

With tests 1, 2, 3, and 4 either strict orthophoria for distance or not more than 1 degree of esophoria or exophoria and $\frac{1}{2}$ degree of hyperphoria. The Maddox rod, it may be noted, not infrequently shows from $\frac{1}{2}$ degree to 1 degree more esophoria than the other tests indicate.

With tests 5, 6, and 7 either orthophoria for near or not more than 2 degrees of exophoria. If, as should not be the case, a coarse, ill-defined test object is used upon which the patient cannot fix accurately, more exophoria may be developed particularly by the phorometer.

With test 8 a convergence near-point of not more than $2\frac{1}{2}$ inches from the cornea.

With test 9 a prism-divergence (abduction) for twenty feet of not less than 4 degrees and not more than 8 degrees.

With test 10 a prism-convergence (adduction) of between 15 degrees and 20 degrees, done with ease after one or two trials. In a normal patient this amount can be rapidly increased by practice until in a few days it is brought up to 60 degrees to 80 degrees of prism; that is, a prism 30 degrees to 40 degrees before each eye.

With tests 11 and 12 the patient follows the candle in all its movements without lagging or hesitation of either eye, and no diplopia occurs even up to the very limit of the excursion in any direction.

With test 13 torsion not exceeding 2 degrees in either eye.

With test 14 the excursion of either eye will be found to be not less than 35 degrees and usually not less than 40 degrees in any direction. In looking down, indeed, the excursion should be not less than 50 degrees, and is usually not less than 55 degrees, and in looking to the right and the left should not fall below 40 degrees.

Way of Making Tests in Case of Squint.—In cases of squint, binocular vision, as we have seen, is often altogether absent and the diplopia tests fail since the patient cannot be got to recognize double images. Hence, the phorometer and the Maddox rod tests and the tests of divergence and convergence with prisms are inapplicable. We then rely mainly upon the screen test, which should be made carefully for distance and near. Furthermore, by our measurement of the excursions of the eyes, either in monocular fixation (tropometer) or better in binocular fixation in following a white-headed pin or a lighted taper, we can ascertain whether one eye follows the other or not in all its movements or at some point lags behind. The screen test may also be applied in the different cardinal directions of the gaze to ascertain whether the deviation remains the same or not in various parts of the field. Lastly, by carrying a pencil or small electric light toward the eyes we can determine whether there is or is not still a tendency for them to converge upon it properly.

The test object chosen should always be such as the eye can recognize and fixate. Thus in dealing with an amblyopic eye it is necessary to use some bright and conspicuous object, such as a lighted candle, for the patient to look at. When the patient has good vision, the test object, particularly for near-points, should be as small as he can well see and be sharply defined, so that he is obliged to fix accurately upon it.

The conditions under which the tests are made, for example, whether

with or without atropine, or whether with or without correction of the refraction, should always be noted.

Nature of Deviations in General.—Deviations of the eyes may be due to some affection of the individual muscles, in which case they are usually monocular or, at all events, affect the two eyes in different ways; or may be due to derangement of one of the coördinate movements of the eyes (convergence, divergence, or parallel movements). In the latter case they are essentially binocular, and affect each eye equally and in a similar way.

We have, therefore, the following varieties of ocular deviations, viz.:

A. Affections of the individual ocular muscles:
  1. Paralysis of individual ocular muscles.
  2. Spasm of individual ocular muscles.

B. Affections of coördinate movements:
  1. Anomalies of the converging function.
     Convergence-excess.
     Convergence-insufficiency and paralysis.
  2. Anomalies of the diverging function.
     Divergence-excess.
     Divergence-insufficiency and paralysis.
  3. Anomalies due to torsion.
     Cyclophoria.
  4. Anomalies of the associated parallel movements.
     Conjugate paralysis.
     Conjugate spasm.
     Nystagmus.

Paralyses of Individual Muscles.—**Diplopia.**—What happens in the case of paralysis of an eye muscle can best be understood by taking a concrete example. Suppose, for instance, the right externus is paralyzed. Then when an attempt is made to look to the right the left eye will move properly but the right will lag behind, or, if the paralysis is complete, will not move at all. The further the eyes try to move to the right the greater the discrepancy will become. If, on the other hand, the eyes move to the left the discrepancy between the movements of the two eyes will become less and less marked; and when the eyes have passed out of the field of action of the externus (see page 719), and are directed some 20 degrees to the left, the right eye moves parallel with the left. Hence, in paralysis of the right externus we have a convergence (paralytic squint) and with it a homonymous diplopia, which increases as the eyes are directed to the right and decreases as the eyes are directed to the left—in other words, we have a non-comitant deviation. Furthermore, it can be seen that the ability of the right eye to move outward is impaired; that is, its range of excursion is diminished in this direction, namely, to the right.

Applying these facts to each of the muscles in turn, we may say that, in paralysis of any muscle, the movement of the eye is limited, and the more so the more the eyes are carried in the direction in which that muscle naturally moves the eye. As a result of this, as soon as the eye enters in

the field of action of the muscle affected the *paralyzed eye lags* more and more behind its fellow and there is an *increasing diplopia,* while outside of this field of action there is no deviation and no diplopia.

Furthermore, since by paralysis of the muscle the affected eye is deflected in a direction (*B*) diametrically opposite to (*A*) that in which the muscle if unparalyzed would carry it, and since when the eye is deflected in a wrong direction (*B*) the image of that eye is thrown in the opposite direction (*A*), we may say: *In diplopia due to paralysis the image belonging to the affected eye will always be deflected in the direction in which the muscle if unparalyzed would have carried it.* Thus in paralysis of the right superior rectus, a muscle which carries the right eye up, in (to the left), and tilts the vertical meridian to the left, the image of the right eye is carried up above the other, is carried to the left of the other (*i. e.*, there is crossed diplopia), and is tilted to the left.

Varieties of Paralysis.—A paralysis may affect one or several of the eye muscles. Very often all the muscles supplied by the third nerve are paralyzed (*oculomotor paralysis*). In this case the eye cannot move upward because of the paralysis of the inferior oblique and superior rectus, nor move inward on account of the paralysis of the internal rectus, nor downward, except in slight degree, because the only active depressor (the superior oblique) is unable to act efficiently, since, owing to the unopposed action of the external rectus, the eye is deflected outward. Movement outward is retained.

Furthermore, since the levator, sphincter iridis, and ciliary muscle are paralyzed the upper lid droops (ptosis), the pupil is dilated and immobile, and the accommodation is paralyzed so as to cause marked blurring of the vision for near, and in hyperopes, blurring for distance also.

In many cases the exterior muscles supplied by the third nerve are paralyzed in greater or less degree, but the ciliary muscle and sphincter are intact (*ophthalmoplegia exterior*). Again, the ciliary muscle and sphincter alone may be paralyzed (*ophthalmoplegia interior*).

Taking the individual muscles supplied by the third nerve, we find that *isolated paralysis* of the superior rectus is very frequent, paralysis of the inferior rectus (especially traumatic paralysis) fairly so, while isolated paralysis of the inferior oblique is one of the greatest of rarities and is generally traumatic. Isolated paralysis of the externus (*abducens paralysis* is very common; isolated paralysis of the superior oblique (*trochlear paralysis*) fairly so.

Paralysis of all the exterior muscles of the eye is called *total ophthalmoplegia.*

Etiology of Paralysis.—Paralysis, if we use the term in the widest sense so as to include powerlessness of a muscle from whatever cause, may be classed as structural, insertional, and innervational.

Structural Paralysis.—In structural paralysis the muscle is weak, either because it is congenitally undeveloped, altogether absent, or replaced by connective tissue, or because it is atrophic from disease or weakened by injury.

Insertional Paralysis.—This is a weakness due to malposition of the tendon so that the muscle, although strong enough, does not act effectively upon the eyeball. It may be congenital, or may be acquired as a result of section of the tendon by accident or design (tenotomy), causing it to retract and reattach itself in an unfavorable situation.

Innervational Paralysis (*Paralysis Proper*).—This is weakness due to insufficient nerve supply.

The seat of a lesion producing a paralysis may be in the orbit (*orbital* paralysis), or at the base of the brain in the middle cranial fossa (*basal* paralysis), or in the brain substance between the nuclei and the point of emergence of the nerves (*fascicular* paralysis), or in the nuclei themselves (*nuclear* paralysis). Lesions situated above the nuclei do not cause paralysis of the muscles, but paralysis of one or the other of the conjugate movements.

The lesions causing an innervational paralysis are:

1. *Solution of continuity* or *congenital defect* either of the nerve itself or of its central connections.

2. *Pressure* upon the nerve or its central neurons from—

a. Inflammatory exudates (meningitis, brain abscess, periostitis, disease of the sinuses adjoining the orbit, etc.).

b. Callus (in fractures of the base or of the orbit).

c. Hemorrhages either from traumatism or occurring spontaneously in arteriosclerosis or in miliary aneurysms of the cerebral vessels.

d. Neoplasms (especially gummata).

e. Enlarged vessels (aneurysm) or thrombosis (especially of the cavernous sinus).

3. *Anemia* or *hyperemia* of the nerve or its central connections; occurring either as the result of pressure from any cause upon the vessels supplying the nerve or its nucleus, or as one of the symptoms of a general disturbance of the cerebral circulation.

4. *Softening* or *degeneration* of the nerve or its nucleus.

The main *conditions giving rise to these lesions* are:

1. *Congenital anomalies* of the muscle or its tendon, less often probably of its supplying nerve. Not very common.

2. *Traumatism*, injuring the nerve or muscle directly or causing pressure from hemorrhage, callus, etc. Not common, paralysis of the abducens being the most frequently observed.

3. *Syphilis* in the tertiary stage. This with the so-called parasyphilitic diseases, *tabes* and *general paresis*, is by far the most frequent cause of paralysis.

4. *Bulbar paralysis* and *myasthenia gravis*.

5. *Polioencephalitis superior* (see page 741).

6. *Multiple sclerosis*.

7. *Meningitis*.

8. *Tuberculosis*.—Paralysis from this cause is uncommon except as a result of a tuberculous meningitis.

9. *Diphtheria*.—This frequently causes a bilateral paralysis of accommodation (with or without paralysis of the sphincter), rarely paralysis of the exterior muscles.

10. *Influenza.*

11. *Rheumatism.*—But few paralyses can be ascribed certainly to the effect of rheumatism. But quite frequently we meet with an acute paralysis, due apparently to exposure to cold, often associated with paralysis of the facial, or neuralgia of the trigeminus, and relieved by antirheumatic medication. Such paralyses are usually called rheumatic.

12. *Hysteria* and *neurasthenia* rarely produce true paralysis of the eye muscles as such, but rather act to cause paralysis or spasm of some associated movements of the eyes (especially convergence).

13. *Poisons.*—Atropine, homatropine, and hyoscyamine, especially if instilled into the eye, produce paralysis of the sphincter iridis and ciliary muscle, *i. e.*, an ophthalmoplegia interior which lasts from two to eight days according to the substance used and its dose. A similar effect is produced by some ptomaines, which also occasionally cause paralysis of the exterior muscles. Lead also causes various paralyses. Other poisons (coal gas, alcohol, etc.) occasionally act in this way.

14. *Other causes* very rarely producing paralysis are various spinal diseases (syringomyelia, lateral sclerosis), zoster ophthalmicus, pneumonia, malaria, beri-beri, digestive auto-intoxication, diabetes, renal disease, exophthalmic goiter, and acromegaly.

Symptoms.—Objective Signs.—The objective signs of a paralysis of one of the eye muscles are as follows:

1. *Limitation of Movement.*—Many, in diagnosticating paralysis or insufficiency of a muscle, lay much stress upon the obvious limitation of movement or lagging that it produces. Theoretically we should be able to make out the characteristic limitation of movement in paralysis of each of the muscles, thus:

In Paralysis of	Limitation of Movement.
External rectus.	Outward.
Internal rectus.	Inward.
Superior rectus.	Upward and outward.
Inferior oblique.	Upward and inward.
Inferior rectus.	Downward and outward
Superior oblique.	Downward and inward.

Such limitation of movement may be recognized in binocular vision by the simple excursion test; that is, by watching to see whether one eye lags behind the other in following a pencil or candle, or, more precisely, although less certainly, in uniocular vision, by determining the field of fixation with the tropometer or perimeter. Except, however, in cases of almost complete paralysis, it is often very difficult to make out the limitation by any of these methods. This is especially true of paresis of the elevators and depressors. An insufficiency of the inferior rectus, for example, great enough to afford a vertical diplopia of a number of degrees, which increases rapidly as the eyes are carried downward, may produce no apparent limitation of the downward movement of the affected eye, so far, at least, as is indicated by the tropometer or perimeter. These instruments, therefore, are not as reliable as the measurement of the

field of binocular single vision with the candle, giving the amount of diplopia in different directions of the gaze.

2. *Screen Deviation Varying in Different Directions of the Gaze.*—If no diplopia can be made out, we can, in cases of marked paresis, determine the deviation in different directions of the gaze by the screen test, and, from the way in which the deviation increases or decreases, infer what muscle is affected. To do this, we have simply to substitute in the table on page 717 for homonymous, crossed, right and left diplopia, the expressions esophoria, exophoria, and right and left hyperophoria, as shown by the screen test.

3. *Primary and Secondary Deviation.*—If the right externus is paretic and the left eye fixes an object situated straight ahead, the right eye will deviate inward a certain amount, say 1 mm. Suppose, then, the left eye is screened so that the right eye has to fix. To do this, the right eye will have to move to the right through the contraction of its external rectus. If the latter is paretic it requires a very strong effort to move it; that is, it must be innervated very strongly in order to carry the eye through the requisite space of 1 mm. But this same innervation impelling the right eye to the right is conveyed simultaneously to the left eye, causing its internal rectus to contract. Since the left internal rectus is normal, this excessive innervation supplied to it will make it contract excessively, so that the left eye will be carried to the right, not 1 mm. but 2 or 3 mm. In other words, the deviation of the left or sound eye behind the screen (*secondary deviation*) will be much greater than that of the paretic eye (*primary deviation*).

4. *False Projection.*—If the right externus is paralyzed and the patient, with the left eye closed, is told to place the finger quickly on an object situated to the right, he will in general shoot by it or to the right of the object. This false projection is due to the fact that having to put forth an excessive innervation in order to direct his eye toward the object on his right, he feels as though that object were further to the right than it really is. So, also, in paralysis of an elevator the patient would shoot above an object, and in paralysis of a depressor below it.

5. *Faulty Position of the Head.*—In order to avoid diplopia, the patient with paralysis will turn his head in such a way that he does not have to make his eyes move out of the field of action of the muscle affected. For instance, in paralysis of a right-turner (right externus, left internus) he will turn his head to the right, so that in looking at an object in front of him his eyes will be directed somewhat to the left, in which case he will not see double. So, also, in paralysis of an elevator he may turn his head up and back and in paralysis of a depressor, down and forward, although in these forms of paralysis the diplopia is more frequently obviated by turning the head toward one shoulder.

Subjective Symptoms.—The chief subjective symptom of paralysis is the *diplopia.* This often develops very suddenly. The patient himself soon learns that the double vision increases fast when he turns his eyes in a certain direction, and seeks to obviate it either by closing the eye or by turning the head (see page 742).

Other subjective symptoms, very generally met with in paralysis, are *blurring of vision*, due to the mixing up or overlapping of the double images; an *apparent movement of objects* seen with the affected eye, as soon as they come within the field of action of the paralyzed muscle; and *vertigo* and *nausea*, due partly to this apparent movement and partly to the diplopia.

Patients with paralysis often also have headaches, anesthesia or paresthesiæ of the face, etc., but these are to be regarded not as symptoms of the paralysis itself, but of the disease that causes it.

Diagnosis.—The diagnosis of the muscle affected in paralysis will be facilitated by the following table:

TABLE OF MUSCLES AFFECTED IN PARALYSIS.[1]

A. There is a *lateral* (*i. e.*, a homonymous or crossed) *diplopia* which increases markedly as the eyes are carried *laterally* (to right or left). A LATERAL ROTATOR is paralyzed.

The lateral diplopia increases in looking to the right (paralysis of a RIGHT-TURNER). Diplopia homonymous. *R. external rectus.* Diplopia crossed. *L. internal rectus.*	The lateral diplopia increases in looking to the left (paralysis of a LEFT-TURNER). Diplopia homonymous. *L. external rectus.* Diplopia crossed. *R. internal rectus.*

B. There is a *vertical diplopia* which increases in looking *up*. An ELEVATOR is paralyzed.

The vertical diplopia increases up and to the right. (Paralysis of RIGHT-HAND ELEVATOR). Left diplopia (image of right eye above). *R. superior rectus.* Right diplopia (image of left eye above). *L. inferior oblique.*	The vertical diplopia increases up and to the left (paralysis of a LEFT-HAND ELEVATOR). Right diplopia (image of left eye above). *L. superior rectus.* Left diplopia (image of right eye above). R. *inferior oblique.*

C. There is a *vertical diplopia* which increases in looking *down*. A DEPRESSOR is paralyzed.

The vertical diplopia increases down and to the right (paralysis of a RIGHT-HAND DEPRESSOR). Right diplopia (image of right eye below). *R. inferior rectus.* Left diplopia (image of left eye below). *L. superior oblique.*	The vertical diplopia increases down and to the left (paralysis of a LEFT-HAND DEPRESSOR). Left diplopia (image of left eye below). *L. inferior rectus.* Right diplopia (image of right eye below). *R. superior oblique.*

Since the superior and inferior recti take some part in moving the eye inward, an eye in which one of these muscles is paralyzed will fail to move inward as well as it should; that is, there will be a relative divergence of that eye, and consequently a crossed diplopia. So also in paralysis of the obliques, which are abductors of the eye, there will usually be a homonymous diplopia. Such a *crossed* or *homonymous diplopia*, however, is by no means invariably present, since the lateral deviation due to the paralysis may be neutralized by various causes. Thus I have seen at least one case of paralysis of the inferior rectus without crossed diplopia, and one of paralysis of the inferior oblique with crossed diplopia. When the lateral diplopia is present in paralysis of the obliques or of the superior and inferior recti it always increases on the side opposite to that on which the vertical diplopia increases. Thus in paralysis of the right superior rectus the vertical diplopia increases up

[1] See Duane in Posey and Spiller, The Eye and the Nervous System, page 214.

and to the right, but the accompanying crossed diplopia increases up and to the left.

Furthermore, in paralysis of the superior rectus and superior oblique the image formed by the paralyzed eye appears to the patient to be *tilted* inward (toward the left, if the paralysis affects the right eye, and vice versa); while in paralysis of the inferior rectus and inferior oblique it appears tilted outward. The patient may not always recognize this tilting of the image of the affected eye, or he may even think that the image of the sound eye is tilted; but an examination with the Maddox rod (see page 728) will then usually show which eye is really at fault and which way its image is inclined.

All these facts with regard to the diplopia in paralysis are well shown in the accompanying diagrams.

Course and Prognosis.—Congenital paralyses usually remain unchanged throughout life.

Acquired paralyses vary greatly in their course. Many begin suddenly, and after lasting a short time, a few weeks or months, disappear again without leaving any trace. This is particularly the case with the rheumatic and the pre-tabic paralyses. Those due to cerebral anemia and hyperemia are very transient, indeed, causing a mydriasis, an inequality of the pupils, or a diplopia, that lasts only a few hours. Again, we meet with many cases in which the paralysis lasts indefinitely, or changes only after the lapse of months or years. Hence, the prognosis in any case of paralysis must be guarded. Even in those paralyses which disappear quickly the prognosis cannot be stated as very good, since the paralyses themselves are apt to recur, and, moreover, they are often the precursors of grave and deep-seated nervous diseases.

Recovery always takes place in diphtherial paralysis of the accommodation. The same is generally true of diphtherial paralysis of the exterior muscles, although the author has noted exceptions to this rule.

In acquired paralyses which have lasted a long time the deviation is frequently enhanced by the development of *secondary contracture* in the antagonist of the paralyzed muscle. This rarely, if ever, occurs in congenital paralysis.

Special Types of Paralysis.—Some types of paralysis peculiar in their course, or in their associated symptoms, are:

1. *Poliencephalitis Superior.*—This is an acute, or subacute, usually fatal, hemorrhagic inflammation of the gray matter about the aqueduct and third ventricle, causing headache, vomiting, and paralyses of the eye muscles, which may increase to the point of a total ophthalmoplegia.

2. *Chronic Progressive Ophthalmoplegia.*—This is an extremely chronic affection, in which nuclear or rarely basal changes produce, in the course of months or years, paralysis of one eye-muscle after another, and often, by involving other centres cause tabes or general paresis or ultimately death.

3. *Recurrent Ophthalmoplegia* (Ophthalmoplegic Migraine).—This is a condition in which a partial or total oculomotor paralysis, preceded frequently by a violent migraine, sets in, lasts from one or two days to

several months, and then disappears to recur again at more or less periodic intervals. The paralysis may be combined with an abducens palsy, and a similar recurrent paralysis of the abducens alone has been observed. The disease is held to be due to some basal lesion—in many cases probably to a rheumatic periostitis of the orbital fissure.

4. *Bilateral Transient Ophthalmoplegia.*—In this, usually from chilling of the body or similar cause, a paralysis, always bilateral and usually affecting all the eye muscles, comes on pretty acutely, and disappears after lasting one or two months.

5. *Gerlier's disease* (Vertige Paralysant).—This is a disease of Switzerland, marked by brief, frequently recurring attacks of vertigo, impaired sight, diplopia, ptosis, and paralysis of some of the eye muscles, especially the external and internal recti.

Treatment.—The treatment of paralysis must, in the first place, be directed to the *cause* of the trouble. In syphilitic and parasyphilitic paralyses the very vigorous use of the iodides and of mercury, the latter preferably by inunction or intramuscular injection, is indicated and often gives fair results. In rheumatic paralyses, so called, the salicylates seem to act favorably. In diphtherial paralysis a tonic treatment with abstention from eye work is indicated.

Very little is to be expected from the use of *electricity* in the treatment of paralysis, and the same may be said of *strychnine.*

Prisms are of very little avail except in the slightest degree of paralysis. The very fact that the diplopia changes in different directions of the gaze makes prisms inapplicable, for the prism which would correct the diplopia for one direction of the gaze would be too strong or too weak for another. Moreover, in paralysis of any amount the diplopia is too great to be adequately corrected by prisms.

Exercises with prisms, graduated exercises in moving the paretic muscles by voluntary effort, and passive traction made upon the muscle (with forceps under cocaine) help in some cases, particularly when the muscle is regaining its power.

Occlusion of the paretic eye, either by means of a ground glass or with a patch, is a means that many patients find helpful in avoiding diplopia.

In cases where we are confident that the paralysis has become stable, we may attempt to relieve the case by *operation.* For this the following procedures are applicable:

In paralysis of an externus, advancement of the affected muscle, supplemented by cautious tenotomy of the internus of the same eye, and in some cases of the internus of the opposite eye. In paralysis of the internus, advancement of the affected internus, supplemented by tenotomy of the externus of the other eye. In paralysis of the superior rectus, advancement of the paralyzed muscle. As a substitute for this, tenotomy of the inferior oblique of the other eye may be performed. In paralysis of the inferior rectus, advancement of the affected muscle, which may be either replaced or supplemented by tenotomy of the superior oblique of the other eye. In paralysis of the inferior oblique, tenotomy of the superior

rectus of the other eye. In paralysis of the superior oblique, tenotomy of the inferior rectus of the other eye.

It is generally stated that when the paralysis is complete but little can be expected from the advancement of the paralyzed muscle. This, however, applies only to innervational paralysis, and even in this is not without exception.

Spasms and Overaction of Ocular Muscles.—True spasm of the individual ocular muscles is rare. It causes a forced deflection of the affected eye in, out, up, or down (*spastic squint*). A tonic spasmodic contraction of one or more muscles occurs in meningitis and occasionally in hysteria, although in the latter spasm of the coördinate movements, and particularly of convergence, is more common.

Tonic spasm of the eye muscles may also occur in tetanus, sometimes all the external muscles being involved together with the sphincter and ciliary muscle, causing rigidity of the eyeball, miosis, and spasm of accommodation.

Clonic spasm of the ocular muscles is also observed.

A sort of false spasm, really a variety of *secondary deviation* (see page 739), not infrequently occurs in the muscles of one eye when the fellow eye is paretic. Thus suppose that the superior rectus of the right eye is paralyzed, and that, nevertheless, as often happens, that eye is used for fixation. When, then, the patient tries to look at an object situated at his right, the right eye tends to sink and can be held up in place only by a very great effort. This same effort being transmitted to the left eye, causes it to rise unduly, and, in fact, shoot obliquely up and to the right, just as though there was a spasm of the left inferior oblique.

In old cases of paralysis a kind of secondary spasm occurs in the antagonist to the paralyzed muscle. Thus in old paralysis of the right external rectus the internal rectus becomes ultimately *contractured* and acts excessively, so that, added to the paralytic deviation of the right eye inward, which is marked when the gaze is directed to the right, there is a spastic deviation of the right eye inward which is marked when the gaze is directed to the left.

Slight overaction of the muscles of one eye produces nearly the same appearance as slight insufficiency of the muscles of the other, and the two conditions are often very hard to distinguish.

Nature of Divergence and Convergence Anomalies.—Comitant Heterophoria and Strabismus.—Anomalies of divergence and convergence are doubtless always of central origin, that is, they are not in any sense due to disorder of the internal and external recti, which are, in fact, normal, nor to any affection of the oculomotor or abducens nerves, per se, but to involvement of the centres or tracts which by coördinating the action of the two oculomotor and the two abducens nuclei effect a simultaneous contraction of the two interni, on the one hand, and simultaneous relaxation of the two externi on the other.

As we diverge our eyes or converge them with the same facility when we look to the right as we do when we look to the left, anomalies of convergence and divergence will produce a deviation that is equally marked

whether the eyes are turned to the right or whether they are turned to the left. In other words, a deviation so produced is practically comitant, provided the test object be kept at a uniform distance from the eyes. But since we ordinarily use our convergence very strongly when looking at near objects, and little or not at all when looking at distance, the action of a convergence anomaly in producing deviations will be much more marked in near than in distance vision. With a divergence anomaly the reverse will be true. Hence, while divergence and convergence anomalies are comitant in the sense that the deviation changes but little when the gaze is carred to the right or to the left, they are non-comitant in that the deviation produced by a convergence anomaly increases, and that produced by a divergence anomaly diminishes, as the object of vision approaches the eyes, *i. e.*, when uncomplicated, such anomalies produce typical periodic deviations (see page 712.)

The great majority of cases of periodic heterophoria and squint are due to an uncomplicated anomaly of either divergence or convergence, while nearly all cases of continuous squint are the result of an anomaly of divergence combined with one of convergence and often associated with insufficiency of the muscle as well.

Convergence excess and divergence insufficiency will tend to make the visual lines converge unduly, and hence will cause esophoria or esotropia; divergence excess and convergence insufficiency, on the other hand, will cause exophoria or exotropia. Accordingly we may say that most cases of *esophoria and convergent squint* are due to convergence excess, or divergence insufficiency, or a combination of the two; and most cases of *exophoria and divergent squint*, to divergence excess, or convergence insufficiency, or both combined.

Esophoria and Convergent Squint.—1. **Non-comitant Esophoria.**—Apart from an out-and-out paralytic squint, we occasionally find an esophoria or esotropia due to a *primary weakness* or ill-development of the externi (true insufficiency of the externi) or to overdevelopment of the interni. Such cases exhibit the characters of a slight paresis or slight spasm of the muscles; that is, they present an esophoria or inward deviation which, moderate in the primary position, increases notably either to the right or to the left, or to both right and left. Furthermore, we find on careful inspection or upon examination with the tropometer or perimeter, some limitation of the movement of one or both eyes outward and some excess of movement of one or both eyes inward.

Much more commonly such underaction of the externi or overaction of the interni develops as a result of *secondary changes* in the muscle due to a long standing divergence or convergence anomaly, especially one which causes a constant convergent squint. (See Development of Convergent Squint.)

2. **Convergence Excess.**—This is characterized by the following signs:

Esophoria or evidences of inward deviation by all tests (screen, parallax, Maddox rod, and phorometer) marked for near, slight or absent for distance; convergence near-point and prism-convergence normal or supernormal; prism-divergence (abduction) normal or but slightly sub-

normal; inward and outward excursions of each eye normal; esophoria and its evidences not increasing to either right or left.

Convergence excess is often *accommodative*, being due to excessive strain upon the accommodation imposed by the attempt to overcome hyperopia or astigmatism. In such cases the continuous use of atropine and of glasses for the correction of the hyperopia and astigmatism will cause the deviation to disappear.[1]

Temporary spasm of convergence produced by hysteria has been described.

3. **Divergence Insufficiency.**—Characters: Esophoria or inward deviation by all tests (screen, parallax, Maddox rod, phorometer) marked for distance, slight or absent for near; near-point of convergence and prism-convergence (adduction) normal, or perhaps subnormal; prism-divergence (abduction) much below normal, being less than 4 degrees or even negative (*i. e.*, the patient has homonymous diplopia for distance); esophoria or its evidences not increasing either to the right or to the left; movements of eyes outward fully normal and movements inward not greater than normal.

Most cases of divergence insufficiency that we meet with have evidently existed for a long time and their origin and mode of development are quite unknown. Occasionally we see a case of suddenly developing *divergence paralysis* which may occur with or without evidences of organic nerve disease (tabes, brain tumors, etc.). This is characterized by homonymous diplopia which is very great in amount for distance, diminishes steadily as the test object is brought towards the eyes, and, instead of growing greater, tends to grow less when the eyes are directed to the right and to the left: marked convergent squint for distance with orthophoria at some near-point; no restriction in the movement of either externus, nor excess of action of either internus, so that the excursions of the eyes are normal.

4. **Combined Convergence Excess and Divergence Insufficiency.**—Regularly when a convergence excess has lasted for a long time it is followed by a divergence insufficiency, or, on the other hand, a primary divergence insufficiency is followed sooner or later by a convergence excess. The characters that are then found are: Inward deviation (esophoria, convergent squint) marked for both distance and near-points; convergence near-point, excessively close; prism-divergence, low or altogether absent.

Development of Convergent Squint.—It is in this way that most convergent squints develop. Thus a child with a hyperopia of several D. develops, because of excessive accommodative action, a *convergence excess*. He then has an esophoria for near but still orthophoria for distance. Later, a divergence insufficiency being superadded to his convergence excess he has an esophoria for distance (with diminished prism-divergence) and a still more marked esophoria for near. This latter finally becomes so great that he can no longer maintain binocular

[1] During the first hour or half hour of their application, atropine and homatropine often increase the deviation in a case of convergence excess.

fixation and develops a squint (periodic convergent squint). This is at first intermittent and spasmodic; afterward constant. Ultimately, as the divergence insufficiency increases, his esophoria for distance becomes so great that he can no longer maintain binocular fixation here either, and he then has a convergent squint for distance also (continuous squint).

A rather small minority of convergent squints develop from a *divergence insufficiency* instead of a convergence excess. In this case we have, first, an esophoria for distance and orthophoria for near, succeeded in turn by convergent squint for distance and esophoria for near (periodic squint), and ultimately by convergent squint for both distance and near (continuous squint).

In whichever way developed, it usually happens later on in the course of the squint that the interni become contractured and the externi weakened from stretching, so that to the divergence insufficiency and the convergence excess there is added a *true muscular anomaly* which still further enhances the deviation. In this case the inward rotation of one or both eyes is increased and the outward rotation is diminished beyond the normal.

The *development of a convergent squint out of an esophoria* in the way just outlined is facilitated by the presence of anisometropia or any other condition (fundus disease or opacity of the media confined to one eye) that renders the sight of one eye much worse than that of the other. In such a case the image of the worse eye no longer serves to reinforce that of the good eye—it may, indeed, even confuse it, and hence the patient sees as well or even better if he allows the worse eye to follow its natural tendency to deviate. In some cases he evidently forces it to deviate, so as to get the disturbing image out of the way.

Etiology.—The ultimate cause of squint is regarded by many as cerebral, being ascribed to lack of development of the fusion faculty (see page 713). The result of this is that the two retinal images, instead of being blended, are perceived and projected independently, and ultimately the mind takes cognizance of only one. Others believe that the impairment of fusion power is the result rather than the cause of squint.

During the first stages in the development of a squint the patient always without doubt sees double; later on he almost invariably learns to *ignore the double images*, and cannot, in fact, be made to see double by any device. Moreover, if a squint develops early in life the squinting eye becomes highly *amblyopic*, and the more so the earlier the squint develops.

Symptoms.—It must be noted that in a convergent squint the patient *really turns both eyes inward*. Thus in Fig. 354 both eyes instead of being directed at the object C tend to converge equally, so that their lines of sight meet at S. As, however, this would prevent the image of the object from falling on either fovea, the patient then turns one eye, say the right, to the right through the angle $S\ R\ C$, so that it is directed to C; the left eye must then turn to the right through an equal angle, namely, $S\ L\ Q$, so that it is directed not at S but at Q. Thus apparently the left eye alone squints, but really the strabismus is bilateral.

Which eye the patient will use to fix with in this case will depend generally upon the vision. If there is much difference between the sight of the two eyes he will naturally prefer to look with the better eye and squint all the time with the other (*unilateral squint*). If, on the other hand, the vision and refractive power of the two eyes are equal it will often happen that he will use now one now the other for seeing, and squint with the one that for the time being is not in use (*alternating squint*).

Owing to structural changes taking place in the orbit as it develops, which changes tend to increase the power of the externi and diminish that of the interni, a convergent squint may *diminish*, disappear, or even be converted into a divergent squint during the growing period.

Fig. 354

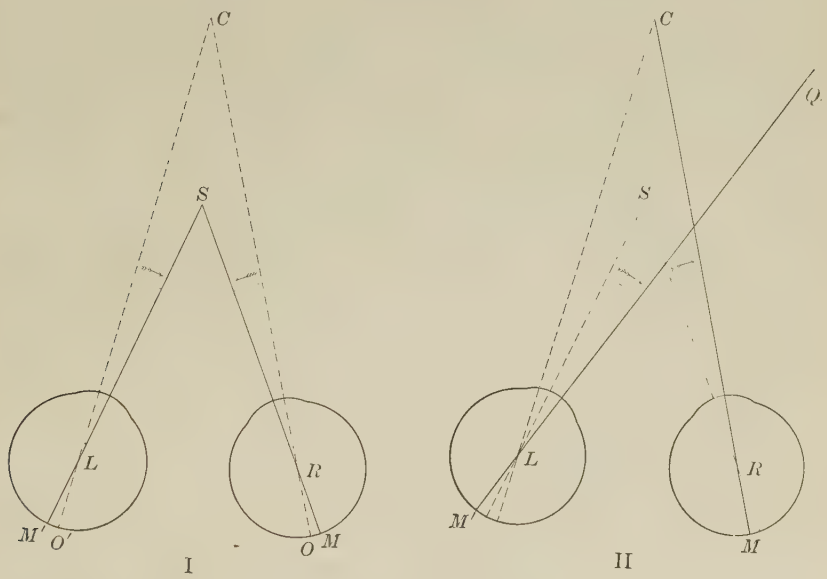

Position of the Eyes in Convergent Squint.—The primitive position (*I*) of the eyes is one of excessive convergence, both being equally turned too far in, so that each is pointing at *S* instead of *C*, and the images instead of being formed on the foveæ, *M* and *M'*, fall within the latter, *i. e.*, on *O* and *O'*. To get the image on the fovea of at least one eye the patient then (*II*) turns both eyes equally to the right until the image of *C* falls on *M*. *R* is now directed at *C*, having rotated to the right through the angle *S R C*, and *L* is directed at *Q*, having rotated to the right through the angle *S L Q*=*S R C*. The left eye, then, is apparently the only one that squints, although in reality both eyes are converged excessively.

Exophoria and Divergent Squint.—1. **Non-comitant Exophoria.**—Apart from an out-and-out paralytic squint, we occasionally find an exophoria due to a *primary weakness* or ill-development of the interni (true insufficiency of the interni) or to overdevelopment of the externi.[1] Such cases exhibit the characters of a slight paresis or slight spasm of the muscles, *i. e.*, they present an exophoria or outward deviation which,

[1] Most cases of so-called insufficiency of the interni are really cases of insufficiency of convergence.

moderate in the primary position, increases perceptibly either to the right or to the left, or both right and left. Examination with the tropometer or even inspection in such cases will show some limitation of the movement of one or both eyes inward, or some excess of rotation outward.

Much more commonly such an underaction of the interni or overaction of the externi occurs as the result of *secondary changes* in the muscles due to a long-standing divergence or convergence anomaly, especially one which causes a constant divergent strabismus. (See Development of Divergent Squint).

2. **Convergence Insufficiency.**—This is marked by the following signs: Exophoria or evidences of outward deviation by all tests (screen, parallax, Maddox rod, and phorometer) marked for near, slight or absent for distance; convergence near-point abnormally remote (more than 2″ to 3″ from the root of the nose); prism-divergence (abduction) about normal; prism-convergence (adduction) subnormal and difficult to acquire and to maintain; exophoria and its evidences (crossed diplopia, etc.) not increasing to either right or left; inward rotation of each eye normal, and outward rotation not excessive.

Many cases of convergence insufficiency are *accommodative*, being due to insufficient accommodative action in myopes. That is, a myope not having to use any accommodation even at near-points does not converge his eyes as he would if he did use his accommodation, and so lets them diverge at near. In most cases of this sort there is no real insufficiency of convergence at first, but simply a disuse of this function, as shown by the fact that though there is a large amount of exophoria for near, the convergence near-point is normal; but, later on, from this disuse of convergence a true convergence insufficiency develops.

A similar accommodative convergence insufficiency (due to relaxation of the accommodation) occurs temporarily in hyperopes and presbyopes who put on convex glasses for the first time.

A convergence insufficiency which is independent of refractive errors (*non-accommodative* convergence insufficiency) is found not infrequently in neurasthenia, traumatic neuroses, and hysteria, and also occurs without assignable cause.

Occasionally a *paralysis of convergence* is met with. This is marked by a suddenly developing, insuperable crossed diplopia and divergent squint, both diplopia and squint being very marked at near-points and diminishing steadily as the test object is carried away from the eyes until for far distance nearly normal relations obtain. The rotations of each eye are perfectly performed and the crossed diplopia does not increase either to the right or to the left.

3. **Divergence Excess.**—Characters: Exophoria or outward deviation by all tests (screen, parallax, Maddox rod, phorometer) marked for distance, slight or absent for near; near-point of convergence normal; prism-convergence (adduction) normal; prism-divergence (abduction) excessive (10 degrees or more). Movements of eyes outward not greater, and movements inward not less than normal; exophoria and its evidences not increasing to either right or left.

4. **Combined Convergence Insufficiency and Divergence Excess.**—Regularly when a convergence insufficiency has lasted a long time it is followed by a divergence excess, and, on the contrary, a divergence excess ultimately superinduces a convergence insufficiency. The characters then found are: Outward deviation (exophoria and divergent strabismus) marked for both distance and near; convergence near-point remote or converging power entirely absent.

Development of Divergent Squint.—It is in this way that most divergent squints develop. Thus a patient with myopia develops a convergence disuse which becomes converted into true *convergence insufficiency* with marked exophoria for near and orthophoria for distance; to this is later superadded a divergence excess, so that there is exophoria for both distance and near, and then as the convergence near-point recedes there is rather marked divergent squint for near (periodic divergent squint) which is at first intermittent, later constant. Ultimately the divergence excess increases and produces a divergent squint for distance also, so that the strabismus is now no longer periodic but continuous.

In quite a number of divergent squints the primary condition is a *divergence excess.* In this case there is first an exophoria for distance and orthophoria for near; then a convergence insufficiency is superadded, producing exophoria for near also with recession of the convergence near-point. Later by an extension of the process there is divergent squint for distance with exophoria for near (periodic strabismus divergens) and ultimately divergent squint for both distance and near (continuous strabismus divergens).

In whichever way developed the strabismus divergens is later on enhanced by a *consecutive weakening* of the interni from stretching and by overaction of the externi. When this takes place the rotations of the eye are no longer normal, but the rotation outward is increased and the rotation inward diminished.

As in the case of convergent squint (see p. 746), and to even a greater extent, the development of divergent strabismus is facilitated by anything *that renders the vision of the two eyes unlike*—anisometropia and unilateral amblyopia from whatever source being a fruitful cause of divergent squint.

Divergent strabismus usually develops later in life than convergent strabismus, and is more apt to be associated with persistence of the diplopia, which is not, however, often obtrusive.

The patient with divergent strabismus *really turns both eyes out*—in fact, turns both eyes out equally. As, however, this would throw the image of an object looked at away from the fovea of both eyes, he then turns both eyes equally to either right or left until the image falls on the fovea in one eye, say the right. This movement will set the right eye straight, but will increase the outward deflection of the left eye. Apparently, then, the left eye alone is squinting, although in reality both eyes deviate. (See remarks under Convergent Squint, page 746, and Fig. 354.)

Hyperphoria and Hypertropia.—Hyperphoria is often due to insufficiency or slight paresis of the superior or inferior recti or of the obliques. In such cases hyperphoria or its evidences (deviation behind the screen and vertical diplopia) increase or decrease characteristically in looking up or looking down (*non-comitant* hyperphoria). This is particularly the case with hyperphoria of high degree and with actual vertical squint (strabismus sursumvergens or deorsumvergens), which we can almost always trace to insufficiency of this sort.

In slight cases of hyperphoria the deviation may be about the same in all directions of the gaze (*comitant* hyperphoria).

Hyperphoria when once developed shows little tendency to increase, except in paresis of the vertical muscles, which, if marked, is apt to be still further exaggerated by *secondary contractures* of the antagonists and sometimes by secondary deviation of the sound eye (see page 747).

Cyclophoria.—Cases of cyclophoria, or the condition in which the vertical meridian of one eye tends to deviate from parallelism with that of the fellow eye, have been described. The author has never seen a case in which, without a paresis of one of the elevator or depressor muscles, there was a constant tendency to deflection of the vertical meridians. Transient and varying deflections of this sort he has noted in a few instances, but never has been able to attribute any clinical significance to them.

Symptoms of Heterophoria and Squint.—The symptoms of heterophoria and squint are:

A. Diplopia.—Diplopia, which, in turn, produces confusion and blurring of vision and sometimes vertigo and nausea.

The diplopia is most pronounced in cases of paralysis in which it often persists for years and causes great distress. In squint where there is regularly suppression of the diplopia, there is, as a consequence, loss of binocular vision and generally inability to appreciate depth and distance (absence of stereoscopic vision).

B. Reflex Evidences.—Reflex evidences of a muscular or nervous effort put forth to correct the deviation, such as asthenopia, eye-ache, conjunctival irritation, headaches (frontal, temporal, and occipital), and other pains variously located; occasionally also spasm of the facial or other muscles; sometimes digestive disturbances.

The reflex disturbances are particularly marked when the diplopia is slight and inconstant and the deviation superable, *i. e.*, in heterophoria, because in these cases clear vision can be obtained by effort and the patient, hence, makes the effort constantly. They are particularly marked and troublesome in hyperphoria and in divergence insufficiency. In convergence insufficiency, asthenopia and conjunctival irritation are the most common symptoms. These are particularly marked in the non-accommodative form.

In convergence excess and divergence excess there are often no symptoms whatever

Treatment of Heterophoria and Squint.—1. **Correction of Refraction.**—The first indication in the treatment of these affections is to

correct the refraction. It is of particular importance in convergence excess (and especially in a beginning convergent squint) to correct all or as nearly all as possible of the hyperopia and astigmatism present. Such a correction, by eliminating the accommodative element, will, in recent cases, effect a perfect cure, while if consecutive changes (divergence insufficiency, etc.) have taken place it will at most diminish the deviation. So also in convergence insufficiency associated with myopia, the full correction of the myopia is of great importance.

To accomplish the best results, treatment with glasses should be begun as soon as possible after the deviation is noticed. We should not hesitate to put glasses on a child of three or even younger if he has already developed a well-marked squint.

It must be noted that the effect of glasses in correcting a squint is a gradual one, it often taking a number of months for the full effect to be secured.

In many cases of heterophoria, whether dependent upon accommodative trouble or not, the symptoms are often relieved by the correction of the refraction, although the deviation itself will not be particularly effected.

2. **General Treatment.**—General treatment (tonics, open-air exercise, etc.) is required in neurasthenic and hysterical cases, and will, moreover, often relieve the symptoms in other cases, even though the heterophoria itself is not affected.

3. **Exercise of the Eye Muscles.**—Graded exercises in converging the eyes are of service in exophoria due to convergence insufficiency and occasionally also in divergence excess. A simple and often very efficient form of this exercise consists in repeated daily practice in converging on a fine object (dot on a card, small electric light), which is carried in from arm's length right down to the nose. In cases that do not yield readily to this exercise, it is best to supplement it by practice with prisms, held before the eyes with the base out (or toward the temple). Such prisms produce a crossed diplopia which the patient can overcome only by converging his eyes (see page 716). In applying prisms for this purpose their strength should be increased as rapidly as possible by, say, two-minute exercises, repeated several times daily, until the patient can overcome a total of 60 degrees or more (30 degrees before each eye). A sharply defined test object (spot or small flame) should be used and should be placed at twenty feet, when the exophoria is mainly due to divergence excess, and at one foot when the exophoria is due to convergence insufficiency.

Similar graded exercises with prisms of 10 to 20 degrees, base in, may be of service in esophoria, especially when due to convergence excess. In this exercise the test object used is a dot on a card which is held first at ten inches from the eyes, then gradually carried out to arm's length.

4. **Fusion Training; Orthoptic Exercises.**—In cases of squint, particularly in its early stages, attempts should be made to educate the fusion faculty. To improve the sight of the squinting eye, something may be effected by exercising the latter, which is done by *excluding the good eye*

from vision, either by bandaging it, or, more effectively, by keeping it for weeks under the influence of *atropine.*

Persistent exercises (orthoptic exercises) with the *stereoscope,* or, better still, with *Worth's amblyoscope,* are of great service in training the fusion faculty and compelling the two eyes to act together.

The amblyoscope consists of two tubes which can be diverged or converged at will, so that they can be adjusted for any angle of squint. Each tube contains at its distal end a picture, and the patient endeavors to fuse the two pictures before him into one, and maintain the fusion

Fig. 355



Worth's amblyoscope.

when the angle between the tubes is varied. If one eye is amblyopic the vision of the other eye is correspondingly reduced by inserting a smoked glass or a celluloid plate over the mouth of the tube through which that eye is looking. It is used not only for training the fusion faculty, but also for directly diminishing the amount of the squint, since in many cases the patient learns to get and maintain binocular vision even when the angle between the tubes is steadily diminished, so that he has to put his eyes more and more nearly straight in order to see properly through the instrument.

Another useful orthoptic exercise is *bar reading* (see page 732). The younger the patient with the squint the more important it is to follow out these measures, as in early life they may act an important part in preventing the development of an amblyopia in the squinting eye, while if we wait until the amblyopia has developed all measures for its relief are apt to be nugatory.

5. **Prisms for Constant Use.**—Instead of being used to exercise the eyes by producing a diplopia which the eyes have then to overcome, *prisms* may be used for the opposite purpose of neutralizing a diplopia or a deviation which already exists. In this case they are usually worn constantly and either alone or in combination with the glass correcting the refraction. In esophoria the prism will be placed with the base out, in exophoria with the base in, in hyperphoria with the base down if put before the higher eye, and with the base up if put before the lower eye.

In esophoria and exophoria, while prisms used in this way often help for a time, they frequently tend to increase the deviation, and their prolonged use is not generally advisable. In hyperphoria the same objection does not hold good, and they are often very serviceable.

We cannot in general put prisms of more than 3 degrees before one eye. If we do, we are apt to get distortion and unpleasant chromatic effects. Hence, if we wish to prescribe a prism of 6 degrees we will put 3 degrees before one eye and 3 degrees before the other.

Instead of prescribing prisms we can accomplish the same object by decentring or displacing the spherical or cylindrical glass which the patient is to wear, so that he looks more or less through the edge of it instead of through the middle.

6. **Operative Treatment.**—When all other means fail an operation is indicated. The general principles upon which this is performed are as follows:

In an *esophoria* or a *convergent squint* due mainly to convergence excess we tenotomize one or preferably both interni. When the element of divergence insufficiency is predominant, or when the element of convergence excess is already relieved by glasses, we advance one or both externi. In many cases both tenotomy of the interni and advancement of the externi will be required to produce a correction.

In operating for convergent squint the general rule is to leave a slight degree of convergence still, but if the operation be properly performed, it is best to approximate as closely as possible to orthophoria.

Sometimes after a perfectly successful operation for convergent squint, the eyes after remaining straight for a time *diverge little by little*, until, ultimately, a regular divergent squint is produced. This is due sometimes to insufficiency of the tenotomized internus, sometimes apparently to overaction of the externi or to a true divergence excess. The condition, which may occur years after the original operation, and in some cases occurs without operation, is probably traceable ultimately to developmental changes taking place in the orbits (see page 747). It can be remedied by advancement of the affected internal rectus.

No operation should be done for convergent squint, especially in children, until the *effect of glasses* has been tested through a period of at least several months (preferably longer), nor, if the case admits of it, until some attempt has been made to restore binocular vision or reduce the squint by means of *orthoptic exercises*. Moreover, the wearing of glasses and the orthoptic exercises should be kept up after the operation until the best results are secured.

When once it is decided that an operation should be performed it is better to do it as early in life as possible. The dread of a future divergence should not deter us from operating on children of three or four years of age, if necessary, since such a divergence occurs but rarely and in any case can be remedied by operation later.

In *exophoria* and *divergent squint*, due mainly to a divergence excess, we tenotomize both externi. When there is a marked convergence insufficiency, and particularly if, at the same time, there is a true insufficiency of the interni, per se, we advance the latter muscles. In marked cases of divergent strabismus we usually have to combine tenotomy of the externi with advancement of the interni.

The effect of an operation for divergent squint or for an exophoria usually tends to diminish, often considerably, during the first few weeks, and sometimes also later on. Hence, we should regularly try to secure an immediate overcorrection of moderate amount when doing the operation.

The *effect of an operation* either for divergent or for convergent squint, and especially of one for heterophoria, should be modified whenever necessary by exercise with prisms, convergence practice, or orthoptic exercises. This treatment can be begun within a day or two after a tenotomy, but not till several days after an advancement.

The *amblyopia* of a squinting eye is not generally relieved by operation. There are, however, exceptions to this rule, and there probably would be more, if after the operation persistent attempts were made to educate the vision and the fusion faculty in the ways already detailed.

In *hyperphoria*, the usual operation is tenotomy of the superior rectus. Tenotomy of the inferior rectus should be avoided whenever possible unless we are dealing with an insufficiency of a depresser.

Hyperphoria (vertical squint) due to a marked paresis of the vertical muscles should be treated according to the principles laid down in the section on Paralysis.

Disorders of Associated Parallel Movements.—Conjugate Deviation.—Every now and then cases are met with in which both eyes are deviated to one side, say to the left, and cannot be carried in the other direction beyond the mid-line. Such conjugate deviation, as it is called, may be due to (1) a *conjugate paralysis*, *i. e.*, to abolition of the power of the two eyes to execute a parallel movement to the right, or (2) to *conjugate spasm*, *i. e.*, to a forced and spastic movement of both eyes to the left.

In conjugate paralysis the power of convergence is sometimes retained. It may be, for instance, that neither eye is able to move to the left in following a pencil that is carried from right to left, yet the right eye can

turn to the left in converging, *i. e.*, in following a pencil which is carried from arm's length in toward the nose. This state of things, which is the direct opposite of what takes place in a convergence paralysis (see page 730), proves that in these cases, at least, the conjugate paralysis does not affect the internal rectus, per se, nor its nucleus, but some association tract coördinating the action of the internal rectus with the opposite externus. And that the same thing is true for the majority of cases is shown by the fact that the causal lesion is almost always found either in the pons or in the brain above the third nerve nucleus.

In conjugate paralysis the *lesion*, if situated in the cerebral cortex or anywhere above the pons, is regularly on the side toward which the eyes are deviated; but if situated in the pons, is on the opposite side.

In conjugate spasm just the opposite holds good.

In rare cases conjugate deviation is produced by symmetrical lesions affecting the third and sixth nerves at the base of the skull.

Other rare forms of conjugate deviation are those in which the movements of both eyes *up* or of both eyes *down* are absent. This paralysis of sursumversion or of deorsumversion may occur either from cerebral disease (especially disease of the corpora quadrigemina or of both third nerve nuclei) or as a congenital condition.

Conjugate deviation, especially of the spastic form, may be due to hysteria.

Symptoms.—The main symptoms of a conjugate deviation are false projection and vertigo. These, however, are often absent, and, even when present, frequently pass unnoticed on account of the severity of the accompanying symptoms due to the apoplexy or other condition causing the deviation.

Nystagmus.—Nystagmus is a very rapid, short and tremulous, to-and-fro movement of the eye. The eye makes from one to three oscillations a second, each oscillation being from 1 to 4 mm. in length. The oscillations may be horizontal, vertical, or rotary; the eye in the last case rolling like a wheel round its antero-posterior axis. In so-called mixed nystagmus, oscillations of different kinds are combined (horizontal with vertical, or rotary with either vertical or horizontal).

Almost without exception in nystagmus both eyes are affected, and, moreover, are affected precisely alike. Thus in a horizontal nystagmus, both eyes will make equal and simultaneous, sharp, darting movements to the right and back again; in a rotary nystagmus both eyes make quick, equal and simultaneous, clock-wise movements, etc.

Bilateral nystagmus is usually horizontal, although rotary nystagmus is fairly frequent. Vertical bilateral nystagmus is rare. On the other hand, unilateral nystagmus, when it occurs, is almost invariably vertical.

A nystagmus often increases when the eyes are carried in some special direction, and decreases when the eyes are carried in some other direction; or it may decrease if the eyes are converged, or if one eye is covered, etc.

From the absolute similarity and equality of the oscillatory movements in bilateral nystagmus it is inferred that the condition is due to some

perversion of the centres governing the coördinate movements of the eyes rather than to any trouble with the muscles themselves or with their supplying nerves. This explanation probably holds good for the unilateral form too.

This perversion of coördination occurs in two main sets of cases, viz.:

1. In those who *from birth or very early infancy* have suffered from some condition, such as congenital cataract, opacities of the cornea, albinism, or fundus disease, which produces marked impairment of sight in both eyes. Except that the vision is always more or less poor, there are but slight subjective symptoms, and in particular no sensation of movement in objects looked at.

2. As a *late acquired affection* in (*a*) disseminated sclerosis, hereditary ataxia, and disease of the cerebellum—rarely in other forms of nervous disease; (*b*) in conditions of irritation of the labyrinth of the ear produced either by otitis or by disturbances of equilibrium such as are set up by turning the body rapidly round and round; (*c*) in conditions of exhaustion of the eyes produced by prolonged use of them day after day in a poor light. In the peculiar nystagmus developing in coal miners (*miner's nystagmus*) the evil effects of bad illumination are aggravated by exhaustion of the ocular muscles due to the constant strained position of the eyes; for the miners affected are those who work lying on their backs with their eyes directed all the time upward and backward. In this and in some other forms of late acquired nystagmus (expecially that due to labyrinthine irritation) the oscillation of the eyes produces a corresponding vibration of all objects looked at and consequent marked confusion and vertigo..

Nystagmus sometimes disappears spontaneously, and late acquired nystagmus, especially the labyrinthine form and miner's nystagmus can often be made to disappear if we succeed in removing the cause.

Retraction Movements of Eyeball of Congenital Origin.—Retraction movements of the eye are found as a congenital condition, especially in conjunction with a peculiar syndrome (Figs. 356, 357, 358) having the following characteristics.[1]

1. Partial, often complete, loss of outward movement (abduction).
2. Partial, very rarely complete, loss of inward movement (adduction).
3. Retraction of the affected eyeball into the orbit on attempts to adduct (0.5 to 10 mm.).
4. Oblique movements of the eyeball occurring upward and inward if the eye is adducted on a plane above the horizontal, downward and inward on adduction on a plane below the horizontal.
5. Narrowing of the palpebral fissure when the eye is adducted.
6. Deficiency of convergence.

The condition is more frequent in females and affects the left eye much more often than the right.

7. Protraction (protrusion) with slight widening of the palpebral fissure on forcible abduction in many cases.

[1] Duane, Arch. of Ophth., March, 1905, vol, xxxiv, page 133.

The vision is usually less in the affected than in the normal eye, but it may be of normal acuity. Diplopia is annoying in some cases.

Fig. 356



External rotation to the right.

Fig. 357



External rotation to the left.

Fig. 358



Head turned slightly to the right (orthophoria).

Retraction movement of the eyeball.

Anatomical Conditions Present.—Dissection has shown that, in some cases at least, the externus is replaced by an elastic or inelastic connective-tissue cord. There are varying degrees of absence of contractile muscle tissue in the externus. The internus (*a*) may be normal and normally

inserted; (*b*) the internus may be normal and inserted too far back; in addition a fasciculus of the muscle may have an insertion well back of the main insertion, the fasciculus acting as a retractor muscle. The *retraction*, according to Türck, is due to the inextensibility of the externus. On contraction of the internus the externus does not elongate (as it does normally); consequently the centre of rotation of the eyeball is shifted to the vicinity of the insertion of the externus, and the eyeball is rotated from this point, being pulled inward and backward.

Treatment.—The position of the eyeball can be improved by a properly performed advancement of the externus or a tenotomy of the internus, or both, as the case may require.

CHAPTER XXVIII.

OCULAR CONDITIONS CONNECTED WITH GENERAL DISEASE.

Diseases of Nervous System.—The symptoms and conditions affecting the eye occurring in many of the diseases and conditions of the nervous system have been described in preceding chapters. Mention will be made in this chapter of those previously insufficiently described.

Coma.—In all conditions of coma the eye symptoms and signs may give valuable information. If due to organic brain disease there may be deviation of the eyes, choked disk, dilated pupils. If the intracranial pressure is increased, dilated pupils, clonic conjugate deviation. If from cerebral hemorrhage, miosis, inequality of pupils, conjugate deviation. If from uremia, albuminuric retinitis. Narcotic poisoning occasions extreme equal miosis. When due to atropine or hyoscyamine, pupils widely dilated.

Chorea.—"True" or Sydenham's chorea is regarded by many authors at the present time as an acute infectious disease. The ocular symptoms accompanying it are those of clonic spasm of voluntary muscles. The condition is not caused by muscular anomalies. The "habit chorea" of S. Weir Mitchell, simple tic of Osler, which ordinarily involves the muscles of the upper part of the face on one side, but may extend to the lower part of the face and neck, is often relieved by the correction of errors of refraction and errors of the ocular muscles. It is very probable that eye strain consequent on these errors may produce the spasm. The degree of spasm is not necessarily in proportion to the degree of eye strain, but seems to depend on the impressionability of the patient.

Habit chorea can be readily differentiated from true chorea. It is not influenced by season, is not confined to the young, and is not self-limited. The cases depending on eye strain recover when the eye strain is removed.

Epilepsy.—Subjective visual sensations precede the explosion in epilepsy twice as frequently as the sensations of all other special senses combined (Gowers). The "auræ" differ largely in different individuals. The phenomena may apparently emanate from both sides of the brain or from one side only (hemianopic). The phenomena consist of flashes of light, sparks, balls of fire traversing the visual field, prismatic colors, images of special objects, panoramic views frequently confined to one-half of the field of vision, partial or complete loss of vision. The visual sensations are transient, seldom being present after the spasm passes.

Spasm of retinal arteries with dilatation of retinal veins has been observed during the attack.

The pupils are dilated, as a rule, when the "fit" is established and

remain dilated until the patient regains consciousness. The light reflex is lost, a point that seems to distinguish this from false epilepsy. Spasm of extrinsic ocular muscles frequently occurs, causing deviation of the eyeballs toward the side of greatest contraction (Gowers). Subconjunctival ecchymoses may be present after a seizure.

In some cases epileptiform seizures appear to be due to eye strain, the seizures ceasing when the eye strain is relieved.

Headache and Vertigo.—These, if persistent, should merit a careful examination of the eye. The former is caused more frequently by eye strain than by anything else. Errors of refraction, anomalies of the extrinsic and intrinsic muscles of the eye, all may produce it. Examination of the irides, of the movements of the eyes, and of the interior of the eyes may disclose conditions (pareses, optic neuritis, retinal hemorrhage, vascular changes) which may aid largely in establishing a diagnosis. Vertigo is not infrequently due to refractive and muscular anomalies, and nausea either accompanying headache and vertigo or without either is, in a small percentage of the cases, due to the same cause.

Migraine.—See Scintillating Scotoma, page 539.

Bulbar Paralysis (*Progressive Bulbar Paralysis*[1]).—If the disease, the principal symptoms of which are those of bulbar paralysis, was confined to the medulla oblongata, the accompanying eye symptoms would be few if any. As a matter of fact the disease is not so confined. It may enter into the cord and produce the eye symptoms that accompany tabes, or extend into the brain and affect the motor, sensory, or visual centres connected with the eye and its adnexa. Thus involvement of the nucleus of the seventh may affect the orbicularis palpebrarum muscle; of the fifth, the sensibility of lids, conjunctiva, or cornea; of the third, the extrinsic and intrinsic muscles, producing more or less complete hemiplegia, externa or interna, etc.

Myasthenia Gravis (*Erb's Disease; Asthenic Paralysis*).—This disease has many of the characteristics of bulbar paralysis. It is insidious in its onset. Ptosis is an early symptom in 50 per cent. of the cases.[2] Ptosis occurs sooner or later in about 85 per cent. of the cases. External ophthalmoplegia and paralysis of the orbicularis palpebrarum are frequent, but ophthalmoplegia interna seldom occurs. Defective upward movement of the eye, with fair preservation of lateral and downward movements, is noted. The muscular paresis is more marked on fatigue.

Multiple Sclerosis (*Sclerosis en Plaque*).—Since this disease is one affecting the central nervous system generally and the patches of degeneration may occur at any part, it is easy to understand how the eye may be variously affected through its nervous connection with the brain. Optic atrophy, partial or complete, occurs in 50 per cent. of the cases (Hirsch). The atrophy is usually monocular: it may be partial. The process may become arrested at a certain stage and not again become progressive.

[1] For a complete description of this and allied disorders, see Posey and Spiller, The Eye and the Nervous System, chapter X.

[2] Hun, Albany Med. Ann., 1904, xxv, 28.

Improvement in vision has been observed in some cases. The atrophy may be a simple atrophy or may be preceded by optic neuritis. While in the greater number of cases the ophthalmoscope shows a pale disk, in some cases the ophthalmoscopic examination is negative, the lesion occurring cerebral from the basal ganglia.

Tabes Dorsalis.—See Iris and Optic Nerve.

Diathetic Diseases.—**Gout** (*Uric Acid or Lithemic Diathesis*).—Patcher[1] defines gout as "a nutritional disorder characterized by disturbances in nitrogen metabolism, with an excess of uric acid in the circulating blood." Deposits of the biurate of soda take place in varions tissues of the body. The ocular symptoms that accompany gout are due to (*a*) gouty deposits in the walls of the blood-vessels interfering with nutrition by obstruction to the flow of blood, or by the prevention of the escape of nutritive substances from the blood, or (*b*) to deposits of the biurate of soda in the tissues of the eye.

The conditions due to gout are dry eczema of the lids, tophi, keratitis with deposits of urates, scleritis, conjunctivitis, iritis, chorioiditis, cyclitis and retinitis, macular exudative retinitis, often monocular, hemorrhagic retinitis, cataract, glaucoma, thrombosis of retinal arteries.

Treatment.—This is largely diathetic. Local remedies must also be employed as indicated.

Rickets.—See chapter on Crystalline Lens.

Scurvy.—Subconjunctival hemorrhage and hemorrhage beneath the skin of the eyelids may occur early in scurvy, particularly in scurvy affecting infants. Tortuosity of retinal vessels, hemorrage into the retina, and hemorrhage into the orbits with proptosis occurred in 49 out of 379 cases.[2] Night-blindness is not uncommon, apparently due to faulty nutrition to the retina. This disappears, as a rule, when the scurvy is recovered from.

Diabetes Mellitus.—The eye complications due to this disease are numerous. Gangrene of the lids, xanthoma diabeticorum, cataract in 4 to 5 per cent. of the cases, retinitis (see Retina), iritis (rare), sometimes with hypopyon, diabetic amblyopia, optic neuritis, cholesterin crystals in the vitreous, intra-ocular lipemia due to a substance in the blood allied to fat.[3]

König[4] examined 500 cases of diabetes in regard to eye complications and found cataract, 10; disturbances of accommodation, 20; gangrene of lids, 2; hemorrhagic glaucoma, 2; polioencephalitis superior, 2; atrophy of optic nerve and retinitis, each 3.

The distinguishing points between diabetic and tobacco retrobulbar neuritis are (1) the relative later appearance of the pallor of the temporal half of the disk in diabetic cases, (2) the relatively greater frequency of scotoma for blue and absolute scotoma, (3) the greater age of the patient.

Transient Myopia and *Hyperopia.*—These develop in diabetes. Myopia develops rapidly, reaching a maximum in from five to ten days.

[1] Osler's Modern Medicine, p. 808.
[2] R. Hutchinson, Osler's Modern Medicine, p. 904.
[3] Reis, Graefe's Arch., lv, p. 3.
[4] Soc. franç. d'opht., cxiii, p. 365.

The change accompanies an increase in the amount of sugar in the urine and decreases when the sugar diminishes[1] or persists.[2] The myopia is supposed to be due to an increase in the refraction of the lens, due to the presence of sugar in the fluids of the eye. This has apparently been substantiated by the direct examination of such a lens (Heine).

Hyperopia.—Horner[3] was among the first to report a rapidly acquired hyperopia in diabetes. Treatment of the diabetes reduced the hyperopia by two dioptres. Recently, Jackson, Groenou, Lundsgaard,[4] and other have published similar cases. The hyperopia develops within a few days, during an exacerbation of the diabetes, and subsides as the diabetes improves. Paresis of accommodation is an accompaniment. A number of theories are advanced to explain the phenomena: (*a*) The development of a latent hyperopia with cycloplegia; (*b*) shortening of the antero-posterior axis of the globe from loss of fluid from the eye; (*c*) increase in the index of refraction of the vitreous. Transient astigmia also develops in these cases.

Premature presbyopia, subnormal accommodation, is sometimes an early symptom of diabetes (de Schweinitz).

Infectious Diseases.—Cholera.—The eyeballs recede into the orbit because of a diminution of the fluids of the orbital tissue. The cornea is prone to suffer from desiccation. Cyanosis of the lids and of the fundus oculi occurs to some degree in many cases. Subconjunctival hemorrhage occurs in the severe cases. The condition of the pupil during the algid stage decides the prognosis.[5] If the irides react to light the prognosis is favorable; if they do not react to light, the prognosis is unfavorable.

Chickenpox.—The eruption of chickenpox may appear on the conjunctiva and cornea;[6] the vesicles rupture, a superficial ulcer forms, and healing takes place without leaving a trace.

Cerebrospinal Meningitis.—The affections of the eye in this disease are relatively infrequent, varying largely in different epidemics. Ballantyne[7] reports the changes observed in the eye in 73 cases studied. Stimulation of Müller's muscle, with Graefe and Dalrymple signs, 15; conjunctival hemorrhage, 4; nystagmus, 7; congestion and blurring of margins of optic disk, 9; optic neuritis, binocular, 5. Secondary optic-nerve atrophy, paralysis of the extrinsic ocular muscles and metastatic panophthalmitis occur in a very small percentage of the cases. Of 5092 cases studied by Nieden,[8] 3.5 per cent. had some ocular lesion. A number of cases of edema of conjunctiva and lids due to venous congestion were noticed. Abnormality of the pupils occurs.

Diphtheria.—Optic neuritis, transient in nature, is an accompaniment of diphtheria in a small percentage of the cases. Vision is temporarily

[1] Hirschberg, Centralbl. f. Augenheilk., 1886 and 1891; Grimsdale, Brit. Med. Jour., February 4, 1890; Weeks, Trans. Amer. Acad. of Ophth. and Oto-Laryng., 1905.

[2] Risley, Trans. Amer. Ophth. Soc., 1891, p. 121.

[3] Klin. Monatsbl. f. Augenheilk., 1873, page 490.

[4] Zeitschr. f. Augenheilk., February, 1907.

[5] Corte, Deutsch. med. Woch., January 22, 1891.

[6] Oppenheimer, Ophthalmology, October, 1905, p. 85.

[7] Brit. Med. Jour., July 27, 1907.

[8] Klin. Monatsbl. f. Augenheilk., July, 1905, p. 74.

impaired. The later effects are the paralysis of the intrinsic and extrinsic muscles of the eyes. Total ophthalmoplegia may develop. (See Conjunctiva, Disease of the Lachrymal Apparatus and Muscular Anomalies).

Erysipelas.—Eye affections from this cause are due to extension of erysipelas from the face. Abscess of the lid, with destruction of the skin of the lid, is not infrequent. Orbital cellulitis, thrombosis of orbital veins, abscess of the orbit may develop, accompanied by exophthalmos and ophthalmoplegia externa. Corneal anesthesia, corneal ulcer of all degrees of severity, iritis, uveitis, panophthalmitis, thrombosis of retinal veins, hemorrhagic retinitis, optic neuritis followed by atrophy and complete blindness may occur, on one or both sides, as a result of the invasion of the orbital tissues by the Streptococcus pyogenes. Glaucoma has been observed as a complication, as has also inflammation of the lachrymal gland and sac.

Gonorrhea.—Gonorrhea affects the eye, either primarily by conveyance of the gonococcus to the conjunctiva, or by metastasis—endogenous infection, or probably by the presence of its toxins.[1]

Influenza (*La Grippe*).—The most common eye affection in influenza is conjunctivitis. A very mild congestion of the conjunctiva accompanies almost all cases of influenza, but an acute mucopurulent conjunctivitis, such as is at times produced primarily by the influenza bacillus (see page 227), is not common as a complication of the general disease. Ulcer of the cornea with perforation and panophthalmitis (Jackson); transient paralysis of various muscles, most commonly of the abducens; paresis of accommodation, usually bilateral; optic neuritis, which may be recovered from or may be followed by atrophy; retrobulbar neuritis with central scotoma, usually absolute, transient in the greater number of cases, may occur. Sönderlink[2] reports a case of optic neuritis followed by atrophy and blindness. Hemianopsia[3] has been observed, probably due to cortical or subcortical lesion. Intense pain in the eyeballs, at apices of orbits and over frontal sinuses, lasting three to five days, is common. It is very probable that many of the paralyses and optic-nerve affections accompanying influenza are due to extension of the inflammation from the frontal, ethmoid, and sphenoid sinuses, and not to the presence of the influenza bacillus in the tissue of the nerves affected. The toxins produced by the bacilli may play a role. Many of the numerous affections of the eye that have been observed to accompany influenza[4] are evidently coincident and due to the presence of other microörganisms.

Leprosy.—All of the tissues of the eye suffer in leprosy. The manifestations are described in the chapters on diseases of the various parts of the eye.

Measles.—A mild conjunctivitis, in the scant secretion from which the staphylococci and the streptococci are sometimes found, occurs in

[1] Ullman, Wiener klin. Rundschau, 1907, 15 to 21.
[2] Receuil d'opht., April, 1905.
[3] Gifford, Ophth. Record, May, 1893.
[4] Pflüger, Berl. klin. Woch., 1890, No. 27.

almost every case of measles, usually just preceding the rash. The lowered power of resistance of the system permits the invasion of other parts by these microörganisms, and hordeolum, blepharitis marginalis, dacryo-adenitis, dacryocystitis, and corneal ulceration may develop. An occasional case of subnormal accommodation and paresis of ocular muscles has been observed.

Trantas[1] described an eruption affecting the centre of the cornea accompanying the skin eruption which he found in thirty-one out of forty-one cases examined. The change consists in the development of numerous, very small, gray points in the superficial layers of the cornea; the epithelium is wrinkled over them, but not lost. Vision impaired but little, if at all. Corneal sensation blunted in some cases. The spots disappear in from three to six days.

Mumps.—The principal ocular disturbance associated with mumps that can be separated from other coincident affections is dacryo-adenitis. This occurs in a small percentage of the cases, the number varying in different epidemics. The lachrymal gland suppurates only rarely. Edema of the lids of very marked degree may develop. Woodward[2] has collected 23 cases of neuroretinitis in which vision was more or less impaired in 12, recovery in 11; 3 cases of retrobulbar neuritis, complete recovery in all; 6 cases of optic-nerve atrophy, blindness, 4, nearly complete blindness, 2; 6 cases of iritis; 14 cases of dacryo-adenitis; 3 cases each of paralysis of accommodation and of the extra-ocular muscles.

Malaria.—Keratitis (Kipp), optic neuritis, retinal hemorrhages (Jones), retinochorioiditis, amblyopia (possibly due to quinine taken) are observed. Cataract developing rapidly in relatively young individuals has been reported (Cosmettos, Terson). On the whole, the ocular symptoms accompanying malaria are rare.

Rheumatism (*Rheumatic Fever*).—Recent research has apparently relegated this disease to the category of those produced by a specific microörganism, the diplococcus rheumaticus. The eye affections that have been observed are acute conjunctivitis and acute iridocyclitis. The chronic relapsing form of iritis which accompanies an arthritic family history and rheumatoid pains is apparently not related to acute rheumatism.

Relapsing Fever.—Uveitis of varying degrees of severity, followed in a small percentage of the cases by shrinking of the vitreous and atrophy of the globe, is described by Knies.[3] The uveitis begins after the third week of the fever. Its frequency differs largely in different epidemics. In some epidemics "nearly 90 per cent. of the cases are affected." Both eyes are involved in about 20 per cent. Recovery is the rule.

Ljabinsky[4] reports 22 cases of iridocyclitis in 640 cases of relapsing fever observed by him. All were in males over twenty years of age. Interval between the last attack of fever and the first ocular symptoms, one to ninety-five days. Other eye affections are rare in relapsing fever.

[1] Annal. d'oculist., August, 1903. [2] Ann. of Ophth., January and April, 1907.
[3] The Eye in Relation to Disease, New York, 1895, p. 385.
[4] Wjestnik, April, 1886, No. 6; 1887, No. 1.

Septicemia, Pyemia.—These terms are employed to designate secondary invasion of the system by pyogenic microörganisms, principally the streptococcus and staphylococcus. The pathogenic germs, pneumococcus, gonococcus, colon and typhoid bacillus may produce pus and may produce pyemia. The affections of the eye due to the conveyance of these microörganisms to the tissues of the eye by the blood or lymph streams are various. When the streptococci and staphylococci are concerned the metastasis usually results in a panophthalmitis.

Smallpox.—For a comprehensive review of the eye affections accompanying smallpox, see Thilliez and Bonté.[1] Before the days of Jenner, 35 per cent. of the blindness in France was said to be due to smallpox. The lids are the site of the pustules in 20 to 30 per cent. of the cases. Some destruction of tissue may follow. The lids may become very edematous, preventing opening the eyes. Pustules may appear on the conjunctiva; also at the puncta lachrymalia, eventually closing these openings. Pustules may develop on the cornea, causing all degrees of destruction of corneal tissue. It is believed that the suppuration that follows the development of a pustule on the cornea is due to secondary infection and that it can be prevented by suitable asepsis. Subconjunctival hemorrhage may occur in hemorrhagic smallpox. Retinitis, glaucoma, parenchymatous keratitis, and paralysis of eye muscles have been observed.

Scarlet Fever.—Two cases of orbital cellulitis as a sequel of scarlet fever are reported by Chaunce;[2] both patients died. A mild conjunctivitis or conjunctival irritation with lachrymation often accompanies the eruptive stage of scarlatina. Hirschberg reports transient amaurosis consequent on cerebral anemia.

Typhoid Fever. —Conjunctivitis, keratitis, embolism of retinal arteries, optic neuritis, optic-nerve atrophy, panophthalmitis, thrombosis of orbital veins, cataract, and paresis of ocular muscles have been observed as rare complications in typhoid. Since the typhoid bacillus is present in all the tissues of the body to a greater or less degree, it is not strange that manifestations in the eye, particularly those connected with the blood-vessels, are not uncommon. Retinal hemorrhage occurs fairly frequently.[3] Inflammation of the uveal tract is rare. In the later stages of the disease enophthalmos from wasting of orbital tissues, superficial and sometimes deep and extensive keratitis from inefficient closure of the lids, and diminished accommodative power are experienced.

Of 1138 cases of typhoid, ocular affections occurred in 32. The chorioid was affected most frequently.[4]

Typhoid fever possesses some therapeutic value, according to Todd,[5] who noted the disappearance of trachoma and dense pannus during the course of a severe attack of typhoid fever in a young woman.

Yellow Fever.—Marked conjunctival hyperemia in the early stage. The red appearance of the conjunctiva is modified by an admixture of

[1] La clin. opht., February 25, 1907.
[2] American Medicine, June 17, 1903.
[3] Bull, Med. News, April, 1897.
[4] Adamuck, Petersburg. med. Woch., 1894, 38 and 39.
[5] Ophth. Rec., January, 1906.

yellow as the disease progresses. Subconjunctival and retinal hemorrhages may occur.

Pneumonia.—The cause of lobar pneumonia, the pneumococcus, may invade every tissue of the eye except the lens and produce pathological changes. The changes produced are described in the chapters on diseases of the various tissues of the eye.

Plague.—Eye complications are not infrequent. Maynard[1] observed the following complications in an epidemic at Patua: Cornea, infiltration, 6 cases; sloughing, 4; iritis, 12; scleral staphyloma, 2; lens, incipient cataract, 7; mature cataract, 5; retinal hemorrhage, 1 case. According to Calvert,[2] conjunctivitis is common. Keratitis, iridocyclitis, and hypopyon occur. Panophthalmitis occurs rarely.

Beriberi.—Spasm and paralysis of ocular muscles, atrophy of the optic nerve (Laurencao), and neuritis have been observed in this affection. The amblyopia occasioned is recovered from in some of the cases.

Whooping Cough.—Conjunctivitis is not uncommon in whooping cough, usually of the mucopurulent variety, not very severe. Subconjunctival hemorrhage occurs as a result of the paroxysms. Hemorrhage into the orbit may produce exophthalmos, ophthalmoplegia externa and ptosis. Optic neuritis leading to blindness has been observed.[3]

Diseases of Circulatory System.—Anemia (Secondary) and Chlorosis.—If the anemia is pronounced the conjunctiva is of a pale-pink color, sclera pearly white, the retinal vessels tortuous and paler than normal. Retinal hemorrhages may occur. In 246 cases of simple chlorosis systematically examined retinal hemorrhages occurred in 3 cases (Pagenstecher).

Anemia, Pernicious.—The principal affection of the eye in this disease is retinal hemorrhage. Of 238 American cases examined, retinal hemorrhage occured in 84 (31 per cent.). A series of foreign cases, 326 cases, showed retinal hemorrhage in 236 (72 per cent.). The examination of the American cases was made but once; of the foreign, repeatedly.[4]

Leukemia, Myeloid.—Of 66 cases examined, retinal hemorrhage was found in 7 (Cabot). Infiltration of the chorioid with lymphocytes located about the optic disk has been observed by Stock.[5] The formation of lymphoid tumors in the orbit has been described (see page 633).

Leukemia, Lymphoid.—This form of leukemia is rarer than the former in occurrence, but retinal hemorrhage takes place in a higher percentage of the cases. Of 9 cases examined retinal hemorrhages were found in 8.[6]

Endocarditis.—This may cause embolus of the central artery of the retina by the detachment of small masses from the endocardium. Aortic regurgitation, because of the sudden drop in blood pressure after systole, may cause pulsation of retinal arteries. Increase of the action of the

[1] Brit. Med. Jour., September 14, 1901.
[2] Osler's Modern Medicine, ii, p. 770.
[3] Gamble, Arch. of Ophth., July, 1903.
[4] Cabot, Osler's Modern Medicine, iv, p. 626.
[5] Klin. Monatsbl. f. Augenheilk., April and May, 1906.
[6] Cabot, Osler's Modern Medicine, iv, p. 666.

heart under these conditions may cause increase in intra-ocular tension by increase of the secretion of fluids into the eye. It may also produce retinal hemorrhage. Anasarca from disease of the heart may show itself in the eyelids, particularly after the patient has been in the recumbent position for some time, as after a night's rest.

Cyanosis.—Cyanosis due to admixture of venous and arterial blood, principally by an open foramen ovale, shows itself in the eye by a cyanotic appearance of the lids, conjunctiva and fundus oculi.

Purpura Hemorrhagica.—Multiple hemorrhages in the optic nerve and retina have been noted,[1] also atrophy of the optic nerve (Schultz-Zehden).

Disease of the Kidneys.—See Retina, page 443.

Condition of Sexual Organs.—Excessive sexual intercourse may produce atrophy of the optic nerve in the male. Retinal hemorrhage may occur (Knies).

Menstruation.—The establishment of menstruation is accompanied by disturbances affecting the eye in a very few cases. Dor[2] reported the case of a girl, aged fourteen years, who had a hemorrhage into the vitreous at her first menstrual period, which disappeared and reappeared whenever menstruation took place until the beginning of regular menstruation. In a second case hysterical amblyopia developed with the beginnnig of the menses and disappeared when menstruation was fully established. Swelling of the lids, blue rings about the eyes, colored sweating, vicarious menstruation through the skin of the lids (Claiborne), weakened accommodation, transient amblyopia, and hemianopsia may occur.

Pregnancy.—The ocular disturbances that accompany normal pregnancy are chiefly reflex: Asthenopic symptoms, subnormal accommodation, mydriasis, retinal hemorrhage rarely. All pathological conditions affecting the eye locally or systemically that may be aggravated by increase in the volume and force of the circulation are accentuated by pregnancy; thus glaucoma, retinal hemorrhage, and exophthalmos are unfavorably influenced. Affections of the kidneys due to pregnancy produce retinitis (see page 450) in a large percentage of the cases.

Parturition.—This may be accompanied by subconjunctival hemorrhage, hemorrhage into the orbit, retinal hemorrhage, and, in some cases of great loss of blood, by partial or complete blindness.

Puerperium.—If not aseptic the puerperium may be complicated by metastatic panophthalmitis. The prognosis as regards life in these cases is not good. Axenfeld collected 105 cases of metastatic iridochorioiditis, 75 of which were fatal. The puerperium may also be accompanied by optic neuritis and atrophy, retrobulbar neuritis, embolism of the central artery, and by retinal hemorrhages.

Lactation.—Temporary failure of vision may accompany lactation. Nettleship records four cases, in one of which there was the picture of retrobulbar optic neuritis; in the others no ophthalmoscopic changes were present. Night-blindness has been recorded.

[1] Marx, Graefe's Arch., lxiv, p. 1.

[2] Soc. franç. d'opht., January 31, 1884.

Exophthalmic Goiter (*Graves' Disease*).—**Etiology.**—The cause of this disease is still undecided. It has been attributed to disease of the sympathetic nervous system, to a lesion of a centre in the medulla oblongata, and to perverted function of the thyroid gland. The latter is the more probable. It is conceded that anomalies of the thyroid gland accompany the greater number, it not all, of the cases, enlargement of the gland being present in many.

Fig. 359

Exophthalmic goiter. (Burr.)

Symptoms.—The disease is characterized by rapid pulse (tachycardia), tremor, and nervous irritability. Exophthalmos is present in the greater number of cases—about 64 per cent.[1]

The eye symptoms which accompany Graves' disease may be considered under the following headings: Exophthalmos, Graefe's sign, Dalrymple's sign, Stellwag's sign, Gifford's sign, Rosenbach's sign, epiphora, tâche cérébrale, pigmentation of the skin of lids, overhanging fold of skin of upper lid, protrusion of skin at lower margin of orbits, periodic edema of eyelids, disappearance of eyebrows and eyelashes, cornea, iris, fundus oculi, affections of ocular muscles.

Exophthalmos.—This familiar symptom may be present in varying degree, from an almost imperceptible increase in the prominence of the eyes to a condition rendering it impossible to close the lids over the globe. In rare cases the eyeballs are forced outside of the lids, a condition resembling paraphimosis resulting. The globe may be readily pressed back into the orbit, but the exophthalmos recurs as soon as the pressure is removed.

Thompson, Amer. Jour. Med. Sci., December, 1900.

The exophthalmos is usually bilateral, but may be unilateral. The symptom may appear only under special circumstances. De Mussy reports a case in which the exophthalmos was present only during choreic attacks, and Savage reports a case which presented the condition only at the time of menstruation.

It is generally conceded that the exophthalmos is due to hyperplasia of the fatty tissue and to dilatation of the vessels of the orbit.

Graefe's Sign.—This[1] consists in a failure of the upper lid to follow the eyeball when the patient looks downward, thereby exposing an unusual area of the sclera above and to the sides of the cornea. If the eye is rotated upward the upper lid follows the globe more energetically and to a greater degree than normal. The sign is not always present in Graves' disease. Different writers report differently regarding it. It occurred in 98 per cent. of the cases observed by Sharkey;[2] in 55.5 per cent. of the cases observed by Lewin;[3] in 13.3 per cent. of the cases observed by Hill Griffith; in 17.6 per cent. of the cases observed by West. While in the great majority the sign is bilateral, it has been observed in but one eye in some cases. Graefe's sign is not pathognomonic of Graves' disease. It may occur in individuals apparently in good health.[4] The writer has observed it from time to time. In cases of simple chronic glaucoma it is not infrequent. "Kocher and Jessup have shown that similar phenomena, but to a less degree, may be produced by instilling cocaine into the conjunctiva," the condition being attributed to stimulation of the nerve-endings of the sympathetic and consequent contraction of the muscular fibers supplied by them.

Fig. 360

Graefe's symptom. (Axenfeld.)

The Graefe sign appears independently of the degree of exophthalmos. It may disappear at any stage of the disease and may reappear. The lower lid may present a similar condition, but to a less degree.

A number of theories have been advanced to explain this sign.[5] Von Graefe was of the opinion that the phenomenon is due to contraction of the non-striated muscle fibers of the muscle of Müller as a result of irritation of the sympathetic.

Dalrymple's Sign.—This is the term applied to the condition which obtains when the lids are too widely separated and a staring expression is induced. This sign may or may not coexist with the Graefe sign. It is usually bilateral. It is not pathognomonic of Graves' disease, being not infrequently observed in health. The phenomenon is due to retraction of the lids by contraction of the non-striated muscle fibers of the lids and orbit consequent on stimulation of the sympathetic.

[1] Deutsche Klinik, 1864, No. 16, p. 158. [2] Brit. Med. Jour., October 25, 1890.
[3] Wilbrand u. Sanger, i, p. 44. [4] Posey and Spiller, The Eye and Nervous System, p. 833.
[5] Wilbrand u. Sanger, Neurol. des Auges, i, p. 44.

Stellwag's Sign.—Ordinarily the Dalrymple sign is credited to Stellwag, but, in a strict sense, the Stellwag sign is the infrequency and the incompleteness of nictitation. This sign may co-exist with exophthalmos and with the Graefe sign, or both may be absent. The sign is not pathognomonic, but, taken in connection with other signs of Graves' disease, is of much value in assisting in making a diagnosis.

Gifford's Sign.—In an article read before the Section on Ophthalmology, New York Academy of Medicine, 1906, Harold Gifford reported having observed as an early sign in Graves' disease an inability or great difficulty in everting the upper lid on account of retraction and rigidity of the lid. The sign was not always present. When it did occur it appeared early and disappeared in from three to six weeks. The observations of Gifford were confirmed by Charles Stedman Bull in the discussion of the paper.

Rosenbach's Sign.—This consists in trembling of the upper lid when the patient closes the eyes gently as though in sleep. The trembling disappears when the eye is again opened and is not present when the patient actually sleeps. The symptom is frequently, but not always, present in Graves' disease. It has been observed in other diseases and in health.

Epiphora.—This is regarded by Berger (Posey and Spiller) as an initial symptom of Graves' disease, attributing it to the known influence of the sympathetic on the secretion of tears. Irritation of the sympathetic increases the flow. Undue exposure of the globe to the air may also be a factor in the production of an excessive flow of tears when the Graefe and Dalrymple signs co-exist. Profuse lachrymation is usually bilateral, but may be unilateral. Wilbrand narrates a case in which the epiphora was confined to one eye and was nocturnal, the flow being sufficiently profuse to awaken the patient. Exophthalmos and the Graefe and the Stellwag signs were present. As the disease progresses the lachrymation grows less and may become quite scanty.

Tâche Cérébrale.—A sign of vasomotor irritability is the "tâche cérébrale." This is not infrequently demonstrable in Graves' disease (Trousseau). By drawing the finger over the skin of the lid a transient flushing will follow.

Pigmentation.—Pigmentation of the skin of the lids has been observed by many clinicians in connection with Graves' disease. It is not a constant symptom. The skin of the upper lid is the site of the pigmentation. The color is light brown, resembling that of Addison's disease. An abnormal dryness of the skin is sometimes observed.

Overhanging Fold of Skin.—When the Graefe or the Dalrymple sign is persistent, a fold of the skin of the upper lid not infrequently falls over the retracted margin of the lid and in exceptional cases may reach the eyeball.

Protrusion of Skin of the Lower Lid.—The excess of orbital contents which causes the exophthalmos produces, in favorable cases (namely, those in which the septum orbitale of the lower lid is somewhat relaxed), a rounded, sac-like prominence of the lid at the lower margin of the orbit by the pressure against these structures.

Periodic Edema.—Transient edema of the lids is sometimes present.

Disappearance of Eyebrows and Eyelashes.—The hair of the eyebrows and the eyelashes is sometimes lost. The loss is usually bilateral, but unilateral loss has been reported.

Cornea.—As a result of the exposure consequent on extreme exophthalmos, infrequency of winking, and scanty lachrymation, ulcer of the cornea sometimes occurs. The writer has observed almost complete loss of corneal tissue in both eyes from this cause. Slight impairment of sensibility is not uncommon.

Iris.—Moderate dilatation of the pupil is frequently observed; also inequality of the pupils. These symptoms are due to irritation of the sympathetic. In cases of inequality of the pupils the irritation is of varying degree on the two sides.

Fundus Oculi.—According to Knies,[1] in advanced cases the ophthalmoscope often shows arterial pulsation extending far into the periphery of the fundus. Becker[2] found arterial pulsation in six of seven cases examined.

Affections of Ocular Muscles.—Palsy of the extrinsic muscles is not very uncommon in Graves' disease. Bilateral abducens paralysis is most frequently seen, but isolated and multiple pareses and paralyses have been described by various writers. The paralyses occur late in the disease, as a rule, but may occur relatively early. They may be transient, but in the greater number of cases are persistent. It is a significant fact that the intrinsic ocular muscles and the optic nerve are seldom affected. Not infrequently a single muscle of those supplied by the third nerve is involved. Almost complete paralysis of the extrinsic muscles of the eye has been reported. These various manifestations of paralysis of ocular muscles point to peripheral lesions in some cases, to nuclear lesions in others. Contraction of the visual fields has been observed.

Treatment.—Local measures are employed to protect the cornea from injury due to overexposure. If the eye is not covered sufficiently often by the lids, aseptic vaseline may be introduced sufficiently often to prevent desiccation. If this is not efficient the palpebral fissure may be shortened by tarsorrhaphy. The general treatment of Graves' disease properly belongs to the internist and neurologist. It may be said that Doe[3] reports having obtained very satisfactory results by the feeding of fresh thymus gland (from the calf), 5 to 20 grains being given daily. Many remedies have been advised, among which are aconite, quinine, digitalis, and belladonna. Change of climate and altitude have benefited some cases. Excision of the enlarged thyroid in exophthalmic goiter has been practised with good results in about 80 per cent. of the cases;[4] there was a mortality of about 8 per cent.

Myxedema and Cretinism.—**Etiology.**—It is now generally admitted that the exciting cause in primary myxedema is loss of the function of the thyroid gland either by congenital absence, by removal

[1] The Eye in General Disease, Noyes, p. 443.
[2] Monatsblt. f. Augenheilk., 1880, p. 1.
[3] Rev. gén. d'opht., October, 1906.
[4] Kocher, Brit. Med. Jour., June 2, 1906.

by surgical means, or by disease of the gland. Since the report of the work of the special committee appointed by the Clinical Society of London to investigate the subject,[1] it is conceded that (1) myxedema and cachexia strumipriva are identical; (2) sporadic cretinism is myxedema occurring in childhood; (3) endemic cretinism is closely allied to myxedema.

Symptoms.—"The upper and lower eyelids are swollen and the skin is wrinkled, the supra-orbital fossa being often filled by the myxedematous swelling, while the skin just below the lower lid is baggy and translucent from the swelling beneath it. As a result of the swelling there is frequently some drooping of the upper eyelid with narrowing of the palpebral fissure, which is partly compensated for by an instinctive elevation of the eyebrows by tonic contraction of the occipitofrontalis muscle. This contraction causes a transverse wrinkling of the skin of the forehead. In advanced cases the skin of the lids is dry, and the hair of the eyebrows and the cilia may be partially or wholly lost. One of the most prominent symptoms is lachrymation due to the swelling of the eyelids.[2]

Wagner[3] reports a case of neuroretinitis of both eyes occurring in a girl, aged twenty-six years, with myxedema. Under the influence of thyroidin the vision of the right eye improved from $\frac{20}{200}$ to $\frac{20}{20}$; the left eye, in which the optic nerve was atrophied, showed no improvement. On account of the improvement of the right eye under thyroidin, Wagner thinks that it is not unlikely that the neuroretinitis was due to the myxedema.

Rarely patients who present the general appearance and symptoms of myxedema have interstitial keratitis of a pronounced type (Raisley). They derive much benefit from the judicious exhibition of the dried thyroid gland of the sheep in dose of approximately gr. iij, t. i. d.

In a case of myxedema observed by Collins[4] there was haziness in the centre of one cornea, which, seen with the corneal microscope, was found to consist of minute globules, gray dots in the anterior layers. Collins took the dots to be dots of mucin such as occur in the skin. The cornea cleared up under treatment with thyroid gland.

Disturbances Accompanying Myxedema of Intracranial Origin.—This group includes the disturbances due to (*a*) the edema of brain tissue, and (*b*) the effects on the optic nerve due to compensatory enlargement of the hypophysis cerebri. To the first may be attributed the visual hallucinations reported by some observers. These could be brought about by disturbances of the neurons of the cortical memory centres for visual impressions, by pressure, or by edema.

Bitemporal heminanopsia and atrophy of the optic nerve, which have been reported in myxedema, are presumably due to changes in the hypophysis cerebri. According to Murray the hypophysis has been found to be enlarged even to double the normal size in some cases. The

[1] Trans. Clin. Soc., London, 1888, Supplement.
[2] Murray, Diseases of the Thyroid Gland, London, 1900.
[3] Graefe-Saemisch, vol. xi, part i, page 331, 2d ed.
[4] Trans. Ophth. Soc. U. K., xxvii, p. 203.

enlargement is apparently due to vicarious activity of the hypophysis in the attempt to compensate for loss of thyroid secretion. The relation between the thyroid gland and the hypophysis cerebri is very conclusively shown by the researches of von A. Shoeneman.[1] In 27 cases with normal hypophyses the thyroid was normal. In 84 cases, with pathological changes in the hypophyses, disease of the thyroid was found without exception.

Especial Features of Cretinism.—The eyes are small, deeply placed, and widely separated. The palpebral fissure is narrow and at times oblique. Slight congenital anomalies were found in the eyes of five out of fifty-seven cretins examined. Pupils and fundi normal. In advanced cretinism the hair of the eyebrows is frequently scanty and is sometimes wanting.

Acromegaly.—The eye symptoms and lesions produced by acromegaly are abnormal thickening of the lids, marked prominence of the orbital margins from thickening of osseous tissue, with apparent sinking of the eyeball in some cases, exophthalmos in others, hyperplasia of the lachrymal gland, pain in the eyes, supra-orbital neuralgia, lachrymation, nystagmus, oculomotor paresis, loss of convergence power, sluggish reaction of irides to light. The most typical symptoms is bitemporal hemianopsia (Hertel). (See page 526.)

Intestinal Parasites.—The eye disturbances may be reflex, caused by absorption of toxins or by the movements of the parasites and their embryos. The parasites chiefly responsible for these disturbances are Ascaris lumbricoides, Tenia solium (Rampoldi), Oxyuris vermicularis. They may be due to the presence of the parasite in the tissues, as in trichiniasis, which produces edema of the lids, pain on moving the eyes, and, rarely, mydriasis and paresis of accommodation. Retinal hemorrhage may accompany the anemia caused by the presence of the Ankylostomum duodenale and bothriocephalus in the intestines.

[1] Hypophysis und Thyroidea, Virchow's Arch., 1892, Band cxxix, H. 2.

CHAPTER XXIX.

OPERATIONS.

Preparation of Surgeon and Assistants. The surgeon and assistants should render the hands and exposed portions of the forearm aseptic in the ordinary way, giving particular attention to the finger nails. A sterile gown should be worn, also a cap and face shield if the hair and beard are long.

Preparation of Patient. A cathartic should be administered, or an enema given sufficiently early to have the bowels empty before operation. The patient should have a bath.

Bacterial Examination. In all cases in which the eyeball or the conjunctiva is to be incised, a microscopic examination of the conjunctival secretion is desirable on the morning of the day of the proposed operation. If pathogenic or pyogenic germs are found the operation should, as a rule, be postponed until these can be eliminated. It is the writer's practice to have the conjunctival sacs irrigated with a saturated solution of boric acid twice daily for two or three days before operation in cases in which this is possible. It is often desirable to have the patients who are to be operated on enter the hospital one or two days before operation for proper preparation.

Preparation of Skin in Region of Operation.—After instilling a drop of a solution of cocaine into the eyes the skin of the eyelids and surrounding parts should be gently scrubbed with soap and water, then with alcohol, then with mercuric chloride (1 to 5000), care being taken to prevent the irritating solutions from entering the conjunctival sac. If the field of operation involves the brows, they should be shaved. The margins of the lids should be carefully cleansed by means of absorbent cotton and mercuric chloride (1 to 5000), removing all scales and extraneous matter. It is often advisable to remove the contents of the Meibomian glands by gentle pressure over a horn spoon or the handle of an instrument. Pressure should be made over the lachrymal sac to empty the sac and the canaliculi. If any pus escapes from the canaliculi the inflammation causing the secretion should be cured before operation necessitating the opening of globe or conjunctiva is undertaken. The conjunctival sac should be thoroughly irrigated either with mercuric chloride (1 to 5000), saturated solution of boric acid, or with sterilized normal saline solution. In all cases in which there is a suspicion of the presence of pathogenic or pyogenic microörganisms the mercuric chloride should be used. The lids should be everted and the palpebral conjunctiva carefully inspected and cleansed.

Preparation of Instruments.—All instruments should be washed in soap and water, particular attention being paid to joints and rough surfaces (a fine brush is very useful for this purpose), dipped in hot water and thoroughly dried. If they are treated to an alcohol bath immediately before being dried, they are more apt to be sterile and not so apt to rust. Jackson advises keeping instruments in a tight case with powdered paraform after they are cleansed. The formaldehyde gas which the paraform gives off keeps the instruments sterile.

Many methods of sterilizing instruments for operation have been advocated, but the treatment with hot soda water followed by immersion in alcohol is most satisfactory. The non-cutting instruments to be employed are placed in boiling water, to which a few grams of the carbonate or bicarbonate of soda are added, and are permitted to boil for from five to fifteen minutes. The cutting instruments are immersed in the same solution and boiled one-half to two minutes. The knives may be wrapped in cotton if there is danger of injuring the cutting edge by contact with the metal sterilizer. The instruments are then immersed in absolute alcohol and are permitted to remain for a few minutes. They may then be transferred to the porcelain instrument tray or laid on sterile towels on the instrument table and kept covered with sterile towels until actually wanted for use. It is not desirable to keep the instruments immersed in a germicidal or aseptic solution after sterilizing, since such solutions almost without exception exert an injurious effect on the fine edge of cutting instruments.

Dressings, Bandages, and Protective Appliances.—**Dressings.**—The dressings employed in eye surgery should be light, non-irritating, aseptic or antiseptic, not easily displaced, and sufficiently protective. *All material for dressings must be sterilized before use.* The materials usually employed are absorbent gauze, absorbent cotton, gauze or flannel bandages. The ordinary dressing for an aseptic wound consists of two or three layers of gauze moistened in a non-irritating sterile solution (physiological saline or boric acid), the contact surface of which may be smeared with a bland ointment to prevent sticking (sterile vaseline, boric acid vaseline, 3 to 5 per cent.; mercuric chloride vaseline (1 to 5000). The gauze is placed over the wound, dry absorbent cotton properly adjusted over this, and a bandage or adhesive strips[1] applied. The absorbent qualities of such a dressing are not great. If there is any secretion of moment it will pass into the dressing better if a piece of rubber tissue or oiled silk large enough to cover the field of operation be placed between the cotton and the bandage. Ordinarily the two-inch gauze bandage is sufficient. If continuous gentle pressure is desired a thin two-inch flannel bandage may be used. If rigidity is desired a bandage that will become hard and firm on drying, as the starch or water-glass bandage, may be employed. If either of the two last mentioned is used it is well to put it on over a few turns of an ordinary gauze bandage.

[1] In Germany and Austria adhesive strips are used almost to the exclusion of the roller bandage in operations on the eyeball.

Iodoform or mercuric chloride gauze (1 to 5000) may be used wherever a mild antiseptic effect is desired, as in suppurating wounds; also to prevent infection and to encourage granulation, as in cases of evisceration of the globe, exenteration of the orbit, etc.

After plastic operations on the lids it is often necessary to apply a smooth dressing and to avoid any dressing that might adhere to and disturb the flap. In these cases sterile rubber tissue or gold-beater's skin moistened in some bland antiseptic fluid or smeared on the contact surface with some bland antiseptic oil or ointment may be placed over the wound and the dressing superimposed.

If a wet dressing is desired it may be obtained by moistening a piece of sterile spongiopilin and applying it to the part, holding it in position with a bandage, or a thin pad of absorbent gauze may be moistened in the solution and covered with a thin layer of moist absorbent cotton, if not sufficiently thick. The whole may be covered with rubber tissue or oiled silk. A bandage may be applied to hold the dressing in position.

Bandages.—The ordinary roller bandage is the most convenient. To occlude one eye (monoculus), the *right*, the roller bandage is first fixed about the vault of the cranium by a single turn, proceeding from in front toward the left; then after passing the left auricle above, the roll proceeds below the occiput, passes below the lobe of the right ear, up over the cheek and eye to the forehead, and over the prominence of the parietal bone; a turn about the vault of the cranium is again taken and the diagonal course again followed; a circular turn terminating at the intersection completes the bandage. It is secured by pins at the intersections. The first diagonal turn is the higher, the second overlaps the first, hugging the side of the nose. The bandage should pass the operated eye from *below* upward in applications of the roller, as the dressing is more accurately held and the pressure can be better regulated when this is done.

When the *left* eye is to be occluded the bandage is carried toward the right from in front.

To occlude *both* eyes (binoculus) the figure-of-eight bandage may be employed. The bandage should be two inches wide and seven yards long. It is commenced as in the preceding, carrying the roll to the side away from the operated eye so that when the bandage passes over the operated eye it will come from below upward. A turn about the vault of the cranium is taken after each diagonal turn; the bandage is secured at the intersections.

A binoculus may be commenced at the forehead and the bandage be carried over one eye (the non-operated one when but one eye has been operated on) at once, continued below the ear, around the base of the cranuim, below the other ear, and up over the other eye. A turn about the vault of the cranium is then taken. The bandage may be secured by one or more turns about the vault of the cranium. This bandage is apt to be loosened or tightened by flexion of the neck and is sometimes objectionable on this account.

Moorefield's, Liebreich's, and Stevenson's special bandages possess no advantages over the roller bandage.

Protective Appliances.—In operations on the eyeball it often happens that greater protection than the bandage affords is necessary; this may be obtained by the application of a rigid shield or mask over the bandage. A number of such appliances have been devised: Fuchs' wire eye screen, Andrews' aluminum eye shield, McCoy's aseptic shield, Ring's ocular mask.

Fig. 361

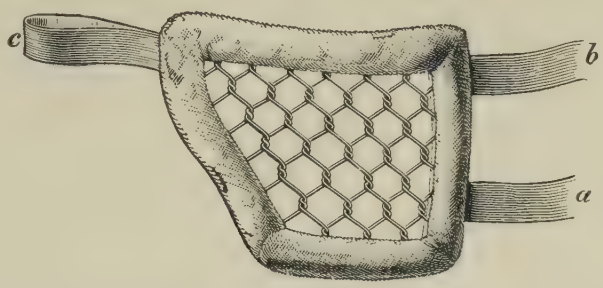

Fuchs' latticed frame used for dressing of the left eye. It is padded on its edges so as not to exert any pressure. *a*, *b*, bands passing from the two temporal extremities and carried respectively below and above the left ear, and across the occiput to the right side of the head; *c*, loop through which one of the bands is passed before they are tied. (Fuchs.)

Of these appliances, that devised by Ring (Fig. 362) is most used in the United States. It is made of papier-maché, lined on the inside with white muslin, outside with black silk, and is secured in place by means of tapes. The appliance is light, sufficiently rigid, and can be readily adjusted to fit the head of any patient. Both eyes can be covered or the mask may be cut to permit vision with one eye. The mask may be used without a dressing if it is desirable to protect or shade an operated eye. This appliance gives great satisfaction after cataract extraction in the added protection that it affords.

Fig. 362



Ring's ocular mask.

Anesthetics.—**General Anesthesia.**—As a rule, in the cases in which the safety of the operation and the comfort of the patient are to be enhanced, general anesthesia should be employed.

The choice of the anesthetic devolves upon the surgeon. Generally speaking, ether is the safest; however, patients with bronchial affections should not have ether. It is the writer's practice to employ ether for children and adults with the exception mentioned, commencing the anesthesia with nitrous oxide gas. The advantages of obtaining primary anesthesia with nitrous oxide gas are obvious. Chloroform

is given to infants and to individuals with bronchial affections. In these cases the administration of the anesthetic is not preceded by nitrous oxide gas. The skin of the face should be smeared with vaseline to prevent burning from the edge of the ether or chloroform cone. The writer has been favorably impressed by the use of ethyl chloride for anesthesia. It is a valuable agent for use for short operations, such as the opening of an abscess or for Stilling's operation on the tear passages.

Local Anesthesia.—*Cocaine.*—Cocaine[1] is the most useful local anesthetic. It may be employed in various strengths, from 2 to 10 per cent. For the extraction of cataract and all ordinary operations the writer employs a 4 per cent. solution. Roughening and loss of corneal epithelium can be avoided in almost all cases by keeping the lids closed. As a rule, the cocaine solution should be instilled every three to five minutes for fifteen to twenty minutes before the operation. The anesthetic effect lasts fifteen to twenty minutes. If profound local anesthesia is desired the fine crystals or powdered cocaine muriate may be introduced into the conjunctival sac. It must be borne in mind that some individuals are susceptible to the poisonous effect of cocaine, and the instillation of a few drops of even a 4 per cent. solution may cause distressing symptoms. The poisonous effect of cocaine is not often experienced by patients who are in the recumbent position. The tendency to induce an attack of acute glaucoma in eyes predisposed to glaucoma must be borne in mind. Inflamed tissues do not absorb cocaine well, consequently do not become so markedly anesthetic. The anesthetic effect of cocaine is apparently enhanced by the conjoint use of adrenalin. Cocaine dilates the pupil and causes some contraction of the blood-vessels.

Holocaine.—The hydrochloride is used. It is an efficient anesthetic, acting in from fifteen to twenty seconds. The effect lasts from eighteen to twenty minutes. Holocaine does not contract the blood-vessels, nor does it dilate the pupil. It does not disturb the corneal epithelium. It may be employed to induce anesthesia of the iris when the anterior chamber is opened without fear of producing opacities of cornea or media. The writer frequently uses holocaine in connection with cocaine after the incision in cataract extraction for an immediate anesthetic effect on the iris. Holocaine is bactericidal and antiseptic (Randolph), keeps well, and has a greater anesthetic effect on inflamed tissues than cocaine.

Eucaine.—This remedy occurs in two forms: Eucaine A, which is irritating to the conjunctiva and causes hyperemia, and eucaine B, which is much less irritating. These remedies are used in the strength of 2 per cent. The anesthetic effect is slightly less than that of cocaine, is not quite so certain, and it does not affect inflamed tissues readily.

Acoin.—Acoin is a crystalline salt, the hydrochloride of a base derived from guanidine. This salt is used in the strength of 1 to 100 to 1 to 300 for

[1] For directions regarding the sterilization of remedies used in the eye, see Special Therapeutics.

the production of local anesthesia after the manner of cocaine. According to Randolph, it has no effect on the accommodation or on the pupil, does not affect the tension of the globe, nor does it cloud the cornea. Its effect is unsatisfactory in conditions of congestion of the conjunctiva. On the whole, its effect is inferior to cocaine as a local anesthetic, but it may be used to advantage for the purpose of removing foreign bodies from the eye and for minor operative procedures when it is not desirable to dilate the pupil or interfere with accommodation.

Tropococaine.—This drug, in a 2 to 3 per cent. solution with sodium chloride ($\frac{6}{10}$ per cent.), is said to be a fairly efficient local anesthetic and not very irritating; if the sodium chloride is not added the irritation is considerable. The drug is not changed in boiling. The complete anesthetic effect is produced in a few minutes, lasts for two to seven minutes, incomplete for two to thirteen minutes (Annin).

Local Hemostasis.—For this purpose some preparation of the suprarenal gland is employed. Adrenalin chloride, with chloretone, is excellent. It may be employed in the strength of 1 to 1000 or much weaker (1 to 10,000) in all operations where a hemostatic effect is desired, either with or without a local anesthetic. It apparently enhances the effect of cocaine. It should be dropped into the eye two to five minutes before the operation is commenced, and may be dropped into the wound from time to time during the operation.

Infiltration Anesthesia.—This form of anesthesia is very serviceable in a number of operations on the lids and eyeball. It will be mentioned in describing individual operations. The injections may be made with an ordinary hypodermic syringe. Various solutions are employed—cocaine, sterile, 1 or 2 per cent., in physiological salt solution, is excellent. It is to be injected just beneath the skin or mucous membrane. If a hemostatic effect is desired, adrenalin chloride (1 to 1000) may be added in the proportion of 1 to 2. The point of the hypodermic needle is passed just beneath the skin or mucous membrane far enough to cover the opening, a drop of the fluid is forced out; the needle is then advanced a very short distance and one or two more drops of the solution are forced out; in this way the area of the operation is covered. Twenty to thirty drops of the solution may be used. If infiltration anesthesia requiring larger quantities of the solution is employed it is best to use a solution containing a less percentage of cocaine in order that poisonous effects may be avoided. Schleich[1] demonstrated conclusively in 1889 that very small quantities of cocaine may be sufficient to induce anesthesia by the infiltration method. He employed a number of solutions; for ordinary purposes, cocaine, 0.01 to 0.02; sodium chloride, 0.2; distilled water, 100; for more profound effect cocaine, 0.1; morphine hydrochloride, 0.025; sodium chloride, 0.2; distilled water, 100. These solutions are practically harmless in quantities sufficient to produce anesthesia. The objection to infiltration anesthesia is principally the distortion of tissues which the entrance of the fluids occasions; this is

[1] International Clinics, 1895, ii, fifth series.

obviated to some extent by gently massaging the tissues after the fluid is injected. The addition of adrenalin must be made with caution. Sloughing of the skin and underlying tissues has been reported.

A solution after the following formula is much used in Europe:

℞—Novocain	0.10 gm.
Adrenalin sol. (1 to 1000)	7.00 gtt.
Sodii chlor.	0.045 gm.
Water (distilled and sterilized)	5.000 gm.

A 1 per cent. solution is made by adding 5 gm. of sterile normal saline solution;[1] 2 or 3 c.c. may be injected.

OPERATIONS ON THE LIDS.

Chalazion.—Excision is, on the whole, the most satisfactory method of treatment. Infiltration anesthesia is employed. The chalazion may be opened from the conjunctival surface and the contents of the sac thoroughly curetted away. If the walls are thin, healing with scarcely a trace will take place, but, if the walls are thick, more or less deformity will remain. In removing chalazia a special chalazion forceps, Desmarre's lid clamp, or Knapp's modification of Desmarre's clamp may be employed.

Fig. 363



Chalazion forceps.

Operation.—An incision is made with a small scalpel through the skin and orbicularis palpebrarum muscle parallel to the margin of the lid down to the capsule of the tumor. The tumor is then carefully dissected out. It can often be removed entire without perforating the tarsal conjunctiva. The margins of the wound are approximated and united by one to three silk sutures. A collodion dressing will suffice. If the growth is to be removed from the conjunctival surface the plate of the clamp is placed on the skin surface, and the lid is everted. The sac is opened by an incision parallel to the margin of the lid. The wall of the sac is subsequently dissected out. (This is the operation preferred for chalazia of the lower lid.) The cavity fills with blood-clot, which absorbs in a few days.

Ptosis.—As a rule, general anesthesia is required. The operation selected should depend on certain conditions. If the levator of the lid

[1] Made by Lucius and Brüning, Hoechst am-Main, Germany, and sold in sealed glass capsules, each containing 5 c.c. of the solution.

still possesses some power of contraction, we may strive to increase its influence on the lid by advancing or shortening its tendon.

Everbusch's Operation.—*Instruments.*—Knapp lid clamp, or horn spoon, scalpel, forceps, needles, and needle holder.

A horizontal incision is made through the tissues of the lid down to the fascia, about midway between the margin of the lid and the margin of the orbit. A dissection is made to expose the tendon of the levator palpebræ superioris muscle, which is here blended with the fascia and the tarsus. A suture of silk is looped through the tendon as high as possible; each end is brought down between orbicularis and tarsus and brought out on the intermarginal space; three such sutures are inserted. Traction on the ends of the sutures will produce folding of the tendon on the anterior surface of the tarsus, effecting the desired shortening. The sutures are now tied, and the opening of the skin of the lid closed with sutures.

Fig. 364

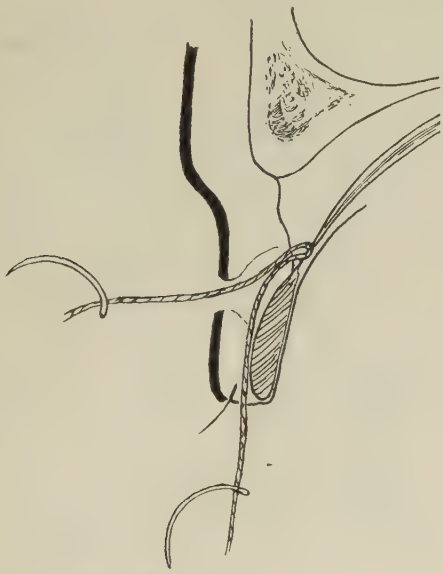

Everbusch's operation for ptosis.

Fig. 365

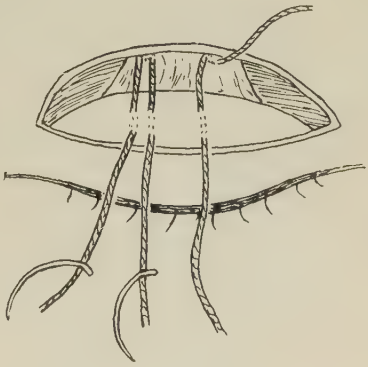

De Lapersonne's operation.

Wolff's Operation.—An incision is made along the upper border of the tarsus down to the fascia, and the tissues dissected up to expose the tendon of the levator. At the lateral margins of the levator palpebræ superioris vertical incisions are made. Two strabismus hooks are now inserted behind the tendon, one being passed down close to the insertion into the tarsus, and one carried up sufficiently high to include the portion of the tendon to be excised between the shanks of the two hooks. Two catgut sutures are now looped through the tendon just below the upper hook. A transverse section of the tendon below the sutures, of sufficient width, is now excised. Both ends of each suture are now carried behind the stump of the tendon of the tarsus and brought out on its anterior surface

and tied. The piece of tendon excised must be as wide as the difference between the position of the lid before operation and the position desired.

Operation of de Lapersonne.[1]—The upper margin of the tarsus and the insertion of the tendon of the levator palpebræ superioris muscle are exposed. A vertical incision is made at each margin of the tendon down to the conjunctiva, and the tendon raised on a strabismus hook. Sutures (catgut) are passed as shown in Fig. 365. An incision is then made through the tendon just above the insertion in the tarsus. If necessary a piece of the tendon is excised. The sutures are then tied, reattaching the tendon to the upper anterior surface of the tarsus. If the skin of the lid is redundant a narrow strip is excised. The lid wound is then united by fine sutures.

In cases where the action of the levator palpebræ superioris is nil, operation has for its object (*a*) the shortening of the attachment of the tarsus to the occipitofrontalis muscle, or (*b*) the shortening of the lid itself, (*c*) the aid of the superior rectus in raising the eyelid.

Dransart's Method.—Dransart first advocated connecting the tarsus with the occipitofrontalis muscle by means of cicatricial bands. After making a horizontal incision through the tissues of the lid and exposing the upper border of the tarsus he passed three double catgut sutures, 6 to 8 mm. apart, through the upper border of the tarsus and tendon of the levator muscle, causing the sutures to emerge above the eyebrow. The ends of the sutures were knotted and were left buried in the tissues.

Fig. 366



De Wecker's operation for ptosis.

De Wecker's Method.—The method of De Wecker is satisfactory in mild cases. It requires some time to reach the desired result, and some pain is occasioned. He excises a band of muscle and sometimes a narrow strip of skin, the incision being 5 mm. above the margin of the lid and parallel to it. Two double-armed sutures are employed. The ends of each suture are passed through skin and muscle at the lower margin of the wound, forming a loop on the surface of the skin, 4 to 6 mm. long. The ends of the suture are now carried beneath skin and muscle and caused to emerge above the brow at the same distance apart, and tied over a roll of

[1] Arch. d'ophtalmologie, August, 1903.

gauze or kid. The sutures are tightened from day to day and are permitted to suppurate out, leaving a cicatricial band and a natural fold in the lid.

Panas' Operation.—*Instruments.*—Scalpel, dissecting forceps, horn spatula, scissors, squint hook, artery forceps, needles, and needle holder.

General anesthesia is employed. The eyebrow should be shaved. A horizontal incision 2 cm. long is made through the skin to the septum orbitale, just below the margin of the orbit. A second incision is made down to the periosteum, parallel to the first and just at the upper border of the brow. These incisions are connected by passing a knife from one to the other beneath the skin of the brow, undermining the brow. Two vertical incisions, beginning 2 or 3 mm. from each angle of the lower

Fig. 367

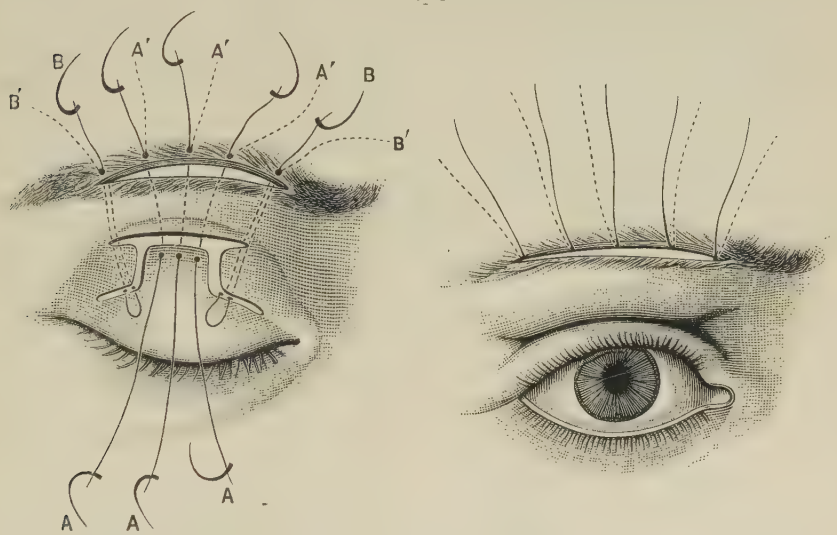

Panas' operation. A, A', central sutures; B, B', lateral sutures. Panas' operation (after).

horizontal incision, are carried down 2 or 3 mm. below the upper margin of the tarsus. The inner vertical incision is terminated by a short curved incision, which ends near the lachrymal punctum; the outer vertical incision, by a curved incision which terminates near the outer canthus The flap included between the vertical incisions, consisting of skin and orbicularis palpebrarum muscle, is dissected up far enough to expose the upper half of the tarsus. Three sutures are passed through the upper border of the flap. The flap is drawn beneath the bridge of tissue, the brow, and its border is fastened to the skin of the upper margin of the incision above the brow. To prevent ectropion two lateral sutures are placed, commencing at the lower margin of the lateral incisions, passing beneath the skin so as to include the septum orbitale and the conjunctiva just above the tarsus, and emerging through the integument at the upper

border of the lower horizontal incision at its extremities. The degree of the effect produced can be regulated somewhat by the traction on the flap.

The stitches may be removed in five to seven days. The pocket left beneath the bridge of tissue gradually disappears.

Gillet de Grandmont's Operation.—The operation devised by Gillet de Grandmont has for its object the shortening of the lid by excising a portion of the tarsus and tarsal conjunctiva.

The lid is held on a horn spoon or in a Snellen clamp. An incision is made parallel to the margin of the lid and 3 or 4 mm. above it, reaching a little beyond and down to the tarsus. The subcutaneous tissue is dissected away, exposing the tarsus. An incision, parallel to the margin of the tarsus and 2 or 3 mm. above the margin, is made through the tarsus and conjunctiva to the horn plate. A curved incision is now made, extending from one extremity to the other of the first incision, through the tarsus and conjunctiva, the height of the incision depending on the effect desired, usually about 3 mm. The semilunar piece of cartilage with conjunctiva attached is removed, and the defect in the tarsus closed by means of catgut sutures. The superficial wound is closed by silk sutures. Emil Gruening has modified this procedure by removing a quadrilateral section of tarsus and conjunctiva, and by bringing the edges of the tarsus together by means of silk sutures, which are looped through the epitarsal tissue at the upper margin of the tarsus, passed between tarsus and orbicularis in the lower part of the lid, and tied on the intermarginal space. Three or four sutures are inserted. The wound through the skin is sutured or not, as the surgeon fancies.

Fig. 368

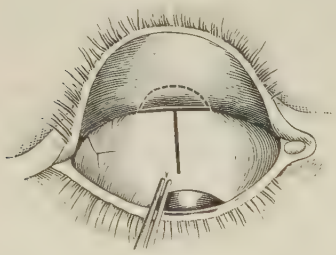

Motais' operation. The T indicates the incision in the ocular conjunctiva; the arc in dotted line, the resection of the tarsus. (Morax.)

Fig. 369

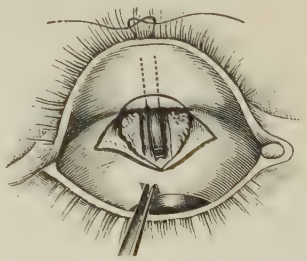

Liberation of the tongue of the superior rectus. (Morax).

Motais' Operation.[1]—The eyeball is rotated sharply downward and retained in that position by means of a "guy" suture or fixation forceps. The upper lid is retracted. The insertion of the superior rectus muscle is exposed and raised on a strabismus hook. By means of a curved needle a suture is passed through the tendon of the superior rectus so as to secure the middle third of the tendon on a loop (Fig. 369). A tongue

[1] Bull. de l'Acad. de Méd., Paris, March 24, 1903.

of the tendon and muscle, including the middle third, is then dissected up, the end at the insertion of the tongue being freed. An incision is now made at the middle of the upper border of the tarsus, through conjunctiva and the tissues attached to the margin of the tarsus, long enough to admit of the free passage of the prepared tongue of muscle. By continuing the dissection between the tarsus and the overlying tissues, a canal extending about two-thirds the width of the tarsus is formed. The ends of the sutures are passed into this canal and are caused to emerge on the cutaneous surface 2 or 3 mm. above the margin of the lid, 4 mm. apart; they are tied over a roll of gauze or rubber tube, drawing the end of the tongue of tendon and muscle to the upper margin of the tarsus, where it becomes united. Diplopia from depression of the globe frequently follows, but is said to disappear within a few weeks.

Fig. 370

Rotation of the tongue of muscle from the superior rectus to the lid. (Morax.)

Entropion of the lid may occur as a result of the traction on the tarsus (A. Knapp), necessitating abandonment of the operation.

Operations for Entropion.—When spastic entropion cannot be satisfactorily controlled by treatment as indicated on page 188, surgical measures must be resorted to.

Gaillard's Suture Operation.—This procedure is based on the fact that the taking up of a horizontal fold of skin causes the entropion to disappear. The needle of a double-armed suture is passed beneath the skin from above downward, beginning at the junction of the inner with the middle third, just below the cilia and emerging on the cheek about 14 mm. below the point of entrance. The second needle should be passed parallel to the first at a distance of 2 or 3 mm. A similar suture is passed at the union of the outer with the middle third. Each suture is tied over a small roll of gauze; both are made sufficiently tight to cause the required eversion. The sutures are permitted to remain in position until cicatricial bands form along the line of the sutures. The favorable results are permanent in the milder cases.

Morax suggests creating cicatricial cords by passing fine platinum wire subcutaneously, after the manner of the sutures of Gaillard or Snellen, and creating an eschar by the electric current. In two or three weeks the desired cicatricial cord will be established.

Operation for Removal of Redundant Tissue in the Lower Lid in Spastic Entropion.—Permanent correction of entropion may be effected by the excision of the redundant skin and subcutaneous tissue of the lower lid.

Infiltration anesthesia is used. An incision is made 3 mm. below and parallel to the margin of the lid, extending from the punctum almost to the outer commissure. This incision is made with a scalpel, the lid having been made tense over a horn spoon. A curved incision is now made, connecting with the extremities of the first incision, including as much integument below the first incision as is thought desirable. The second incision can best be made with the scissors. The subcutaneous tissue and underlying fibers of the orbicularis muscle may be excised at the same time. The margins of the wound are approximated by means of fine silk sutures. Three sutures are then passed through the margin of the lid from above downward, beginning on the intermarginal space (see Fig. 372) and emerging on the cutaneous surface 2 mm. below, one suture in

Fig. 371

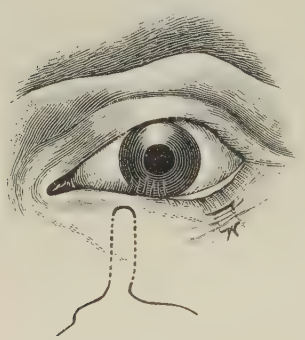

Gaillard's sutures. Anterior aspect. (Morax.)

Fig. 372

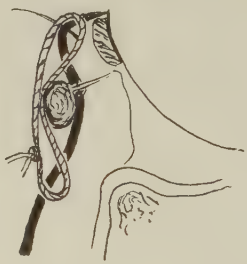

Operation for spastic entropion.

the middle of the lid and one on each side of the middle about half-way to the canthi. Each suture is then passed into the skin of the cheek about 4 mm. directly below its point of first emergence, again emerging 2 mm. farther down. A small roll (3 mm. in diameter) of iodoform gauze is passed beneath the sutures and the ends of the sutures are tied, causing marked ectropion of the margin of the lower lid.

Dressing.—Sterile vaseline, rubber tissue, iodoform or plain sterile gauze, and a bandage. The stitches are removed at the end of six or seven days. Permanent relief is obtained. Other operations are advocated, but they do not give uniformly good results.[1]

Operation for Distichiasis, Trichiasis, and Cicatricial Entropion.—Instruments required: Small scalpels, mouse-tooth forceps, curved scissors, needles, and needle holder; Jaeger's horn plate or Knapp's modification of Desmarres' lid clamp.

[1] For the operation of Goldzieher, see Klin. Monatsbl. f. Augenheilk., October, 1908.

Removal of Hair Bulbs.—Infiltration anesthesia is employed. An incision is made along the intermarginal space just below the upper surface of the tarsus. The tarsal plate is split near its upper surface deep enough to pass beyond the hair bulbs (3.5 mm) and long enough to include all misplaced hairs, care being observed to have all the bulbs in the skin flap. In making this incision, the lid may be grasped between the thumb and forefinger or a horn plate may be passed under the lid and firmly held by an assistant. By placing the index finger of the left hand on the upper lid, the margin of the lid may be slightly turned outward, rendering it

Fig. 373

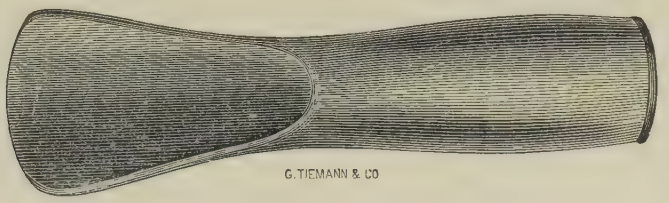

Jaeger's plate lid-holder.

more accessible. An incision in the intermarginal space parallel to the first, placed sufficiently near the outer angle of the margin of the lid to include the follicles of the hairs to be removed, is made. The incisions are joined at the ends and the strip of tissue removed. If it is thought desirable to maintain the width of the edge of the lid, a wedge-shaped piece of mucous membrane from the lip, or of skin from behind the ear, may be placed in the gaping incision. The bleeding is somewhat annoying. If the lid clamp is employed the incision can be made without hemorrhage, but the lid margin is not quite so accessible.

Fig. 374

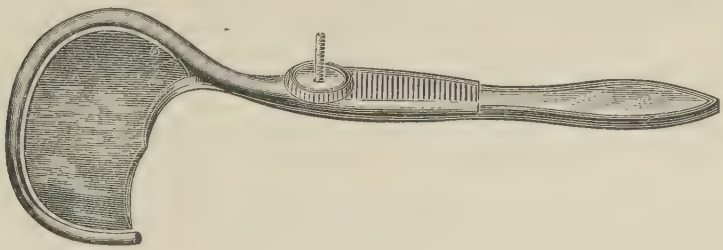

Knapp's modification of Desmarres' lid clamp.

Electrolysis.—This is sufficient in some cases, serving to destroy the hair bulbs and preventing a return of the cilia. A fine broach or sewing needle, attached to the negative pole of a galvanic battery, is inserted along the shaft of the hair to the bulb. A moistened sponge electrode, attached to the positive pole of the battery, is grasped in the hand and the current, of the strength of 2 to 4 milliampères, is turned on. A white

foam is immediately seen to escape at the shaft of the needle. After fifteen to twenty seconds the current is interrupted. The hair will now come out easily if the hair bulb has been reached; it will have been destroyed and the hair will not grow again. Only about 20 per cent. of the hair bulbs are reached at any one sitting, consequently repeated sittings are required to promote a cure. The process is painful, but it may be rendered less so by infiltration anesthesia. If many cilia are to be removed, ether anesthesia is desirable.

Reconstruction of the Lid Margin.—This operation is applicable to cases of cicatricial entropion of the lower lid, to the greater number of cases of distichiasis and trichiasis, and to the milder forms of cicatricial entropion of the upper lid.

General or infiltration anesthesia is employed. The intermarginal incision is made as described on page 787 for the first incision, is carried deep enough to permit a gaping of 2 mm., and is made long enough to effect the desired result. A wedge-shaped piece of skin or mucous membrane, of suitable size to fill the gap, is detached and placed in position, after the removal of the clamp and cessation of the bleeding. Ordinarily no suture is required. After the graft is in position, some sterilized vaseline is applied and the eye bandaged in the ordinary way. Sloughing of the flap rarely occurs.

Regarding the strip to be transplanted: If mucous membrane is desired it may be obtained from the lip. A strip of skin may be obtained from the *upper lid* if the skin is superabundant, or, better still, from the hairless skin at the back of the ear. A Graefe knife is an excellent instrument to use in removing the flap, cutting from heel to point, employing a long portion of the cutting edge. If the lip is chosen, a lid clamp may be used as a hemostat.

Resection of Tarsus.—This operation is of service in trichiasis and mild cases of cicatricial entropion due to trachoma.

Operation.—General or infiltration anesthesia is used The operation may be combined with canthoplasty in cases in which the palpebral fissure is shortened. The upper lid is everted and the anesthetic fluid injected beneath the conjunctiva, entering the needle near the outer extremity of the tarsus. Approximately 2 c.c. of fluid is injected. This should throw the conjunctiva of the retrotarsal fold and fornix into view. An incision is made through the tarsal conjunctiva about 3 mm. back of the margin of the lid and parallel to it, extending the entire length of the tarsus. The conjunctiva is now dissected free from the tarsus above the incision and the dissection carried well into the fornix. This exposes the posterior surface of the tarsus above the incision; also the upper border of the tarsus. The tissues attached to the upper border of the tarsus are divided, the upper margin of the tarsus seized with forceps and drawn forward. The anterior surface of the tarsus is freed from the overlying tissues almost to the lid margin. All of the tarsus but a strip 2 or 3 mm. wide at its lower margin is now excised, either with the knife or scissors. Three double-armed silk sutures are passed through the margin of the conjunctival flap at equal distance apart, forming loops on the conjunctival

surface 2 to 3 mm. long. The sutures are carried through the tissue of the lid just back of the cut margin of the remaining strip of tarsus at points corresponding to the position of the sutures in the conjunctiva and are tied on the cutaneous surface, usually over small rolls of sterile gauze, without much tension. A bandage is then applied.

This operation is said to correct trichiasis and mild entropion. It slightly shortens the retrotarsal fold. Blaskowitz (Budapest) excises a narrow strip of conjunctiva containing trachomatous tissue at the same time, if such tissue is present.

Hotz's Operation.—The principle on which this operation is based, namely, the permanent attachment of the upper border of the skin flap containing the cilia to a fixed point with traction, the fixed point being the curved upper margin of the tarsus, was first advocated by Anagnostakis.[1] Modern ophthalmology is indebted to Hotz, of Chicago, for bringing it into prominence at the present time. Hotz, by his own independent investigation, was led to adopt and to advocate the procedure.

Fig. 375

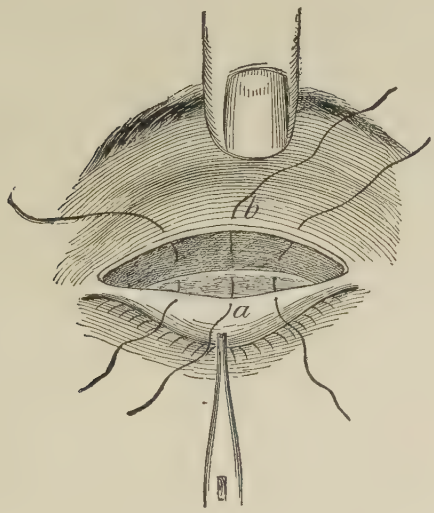

Fig. 376

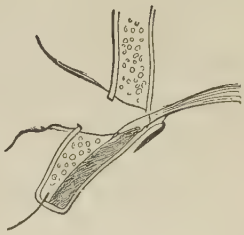

Operation of Anagnostakis and Hotz. (De Schweinitz and Randall.)

General or infiltration anesthesia is employed. An incision is made through the skin of the upper lid and underlying tissues to the tarsus, corresponding with or slightly below the upper border of the tarsus, and parallel with it, along its entire length in severe cases. This forms a curved incision, the lid flap being about 2 mm. wide at each end and 6 to 8 mm. wide in the centre. The upper border of the tarsus is exposed by dissecting out a narrow strip of muscle fibers and subcutaneous tissue. Three silk sutures are then passed; each including the skin at each margin of the wound and the tissue of the upper border of

[1] Annal. d'oculistique, 1857.

the tarsus. This procedure unites the skin of the lid flap to the upper border of the tarsus, making the skin slightly tense and producing sufficient eversion of the eyelashes in mild cases. The sutures are removed in six or eight days. Hotz augments the effect of the operation in severe cases by reconstructing the margin of the lid after the manner described on page 788.

Hotz's operation may be employed on the lower lid, but on account of the narrowness of the tarsus the sutures must be passed through the tarso-orbital fascia.

There is a class of cases in which the tarsus is much thickened and much curved, in which the result may be more advantageously secured by grooving the tarsus after the manner of Snellen.

Snellen's Operation.—The principle involved in this operation is the straightening of the tarsus. It also apparently accomplishes, incidentally, the attachment of the flap bearing the cilia, to a fixed point—the upper border of the tarsus.

General anesthesia is employed. The lid clamp is put into position and an incision is made through skin and subcutaneous tissue to the tarsus, parallel to the margin of the lid and 3 mm. above it. A strip of

Fig. 377

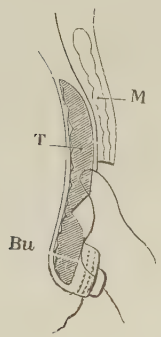

Diagrammatic section of upper lid; showing Snellen's operation, and line of section in Burow's operation (*Bu*). (Altered from De Wecker.)

Fig. 378

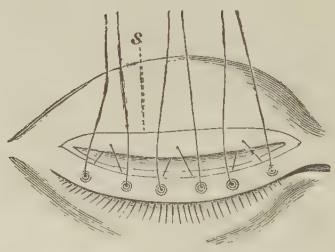

Snellen's operation for trichiasis: *s*, edge of retracted skin and muscle. (After De Wecker.)

subcutaneous tissue is now excised, including a strip of the orbicularis palpebrarum muscle, exposing the middle zone of the tarsus throughout its entire length. A wedge-shaped strip —its base being at the outer, its apex at the inner surface, extending the whole length of the tarsus — is now removed. In excising the strip of tarsus, a very sharp knife is necessary. A small scalpel, a Graefe knife, or a Beer cataract knife are suitable.

Wilder has devised a double knife for this purpose, which may be employed.

One of the needles of a double-armed suture is now passed through the

tissues covering the upper margin of the tarsus from above downward; continuing, the needle is passed between skin and tarsus, emerging at the root of the lashes. The second needle is passed in the same manner, parallel to the first and about 2 mm. from it. This forms a loop which lies on the upper margin of the tarsus, on the anterior surface. The suture is tied over a glass bead. The ends of the suture are carried upward to the brow and held by a strip of adhesive plaster, traction sufficient to strongly turn the lashes out being made. The incision through the skin is not sutured. The margins of the wound are thrown into apposition by the manner of inserting and securing the sutures.

Fig. 379

Wilder's entropion knife.

Spencer Watson's Operation.—An operation has been devised by Spencer Watson, which consists in transplanting a strip of skin with a pedicle into the intermarginal space, reconstructing the margin of the lid. It is of service when the entropion is partial, and when it affects the lower lid.

An incision is made in the intermarginal space and a second incision, parallel to it, is made through the skin of the lid just above the hair bulbs. These incisions are brought together at one end, and the flap containing the hair bulbs is separated, leaving an attachment at the end near the outer commissure. An incision is now made through the skin of the lid, above the second incision, in such a manner that a flap may be formed, the base of which will correspond to the apex of the flap containing the cilia. The skin flap is then made to occupy the space below the flap containing the cilia, and the flap containing the cilia is placed in the upper defect.

Fig. 380

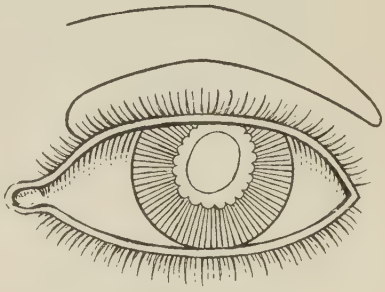

Spencer Watson's operation.

Other Operations.—Operations have been devised by De Wecker, Warlomont, Panas, Diamont, Green, and others, but they possess no special advantage. The operator must choose the operation best suited to the individual case.

Canthotomy and Canthoplasty.—In cases in which it is desirable to temporarily enlarge the palpebral fissure, as in blepharospasm if it leads to spastic entropion; in purulent conjunctivitis, in diphtheritic conjunctivitis, and in some cases of acute trachoma, if the swelling of the lid is such that the pressure endangers the nutrition of the cornea, *canthotomy* is resorted to.

Not infrequently the disease that produces the cicatricial entropion also causes a marked shortening of the palpebral fissure, and it becomes advisable to lengthen the palpebral fissure in order to secure a satisfactory result. This is accomplished by performing the operation of *canthoplasty*. It is also found in these cases that the malformation and shortening of the tarsus and the inflammatory process that has produced this malformation have caused an increase in the tension of the tarsoörbital ligaments, so that the margins of the lids are abnormally tense. In performing canthoplasty in these cases it is advisable to divide the external tarsoörbital ligament.

Operation.—The lids are forcibly opened; one blade of a strong pair of scissors is passed into the conjunctival sac at the outer canthus and carried well to the margin of the orbit in the horizontal plane. The entire tissue included between the blades of the scissors is cut through (the incision is apt to be longer on the mucous than on the cutaneous surface—this must be guarded against). If the lids are still tense, the tarsoörbital ligament is then divided. (The procedure is facilitated by using an eye speculum at this stage.) This is done by dissecting up the conjunctiva and the skin above the apex of the gaping wound, and dividing the dense fibrous tissue that is now exposed, extending from the tarsi to the margin of the orbit. To divide the band connected with the upper tarsus, the blades of the scissors must be directed upward and outward; to divide the band connected with the lower tarsus, the blades must be directed downward and outward. For canthotomy, no sutures are required. The wound eventually closes, leaving the palpebral fissure of the same length as before the operation. If a permanent lengthening of the palpebral fissure is desired, *canthoplasty* should be performed. The steps in this operation are the same as in canthotomy, including the division of the tarsoörbital ligament. Three sutures are then employed to unite the conjunctiva and the skin to close the wound; one suture is placed at the extremity of the incision through

Fig. 381

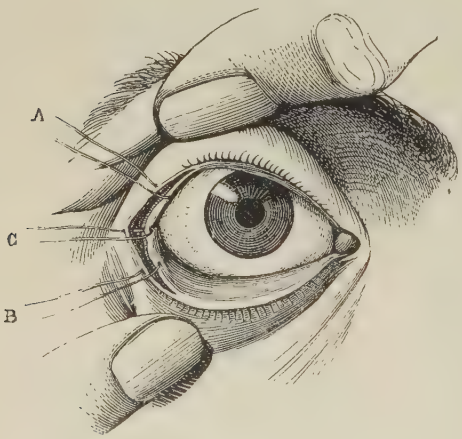

Canthoplasty. *A*, *C*, *B*, sutures. (De Wecker.)

conjunctiva and skin, one above and one below. As a rule, the conjunctiva must be undermined to some extent before the sutures are applied. The sutures should be removed at the end of five to seven days.

Operation for Ectropion.—Paralytic and senile ectropion may be remedied by tarsorrhaphy in some cases, but shortening of the margin of the lid is frequently required to give a satisfactory result.

Tarsorrhaphy.—This consists in uniting the margins of the lids. The operation may be performed at either canthus. Affecting the inner canthus it is known as *median tarsorrhaphy*, the outer canthus as *lateral tarsorrhaphy*.

Lateral Tarsorrhaphy.—Infiltration anesthesia. Fuchs operates as follows: The extent of the desired union is marked out, then an intermarginal incision is made in the lower lid, beginning at the outer canthus and extending medially to the distance of the desired union. A vertical incision is now made through the skin of the lid, uniting with the medial extremity of the intermarginal incision. This produces a flap on the

Fig. 382

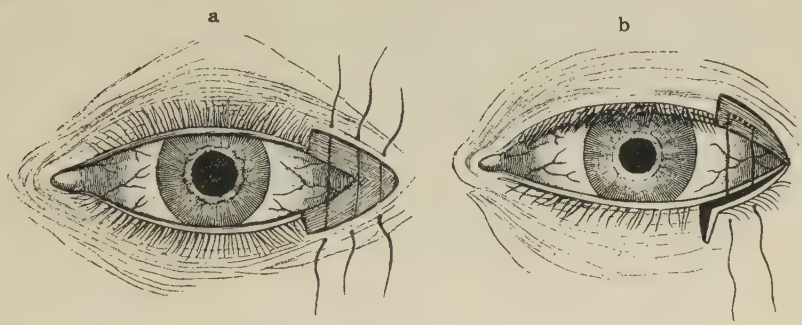

Tarsorrhaphy: *a*, von Graefe's; *b*, Fuchs'. (Haab.)

lower lid, which bears the cilia. The bulbs of the cilia are then destroyed, usually excised. The upper lid is split in a similar manner, the flap containing the cilia being entirely removed. A double-armed suture is employed to bring the denuded surface of the upper lid into contact with the flap of the lower lid. The needles are entered from the conjunctival surface near the margin of the upper lid and emerge near the middle of the denuded surface, a few millimeters apart, so as to form a horizontal loop on the conjunctival surface. They are then carried through the base of the groove on the lower lid and, after drawing the raw surfaces into apposition, are tied over a glass bead or roll of gauze. The external margins of the wound are then united by fine sutures. This procedure gives strong union. The operation of simply denuding the margin of the lid and bringing the narrow denuded surfaces together by sutures is ordinarily successful, but does not give a very strong union.

Median Tarsorrhaphy.—Arlt[1] operated by denuding a narrow surface, beginning at the puncta and extending around the inner angle. The

[1] Graefe-Saemisch, Handbuch, iii, p. 446.

raw surfaces were brought into apposition by means of sutures. Noyes[1] operated by dissecting up a parallelogram of skin above and below the canaliculi, and uniting the raw surfaces by sutures. By these operations the canaliculi are turned into the lachrymal lake.

Shortening the Lid Margin.—Infiltration anesthesia is employed. This may be done by excising a V-shaped piece from the lower lid, extending through the entire thickness of the lid. The margins of the defect are carefully sutured together. It sometimes occurs that union is not satisfactory, and a notch in the lid border results. If the excision is made near the outer canthus the danger of this result is avoided to a great degree.

Kuhnt-Meller Operation.—A satisfactory operation, known as the Kuhnt-Meller operation, is performed as follows: A deep, intermarginal incision is made in the lower lid, beginning in the centre and extending well toward the outer and inner canthi. This incision should leave the skin and orbicularis in the outer half. A triangular portion of sufficient width at the base to shorten the lid margin just enough is now excised from the inner conjunctival half of the split lid, midway between the inner and outer canthi, the apex of the wedge reaching just below the tarsus (Fig. 383).

Fig. 383

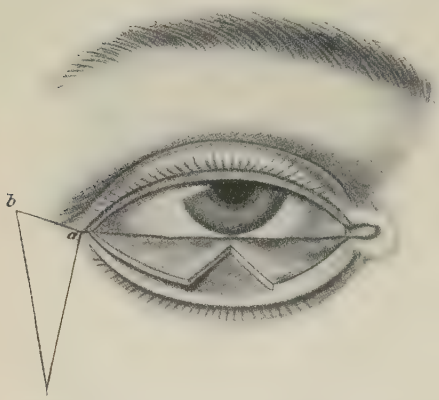

The measured part of the tarsus has been excised. The triangle is drawn in the region from which the skin is to be excised. (Meller.)

The excess of skin is removed by excising a triangular flap of skin at the outer canthus. This is effected by first making an incision through the skin extending from the outer commissure outward and a little upward, the length of the incision being about the length of the base of the tarsal flap excised. The second incision is carried vertically downward from the end of the outer commissure about twice as long as the first. The extremities of these two incisions are united by a third and the skin so isolated is dissected out. The skin of the lid is now undermined so that it will slip into the defect, the cilia are removed for a sufficient distance, and the margins of the lid flap are sutured to the margins of the defect (Fig. 384). A pressure bandage is applied.

The Correction of Ectropion Resulting from Formation of Cicatricial Bands, as after Periostitis or Caries of Margin of Orbit.—**Operation.**—The lid and adjacent integument are separated from the periosteum by thoroughly dividing the cicatricial tissue as nearly subcutane-

[1] Text-book of Ophthal., 1894, p. 284.

ously as possible, or by dissecting out the cicatricial bands so that the lid and skin are freely movable. The margin of the lid, if too long, is shortened. The margins of the lids are freshened at corresponding opposing points, and are united by means of sutures. The ends of the sutures should be left long and should be fastened to the cheek if the operation affects the upper lid, to the brow if the operation affects the lower lid. The sutures should be left in position seven to nine days. The margins of the lids should not be separated under six weeks or two months. If any considerable defect exists at the point of the attachment of the cicatricial tissue to lid or skin of facet his defect should be filled by some suitable plastic operative procedure.

Fig. 384

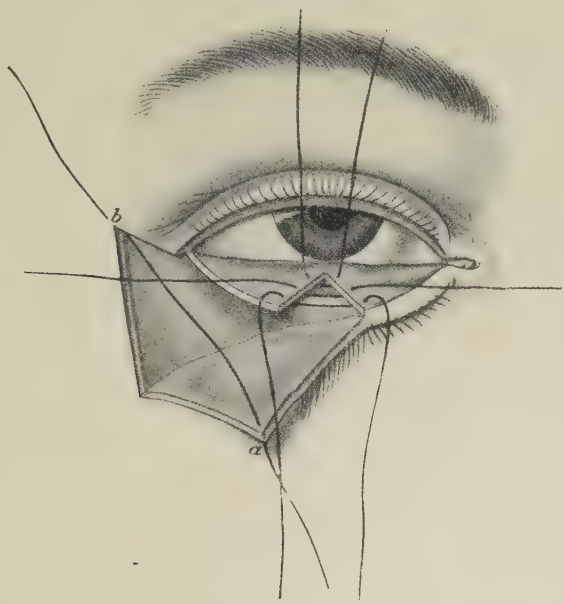

The triangular piece of skin is excised, the skin of the lid undermined and turned outward. The three sutures through the tarsus lie in their proper position. The principal fixation suture of the flap (*a b*) is likewise drawn through. The cilia are excised from the corresponding part. (Meller.)

Verderame's Method.—Verderame[1] operates by making an incision through the normal skin near the cicatrix, freeing the skin from the periosteum by freely undermining it, using scissors. A mass of fat is then dissected from the abdominal wall sufficient to occupy the site of the cicatrix and to elevate the skin slightly above the surrounding healthy surface. The fat is put in place by means of a spatula and the wound closed (Bandage). The result is a correction of the deformity with movable integument over the cicatrix.

Correction of Cicatricial Ectropion of Lower Lid.—This requires, first, that the margin of the lid, which has been stretched and elongated

[1] Klin. Monatsbl. f. Augenheil., October, 1909.

shall be reduced to the proper length; second, that all tendency to drag the margin of the lid downward shall be obviated by supplying enough tissue to maintain the lid in proper position for a length of time sufficient to permit of the establishment of a desirable condition that will be permanent.

Flaps with a pedicle shrink somewhat less and are a little less apt to slough than flaps without a pedicle. The degree of shrinkage depends to some extent on the firmness of the margins of the wound to which the margins of the transplanted flap are attached. It may be stated that, as a rule, the flap with a pedicle shrinks to one-fourth of its original area, and the flap without a pedicle (Wolffe flap) to one-fifth of the original area. The shrinking of the Thiersch graft depends much on the character of the tissue on which it is placed, and not to a great degree on the flap itself. It supplies only a little more than an epithelial covering which, if the cicatricial tissue that forms beneath it does not shrink to a great extent, gives a fair gain in area, averaging, perhaps, one-fourth of the original defect

Flaps with a pedicle must be removed from a portion of the face that will cause traction, as healing advances, as nearly in the direction of the horizontal axis of the palpebral fissure as possible, in order to avoid inability to close the lid and subsequent ectropion. The flap should come from the temple or forehead, or from the upper lid in cases where the skin in this part is superabundant. Flaps should not be taken from the cheek, as a rule. The flap should contain the subcutaneous tissue, and its nutrition should be interfered with as little as possible.

The pedicle should be broad and so situated that the twisting of the flap will twist the pedicle as little as possible. The flap is then dissected up freely and turned into the defect. The margins of the flap are stitched to the margins of the defect to be covered. The defect occasioned by the removal of the flap may be closed almost, if not quite, completely by undermining the edges, sliding them together, and suturing them. The pucker at the lower margin of the pedicle frequently disappears as healing progresses; should it remain after healing is complete the prominent portion may be excised. If there is no irritation or evidence of the formation of a purulent secretion the bandage should not be disturbed under three or four days. The stitches may be removed from the flap in six days, from the original site of the flap and from the margins of the lid in seven to nine days. The union between the margins of the lids should be maintained two or three months. In cases where the flap takes tardily the epithelium becomes gray and gradually peels off, leaving a somewhat irregular, red surface, which soon becomes again covered with epithelium.

The scars that result from removing flaps from the face are disfiguring and unsatisfactory from a cosmetic point of view. Flaps without a pedicle can be employed to much better advantage in nearly all of the plastic operations about the lids. Furthermore, if loss from sloughing of the flap occurs, it is of much more consequence if the flap is from the face than if from some part of the body not exposed to view.

Restoration of Lids by Means of Flaps without a Pedicle.—(*Wolffe's Flap.*)—General or infiltration anesthesia is employed. The lid is dissected from the underlying tissue, being careful to detach the border of the lid and to dissect all palpebral fibers of the orbicularis palpebrarum muscle away with the lid. The orbital fibers of this muscle should be left where they belong. The dissection should be extended until the lid has been freed to the normal extent. If both lids are in a state of ectropion, the upper lid should be operated on first. After the upper lid is freed, it is drawn downward as far as possible without undue stretching and anchored to the tissue of the cheek by means of three or four fairly thick sutures which pass through the margin of the lid and the tissues of the cheek. The upper will overlap the lower lid by about one-half inch. This is for the purpose of making the denuded area, to receive the flap, as large as possible to compensate for subsequent shrinkage. The surface is freed from tags of tissue and rendered as smooth as possible. Dense cicatricial tissue may be dissected out. The surface may now be covered with gauze dipped in warm normal saline solution.

Lower Lid.—After it is dissected from the cicatricial tissue the margin is shortened, if necessary, by removing a V-shaped piece near the outer canthus. The margins of the upper and lower lids are freshened in three places, opposite to each other, and stitched together. The ends of the sutures, which are left long, are now secured to the forehead by means of rubber adhesive plaster, making the denuded area as large as possible by traction.

Removal of Flap.—The flap should have an area about one-half larger than the surface to be covered as it is marked out on the surface from which it is to be removed. The size of the flap may be measured, and its boundaries indicated by pricks made with a needle or with the point of a Graefe knife. The punctures bleed slightly, plainly indicating the boundary. With a very sharp, small scalpel, or a cataract knife, an incision barely through the skin, which is rendered slightly tense by an assistant, is carried around the entire flap. The edge of the knife is now directed toward the centre of the flap and the margin of the flap throughout its entire extent is undermined for a distance of two or three millimeters. The subcutaneous tissue is not included in the flap. The edge of the flap is seized with broad fixation forceps and by means of a small, very sharp knife (Beers, Graefe knife, or scalpel), and the skin is separated from the underlying areolar connective tissue. As soon as the flap is dissected away sufficiently it is seized between the thumb and forefinger and the dissection is continued, cutting at the junction of skin and subcutaneous tissue, which can now be quite distinctly seen. The flap is detached as quickly as possible. It is then conveyed to a piece of gauze moistened with warm saline solution, where it is spread out over a tense surface and any remaining subcutaneous tissue cut off by means of scissors. The flap is then conveyed without undue loss of time to the denuded area, where it is stitched in place, the margins of the flap to the margins of the denuded area, and, in case of great unevenness

of surface or of a long flap, by one or two sutures through the flap near its centre, attaching it to the underlying tissue. During the time of its manipulation the flap should be kept moist and warm by means of gauze pads moistened in normal saline solution.

The attachments of the lids to the cheek may be removed as soon as they cease to be of service (six to fourteen days). If the margins of the lids are united, which should be done whenever possible, particularly when operating on the lower lid, the union is not severed under three to four months, depending on the case.

Blepharoplasty.—For restoring a part or the whole of the lid (destroyed by burns, m lignant growths, traumatism, ulceration, etc.) numerous operations have been devised. As every individual case calls for special consideration, only a few types of operation will be described.[1]

Operation for Making an Entire New Lid (Everbusch).—A suitable flap with a pedicle is cut in the location desired, ordinarily at the temple, and the under surface of the flap and the surface from which the flap was removed are covered with Thiersch grafts. A piece of sterile rubber tissue may be placed between the two layers of Thiersch grafts, and a light bandage applied. After both surfaces have healed the skin flap is carried into the defect, the margins of the defect having been freshened to receive the freshened edge of the flap. When the flap is healed in its new position the pedicle is divided.

Knapp's Method of Blepharoplasty.—If the destruction of the margin of the lid is not extensive, this method can be employed with excellent results. The plan of the operation is well illustrated in Fig. 385.

The flaps are dissected free from the underlying tissue and are slid forward to cover the defect. The ends of the flaps are sutured to each other and to the underlying tissue, and the margins of the flaps are sutured in such a manner that the tension on the flaps is relieved as much as possible. The tension on the flaps must not be great; if it is excessive, more or less destruction of tissue will follow.

Dieffenbach's Method.[1]—Dieffenbach's method is sometimes applicable for replacing loss of tissue in the lower lid. Its performance will, however, lead to disappointment unless the defect is very small and wedge-shaped, the base of the wedge being placed at the border of the lid. If the procedure is followed by shrinking of the flap and of cicatricial tissue along the lines of union, much consequent deformity may result.

Landolt's Method.—Landolt's method, which consists in covering a defect in the lower lid by a flap from the upper lid, is applicable in a few cases where the defect to be covered is small and the skin of the upper lid is superabundant. The possibility of shortening the upper lid so that the eye cannot be closed must always be borne in mind.

Operation.—An incision is made through the skin of the upper lid parallel to and about 3 mm. above its margin. A second incision is made parallel to the first and sufficiently separated from it to include

[1] Casper's Wochenschrift, 1835, S. 7.

the width of flap desired. The flap is now detached from the underlying tissue, and is carried over the border of the upper lid and placed over the defect in the lower lid, leaving the ends of the flap attached. It is now sutured into place. After the flap has healed in place the lateral pedicles are severed. The length of time required is ten days to two weeks.

Fig. 385

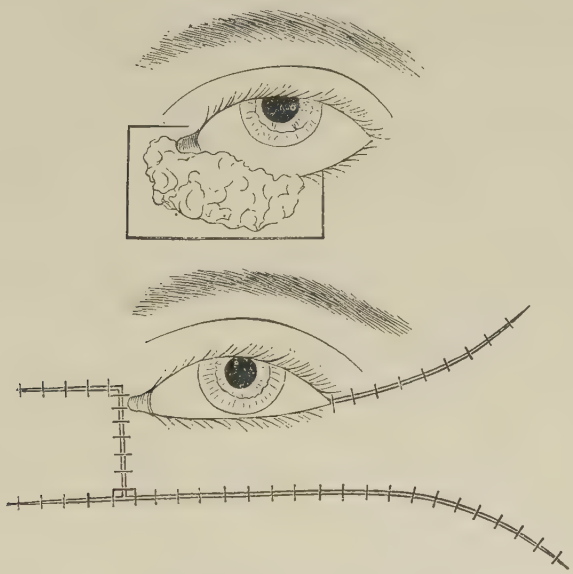

Knapp's method of blepharoplasty.

Operations for Trachoma.—Galezowski, in 1874, advocated the removal of the retrotarsal fold under ether anesthesia. The operation is destructive of conjunctival tissues and should not be resorted to.

The method that has found most favor is that of expression, for which a number of instruments, known as expression forceps, have been devised. In 1889, Prince presented his "ring" forceps for this purpose before the Illinois State Medical Society. Other forceps are those of H. D. Noyes, Knapp, and Gruening. Scarification of the epithelial covering of the granules, before expression is attempted, facilitates the escape of the contents. For this step the Desmarres scarificator or that of the writer may be employed (see Fig. 390). As the operation is painful, ether anesthesia is desirable, but infiltration anesthesia or cocaine may be used.

Operation.—The lids are fully everted by rolling them over lid forceps (Fig. 391) or by seizing the upper margin of the tarsus with forceps and pulling it away from the globe, exposing the retrotarsal fold. The surface is superficially scarified, the shallow incisions being directed parallel to the margin of the lid. The folds of the conjunctiva are now

Fig. 386

Knapp's trachoma forceps.

Fig. 387

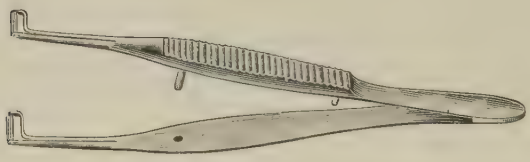

Rust's trachoma forceps.

Fig. 388

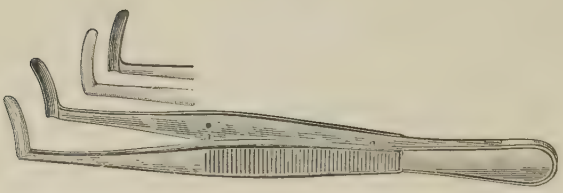

Noyes' trachoma forceps.

Fig. 389



Prince's trachoma forceps.

Fig. 390

Weeks' scarificator.

Fig. 391



Weeks' lid forceps.

seized with the forceps and freed of the trachomatous tissue by a gentle stripping motion. Care must be observed to reach all of the abnormal tissue in the folds at either canthus. Afterward the surface may be bathed with a weak sublimate, boric acid, or normal saline solution, and treated by cold compresses without bandaging, or a bandage may be applied for twenty-four hours. The introduction of an ointment of mercuric chloride in vaseline (1 to 5000) serves to prevent adhesions between the conjunctival surfaces and to exert a mild antiseptic effect.

After Treatment.—Much depends on this. On everting the lids after twenty-four hours a thin pellicle of fibrin will be found covering the tissue operated upon. Folds of conjunctiva that lie in apposition will be found adhered together by the fibrin. Where it occurs on free surfaces the layer of fibrin should not be disturbed; it disappears in a few days, leaving a surface that is covered with epithelium. The adhesions between folds of conjunctiva should be broken up every twenty-four hours. In breaking up adhesions a probe or glass rod may be used, cocaine anesthesia should be employed, and the surface of the conjunctiva should be well lubricated with mercuric chloride vaseline. The tendency to the formation of adhesions continues for a week or ten days. The conjunctival surface should be treated with an antiseptic wash three times daily. If there is some secretion following the operation the nitrate of silver solution, 1 per cent., may be applied once in twenty-four hours. If the surface remains rough, mild applications of the sulphate of copper crystal are of value.

Fig. 392

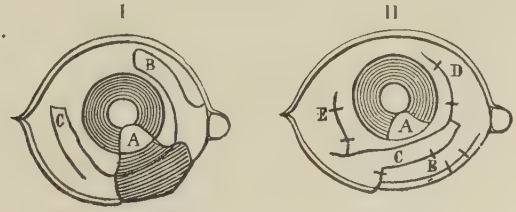

Teale's operation for symblepharon. I. Incision. II. Sutures. (Terson.)

Symblepharon.—If the symblepharon is of the anterior form (see page 256) simple detachment from the globe, followed by breaking up any adhesions that might form from day to day by means of a probe, lubricated with mercuric chloride vaseline (1 to 5000), until the defects are covered by epithelium, will suffice.

In cases of columnar or frenular symblepharon it is sufficient to dissect the eyelid from the eyeball and to cover the defect on the bulbar side either by undermining the ocular conjunctiva and sliding it over the defect, uniting the edges of the conjunctiva by means of sutures, or the device of Teale (Fig. 392) may be resorted to. If the symblepharon extends onto the cornea the portion on the cornea may be permitted to remain. If opposed by normal epithelium the defect on the lid will heal without reattachment to the eyeball. The healing should be watched,

and any tendency toward reëstablishing the symblepharon combated either by wearing a glass or lead shell or by inserting a Thiersch graft. In the correction of posterior or total symblepharon, flaps of skin or mucous membrane or Thiersch grafts must be employed. The conjunctiva of the rabbit has been used for this purpose, but, as is well known, heterogeneous tissues when transplanted to man tend to gradually disappear, apparently by absorption, in spite of early union to the surface, and are therefore unsatisfactory. The first step in all such operations is to dissect the lid from the eyeball, leaving the tissues belonging to each on their respective sides. The groove between globe and lid should be a little deeper than the original depth of the conjunctival sac if the flap is to be held in position by means of a shell. If a skin flap is used it should be thin (from the inner surface of the arm or thigh), and should be free from subcutaneous tissue. It should be one-third larger in area than the area of the defect. Its edges may be stitched to the edges of the defect, and the shell (glass or lead) inserted. If the defect is large, the margins of the eyelids should be stitched together and be allowed to remain united until the flap has "taken." The shell should be worn as long as possible (two to three weeks), to assure a permanent good result. The tendency is to undue shrinkage of the flap and abolition of the new-formed sac. A very good way of introducing the flap is by stretching it over that part of the shell that will bring the flap in proper relation to the defect, then inserting flap and shell at the same time (May). This is particularly advantageous when Thiersch grafts are employed. In regard to the shell, it may be made of glass or of lead; it should be made to conform to the contour of the globe, and should be fenestrated, so as not to cover the cornea. If lead is employed it is very advantageous to coat it with paraffin of a high melting point, as advised by Wilder,[1] in order that the surface may be absolutely smooth. All flaps should be aseptic, and should be kept moist and warm by means of a warm saline solution (0.6 per cent.) during the time of their preparation and manipulation.

If the flap of skin (Wolffe flap) is employed and it is designed to attach it to the periosteum at the margin of the orbit, the groove between globe and lid should be carried to the epiperiosteal tissue at the margin of the orbit and the flap attached as described on page 804.

Restoration of Culs-de-Sac.—For restoring the culs-de-sac in case of their obliteration (contraction of the orbit), with absence of the globe, the so-called Wolffe graft has been very successful in the author's hands. The surface from which the graft is to be taken should supply a suitable quality of skin. This can be obtained from the inner surface of the arm, forearm, or inner surface of the thigh. The surface should be prepared some hours before, so as not to lose time during the operation.

Preparing for Reception of Flap.—To obtain sufficient room to operate readily, the outer canthus may be extended to the margin of the orbit by a free canthotomy; this is not necessary in all cases. The lid

[1] Trans. Oph. Sec. A. M. A., 1906.

should be dissected from the orbital tissue, including with it only the tarsus and orbicularis palpebrarum muscle. If much tissue is dissected away with the lid, the result will be a lid that is too thick. Should there be considerable conjunctiva, the incision through it should be so made that the greater part of the conjunctiva will serve to cover the orbital stump. It is better to leave but a very narrow strip of conjunctiva attached to the margin of the lid. The lid is detached until the groove between lid and orbital tissue extends to the tissue immediately above the periosteum at the margin of the orbit. The groove should extend from the inner canthus to the outer commissure, connecting with the incision which has been made to prolong the palpebral fissure. Cicatricial tissue may require removal but is usually not sufficient in quantity.

After completing the groove, the plate to be employed should be fitted. The plate may be conveniently made of the flexible rubber used by dentists, termed "base-plate gutta-percha." By dipping in hot water, the piece to be used may be made to assume the desired shape, and if, while the shape is maintained the rubber is dipped in cold water, the shape will be fixed. The rubber may be cut any size by means of scissors, and the edge made perfectly smooth by treating it with a hot strabismus hook or similar instrument, having first applied some vaseline or oil to the edge to be so treated. The shell should be made sufficiently large to completely fill the pocket. If there is no pocket in the upper lid in which the upper edge of the shell can be lodged until the time for making an upper cul-de-sac arrives, a shallow groove may be cut in the tissues immediately back of the margin of the upper lid.

Fig. 393

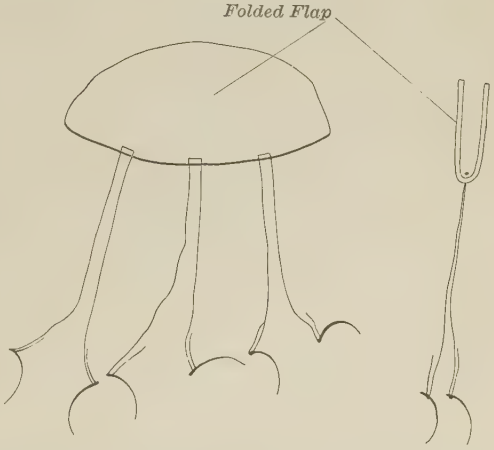

In preparing the upper cul-de-sac the dissection should correspond with the dissection for the lower cul-de-sac, except that before reaching the periosteum the tendon of the levator palpebræ superioris must be cut across.

After having completed the groove, it is packed with pledgets of absorbent cotton moistened with normal saline solution, and the lids are covered with a pad dipped in the saline solution.

The Flap.—The dissection is made as described for the flap to restore the skin of the lid (see page 797). After removal the flap is folded so that the epithelial surfaces are in apposition. Three double-armed sutures are passed through the flap at the bottom of the groove formed between the two layers of the flap, the needles of one suture being so

passed that a loop two millimeters in length falls on the cutaneous surface at the centre of the flap, and one about ten millimeters each side of the centre of the flap (Fig. 393).

Adjustment of Flap.—The flap contained in the moistened gauze is placed on the brow near the wound if the lower lid is being operated upon (on the cheek if the upper lid is being operated upon), and the double sutures (which have been made sufficiently long) are passed through the tissue at the apex of the groove through the periosteal tissue at the margin of the orbit, and are made to emerge on the skin of

Fig 394

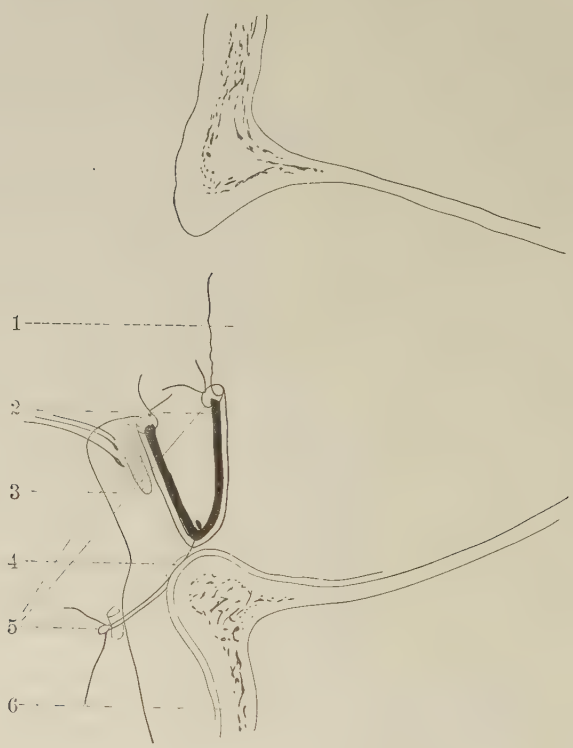

Flap operation for restoration of cul-de-sac. Flap in position. 1, orbital tissue: 2, flap; 3, lid; 4, periosteal tissue 5, sutures; 6, bone of orbit.

the cheek just below the margin of the orbit, the position of the sutures corresponding to their position in the flap. The threads of each suture are passed parrallel to each other. After the needles of all the sutures have been passed, traction is made on all of the sutures uniformly, and the flap, freed from the gauze which contained it, is drawn into position in the groove. The sutures are now tied over small rolls of iodoform gauze placed on the skin of the cheek (or brow). The traction made is just sufficient to hold the flap firmly in contact with the tissues at the

bottom of the groove. The margins of the flap are now attached by small interrupted sutures to the margin of the lid and the margin of the mucous membrane or other tissue of the orbital stump, so as to completely cover the denuded area. If much excess of flap is present, it should be trimmed off, but the flap should be sufficiently large to prevent traction at any point.

Insertion of Plate.—After having secured the flap, the plate must be placed in the cul-de-sac and there maintained until the cul-de-sac is ready for the reception of the artificial eye. Before insertion the plate should be thoroughly sterilized by washing and treating with alcohol and bichloride solution. A lubricant in the form of bichloride vaseline (1 to 5000), is applied to the plate before it is slipped into position. The plate should not be large enough to exert great pressure on the flap at the base of the cul-de-sac, but it should fit snugly.

Subsequent Treatment.—The lids are now properly adjusted and are covered with a small piece of rubber tissue which may be smeared with the vaseline. The piece of rubber tissue should be notched at the sides so that any secretion that may form can escape from the wound into the dressings, at the inner and outer canthi. Iodoform gauze, plain absorbent gauze, and absorbent cotton are placed above the rubber tissue and a bandage applied. Unless unfavorable symptoms arise the bandage is not disturbed for three or four days. The eye is then inspected and if there is no evidence of infection a similar bandage is applied and is not disturbed for three days. The flap can then be inspected. If everything goes well, it is best to permit the plate to remain for ten days or two weeks before removing it. If there should be evidence of inflammation, it may be necessary to remove the plate to cleanse the parts, after which the plate should be again inserted.[1]

The periosteal sutures should be permitted to remain in place until they become somewhat loosened—usually from six to ten days. The stitches that unite the flap to the tissues of the lid and orbit may be removed at the end of a week or on first removal of the plate.

As the healing process advances, some shrinkage of the flap occurs, necessitating a slight reduction in the size of the plate. Shrinkage usually begins from ten days to two weeks after the operation, and continues, ordinarily, for about three months. It is necessary to keep the plate or an artificial eye *in situ* until the shrinkage has ceased, removing the plate or shell every four to seven days for the purpose of cleansing. An artificial eye can ordinarily be worn three weeks after the operation. The flap does not become modified greatly in character by its retention in the orbit, but the functions of the skin are preserved to some extent, and in many cases an abnormal growth of hair takes place. In rare cases an odor develops, apparently due to the growth of some species of microörganism. This can be corrected by treating the

[1] For a full discussion of the operations employed for restoring the cul-de-sac, see Coulomb, L'Œil Artificial, Paris, 1905.

parts with a solution of the chlorate of potash, or 60 per cent. alcohol in which mercuric chloride in a strength of 1 to 2000 has been dissolved.

Pterygium.—The operative procedures resorted to most frequently are excision, transplantation, and strangulation.

Instruments.—Speculum, fixation forceps, Graefe knife, scissors, needles, needle holder.

Excision.—The neck of the pterygium is grasped by the fixation forceps and pierced close to the limbus by a sharp cataract knife, the knife passing just below the tissue of the pterygium and parallel with its surface, the edge of the knife directed toward the cornea. By a to-and-fro motion the knife is made to pass beneath the head of the pterygium, dissecting it from the cornea. Instead of this procedure, a thin strabismus hook may be passed through the incision made beneath the *neck* of the pterygium (Prince's method), and the head of the pterygium may be torn from the cornea (evulsion). The body of the pterygium is now dissected from the underlying tissues for a distance of 3 to 6 mm. and a diamond-shaped piece excised, the inner apex lying at the caruncle. The conjunctiva is now undermined above and below, and the edges brought together by sutures covering the defect as far as the margin of the cornea. The corneal defect becomes covered with epithelium in a few days and healing progresses satisfactorily, leaving some opacity.

Transplantation (Knapp).—Instead of excising the pterygium after having dissected the growth toward the caruncle, the corneous tissue may be removed and a suture passed through the apex of the pterygium. A straight incision may now be made in the lower bulbar conjunctiva, extending from the margin of the wound about four millimeters from the cornea, downward and outward toward the fornix, sufficiently long to accommodate the free part of the pterygium. The suture through the head of the pterygium is now passed through the conjunctiva, at the apex of the last incision, and the head of the pterygium drawn into the space and there fixed. This directs the tissue of the pterygium into the lower fornix. All defects other than the corneal are now covered by suturing the edges of the conjunctiva. Instead of transplanting all of the pterygium below, the body of the pterygium may be split; one-half may be transplanted below, one-half above. McReynolds does not make the incision through the bulbar conjunctiva into the lower fornix, but buries the head of the pterygium beneath, after fully undermining the conjunctiva. McReynolds has devised a special knife for dissecting off the head

Fig. 395

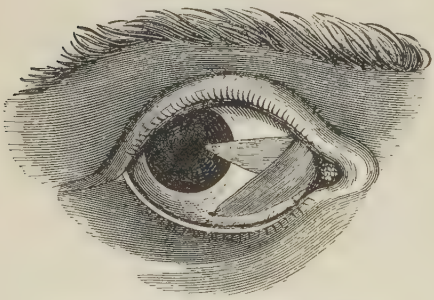

Transplantation of pterygium. (Terson.)

of the pterygium. Unless the knife is very sharp its use will be disappointing.[1]

Strangulation.—The neck of the pterygium is grasped by the fixation forceps and slightly ra sed. A suture with a needle near both ends is employed, one needle passing upward beneath the neck of the pterygium at the corneal margin, the other needle passing upward beneath the neck of the pterygium three millimeters from the corneal margin. The ends of the suture are not drawn through, but the loop holding each needle is cut, liberating the needle and forming three sutures. The suture at the corneal margin is tied tightly over the pterygium, as is also the suture nearest the caruncle. The middle suture encircles the base of that portion of the pterygium lying between the two end sutures. The middle suture is now tied, producing strangulation of the section. The sutures are permitted to remain until they come away spontaneously. Deprived of nutrition the head of the pterygium atrophies and disappears, leaving only an opacity.

Fig. 396

Strangulation of pterygium. (Terson.)

Recurrences.—These are not infrequent after removal by excision, but are very infrequent after transplantation and strangulation.

OPERATION ON THE LACHRYMAL APPARATUS.

Extirpation of Lachrymal Gland.—**Instruments.**—Small scalpel; anatomical forceps; broad fixation forceps; small, slender, blunt-pointed scissors, curved on the flat; strabismus hook; retractors.

Preparations.—In preparing for the operation it is not necessary to shave the brow, although it is better to do so; asepsis may be obtained without this measure.

Operation.—An incision is made, beginning at the middle of the margin of the orbit above, following the margin of the orbit to a point opposite to the outer commissure. The incision is carried down to the periosteum just anterior to the insertion of the septum orbitale. The lips of the wound are held apart by retractors and the bleeding is controlled by means of hemostatic forceps. The septum orbitale at the upper outer angle is exposed and divided close to the margin of the orbit. When this is done sufficiently, and a small mass of orbital fat which always presents

[1] For a full discussion of McReynolds' method, see Trans. of Am. Acad. of Ophthal. and Otolaryngol., 1909.

is removed, the margin of the gland may come into view. It is sometimes necessary to depress the orbital tissue slightly and to draw the gland downward with an instrument before it can be seen. The gland does not differ greatly in color from the orbital tissue, particularly after the tissues become infiltrated with blood, and some difficulty may be experienced in recognizing the gland structure. It is, however, a very little deeper in color than the orbital fat and is firmer in consistence. It is friable and will not withstand strong traction. The edge of the gland may now be seized with broad fixation forceps, and the gland freed as much as possible by blunt dissection. Some of the tissue of the palpebral gland may be included when the common ducts are divided. An endeavor should be made to remove the entire gland. Perforation of the conjunctiva should be avoided. When the vessels to the gland are divided the hemorrhage may be profuse. A large hematoma of the orbit may develop and even cause loss of the eye.[1] This may be avoided by securing the larger vessels and by keeping the wound open until all active hemorrhage has ceased. The cavity may then be douched with a hot bichloride solution and the wound closed. The wound in the septum orbitale may be closed with catgut sutures, the cutaneous wound with silk sutures. If a continuous suture be used for the skin the resulting scar will be almost imperceptible. An antiseptic dressing is applied. Healing by first intention may be expected.

Extirpation of Accessory Lachrymal Gland.—Thorough anesthesia of the conjunctiva by instilling a 4 per cent. solution of cocaine into the conjunctival sac and infiltration anesthesia should be employed. The upper lid is now forcibly retracted by means of a narrow lid retractor and the patient is directed to look downward and inward. (In some cases it is necessary to forcibly rotate the eye downward and have it so held by an assistant by means of fixation forceps or a properly inserted "guy" thread.) Slight pressure on the skin of the lid over the site of the palpebral lachrymal gland will cause the gland to present beyond the margin of the lid. An incision is made through the conjunctiva parallel to the margin of the lid, the conjunctiva dissected back on both sides, and the lobulated mass, thus laid bare, excised. If the dissection is carefully conducted the mass may be removed satisfactorily. The wound in the conjunctiva may be allowed to close of itself or the margins may be united by catgut or silk sutures. This operation obliterates the common ducts. It is less formidable than the one for the removal of the orbital portion of the gland, and, according to Terson, may be tried for relief of epiphora if the palpebral gland is of considerable size. The writer has had no experience with this operation.

Obliteration of Puncta Lachrymalia.—This may be done by cauterizing the puncta. Obliteration of the canaliculi may be accomplished by ligation or by cauterization.

Operations for Relief of Stenosis of Lachrymal Duct.—In operations for the relief of stenosis of the lachrymal duct, free access should

[1] Gifford, Amer. Jour. of Ophth., 1889.

be had to the upper end of the canal by way of the *upper* or *lower* canaliculus. Opening of the lower canaliculus is resorted to by the greater number of operators, as it is believed that the tears find their way into the sac and lachrymal canal more readily when this is done than when the upper canaliculus is opened. Slitting of the canaliculus is accomplished by means of a canaliculus knife, of which there are many models. That devised by Agnew is the one preferred by the writer. The shank is long and flexible, permitting the passing of the knife into the lachrymal duct for the division of any strictures that may exist. (Knives with short shanks are only intended for use in slitting the canaliculi.) (Fig. 397.)

Fig. 397

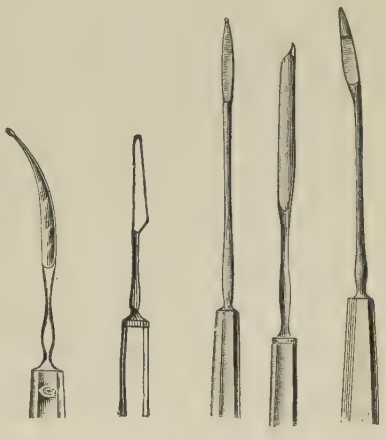

1 2 3 4 5

Canaliculus knives. 1, Bowman's. 2, Stilling's. 3, Agnew's flexible shank. 4, Noyes. 5, Weber's.

The operation on the lachrymal passages and the passing of probes can be conducted with little pain to the patient if cocaine is properly employed. A few drops of a 4 per cent. solution should be introduced into the canaliculus and sac by means of a lachrymal syringe. After five to ten minutes the canaliculus may be divided. A solution of cocaine may now be introduced into the lachrymal duct by means of the syringe or small pipette, and after a few minutes the knife may be passed to the inferior nasal meatus.

In opening the canaliculi the operator should stand back of the patient, using the right hand for the right canaliculus and the left hand for the left canaliculus.

The margin of the lower lid is put on the stretch by drawing it outward with the thumb or index finger of the left hand. The probe point of the knife is then passed into the punctum perpendicular to its opening. (It is sometimes necessary to dilate the punctum by means of a small probe or dilator made for that purpose, before the point of the knife will enter.) Once entered the handle of the knife is carried outward and downward until the axis of the blade corresponds with the axis of the canaliculus. The knife is now steadily advanced until the point impinges on the tissue overlying the lachrymal bone. This will be appreciated by the operator by the firm resistance felt. With the lid still on the stretch the handle of the knife is swept upward, passing close to the brow until the axis of the knife corresponds in direction to the axis of the lachrymal duct. The probe point of the knife should be held against the nasal surface of the lachrymal sac, while the handle of the knife is swept through the arc just described, but no pressure should be exerted upon it. This maneuver serves to slit the canaliculus to the lachrymal

sac and to enlarge the opening into the sac. The cutting edge of the knife should be made to divide the canaliculus on the upper posterior surface—the mucous membrane surface—so that the opening will lie in the lachrymal lake. If the slit is on the cutaneous surface there will be some deformity, and the tears will not flow readily into the sac. If the design is to probe the lachrymal duct only the knife is now withdrawn; however, if it is designed to make the duct freely permeable that is, to divide strictures and obstructive folds, the knife is gently pushed into and through the duct until the probe point reaches the floor of the inferior nasal meatus. The knife is then turned slightly and is drawn out. The tissue of the stricture is severed at each passage of the knife. In *passing probes* the same maneuver is practised as in passing the lachrymal knife.

Fig. 398

Slitting canaliculi and passing knife into lachrymal duct. (Czermak.)

Excision of Lachrymal Sac.—Overlying the sac are the skin, superficial fascia, fibers of the orbicularis palpebrarum muscle, and the deep fascia which is the anterior reflection of the septum orbitale, the lower portion of which is inserted into the anterior crest of the lachrymal groove. The fascia is thickened near the upper end of the sac, forming the internal canthal ligament.

Between the periosteum and the fibrous coat of the sac is a thin layer of capillaries and small vessels (erectile tissue) which is continuous with that in the nasal duct. This tissue is more plentiful in the lower portion of the sac. In inflammatory processes this tissue is greatly congested.

Indications.—Removal of the lachrymal sac may be resorted to—

1. In all conditions of dacryocystitis after conservative measures have failed.

2. In actual occlusion of the nasal duct proper (*a*) in stenosis of osseous origin, (*b*) in high degrees of cicatricial stenosis.

3. In confirmed chronic dacryocystitis with development of polypoid tissue and in cases in which acute exacerbations of a phlegmonous character occur.

4. Whenever conservative treatment is impracticable.

5. In conditions of marked relaxation and distention of the sac due either to purulent or mucoid collections (mucocele).

6. In tuberculosis of the sac.

7. In connection with operations on the eyeball in cases of dacryocystitis in which (*a*) a cure cannot be brought about by conservative measures, (*b*) the time for conservative treatment cannot be given.

8. In lachrymal fistula when conservative measures fail.
9. In hypopyon keratitis (Axenfeld).
10. In caries of surrounding bone (Meller).
11. In recurring erysipelas affecting the sac.

Preparation for Operation.—When practicable the lachrymal sac should be thoroughly irrigated with an antiseptic solution to remove infectious material (solution of mercuric chloride, 1 to 2000), after which a few drops of cocaine (4 per cent.) may be injected. The nasal mucous membrane may also be cleansed with a non-irritating spray or douche. The eyelids may be closed and fixed by means of adhesive strips (Czermack), for the purpose of protecting the cornea, and so held until the operation is complete.

Anesthesia.—Infiltration anesthesia, accompanied by local anesthesia of the conjunctiva. The solution for infiltration employed by Meller is excellent (cocaine solution, 1 per cent., 8 to 9 parts; adrenalin, 1 to 1000, 1 to 2 parts; 1 c.c. in a Parvez syringe). The needle of the syringe is made to pierce the skin of the lower lid about 1.5 cm. below and slightly to the temporal side of the inner canthus. A few drops of the solution are now forced out and the point of the needle advanced a few millimeters in the direction of the sac, keeping just beneath the skin; a few more drops are then forced out. This is continued until the needle passes over and beyond the internal canthal ligament. The needle is then withdrawn, passed into the tissue between the upper part of the lachrymal groove and the cupola of the sac on the median side, just above the inner canthal ligament, and a few drops of the solution injected. This process is repeated just below the canthal ligament. If the tissues are puffy as a result of the injection of the fluid, gentle massage will restore them to an approximately normal condition. Infiltration anesthesia as described renders the operation almost bloodless. General anesthesia is necessary in cases in which there is much inflammation of the sac and in individuals of a nervous temperament. Infiltration anesthesia will be of value even if general anesthesia is employed, as it partly controls hemorrhage.

Types of Operation.—There are two types of operation: (1) Removal without disturbing the periosteum, and (2) removal with the underlying periosteum. The operation of Meller (Vienna) is one of the best. It may be done with or without disturbing the periosteum.

Instruments.—Scalpel, dissection forceps, Meller's tear-sac speculum, small curved scissors with pointed blades, sharp curette for nasal duct.[1]

Operation.—The incision begins 2 mm. above the internal canthal ligament, 3 mm. from the internal canthus, is about vertical at first, then curves downward and outward over the outer crest of the lachrymal groove for a distance of 1.5 to 2 cm. The incision is carried through the skin, exposing the superficial fascia. The skin at the edge of the incision is undermined to some extent to afford as wide an opening as

[1] The retractors of Müller and Axenfeld, Klin. Monatsbl. f. Augenheilk., February, 1903, and of Stevenson, Trans. Ohio State Med. Assoc., 1907, are excellent.

possible, and Meller's speculum inserted. The body of the speculum lies diagonally on the cheek. The superficial fascia is now raised by the forceps, split with the scissors in a line with the incision and pushed to the sides. This exposes some of the fibers of the orbicularis palpebrarum muscle. The muscle is split as the fascia was split and pushed to each side, exposing the deep fascia. It should now be easy to recognize the attachment of the deep fascia to the anterior crest of the lachrymal groove and to see the thickened upper portion, the internal canthal ligament. The deep fascia should now be split 1 to 2 mm. from the anterior lachrymal crest, the incision extending above to include the internal canthal ligament and downward to the opening of the lachrymal duct. This fascia must be split very carefully, as the sac lies immediately beneath it and may be injured. A nick may be made in the fascia, and a probe-pointed knife be inserted above and below, the point passed close beneath the fascia and the fascia divided to the desired extent. The tissue of the sac will now be recognized; unless the sac is inflamed, it is of a bluish tint. Dissection is now carried to the

Fig. 399

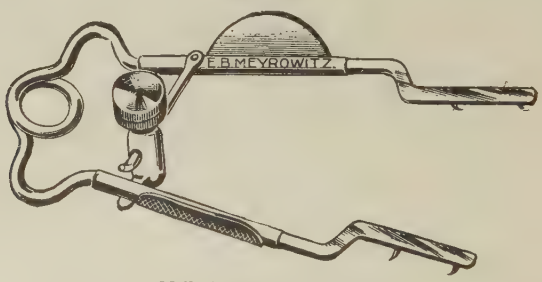

Meller's tear-sac speculum.

temporal side of the sac, the tissues being separated as far as possible by the closed points of the scissors. A few connective-tissue fibers may have to be cut. This dissection is relatively easy below. At the upper part the canaliculi enters the sac. These are isolated and cut across. The dissection is carried around until the posterior lachrymal crest is reached, without perforating the posterior reflection of the septum orbitale, which would permit the orbital fat to present. The dissection is now conducted from the mesial side, the sac being separated from the periosteum (or the periosteum may be raised from the lachrymal groove with the sac by first cutting through it on the posterior aspect of the anterior lachrymal crest; the periosteum should not be raised beyond the posterior lachrymal crest). The dissection is continued until the body of the sac is freed. The cupola of the sac is then detached. This must be done by carefully dividing its rather close attachment to the tissues above. If these tissues are cut into to any great extent, quite large blood-vessels will be encountered. Their division will flood the wound with blood and prolong the operation. Having detached the sac above, it is now pulled forward and outward,

the tissues separated as far as possible into the nasal duct and excised. The excised sac is now carefully inspected to determine whether any part of it has been left. If it is not intact the parts retained must be searched for in the cavity from which the sac has been taken and removed. The cavity should be carefully inspected and all tags of tissue removed. The mucous membrane lining the nasal duct must now be thoroughly curetted and a probe passed into the nasal meatus. The opening into the nose should be made free in all cases except in those of complete bony occlusion, in which cases it is not necessary.

Although not thought necessary by Meller, the experience of Holmes, the writer, and others, teaches the necessity of destroying at least the mesial half of the mucous membrane of the canaliculi. The portion of the canaliculi that can be conveniently reached from the cavity from which the sac has been removed is dissected out and excised.

Fig. 400



Excision of the lachrymal sac. (Haab.)

The wound is now thoroughly irrigated with mercuric chloride, 1 to 5000, and closed by means of two to four silk sutures. Two of the sutures may include the deep fascia. The margins of the wound should be brought into perfect apposition. A small, loose roll of iodoform-gauze is placed along the line of incision, sterile gauze above this, and a bandage or adhesive strips over all. Some pressure should be made to keep the tissues in their natural position.

Healing should take place by first intention. If there are no evidences of inflammatory reaction the dressing need not be disturbed until the third or fourth day. The stitches may be removed on the fifth to the seventh day.

Difficulties Encountered.—(*a*) The tissues at the site of the operation may be so thickened that the crest of the nasal process of the superior

maxilla cannot be recognized. In such a case the incision must be placed as nearly right as possible. (*b*) The hemorrhage may be very profuse and obscure the parts. This must be stopped by ligation and properly applied pressure. Pressure over the facial artery below the margin of the orbit is sometimes of service. (*c*) There is often considerable difficulty in recognizing the sac, and it may be cut into. In such a case the edge of the sac should be seized and the sac carefully dissected out. (*d*) The sac is often friable and comes away in pieces. Under these conditions the sharp curette must be resorted to in order to insure complete removal of all mucous membrane. (*e*) The thin bony structure forming the lachrymal groove may be broken through, forming an opening into the nose. This accident is of no importance. (*f*) The site of the lachrymal canal may not be readily recognized. This cannot occur if a probe is passed or if the crest of the nasal process of the superior maxilla is followed. (*g*) The canaliculi are difficult to find from the surface of the dissection wound. These may be easily located by passing a probe from the lachrymal puncta.

Fig. 401

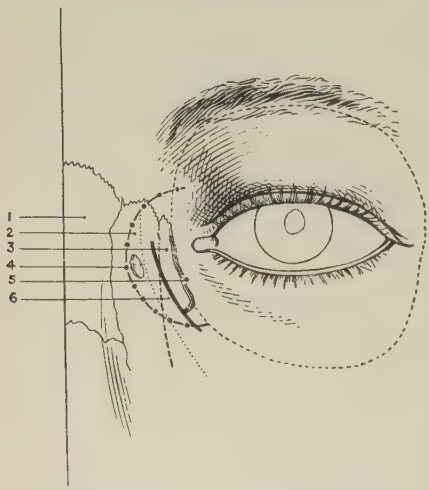

1. Nasal bone. 2. Nasal process of superior maxilla. 3. Lachrymal bone. 4. Attachment for internal palpebral ligament. 5. Inner or lachrymal crest. 6. Outer or nasal crest of lachrymal groove. Graefe's incision – – –; Kuhnt's incision ——; Axenfeld's incision . . . .; Völcker's incision –·–·

The incisions employed by different operators are depicted in Fig. 401.

Other Operations.—The operations of Kuhnt[1] and of Axenfeld[2] contemplate the removal of the sac with the periosteum of the lachrymal groove. The incision (Fig. 401) is carried down to the bone at once. The retractor is then inserted, the periosteum is raised by means of a periosteal retractor, cut through near the apex of the crest high enough to clear the dome of the sac, divided downward at the posterior lachrymal crest, and the sac lifted out with it. The lateral dissection is then made and the operation completed as described above.

Czermak and some other operators prefer to remove the sac without dividing the internal canthal ligament. While extirpation of the sac can be accomplished in this manner, the operation is rendered much more difficult without compensating advantages.

Von Hoffman's Operation.—Von Hoffman[3] operates by an opening principally through mucous membrane.

[1] Ulrich, Inaug. Dissert., Jena, 1888. [2] Klin. Monatsbl. f. Augenheilk., xli, S. 128.
[3] Bericht. u. d. 25 Versaml. d. Ophth. Gesel., Wiesbaden, 1896-97.

Instruments.—Weber's canaliculus knife, scalpel, forceps, curved blunt-pointed scissors, artery forceps, special lachrymal retractor.

Operation.—Infiltration anesthesia. By means of a locking retractor the margins of the lids are widely separated. The canaliculi, which may be slit up for easier recognition, are dissected out to the sac to which they may remain attached to facilitate the recognition and removal of the sac, or they may be excised. In dissecting out the canaliculi a narrow strip of overlying mucous membrane and skin may be removed, extending from one punctum to the other, making a crescent-shaped wound. The caruncle is not disturbed. The skin is now retracted toward the nose, and, by a careful blunt-and-sharp dissection between the internal canthal ligament and the sac, the sac is exposed and separated from its anterior attachments. It is then drawn outward and separated from the periosteum below and the dome freed by means of the scissors. Its posterior adhesions are separated; the sac is drawn upward and severed as far down in the nasal duct as possible. The nasal duct is thoroughly curetted and the margins of the wound closed by sutures.

This operation is a difficult one and should not be attempted when the tissues are inflamed.

Methods for Rendering the Sac Recognizable.—Numerous methods have been employed to render the sac easily recognizable. These are (1) the introduction of coloring matter; (2) the introduction of semi-solid substances to fill out the sac; (3) the introduction of solid substances.

1. Some operators have practised injecting the lachrymal sac with a solution of methylene blue, the staining of the mucous membrane showing through the wall of the sac and rendering it more easily recognizable.

2. (*a*) Holmes[1] introduced a paste of starch colored with iodine by injecting it through a canaliculus, subsequently closing the canaliculi with small hemostatic forceps. The procedure was not entirely satisfactory. (*b*) Paraffin with a melting point of 110° to 120° F. has been injected through a slit canaliculus to distend the sac; cold compresses were then applied, and after the paraffin had hardened the sac was removed. (*c*) By means of a powerful syringe paraffin of a higher melting point has been injected cold in the form of small pieces into which the paraffin breaks as it leaves the nozzle of the syringe. The injection is through a slit canaliculus. The small particles are crowded into and distend the sac (Borsch).[2] (*d*) Skeel (personal communication) suggests filling the sac with sterile cottonwool, either through a slit canaliculus or through an incision in the sac, to distend it, just before the operation.

3. Ohlstrom[3] fills the sac with a little hammer. The incision is made through the skin in the usual manner; then an incision is made through

[1] Holmes, Arch. of Ophthalmology, xxxiii, 1, 1899.
[2] Axenfeld, Klin. Monatsbl. f. Augenheilk, xli, S. 128.
[3] G. Ohlstrom, Centralblt. f. Augenheilk., March, 1897.

the anterior portion of the sac, 4 to 5 mm. long, and the small hammer, which almost fills the sac, is introduced. The opening through the sac is closed about the handle of the hammer above and below by means of fixation forceps or sutures; the dissection is then finished in the ordinary way.

The introduction of substances into the sac is not necessary, but they render the recognition of the sac more easy.

Statistics prove that in properly selected cases the operation of excision of the sac is one of much value. Adolph[1] reports 226 cases from Kuhnt's clinic in which all but 4.8 per cent. healed by primary intention. Many operators prefer the subperiosteal operation, as the hemorrhage is somewhat less and the procedure is slightly more expeditious.

OPERATIONS ON THE CORNEA.

Paracentesis.—**Instruments.**—Speculum, fixation forceps, paracentesis needle, spatula.

Operation.—Cocaine anesthesia. The operator stands behind the patient. The speculum is inserted, the ocular conjunctiva grasped at the corneal margin above. The cornea is pierced at the corneal margin below with the paracentesis needle (the instrument employed may be a small keratome, a broad needle, or the Desmarres paracentesis needle, which is supplied with a shoulder to prevent the too deep entrance of the blade), usually in the vertical meridian. The needle is then withdrawn slowly in order that the aqueous may not escape rapidly and cause prolapse of the iris. Should the iris prolapse, it may be replaced by means of the spatula. The spatula may also be used to reopen the wound should this become necessary.

Fig. 402

Paracentesis needle.

Atropine may be instilled if there is congestion of the iris.

Paracentesis is performed (*a*) for the temporary relief of tension in cases in which immediate iridectomy is not convenient or desirable, as in hemorrhagic glaucoma and in some cases of acute glaucoma in which the anterior chamber is not abolished; in cases of healing corneal ulcer with threatened staphyloma; in cases of plastic iritis with increase of tension due to plugging of the spaces of Fontana; in cases of swelling of the substance of the lens after operation or injury. (*b*) In corneal ulcer to stop the progress of an ulcer that has resisted medication, and to anticipate perforation in deep ulcers. If the ulcer is bulging the paracentesis is made through the floor of the ulcer. In these cases and in the cases of threatened staphyloma, a compress bandage should be applied after paracentesis.

[1] Adolph, Zeitschrift f. Augenheilk., viii, 4, p. 441.

Saemisch Operation.—**Instruments.**—Speculum, fixation forceps, Graefe knife, spatula.

Operation.—Cocaine anesthesia. The speculum is inserted, and the globe fixed by means of the fixation forceps applied at the lower margin of the cornea. The point of a narrow Graefe knife, back of the knife toward the iris, is then entered through clear cornea at the margin of the ulcer, carried across the anterior chamber and made to emerge through clear cornea at a corresponding point. The blade is then made to cut out through the base of the ucler. Ordinarily this is in the lower part of the cornea (Fig. 403). The incision should be parallel to the margin of the lower lid. The anterior chamber is emptied by spreading the wound with the spatula and irrigating with normal saline solution. Bandage. Cleansing of the anterior chamber may be repeated every twenty-four hours, until the ulcer clears. Thorough asepsis is necessary. The results after Saemisch's section are usually good. General infection of the globe seldom occurs. Anterior synechiæ form, but prolapse of iris is uncommon.

Fig. 403

Saemisch section.

Cauterizing the Cornea.—Cocaine anesthesia is used. The operation may be done by means of a small galvanocautery, a platinum point of suitable size, or a strabismus hook, heated over a flame. Although in some individuals the eye may be satisfactorily fixed by means of the fingers, in many cases a speculum and fixation forceps are necessary to satisfactorily fix the eye. If there is any doubt regarding the area to be cauterized, a solution of fluorescin may be employed, but one must bear in mind the fact that areas of roughened epithelium and diseased epithelium are also stained with this drug. Necrotic tissues should be removed from ulcerated surfaces by curetting and the area freed from excess of fluid before using the cautery. The cautery-point should be brought to a red glow and lightly but thoroughly applied. After the operation some bland aseptic oil or vaseline should be put into the eye and a bandage applied. Dressing every twelve hours.

Fig. 404

Tattooing needle.

Tattooing.—**Instruments.**—Speculum, fixation forceps, tattooing needle; material (India ink). (The ink is rubbed up into a thick paste in water and sterilized.) The eye must be free from inflammation.

Operation.—Cocaine anesthesia is employed. The speculum is inserted and the eye fixed. The area to be tattooed is usually freed of epithelium, dried with damp "wipes," and some of the India ink applied. The ink is now introduced beneath the superficial lamellæ of the cornea by oblique stabs with the tattooing instrument and quite gentle rubbing by means of a glass rod. The instrument employed may be a single needle or a number of needles set side by side with the points on a level or forming a bevel (Fig. 404). The latter is an excellent instrument, permitting of rapid work. The operation should proceed until a degree of pigmentation in excess of that desired is obtained. This can be determined by flooding the cornea with a sterile solution of boric acid from

time to time and removing unfixed pigment by means of wipes. When the desired effect is obtained, the excess of pigment is flooded away with boric-acid solution and a bandage applied. If a pupillary area is to be defined, it can be marked out by means of the corneal trephine.[1] The color of the pupil and iris may be imitated. Chevallereau and Pollak have employed Naples yellow, brown and red ochre, copper carbonate, natural and burnt umber, ultramarine blue and ivory black. The pigments were obtained pure, were reduced to a very fine powder, mixed to a paste in water and sterilized. They report no irritation following the operation and a permanent resulting color.[2]

Quite severe reaction sometimes follows tattooing. Sympathetic ophthalmic has been reported (Panas). The writer has never seen any bad results; the epithelium is soon restored and healing is satisfactory, as a rule.

OPERATIONS ON THE IRIS.

Iridectomy.—**Instruments.**—The instruments required for this operation are: A stop speculum, lance-shaped knife (keratome), straight or bent at an angle, the point of which should be sharp and rigid (a Graefe knife or a broad needle may be used), iris forceps curved, iris scissors curved on the flat—points not too sharp, spatula, and clot forceps.

Fig. 405

Agnew's angular keratome.

Anesthesia.—Local anesthesia is sufficient except in those cases in which the globe and ocular conjunctiva are much congested, as in acute glaucoma, when general anesthesia may be necessary. The bent keratome may be used if the anterior chamber is deep; if the anterior chamber is shallow, the Graefe knife should be employed.

Operation.—The stop speculum is inserted and, after separating the lids sufficiently (usually not to the maximum degree), the blades are fixed. The conjunctiva and the subconjunctival tissue are grasped with the fixation forceps, meridionally, close to the cornea, directly opposite to the point of entrance of the keratome—if that instrument is to be used; in front of the middle of the insertion of the internal rectus, if the Graefe knife is to be employed—and the incision is made above. The attachment of the fixation forceps affords a point for counterpressure in both instances. The eye is now rotated downward sufficiently to permit the operator to easily reach the site for the incision. There should be no dragging on the eye. The point of the keratome is made to pierce the fibrous coat, almost at right angles with the surface. As soon as the point enters the anterior chamber the knife should be advanced in the plane of the iris with an even, steady pressure until the incision is of the desired length. In withdrawing the blade the point should be raised by tilting

[1] Holth, La clinic oculist., p. 1794.

[2] Year-Book, 1907, p. 150.

the handle backward until the point is almost in contact with the posterior surface of the cornea. It is then withdrawn slowly to permit of slow escape of aqueous, lateral movements being made in the endeavor to cause the inner line of the incision to correspond to the outer line in length. After removing the knife the fixation forceps should be transferred to an assistant. He should be instructed not to rest his hand on the lower jaw, as that is apt to be moved, and not to press or draw on the forceps.

Fig. 406

Iris forceps.

Fig. 407

Iris scissors.

Fig. 408



Jaeger's angular keratome.

Fig. 409



Jaeger's straight keratome.

Fig. 410

Probe and spatula.

The iris forceps are held in the left hand. If it is necessary to enter the anterior chamber, the blades should be closed and the forceps should be entered at the middle of the incision. The end of the blades should be carried forward (care being observed not to press on the iris) to a point just short of the pupillary margin, when the blades should be permitted to part wide enough to include a fold of iris; they are then closed. The seized portion of the iris is now withdrawn and excised in a manner to

accomplish the desired result. The fixation forceps are now taken from the assistant. (If general anesthesia is employed the eye is not released until the iris is freed from the wound. If local anesthesia is employed the eye is released and the speculum is removed.) The eye is now freed from blood and blood-clot. With the end of the spatula bent so as to permit of its easy entrance into the anterior chamber the margin of the iris is freed from the left angle of the wound (holding the spatula in the right hand), and the right border of the iris from the right angle of the wound (holding the spatula in the left hand). The point of the spatula as it enters the anterior chamber should pass between the iris and the cornea. Care should be observed not to touch the capsule of the lens.

Fig. 411

Incision for iridectomy other than in glaucoma. (Photograph by Geo. S. Dixon.)

When the iris has been freed (from the sclerocorneal wound) the margins of the wound are carefully adjusted, the conjunctival sac cleansed by douching with normal saline or a 3 per cent. boric-acid solution, and the eye bandaged. The eye should be inspected at the end of twenty-four hours, and dressed every day until the wound is healed.

Iridectomy, for visual purposes, should be made in such a manner that there will be as little disturbances from "dazzling" as possible. To insure this the coloboma should be small, should be made at a point where the media are clear, and should not extend to the ciliary insertion of the iris. The site of the coloboma, for visual purposes, depends on the condition of the tissues. If the media are clear it is best to make the

Fig. 412

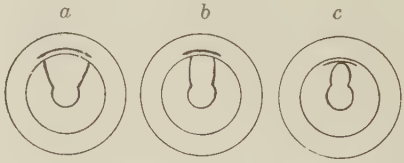

Forms of iridectomy: *a*, in glaucoma; *b*, in cataract; *c*, for visual purposes.

coloboma in the lower inner quadrant, as the visual line ordinarily cuts the cornea below and to the inner side of the centre of the cornea. The coloboma must be made back of *transparent cornea* in whatever part of the cornea it may be placed. If the area of clear cornea is narrow the incision should be made in the scleral margin.

In cases where the iris is adherent to the lens it is sometimes impossible

to grasp it and bring it out of the wound with the ordinary iris forceps. Under these conditions it is necessary to employ strong but delicate forceps with teeth placed on the lower aspect of the blades. The number of teeth desirable is ordinarily two on one blade, and three on the opposite blade. The iris forceps of Liebreich are well adapted for this work.

Fig. 413



Liebreich's iris forceps.

It sometimes occurs that iridectomy is desirable in an aphakic eye, where the support to the iris (the lens) is gone. As it is very difficult to seize the iris with forceps, a Tyrell hook, either blunt or sharp, may be used in such cases. After the incision through the cornea is made the hook is introduced sideways—after bending the shank of the hook at a suitable angle, and when the hook passes the pupillary margin of the iris, it is turned so as to hook over the edge of the iris. It is then turned sideways again, and the iris is drawn through the wound and excised.

Iridotomy.—This operation consists in dividing the iris simply. Iridotomy is performed in aphakic eyes in cases where, from the formation of a pupillary membrane after the extraction of the lens or after traumatism which has caused the lens substance to disappear in whole or in part, the pupil is obliterated, and in cases in which the pupil is closed by displacement following involvement of the iris in the corneal wound. Iridotomy cannot well be performed in eyes with a transparent lens, for obvious reasons.

Fig. 414

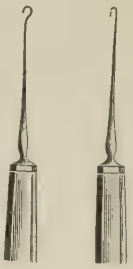

Tyrell's hooks.

Operation.—Iridotomy may be done (*a*) with a Graefe knife, as follows: The lids are held apart by means of a speculum. The eye is grasped with fixation forceps at a point approximately opposite to the point of entrance of the knife. The knife should pierce the cornea at a point suitable for dividing the iris and pupillary membrane at right angles to the direction of greatest tension, the plane of the blade corresponding to the proposed line of incision. After piercing the cornea, the point of the

Fig. 415

Ziegler's model of knife-needle.

knife should be carried through the iris at one extremity of the incision, and then swept rapidly through the tissue to be divided. If the knife is small and very sharp, and the cornea incision is not made larger than the blade (this can be accomplished by slight pressure against the corneal

tissue with the back of the knife while the incision in cornea, iris, and pupillary membrane is being made), the iridotomy can be made and the knife withdrawn without much loss of aqueous. The incision in the iris gapes, forming a slit-like pupil which remains open.

Fig. 416

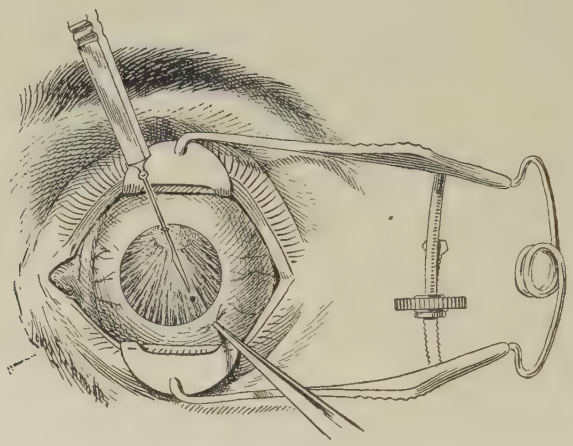

Ziegler's V-shaped iridotomy.

Ziegler[1] advocates the making of a V-shaped iridotomy, using the Hays knife-needle modified by himself. He describes the operation as follows:

First Stage.—With the blade turned on the flat, the knife-needle is entered at the corneoscleral junction, or through the upper part of the cornea, and passed completely across the anterior chamber to within three millimeters of the apparent iris periphery. The knife is then turned edge downward, and carried three millimeters to the left of the vertical plane (Fig. 417).

Fig. 417

Plan of first incision.

Fig. 418

First incision completed. Plan of second incision.

Fig. 419

Pupil resulting from V-shaped iridotomy.

Second Stage.—The point is now allowed to rest on the iris-membrane, and with a dart-like thrust the membrane is pierced. Then without making pressure on the tissue to be cut, the knife is drawn gently up and down with a saw-like motion, until the incision has been carried through the iris tissue from the point of the membrane puncture to just beneath the

[1] Trans. Oph. Sec., A. M. A., 1908.

point of the corneal puncture. This movement is made wholly in a line with the axis of the knife, the shank passing to and fro through the corneal puncture, and the loss of any aqueous being carefully avoided in the manipulation.

Third Stage.—The pressure of the vitreous will now cause the edges of the incision to immediately bulge open into a long oval (Fig. 418) through which the knife-blade is raised upward, until above the iris-membrane, and then swung across the anterior chamber to a corresponding point on the right of the vertical plane, which, owing to the disturbance in the relation of the parts made by the first cut, is now somewhat displaced and the second puncture must be made at least one millimeter farther over, *i. e.*, four millimeters to the right of the vertical plane (Fig. 418).

Fourth Stage.—With the knife-point again resting on the membrane, a second puncture is made by the same quick thrust, and the incision rapidly carried forward by the sawing movement to meet the extremity of the first incision, at the apex of the triangle, thus making a *converging* V-shaped cut (Fig. 419). Care must be taken at this point that the pressure of the knife-edge on the tissue shall be most gentle, and that the second incision shall terminate a trifle inside the extremity of the first, in order that the last fiber may be severed and thus allow the apex of the flap to fall down behind the lower part of the iris membrane. If the flap does not roll back of its own accord it may be pushed downward with the point of the knife. When the operation is completed the knife is again turned on the flat and quickly withdrawn.

Fig. 420

De Wecker's scissors.

De Wecker's Operation.—Iridotomy may be done with De Wecker's iris scissors (pince ciseaux) after making a linear incision through the cornea near the limbus at a suitable place. The incision through the cornea is made large enough to permit the entrance of the blade of the scissors into the anterior chamber and their proper manipulation when there.

The point of the knife as it enters the anterior chamber may be made to pierce the iris or the pupillary membrane, as desired, at the point for the commencement of the incision through the pupillary membrane and iris. The scissors—which are supplied with one sharp-pointed and one blunt-pointed blade—are passed into the corneal wound closed. As soon as the anterior chamber is entered the scissors are opened, the sharp-pointed blade is passed beneath the pupillary membrane or thickened secondary cataract and iris, and the dull-pointed blade between the cornea and these structures, and when introduced sufficiently far the tissues between the blades are divided; more than one cut may be made through the cicatricial membrane or iris, or both. In operating to establish a

clear pupil, after cataract extraction with dense, secondary cataract this method is an excellent one to employ. The operation with De Wecker's scissors is more complicated and extensive than with the knife alone. Loss of vitreous frequently occurs, but the operation does not entail dragging on the tissues (iris and ciliary body), consequently is seldom followed by reaction.

Iridotomy is a satisfactory operation only in cases in which all inflammatory processes have subsided. If the eye is not perfectly quiet, an exudative process may be awakened and the opening in the iris may become closed. The pupillary membrane is sometimes calcareous and too dense to permit the passage of the knife, defeating attempts at iridotomy by the use of the Graefe knife.

Extra-ocular Iridotomy.—This consists in making an incision through the cornea, drawing out the iris and incising it meridionally, then returning it to the anterior chamber; this may be done without injury to the lens. It is an operation seldom resorted to, as a small iridectomy is preferable.

In cases of bombé iris, iridotomy may be done by transfixing the iris without injuring the lens, but this procedure is seldom, if ever, necessary.

Iridodesis.—This is an operation for elongating the pupil by including a portion of iris in a wound in the cornea by means of a suture. Devised by Critchett,[1] and since abandoned for iridectomy.

Iridencleisis.—This is a similar operation, devised by De Wecker, resembling iridodesis, except that no suture is employed.

Iridodialysis.—This has been advocated in some cases where a clear portion of the cornea exists at the periphery only, in which an iridectomy might be followed by opacity of this part of the cornea. The operation consists in making an incision through the cornea sufficiently remote from the clear portion, seizing the iris with forceps or hook, and tearing it from its ciliary attachment at the desired place, drawing it out of the wound, and excising a small piece. The traction necessary is very apt to set up a plastic inflammation. The operation is now practically abandoned.

Fig. 421

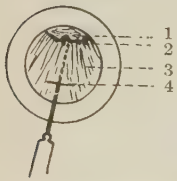

Iridocystectomy. 1, membranous cataract. 2, margin of iris. 3, iris. 4, incision through cornea.

Iridocystectomy.—This operation was devised by H. Knapp, and has been employed by him many years. It is indicated for the purpose of making a new pupil in cases of iridocyclitis or greatly thickened capsule which has caused closure of the pupil after cataract extraction. It is described as follows by Knapp.[2]

Operation.—"Under cocaine anesthesia a Beer's knife pierces the cornea about 3 or 4 mm. above the lower corneal margin opposite the scar from the extraction, and transfixes the iris or pupillary pseudomembrane. With a blunt hook the lower half of the incised tissue is seized, drawn out of the eye, and abscissed close to the cornea. Eye bandaged. There are scarcely any accidents worth mentioning. The healing is usually prompt and yields most surprisingly good visual results." The writer has employed this operation with much satisfaction.

[1] R. L. O. H. Rep., i, p. 220.

[2] Norris and Oliver's System, iii, p. 792.

Division of Synechiæ.—**Anterior Synechiæ.**—The operation after Lang is as follows: In addition to the speculum and fixation forceps a sharp and a blunt knife-needle, closely resembling the Knapp knife-needle, are employed. (The writer has used sickle-shaped knife-needles for the same purpose.) After fixing the globe an opening is made in the cornea at a point favorable for the division of the synechia and the knife is withdrawn. The probe-pointed or the sharp-pointed knife-needle, as desired, is now passed into the anterior chamber behind the synechia and the attachment to the cornea divided by a to-and-fro motion. The eye is then bandaged. It is not always easy to divide synechiæ, and the operation may fail. When it succeeds, the iris may be dilated by atropine and rapid healing obtained, with a permanent result.

Fig. 422

Sickle-shaped knife.

Posterior Synechiæ.—Streatfield[1] regarded posterior synechiæ as a cause of recurrent iritis, and adopted the following method of procedure to break them up: A small corneal incision was made at a convenient place, a small blunt hook was inserted through the incision, insinuated behind the synechia, and the synechia detached by traction.

Passavant made a linear incision at the sclerocorneal junction, grasped the iris with forceps, and detached the adhesion by traction.

Operations employed for this purpose are fraught with danger to lens capsule and lens, and, since the effect of partial posterior synechia on the eye is not particularly harmful, should not be generally attempted.

Operative Treatment of Glaucoma. — **Iridectomy.**—Although the main features of iridectomy for glaucoma are as described on page 414, there are some decided differences which must be considered here.

Preparation.—The pupil should be contracted by the use of pilocarpine or eserine before operation, if possible. If acute glaucoma can be influenced by the use of eserine, the operation should be deferred until the acute stage has subsided. In cases of very shallow anterior chamber, it is sometimes advisable to perform a small posterior sclerotomy forty-eight to seventy-two hours before the iridectomy.

Knife.—Operators differ much in their choice of the knife to be employed. The writer prefers a Graefe knife in all cases except those in which the anterior chamber is deep, since in his opinion the iris angle can be entered more readily and the danger of injuring iris and lens is less with this knife than with the keratome.

Incision.—The incision should be so placed that it will enter the anterior chamber at the filtration angle, that is, about 2 mm. back of the corneal margin, in order to make it possible to remove the iris at its ciliary insertion (Fig. 423).[2] The length of the incision should be sufficient

[1] Moorefield Reports, vol. ii.

[2] By consulting this photographic figure it will be seen that the incision for iridectomy in glaucoma may pass through Schlemm's canal, and when carried well back may sever a portion of the annular ligament and open into the subchorioidal lymph space.

to permit of the removal of one-sixth to one-fifth of the iris—ordinarily 5 to 6.5 mm. If a Graefe knife is employed, it is well to make a conjunctival flap. On completing the incision it frequently happens that the iris prolapses into the wound, rendering it unnecessary to enter the anterior chamber with the iris forceps. To excise the iris in glaucoma, the seized portion is carefully drawn outward and a little toward the operator's left. The border of the protruding piece of iris to the operator's right is then cut through with the scissors (held in the right hand), close to the wound in the sclera, passing through the sphincter to the root of the iris. The iris is then drawn a little farther to the left and partly torn from the ciliary attachment or cut close to the wound with the scissors. A very little traction is now made toward the operator's right, and the iris is removed by a final snip. This insures leaving little if any iris "stump." The columns of the coloboma are now replaced and the eye bandaged.

Fig. 423

Incision in glaucoma. (Photograph by Geo. S. Dixon.)

After-treatment.—It is advisable to test the tension from day to day, and if there is any rise above the normal to begin the use of miotics early. The writer gently massages the eye one to three minutes at each dressing, beginning three to five days after the operation and continuing until healing is complete, under the impression that the resulting condition is more favorable for a permanent arrest of the affection.

Fig. 424

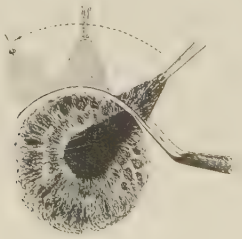

Excision of iris in glaucoma. (Morax.)

Fig. 425



Appearance of coloboma. (Morax.)

Lagrange Operation.—Iridectomy in glaucoma as modified by Lagrange for the purpose of forming a filtration cicatrix, "combined iridectomy and sclerotomy." Instruments as for iridectomy, with the

addition of a pair of small, very sharp scissors curved on the flat (made by Luer, Paris).

Operation.—A Graefe knife is employed. The puncture and counter-puncture are made 1 mm. from the corneal margin, and about 7 mm. apart. The incision is continued in the iris angle. In terminating the incision the edge of the knife is turned backward so as to bevel the sclera. A large conjunctival flap (about 4 mm.) is made. The conjunctival flap is now seized by means of fine-toothed forceps and drawn forward, tilting the edge of the scleral flap upward. A fusiform piece of the bevelled scleral flap is now removed by means of the curved scissors without interfering with the conjunctival flap. This piece may include the entire thickness of the sclera at the middle of the incision. The excision of the iris is now performed in the ordinary way (see page 426); finally, the wound is covered by the conjunctival flap. Lagrange reports very gratifying results. The writer has performed this operation in a large number of cases with excellent results. The cicatrix[1] is not always a permanent filtration cicatrix, but it remains a filtration cicatrix longer than after the ordinary iridectomy. (For the results of iridectomy in glaucoma, see page 416.)

Fig. 426

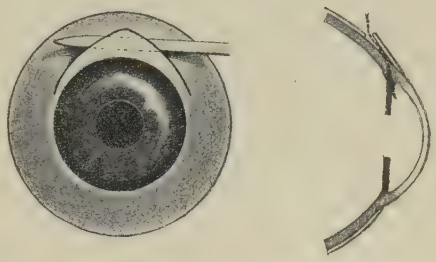

Fig. 427

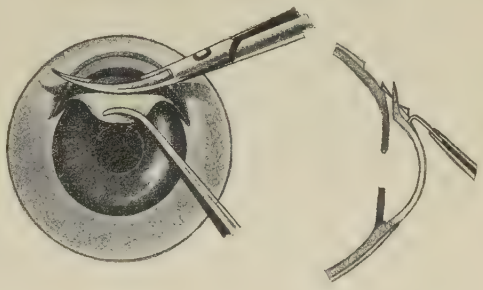

Lagrange operation. (Archives d'ophtalmologie.)

OPERATIONS ON THE SCLERA.

Sclerotomy.—Two forms of sclerotomy are recognized: the operation which aims to make two slit-like openings into the anterior chamber—*anterior sclerotomy*, and that which results in an opening into the vitreous chamber—*posterior sclerotomy*.

Anterior Sclerotomy.—This was devised and largely advocated by De Wecker.[2]

Operation.—Local anesthesia is employed. A drop of 0.5 per cent. solution of eserine sulphate should be instilled into the eye some minutes

[1] See Henderson, Ophthalmoscope, December, 1907.
[2] Ann. d'oculistique, March and April, 1872.

before the operation. The puncture and counterpuncture should be made 1.5 to 2 mm. from the corneal margin in the sclera—as in making the Graefe linear incision—in order to enter the filtration angle (Fig. 428), and should include about two-fifths of the circumference of the globe at this plane. The incision may be made either above or below the horizontal meridian. It should be slowly enlarged in the same plane until the sum of the two incisions aggregates the length of the incision for iridectomy, namely, 7 to 8 mm., leaving a thin bridge of sclera at the apex. The knife is now turned on the flat, and the aqueous is permitted to escape slowly. When this is accomplished the knife is slowly withdrawn, care being taken not to permit prolapse of the iris. If prolapse occurs the iris should be carefully replaced (in cases where this cannot be readily accomplished, the iris may be excised). A drop of 0.5 per cent. solution of eserine may now be instilled and a compress bandage applied.

Fig. 428

Anterior sclerotomy.

The operation has not fulfilled the hopes of its originator. It is now employed chiefly as an adjuvant to iridectomy, namely, before iridectomy for temporary reduction in tension, after iridectomy in the place of a second iridectomy in cases where the reduction in the tension following the iridectomy is not as much as the case requires, also in hemorrhagic glaucoma, and in prodromal and simple glaucoma when the consent to iridectomy cannot be obtained.

Posterior Sclerotomy (*Paracentesis of the Posterior Chamber*).—Ordinarily, posterior sclerotomy is performed in the lower outer quadrant of the sclera, anterior to the equator of the globe and sufficiently far back to avoid wounding the ciliary body. The incision should stop at least 6 mm. from the corneal margin. Local anesthesia is employed. The lids are held apart by a wire speculum. The ocular conjunctiva and subconjunctival tissues are grasped with the fixation forceps opposite to the point where the incision is to be made, and the eye is rotated so as to expose the site of the incision. (It is convenient to pass a silk suture through the ocular conjunctiva and episcleral tissue, to be held by the assistant, in place of the forceps, to control the rotation of the eye.) A meridional incision is now made through the ocular conjunctiva and subconjunctival tissues, laying bare the sclera. If desirable, the margins of this wound may be separated by means of retractors. A Graefe knife is employed. The incision through the sclera should be meridional, beginning at about the equator of the globe and extending toward the centre of the cornea a sufficient distance (3 to 6 mm.); if for evacuating fluid in a case of detachment of the retina or as a preliminary to iridectomy, a short incision is sufficient. In both cases the knife is turned on the flat on completing the incision. In detachment of the retina the retinal fluid is permitted to flow out; as a preliminary operation to iridectomy a drop of vitreous is permitted to escape. When performed for relief of pain and decrease of tension in absolute glaucoma it is best to make the incision longer and to convert it into a T-shaped

incision by turning the knife and making a short arm (about 2 mm.) at right angles with the meridional incision. A few drops of vitreous should be permitted to escape. In removing foreign bodies and entozoa the size of the incision must be regulated by the size of the object to be removed. In completing the operation the vitreous that protrudes may be excised, the scleral edges approximated, and the ocular conjunctiva and subconjunctival tissue sutured over the scleral incision. When this operation is performed for detachment of the retina the sclera need not be laid bare by dissecting away the conjunctiva and subconjunctival tissue. Simple puncture will suffice, the subretinal fluid being permitted to escape subconjunctivally.

Sclerociliotomy.—This operation, as performed by Hancock for the cure of glaucoma (1860), consists in plunging a Beer's knife into the globe at the lower sclerocorneal junction, directing the point backward and a little downward (the cutting edge downward), making a *meridional* section that opens the anterior and posterior chambers, divides the ciliary body, and enters the vitreous chamber. The incision is made 4 to 5 mm. long and is in the sclera. As the knife is withdrawn it is turned slightly, permitting escape of the aqueous and some vitreous. The operation has not met with general favor, but Pollak reports having operated in this manner "between sixty and seventy times without a single failure." It must be borne in mind that wounds in the ciliary region are not devoid of danger.

Fig. 429



Hancock's operation.

Incision of Iris Angle (*de Vincentii's Operation*).—**Instruments.**—Speculum, fixation forceps, special sickle-shaped needle, so constructed that the aqueous will not escape during the operation.

Operation.—The sclera is pierced 1.5 mm. from the corneal margin, the anterior chamber entered, and the point of the needle carried across the anterior chamber to the opposite side, parallel to the plane of the iris. On withdrawing the needle the tissues at the iris angle (ligamentum pectinatum) are cut and Schlemm's canal opened into. The incision is made as long as possible. Tailer[1] reports sixty-two operations for glaucoma of various forms. The results were satisfactory. Sgrosso reports fifteen cases, eleven glaucoma simplex—tension and vision improved. There was a relapse in one case one month later.

Trephining the Sclera.—**Instruments.**—Speculum, mouse-tooth forceps, scissors, suture, trephine (von Hippel).

Operation.—Cocaine anesthesia is employed. The sclera is laid bare at a desirable point, usually between the margins of the external and inferior recti muscles, by dissecting through conjunctiva and subconjunctival tissue. The trephine, set to cut through the sclera only, is applied and a piece of the sclera removed (diameter 4 to 5 mm.). The chorioid and retina either rupture spontaneously or are punctured, and

[1] Lav. della clin. ocul. d. R. U. di Nap., iv, p. 197.

a bead of vitreous is permitted to escape. The conjunctiva and subconjunctival tissue are closed over the defect in the sclera and the eye is bandaged.

Cyclodialysis (*Heine's Operation*).[1]—**Instruments.**—Speculum, fixation forceps, scissors, keratome, iris spatula.

Operation.—*Stage* 1.—The sclera is exposed at some point 5 to 8 mm. from the corneal margin by dissecting up the conjunctiva.

Fig. 430

Heine's operation for cyclodialysis.

Stage 2. An equatorial incision 2 mm. long is made obliquely forward through the sclera, 5 to 8 mm. back of the corneal margin. The incision passes through the sclera only.

Stage 3.—The end of the spatula is then passed through the wound, kept in contact with the sclera, and passed forward through the annular ligament and ligamentum pectinatum until it appears in the anterior chamber. By lateral movements the ligaments are ruptured to the desired extent, separating ciliary body and iris from the sclera.

Stage 4.—The spatula is withdrawn (*a*) without permitting much escape of aqueous, in which case the tension is not reduced at once; (*b*) the spatula is rotated in withdrawal and aqueous escapes, reducing tension.

By this operation the perichorioidal space and the anterior chamber are made to communicate. Some irritation of the eye may follow and hemorrhage into the anterior chamber may occur. The first rapidly subsides and the second is soon absorbed.

Results.—The results of this operation, as studied by G. Weinicke[2] in the analysis of sixty-one patients on whom cyclodialysis had been performed 76 times are as follows: The cases were acute glaucoma, 9; hemorrhagic glaucoma, 4; subacute, chronic or absolute glaucoma, 31; simple glaucoma, 9; traumatic glaucoma, 2; buphthalmos, 7. Many of the cases were reported after a lapse of years. In 57 per cent. there was improvement as long as the cases were under observation: in 25 per cent., temporary improvement; in 18 per cent., no improvement. Of the 18 per cent., 9 were improved by subsequent cyclodialysis.

OPERATIONS ON NERVES OF THE EYE.

Laceration of Infratrochlear Nerve (*Badal's Operation*).—A curved incision is made along the border of the orbit, extending from the upper border of the internal canthal ligament $1\frac{1}{2}$ to 2 cm., cutting through the skin and orbicularis muscle. The nerve trunk pierces the septum orbitale at the margin of the orbit a very little higher than the upper border of the insertion of the inner canthal ligament. It is sought for

[1] Deutsch. med. Woch., No. 21, 1905.
[2] Klin. Monatsbl. f. Augenheilk., November and December, 1908.

in the cellular connective tissue, seized with forceps, and torn out or excised. The wound is closed by sutures.

Lagrange, as a result of eighty-one operations, concludes that the operation is capable of relieving pain in acute glaucoma, and even of lowering tension, but its effects are uncertain in chronic glaucoma. Other surgeons report similar results.

Opticociliary Neurotomy.—This operation is performed in various ways. The method employed by Golowin[1] appears to be well planned. The outer commissure and external rectus muscle are divided and the eye rotated strongly inward. Before dividing the optic nerve, ciliary nerves, and vessels they are seized with small clamp forceps 1 cm. behind the globe to prevent hemorrhage. The optic and ciliary nerves are then cut near the forceps, care being observed to include the bunch of ciliary nerves that lie beneath the internal rectus muscle. The globe is then rotated farther outward, and a section of the optic nerve and ciliary nerves separated from the globe and removed. If the forceps controlling the hemorrhage are permitted to remain in position ten minutes, hemorrhage does not occur to any great extent. The external rectus may be united by sutures,and the conjunctival wound closed. A firm compress bandage is necessary, as some bleeding may take place.

Results.—The eye may retain the appearance presented before the operation; the operation may be followed by hemorrhage into the tissue of the orbit producing exophthalmos or ulceration of the cornea, and atrophy of the globe due to trophic disturbances may result.

Golowin advises this operation in absolute glaucoma with pain; in absolute glaucoma without pain, when iridectomy is not possible; and in glaucoma when pain continues in spite of other operations. It has also been resorted to in painful but cosmetically perfect eyes without vision, due to other causes than glaucoma, and in eyes that threaten sympathetic inflammation (see page 391).

Resection of Superior Ganglion of Cervical Sympathetic.—Operation.—Three routes are open to the operator—one behind, one in front of and one through the sternomastoid muscle. The anterior route is the simpler and more direct. The incision need not be more than 5 cm. long; it should begin or end just anterior to the tip of the mastoid process, and extend along the anterior margin of the sternomastoid muscle. It is best to stop all bleeding, so far as possible, before passing the deep cervical fascia. The deep cervical fascia is now divided (grooved director may be employed). By means of a retractor, the sternomastoid muscle is drawn outward and backward. The spinal accessory nerve may now come into view as it passes into the sternomastoid muscle. The belly of the digastric muscle forms the base of a triangle that is now entered, which contains loose connective and some adipose tissue. The bundle of large vessels and the pneumogastric nerve lie along the anterior border of this triangle, and by continuing the blunt dissection these are soon found. The bundle of vessels and nerve are drawn

[1] Zeit. f. Augenheilk., v, p. 414.

gently forward and toward the median line. In the writer's experience, the sympathetic is always raised with the sheath of the large vessels. It is well to determine the location of the pneumogastric nerve, and to this end it is expedient to open the sheath of the vessels posteriorly. The white trunk of the pneumogastric nerve will then come into view. It should not be injured in any way. Search in the tissue of the sheath backward and a little inward will result in finding the sympathetic nerve. This should be followed upward by dull dissection until the superior ganglion is exposed. The lateral branches going to and from the ganglion should be divided, and the ganglion freed well up to the base of the skull; it may then be seized with forceps at its upper extremity and torn out, or it may be cut close to the skull. The trunk of the nerve just below the ganglion may then be cut across. The deep fascia is united by catgut sutures, the wound in the integument closed by means of a continuous suture, and the bandage applied.

Union by first intention usually follows. There is frequently slight swelling of the tissues in the vicinity of the wound, because of the trauma produced (for the indications for this operation, see page 418).

OPERATIVE TREATMENT OF CATARACT.

Preparation of Patient.—A patient who is operated upon for the extraction of cataract should remain in bed for a few days after the operation. It is advisable that he should be very quiet during the first twenty-four to forty-eight hours. To insure this, the general condition of the patient should be made as favorable as possible. Inquiry should be made regarding diseases of any nature, especially acute or chronic pulmonary trouble. Should either of these be present the operation should be postponed until the patient recovers, or, in case of chronic disease with recovery improbable, measures must be taken to prevent coughing.

An examination of the urine should be made in each case before the operation. If albumin or sugar is present, while the operation may not be contra-indicated (other conditions being favorable, the author has never hesitated to operate on account of the presence of albumin or sugar in the urine), the prognosis may be modified. The possibility of the occurrence of uremic or diabetic coma should be thought of. If acetonuria accompanies diabetes the danger of diabetic coma is much greater than if it does not, and it is better to delay operation until the acetonuria can be eliminated.

Local Precautions.—The lids, conjunctiva, and lachrymal apparatus should be carefully examined.

Lids.—Pustular blepharitis marginalis and suppurative processes on the skin of lids or face must be corrected before operating. The tendency to spastic ectropion should be looked for and precautions taken to prevent it.

Conjunctiva.—A bacteriological examination of the conjunctival secretions should be made within forty-eight hours of the time set for the

operation. If pathogenic or pyogenic germs in considerable number are found the operation should be postponed until they can be eliminated. Slight roughness of the conjunctiva, as after recovery from trachoma, or the slightly hyperemic condition of the conjunctiva as a result of a mild chronic conjunctivitis, sometimes met with in old people, need not prevent the operation, even if some mucoid discharge be present. It is best to treat such conditions for some days and to observe the case sufficiently long to become convinced of the innocuous nature of the condition before venturing to operate. The Meibomian glands should be inspected and some pressure on them should be made to determine the nature of their secretion. If the secretion from one or more glands is found to be purulent the operation should be postponed until the disease of the glands is recovered from.

Lithiasis conjunctivæ, if it exists, demands attention. The concretions should be carefully removed.

Lachrymal Apparatus.—The secreting portion seldom presents conditions that are inimical to operations on the globe, but the *conducting portion* is often at fault and should always be carefully examined. Pathogenic and pyogenic germs abound in the secretion in dacryocystitis; this condition, if it exists, should be corrected before the eyeball is opened. Extirpation of the lachrymal sac may become necessary. If there is disease of the lachrymal passages the nasal mucous membrane should be examined and treated if not normal.

Antisepsis.—It is the custom of some surgeons to wash the conjunctiva with a solution of boric acid, 3 per cent., or of the bichloride of mercury, 1 to 5000, and to bandage the eyes over night, using a dressing moistened in the bichloride solution. Some mucoid secretion will invariably be found on that part of the dressing corresponding to the palpebral fissure in the morning, and virile microörganisms may sometimes be found in the secretion. J. A. White,[1] after cleansing the conjunctival sac and eyelids, introduces an ointment of the bichloride of mercury, 1 to 3000, and bandages the eye over night. The bandage is removed just before operation; this is an excellent procedure. There is no doubt that many surface microörganisms will be destroyed, but complete sterilization of lids or conjunctiva cannot be so obtained, nor can it be reached by any practical method. Fortunately, few of the microörganisms on the normal conjunctiva are pathogenic or pyogenic.[2]

[1] Trans. Sec. on Oph., Amer. Med. Assoc., 1904.

WHITE'S OINTMENT.

℞—Mercuric chloride	. . . . .	gr. j
Sodium chloride	. . . . .	gr. vi
Vaseline	. . . . .	℥ vi

Boil the vaseline and add the salts dissolved in a few drops of water to the hot vaseline.

[2] Herbert (Cataract Extraction, 1903, 1.25) advises irrigating the conjunctival sacs with a solution of the bichloride of mercury, 1 to 3000, ten minutes before operation, and writes of its effects as follows: "Strong perchloride, in virtue of its irritating and coagulating properties, produces in normal and nearly normal membranes a rapid secretion of mucus, with shedding of the superficial epithelium, so that after the ten-minute cocaine interval the accumulated result is ordinarily seen in

After years of experience with various methods of antisepsis the author now proceeds as follows: (The operation for the extraction is almost always performed when the patient is in the bed that he is to occupy during the progress of the healing.) Fifteen to twenty minutes before the operation the skin of the face and lids is scrubbed with soap and water, particular attention being paid to the hair of the brows. The surface is then thoroughly washed with a solution of mercuric chloride, 1 to 5000, and the conjunctival sac is irrigated with a sterile solution of boric acid. The lids are then covered with a pad of absorbent cotton moistened in the mercuric chloride solution. Just before the operation the margins of the lids are carefully inspected and cleansed with a solution of mercuric chloride. The Meibomian glands, caruncle, lachrymal canaliculi, and sac are carefully inspected and properly cared for. The conjunctival sac is flushed out with boric-acid solution. Care is taken not to unduly irritate the conjunctiva. During the operation the eye is frequently irrigated with a tepid normal saline or boric-acid solution. If an eye is not practically sterile, as shown by the bacteriological examination, the operation is deferred.

Anesthesia.—General Anesthesia.—This is seldom employed. In rare cases of nervous and irresponsible adults and in small children it is resorted to. In children, chloroform is preferred; in adults, ether preceded by nitrous oxide gas. The subsequent general annoyance, nausea, vomiting, etc., is prejudicial to the satisfactory healing of the wound, consequently general anesthesia should be avoided if possible.

Local Anesthesia.—In anesthetizing the eye for the extraction of cataract it is advisable to accomplish it so thoroughly that the iris also will be anesthetized in order that an iridectomy, if necessary, can be performed without pain to the patient. Sterile solutions of cocaine muriate (4 per cent.) and holocain muriate (1 per cent.) are used. The anesthesia is commenced by instilling one to three drops of the cocaine solution every three minutes until five instillations are made, beginning fifteen minutes before the operation is commenced. The eyes are kept closed during the intervals to prevent desiccation and loss of corneal epithelium. A drop of cocaine solution is instilled into the fellow eye to render it less sensitive and to enable the patient to open that eye readily should the surgeon require it.

Adrenalin.—In order to render the bleeding as slight as possible in case a conjunctival flap is to be made, one or two drops of a sterile solution of adrenalin chloride (1 to 5000 to 1 to 10,000) are put into the eye about three minutes before the operation is commenced. It not only blanches the external tissues, but also causes some constriction of the vessels of the iris. It also appears to increase the anesthetic effect of the cocaine.

readily removable flakes of mucus lying in the fornices, with possibly a trace of membrane formation over the tarsi." Here we have an obvious explanation, on the one hand, of the way in which micro-organisms may be protected against the germicide action of the lotion, being embedded in this mucus, and, on the other hand, of a ready means of removal of the organisms by simply washing away this accumulation. He reports a series of 497 consecutive cases of extraction free from grave infection.

Holocain.—As is well known, the anesthetic effect of holocain in 1 to 2 per cent. solution is more pronounced than that of cocaine. It also affects the tissues more rapidly, requiring only about thirty seconds to produce anesthesia. A 1 per cent. solution of holocain is dropped into the eye just after the corneal incision is made (also sometimes immediately before the incision is commenced), a slight gaping of the wound enables the solution to reach the iris. If this is done an iridectomy may be made without pain of moment to the patient.

Eyelashes.—If the eyelashes are apt to fall against the knife at any point they may be cut off at that part of the lid only. Epilation is painful to the patient and is unnecessary.

Fig. 431

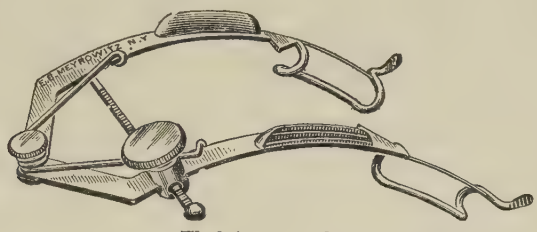

Weeks' eye speculum.

Instruments.—**Speculum.**—The speculum should possess the following qualities:

1. It should be as light as possible, compatible with strength and rigidity.
2. It should not press or drag upon the eyeball, but should tend to raise the lid from the globe.
3. The retractor blade should be about 15 mm. long, should engage the lid to a depth of about 4 mm., and should be supplied with a wire bar (or should not be fenestrated) to retract the eyelashes.
4. The catch, screw, or spring for regulating the spread of the speculum should be capable of easy manipulation.

Fig. 432



Graefe's fixation forceps with catch.

Fixation Forceps.—A number of models are in use. Operators differ in their preferences. The author prefers forceps with blades measuring 3 to 3.5 mm. in width, the free ends slightly curved to conform to the curve of the globe, and bearing small, sharp-pointed teeth, four on one blade and five on the opposing blade, and made sharp so that the teeth may pierce the superficial layers of the sclera. The forceps should not be unnecessarily heavy or cumbersome, should be sufficiently rigid, the spring easy, and the catch unfailing and easily released.

Knife.—The knife should be of the Graefe pattern. The blade should be 3 cm. in length and should not exceed 2.25 mm. in width—preferably 2 mm. or very slightly less. A wider knife passes less readily because of greater friction, and does not permit of easy change in the plane of the section. It should be as thin as is compatible with rigidity, and the back should be bevelled on both sides. The third toward the point should be nearly of "uniform taper," the remaining two-thirds

Fig. 433 Fig. 434 Fig. 435 Fig. 436 Fig. 437 Fig. 438 Fig. 439



Modified Graefe cataract knives.

Fig. 433.—De Wecker's.
Fig. 434.—Schiel's.
Fig. 435.—Schweigger's.
Fig. 436.—Terson's.
Fig. 437.—Nicati's.
Fig. 438.—Mengin's.
Fig. 439.—Double-edged.

of uniform width. The back and cutting edge should taper approximately evenly; a very "bellying" cutting edge does not enter easily. The point of the knife should be rigid on moderate pressure. Very thin elastic points are apt to cause a change in the direction of the puncture and counterpuncture, being easily deflected while penetrating the fibrous coat. The point and cutting edge must be as sharp as possible.

Fig. 440



Iris forceps.

Iris Forceps.—These should be about 9 cm. long, should be delicately made, blades curved, and armed with one tooth on the male and two

on the female blade. The teeth should be placed at the ends of the blades, and so made that they will present a smooth surface when closed. The spring should not be too stiff.

Iris Scissors.—The iris scissors should be 10.5 cm. to 11 cm. long, curved on the flat, blades thin with moderately dull points. They should be well made (De Wecker's iris scissors are also excellent.)

Fig. 441



Iris scissors.

Cystitome.—The small Knapp cystitome with a flexible shank is an excellent one. The cystitome should have a curved cutting edge, the point should project below the shank about 0.5 mm., the capsule

Fig. 442

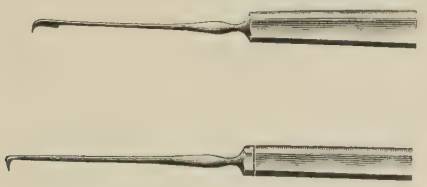

Cystitomes.

should be cut, not torn, and the point of the cystitome should not be long enough to engage in the lens substance except in the slightest degree, otherwise a partial rotation or a dislocation of the lens may result from its use.

Fig. 443



Smith's capsule forceps.

Capsule Forceps.—Many operators use special forceps for removing a portion of the anterior part of the lens capsule, either in connection with or without the cystitome. The capsule forceps of Smith, of Detroit (Fig. 443), are excellent.

Spoon.—This may be made of metal or hard rubber. On account of facility in sterilizing, the metal spoon is better. Bowman's, Critchett's, or Daviel's spoons are suitable.

Fig. 444

Bowman's flat lens spoon.

Spatula.—A flexible metal spatula of the ordinary pattern is suitable. A very serviceable instrument is one having a spatula on one end and a small bulbous-pointed probe on the other end of the handle.

Fig. 445

Spatula and probe.

Scissors.—Scissors for enlarging the incision should be ready. Strong scissors with fine points are best (Stevens).

Fig. 446



Stevens' scissors.

Vectis.—A fenestrated lens spoon or a smooth flexible wire loop should be on the instrument tray for use should it be necessary to remove the lens by traction. If a wire loop is employed the wire should be fairly stiff.

Fig. 447

Wire loop or vectis.

Lid Retractor.—A Desmarres lid retractor (see page 115) or a strabismus hook should be on the tray.

Incision.[1]—**Desirable Features.**—(1) The incision must be large enough to permit the lens to escape readily. If a linear incision or an incision approaching the linear incision is made the length of the incision should be 10.5 to 12 mm. If a flap incision is employed it should include two-fifths of the circumference of the cornea for a moderately large cataract if an iridectomy is to be made, and a little more than two-fifths of the circumference of the cornea if a simple extraction is contemplated.

2. The incision should be placed where the healing of the wound will be rapid. While incisions that lie wholly or in part in the cornea are permissible in young individuals whose nutritive processes are vigorous, it is not desirable to place the wound in clear cornea in the aged or feeble because of the danger of imperfect or retarded healing.

Fig. 448

Daviel's incision.

Fig. 449

Daviel's later incision.

Fig. 450

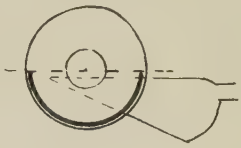

Richter's incision (Beer's knife.)

Fig. 451

De Wenzel's incision

Fig. 452

Santerelli's incision.

Fig. 453

Wardrop's incision.

Fig. 454

Guthrie's incision.

Fig. 455

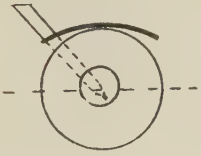

Graefe's incision.

Fig. 456

Jacobson's incision.

Fig. 457

Critchett's incision.

Fig. 458

Horner's incision

Fig. 459

Steffan's incision.

[1] Daviel's incision (1772). (Mémoirs de l'Académie Roy. de la Chirurgie, Paris, 1753, Tome ii, p. 337.)

Fig. 460

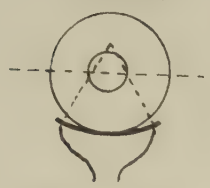

Weber's incision.

Fig. 461

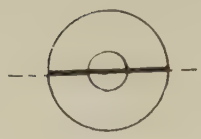

Kuchler's incision.

Fig. 462

Le Brun's incision.

Fig. 463

Liebreich's incision.

Fig. 464

Ed. de Jager's incision.

Fig. 465

Horner's incision (after Muralt).

Fig. 466

De Wecker's incision.

Fig. 467

Snellen's incision.

Fig. 468

Modifications.

Fig. 469

"Shoulder" incision.

Fig. 470

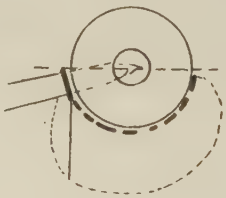

Czermak's incision.

Fig 471

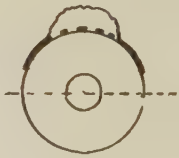

Incision practised by the writer.

In all such cases the incision should lie in the limbus or a very little back of the limbus, where the nutrition necessary to promote healing will be supplied directly and abundantly.

3. The incisions should be placed so that the field of operation will not be too greatly interfered with by hemorrhage.

4. The incision should not be made too close to the ciliary body.

In the opinion of the writer, a desirable incision is one located in the limbus, including about two-fifths of the circumference of the cornea, directed upward and terminating with a conjunctival flap.

Position of Patient.—Whether the patient is in the sitting or the prone position during the operation, the head should be so placed that the vertical transverse plane dips 15 or 20 degrees from the horizontal—the

chin lower than the forehead. This is attained in the chair by the position of the head-rest; when the patient lies on the operating table or bed the position may be obtained by means of suitable cushions.

Position of Surgeon.—Operators in the United States prefer, as a rule, to stand behind the patient while making the incision for both eyes, using the right hand for the right, the left hand for the left eye. The ability to do this is soon acquired, whether the surgeon is ordinarily ambidextrous or not. If it is impossible to use the left hand for making the incision in the left eye, it becomes necessary to stand or sit in front of the patient while making this incision, when the surgeon must cut away from himself. The height of the patient's head should be so regulated that the surgeon's hands and arms will not be in a cramped position—ordinarily on a level with the elbow. On the continent many operators stand on the right side of the patient for all operations, the patient being in the recumbent or semi-recumbent position.

Combined Operation (*Extraction with Iridectomy*).—**Indications.**—In hypermature cataract with thickened capsule; in swollen cataract; in cataract with posterior synechiæ; in patients with rigid scleræ and with increased tension; in very aged individuals, and in those of a nervous temperament who would be greatly disturbed should prolapse of the iris occur subsequently; in the rheumatic or gouty; in complicated cataract; in cases in which one eye has been lost from any cause; when the iris is sluggish or atrophic; and during simple extraction if difficulty is experienced in replacing the iris—the combined operation should be performed.

The operator should bear in mind the fact that vision after extraction with iridectomy is as good as by any other method, that removal of the lens substance is accomplished with greater facility when an iridectomy is made, and that complications involving the iris are much less liable to occur.

Operation (**Right Eye**).—The speculum is introduced by first engaging the upper lid, then, with the speculum closed, engaging the lower lid. The blades of the speculum are then permitted to spread until the tissues at the outer and inner canthi are put on the stretch, but not sufficiently to occasion pain (just short of the maximum), and then fixed. The conjunctival sac should now be freely irrigated with a tepid sterile boric acid or normal saline solution. The knife is grasped between the thumb, index, and middle fingers, so that the axis of the handle is almost at right angles with the axes of the digits. This affords a freedom of movement and control that can be obtained in no other way. The fixation forceps are grasped in the left hand in the same manner, the thumb being on the side of the catch, in order that the forceps may be quickly and easily released. The blades of the forceps, closed, are placed on the globe meridionally 1 mm. from the margin of the cornea and a little below the horizontal meridian to the nasal side. The blades are then permitted to separate about 4 mm., and while slightly increasing the pressure on the globe the forceps are closed, including the conjunctiva, the anterior insertion of Tenon's capsule, and, if possible, some of the superficial fibers

of the sclera. This attachment serves to fix the globe and to afford counterpressure for the counterpuncture.

The patient is now directed to look downward, or at some object slightly above the horizon, so that the upper part of the cornea is exposed; the eye is held in this position. The right hand is steadied by resting the little finger against the temple or side of the head. The point of the knife is made to pierce the cornea at the limbus 1.5 mm. above the horizontal meridian in a direction slightly backward from a plane cutting the circumference of the cornea. As soon as the point appears in the anterior chamber, it is steadily carried across the chamber to the point of counterpuncture, which should correspond to the puncture. The knife is carried steadily on, making the counterpuncture without raising the conjunctiva, and stopping just short of the margin of the lid. Up to this point there

Fig. 472

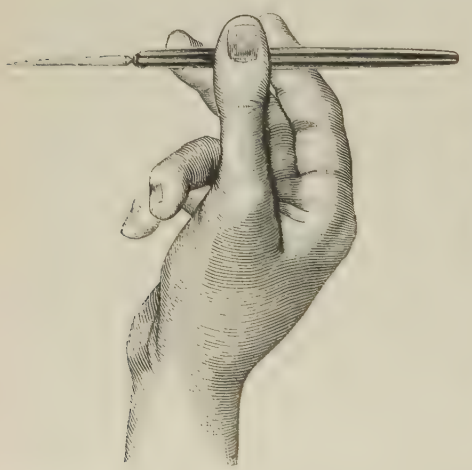

Method of holding the straight Graefe knife for upward incision. (Czermak.)

Fig. 473

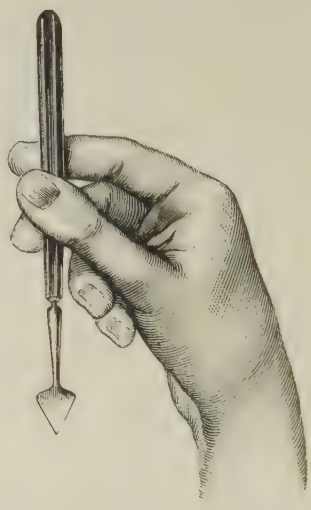

Method of holding the bent keratome for incision of the upper corneal margin. (Czermak.)

need have been but little, if any, loss of aqueous humor. The plane of the knife should be parallel to the plane of the base of the cornea, and should not be changed until the conjunctival flap is being formed. By a long, steady, rather quick to-and-fro movement of the knife, keeping the cutting edge gently pressed against the corneal tissue, the section is carried above the pupillary margin of the iris; the section is then completed more deliberately, the final division of the fibrous coat being made slowly to prevent prolapse of iris. The edge of the knife is now changed to upward and backward, and the conjunctival flap made of the desired length. The direction of the force applied to the knife should be in the axis of the blade. If pressure is so exerted that the blade is caused to bend on the flat before the counterpuncture is made, the point of exit will be changed and a very faulty incision may result. The conjunctival flap is pushed forward over

the cornea by means of the knife, immediately after it is formed; the knife is then handed to an assistant and one or two drops of holocain (1 per cent.) are dropped into the wound.

Iridectomy.—If the patient is tractable the fixation forceps may now be removed, otherwise they should be transferred to a trained assistant, who should hold them without pressing or dragging on the eye. The operator should not be obliged to look for the other instruments needed. They should be handed to him by an assistant while he gives his whole attention to the patient.

The *iris scissors* are grasped in the right hand on the side of the convexity of the blades, the thumb and third finger engaging the fenestra of the handles.

The *iris forceps* are grasped, as are the knife and fixation forceps, between the ends of the thumb and first two fingers. The forceps should be closed and the blades caused to enter the eye in the vertical meridian, passing almost to the pupillary margin. The forceps are then permitted to open and the fold of the iris that falls between the blades is grasped and pulled outside of the wound. (In order to effect this maneuver the operator is obliged to step a little to the right and to the side of the patient's head.) A small iridectomy is all that is necessary. It may be obtained by cutting the iris at right angles with the incision, or the iris may be excised in the line of the incision. One stroke should suffice. The cut may be made with a free hand, or the hand may be steadied by resting it gently on the face. This can readily be done if the hand is held below the scissors, the convex surface of the scissors being directed toward the globe. (The iris scissors of De Wecker are preferred by some operators, Fig. 419.) The patient may experience slight pain when the iris is seized and excised, and should be cautioned to that effect and directed not to move the eyeball. (It is often necessary to hold the eye with the fixation forceps, gently but firmly, at this stage.)

Removal of a Portion of Capsule of Lens.—If capsule forceps are employed they should enter the anterior chamber as the iris forceps are entered, the points of the closed blades being carried nearly to the opposite margin of the pupil. They are then opened almost as wide as the pupil, slight pressure is made, and the blades are closed, grasping the capsule. The included piece is withdrawn. (It may be liberated in physiological salt solution, to determine the size.) If the opening obtained in the capsule is not of sufficient size the cystitome may be employed to enlarge it.

Capsulotomy.—The fixation forceps, if in place, are now taken charge of by the operator. The cystitome with a straight shaft (Fig. 442) may be used when iridectomy has been performed, or the shaft may be bent at an oblique angle 8 mm. from the point, in such a manner that the back of the cystitome will enter the wound first. (In simple extraction the bent cystitome should be used.) The cystitome is now introduced, back downward, parallel to the line of puncture and counterpuncture, the end of the instrument being just above the nasal margin of the pupil, carried into the eye without interfering with iris or lens until it has

passed over one-third of the vertical diameter of the lens, when the point is carried slightly beneath the nasal margin of the iris. The blade is then turned so that the cutting edge will present to the capsule. The capsule is pierced by gentle pressure and the knife is drawn toward the temporal side, describing a gentle curve, with the concavity downward, until the capsule is cut to a point corresponding with the commencement of the incision. The insertion of the suspensory ligament must not be interfered with. This constitutes the peripheral capsulotomy. This may be converted into a T-shaped capsulotomy by carrying the point of the cystitome between capsule and cornea to the lower margin of the pupil and cutting upward, causing the vertical to meet the curved incision. (The peripheral capsulotomy is preferred by Knapp.) The cystitome is withdrawn from the eye back upward, in order not to engage the tissues of the eye.

Extraction of Lens.—The eye is now released from the grasp of the fixation forceps, care being observed not to permit the blades of the forceps to spring apart suddenly. It the patient is restless or not easily controlled, or if the speculum tends to press against the eyeball, it is removed; otherwise the speculum may remain until the lens is extracted, or even until the "toilet" of the wound is complete. If the speculum is removed the lids may be controlled by the operator or by an assistant. It is often desirable to raise the upper lid by means of a lid retractor (Fig. 84). The lower lid should be carefully controlled, as it is the source of greatest danger. The lens spoon is grasped in the right hand and the spatula in the left hand (the reverse for the left eye), each instrument being held as directed for holding the cataract knife. The eye should be rotated downward. The curved blade of the spatula is held where it may be ready for immediate use, to exert pressure upon the sclera, to control the conjunctival flap, or to assist in the exit of the lens. Pressure is now made with the back of the lens spoon at the lower margin of the cornea, the pressure being gentle, steady, and firm, and directed toward the centre of curvature of the globe. Pressure so made will cause the upper margin of the lens to tilt forward into the wound (Fig. 474). The direction of the pressure should not be changed until the lens presents. Intermittent pressure may be serviceable in some cases, but an even, steady pressure is usually better. As the lens advances, the direction of the pressure may be gradually changed to follow the lens, keeping well at the lower border. As the greatest diameter of the lens passes through the section pressure is much reduced, the spoon is made to pass upward over the cornea slowly, with gentle pressure, in order to

Fig. 474

Pressure employed in extracting cataract. *a*. Spatula (exaggerated). *b*. Daviel's spoon. (Modified from Morax.)

cause as much of the lens substance as possible to escape. If fragments of cortical lens substance remain the lens spoon may be passed over the cornea from below upward a number of times. If the pupil is clear and black no further efforts to remove lens substance need be made. If cortical substance still remains the anterior chamber may be irrigated with a sterile physiological salt solution. If this becomes necessary the speculum (if in position) should be removed before irrigation is performed, except in the most tractable patients.

Many instruments have been devised for irrigating the anterior chamber. One of the best is a small flexible rubber bulb with a capacity of one to two ounces, to which is attached a detachable glass nozzle, flattened at the end and slightly curved on the flat. This can be readily and thoroughly sterilized, is under the complete control of the operator, is simple, and can be manipulated with ease. In irrigating the anterior chamber the eye should be rotated downward, the nozzle of the irrigator should be gently pressed against the scleral lip, causing the wound to gape slightly. The solution should flow into and out of the anterior chamber freely. The force required must be judged by the operator. The nozzle of the irrigator may be introduced into the anterior chamber for a short distance, if it seems desirable to do so, without danger, provided the nozzle is kept away from the zonula or capsule of the lens.

Fig. 475

Instrument for irrigation of the anterior chamber.

Toilet of Wound.—After the extraction of the lens, if the patient appears to be at all fatigued, a light pad of absorbent cotton, moistened in boric-acid solution, may be applied to both eyes and be permitted to remain for a few minutes. All clots and shreds of fibrin are removed afterward by means of the clot forceps, and the conjunctival sac irrigated to remove all debris. The iris is freed from the angles of the wound by means of the spatula. The spatula is held as directed for the cataract knife, and the point, suitably bent, is introduced into the anterior chamber, passing between the iris and the cornea at either angle of the wound. (If the operator is ambidextrous the spatula should be held in the right hand for dislodging the iris at the left angle of the wound, and in the left hand for dislodging the iris from the right angle of the wound.) By gently stroking the iris it may be dislodged and the remaining portion restored to its normal position. All shreds of fibrin, portions of capsule, and particles of cortical substance should be removed and the conjunctival flap carefully adjusted. When finished the margins of the wound should be in perfect apposition. The conjunctival sac may again be carefully irrigated, a drop of 1 per cent. solution of the sulphate of atropine instilled, and the eye bandaged.

Bandage.—The writer proceeds as follows: The patient is directed to close the eyes, and one or two layers of thin sterile gauze—cut to form and

moistened with a solution of boric acid—are smeared on one side with sterile vaseline, borated vaseline, or mercuric chloride vaseline (1 to 5000), and the smeared surface nicely adjusted to the eyelids. A thin pad of dry cotton is now applied. This is sometimes held in place by a single strip of isinglass adhesive plaster; over this a thin gauze bandage (figure of eight) is applied, only enough turns being used to keep it in place. Both eyes are bandaged. A papier maché mask (Ring's) is put over this, and the patient is instructed to lie as quietly as possible for the first twenty-four hours.

Simple Extraction.—**Indications.**—If the lens is not swollen, the cataract mature, and the iris reacts readily to stimulus of light, provided there is no definite indication for the performance of iridectomy (see page 841), simple extraction may be done. The cosmetic effect is better than after iridectomy, and because of this not a few individuals prefer it. Fortunately, this desire is much greater in young persons in whom the operation is most likely to be successful. It must be borne in mind that prolapse of the iris after extraction is a *distressing complication*, and that it should be avoided if possible.

Section.—As in the "combined operation," except that the section may be a very little larger. In all other respects the operation is as the combined method, except that the iridectomy is omitted.

Should there be any indication of a probable subsequent prolapse, as the retention of considerable lens substance, injury to the iris on extraction of the lens, impossibility to obtain a central circular pupil, or continued pressure by the patient, an iridectomy should be made.[1]

Anglecucci[2] advocates the following method of fixing the eye, doing away with the speculum. The conjunctiva and underlying tendon of the superior rectus muscle are grasped with broad fixation forceps. This serves to hold up the upper lid as well as to fix the eye. The capsulotomy is done with the cataract knife between puncture and counter-puncture. This method is simple, but possesses some elements of danger. The pressure of the upper lid against the fixation forceps with spasm of the orbicularis muscle may cause prolapse of vitreous, and the capsulotomy with the cataract knife is less safe than with the capsulotome.

Instead of an iridectomy some operators perform iridotomy in order to facilitate the escape of the lens. This was described by Beer in 1792. It has been revived by Chareimac,[3] Galezowski, and others.

Corneal Suture.—A number of surgeons have employed sutures for the closure of the wound after the extraction. Williams[4] reported having treated fifty-four cases in this way. He used a single fine

[1] A few operators dispense with the speculum, separating the lids by means of the fingers. This is done either by the operator or by a skilled assistant. The fixation forceps may also be dispensed with (Trousseau), the globe being steadied by gentle pressure. The section and capsulotomy are made with the cataract knife, and the lens is expressed by pressure through the lower lid, counter-pressure by means of the border of the upper lid against the scleral flap.

[2] Arch. di ottalm., v, p. 71.

[3] Ann. d'ocul., January and February, 1883.

[4] Trans. Am. Oph. Soc., 1866, p. 45, and 1868, p. 58.

thread, inserting it after the section was made, removing it after the fifth day.

Mendozo[1] inserts the suture before the section is made, looping the suture and cutting between the two points of insertion. The suture is removed in five days. The introduction of a suture, if it passes through corneal or scleral tissue, is somewhat difficult of application, adds a disturbing element, and, except in very rare cases, is unnecessary.

Chandler's "Modified Simple Extraction."[2]—After extraction of the lens, before the cortical substance is removed, the iris is seized near its insertion by means of delicate forceps, with the teeth placed at the ends of the blades. The seized portion of the iris is withdrawn from the wound and snipped off by means of thin-bladed scissors; the piece removed should be approximately 1 mm. in diameter. Through the opening thus made, retained cortical lens substance is permitted to escape. The operation was devised to avoid prolapse of the iris after simple extraction. Chandler reports three hundred and thirteen cases with four prolapses, two of which were the result of violence after the anterior chamber had been restored. Since the average of prolapse in simple extraction by good operators is approximately 6 per cent., the reduction by this method is very satisfactory.

Accidents during Operation.—The speculum sometimes becomes displaced; this accident is seldom of a serious nature. In removing the speculum, undue pressure may be made on the globe with one or the other blade, causing loss of vitreous.

On grasping the globe with the fixation forceps, one of the larger anterior ciliary vessels may be torn across, causing subconjunctival hemorrhage of such proportions that the ocular conjunctiva will be considerably elevated, making the section difficult. Under these circumstances it is best to abandon the operation until the blood has been absorbed.

Section.—On entering the anterior chamber the point of the knife may engage the iris. If aqueous has not been lost, the knife may be partly withdrawn to disengage the iris and the section completed. In making the counterpuncture the point of the knife may engage the cornea too far in front, or it may pass too far backward, endangering the iris. It is better to proceed slowly and to partly withdraw the knife in order to have the counterpuncture in the proper place.

Prolapse of Iris before Knife.—If an iridectomy is contemplated the section may be completed. If not, the knife may be withdrawn and the operation proceeded with some days later. When the iris is cut by the knife the patient experiences more or less pain from the dragging as well as from the cutting. A satisfactory iridectomy is seldom made with the cataract knife; it must be completed subsequently. All tags of iris should be carefully excised.

On account of a rather shallow anterior chamber it may be impossible to make the section sufficiently large with the knife without wounding

[1] Soc. d'opht. de Paris, December 4, 1888.

[2] Arch. of Ophth., xxxiii, No. 1, p. 1.

the iris. Again, it may be found after the section has been made with the knife that it is too small. The section must then be enlarged. This is done by means of a pair of scissors. The Stevens scissors (Fig. 447) are excellent for this purpose. The section is enlarged from one or both of the extremities of the incision, as desired.

The knife may be introduced with the cutting edge in the wrong direction. When this occurs it is sometimes possible to rotate the knife quickly, the back of the knife passing next to the iris, and to complete the section. If aqueous humor has been lost it is better to withdraw the knife and to postpone the operation until the anterior chamber has refilled.

The iris may prolapse immediately on completing the section. This is usually due to the too sudden escape of aqueous humor. If an iridectomy is to be done, this is not a disadvantage, as the iris may be seized without entering the anterior chamber. If no iridectomy is contemplated the iris may be replaced by the spatula before proceeding farther.

Hemorrhage.—Hemorrhage may be profuse from conjunctiva and iris and fill the anterior chamber. The blood may be sufficiently removed, so that it will not obstruct the field of operation, by stroking the cornea from below upward with the spatula or irrigating with physiological salt solution. However, it is sometimes necessary to wait a few minutes to permit the hemorrhage to cease. Gentle pressure by means of a pad of moistened gauze will aid in controlling the hemorrhage. If the bleeding continues, so as to mask the field of operation, the cystitome should be introduced and the capsulotomy made as well as possible. The lens should then be expressed. Much, if not all, of the blood escapes with the lens, and the anterior chamber frequently remains free.

When the capsulotomy is being performed, the lens may be partly or wholly dislocated. If partly dislocated, the expression of the lens may be accomplished in the ordinary way. If totally dislocated, the lens spoon or wire loop (vectis) should be employed. The capsulotomy may not have been made, or may not have been sufficiently extensive. In such cases the lens *in its capsule* may present at the wound and refuse to advance. An incision in the presenting capsule should be made at this stage.

Loss of Vitreous.—This may occur at any stage of the operation after the incision has commenced, and may be due to the patient, or to the operator, or to the condition of the eye. The most frequent cause is spasm of the orbicularis exerting direct pressure on the globe or forcing the speculum against the globe. If the vitreous escapes before the section is completed it is evident that the suspensory ligament is deficient in some part. The removal of the lens by means of the lens spoon or by means of the wire loop then becomes necessary. Immediately after the completion of the section, spasm of the orbicularis may take place and the lens may be forcibly expelled, followed by vitreous. In making the capsulotomy, the instrument may rupture the suspensory ligament and loss of vitreous precede or follow the expulsion of the lens; or the lens

may be dislocated, causing loss of vitreous. In expressing the lens, it may be held by the capsule and rupture of the suspensory ligament may take place, causing loss of vitreous. Loss of vitreous may attend the attempt to remove cortical lens matter, whether it is done by expression or irrigation. Pressure from the lower lid is more to be dreaded than pressure from the upper lid. It is consequently wise to carefully control the lower lid, usually by slight downward traction, from the time the speculum is removed until the toilet of the wound is completed. Escape of vitreous after the eye has been dressed is due either to an over-tight bandage, to strain in vomiting or coughing, or to traumatism. The vitreous may simply present in the wound, parting the lips of the wound and pressing the corneal flap forward. After the escape of vitreous the cornea may collapse, the edge of the corneal flap passing beneath the edge of the sclera. Fluid vitreous with deficient suspensory ligament is sometimes met with. When this condition obtains, section for the removal of cataract is attended by collapse of the globe.

Treatment.—If the vitreous lies in the wound and is of sufficient consistence to keep the lips of the wounds separated it should be excised, provided this can be done without causing much additional loss, and the margins of the wound approximated. It is sometimes, but not very often, better to close the eye at once and to apply a dressing, omitting the toilet of the wound. If the eyeball becomes collapsed, normal saline solution may be injected for the purpose of filling out the globe.

Results.—The contour of the globe is usually restored in twenty-four hours, whether shreds of vitreous lie in the wound or not. The wound may be smoothly closed, or shreds of vitreous may be hanging from it. If possible, these shreds should be removed by means of scissors, or by the cautery, at the end of twenty-four or forty-eight hours. They excite irritation and facilitate the passage of microörganisms into the interior of the eye. In intractable patients the shreds of vitreous must be permitted to come away spontaneously. This usually occurs in from four to seven days, and if infection has not taken place satisfactory, healing follows. Useful vision is often obtained, even if loss of vitreous does occur, but the accident is one to be avoided if possible, as subsequent undesirable conditions are apt to arise, such as floating bodies in the vitreous chamber, connective-tissue bands, and detachment of the retina.

The frequency of loss of vitreous varies with different operators. Hubert[1] reports 5 per cent. of loss of vitreous in 1484 extractions.

Catching of Corneal Flap.—The corneal flap is sometimes caught in the blade of the forceps, or by the margin of the lid, and folded forward; when this happens the flap should be quickly restored.

Hemorrhage from Fundus (*Explosive Hemorrhage*).—The intra-ocular hemorrhage that sometimes occurs after cataract extraction is of all degrees of severity. A few or many hemorrhages may occur in the retina, small or copious hemorrhages may take place from the chorioid and ciliary body. Frequently the first intimation of intra-ocular hemorrhage

[1] Cataract Extraction, p. 42.

is a bulging of the vitreous into the wound. In some cases the vitreous and retina are forced out through the incision.

Treatment.—A pressure bandage must be applied and kept in position until the hemorrhage has ceased, or, if there is much pain, the bandage is removed and cold compresses applied. Subsequently the globe shrinks and enucleation becomes necessary.

After-treatment in Extraction of Cataract.—The patient is ordinarily kept in a moderately darkened room, but healing progresses equally well in the open ward. The eye is inspected at the end of twenty-four hours if iridectomy has been performed, and atropine instilled. If iridectomy has not been performed, the first inspection is made forty-eight hours after the operation, provided there is no evidence of any complication—no pain in or about the eye, bandage not misplaced, etc. If there is evidence of disturbance, the eye is inspected whenever this becomes apparent. The bandage or other dressing is kept on both eyes from three to five days, and on the operated eye five to eight days, if all goes well.

Linear Extraction.—**Indications.**—This method is applicable for the removal of cataractous lenses before the nucleus has become hard. It is most largely employed to remove cataractous lens substance after discission for congenital cataract, and as the second procedure in the removal of the lens in high myopia. After traumatism resulting in rupture of the lens capsule and swelling of the lens substance, and when increased tension of the globe is due to the presence of soft swollen lens substance, linear extraction is strongly indicated. The operation is seldom advisable after the age of twenty-five years, but in high myopia and in exceptional cases it may be the best operation to perform up to a much later period of life.

Instruments.—Speculum; knife: (*a*) triangular keratome bent on the flat (Fig. 408), (*b*) broad needle bent on the flat (Fig. 405), or (*c*) a Graefe knife; fixation forceps; cystitome; spatula; lens spoon.

Operation.—A linear incision is made through the cornea 5 mm. in length midway between the corneal margin and the centre of the cornea, using either of the cutting instruments described. If not already disintegrated, the lens is freely broken up by means of the cystitome. Pressure is now made on the outer edge of the wound with the spatula to cause the wound to gape. The soft lens matter will flow out; this may be gently assisted by stroking the cornea with the lens spoon. Irrigation with normal saline solution will greatly aid in removing particles of lens substance. The margins of the wound are now carefully adjusted, atropine instilled, and the eyes bandaged. Dressing is renewed once daily. The non-operated eye is freed on the second day; the operated eye on the fifth day. During the healing process the iris must be kept well dilated. Healing progresses rapidly and is uncomplicated in the greater number of cases.

Complications.—Infection, prolapse, or incarceration of the iris, lens capsule, or vitreous may occur. Infection of the eye after linear extraction should be treated as infection after other operative procedures.

Prolapsed iris should be replaced, or, if difficulty is experienced in doing this, the prolapsed portion may be excised. Prolapsing lens capsule should be excised.

Indications for Iridectomy Preliminary to Extraction of Cataract.—(*a*) In slowly advancing unripe cataract, for hastening the maturity of the lens. (*b*) In glaucoma with incipient cataract. (*c*) When an unsuccessful operation for the extraction of cataract has been performed on the fellow eye.

Fig. 476

Fig. 477

Linear incision for the extraction of soft cataract.

Extraction of Lens in its Capsule.—If the lens could be removed in its capsule without endangering the integrity of the eye the operation would be ideal. The anatomical conditions render the procedure a hazardous one unless the attachment of the suspensory ligament to the lens has become weakened, or the ligament itself has become weakened. The escape of vitreous occurs in a high percentage of cases whatever the condition of the suspensory ligament. If during the extraction injury to the ciliary processes is considerable (because of traction on the suspensory ligament) a condition of the eye may be induced that will lead to the destruction of vision. The operation has been systematically practised by many competent ophthalmologists, to be given up eventually on account of the high percentage of failure. Extraction of the lens within its capsule is indicated in cases of subluxation, and in complete dislocation of the lens, and is permissible in cases in which it is probable that it is more difficult to open the capsule than to rupture the suspensory ligament. This sometimes occurs in cases of hypermature cataract, in shrunken cataract, and in Morgagnian cataract.

Operation.—The instruments required are the same as for the combined operation. The loop vectis may be smooth, or it may be armed with shallow barbs placed on the concave surface of the loop.

In many cases it is unnecessary to perform iridectomy. When the operation is to be performed without iridectomy the pupil should be dilated ad maximum before the section is made. The section should be as in the simple operation (page 846). The iridectomy is now performed if necessary. The lens loop or the wire loop, either smooth or barbed (the writer prefers the smooth loop), is passed behind the lens, keeping

close to the capsule of the lens and passing to its lower border. If the iris is intact the upper margin is pressed backward and a little upward with the wire loop to permit the latter to pass behind the lens. If the suspensory ligament is partially intact, limited lateral movements of the wire loop will serve to detach it, in part at least, from the lens. The lens is now engaged in the fenestrum and gently pressed forward against the cornea. It is then lifted upward and out of the wound. The eyeball, which has been held with the fixation forceps during this procedure, is now released, the speculum removed, and the toilet (see page 845) of the wound completed. Whatever tissue may protrude from the wound must be excised and the edges of the wound be properly adjusted. The after-treatment is as in the ordinary extraction of cataract. In the removal of the lens dislocated into the posterior chamber the wire loop is not employed by all operators. Knapp prefers to cause the lens to present in the wound by slightly depressing the scleral flap with a lens spoon and then making sudden, rather deep, pressure on the globe, between the margin of the cornea and the equator of the globe, at a point directly opposite the incision. The pressure is made either with a lens spoon or through the lower lid by means of the thumb or finger, the speculum having been removed. This maneuver is successful in the greater number of cases, but in the experience of the writer is not so certain as with the wire loop, and there is apt to be a greater loss of vitreous.

Fig. 478

Barbed vectis.

Major Smith's Method of Cataract Extraction.—The following is the method employed by Major Smith of Jollundur, India, for the removal of cataract in individuals over thirty years of age:

Instruments.—Small spring speculum without stop; fixation forceps; Graefe knife; scissors and forceps for iridectomy; a broad, firm spatula, and two rigid hooks much like strabismus hooks,[1] one with a shorter shank than the other.

Operation.—Local anesthesia is employed. Patient in the recumbent position, the operator standing back of the patient's head. The speculum is introduced and permitted to separate the lids by the strength of the spring. The eye is fixed by grasping episcleral tissue just below the lower margin of the cornea. Section with a Graefe knife, the puncture and counterpuncture being in the horizontal meridian 1 mm. from the corneal margin in the sclera. The incision is a modified Lebrun usually ending in the cornea (Fig. 479) 1.5 to 2.5 mm. from the upper corneal margin, finishing with the edge of the knife directed forward at right angles to the corneal surface. An iridectomy is made. The iris is seized at the apex of the incision without entering the eye if possible, drawn out moderately and excised. The fixation forceps and speculum are now removed, the lower lid,

Fig. 479

Major Smith's incision. (Approximate.)

[1] May be had from George Tiemann & Co., New York.

brow, and upper lid secured and held from the globe by an assistant. The upper lid is held by means of the shorter of the two hooks. The lid is drawn upward and slightly outward. Pressure is now made by the operator, by means of the point of the other hook, at the lower part or margin of the cornea directly backward toward the centre of rotation of the eyeball over the lower third or fourth of the lens. If the lens is to come out without being reversed this pressure (which should be firm and continuous) is kept up until the lens starts, when the direction of the pressure is changed to follow the lens.

If the prospects are that the lens will be reversed before presenting at the wound, the detachment of the capsule from the zonula below is facilitated by dragging down on the cornea while making the pressure. As the lens starts, pressure is made so as to get beneath the lens and to assist the turning. As the lower edge of the lens presents in the wound, pressure is directed upward, care being observed to follow the lens closely. If the lens does not readily engage in the wound, slight pressure is made on the upper lip of the wound with the spatula. When the lens is well engaged in the wound it may be assisted out by means of the hook, with which the pressure is made. The iris is now replaced, the margins of the wound placed in proper apposition, and the eye bandaged.

During the expression of the lens the eye takes any position that it may rotate into. No attempt is made to have the patient look in any direction.

The reported cases show 4.5 to 7 per cent. of loss of vitreous; very little iritis.[1]

Extraction by Suction.—This method is applicable for soft and semi-fluid cataracts and for the removal of cortical material after ordinary extraction. In former years it was used quite extensively, but it is resorted to by modern ophthalmologists very rarely.

Fig. 480

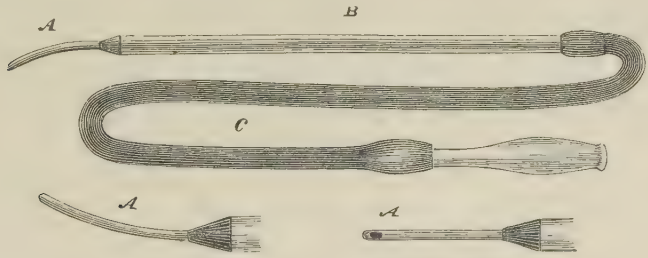

Teal's suction curette: *A*, tubular curette attached to a stem (*B*) formed of a glass tube; *C*, an India-rubber tube with a mouth-piece. (Wells.)

Instruments.—Broad needle bent on the flat, or an angular keratome; speculum, fixation forceps, cystitome, spatula, suction apparatus, Teal's suction curette (Fig. 480), or the suction curette of Bowman.

[1] Major H. Smith (Indian Med. Gazette, February, 1907; Trans. Am. Ophth. Soc., 1908) has practised extraction of the lens in the capsule in many thousands of cases. His method is largely original. While the operation is expeditious and well adapted to the East Indian, it does not apparently possess sufficient elements of safety to render its employment advisable in the countries in which good vision is more necessary.

Operation.—The iris should be well dilated. The speculum is placed in position and the eyeball is fixed by grasping the ocular conjunctiva at a point opposite to the site of the incision. A linear incision, about 4 mm. long, is now made through the cornea at a point opposite to the margin of the pupil when it is moderately dilated. The lens is thoroughly broken up by means of the cystitome. The nozzle of the suction instrument is now carried into the anterior chamber to the centre of the pupil, the opening being directed toward the cornea. The tip is buried in the soft lens substance, and, if the Teal instrument is employed, suction is made with the mouth, and the lens substance is drawn into the instrument. The pressure should be carefully regulated. The opening in the nozzle should not be permitted to engage the iris or to pass into the vitreous chamber. If the syringe is used, suction is regulated by the piston. This operation is employed but little at the present time, linear extraction and irrigation having taken its place. There is some danger of exciting undue reaction in the use of this method if excessive suction is employed.

Reclination (*Couching; Depressing*).—This operation was practised almost exclusively before Daviel introduced his method for extracting the lens (1745–1748). It had been abandoned entirely excepting in the Far East, until recent years, when it was revived by M. Henry Power in England, and by some of the ophthalmic surgeons of France. Rampoldi[1] recommends it for patients in whom the success of extraction is doubtful. He has performed the operation in cases of blenorrhora of the lachrymal sac with good results. It has been restored to in cases in which one eye has been lost by hemorrhage after extraction, and in lunatics in whom extraction could not be well performed.

In contemplating this procedure, the surgeon should fully consider the high percentage of loss that follows this operation. Mooren reports having seen twenty-one cases of absolute blindness following the reclination of the lens, in two years. In six of these cases sympathetic ophthalmia had occasioned loss of the other eye. Mader[2] has collected the reports of thirty-nine cases of reclination. Many were blind, and those possessing some vision had symptoms of impending total loss.[3]

Instruments.—Speculum, fixation forceps, reclination needle (couching).

Fig. 481



Couching needle.

Operation.—After the introduction of the speculum the eyeball is fixed at the nasal side in the horizontal meridian. The needle is made to pierce the sclera 4 mm. to the outer side of the cornea in the horizontal meridian and to enter the posterior chamber, the convexity of the blade being directed backward. The point of the needle is made to point between iris and lens, avoiding penetrating the lens if possible until it

[1] Ann. di ottal., xv, 5-6, p. 423.
[2] Wiener klin. Woch, 1898, No. 50.
[3] Norris and Oliver's System, iv, p. 369.

passes beyond the vertical meridian of the lens at the upper margin of the pupil. The lens, usually in its capsule, is then forcibly tipped backward into the vitreous chamber, using the sclera as the fulcrum. It is necessary to push the lens well out of and below the pupillary area, then to remove the pressure. If the lens does not reappear in the pupillary area the needle may be withdrawn. If it does reappear it must be again depressed. The needle may be entered at the angle of the anterior chamber, anterior to the iris, but the control of the lens is not so complete.

Results.—The immediate result, as a rule, is brilliant. The pupil becomes clear and vision is restored. It may happen that the posterior portion of the lens capsule ruptures and the nucleus of the lens only is depressed, leaving more or less broken lens substance in the capsule to obstruct the pupillary area. This is left to absorb, or is dealt with subsequently. Some blood may appear in the anterior or posterior chambers as a result of traction on the ciliary processes or wound to the vascular coat by the needle. Subsequently the opaque lens may again appear in the pupillary area. The lens may become dislocated into the anterior chamber. The dislocated lens acts as a foreign body in the interior of the eye.

Discission.—This method for the removal of cataract is one of the safest and most satisfactory, provided the lens substance is in such condition that it can be absorbed within a reasonable time, and the conditions are such that the patient can remain under observation until the treatment can be completed. The operation is indicated for the removal of congenital cataract when undertaken in early life, of cataract occurring in individuals under the age of twenty from whatever cause (if we except some forms of shrunken and complicated cataract), and of soft cataract. Discission is also employed for breaking up the lens in certain forms of cataract and in high myopia in adults, preparatory to linear extraction. The operation was formerly employed for the removal of senile cataract (Hayes), but the advantages of extraction are so much greater that this has been abandoned. The operation is also employed in the treatment of capsular cataract following extraction.

Instruments.—Speculum, fixation forceps, discission needle. The stop needle of Bowman and various other needles are employed, but Knapp's knife needle is probably the best for this purpose. The needle should be very sharp. It should be so made that the shank will completely fill the incision in the cornea made by the blade in its passage into the anterior chamber, in order that no escape of aqueous humor will take place. This may be tested by fastening the skin of the testing drum in position, filling the drum with water, and piercing the skin from below with the needle. The opening made should be so completely filled by the shaft of the knife that no water will escape. A spirit lamp and a small cautery should be at hand.

The operation is best performed in a darkened room by artificial illumination. Light from any good oil, gas, or electric lamp will suffice. It should be concentrated on the field of operation by means of a suitable condensing lens. An ordinary hand lens, four to six inches in

diameter, and having a principal focal distance of eight or nine inches, will serve admirably. The pupil should be fully dilated.

Operation.—This may be performed with one or with two needles.

Operation with One Needle.—The speculum is introduced and the globe fixed with the fixation forceps. The needle, the blade of which

Fig. 482

Knapp's knife needle.

Fig. 483

Bowman's stop needle

should be short enough to be entirely within the anterior chamber when the lens capsule is reached with its point, is made to pierce the cornea at a point midway between the centre and the margin of the cornea, usually to the temporal side and near the horizontal meridian, the plane of the blade of the knife needle being placed at right angles with the corneal meridian on which it enters. The point of the needle is now carried

Fig. 484

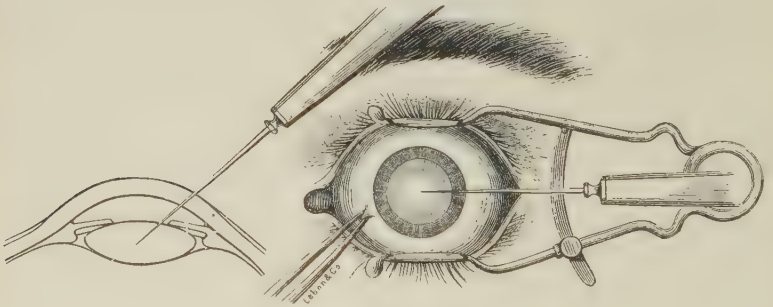

Discission of cataract. (Juler.)

beyond the anterior pole of the lens, and when sufficiently advanced the cutting edge is turned toward the lens, the point of the needle made to pierce the capsule. By elevating the handle of the instrument an incision of sufficient length is made into the substance of the lens in the meridian of entrance. By depressing the handle of the knife the blade

is freed from the lens in the same manner that it entered, and the instrument rotated so that the back of the blade is directed above or below as desired. If above, the point is made to reach the meridian at right angles with that incised, as far above as is necessary to enter the lens and to make an incision to connect with the first incision at its centre. A similar maneuver, above or below, as required, serves to complete a crucial incision.

The knife is now rotated so that its position is the same as when the cornea was pierced and is withdrawn. If it occurs that a shred of vitreous humor, lens substance, or capsule becomes engaged in the wound as the needle is withdrawn, the point of the puncture should be touched with the small cautery at a red heat for the purpose of sealing the puncture wound. This procedure prevents infection of the wound. The fixation forceps and the speculum are removed, atropine instilled, and the eye bandaged.

Operation with Two Needles.—The first needle is entered as for the operation with one needle, the point of the needle being made to pierce the capsule of the lens at its anterior pole. The fixation forceps are now removed, and the second needle is made to pierce the cornea at a point corresponding to the point of entrance of the first needle, and directly opposite. The edge of each needle is turned toward the points of entrance, the handles approximated, making an incision in capsule and lens substance. An incision at right angles with the first may be made before removing the needles from the eye. The needles are removed as previoulsy described. The points of entrance may now be cauterized. The extent and depth of the incision, and the disturbance of the lens substance must depend upon the effect desired.

It should be remembered that the reaction consequent on discission differs widely in different individuals. If the operation is made for the purpose of causing the lens substance to disappear by absorption, little more than a very small crucial incision through the capsule should be made at the first operation, in order that the peculiarity of the individual regarding reaction may be determined. The extent of subsequent operations can be based on the knowledge thus obtained.

The removal of congenital or soft cataract by discission usually requires three operations, repeated at intervals (usually two or three months), determined by the progress of the process of absorption. When absorption ceases the operation should be repeated. The last operation should include division of the posterior portion of the lens capsule. The ultimate result should be a perfectly clear circular pupil.

Accidents and Complications.—These should be few. One of the most common is the abolition of the anterior chamber due to the escape of aqueous humor. If difficulty is experienced in finishing the incision into the lens substance the needle should be withdrawn and the operation again attempted after the anterior chamber is restored. It may occur that the capsule and lens substance are so hard and dense that they are not readily pierced by the point of the needle. A shrunken, calcareous lens may present such a difficulty. Under these circumstances

the operation must be abandoned and the cataract dealt with in another way. Dislocation of the lens may be produced. This accident would necessitate the abandonment of the operation. Cyclitis may result from traction on the suspensory ligament, and iritis and panophthalmitis may follow infection through the canals of entrance. Infection through the wound canal usually takes place along a shred of tissue that is engaged in the canal. This will not occur if the wound is closed with the cautery immediately on completion of the operation.

Accidents after Operation for the Removal of Cataract.—**Incarceration of Iris.**—This does not call for any particular treatment, as a rule. If it occurs after simple extraction and is observed a few hours after it has happened, the use of eserine may suffice to correct it. Replacement by means of the spatula may be advisable in some cases.

Prolapse of Iris.—If observed shortly after it occurs, prolapsed iris may be restored with the spatula and it may not again prolapse, but this is not the rule. If not retained after replacement, or if seen too late to make replacement advisable—twenty-four to forty-eight hours—the prolapse must be excised. In doing this the prolapsed portion should be carefully disengaged from the plastic lymph that binds it to the wound, by means of a spatula or knife, seized with iris forceps, carefully drawn out, and cleanly excised. Subsequently the columns of the coloboma must be disengaged from the angles of the corneal wound.

Escape of Aqueous on Dressing the Eye.—This should give no concern if there is no complication.

Delayed Restoration of Anterior Chamber.—In the greater number of cases of cataract extraction the anterior chamber becomes partly or wholly restored within the first twenty-four hours. In some cases two or three weeks may elapse before this occurs. The cases are more frequent in corneal section than when the incision is made at the limbus or with a conjunctival flap, but they may occur wherever the incision is placed. It is very probable that the greater number of cases are due to the inclusion of a shred of lens capsule, a tag of iris or of conjunctival tissue between the lips of the wound. Some of the cases are due to delayed healing. It seldom happens that delayed restoration of the anterior chamber is followed by bad results. The eye should be kept under a dressing until restoration takes place. Anterior synechiæ may form as a result, which may require subsequent treatment.

Delayed Healing.—This occurs not infrequently in the aged, and in debilitated patients from whatever cause, if the incision is finished in corneal tissue—seldom if in the limbus. The writer has never observed it when the incision was made with a conjunctival flap. When delayed healing occurs the margins of the wound become slightly separated, the external angle of the cut surface softened and rounded, forming a groove, and closure proceeds slowly by a process of granulation. In the favorable cases a number of weeks is sometimes required for the closure of the wound; anterior synechiæ form, and the cicatrix—which is usually much broadened—permits of much distortion of the curvature of the cornea. In unfavorable cases a slow iridocyclitis or panophthal-

mitis following infection causes destruction of the eye. Sympathetic ophthalmia may ensue.

Striped Keratitis (see page 296).—This may develop and persist for one or two weeks.

Detachment of Chorioid.—Detachment of the chorioid follows cataract extraction by the "combined" method in a small percentage of the cases due to detachment of a portion of the annular ligament at the time of making the iridectomy or when delivering the lens. This accident permits the aqueous to pass between sclera and chorioid. In the cases reported,[1] recovery with good vision was the rule.

Cystoid Cicatrices.—These sometimes develop in the process of healing.

Postoperative Mania.—Postoperative mania sometimes follows operations on the eye, particularly cataract extraction; however, the percentage is probably not more than one-third of 1 per cent. The mania begins on the first to the fourth day as a mild restlessness, and develops in one to three days into active delirium. Males and females are affected in about equal proportion.

Etiology.—Interference with the habits of the individual, as the cutting off of alcoholic stimulants and the absence of exercise, apparently often determines the attack. Marked cases of delirium tremens may develop. In other patients the cause appears to be psychic and is produced by bandaging both eyes and confining the individual to the bed. The *form* of operation does not appear to influence the mania.

Duration.—This varies much in different cases.

Treatment.—Sodium bromide and chloral hydrate in fairly strong dose suffice to control the condition in some cases. Hyoscyamus, fl. ext. (gm. 0.30 to 0.60), hyoscyamine sulphate (gm. 0.0005), hyoscine hydrobromide (gm. 0.0005), cautiously increased, are of much value in controlling the mania. Opium in some form is sometimes valuable.

It is necessary in the greater number of cases to remove the bandage from one eye and in some cases to permit the patient to get out of bed and obtain exercise by walking about the room. Not infrequently the delirium disappears when these measures are taken.

Artificial Ripening of Cataract.—It is believed by many operators that the ripening of cataract may be hastened by the employment of certain methods and the condition for the extraction be rendered more favorable than those that obtain in immature cataract. After quite an extensive experience the writer has abandoned these operations, believing that the extraction of immature cataract, when necessary, can be performed with equal facility and as good results obtained without as with the ripening operation. Of the operations devised the following are those most in use:

Discission for Ripening Cataract.—Discission for ripening cataract has been employed for many years,[2] the incision in the capsule being made large or small, as the operator fancied. Lage[3] makes a small incision

[1] Fuchs, Trans. Ninth International Congress, Utrecht, 1899.

[2] Muter, London, 1813; Graefe, 1864.

[3] La clin. ophtal., June, 1903.

in the capsule at the anterior pole of the lens by means of a cataract knife entered obliquely through the cornea near the limbus; he permits the aqueous to escape on withdrawing the knife, and then massages the lens through the cornea. In this way he obtains more rapid maturation than by massage alone. A similar operation was practised by Röhmer.[1]

Foerster's Method.[2]—An iridectomy is made as in the combined operation for the extraction of cataract. After this is done a smooth strabismus hook is used to press the cornea against the lens in the pupillary area, employing rather firm massage for a few seconds. The procedure disturbs the lens substance, particularly the cortical lamellæ, and opacification progresses rapidly. Complete opacification is reached, ordinarily in from two to six weeks, when the lens may be extracted.

Multiple Puncture.—Allesandro[3] employed multiple puncture of the anterior portion of the lens capsule.

Massage.—T. R. Pooley (New York) has advocated massage of the lens through the cornea after escape of aqueous by simple paracentesis.

The method of massage through the cornea is called indirect massage in contradistinction to massage applied to the capsule through the incision, which is termed direct massage. This was introduced by Boerne Bettman,[4] who made an iridectomy, introduced a Daviel spoon or spatula into the anterior chamber, and gently massaged the lens through the lens capsule, carefully avoiding rupture of the capsule.

Other Methods.[5]—McKeown advocated injecting water at a temperature of 100° F. into the lens substance by means of a hypodermic syringe.

Wollberg,[6] in view of the fact that glassblowers who are exposed to intense heat frequently develop cataract, has developed a method for the rapid maturing of cataract by subjecting the eye to a high temperature. A special apparatus is employed, and hot air at a temperature of 70° C. (158° F.) is projected against the closed upper lid for about five minutes at each sitting.

Operation on Lens Capsule after Cataract Extraction.—The removal of cataract without the capsule is followed in many cases by an interference with the passage of rays of light through the pupillary space, either by retention of lens substance, wrinkling of the capsule, the formation of opaque bands, or the deposition of inflammatory products on the capsule. These conditions call for operative procedures, which must be varied to suit the individual case.

Discission.—This operation is most frequently required. It is performed either with a knife needle (Bowman's, Hayes', Knapp's) or with a Graefe cataract knife or some form of keratome.

Discission with the knife needle is indicated in cases in which the membrane obstructing the pupillary area is uniformly thin throughout the area to be traversed by the knife. Thickened bands cannot be

[1] Soc. Franç. d'ophtal. bul. et mém., 1888, p. 123.
[2] Foerster (Breslau), Arch. f. Augen., xii, p. 3.
[3] Archiv. di. ottol., 1902, p. 201.
[4] Jour. Amer. Med. Assoc., December 3, 1887.
[5] Brit. Med. Jour., 1884, ii, p. 238.
[6] Woch. f. Hyg. u. Ther. d. Aug., September, 1904.

readily cut by the knife needle. As a rule, the endeavor to cut them results in dislocating the capsule, tearing it from the ciliary process and causing more traumatism than is advisable.

The operation with the knife is as described on page 856. When the obstructing capsular membrane is traversed by thick bands, discission with the cataract knife as employed for iridotomy through the cornea (see page 821) may be selected. If the capsule is dense, it may be divided by means of De Wecker's scissors (De Wecker's operation), as described on page 823.

The removal of the capsular pupillary obstruction may be undertaken in place of discission. Panas removed the capsule to afford a clear pupil, by making a linear incision (3 to 4 mm.) near the periphery of the cornea, introducing capsule forceps, seizing the capsule and drawing it through the wound. Dense capsular opacities are often advantageously dealt with by the procedure of Knapp, iridocystectomy (see page 824). The cornea may be pierced with a broad needle, which may be made to pass through or avoid the capsule, as the operator may desire.

A sharp, bent hook (Agnew, Green), or a spiral hook (Wilson), is now introduced, the capsule engaged, twisted about the hook, drawn from the wound, and excised.

Operations on the capsule are not without danger to vision. Too much traction may induce a slow cyclitis, which may be followed by atrophy of the globe. Infection through the wound canal may take place. Glaucoma may follow discission.

OPERATIONS ON THE CORNEA.

Transplantation of Conjunctival Flaps.—The transplantation of conjunctival flaps to the cornea has been practised in (1) infected injury to the cornea (Haarland), (2) in virulent forms of gonorrheal ulcer (Scholer, Kuhnt, Goldsieher) and severe corneal ulcers from other causes (Kuhnt), (3) corneal fistula (Weeks), (4) after operations involving opening the anterior chamber to prevent infection (Ellett), (5) after the transplantation of corneal tissue (Fuchs, Zirm).

Various methods of obtaining the flap are employed. (*a*) The conjunctiva may be detached around the entire cornea, conjunctival and subconjunctival tissue undermined, and the entire cornea covered by drawing the conjunctiva over it by means of a "tobacco-pouch" suture. (*b*) A flap of conjunctiva sufficiently large to amply cover the corneal defect is dissected up, beginning at the margin of the cornea nearest to the area to be covered. A similar flap opposite to the first is made, and the margins of the opposing flaps united over the cornea by means of sutures; or the flap nearest the corneal defect only is prepared, the defect being covered by drawing the flap over the cornea by means of sutures inserted in the tissue of the limbus opposite. (*c*) A strip of bulbar conjunctiva sufficiently wide

to amply cover the defect may be dissected from a site favorable for the covering of the defect, both ends of the strip being left attached, forming pedicles. The strip is then drawn over the corneal defect and fastened by suitably placed "guy" sutures. In covering corneal defects with conjunctival flaps, the margins of ulcers should be cleansed and scraped, and the area of corneal tissue to which it is desired to have the flap adhere denuded of epithelium. Prolapse of iris should be excised. In closing fistulous openings, interfering iris should be removed by a properly placed iridectomy.

Keratoplasty.—The transplantation of corneal tissue has been attempted by many surgeons since the time of Reisinger (1828). In the greater number of instances, attempts have been made to transplant the cornea of the dog or rabbit to the eye of man. These experiments have failed without exception. In 1877, von Hippel devised a corneal trephine (Fig. 485), which is admirably suited for the excision of the flap to be transplanted and the preparation of the opening for its reception.

Fig. 485

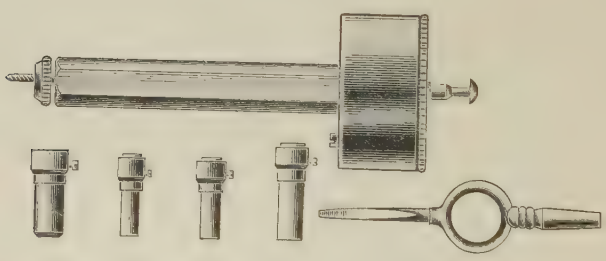

Von Hippel's corneal trephine.

Because of the generally unsatisfactory results, keratoplasty has fallen into disuse until recently, when Zirm[1] published the report of a successful case in which vision was improved from $\frac{3}{200}$ to $\frac{3}{20}$, the transplanted cornea remaining clear and vision as indicated ten months after the operation. In this case human cornea was employed to furnish the desired flap.

Indications.—Completely opaque cornea, as after burns from lime, ammonium, etc., results of parenchymatous keratitis with vision reduced to movements of hands and no clear cornea, adherent leukomata with total opacity of the cornea.

Operation.—General anesthesia is employed. Human cornea should be used, taken preferably from the eye of a young individual, which requires enucleation because of injury. An opportunity for obtaining such material must, of course, be improved as it presents. Great care should be observed to obtain asepsis. The preparation of the

[1] Graefe's Archiv, Band lxiv, H. 3, S. 580.

site for the reception of the flap should be completed before the flap to be transferred is removed. A trephine of 5 mm. in diameter is selected and so adjusted that it will make an incision through the tissue to be removed, but will not injure underlying structures. If the lens is clear, it should not be injured; if opaque, it should be removed before the keratoplasty is attempted. Fragments of the lens may be removed at the time of the keratoplasty if necessary. The work of the trephine must often be supplemented by the small knife or scissors in order to remove the button of tissue.

The opening through the cornea, which includes its entire thickness, is now examined with the ophthalmoscope to determine the transparency of the underlying media, which should be secured. The eye, from which the flap is to be transplanted is obtained, is now enucleated (the patient having previously been anesthetized) as expeditiously as possible, placed in warm physiologic salt solution, and a button of clear cornea removed with the same trephine that was used to prepare the site for its reception. The detachment of the flap should be effected with as little manipulation as possible. By means of a spatula, the button of clear cornea is placed—epithelial surface down—on a pad of sterile gauze moistened in the salt solution, and transferred immediately to the opening made for its reception, into which it should fit perfectly and be flush with the surface. The button of clear cornea is fixed in position by sutures of silk which cross over its centre (Fig. 486) and are passed beneath the conjunctiva at the margin of the cornea. A bandage is applied to both eyes. At the end of forty-eight hours the threads may be removed and a piece of rubber tissue smeared with sterile vaseline may be placed on the cornea to keep the flap in position.

Fig. 486

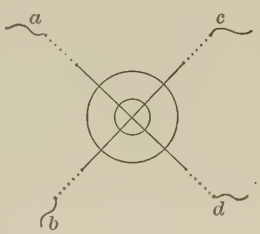

Arrangement of sutures to retain corneal flap in keratoplasty. (Zirm.)

OPERATIONS ON THE ORBIT.

Exenteration.—The operation for exenteration of the orbit is proceeded with differently, according as the desire is to remove the whole or but part of the contents of the orbit. For total exenteration, the procedure is as follows:

The palpebral fissure is extended inward and outward by free canthotomies, and the internal and external canthal ligaments are freely divided in order to permit of complete exposure of the margin of the orbit. The conjunctiva and subconjunctival tissues are then divided down to the margin of the orbit throughout by way of a conjunctival incision. This necessitates division of the tendon of the levator palpebræ superioris muscle. The periosteum at the margin of the orbit is now divided throughout, and is stripped from the walls of the orbit by

means of the periosteal elevator. The détachment of the periosteum is carried as far as possible. The lachrymal sac, the infra-orbital canal, the sphenomaxillary and sphenoid fissures will, as they are reached, obstruct the complete removal of the periosteum. At these places the periosteum must be divided, after which the detachment of the periosteum can be continued to the apex of the orbit. It will be found convenient to cut across the orbital tissues at a distance of from 1.5 to 2 cm. from the apex of the orbit; this will enable the operator to remove by far the greater part of the orbital contents. The bleeding, up to the point of the removal of the contents of the orbit, will not be excessive. On cutting across the orbital tissue quite profuse hemorrhage may be expected from the branches of the ophthalmic artery, and also from the veins of the orbit. This may be controlled in large part by means of gauze packing or by artery forceps.

It is sometimes desirable to use hot water—at a temperature of 180° F. to control the oozing. After having controlled the hemorrhage the removal of the tissue close to the apex of the orbit may be proceeded with. If possible the ophthalmic artery should be isolated and secured by catgut suture. This is not always possible; if it is not done, hemorrhage from it may be controlled by pressure. Having divided the optic nerve and its surrounding tissue within 5 to 10 mm. of the optic foramen, the apex of the orbit may be packed somewhat firmly with iodoform gauze. The lids are now prepared so that the skin of the lids, after removal of the tarsus and cilia, may be turned in on to the orbital wall above and below. Having placed the lids in this position the exposed wall of the orbit is covered with sterile rubber tissue and the cavity packed with iodoform gauze. An antiseptic dressing is now applied and left in position for three or four days if no complications arise which demand its removal.

As a rule, at the end of ten days all exposed bone will be covered with a thin layer of new tissue, the surface of which will be smooth from contact with the rubber tissue. Thiersch grafts are then cut and transferred to rubber tissue, the surface of which is sparingly smeared with bichloride vaseline, the epithelial surface lying on the rubber tissue. When prepared in this way the graft can be cut to any form and easily transferred to the desired place, leaving the rubber tissue undisturbed. Under these conditions healing is rapid and perfect.

Removal of Tumors.—In the removal of tumors from the orbit, the method employed must be determined by the needs of the individual case. If the growth is situated well forward it often suffices to operate through the soft tissues without disturbing the bony walls of the orbit. If the bony walls are involved in the growth the involved portion must, of course, be removed. When the growth extends deep into the orbit or occupies a position well back of the globe it becomes desirable to operate in such a manner that the contents of the orbit can be well exposed. For this purpose the operation of Krönlein[1] is well adapted.

[1] Beiträge z. klin. Chirurg., Band iv, i, Tübingen, 1887.

Krönlein's Operation.—*Instruments.*—Scalpel, retractors, periosteal retractor, dissecting forceps, bone forceps, bone chisels, mallet, artery forceps, sutures. A small circular dental saw may be used to advantage.

Operation.—The brow and hair in the vicinity of the field of operation should be shaved off and the skin rendered aseptic. The head is rotated toward the sound side to render the field of operation easily accessible. An incision beginning on the temporal ridge about 2 cm. from the outer upper angle of the orbit, curving forward to about 5 mm. from the outer canthus and backward, terminating over the middle of the upper edge of the zygoma, is carried down to the periosteum where the incision reaches the margin of the orbit, and to the epiperiosteal tissue beyond this point above and below. The incision should be sufficiently large to permit of easy access to the deep tissues. The periosteum is now split at the margin of the orbit, along the entire temporal side, and by means of a blunt-pointed periosteal elevator the periosteum is raised from the outer orbital wall to the infra-orbital groove below and well on to the orbital surface of the great wing of the sphenoid laterally and above. By means of suitable retractors the contents of the orbit enclosed in periosteum are now drawn well to the nasal side, freely exposing the outer bony wall of the orbit.

Fig. 487

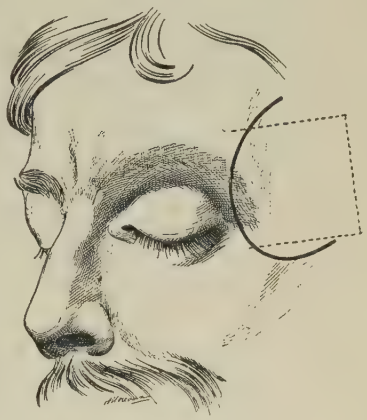

Krönlein's incision. (Morax.)

Fig. 488

Krönlein's operation. The skin incision is shown by the curved line, that through the bone by the heavy lines. (Haab.)

Resection of the outer portion of the bony wall of the orbit is now made, chiefly from the orbital surface. The base of the external angular process of the frontal bone is cut through either with the chisel or circular bone-saw, and the incision carried diagonally downward and backward to the outer border of the sphenomaxillary fissure, 8 to 10 mm. back of the anterior extremity of the fissure. The base of the orbital process of the malar bone is now divided on a level with the upper border of the zygoma directly backward to the anterior end of the sphenomaxillary fissure. The incisions

should be made in the order named, for if the lower incision is made first the loss of support will make it difficult to complete the incision after the base of the external angular process of the frontal bone is divided. It is well to remember that the anterior end of the fissure is approximately 18 mm. from the margin of the orbit. Its location can be conveniently determined by means of a small strabismus hook. The bony flap can now be dislocated outward, exposing the greater wing of the sphenoid back to the sphenoidal fissure.

The orbital periosteum may now be divided in the horizontal line and the contents of the orbit exposed. If necessary the external rectus muscle may be divided.

In completing the operation the ends of the severed external rectus must be united, the bone-flap returned to its former position, and the wound carefully closed. Catgut sutures must be used in suturing deep structures. Silk may be used externally.

Union by first intention is the rule. The degree of permanent injury to the contents of the orbit depends entirely on the severity of the traumatism inflicted.

Various modifications of this operation have been devised,[1] but they do not present advantages over the operation described.

OPERATIONS ON THE GLOBE.

Enucleation.—**Instruments.**—Speculum, fixation forceps, mouse-tooth forceps, strabismus hook, moderately blunt-pointed strabismus scissors, curved on the flat, enucleation scissors.

Fig. 489



Enucleation scissors.

Operation (Bonnet's Method).—General anesthesia is employed.

Stage 1.—After inserting the speculum the conjunctiva is seized near the corneal margin and detached from the sclera as close to the margin of the cornea as possible around the entire circumference of the cornea, for the purpose of retaining as much of the conjunctiva as possible; at the same time the anterior attachments of Tenon's capsule are divided, opening freely into Tenon's space.

[1] Parinaud and Roche, Annal. d'oculist., cxxvi, p. 241; Angelucci, Trans. Ital. Oph. Soc., Naples, 1905.

Stage 2.—The tendons of the recti muscles are caught up with the strabismus hook and successively divided by means of the strabismus scissors, between the hook and the sclera the tendon most accessible being divided first. In detaching the tissues from the globe the points of the scissors should "hug" the sclera in order that the parietal layer of Tenon's capsule need not be cut through, and that all orbital tissues except the eyeball may be left in the orbit. The strabismus hook may now be swept around the eyeball as far back as the equator to make sure that all attachments are severed except those at the posterior pole and the attachments of the oblique muscles. By pressure backward with the speculum the eyeball may be brought in front of the blades of the speculum. If the eyeball will not come through the opening in the conjunctiva readily, lateral incisions in the horizontal meridian of the conjunctiva may be made. If the globe is too large to come through the palpebral fissure a simple external canthoplasty may be performed.

Stage 3.—The eyeball may be steadied by grasping the stump of an internal or external rectus tendon with fixation forceps or not as the operator elects. The point of the curved enucleation scissors is passed backward along the nasal surface of the eyeball until the optic nerve is reached. This will be recognized as a tense cord on moving the point of the scissors up and down. When located the point of the scissors is brought opposite the nerve, the blades opened and passed so as to grasp the nerve. If there is no indication for excising a long piece of the optic nerve it is divided close to the eyeball. If a long piece of the optic nerve is to be excised it is followed down between the blades of the scissors and cut as long as necessary. The globe is lifted out of the orbit with the scissors, rotated to the temporal side, seized with the fingers and the attachments of the obliques and other remaining tissues divided, releasing the globe. Quite sharp hemorrhage follows the division of the central retinal vessels. This can be controlled by pressure.

The margins of the conjunctiva and subconjunctival tissue may now be loosely approximated by means of a "tobacco-pouch" suture of catgut and a compress bandage applied.

The bandage may be changed every twenty-four hours until healing is complete (five to ten days). The patient may sit up on the second day and be about in five to seven days. An artificial eye may be inserted in two or three weeks from the time of the operation.

Other methods of enucleating the eyeball have been described, but none are superior to the one given. All operations that unnecessarily sacrifice conjunctiva are faulty. The conjunctival sacs should be kept as large as possible in order to satisfactorily lodge the artificial eye.

Accidents.—*Perforation of Sclera.*—This may occur at any time during the detachment of the tissues from the eyeball. If it occurs before the cutting of the optic nerve is attempted the globe collapses, part of or the entire contents passing into the wound. It is sometimes

possible to retain the contents of the eyeball in the sclera by closing the wound with fixation forceps or by means of a suture. If the eyeball is collapsed it is frequently advisable to pass a strong suture through the sclera by which the eyeball can be held until the dissection is complete. The dissection must be carefully proceeded with until the eyeball is removed. If the sclera is cut through when the attempt to sever the optic nerve is made and sclera and nerve are left in the orbit they must be searched for, recovered, and properly excised.

Hemorrhage.—Profuse and persistent hemorrhage occasionally occurs. This is most apt to take place in old people with atheromatous and dilated vessels. If a firm compress bandage does not suffice to stop the bleeding, the wound and conjunctival sac may be firmly packed with gauze and a compress bandage superimposed. If the tissues of the orbit become filled with blood, resulting in the formation of a hematoma, the clot will eventually become absorbed without harmful results. Occasionally serious results follow. Sattler[1] reports a case of partial sloughing of the eyelids from the pressure of a hematoma after enucleation; also a case in which the hemorrhage was controlled only after four days.

Secondary Hemorrhage.—This is very rare. If it occurs the bandages may be removed, the wound cavity irrigated with an antiseptic solution, and the cavity packed with gauze.

Meningitis.—This complication following the enucleation of a non-suppurating eyeball is extremely rare, but a number of cases have been reported.[2] Quite a large number of cases have been reported following enucleation of suppurating eyes. Andrews[3] collected thirty cases, and many have been reported by other observers. Tetanus has also been reported.[4] The pneumococcus and the streptococcus have been found in the fatal cases.

METHODS FOR IMPROVING MOVEMENT OF ARTIFICIAL EYE.

Uniting Ends of Muscles over End of Optic Nerve.—De Schweinitz's Method.—The conjunctiva and subconjunctival tissue are divided as for enucleation. Each rectus tendon, as it is exposed, is lifted on a strabismus hook and "secured with a double-armed silk suture, which is knotted upon it." The eyeball is now enucleated and a small ball of sterilized gauze inserted into Tenon's capsule. Each rectus tendon is now drawn forward to the edge of the cut conjunctiva and fastened to it by means of the suture that is knotted to the tendon. The ball of gauze which has served to check the hemorrhage and to facilitate the drawing forward of the tendons is now removed and the edges of Tenon's capsule are united by interrupted sutures in a vertical line.

Snell's Method.—The tendons of the recti muscles are exposed in the usual way. Each in turn is caught up with the squint hook and a

[1] Jour. Amer. Med. Assoc., November 21, 1896.
[2] Nettleship, Andrews, Davison.
[3] N. Y. Med. Jour., December 29, 1882.
[4] Fernandez, Rev. gén. d'opht., 1896, p. 58.

suture looped through from side to side, just back of the squint hook. The suture is tied, not too tightly, and the suture continued through Tenon's capsule and the conjunctiva. The globe is removed in the ordinary way. The sutures which hold the lateral recti are tied first, after which those that hold the vertical recti muscles are tied.

Todd's Method.—Todd uses a single suture. After the recti tendons are exposed in the usual way they are picked up in turn on a strabismus hook. A suture is passed downward through the conjunctiva and the tendon beneath; then upward through the tendon and underlying conjunctiva. About one-third of the tendon is included. The same suture is continued through all of the recti tendons. The eye is then enucleated and the ends of the suture ("purse-string") are tied.

These modifications increase slightly the movements of the stump.

The Insertion of a Body into Tenon's Capsule at Time of Enucleation.—Frost[1] inserts a glass globe into Tenon's capsule after enucleation. Without waiting for the hemorrhage to cease, a glass globe, 13 mm. in diameter, is introduced into the capsule. The tendons of the recti muscles, Tenon's capsule, and the conjunctiva, are sutured over the globe.

Alter[2] inserts a ball of hard paraffin, much as Frost employs the glass ball.

Balls of gold, silver, aluminum, made complete or in filagree and fenestrated, have been used. Not infrequently the surgeon is disappointed by the result, the ball escaping from the capsule during the healing process. Balls of sponge have been inserted (Claiborne, Suker). This substance ultimately undergoes absorption.

Ramsey[3] injects hard paraffin into Tenon's capsule shortly after the enucleation.

The reaction is greater and the time of convalescence is longer after the insertion of a foreign substance than after simple enucleation.

Orbital Heteroplasty.—The transplantation of a rabbit's eye into the capsule of Tenon has been practised, first, for the purpose of providing a sufficiently sightly eye to obviate the wearing of an artificial eye; second, for providing a movable stump over which to wear an artificial eye.[4] Chibert[5] was one of the first to practise this operation. Immediately after the enucleation of the human eye the freshly enucleated eye of a rabbit was placed in Tenon's capsule, and the optic nerve, recti muscles, margin of Tenon's capsule, and conjunctiva stitched to corresponding anatomical parts. The immediate result is comparatively good union and a movable globe. The cornea may remain clear for a few days; then it becomes hazy and sloughs in the greater number of cases. A shrunken, globular, movable mass, over which an artificial eye may be worn, is the result. The operation has been practised by

[1] Middlemore Prize Essay, 1885.

[2] Ophthalmic Record, xii, No. 3, p. 117.

[3] Ophthal. Review, July, 1903.

[4] In plastic operations on the eye, as in plastic operations in other parts of the body, it has invariably been found that heterogeneous tissues tend to shrink and disappear to a very much greater degree than do homogeneous tissues.

[5] Revue gén. d'opht., 1895.

Lagrange, Duci, and others, with like results. No serious subsequent complications have been reported.

If it is thought desirable to increase the bulk of the tissue within Tenon's capsule after enucleation it may be accomplished after the method of Rollet.[1] As the enucleation, which is done in the usual way, progresses, the recti muscles are secured by sutures. After the eyeball is removed a circular piece of skin and the underlying fat, having a diameter a little larger than the cornea, is dissected from the deltoid region and placed in the empty capsule of Tenon. The recti muscles are stitched to the mass of tissue just beneath the surface of the skin, and the conjunctiva and margin of Tenon's capsule to the margin of the skin. Rollett reports good results in obtaining a freely movable stump.

Substitute for Enucleation.—Partial amputation.

Lagrange's Operation.[2]—Instruments as for enucleation, except that the enucleation scissors are omitted and a Beer's knife is added.

Operation.—The insertion of the recti tendons is laid bare in the usual way and each tendon is secured by a strong silk thread. A purse-string suture is now passed through the conjunctiva around the opening. The cornea and as much of the ciliary region as the surgeon thinks necessary are now removed, principally by means of the Beer's knife. It is best to remove all of the ciliary zone, and with it the iris and part of the vitreous. The purse-string suture is now tied just sufficiently firmly to prevent further loss of vitreous. The sutures holding the muscles are now tied in pairs, lateral recti together and vertical recti together. The tendons are dragged over the opening in the sclera, beneath the conjunctiva, to close the scleral opening. Finally the purse-string suture is tied firmly. This operation is said to form a freely movable stump.

Removal of Contents of Sclera (*Evisceration*).—Noyes[3] was the first to propose this procedure. He employed it in the treatment of beginning panophthalmitis, to cut short the process. Noyes incised the cornea freely, then wiped out the contents of the sclera until that membrane was perfectly clean. A bandage was then applied and healing with a movable stump usually followed. In later years, Noyes followed the evisceration by irrigating with a solution of mercuric chloride to render all aseptic, and then loosely packed the cavity with iodoform gauze. The gauze was renewed when necessary (one to three days), and completely removed as soon as granulation tissue appeared in the cavity.

Von Graefe (1884) employed evisceration, but modified Noyes' method by excising the cornea and enough of the sclera to include the ciliary zone.

Gifford's Methods.—Gifford[4] advocates evisceration with retention of the cornea in all cases in which the cornea is not seriously diseased. He employs two methods:

[1] La clin. opht., 1704, p. 377.
[2] Ann. d'oculist., cxxvi, p. 225.
[3] Trans. Fourth Int. Ophth. Congress, London, 1873.
[4] Arch. of Oph., vol. xxix.

1. An incision is made through the conjunctiva and subconjunctival tissue, extending from the middle of the insertion of the external rectus to the middle of the insertion of the superior rectus muscle. From the lower angle of this incision a second incision is carried to the fornix conjunctivæ. The flap thus formed is dissected up so as to expose the sclera.

A meridional incision through the sclera between the tendons of the external and superior recti muscles, about 18 mm. long, is now made with a Graefe knife. Through the opening thus made the entire contents of the eyeball are removed. A sharp spoon is used, if necessary. The conjunctival flap is then replaced and held by a few sutures.

2. An incision is made directly across the cornea in the horizontal meridian and continued into the sclera as far as necessary. The contents of the eyeball are removed through this opening, the cavity thoroughly irrigated with an antiseptic solution, and the eye bandaged. The stump remaining after healing takes place is movable and serves very well for the adjustment of an artificial eye. In some of his cases Gifford has inserted an artificial vitreous body to obtain a larger body on which to fit the artificial eye. In these cases he sutures the cornea.

Results.—In the greater number of cases the healing after evisceration progresses satisfactorily; granulation tissue develops in the scleral cavity, and a satisfactory stump results. In some cases granulations do not develop, but the sclera slowly disappears by necrosis and the healing is greatly prolonged. This is particularly apt to be the case in aged individuals. When it is evident that the healing is taking this course, the sclera should be dissected out and a wound such as is present after simple enucleation should be produced.

Subenucleation (*Nicati's Operation*[1]).—The conjunctiva is opened over the insertion of the internal rectus, the tendon exposed, and a double-armed suture passed from below upward, one near the lower and one near the upper border, passing on through conjunctiva. The tendon is now divided between the suture and the globe. The globe is rotated outward and the optic nerve divided with enucleation scissors. The posterior pole of the globe is caught with a sharp hook and rotated into view, the insertion of the oblique muscles severed, the posterior half of the globe excised, and the contents of the fibrous coat thoroughly removed. The internal rectus is now sutured to the stump on the segment of the globe, the needles passing from below and including the conjunctiva.

Fig. 490



Mules' vitreous spheres.

Insertion of an Artificial Vitreous.—Mules[2] proposed the insertion of a hollow glass sphere (Fig. 490) into the empty sclera to improve

[1] Arch. d'opht., xxii, p. 347.

[2] Trans. Ophth. Soc. United Kingdom, v. p. 200.

the cosmetic effect on the wearing of an artificial eye. Mules' operation, with slight modifications, is the one most generally practiced today.

Instruments.—Speculum, fixation forceps, cataract knife, scissors, sharp spoon, artificial vitreous, and introducer (Fig. 491), needles and needle-holder.

Fig. 491



Introducer for Mules' spheres.

Operation.—The conjunctiva is incised at the limbus and dissected from the sclera to the insertion of the recti muscles. The cornea is now removed with about 1 mm. of sclera and the contents of the eyeball thoroughly removed as in simple evisceration. The bleeding should be stopped (this may be done by packing with gauze) and all rendered perfectly aseptic by irrigating with quite warm mercuric chloride solution (1 to 5000). The glass sphere, which should not be large enough to be pressed upon when enclosed (10 to 13 mm.), is introduced either with the fingers or, preferably, by means of the introducer devised by Mules (Fig. 488). The scleral lips of the wound are now firmly stitched together by means of chromatized catgut suture in the *vertical meridian,* excising scleral tissue at the angles to prevent puckering if necessary, and the conjunctiva and subconjunctival tissue firmly closed over this in the *horizontal meridian* by means of silk sutures. All must be thoroughly aseptic. A moderately firm compress bandage is now applied and the patient put to bed. Considerable reaction is the rule. Marked chemosis and some swelling of the lids may develop and continue for some days. This may be controlled (*a*) by continuing the compress bandage if the parts are not too painful; (*b*) by applications of cold. The patient should be kept in bed for from five to seven days. The convalescence requires about twice as long as for simple enucleation.

Failure to retain the artificial vitreous from loosening and giving way of sutures is not very uncommon, but a large percentage of success may be obtained by careful technique. It is particularly necessary to suture the scleral lips firmly together. If they are overlapped and sutured a firm union will be obtained.

Contra-indications.—The operation is contra-indicated in the aged, in all cases of malignant diseases of the globe, in eyes that threaten sympathetic ophthalmitis, in all cases of shrunken or diseased scleræ, and in dacryocystitis.

On the Wearing of Artificial Eyes.—An artificial eye should not be worn over a sensitive stump, as sympathetic irritation is apt to be induced and to persist while the artificial eye is being worn. The artificial eye should be perfectly smooth and have a high polish. If rough the epithelium with which it comes in contact will be eroded, secretion will develop, and, if not corrected, shrinking of the conjunctiva will take place. The

artificial eye should not unduly distend the conjunctival sac, nor should it be so large that the lids cannot readily be closed over it. It should support the lids as nearly as possible in their normal position. The shape of the artificial eye should depend largely on the shape of the stump against which it rests. The thin shell is suitable for those cases in which a globe of some size is present, that is, in cases in which a shrunken eyeball is present, and in cases in which an artificial vitreous occupies

Fig. 492

Fig. 493

Artificial eyes. (Coulomb.)

the sclera, or a globular mass is implanted in Tenon's capsule. In some cases it may be advisable to make the upper outer quadrant of the shell more prominent than obtains in the ordinary artificial eye. The thick artificial eye (Snellen model) is best suited for all flat stumps, namely, all eyes in which simple enucleation has been performed.

REMOVAL OF FOREIGN BODIES FROM GLOBE AND ORBIT.

If a foreign body has entered the eyeball or orbit its exact location should be determined before any attempt is made at removal. If it cannot be seen by simple inspection or by the use of the ophthalmoscope, *x*-ray skiagraphy should be employed. Localization by means of the *x*-rays—first systematically employed by Sweet, of Philadelphia,[1] closely followed by Mackenzie-Davidson, of London[2]—"depends upon the determination of the three coördinates *x*, *y*, and *z* (Fig. 494), which fix the position of a given point in space." This is done by triangulation. Sweet's method is an excellent one. Mackenzie-Davidson's method has been improved upon by Hulen[3] and by Dixon.

Fig. 494

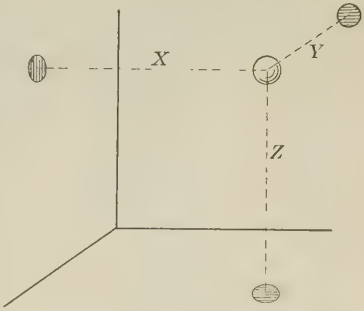

Localization of foreign body in the eye.

Dixon's Method of Localizing Foreign Bodies in Eye and Orbit.—Dixon has devised an apparatus for skiagraphing patients supine (Fig. 495.) It is mounted permanently on a table (*C*). It has a vertical plate-holder (*A*), sufficiently large to accommodate a 4 x 5 plate in its envelopes, which is erected on a platform elevated by cleats to compensate for

[1] Trans. Amer. Ophth. Soc., 1897.
[2] Brit. Med. Jour. January 1, 1898.
[3] Jour. Amer. Med. Assoc., April 2, 1904.

the shoulders of the ordinary-sized patient. Any change desired in the elevation of the head and shoulders can be made by the use of sand bags. The plate-holder is supplied with the usual cross-wires (3) and a spring (8) to retain the plate in position during exposure. A mouth gag (7) of aluminum is attached to the face of the frame with a "jamb-nut" to hold the patient's head steady. A clamp (19) is supplied with the apparatus for the purpose of giving additional stability to the head in case the operator cares to employ it. It is also supplied with a means of fixing the vision, consisting of a steel rod (5) on the edge of the frame. It has a sliding cross-piece of brass tubing at the top. Through this tube a thread is run, and to the end of the thread is attached a little woollen ball (16) balanced by a piece of lead attached to the other end of the thread. The rod can be rotated and fixed by a screw (6), giving the two motions required for adjustment. An upright sight (4) is fastened to the outer end of the platform—the lower part of the notch is at the exact height of the cross-wire centre.

Fig. 495



Dixon's apparatus for localizing foreign bodies in the eye and orbit.

The tube holder (*B*) consists of a box (18) open at each end, within which moves a pillar (11) controlled by a worm gear operated by a crank (15) from the opposite side of the table. Attached to the upper end of the pillar is a diaphragm (9) adjustable for height. It is supplied with cross-threads for alignment with the cross-wires in the plate frame. A projecting arm (14), one end of which is mortised into the head of the pillar, carries a cross-piece (12) to which is attached

the arrangement (13) for clamping the tube. Both the arm and the cross-pieces are slotted so that the parts supporting the tube can be moved in all necessary directions and clamped. The arm (14) is graduated so that it is possible to read off the distance of the centre of the target from the plate at any time, thus rendering actual measurement unnecessary.

The face of the upper end of the pillar (11) and the lower end of the diaphragm (10) are graduated in centimeters—six above and six below zero (0).

Attached to the side of the box (18) is an adjustable indicator (17) to measure the distance the tube has been moved.

The apparatus is comparatively light and can be easily reversed (for right or left exposure) and placed in contact with any form of *x*-ray table which may be in use.

Dixon's indicator (Fig. 496, *B*) consists of a small brass bar soldered to a ball which will fit the socket of a mirror head-band.

A second instrument has been devised by Dixon for the purpose of squaring the head (Fig. 496, *A*).

Fig. 496



A — *A*, squaring appliance.

B — *B*, indicator.

Application: A pencil line should be drawn on the side of the head, running backward from the outer canthus of the injured eye on a plane approximating the horizontal plane of the globe. Then adjust the head-band intended to carry the indicator or marker, but the indicator should be removed to prevent accident during the subsequent manipulation of the patient.

The tube having been adjusted by centring the anode with the cross-wires in the plate frame, the distance of the anode from the plate measured and recorded, the patient can be laid on the table, the head adjusted by means of the squaring apparatus, and fixed by dropping the sterilized gag into the mouth, care being exercised to have the line on the side of the head parallel with the perpendicular cross-wire, but sufficiently above or below to prevent the wire from obscuring the shadow of a

small foreign body in the globe. The usual practice is to adjust the head so that the wire will be on a level with the lower margin of the orbit. The vision should now be fixed by means of the little woollen ball, and the indicator slipped on to the pole or rod attached to the head-band. While the patient's vision is steadily fixed on the ball over his head the indicator is brought as near the centre of the cornea as is compatible with safety and comfort. The distance of the point of the indicator from the centre of the cornea is then carefully measured with a lens and strap gauge and recorded. The tube is now to be racked 3 cm. below the centre, the plate inserted in the plate frame, the patient directed to fix his vision steadily on the little woollen ball and the first exposure made. Without allowing the patient to move, or withdraw his gaze from the ball, the tube is racked 3 cm. above the centre (making a total displacement of 6 cm.), the exposed plate is replaced by a new one, and the exposure repeated.

After the plates have been developed the cross-wires will be found in the same position on both plates, but everything else will be displaced, and this displacement is the key to the proposition.

Fig. 497



Fig. 498



Skingraphs.

The distance of the anode from the surface of the plate, in the case selected for illustration (Figs. 497 and 498), was 51.5 cm., and the point of the indicator was 3 mm. directly anterior to the centre of the cornea. These are all the preliminary measurements required.

To work out the location of the foreign body on Hulen's lines, a drawing-board, a T-square the length of the board (which should not be less than 2 feet), a pair of fine dividers, a rule preferably graduated to millimeters, a ruling pen, and a piece of drawing paper are necessary.

Draw a line (marked *a* in Fig. 499) the full length of the board, which will represent the centre of the anode before displacement, another line (marked *b*) at one end and at right angles to the first, which will represent the plane of the tube and the direction of displacement of the

anode, and a third line (marked *c*) also at right angles to the first but at a distance of 51.5 cm. from the second, which was the distance of the anode from the plate and represents the plane of the plate.

Referring to the plates, which are reproduced in Figs. 497 and 498, we find that the shadow of the cross-wire *a* corresponds to the centre anodal line *a* (Fig. 499), and *b* to the line *b* indicating the plane of anodal displacement. If we measure with the dividers the distance from the line *a* on the plate (Fig. 497) to the point of the indicator and mark off this distance on the line *c* of the diagram (Fig. 499) (measuring from *a*), and if we measure the distance of the shadow of the foreign body from the line *a* on the same plate and transfer it to the same line *c* (Fig. 499), then take the measurements of the shadow on the second plate (Fig. 498) and transfer them exactly in the same manner, we will have four points marked off on the plate line in their proper relative positions at the time of exposure—*o* for the indicator shadows and *x* for the foreign-body shadows (Fig. 499).

Now measure off on the anodal line *b* of the diagram 3 cm. on each side of the centre (line *a*), and we have represented the points occupied by the anode at the time of exposure. Mark these points Ex. 1 and Ex. 2. From the point indicated by Ex. 1 draw a line to *o′* and another to *x′*, and from the point indicated by Ex. 2 to *o* and *x*, the lines will be found to have crosssed at *o″* and *x″*, the former showing the location of the indicator which is known, and the latter the location of the foreign body antero-posteriorly and also its distance laterally from the vertical plane represented by the right-angle line *d*. When the *x″* lines cross nearer to the plate than the *o″* lines, then of course the foreign body must be on the temporal side; if they cross farther from the plate line, then the foreign body must be on the nasal side of the globe, because we know the indicator was adjusted at the centre of the cornea. In this case we find the foreign body (*x″*)

Fig. 499

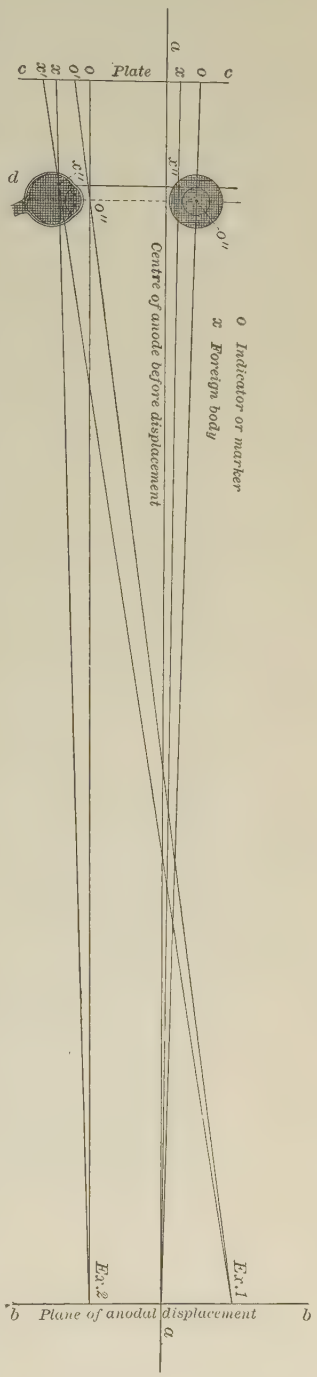

Scheme of triangulation for the location of foreign bodies in the eye. (Hulen.)

6 mm. to the temporal side and 13 mm. behind the point of the indicator, and as the indicator was 3 mm. in front of the cornea we have 13 mm. — 3 mm. = 10 mm. as the distance behind the centre of the cornea. To determine the third measurement, the elevation: It will be noted at once that the shadows on both plates are the same distance from the line *b*, consequently there could have been no displacement of the anode on this plane. Therefore, measure the distance from the line *b* to the shadow of the foreign body and also to the

Fig. 500

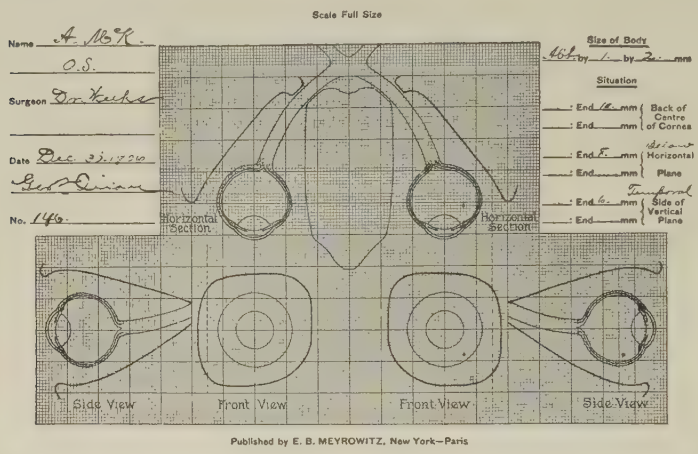

Modification of Sweet's chart for plotting the location of foreign bodies in the eye and orbit.

indicator on one plate and transfer these measurements of the plate line, measuring from the centre line *a*—the lines *a* and *b* for the purpose of this measurement being the same. Lines drawn from the centre to these two points will of course diverge, and the extent of divergence at the level of the foreign body, indicated by the line *d*, will be the distance above or below the horizontal plane of the globe, and a glance at the plates will show the direction. In this case we find the distance from *o* to *x* to be 8 mm.

Fig. 501

The Hirschberg magnet.

All measurements having been made, it remains to transfer them to the chart (Fig. 500). Measure off 10 mm. back from the centre of the cornea, 8 mm. below the horizontal plane, and 6 mm. to the temporal side, and thus indicate the location of the foreign body.

After considerable experience with this method Dixon finds but one objection, and that is not a very serious one. It is important to know the probable size of a foreign body before making any attempt to remove it. In case of small bodies this can be done to a nicety, but when large foreign bodies are present it is not easy, and sometimes impossible when radiographs are taken from one side only, and a third exposure would be necessary in an anterio-posterior direction.

Fig. 502

Haab's giant magnet.

Removal by Means of Magnets. The removal of all magnetic bodies is greatly facilitated by the use of the magnet. The smaller magnets, Hirschberg's and Johnson's, are useful if the anterior or vitreous chamber is to be entered. The giant magnets, Haab's,

Sweet's, Mellinger's "Innenpol magnet," should be employed if the foreign body is situated deep in the tissues of the globe or in the orbit.

Procedure.—The plan of procedure should be carefully determined upon before operating. The principal points to bear in mind in removing foreign bodies from the eyeball are (1) to produce the least possible traumatism, (2) to avoid entanglement in the ciliary processes. The location of a foreign body in the orbit will determine the avenue through which it is to be removed. Foreign bodies in the globe, if in the lens or anterior to the lens, may be removed through the opening by which they entered. Foreign bodies lying in the vitreous chamber or lodged in the retina or chorioid may be removed by the anterior route, that is, by bringing them into the anterior chamber (generally applicable in the case of small foreign bodies), the method advocated by Haab; or by the posterior route, namely, through an opening in the sclera near the site of the foreign body, if possible, usually in the lower outer anterior quadrant.

Fig. 503

The "Innenpol magnet."

If it is decided to bring the foreign body into the anterior chamber, the point of the magnet should be brought in a line with the centre of the cornea, and sufficiently close to produce the desired result. As the traction force on the piece of metal depends on the proximity of the metal to the magnet, the distance must be regulated to meet the requirements. A foot plate should be employed so that the current to the magnet can be closed and broken by the operator at will. With the eye in proper position the current is closed. Frequently the foreign body will come to the back of the lens at once, slip around the equator, pass through the zonula, and cause the iris to bulge forward near its base, usually below. At this point the current should be immediately broken. The relation of eye to magnet should now be so changed that the foreign body will be drawn into the pupillary area along the posterior surface of the iris. Having reached the pupillary area, the current is broken and the foreign body is permitted to fall into the anterior chamber. The patient should now be placed in the recumbent position. The foreign body may now be removed through the wound of entrance or an incision may be made in the cornea near its margin, the shallow T-incision being preferable, and the foreign body extracted either by means of the small magnet, the tip of which is placed between the lips of the wound, or by means

of the large magnet, approaching the eye to it. If the iris prolapses, it may be returned by means of the spatula.

One should not attempt to draw the foreign body through the iris, nor should much force be employed in the attempt to draw the foreign body into the pupillary area. If the foreign body becomes engaged in the iris it has been advised to incise the cornea at a point opposite to the site of the foreign body, to pass a steel spatula between iris and lens to the foreign body, and to attach the spatula to the magnet. The foreign body will then be withdrawn on the point of the spatula (Lang). The force employed to free the foreign body from the iris must not be great, as there is danger of complete iridodialysis. The procedure adopted by the writer in these cases is to incise the cornea immediately over the lodged foreign body, produce slight iridodialysis, buttonhole the iris, or do a small iridectomy, then apply the magnet; the foreign body usually comes away promptly.

Fig. 504

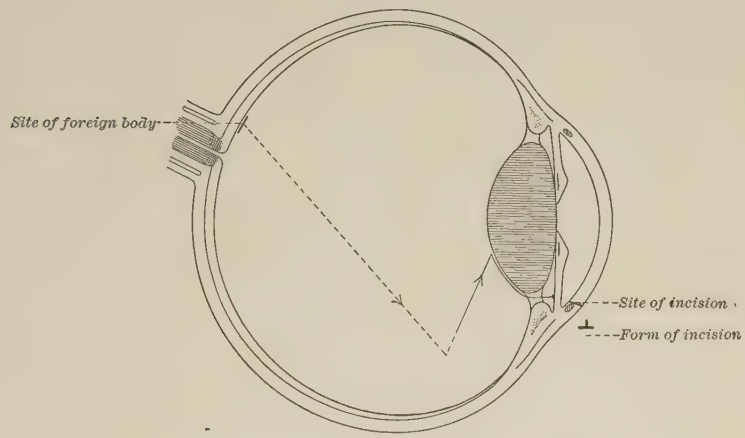

Foreign body in retina. Removal by anterior route (author's case).

In cases in which it is thought best to remove the foreign body by an opening through the sclera, the opening should be made as near the site of the foreign body as possible. Other things being equal, the outer lower quadrant is the point of selection. A strong suture is passed through the ocular conjunctiva at the sclerocorneal margin outward and below, and the eyeball rotated upward and nasally by traction on this suture. The conjunctival and subconjunctival tissues are opened meridionally just below the insertion of the external rectus, exposing the sclera. The incision through sclera, chorioid, and retina is made meridionally, beginning near the equator and ending just at the margin of the ciliary zone. This is converted into a shallow T-shaped incision by means of the knife or scissors. The tip of the magnet is brought to the lips of the wound. In the greater number of cases the foreign body becomes attached to the magnet immediately. If this does not occur, it may

become necessary to pass the point of a small tip into the vitreous in the direction of or to the foreign body. This is sometimes the case when the foreign body possesses faint magnetic properties, as in manganese steel, or when the foreign body is firmly stuck in the membranes of the eye.

After the foreign body is removed the episcleral tissue should be sutured over the wound. It is seldom necessary to suture the sclera itself.

Results.—Dixon has supplied the author with the following data of *x*-ray skiagraphic work at the New York Eye and Ear Infirmary, from November 24, 1904, to July 2, 1908.

During this period 403 patients were examined for suspected foreign body in the eye or orbit. Of these, 389 were males and 15 females. The findings were positive in 203 cases and negative in 200.

The results of operation in the positive cases: 93, or 72.66 per cent., of the eyes were improved; 10, or 7.8 per cent., unimproved; and 25, or 19.5 per cent., were lost.

If the foreign body in the eye is non-metallic the problem of its removal is more complicated. When the media are sufficiently clear to enable the operator to see the foreign body, an incision may be made in the most suitable place and the foreign body may be seized by means of suitable forceps. If not visible the site of the foreign body may be determined by skiagraphy and an attempt made to seize it by entering the forceps in the direction and to the point indicated as its site, after having made a suitable incision.

OPERATIONS ON THE MUSCLES.

Tenotomy.—Partial Tenotomy.—Partial tenotomy may be restored to to correct low degrees of deviation in which operative procedure is deemed necessary. A permanent effect in the direction of the action of the muscle or an effect in the direction of the divided portion of the tendon of the muscles may be obtained, varying from 1 to 5 degrees. A number of forms of partial tenotomy are practised.

Tenotomy of Central Portion of Tendon to Diminish Direct Action of Muscle.—*Stevens' Instruments.*—Fine-tooth forceps, scissors, small tendon hook, speculum, needle-holder, and sutures.

Operation.—The conjunctiva is raised just back of the middle of the insertion of the tendon in a meridional fold by means of the fine-tooth forceps and an opening 1 to 2 mm. (0.5 mm., Stevens) long in the direction of the line of attachment of the tendon made with the scissors. The opening is spread with the points of the scissors, the forceps released, passed into the opening closed, the scissors being removed at the same time. The points of the forceps are carried over the tendon just back of the insertion, separated and made to grasp the central fibers of the tendon and the undivided overlying tissue. The grasped tissue is divided by means of the scissors, between the forceps and the insertion of the

tendon. The lower or upper half of the tendon is now caught up on the small strabismus hook by inserting it through the hole in the tendon, and the fibers of the tendon are divided to the desired extent. The other half of the tendon is treated in the same manner.

Fig. 505



Stevens' tenotomy scissors.

Fig. 506

Weeks' eye speculum.

Fig. 507

Stevens' fine-tooth forceps.

Fig. 508

Stevens' tendon hook.

Fig. 509

Stevens' needle-holder.

If an effect of two to four degrees is desired, only a very few of the fibers of the tendon at the margin of the tendon can be left undivided. In order to be sure as to just how much is divided, it is well to make the incision in the conjunctiva long enough to permit of the exposure of the tendon by traction with the hook, pushing the conjunctiva over the point of the hook by means of the points of the scissors. Having divided the tendon equally on both sides to the desired extent, the conjunctival opening, if large, is closed by a suture; if small, is left to close spontaneously. The opening in the conjunctiva should be just a little back of the insertion of the tendon in order to avoid exposure of the scleral stump of the tendon in the healing process.

If a slight (one to one and one-half degrees) torsion effect is desired, when making partial tenotomy, the tenotomy may include one or the other border of the muscle, as the case may be, the extent of the partial tenotomy depending on the amount of torsion that the operator desires to correct.

Partial tenotomy, as described above, will produce a permanent effect two or three degrees less than that indicated immediately after the operation when performed on the lateral recti muscles. When performed on the superior rectus the permanent effect will equal (with but slight variation) the immediate effect.

Verhoeff[1] performs a partial tenotomy in which, after exposing the tendon, incisions as in Fig. 510 *A*, are made, with the approximate result as in Fig. 510, *B*. It is claimed that a correction of about 10 degrees may be obtained by this operation.

FIG. 510

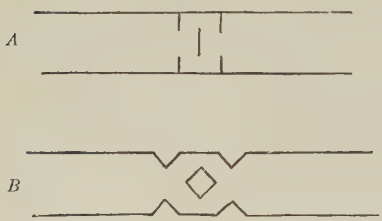

Verhoeff's operation. (Grimsdale.)

FIG. 512

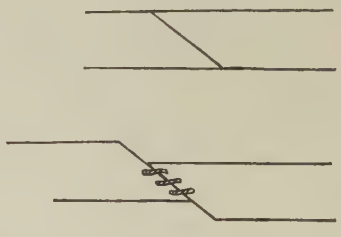

FIG. 511

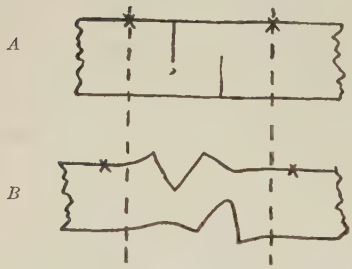

Todd's method of partial tenotomy: *A*, the relative positions of the incisions, and *B*, the lengthening produced.

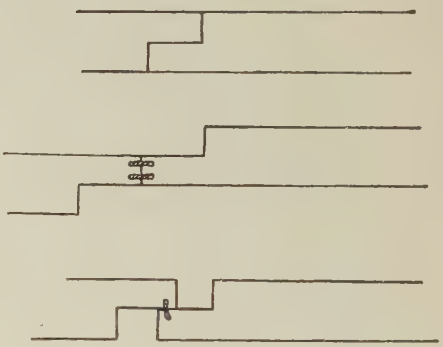

Stephenson's operation. (Grimsdale and Brewerton.)

Todd[2] performs a partial tenotomy in which the tendon is divided as in Fig. 511. The author claims that all grades of effect up to 10 or 12 degrees may be obtained.

Various other methods for lengthening the tendon have been devised by Stevenson[3] and by others.

Complete Tenotomy.—*Open Method.*—The conjunctiva and subconjunctival tissue may be grasped with the forceps, raising a meridional

[1] Klin. Monatsblt. f. Augenheilk., xli, 1, p. 393.
[2] Trans. Sec. on Ophth., A. M. A., 1907.
[3] Trans. Ophth. Soc. United Kingdom, 1902.

fold. This is divided 1 or 2 mm. back of the insertion of the tendon and parallel to the line of insertion. The incision is enlarged at both ends sufficiently to expose the tendon. The tendon is now buttonholed close to its insertion after raising a fold by means of the forceps. A small strabismus hook is now passed through the central opening on which one-half of the tendon is raised and divided. The lateral attachments of Tenon's capsule should be undisturbed. (Some operators seek to obtain a greater effect by dividing these lateral attachments.) The conjunctival wound is now closed by interrupted sutures.

Fig. 513

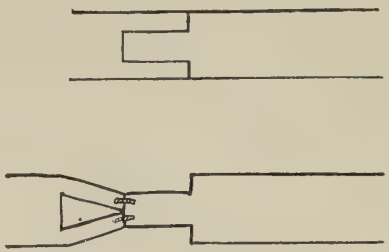

Modification of Stephenson's operation by Grimsdale and Brewerton.

Instead of first dissecting away conjunctiva and subconjunctival tissue, the conjunctiva, underlying tissue, and tendon may all be grasped and raised in a longitudinal fold and all be cut, just back of the insertion of the tendon, at the same time. A small strabismus hook may then be passed alternately above and below beneath the tendon and the division of the tendon completed. The conjunctival wound, which need not exceed that made in the first snip, may now be closed with a small silk suture.

Subconjunctival Tenotomy.—The conjunctiva and the underlying parietal layer of Tenon's capsule are incised along one border of the tendon for a distance of 3 or 4 mm., beginning at the insertion of the tendon. By means of a sufficiently large strabismus hook, which is entered at the opening made and inserted beneath the tendon, the tendon is raised from the sclera, the blades of the scissors are now entered, one above and one below the tendon, and the tendon divided between the hook and the sclera. Two or three snips usually suffice. The division is complete when the strabismus hook, passed back of the insertion of the tendon on the sclera, will come forward over the stump of the tendon to within 3 or 4 mm. of the corneal margin. The wound in the conjunctiva may be closed with a suture.

A partial subconjunctival tenotomy may be made by commencing the incision as described for the "open tenotomy" if the incision is limited to two, or at the most, three millimeters.

Panas,[1] before dividing the tendon, inserts the strabismus hook beneath the tendon and by traction forcibly rotates the globe until the pupil is hidden behind the opposite canthus. This produces a traumatic paralysis of the muscle, which is recovered from in eight to ten days. The effect is to prevent the high degree of retraction of the muscle and an insertion nearer the original insertion after tenotomy than occurs if the contractility of the muscle is normal at the time of the tenotomy. Both interni or externi may be operated on at one sitting.

[1] Arch. d'opht., xvi, 1, p. 1.

Effect of Tenotomy.—"The average effect of tenotomy of the internal rectus is 13 degrees and of the other recti less than half this amount; but it varies within extremely wide limits" (Worth).[1]

Application.—Tenotomy is permissible for the correction of phorias and trophias on muscles possessing excessive dynamic power or in cases of undue rigidity of a muscle. It should never be undertaken until, after a careful study of the case, the operator is convinced that the usefulness of the muscle will not be impaired by the procedure. Tenotomy should be resorted to seldom, if ever, before the age of five years, as the tissues of the orbit are not sufficiently well developed before this age to enable the surgeon to determine the permanency of a deviation of the eyes and the effect of correcting any existing errors of refraction, nor can the effect of orthoptic exercises be determined before this age. As a rule, it is better to defer tenotomy until the age of six or seven years. The worse cases of overcorrection after tenotomy occur when the operation is performed in very early childhood.

Accidents.—*Perforation of Sclera.*—This may be done in the endeavor to cut the tendon, but it occurs rarely. The scleral opening may be closed with a suture, if large; otherwise it may be left to heal spontaneously.

Hemorrhage.—This is seldom of moment. It is prevented by a compress bandage or by the use of adrenalin. If the subconjunctival tissue is filled with blood, greatly distending the ocular conjunctiva, the distention may be relieved by meridional incisions.

Infection.—This occurs rarely; however, it occurs sufficiently often to render it advisable to close all conjunctival incisions by suture.

Sinking of Caruncle.—This will follow if the tenotomy of the tendon is accompanied by extensive detachment of Tenon's capsule without subsequent restoration by suturing.

Advancement.—The design of the operation is to increase the effect of the advanced muscle on the position and on the rotation of the eyeball. The numerous operations devised involve (1) partial division of the tendon with removal of a portion; (2) total division of the tendon (*a*) without removing a portion, (*b*) with resection of a portion; (3) advancement by making a fold in the tendon ("tucking" operation, capsular advancement). In operations involving resection of a portion of the tendon the reattachment may be (*a*) in advance of the original attachment, (*b*) to the stump at the primary insertion.

Advancement by Partial Division of Tendon and Removal of a Portion.—Stevens[2] exposes the tendon as for a partial tenotomy (page 882), except that the opening in the conjunctiva is slightly larger. The conjunctiva next to the cornea is undermined to form a small pocket. The centre of the tendon is now seized with the forceps and is divided with the scissors, as in partial tenotomy. The centre of the tendon is then drawn through the conjunctival opening. One of the needles of a double-

[1] The writer has obtained an effect of 20 degrees by tenotomy of a superior rectus muscle.
[2] Motor Apparatus of the Eye, page 352.

armed, moderately-fine silk suture is passed through the tendon about 2 mm. back of the cut extremity and returned through the tendon, including 1 mm. or more in the loop at the centre of the tendon. A small, grooved director is introduced into the pocket formed by undermining the conjunctiva next to the cornea, in the horizontal meridian in the case of the lateral recti. One needle is carried into the pocket at the upper margin of the grooved director and brought out near the corneal margin, including episcleral tissue and conjunctiva. The other needle is similarly introduced at the lower border of the director. (A triangular piece of tendon may or may not be removed, as the operator fancies, before the sutures are introduced.) The suture is now tied, bringing the muscle forward as desired and usually sufficiently closing the conjunctival wound. If much effect is desired, two sutures instead of one may be employed. No dressing is required, as a rule. The stitches are removed in about six days.

The foregoing is applicable in cases requiring but a very small effect, 2 to 5 degrees.

Advancement by Total Division of Tendon without Resection.—*Valudes' Operation.*—The tendon is exposed by the usual vertical incision and two sutures, double-armed, are passed through the tendon from below, 2 to 4 mm. back of the insertion, that at the upper border including one-fourth of the width of the tendon; that at the lower border including the same amount of tendon. The tendon is now detached from the eyeball at its insertion and is split horizontally for a distance of 6 to 8 mm. The conjunctiva and subconjunctival tissue are undermined above and below at the margin of the cornea. The extremity of the upper half of the tendon is carried beneath conjunctiva and subconjunctival tissue and sutured to the conjunctiva and episcleral tissue well forward toward the vertical meridian of the cornea. The lower half is secured in a like manner below (Fig. 520). The degree of advancement should be governed by the degree of strabismus.

Advancement Combined with Resection.—Critchett's Operation (Fig. 522).—By far the greater number of advancement operations are of this character; one of the oldest and probably one of the best is Critchett's,[1] perhaps slightly modified in the way of fixing the sutures.

Instruments.—Speculum, fine-tooth forceps, strabismus hooks, Prince, Reese, or Weeks forceps, strabismus scissors, needles, sutures.

Operation.—The insertion of the muscle is exposed by the ordinary vertical incision through the conjunctiva and subconjunctival tissue. The end of the tendon is secured by means of the Prince, Reese, or Weeks[2] forceps. The secured tendon is now detached from its insertion and dissected back in order to expose the under surface of the tendon.

[1] Heidelberg Congress, 1862.

[2] If either one of the two first named is used the female blade is inserted beneath the tendon and the male blade is then closed over conjunctiva and Tenon's capsule. If the Weeks forceps are used the middle of the tendon is raised with fine mouse-tooth forceps and divided above and below for a sufficient distance to admit of the introduction of one of the blades beneath the tendon. With the blades of the fine forceps in the slot of the Weeks forceps the other blade is shut down on conjunctiva, Tenon's capsule, and tendon, securing all.

Both needles of a double-armed silk suture (No. 9 silk) are now passed from below outward through the tendon (near its middle), Tenon's capsule and conjunctiva, well back so as to include enough tendon to produce the desired effect, and about 2 mm. apart. One of the needles is returned, piercing the axis of the tendon just back of the loop (quilting suture, Fig. 523). Two lateral sutures (No. 5 silk) are now passed at the same distance from the end of the tendon with or without "quilting." The end of the tendon held by the forceps is now cut away. The conjunctiva and subconjunctival tissue toward the cornea are dissected up and the middle suture passed beneath these tissues through episcleral tissue to secure firm anchorage, emerging at the limbus in the horizontal meridian of the globe. (It is well to mark the horizontal meridian of the globe on the limbus before commencing the operation, as the subsequent rotations of the globe may make it difficult to locate this meridian and torsion may result from faulty insertion of the advanced muscle.) The globe can be held by means of fixation forceps which grasp the stump of the divided

Fig. 514



Prince's forceps.

Fig. 515

Weeks' advancement forceps.

tendon. The lateral sutures are passed in a similar manner, emerging in a line tangential with the cornea at the horizontal meridian, spread a little in order to have the reattached tendon inserted over as broad a line as before the detachment.[1] The sutures are now tied in a surgeon's knot, beginning with the middle suture and all tightened gradually until the tendon is uniformly advanced. The tendon should be brought well forward, tied securely, but not too tight. When this is done the line of union is relatively smooth and the conjunctival opening well closed. Both eyes are bandaged and so kept for from two to five days. The sutures are removed at the end of eight days.[2] The immediate effect produced should be an overcorrection of from three to six degrees.

This advancement, if properly performed, will suffice to correct a

[1] All operations on the muscles that bunch the muscle fibers and prevent a reinsertion of the tendon throughout a line approximately as long as in the original insertion are faulty.

[2] Firm union between tendon and sclera, so that sutures may be removed without fear of retraction of the tendon, does not occur under six to nine days.

deviation of 15 to 20 degrees. If tenotomy of the opponent is performed at the same time, 10 to 15 degrees may be added.

WORTH'S OPERATION.—*Instruments.*—The instruments are as for Critchett's operation. Worth uses special suture material[1] and large-eyed needles made by Weiss, of London.

Operation.—Local anesthesia is employed. A vertical incision is made through conjunctiva and Tenon's capsule, the middle of the incision lying quite close to the cornea. The tendon is now exposed and the female blade of Prince's forceps is passed beneath the tendon just back of the insertion. The male blade of the forceps is closed, including conjunctiva, Tenon's capsule, and tendon. The tendon is divided at its insertion and its attachments are severed. By lifting the tendon with Prince's forceps the under side is exposed. Two sutures[2] are required. One needle is passed in at *a* and brought out on the under side of the muscle. It is then returned through capsule and conjunctiva, emerging at *b*. The suture includes about one-fourth of the upper border of the muscle, also overlying capsule and conjunctiva. The other needle is similarly placed at the lower border. The ends of both sutures are then tightly knotted over the conjunctiva. The end of the suture bearing the needle is passed through conjunctiva, capsule, and muscle 1 or 2 mm. back of the knot, emerging on the under side of the muscle. This needle is then passed beneath the conjunctiva, through the tough circumcorneal fibrous tissue (the sclera), not piercing the sclera, and brought out at *g*. The other suture is similarly placed.

FIG. 516

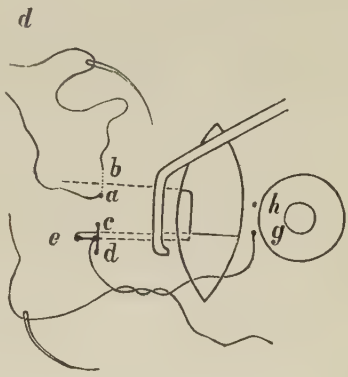

Worth's operation. (Haab.)

The tissues grasped by the Prince forceps are now excised close to the forceps. The end of the muscle is brought forward and the gap in the tissues closed by gradually tightening the sutures. The anterior end of the muscle is brought nearly to the corneal margin. "In operations under cocaine the immediate effect is the permanent effect."

"After the operation the eye is irrigated with sterile saline solution, boric acid ointment smeared on the margins of the lids and a gauze pad applied."

The stitches are removed on the eighth day.

[1] Suture material: Very strong, quite thick, black silk, such as is used for sewing boots. Wind loosely on a winder (made by bending up a piece of galvanized wire). Boil in water to sterilize and remove superfluous dye. Dry before a fire. Thread the end through a large glass bead. Drop the bead into a glass beaker containing a very hot mixture of white beeswax, three parts; white vaseline, five parts. Draw all the silk through the wax. Wind on glass reel. Keep in a sterilized glass jar. Use as wanted. The suture is non-absorbent and glides easily.

[2] A needle is threaded with a piece of the prepared silk thread, twelve to fourteen inches long, and the thread drawn half-way through. The thread is then well twisted.

Advancement Operation of Prof. Straub (Amsterdam).—The usual opening is made through conjunctiva and subconjunctival tissue

Fig. 517

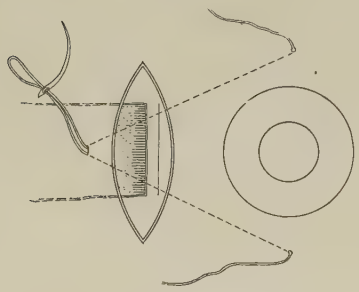

Advancement operation of A. Weber. Position of sutures.

Fig. 518

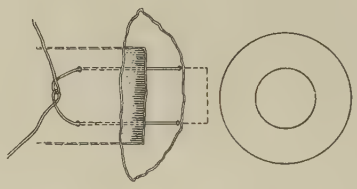

Verhoeff's operation. Position of sutures.

Fig. 519

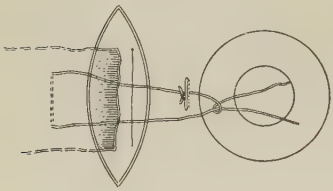

Prince's operation. Position of sutures.

Fig. 520

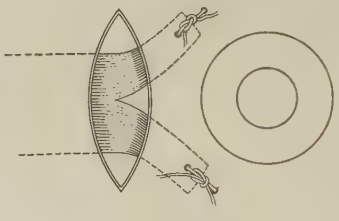

Valude's operation.

Fig. 521

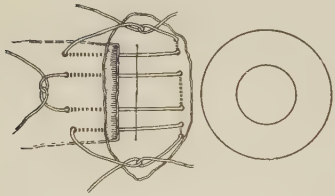

Straub's operation. Position of sutures.

Fig. 522

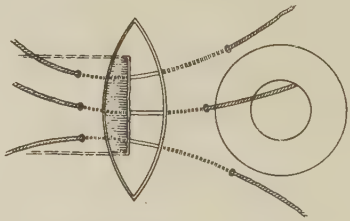

Critchett's operation. Position of sutures.

Fig. 523

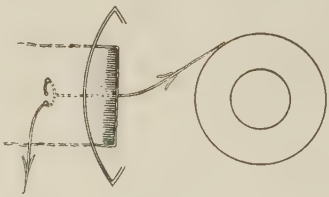

Quilting suture.

between the cornea and the insertion of the tendon, long enough to expose the insertion thoroughly. The conjunctiva is dissected up nearly to the

corneal margin and the loose connective tissue lying on the sclera between the insertion of tendon and the cornea is removed. The tendon and muscle are freed from the insertion well back, the advancement forceps (Prince or Reese) are introduced and the muscle is detached from the sclera, leaving a short stump. Either before or just after the tendon is freed from the sclera, three stitches are passed through the scleral tissue as indicated in Fig. 521, the object being to secure a firm anchorage without piercing the sclera. The sutures are brought through the muscle as indicated in the cut. All of the muscle sutures include the subconjunctival tissue and the conjunctiva. A sufficient length of tendon is now excised and the sutures tied. As the muscle is drawn forward the conjunctival wound is closed. Should the conjunctival and subconjunctival tissue be redundant a portion may be excised. This operation gives very good results.

Other Advancement Operations.—There are many other advancement operations, the principal variations being the manner of inserting the sutures.

A. Weber arranged the suture as in Fig. 517.

Resection Operations.—Operations in which a portion of the tendon is excised and the muscle is sutured to the stump of the tendon on the eyeball are termed resections of the muscle.

Reese's Operation (*Resection*).—*Instruments.*—As in advancement except that the Reese tendon forceps (Fig. 524) are employed.

Fig. 524

Reese's advancement forceps.

Operation.—For the external and the internal recti, make a vertical incision through the conjunctiva 6 mm. from the corneoscleral margin, commencing at the level of the upper corneal border, and extending to the horizontal plane of the lower border.

At the upper and lower limits of the incision just made, grasp the tissue anterior to the sclera with forceps and incise with scissors. This procedure materially facilitates the passage of the stabismus hook under the tendon.

When the tendon is held on the hook, dissect all conjunctiva and subconjunctival tissue back to the canthus, exposing the muscle (Fig. 525); the tendon and exposed portion of the muscle must be freed from the lateral insertions of Tenon's capsule.

One blade of the resection forceps (Reese's) is then inserted beneath the tendon at a right angle to its course, so that the groove on the blade lies directly over the middle fibers of the tendon. Clamp the forceps to the last notch, and do not let the grasp include anything but tendon.

Sever the muscle 2 mm. from its scleral attachment, leaving a stump, so

that the resected end can be sewed to its original insertion. Free the belly of the muscle from any scleral adhesions. Three sutures are necessary.

Put the sutures in, commencing with the middle, which is a No. 3 braided silk, with a needle on each end. Pass the needle through the scleral surface of the muscle posterior to the blade of the forceps 4 mm. back of the point of resection and 1 mm. to the side of the groove on the forceps; then pass the other needle the same way but to the other side of the groove, making a loop with the suture on the scleral surface of the muscle. As the needles pierce the muscle, let them include the dissected edge of the subconjunctival and conjunctival tissues.

The two wing sutures are No. 5 silk with a single needle, passed first through the upper and lower part of the dissected conjunctiva and episcleral tissue, including the superior and inferior borders of the muscle, and slightly posterior to the loop made by the middle suture (Fig. 527.)

Cut the muscle anterior to the sutures, leaving at least 2 mm. in front of the loop.

Fig. 525

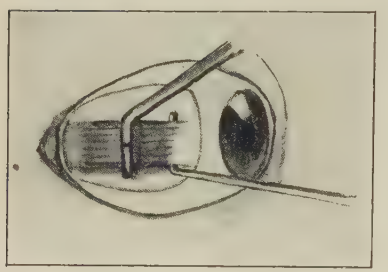

Reese's operation.

Fig. 526

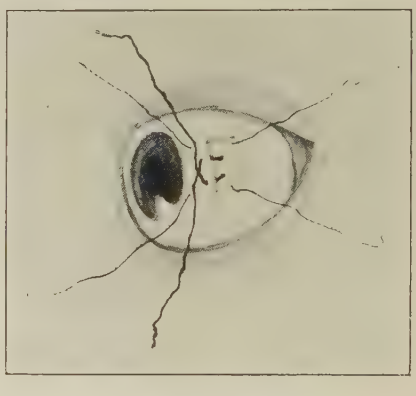

Reese's operation.

Insert the two needles attached to the middle suture 2 mm. apart, through the centre and the other two needles through the upper and lower edges of the scleral stump. These needles should include the conjunctiva, as they pass from behind forward (Fig. 526).

Tie the middle suture first in a loop and do not use a surgeon's knot, as it will not pull up well. The lateral sutures are next tied.

The middle suture is removed in ten days, and the others can be taken out any time after forty-eight hours, or if left in they soon fall out.

Tendon Folding or Tucking.—In these operations the tendon itself furnishes the point of attachment. De Wecker's operation,[1] which is spoken of as musculocapsular advancement, is of this character.

Instruments.—As for Critchett's operation. The suture must be of stout silk.

[1] Annal. d'oculist., xciii, 1885, p. 72.

Operation.—An elliptical piece of conjunctiva and subconjunctival tissue about 1 cm. long by 0.5 mm. wide is excised so as to expose the end of the tendon. The tendon is now raised on the strabismus hook, a suture is passed from the conjunctival surface through conjunctiva, capsule, and muscle, including one-fourth of the muscle at its border, entering the space beneath the muscle far enough back to obtain the effect desired. The suture is continued beneath the hook and passed through the tendon at its insertion. The suture is then continued beneath the conjunctiva and emerges near the corneal margin above (or below) the level of the border of the tendon. A similar suture is passed at the other border of the tendon. The sutures may now be tied, alternately tightening the two, at the same time the folding of the tendon

Fig 527

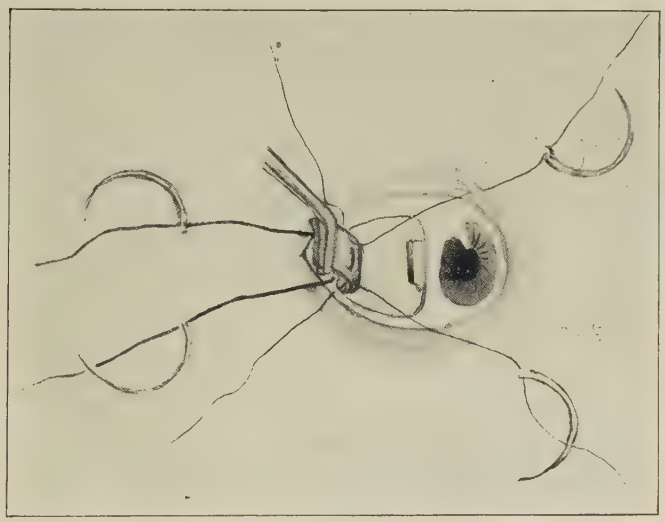

Reese's operation.

may be facilitated by manipulation with the hook or forceps. The conjunctival opening is sufficiently closed by the sutures described. The immediate result is the shortening of the muscle and the production of an elevation at the point of the insertion of the tendon. The elevation gradually disappears. If the effect of the shortening of the tendon is not sufficient, tenotomy of the opponent may be made at the same time.

Todd,[1] Valk,[2] Greene[3] and Howe[4] have each devised a "tucking" operation with special forceps for manipulating the tendon.

Displacement of Insertion of a Muscle to Correct Torsion.—Stevens[5] has devised an operation which he calls "extendocontraction,"

[1] Trans. Sec. on Ophthalmology, Amer. Med. Assoc., 1904.
[2] New York Med. Jour., November 7, 1896.
[3] Ophth. Record, 1899, p. 461.
[4] The Muscles of the Eye, New York, vol. ii.
[5] Motor Apparatus of the Eye, p. 34.

which consists in a displacement of the insertion of the tendon. He employs it on the internal, superior, and external recti muscles. The operation enables him to produce an effect of 2 to 3 degrees. It was suggested for the correction of non-paralytic torsion.

Jackson[1] suggests a change in the insertion of the superior rectus to correct, in part at least, the torsion and upper rotation resulting from paralysis of the superior oblique. He estimates that a displacement of the insertion of a tendon of 1 mm. produces an effect of 5 degrees.

In all advancement operations the effect produced can be estimated only approximately. An operator of large experience should be able to gauge the operation so that there need be but little deviation from the effect desired. Resection and tucking or folding operations permit of a closer estimation of the final result than does advancement with section of the tendon.

Accidents.—Those of tenotomy occur in advancement operations; in addition, the needle employed in attaching the suture to the tissue of the sclera may pierce the sclera and enter the eyeball. If the needle is aseptic, this accident is of no importance. The needle should be withdrawn and the operation proceeded with.

The postoperative accidents are of more importance. Chief of these is the loosening of the sutures (*a*) by untying; (*b*) by cutting through the tissue of the sclera or of a tendon; (*c*) sloughing of the tissues as a result of infection. All of these tend to nullify the effect of the advancement.

[1] Ophthalmic Review, xxii.

CHAPTER XXX.

SPECIAL REMEDIES.

Suprarenal Extract.—This drug was first introduced into ophthalmology by W. H. Bates,[1] and it has since been recognized as a most efficient hemostatic. At the present time the active principle, adrenalin, isolated from the suprarenal gland by Takamine, is placed on the market in various forms and under various names. One of the oldest is adrenalin chloride (adrenalin in solution with chloretone) in the strength of 1 part of adrenalin to 1000 parts of the chloretone solution. It may be employed in the eye in the strength of 1 to 1000 to 1 to 10,000; the weaker solution is promptly effective, producing blanching of the conjunctiva in one or two minutes, penetrating to the interior of the eyeball, and producing its hemostatic effect on the iris. Adrenalin chloride is of value as a hemostatic in operations on the eyeball and conjunctiva. It does not perfectly control the hemorrhage from the larger vessels of the subconjunctival tissue or the larger muscular branches, but makes it less profuse. Adrenalin chloride is valuable as an aid to increase the effect of cocaine and atropine. It does not produce any bad after-effects.

Adrenalin is of value in iritis to enhance the effect of atropine when complete dilatation of the pupil is difficult to obtain. In disease of the lachrymal passages, adrenalin chloride aids in establishing the lumen of the canals.

Adrenalin is contra-indicated in glaucoma. A number of cases of increase of tension on the instillation of solutions of adrenalin are on record.

Dionin (*Ethylmorphine Hydrochlorate*).—In 5 to 10 per cent. solution dionin has been used for the production of prolonged analgesia. When introduced into the conjunctival sac it produces smarting which is quite severe, edema of the ocular and palpebral conjunctiva and of the lids, and increased lachrymation. This lasts for from twenty to forty minutes and is followed by analgesia which persists for from a few hours to thirty-six hours.

If used daily, dionin ceases to produce the manifest irritation after about five instillations. If an interval of from five to seven days is permitted to intervene, the symptoms of irritation, edema, etc., are again produced on instillation of the drug. Many observers are of the opinion that the beneficial results of dionin are greatly lessened when it ceases to produce the characteristic hyperemia and edema; Dean[2] thinks that it still seems to improve the pathological condition.

[1] New York Med. Jour., May 16, 1893.

[2] Iowa Med. Jour., 1907, p. 213.

Dionin is neither a mydriatic nor miotic, but extreme miosis has been observed after its use (Suker, Wray).

Experiments on dogs enabled Batalow[1] to determine that dionin dilates the blood-vessels and lymph-vessels of the conjunctiva. Dionin has been thought to be a lymphogogue, but this is not proved. The very interesting experiments of Snyder[2] failed to show any wandering of lymph cells into conjunctival or other tissues of the eye.

Dionin favors the absorption of corneal and conjunctival infiltrates and exudates. It is of much value in the treatment of corneal ulcer, recent corneal opacities, parenchymatous keratitis, phlyctenular keratitis, scleritis and episcleritis, and is an analgesic in painful affections of the eye other than glaucoma. The use of dionin apparently increases the effect of atropine in iritis.

Dionin may be employed in 2, 5, or 10 per cent. solutions, or in the powder form, dusted on the conjunctival surface.

Massage.—Massage is employed to stimulate nutritive processes in the lids, conjunctiva, and anterior segment of the globe, for the purpose of softening cicatrices in the lids, as a therapeutic measure in trachoma, spring catarrh, and scleritis, to clear corneal opacities, and to decrease tension in glaucoma.

Simple Massage.—This consists in gently manipulating the lid between the thumb and finger, ordinarily from the cutaneous surface. The pressure must be gentle. It is employed to hasten resorption of effused blood and serum in ecchymosis of conjunctiva and lids, also to hasten clearing of the cornea and to disperse fluid after subconjunctival injections.

Medicinal Massage.—This is simple massage plus some form of medication, as the application of ointments to the surface of the lids or into the conjunctival sac. Diffusion of the medicinal substance and its absorption into the tissues are thus obtained.

Mechanical Massage.—This consists in the use of any instrument. Excellent results in the treatment of subacute trachoma are claimed by some operators (Elsching). A satisfactory method is to evert the lids, apply powdered boric acid, and by means of a smooth glass rod vigorously rub the boric acid into the granular surface for from one to ten minutes once a day or every second day.

Vibratory Massage.—This is massage by means of a small instrument operated by electricity, producing very rapid vibration. Massage of this character is thought to be of value in the treatment of hypopyon, in hemorrhage into the anterior and vitreous chambers, in increased tension of the globe (Connor), and even in some cases of atrophy of the optic nerve (Connor).

Pneumatic Massage.—Domec[3] has devised a cupping glass to fit over the eye to which a suction-pump is attached. The strokes of the pump are made gently, synchronously with the respiration, fifty to two hundred

[1] Wjestnik Ophth., i, 1902.
[2] Sec. on Ophth., Amer. Med. Assoc., July, 1905.
[3] La clin. opht., October 25, 1906.

times at a sitting. Each back stroke restores to the normal pressure. The treatment is said to give relief from pain even in glaucoma.

Collyria.—Watery Collyria.—These should be prepared with sterile distilled water. To the water may be added the drug, if any, that is designed to maintain the sterility of the solution—tricresol, 1 to 1000; boric acid, 3 per cent.; mercuric chloride, 1 to 10,000. If the drug which is to form the collyrium is itself a germicide, as the nitrate of silver, protargol, holocaine, etc., the distilled water only should be employed; but if the drug has no germicidal qualities, as cocaine, atropine, eserine, etc., the germicide to insure sterility may be added. Tricresol and boric acid are non-irritating and do not modify the effect of the medicinal factor. The mercuric chloride solution is very slightly irritating to the conjunctiva.

After the remedy has been added to the solution, it is advisable to put the solution in small sterile bottles (capacity ½ ounce), sterilize in a steam sterilizer at 100° C. for twenty minutes, close with sterile stopper (cotton, cork, rubber or glass), and properly label, adding the date of sterilization. The prepared collyria should be kept in a comparatively dry, cool place, protected from the light. If stoppered with cork and not used for some weeks they should be carefully inspected, as fungi may grow through or along the sides of the cork and contaminate the contents of the bottle.

Oily Collyria.—It has been found that collyria prepared with properly sterilized oils are less changeable and equally as efficient, often in less concentration, as watery collyria. Olive, peanut (arachis), almond and castor oils, lanolin or liquid vaseline (albolin) may be used. Scrini,[1] who has made a study of the subject, prefers olive oil as the vehicle. The oil is prepared as follows, after the method of Delacour. The oil is washed with the same quantity of alcohol (95 per cent.) to remove any irritating acid that the oil may contain. The alcohol and oil are left in contact for a few days, the mixture being agitated from time to time. The oil and alcohol separate on standing. The oil is then removed to a suitable glass container and sterilized in a sand-bath at a temperature of 120° C. for one-half hour. The receptacle is then stoppered with sterile cotton and kept in a cool, dark place until wanted.

The alkaloid of the drug is employed, as the acid salts are not fully soluble in the oil. In the preparation of the collyrium it may be necessary to heat the oil to some extent to insure rapid solution of the alkaloid. The following alkaloids may be used: Cocaine (2 per cent.), atropine (1 per cent.), duboisine (1 per cent.), homatropine (1 per cent.), pilocarpine (1 per cent.), eserine (1 per cent.), scopalamine (2 per cent.), eucaine (2 per cent.), holocaine (2 per cent.). If the scopolamine alkaloid does not dissolve because of its hygroscopic quality the hydrobromate may be used.

Scrini regards the oily collyria as most stable, more liable to be sterile, and more reliable in their effect than the watery collyria. They are non-irritating, and are more persistent in their effect. The collyrium may be put into the eye by means of a dropper or a glass rod.

[1] Précis de Thérapeutique Oculaire, page 51.

Subconjunctival Injections.—**Technique.**—Cocaine anesthesia and irrigation of the conjunctival sac with a saturated solution of boric acid. The eyelids are then held apart either by the fingers of an assistant or by means of a speculum. A fold of ocular conjunctiva is raised with mouse-tooth forceps at a distance of from 7 to 10 mm. from the corneal margin, usually above. The point of a sterile hypodermic needle is made to pierce the raised conjunctiva and the solution is injected, usually toward the equator of the globe, just beneath the conjunctiva. If it is designed to inject the solution into Tenon's capsule the capsule as well as the conjunctiva should be raised by the forceps. After injecting, the fluid is distributed by gentle massage through the eyelids. If there is much pain, edema, or extravasation of blood, cold compresses may be employed for some hours.

Remedies Employed.—The following remedies have been employed:

Mercuric chloride, 1 to 1000 to 1 to 3000, usually combined with cocaine or eucaine. (Painful.)

Cyanide (bicyanide, cyanine) of mercury, 1 to 5000, may be combined with dionin, 1 per cent., and sodium chloride, 0.8 per cent. Oxycyanide of mercury, 1 to 5000.

Sodium iodide, 1 to 100, usually with sodium chloride, 0.6 per cent. solution. Sodium salicylate, 0.025 per cent.; cocaine, 0.005 per cent.; (von Moll). Sodium chloride, 0.6 per cent. to 10 per cent. Formalin, 1 to 1000 (Churchman). Hetol, 1 per cent. solution on alternate days.[1]

Sterilized air[2] and solutions of quinine (Moggi) are used.

Beneficial Action.—It is believed that the beneficial action of subconjunctival injections is due to their stimulating effect on the blood and lymph circulation and not to the specific action of the particular remedy. It has been repeatedly observed that solutions of mercury are very apt to provoke a plastic process which results in adhesions between the tissues affected. Local necrosis has followed injections of mercuric chloride. Formalin is intensly irritating, and if used at all should be used with caution. After a careful experimental and clinical study, Verdame[3] concludes that injections of solutions of sodium chloride favor resorption of inflammatory exudates; that they may be used in the strength of 5 per cent. if necessary (the physiological salt solution, 0.6 per cent., is usually employed); that they are equally as efficient as solutions of the salts of mercury and are without their disadvantages.

Subconjunctival injections have been employed for very many diseases of the eye—scleritis, sclerokeratitis, parenchymatous keratitis, ulcers of the cornea, hypopyon keratitis, iritis, cyclitis, various forms of chorioiditis, uveitis, sympathetic ophthalmia, hemorrhages into the retina and vitreous, retinitis pigmentosa, detachment of the retina, atrophy of the optic nerve, panophthalmitis, etc. The mercurial preparations are thought to be particularly beneficial in affections of a syphilitic nature, sodium salicylate in rheumatic manifestations (scleritis, etc.), sodium

[1] Pflüger, Arch. d'opht., xxi, 7, p. 399.
[2] Terson, Annal. d'oculist., December, 1907.
[3] Zeit. f. Augenheilk., April and May, 1906.

chloride in the treatment of detachment of the retina. Hetol has been recommended by Pflüger for diseases of the anterior segment of the eyeball.

Injections are repeated after the reaction of the preceding injection has subsided, or, if no reaction of moment occurs, every second day.

The writer's experience with subconjunctival injections has not caused him to be very enthusiastic regarding them.

Intra-orbital Injections.—Solutions of mercuric chloride in the strength of 1 to 1000 to 1 to 3000, or solutions of the cyanide of mercury, 1 to 5000, may be employed. When used in cases of orbital cellulitis the injection may be made in two or three places at the same sitting. Bull and Weeks have employed solutions of mercuric chloride in orbital cellulitis with benefit. Valois[1] reports satisfactory results from the injection of solutions of the cyanide of mercury in two cases of sympathetic ophthalmia after the classical methods had failed.

Use of Tuberculins, Sera, and Vaccines.—**Tuberculins.**—It is conceded at the present time that tuberculins are very valuable in the treatment of tuberculous affections of the eyeball and its adnexa. Of 56 cases compiled by the writer, virtual cure occurred in 35 and improvement in fifteen cases. The principal tuberculins are as follows:

1. *Koch's Original Tuberculin, "T. O."*—This is a filtrate of an emulsion of bouillon cultures of tubercle bacilli, containing the products of the growth of the bacilli, substances extracted from the bacilli and the unaffected constituents of the bouillon. In process of preparation the tuberculin is exposed to a temperature of 70 to 80° C. As it appears on the market 1 c.c. is supposed to contain 1 mg. of the product before dilution.

2. *Koch's New Tuberculin (Tuberculin Residuum), "T. R."*—This is a centrifugalized extract of dried and ground tubercle bacilli. The sediment obtained by centrifugalizing is dried, reground, and dissolved in glycerin and water. (1 c.c. equals 1 mg. of the dried sediment or extract.)

3. *Bacillus Emulsion, "B. E."*—The liquid of the bouillon culture of tubercle bacilli is filtered off, the bacilli are washed between sheets of sterile filter paper and dried. They are then ground in a mortar until no whole bacilli are found on staining. The powder is taken up in 0.8 per cent. salt solution and added to 5 per cent. glycerin in water, so that 1 mg. of the powder is contained in 0.2 c.c. of the final preparation.

4. *Bouillon Filtrate, "B. F." (Denys).*—This is the unheated filtrate of bouillon cultures of human tubercle bacilli.

Of the tuberculins mentioned, T. O. is thought to possess relatively little therapeutic value because of its having been subjected to heat. The temperature of 70 to 80° C. to which it has been exposed largely destroys its power to produce antibodies or opsonins. It is of much value in diagnosis because of its comparative harmlessness when injected in large doses. It is the preferable preparation for this purpose.

[1] Receuil d'opht., 1903.

Diagnosis of Ocular Tuberculosis.—Since it is often quite impossible to make a diagnosis of ocular tuberculosis by means of the microscope, ophthalmoscope, or history of the case, it is necessary to resort to the well-known tuberculin-reaction test. The test is made as follows: The range of the patient's temperature is ascertained by taking it morning and night for a day or two. If there is no fever present the first injection may be 1 mg. of T. O., given in the subscapular tissue; if there is fever, the dose should be less. The typical reaction usually begins in from six to twelve hours, consequently it is best to give the injection early in the morning or late at night. The temperature should be taken every two hours until the reaction obtained is established or for thirty-six hours. If no reaction is obtained from the first injection, a second injection, this time of 2 mg., may be given after the lapse of two or three days. Trudeau writes: "If no effect has been caused by the tests as applied above (maximum dose 2 mg.) I have usually gone no farther and concluded that no tubercular process was present. . . . If some slight symptoms, however, have been produced by a dose of 2 mg., it may be necessary to give a fourth injection of 3 mg. in order to reach a positive conclusion. Nevertheless, it should be borne in mind that in a few cases the exhibition of even larger doses may cause reaction when the smaller do not. . . . The negative result should not, when applied within the moderate doses described, be considered absolutely infallible."

In employing this test for the diagnosis of *ocular* tuberculosis the reaction to be positive must be a local one. Tubercular foci may exist in other parts of the body, possibly undiscoverable by physical examination.[1] These may produce the general reaction, but would not produce a local reaction in a pathological process in the eye unless the lesion was tubercular. The local reaction is indicated by increased hyperemia and, in cases of tubercular nodules, an apparent swelling of the nodules.

Treatment of Tubercular Eye Lesions.—In the *treatment* of tubercular eye lesions, experience has proved that T. R., B. E., and B. F. are the most valuable preparations. They should be administered as advised by von Hippel, beginning with a dose not to exceed $\frac{1}{500}$ mg., increasing the dose by $\frac{1}{500}$ mg. (or by a larger amount if deemed necessary) at each injection, and giving the injections every third day if there is no general reaction. If there is a general reaction the injections should be discontinued until the reaction has completely subsided—five to seven days; the injections are then resumed in decreased dose. The dose should be so regulated that the effect on the patient is just short of the general reaction. The maximum dose should not exceed 1 mg. As improvement advances the injections should be given less frequently.

Sera.—Bacterial sera are specific remedies against specific bacterial infections. They are prepared, briefly speaking, by immunizing animals against the specific microörganims by injecting living bacteria, or their toxins, into the tissues, veins, or abdominal cavity of the animal, and

[1] The ophthalmotuberculin reaction is of little value in the diagnosis of ocular tuberculosis, since if employed for the diagnosis of tuberculosis it should be used in healthy eyes only, and the reaction obtained may be induced by tuberculosis in any part of the body,

collecting the serum after the animal has attained a high degree of immunity.

VARIETIES.—The bacterial sera at present available are:

Diphtheria antitoxin, initial dose, 1500 to 5000 units; antistreptococcic serum, initial dose, 10 to 20 c.c.(Parke, Davis & Co.); antimeningococcic serum (Flexner's); antigonococcic serum;[1] tetanus antitoxin.

Deutschmann's Serum.[2]—This is obtained from animals that have been fed on living yeast cells in large quantities. It appears on the market in two forms, "Deutschmann's serum" and "Deutschmann's serum E." The latter is about twice the concentration of the former.

Cytogenic Sera.—Cytogenic sera are those obtained from animals injected either subcutaneously or intraperitoneally with animal cells or extracts of the cells (organ pulp or nucleoproteids are employed). Beebe and Rogers[3] have evolved a cytogenic serum for the treatment of exophthalmic goiter, from the sheep, using products (nucleoproteids) from the normal and pathological thyroid glands to inoculate the sheep.

Möbius' Serum.[4]—This is the serum of thyroidectomized sheep. It is used for the treatment of Graves' disease.

DOSE.—Since sera contain (or are supposed to contain) bodies (antibodies) to neutralize or destroy the effect of the toxins developed by the pathogenic germ to which the disease is due, the dose may be regulated by the reaction on the system.

Vaccines.—It has been demonstrated, principally by Sir A. E. Wright, that the injection of dead pathogenic bacteria into the subcutaneous tissue or blood produces in the fluids of the individual substances which render the taking up and destruction of pathogenic bacteria of the same species by the phagocytes much easier and the process more energetic. He is of the opinion that the substance produced unites with the bacteria and prepares them for phagocytosis. Wright terms this substance "opsonin."

The preparations of dead bacteria used for inoculating individuals are termed *vaccines.* A vaccine is specific for the particular strain of bacterium from which it is made. Such a vaccine is termed an autogenous vaccine. If the particular strain of bacteria cannot be obtained for making the vaccine, complementary elements may be found in each of a number of foreign (heterogenous) strains of the same bacterium, the sum of which may almost equal the vaccine made from the specific strain. The latter are termed "polyvalent" or "stock" vaccines.

Since autogenic vaccines, particularly those prepared from the streptococci and staphylococci, may be made by any one having culture facilities at his disposal, the method of prepartion is given below.[5]

[1] Rogers and Torrey, Jour. Amer. Med. Assoc., 1907, p. 913.

[2] Münch. med. Woch., 1907, No. 19.

[3] Jour. Amer. Med. Assoc., February 17, 1906.

[4] Münch. med. Woch., 1903, No. 4.

[5] *Preparation of Vaccines.*—"Luxuriant cultures of the desired organisms are grown upon inclined agar. The growth is then removed with salt solution and a glass rod, and thoroughly emulsified by shaking in a test tube in order to get the germs well distributed and the clumps broken up. The number of germs in a given quantity of the emulsion is then determined by comparing the number of germs and red blood corpuscles in a mixture of one part emulsion, one part of freshly drawn

Sir A. E. Wright advises injecting the vaccine in the loose subcutaneous tissue as near the site of the lesion as possible and "up-stream" as regards the flow of lymph, in order that the opsonins resulting may be carried as directly as possible to the disease area in the lymph stream. The sites usually selected are the loose tissue of the back, the lumbar region, or the groin; these of course do not afford a lymph stream toward the eye; the nearest approach to a desirable site is the tissue at the temple.

The stock vaccines at present available for the treatment of diseases of the eye are:

B. coli vaccine, dose, 5,000,000 to 50,000,000.

Pneumococcus vaccine, dose, 10,000,000 to 50,000,000.

Pyocyaneus vaccine, dose, 5,000,000 to 50,000,000.

Staphylococcus vaccine, dose, 50,000,000 to 1,000,000,000.

Streptococcus vaccine, dose, 10,000,000 to 25,000,000.

Gonococcus vaccine, dose,[1] 5,000,000 to 50,000,000.

The sera, toxins, and vaccines that have been mentioned have all been employed with encouraging results in diseases of the eye except the antimeningococcus serum. The entire subject is as yet in its infancy and will undoubtedly undergo changes before its application is definitely settled.

In regard to the dose of vaccines, Wright[2] says that "the proper principle of dosage in any series of injections is never to advance to a larger dose until it has been ascertained that the dose which is being employed is too small to evoke an adequate immunizing response." According to his view, the dose in size and time of administration should be governed by the "opsonic index;"[3] however, the difficulties of the application of the opsonic index are such that many clinicians regulate the dose according to the clinical indications.

Römer's Serum.—Römer's serum[4] is a polyvalent serum of the pneumococcus at present prepared and put on the market by Merck. It has been recommended by Römer as a prophylactic measure against pneumococcal infection in cases of wounds of the cornea and as a therapeutic measure in the early stage of pneumococcic ulcer of the cornea. It has been found to be of little or no value in the later stages of this form of ulcer.

Administration of Mercury.—Mercurial Inunctions.—The introduction of mercury into the system by inunction is painless, efficient, and safe, provided ptyalism is avoided. Two preparations are employed—mercu-

blood, and three parts of normal salt solution. If there are ten times as many germs as blood-corpuscles the bacterial suspension contains approximately 45,000,000 germs per cubic millimeter. The bacterial suspension is heated at the lowest temperature and shortest time to kill it. The amount of sterilization will differ with different organisms; 60° C. or less, maintained for thirty minutes or less, is usually sufficient. Cultures of the vaccine are finally made to determine sterility and some preservative added" (Parke, Davis & Co.). Tricresol in small quantity (1 to 10,000) is a good preservative.

[1] Tuberculins, sera, toxins and polyvalent vaccines are prepared by Parke, Davis & Co., of Detroit, Michigan; by Mulford & Co., of Philadelphia, and at other laboratories in the United States.

[2] Jour. Amer. Med. Assoc., August 10, 1907.

[3] For a description of the technique of taking the opsonic index and of its application, see Allen, Vaccine Therapy, second edition, P. Blakiston's Son & Co., Philadelphia, Pa.

[4] Zeitschr. f. Augenheilk., March, 1904, p. 193.

rial ointment, U. S. P. (blue ointment), containing 50 per cent. of mercury, and the oleate of mercury, U. S. P., containing 20 per cent. of mercury.

Mercurial Ointment.—The ointment is sometimes rather hard and not sufficiently easily manipulated. This may be avoided by incorporating with it 33 per cent. of vaseline. If the ointment is applied to the skin in one location for a number of days in succession, a mild dermatitis may develop. On this account it is better to change about, using the same location only once in two or three days. The areas best adapted for the inunction are the inner surfaces of the thighs, the inner surfaces of the arms, sides of the chest beneath the axillæ, and the groins. It is desirable to cleanse the surface with soap and water and dry it before applying the ointment. The dose of ointment is ordinarily 4.00 gm. (1 dram). If applied by a person other than the patient, finger-cots may be employed to prevent the absorption of the remedy into the individual's system; ordinarily the amount absorbed through the skin of the fingers of the one applying it is so insignificant that this precaution may be disregarded. The ointment is applied to the skin and gently rubbed in until all has been absorbed. This will require ten to twenty minutes. If it is desired to influence the system rapidly, two inunctions daily may be employed. If after the treatment has been established a mild continuous effect is desired, one inunction daily or every second day will suffice.

The oleate of mercury may be employed in the same manner as the ointment. Absorption of the oleate is thought to be more rapid than absorption of the ointment.

If the ointment is to be used for infants or small children it may be smeared on the lower part of the abdomen and an abdominal bandage applied, a layer of thin linen cloth being placed next to the skin. In adults a closely fitting undershirt to take up surplus ointment and to maintain a more or less continuous contact with the skin, permitting of continuous absorption, may be worn during the treatment.

Intramuscular Injections of Mercury.—By this method the dose may be accurately measured. The rapidity of absorption depends (*a*) on the solubility of the preparation of mercury employed and (*b*) on the character of the menstruum. Oily preparations are absorbed less rapidly than watery preparations. The site usually preferred is the nates about 7 cm. back of the great trochanter, but the muscles of the back may be used. The needle employed should be sufficiently long to enter the tissues 2 to 4 cm. It should be introduced perpendicularly to the surface and should enter muscle tissue. It is sufficient to rub the surface of the skin vigorously with alcohol, 90 to 95 per cent., before piercing the skin with the needle. The puncture should be sealed subsequently with collodion. Massage after the injection is not advised. The preparations employed are:

(*a*) *Watery Solutions.*—(1) Mercuric chloride, 1 to 2 per cent., in solution of sodium chloride, 1 per cent.; inject 1 c.c. every third or seventh day, as required. (Painful.)

2. Succinimide of mercury, 1 per cent. solution; inject 1 to 2 c.c.; said by Selenew to be superior to the salicylate or the gray oil.

3. Sozoiodolate of mercury, 1 per cent., in solution of iodide of sodium, 2 per cent.; inject 1.5 c.c. once a week.

(*b*) *Oily Solutions.*—

No. 1.

℞—Hydrarg. salicylate 1.0
Vaseline liquid . . . . . 10.0—M.
S.—Inject 1 c.c. every fifth or seventh day. Shake well.

No. 2.

℞—Hydrarg. oxidi flav. 0.5
Vaseline liquid . . . . . 10.0—M.
S.—Inject 1 c.c. every fifth or seventh day.

No. 3.

℞—Gray oil 1.0
Olive oil . . . . . 1.0—M.
S.—Inject 0.1 to 1.5 c.c. every second or third day.

Injections of the watery solutions are painful, the mercuric chloride being more painful than the others. The pain may be lessened to some degree by the addition of a small quantity of cocaine (1 per cent.).

Injections of the oily preparations are slightly painful.

Intravenous Injections.—*Technique.*—After cleansing the skin of the forearm, the forearm is constricted just below the elbow. When the superficial veins become prominent, the needle of a sterile hypodermic syringe is caused to enter a vein in the axis of its lumen. When this is accomplished a slight withdrawal of the piston of the syringe will cause the venous blood to enter the syringe. When it is ascertained that the point of the needle is in the lumen of the vein, the piston is pressed home and the withdrawn blood and the medication are slowly forced into the vein, the constricting band having first been removed.

℞—Cyanide of mercury 0.05
Distilled sterile water . . . . . 5.00—M.
S.—Inject 1 c.c. intravenously every second day.

This method is said to be painless. It has been found (Rochon-Duvigneaud) that young subjects tolerate the mercury by intravenous injection better than the aged. It is well to begin with 0.25 to 0.5 c.c. in old people. Syphilographers advise a course of thirty injections, followed by an intermission of varying length.

When mercury is being given by whatever channel, the teeth and mouth should be kept free of decomposing food to prevent ptyalism. It is a good plan to brush the teeth with salt solution, 1 to 2 per cent., after each meal and to wash the mouth at least once a day with a 1 per cent. solution of potassium chlorate. On the development of tenderness of the teeth or puffiness of the gums the mercury should be discontinued until these symptoms have subsided.

Salicylate of Soda.—The giving of this remedy in large doses in the treatment of all non-specific inflammations of the sclera, cornea, iris,

ciliary body, and in sympathetic ophthalmia is advised by Gifford[1] and Morton, and in tenonitis by Gradle. Gifford advises one grain to each pound of body weight in the twenty-four hours. Morton[2] gives forty grains in cold water on an empty stomach every three or four hours in severe cases until relief is obtained. Gifford attributes the effect of the drug to depletion of the inflamed tissues by means of the general capillary distention which it occasions.

The tinnitus occasioned by the giving of large doses of salicylate of soda and the gastric disturbance experienced by many preclude its use in those who are susceptible.

Fig. 528

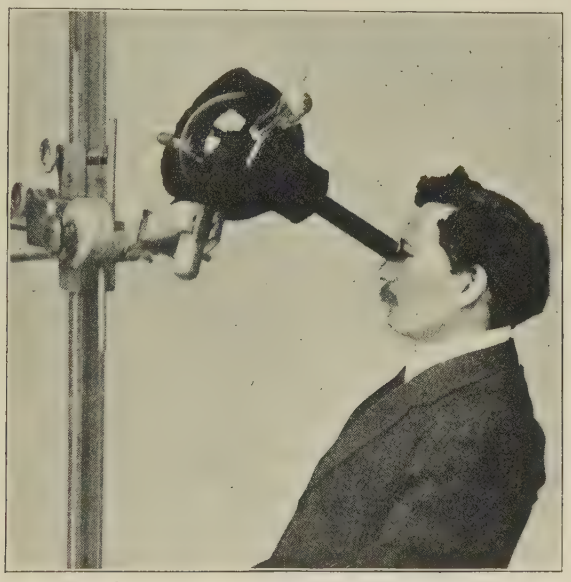

Position of patient and tube when Röntgen rays are employed for treating the eye and eyelids.

Röntgen Rays.—The Röntgen rays for therapeutic purposes may be applied to the eyes or eyelids in the following manner: A low vacuum tube is connected with a ray-proof jacket having an eight-inch tube attached. The lumen of the tube, 1½ inches, is placed with its axis at right angles with the anode. The portion of the eye to be treated is brought close to the end of the tube and the rays generated (Fig. 528). The exposure is made every second or third day and is from five to eight minutes' duration. No ill-effects are produced by this method of exposure. Trachoma, vernal catarrh and epithelioma of lids, conjunctiva and eyeball may be treated in this manner.

Radium.—Radium is applied by placing the glass tube which contains the radium (radium bromide or chloride) directly on the tissue

[1] Ophth. Record, December, 1902.

[2] Ophth. Record, N. S., xii, 1, p. 10.

to be treated and permitting it to remain from three to twenty minutes. No injury to the eye has been reported thus far. Radium has been used with reported benefit in the treatment of sarcoma of the eyelid, trachoma, vernal catarrh, epithelioma, episcleritis, corneal opacities. A salt of radium having a radium activity of 1,500,000 to 1,000,000 units as compared with uranium is employed. The application is painless.

Hyperemia (*Bier's*[1] *Treatment*).—The induction of venous hyperemia in the treatment of affections of the eye has not as yet proved of any particular value.

Renner[2] found that by placing an elastic band around the neck and exerting moderate pressure, redness of the ocular and palpebral conjunctiva developed. He studied the influence of the condition thus produced on diffuse keratitis, simple and hypopyon ulcer of the cornea, maintaining the hyperemia for from six to twelve hours a day. Roemen[3] used the same method in similar cases. The results reported by these observers were not very gratifying.

Gruening has employed this method in combination with the recumbent position and elevation of the hips and lower extremities in the anemia of the retina and optic nerve accompanying methyl-alcohol amblyopia. The results were not encouraging.

Hesse[4] and Hoppe[5] have used a cupping apparatus applied over the eyelids, exerting a negative pressure of from 20 to 50 mm. of mercury. In addition to corneal ulcer, they have treated hordeolum, abscess of the lid, purulent dacryocystitis. The application was made two or three times a day for fifteen to twenty minutes each time. The results were virtually negative.

[1] Montreal Med. Jour., June, 1906.
[2] Münch. med. Woch., January, 1906.
[3] Wiener med. Woch., April, 1906.
[4] Centralbl. f. prak. Augen., June, 1906.
[5] Münch. med. Woch., October, 1906.

CHAPTER XXXI.

PREPARATION OF SPECIMENS FOR DIAGNOSIS IN THE SEARCH FOR MICROÖRGANISMS.

In the ordinary conduct of clinical work, much can be done to clear up the diagnosis by the microscopic examination of secretions and scrapings by the surgeon without much expenditure of time and with simple apparatus.

Collection of Material.—In order to obtain satisfactory results it is necessary that the material should be collected from the proper site and at the proper time.

Conjunctiva.—In all forms of acute conjunctivitis the material should be taken in the early stage or when the acute stage is at its height, as the causal agent may rapidly disappear after the inflammation is established and the preparations show only skin bacteria (staphylococci) and saprophytes. The secretion in conjunctivitis should be taken from the conjunctival surface before the secretion has come in contact with the margins of the lids. If taken in this way almost pure cultures of the pathogenic germ may be found. If the secretion is very scant it may be necessary to take it from the inner canthus. It is often sufficient when secretion is scanty to pass the sterile platinum loop through the moist folds of the lower fornix and to use what is collected for smear or culture. This is particularly true of diplobacillary conjunctivitis.

In obtaining material from an eczematous nodule (phlyctenule) the material should be taken in the early stage of the development of the nodule. The conjunctiva is cocainized, the lids separated by means of a speculum, and the eye fixed. The surface of the nodule and the adjacent area are then rendered aseptic by irrigating with normal salt solution, washing with bichloride solution, 1 to 4000 or 1 to 5000, and again irrigating with normal salt solution. A sterile platinum rod may then be used to open the nodule and to remove a portion of the contents. Smears and cultures may then be made. In examining the contents of follicles, as those of trachoma, the surface is thoroughly sterilized and the follicle excised under antiseptic precautions. The contents of the follicle are then expressed and a portion that has not come in contact with instruments or epithelial surface is selected and removed. In obtaining smears for the study of the trachoma body of Prowazek and Halberstädter, one or two drops of a 4 per cent. solution of cocaine are instilled, and the conjunctival sac is irrigated with normal saline solution, the trachomatous surface is exposed, and the surface gently scraped, either with the edge of a clean sterile coverglass, a sterile platinum spud or scalpel, the debris thus obtained is spread in a thin layer over the surface of the cover glass, dried

in the air and fixed with absolute alcohol. Specimens are best obtained from untreated cases, but may be obtained in old cases of trachoma and even from pannus (Lindner).

Cornea.—In selecting material for examination from the cornea in corneal ulcer it must be remembered that the pathogenic germ will probably not be found unless the process is progressive. If the ulcer is progressive the germ may be found in the secretion covering the progressive part (streptococci, diplobacilli), or it may be found only in the tissue itself at the progressive parts. In pneumococcic ulcer the microorganisms are located in the tissue beneath the overhang in the undermined portion. The microörganisms in all cases may be found in the tissue of the cornea near the surface in the advancing portion of the ulcer. Care must be exercised not to inflict injury on an already damaged cornea in removing the material. The eye is cocainized, irrigated with normal saline solution, a speculum inserted to separate the lids, and the eyeball fixed. After again irrigating with physiological saline solution the surface is gently dried with sterile wipes. The secretion adhering to the walls and floor of the ulcer is now removed by means of a sterile spud and smears and cultures are made from this material. The wall of the *advancing portion* of the ulcer is now very carefully scraped by means of a sterile sharp spud or small sharp curette. Smears of this material should show the pathogenic germs.

Immediately on removal of the material for examination the ulcer should be cauterized or treated with the necessary germicide.

Anterior Chamber.—The aqueous in iritis may contain the specific microörganism, the tubercle bacillus in cases of tubercular iritis, the Spirochæta pallida in syphilitic iritis. The specimen is secured by entering the anterior chamber with a hypodermic needle and aspirating the fluid. The presence of tubercle bacilli is best determined by inoculating the anterior chamber of a rabbit's eye with the withdrawn aqueous. The plastic material forming the hypopyon in hypopyon keratitis may in some cases be partly withdrawn by means of a hypodermic syringe, but in many cases a paracentesis of the anterior chamber will be necessary. It should be remembered that the hypopyon is frequently sterile in nonperforating ulcer and in inflammatory processes in which perforation of the fibrous coat of the globe has not occurred. Material for bacteriological examination cannot often be obtained from the structures within the eye back of the iris, before enucleation, without danger of doing damage to the eye and probably inducing extension of the disease process. When a foreign body is removed cultivation experiments may be made from its surface.

Soft concretions should be teased out in a drop or two of a suitable menstruum. Hard concretions should be crushed on a glass slide by means of a sterile glass rod.

Cultivation.—**Food Media.**—For the cultivation of the more hardy pathogenic organisms (streptococci, staphylococci, Bacillus pyocyaneus, etc.) the ordinary food media (gelatin, agar, bouillon, potato, etc.) suffice, but for the development of some of the microörganisms, media containing

serum are necessary and for some, hemoglobin. The following media are valuable:

Loeffler's Blood Serum.—Serum from the blood of some animal (sheep, horse, or other suitable animal) is collected in a sterile glass receptacle, shaken up with chloroform to sterilize, and decanted. Mix with one-third its volume of grape-sugar bouillon, pour into test-tubes (each 5 c.c.), place in a slanting position, and sterilize at 60° C. one-half hour each day for six days (fractional sterilization). The preparation should be only very slightly alkaline. (For the pneumococcus and the diphtheria group.)

Serum Agar (*Wertheim Formula*).—Neutral agar, 1 per cent solution, cooled to 45° or 50° C.; to this add one-third to one-fourth its volume of ascites, hydrocele, pleuritic or ovarian-cyst fluid (human), previously "fractionally" sterilized at 60° C. Put in culture tubes; slant the tubes and permit to cool. The completed preparation should be only very slightly alkaline. A modification of the reaction should be made with the solution of agar before adding the serum. (Valuable for the cultivation of the Koch-Weeks bacillus, diplobacillus, pneumococcus, gonococcus, etc.—Axenfeld.)

Hemoglobin Media.—In preparing hemoglobin media for the cultivation of hemophile bacteria (influenza group), a drop or two of sterile blood may be caught in a sterile platinum loop and spread over the surface of the blood serum in a blood serum tube, or the blood may be added to bouillon. Human blood may be obtained (at operation, from finger or ear) or pigeon's blood may be used (Axenfeld). When blood is added to agar it may be mixed with it before the agar solidifies or may be spread over the surface of the agar.

When culture tubes are inoculated the media should be at about the incubation temperature in order to present the most favorable conditions for growth.

When one is familiar with the food medium necessary for the growth of each of the various bacteria, the bacterial contents of the smear will determine the food medium to be employed. If the particular form to be cultivated is not known, a number of different media should be inoculated; the material should be spread out over the surface of the media and stick inoculations should be made in order to obtain isolated colonies and to determine the aërobic or anaërobic nature of the germ. Pure cultures may be obtained by reinoculating from isolated colonies.

Inoculation of Eyes of Animals.—The animal if small (rabbit or guinea-pig) is usually held by extending the legs, laying it on its side on a table, and gently pressing the head against the table.

Conjunctival Sac.—To inoculate the conjunctival sac drop an emulsion of the growth to be tested into the conjunctival sac and rub the emulsion into the mucous membrane by means of a sterile glass rod or small sterile cotton probang, or employ friction through the lid.

Cornea.—To inoculate the cornea make a wound in the cornea by means of an infected knife or make a small pocket in the corneal tissue by

means of a knife and rub in some of the emulsion of the germ from a platinum loop or needle.

Interior.—In piercing the fibrous coat of the eye with a needle or knife for the purpose of inoculating the interior of the eye, the puncture should be made diagonally so that it will close after the instrument is withdrawn.

Anterior Chamber.—If solid tissue is to be introduced, the eye is cocainized, a small incision is made through the cornea near the scleral margin in the upper outer quadrant a drop of cocaine is again instilled. The piece of tissue is now pushed through the opening by means of a spatula and carried well into or below the pupillary area. If this is not done the mass is liable to be extruded by flow of aqueous through the wound. Emulsion or fluids are introduced through the needle of a hypodermic syringe, a portion of the aqueous having first been permitted to escape in order to reduce the intra-ocular tension.

Vitreous Chamber.—In introducing solids or liquids into the vitreous chamber for inoculation purposes the tension of the globe should be reduced after the puncture is made by tapping the anterior chamber (if the puncture were made after the aqueous had escaped the eye would be flaccid). Inoculation is then performed with relative ease.

Staining.—Coverglass Preparations (*"Smears"*).—The material is spread in a very thin layer on a coverglass or glass slide by means of a platinum loop, or a small amount of the material (as large as the head of a pin) is placed on a sterile coverglass or slide, another coverglass or slide is placed over the material, and a thin, even layer made on the opposing surfaces of both pieces of glass by pressure, sliding one glass from the other in separating them. The preparation is dried in the air and "fixed" by passing three times through a Bunsen or spirit flame. The film of material should be thin and evenly distributed in order that the effect of the stain may be uniform throughout. This is particularly desirable when staining with Gram.

If differentiation in staining is not necessary, Loeffler's methylene blue or the carbol-fuchsin stain will usually give satisfaction for all bacteria found in the eye except tubercle and leprosy bacilli.

Loeffler's Methylene Blue.—Saturated solution of methylene blue in alcohol, 30 c.c. Solution of caustic potash in sterile distilled water, 0.01 per cent., 100 c.c. A few drops of this solution are placed on the prepared film on the coverglass or slide, and allowed to remain a few minutes. The film is then washed in water (under the tap) and examined in water, or the film may be dried and mounted in oil or balsam.

Fuchsin Stain.—

℞—Distilled water	10 c.c.
Ziehl's[1] carbol-fuchsin	10 to 20 gtt.

Stain a few seconds to one minute. Wash in water. If intensely stained, treat with very dilute acetic acid. Afterward wash well with water.

[1] Ziehl's solution: Fuchsin, 1; absolute alcohol, 10; carbolic acid, 5; distilled water, 100.

For photomicrography fuchsin gives better results than methylene blue.

Nicolle's Thionin Stain.—Morax recommends the following for the Koch-Weeks bacillus and for other microörganisms that stain badly:

The nuclei stain blue, the bacteria reddish.

℞—Thionin, sat. sol., in 50 per cent. alcohol	10
Carbolic acid, 1 per cent. watery solution	100

Stain one-half to one minute. Wash in water.

Gram Stain.—This is very valuable as a means of differentiation. Axenfeld employs it as follows:

After fixation of the smear—

1. Stain for twenty-five seconds in the following solution:

℞—5 per cent. watery sol. gentian violet[1]	88 parts
Ol. anilin pur.	2 parts
Abs. alcohol	10 parts

Filter before using.

2. Wash with water.
3. Iodine in potassium iodide solution (1 to 2 to 300) fifteen seconds; the preparation must take on a dark-brown tint. Then, without washing,
4. Decolorize with absolute alcohol until no color washes out.
5. Wash in water.
6. Counterstain with 5 per cent. watery safranin or weak fuchsin for five seconds.
7. Thoroughly wash with water, dry, and examine in water, oil, or Canada balsam.[2]

The following precautions should be observed:

(*a*) In staining with Gram the preparation film should be uniformly thin.

(*b*) The whole film should be rapidly covered with the stain.

(*c*) Do not overdo the iodine.

(*d*) Wash away the alcohol thoroughly with water.

(*e*) Avoid overstaining with the contrast dye. Wash thoroughly after contrast staining.

In order to control the stain it is of value to place on the slide or cover-glass a very small area of Gram positive micröorganisms—fresh culture

[1] Loeffler (Deutsch. med. Woch., 1906, page 1244) states that methyl violet 6B or BN, dissolved in 1 to 2.5 per cent. carbolic acid in a proportion of 1 to 10, gives better results.

[2] Another commonly used modification is the Gram stain according to Czaplewski:

1. One minute in carbol gentian (sat. alcoholic sol. of gentian violet, 50 c.c.; 5 per cent. carbolic acid watery sol., 50 c.c.; aq. dest., 50 c.c.).
2. Wash.
3. Thirty to sixty seconds in Lugol's solution (iod., 1; pot. iod., 2.; aq., 300).
4. Wash; dry with filter-paper.
5. Differentiate in anilin xylol (2 to 1 + 1.5 per cent. acetone).
6. Wash in xylol; dry in air.
7. Counterstain for one minute in carbol-glycerin-fuchsin (1 gm. fuchsin triturated with 5 c.c. of ac. carbol. liq., 50 c.c. glycerin, and 100 c.c. aq. dest.).
8. Wash and dry.

Should differentiation be difficult, carefully add 1 drop of alcohol to the anilin zylol. Fibrin and richly nucleated structures are more easily differentiated if the material be spread on the slide with water.

of staphylococcus. The conduct of the microörganisms studied to Gram can be readily compared to that of the added microörganisms.

The Gram positive microörganisms of interest in ophthalmology are:
Most of the sarcinæ;
Staphylococci, streptococci, pneumococci;
Bacilli of the diphtheria and subtilis group;
Bacillus perfringens (Chaillous);
Aspergillus fumigatus, streptothrix, and actinomyces.
Gram negative are:
Bacilli of Koch-Weeks and Pfeiffer (L. Müller, influenza);
Diplobacilli of Morax-Axenfeld and Petit;
The colon group;
Gonococcus, meningococcus, micrococcus catarrhalis;
Bacillus pyocyaneus;
Group of Friedländer's pneumobacillus.[1]

Spirochæta Pallida.—This supposed cause of syphillis has been found in the fluid drawn from the anterior chamber in acute iritis,[2] in the cornea in keratomalacia in syphilitic children (Stephenson), and in the cornea of prematurely born syphilitic children (Stock, Römer, and others). It has also been found in all the other tissues of the eye except the lens. According to Schaudinn the Spirochæta pallida is between 10 and 15 μ in length (by the silver method still longer spirals can be found), and of an even breadth of only $\frac{1}{4}$ μ. The ends are pointed and have each a cilium. The coils are sharp, regular, short, and about 1 μ long.[3]

Giemsa's Method of Staining.—Giemsa solution for Romanowski stain, 1 to $1\frac{1}{2}$ drops; water containing 1 to 10 drops of $\frac{1}{1000}$ potassium carbonate, 1 c.c. Mix fresh every time and stain from fifteen minutes to one hour or more; wash rapidly, dry, and mount.

In a successful film the nuclei of the leukocytes are dark red, the Spirochæta pallida is light red, the other spirochætæ bluish. (Grubler, of Leipzig, prepares and sends out under the name "Giemsalösung für die Romanowskyfärbung" the eosin-azur dye, the exact constituents of which can therefore be omitted.)

Preiss' Rapid Method.—Mix twenty drops of Giemsa solution with 10 c.c. of distilled water; divide into three parts; pour one-third over the preparation and heat it high above the flame until steam forms; pour away the stain and repeat with each of the other thirds of the solution; wash with water. Good preparations can thus be obtained in from four to five minutes.

Silver Method of Levaditi for Sections.[4]—The tissue is cut into small pieces (the anterior part of the eye can be treated as a whole) which are taken either direct into 96 per cent. alcohol or first into 10 per cent.

[1] For a complete discussion of the staining of the bacteria of the eye, see Axenfeld and MacNab, English edition, 1908, page 5.

[2] Zur Nedden, Heidel. Congress, 1906.

[3] Full details of the appearances and the differential diagnosis are to be found in the monograph by E. Hoffmann, "Die Aetiologie d. Syphilis," Berlin, 1906 (J. Spinger).

[4] Ann. de l'Inst. Pasteur, 1906, xx, p. 1.

formalin for a few days, and then, after washing with distilled water, placed in alcohol for twenty-four hours. From alcohol they are placed in distilled water until they sink, and then in a dark vessel in the oven in 2 per cent. nitrate of silver for three days (according to Gierke, better 1.5 per cent. for eight days). Wash with distilled water and put into the following developing solution for forty-eight hours: pyrogallic acid, 4; formol, 5; distilled water, 100; embed in paraffin and cut in series. The spirochætæ appear black, with short and variable spirals and pointed ends; occasionally one end divides.

Heim recommends Hoffmann's modification. The pieces of tissue, after fixation in alcohol and formol, are suspended by linen threads in a freshly prepared mixture of 90 c.c. of 1.5 per cent. nitrate of silver and 10 c.c. purest pyridin. In this they remain for three hours cold and then three hours in the paraffin oven at 45° C. in a dark glass-stoppered bottle.

The developing solution must be freshly prepared, thus: Mix 90 c.c. of 4 per cent. pyrogallol with 10 c.c. of pure acetone and add 15 c.c. pyridin to 85 c.c. of the mixture. In this the pieces remain cold over night. Rapid paraffin embedding.

Contrast-staining with polychrome methylene blue is possible. All glass dishes must be thoroughly cleansed with ether and alcohol and the solutions must be fresh.

Trachoma Body Stain.—To stain the trachoma body of Halberstädter and Prowazek a number of methods have been employed with good results.

Technique.—Coverglass dried in the air, fixed in absolute alcohol, twenty to thirty minutes.

The coverglass is permitted to float on the surface of the freshly prepared stain, film surface down, six to nine hours, at a temperature of 37° C. (If the temperature is kept at 50° C. the time is reduced to three hours.)

Stain.—Giemsa's eosin solution (2.5 c.c. 1 per cent. French eosin in 500 c.c. distilled water), 12 parts; azur I (1 to 1000), 3 parts; azur II (0.8 to 1000), 3 parts.

After staining the films are washed in distilled water, dried in the air, and mounted in cedar oil.

Wright's stain for blood films may be employed.[1] This is a very short process.

The Benda Heidenhain iron hematoxylin stain may also be used.

In preparing sections the tissue mass should be hardened in alcohol, embedded, and cut in paraffin.

The staining process is by either of the above methods. Decolorize in absolute alcohol if the stain is too deep. Mount in cedar oil if the Giemsa stain is used, in balsam if Wright's or the Benda Heidenhain stain is employed.

[1] See Mallory and Wright, Pathological Technique, page 372.

Description and Some of the Culture Characteristics of the Pathogenic Microörganisms of the Eye. (Modified from Axenfeld).

	Name and bacteria.	Size in μ.	Flagella.	Capsule.	Gram + or —	Development. Aërobic.	Development. Anaërobic.	Development at the temperature of the room.	Thermal range.	Growth on Loeffler's serum. Liquefies.	Growth on Loeffler's serum. Does not liquefy	Liquefies gelatin.	Bouillon culture. Pellicle.	Bouillon culture. Clouding.	Bouillon culture. Acid formation in grape sugar bouillon.	Milk culture. Coagulation.	Milk culture. Alkaline changed to acid reaction.	Milk culture. Spore development.	Pigment development on agar.	Indol reaction.	Production of gas in sugar agar.
Hemophilic bacteria.	1. Koch-Weeks bacillus	L. 0.5–2.0 T. 0.10–0.15	—	—	—	+ (Serum agar).	—	—	25° to 45° C.	—	—	—	—	+ Serum bouillon	—	—	—	—	—	—	—
	2. Influenza bacillus.	L. 0.5 T. 0.2–0.3	—	—	—	+ (Blood agar).	—	—	24° to 43° C.	—	—	—	—	+ Blood bouillon	—	—	—	—	—	—	—
Diplobacilli.	3. Morax-Axenfeld diplobacillus.	L. 2.0–3.0 T. 1.0–1.5	—	Inconstant.	—	+	—	—	12° to 43° C.	—	+	—	—	—	—	—	—	—	—	—	—
	4. Petit's diplobacillus liquefaciens.	L. 2.0–3.0 T. 1.0–1.5	—	Inconstant.	—	+	—	—	12° to 43° C.	—	+	+	—	+	—	—	—	—	Grayish	—	—
	5. Friedländer's pneumonia bacillus.	L. 1.5 3.5 T. 0.8–1.3	—	+	—	+	+	+	16° to 43° C.	+	—	—	—	+	—	+	Acid.	—	Grayish white.	+	+
	6. Bacterium coli.	L. 0.8–3.2 T. 0.4–0.6	Often many.	—	—	+	+	+	5° to 45° C.	+	—	—	—	+	—	+	Acid.	—	Grayish white.	+	+
	7 Bacillus ulceris corneæ Zur Nedden.	L. 0 9–2.0 T. 0.6	—	—	—	+	—	+	8° to 43° C.	+	—	—	—	+	—	+	Acid.	—	Grayish white.	—	—
Subtilis group.	8. Bacillus subtilis (hay bacillus).	L. 1.2–4.0 T. 0.8–1.2	+	—	+	+	+	+	7° to 43° C.	+	+	+	+	+	—	+	Slightly alkaline.	+	Gray.	—	—
	9. Bacillus mycoides (root bacillus).	L. 1.6 3.6 T. 0.8	Seldom	—	+	+	+	+	7° to 43° C.	+	+	+	+	+	—	+	Alkaline.	+	Gray.	—	—
	10. Bacillusmesentericus.	L. 0.8–2.4 T. 0.7–0.9	Many.	—	+	+	+	+	7° to 43° C.	+	+	+	—	+	—	+	Slightly alkaline.	+	Grayish brown.	+	—
	11. Bacillus pyocyaneus.	— 1.0–6.0 T. 0.6	One.	—	—	+	+	+	8° to 43° C.	+	—	+	+ weak.	+	—	+	—	—	Greenish blue.	—	+
	12. Bacillus perfringens.	L. 3.0–9.0 T. 1.0		—	+	—	+	+	..	..	..	—	+ Deposit	+ Deposit				—	Gray.	—	+
	13. Bacillus mucosus capsulatus (ozena bacillus).	L. 1.5 3.5 T. 0.8–1.3	—	+	—	+	—	+	16° to 43° C.	+	—	—	—	+	—	—	—	—	Grayish white.		
	14. Bacillus of Ducrey (ulcus molle).	L. 1.5 T. 0.4	—	—		+	—	—	..	—	—	—	—	+	—	—	—	—	—	—	—
	15. Bacillus of glanders (bacillus mallei).	L. 1.5–5.0 T. 0.25 0.5	—	—	—	+	—	—	22° to 43° C.	—	—	—	—	+ Sediment.	Flaky ..	+	Acid.	—	Whitish.	—	—

Diphtheria group.	16. Corynebacterium diphtheriæ Löffler.	L. 1.6-5.0 T. 0.5-1.0	—	—	+	+	+	—	16° to 45° C.	+	—	—	—	Flaky.	+	—	Both.	—	Grayish white.	—	—
	17. Corynebacterium pseudo-diphtheriticum.	L. 1.6-5.0 T. 0.5-1.0	—	—	+	+	+	—	14° to 45° C.	+	—	—	—	+	—	—	Slightly acid.	—	Whitish.	—	—
	18. Corynebacterium xerosis.	L. 1.6 5.0 T. 0.5-1.0	—	—	+	+	+	—	16° to 43° C.	+	—	—	—	Flaky.	—	—	Both.	—	Grayish white.	—	—
	19. Mycobacterium tuberculosis.	L.1.6-3.6 T. 0.2 0.3	—	—	+	+	+	—	30° to 42° C.	+	—	—	+	—	—	—	..	—	Whitish yellow.	—	—
Chaird forming.	20. Pneumococcus Fränkel-Weichselbaum	L. 0.8 T. 0.3-0.4	—	+	+	+	+	—	22° to 42° C.	+	—	—	—	Delicate.	—	+	Acid.	—	—	—	—
	21. Streptococcus pyogenes.	0.6-1.0	—	—	+	+	+	+	12° to 45° C.	+	—	—	—	Sediment.	+	+	Acid.	—	Grayish white. translucent	—	—
Staphylococcus group.	22. Staphylococcus pyogenes aureus.	0.5-1.0	—	—	+	+	+	+	8° to 43° C.	+	—	+	+	+	+	+	Acid.	—	Orange yellow.	+	—
	23. Staphylococcus pyogenes albus (liquefaciens).	0.5-1.0	—	—	+	+	+	+	8° to 43° C.	+	—	+	—	+	+	+	Acid.	—	White.	Trace	—
	24. Staphylococcus pyogenes albus, non-liquefaciens (candicans).	0.5-1.0	—	—	+	+	+	+	8° to 43° C.	+	—	—	—	+	—	—	Acid.	—	White.	—	—
	25. Staphylococcus pyogenes citreus.	0.5-1.0	—	—	+	+	+	+	8° to 43° C.	+	—	+	—	+	+	+	Acid.	—	Citron yellow.	—	—
Gram-negative diplococci.	26. Gonococcus (Neisser).	0.8	—	—	—	+ (Serum agar).	—	—	25° to 40° C.	+	—	—	—	+	—	—	—	—	Grayish.	—	—
	27. Diplococcus intracellularis meningitidis.	Varies.	—	—	—	+	—	—	23° to 42° C.	+	—	—	+	+ (?)	—	—	—	—	Grayish white.	—	—
	28. Micrococcus catarrhalis.	Varies.	—	—	—	+	—	+	16° to 42° C.	+	—	—	+	Flaky.	—	—	—	—	Grayish white.	—	—
	29. Micrococcus tetragenus.	1.0	—	+	+	+	+	+	20° to 43° C.	—	+	—	—	—	—	—	—	—	White.	—	—
Fungi.	30. Actinomyces bovis s. hominis (ray fungus).	L. 0.5-00 Small end. T. 0.4-0.6	—	—	+	+	+	+	35° to 50° C.	+	—	+	—	Sediment.	—	+	Slightly alkaline.	—	Greenish yellow.	+	—
	31. Aspergillus fumigatus, glaucus, nigricans.	....	..	..	..	+	..	+	20° to 43° C.	..	..	..	..	..	..	..	..	+	Smoky gray.		
	32. Penicillium glaucum.	....	..	..	..	+	..	+	16° to 43° C.	..	..	..	..	..	..	..	..	+	Black.		
	33. Achorion Schoenleinii (Favus).	....	..	..	..	+	..	+	20° to 43° C.	..	..	..	..	..	..	..	..	+	Yellow.		
	34. Trichophyton, (ringworm fungus).	....	..	..	..	+															
	35. Sporotrichum Beurmanni.	Filaments conidia.	—	—	..	+	—	+	18° to 36° C.	0	0	..	Deposit	..	—	—	Pigmentation.	+	Rounded spots. yellowish white.	—	—

INDEX.

A

Abducens, 38, 41
    paralysis, 736
Abduction, 730
Aberration, 94
    chromatic, 94, 702
    in refraction, 699
    spherical, 14
Ablepharia, 155
Abrasion of cornea, 305
Abscess of conjunctiva, 254
    of cornea, 280
    of eyelids, 160
    of lachrymal sac, 203
    of orbit, 624
Acanthosis nigricans, 169
Accessory sinuses, relation of disease of, to eye, 641
Accommodation, 100, 660
    absolute, 664
    amplitude of, 660, 663
    binocular, 664
    catoptric images in, 661
    degree of, 662
    mechanism of, 660
    paralysis of, 679
    power of, 660, 662
    range of, 660, 663
    reaction of iris in, 123
    region of, 664
    relative, 666
Accommodative asthenopia, 562
Achorion Schönleinnii, 187
Achromatopsia, 527
    hysterical, 569
Acne of conjunctiva, 260
    rosacea of cornea, 300
Acoin as a local anesthetic, 778
Acromegaly, cause of disease of optic chiasm, 526
    eye affections due to, 773
Actinomyces, 209
Actinomycosis of lachrymal sac, 209
    of orbit, 640
Adduction, 730
Adenocarcinoma of eyelids, 183
    of lachrymal gland, 199
Adenoids, relation of, to eye, 641
Adenoma of conjunctiva, 259
    of eyelids, 177
    of lachrymal gland, 199
Adenosarcoma of lachrymal gland, 199
Advancement operations, 886
After-cataract, 590
After-images, 424
Agar serum, 909
Agoraphobia, amblyopia associated with, 535
Albuminuric retinitis, 443
        in pregnancy, 450
Alcohol, methyl, 554
Alcohol-tobacco amblyopia, 546
Alexia, developmental, 533
Alopecia of eyelids, 186
Amaurosis, 527, 544, 568
    hysterical, 568
    toxic, 544
Amaurotic family idiocy, 488
Amblyopia, alcohol-tobacco, 546
    amaurosis, and hemianopsia without intra-ocular inflammatory changes, 527
    astigmic, 527
    cachexia, 560
    color, 527
    congenital, 527
    due to acetanilid, 559
        to alcohol, 544
        to antifebrin, 559
        to arsenic, 558
        to aspidium, 557
        to atoxyl, 551
        to calabar bean, 560
        to cannabis indica, 551
        to carbolic acid, 560
        to carbon and chloride of sulphur, 541
        to chloral hydrate, 560
        to coal-tar products, 559
        to cocaine, 560
        to coffee, 553
        to copper, 553
        to curare, 560
        to ergot, 558
        to exposure to cold, 537
        to filix-mas, 557
        to hasheesh, 551
        to iodoform, 550
        to ioduret and thiuret, 550
        to jaborandi, 560
        to lead, 551
        to leukomains, 560
        to male fern, 557
        to mercury, 559
        to meta-arsen-anilid, 559

Amblyopia due to methyl alcohol, 554
to muscarine, 560
to nitrite of amyl, 559
to nitrobenzol and dinitrobenzol, 551
to oil of wintergreen, 558
to opium, 560
to osmic acid, 560
to phosphorus, 559
to pomegranate, 558
to potassium chlorate, 560
to ptomain-poisoning, 560
to salicylic acid, 558
to saturnine, 551
to scammonium and colocynth, 560
to silver, 559
to stramonium, 553
to sulphuretted hydrogen, 560
to thyroidin, 553
to wood naphtha, 554
spirit, 554
ex anopsia, 533, 718
following paraffin injections, 534
hysterical, 568
lunar, 536
non-toxic, 527
from non-use, 533
psychical, 534
quinine, 555
reflex, 535
simulation, 535
in squint, 718
tobacco, 546
toxic, 544
traumatic, 474, 534
Amblyopic defects of visual fields not dependent on appreciable disease of media, retina, or optic nerve, 539
Amblyoscope, Worth's, 752
Ametrometer, Thompson's, 702
Ametropia, 100
application of glasses for correction of, 676
clinical varieties of, 668
due to errors of refraction, treatment of, 658
Amyloid disease of conjunctiva, 250
Anatomy of capsule, 67
of chorioid, 63
of ciliary body, 61
of conjunctiva, 53
of crystalline lens, 65
of eyeball, 29
of eyelids, 42
of iris, 58
of lachrymal apparatus, 50
of optic chiasm, 84
nerve, 81
of orbits, 29
of retina, 71
of sclera, 56
of vitreous, 69
Anemia of optic nerve, 494
pernicious, eye affections due to, 766
retinitis of, 437
Anemia of retina, 429
Anesthesia of conjunctiva, hysterical, 568
general, 777
infiltration, 779
Schleich's solutions for, 779
of lids, hysterical, 568
local, 778
of retina, traumatic, 474
Anesthetic, local, acoin as a, 778
cocaine as a, 778
eucaine as a, 778
holocaine as a, 778
tropococaine as a, 779
Anesthetics, 777
Aneurism by anastomosis, 177
as a cause of blindness, 520
of central artery of retina, 522
of eyelids, 177
of retinal vessels, 439
Angeoid streaks in retina, 454
Angio-caverno-endothelioma of eyelids, 177
Angiocavernoma of chorioid, 360, 376
of conjunctiva, 211
of lachrymal gland, 220
Angioma, 177, 211, 376
of chorioid, 376
of conjunctiva, 211
of eyelids, 177
of lachrymal gland, 199
of orbit, 632
of retina, 477
Angioneurotic edema of eyelids, 186
Angle, alpha, 664
of convergence, meter, 667
gamma, 664
of incidence, 89
meter, 91
of refraction, 89
Aniridia, 322
corneal defects in, 322
defects of crystalline lens in, 322
Anisometropia, 676, 701
Ankyloblepharon, 157, 191
Anophoria, 711
Anophthalmos, 607
congenital, 607
Anotropia, 712
Anterior chamber, 33
Anthrax of eyelids, 159
Antimetropia, 701
Antitoxin, diphtheria, 901
Antrum, relation of disease of, to eye, 642
Aphakia, 680
Aplasia of optic nerve, 493
Apoplexy, retinal, 442
Apparatus, lachrymal, 442
examination of, 111
Aqueous humor in glaucoma, 410
microscopic examination of, 908
Arc, pupillary reflex, 86
Arcus senilis corneæ, 300
Arecoline, 125
Argyll-Robertson pupil, 122
in tabes dorsalis, 348

Argyria conjunctivæ, 256
Arteria retinæ centralis, 80
Artery, angular, 47
anterior temporal, 47
ciliary, 38
cilioretinal, 81
frontal, 38
hyaloid, 20
eccentric, 597
persistent, 596
pseudo-, 597
infra-orbital, 47
lachrymal, 38, 47
nasal, 38
inferior, 81
superior, 81
ophthalmic, 38, 47
palpebral, 47
papillary, inferior, 81
superior, 81
retinal, 38
supra-orbital, 47
temporal, 81
transverse, 47
Arteries of chorioid, 64
of ciliary body, 63
of eyeball, 38, 47
of eyelids, 47
of retina, 79
Arteriocapillary fibrosis, 440
in retina, nature of changes in, 474
Arteriosclerosis, cause of atrophy of optic nerve, 520
of papillitis, 502
diffusa, 441
nodosa, 441
of retinal vessels, 440
Artificial eye, methods for improving movements of, 868
wearing of, 872
Asbestos chimney, 686
Aspergillus keratitis, 276
Asteroid hyalitis, 602
Asthenic paralysis, eye symptoms accompanying, 760
Asthenopia, 562
accommodative, 562
hysteria and, 562
muscular, 563
neurasthenic, 563
fatigue field of vision in, 564
Rosenbach's phenomenon in, 563
treatment of, 565
reflex, 567
retinal, 566
tarsal, 566
Astigmia, 102, 646, 648
against the rule, 674
axis of, 674
corneal, 648
dynamic, 648
hyperopic, 673
irregular, 648, 673, 700
lenticular, 648
mixed, 673
Astigmia, myopic, 673
postoperative, 648
regular, 103, 648
simple, 673
static, 648
varieties of, 673
with the rule, 674
Astigmic amblyopia, 527
charts, 692, 693
Asymmetry, chromatic, 61
Atheroma, cause of visual defects, 520
Atresia of canaliculi, 201
Atrophy of chorioid, 372
gyrate, 464
of conjunctiva, 251
of eyelashes and eyebrows, 187
of lachrymal gland, 199
of optic nerve, 516
secondary, 522
of retina, gyrate, 464
of retinal bloodvessels, 442
sclerosis of corneal margin and, 300
Atropine, 125, 682
Avulsio bulbi, 514
Avulsion of globe, 630
Axes of astigmia, asymmetrical, 675
heterologous, 675
homologous, 675
symmetrical, 674
Axial myopia, 649
peculiarities in refraction, 646
Axis of astigmia, 674
of a lens, 103
primary optic, 95
optical, 664

B

Bacillus of glanders, entrance of, through conjunctiva, 250
Koch-Weeks, 225
mucosus capsulatus, 250
pyocyaneus ulcer, 275
subtilis conjunctivitis, 250
ulceris corneæ, 267
Zur Nedden's, 267
Bacteria, cultivation of, 908
Bacterial examination before operation, 774
Bacterium coli conjunctivitis, 250
Bandages after operation, 776
Bar reading test for binocular vision, 732
Beriberi, eye affections due to, 766
Bifocal lenses, 706
Binocular diplopia, 715
fixation, 709
anomalies of, 709
field of, 728
tests of, 724
movements of eyeball, 721
single vision, 713
field of, 729
law of, 715
vision, tests of, 727, 732
Bitemporal hemianopsia, 540
Blastomycosis of eyelids, 175

Blennorrhœa, acute, 229
of lachrymal sac, 205
Blepharitis marginalis, 166
squamosa, 167
ulcerosa, 167
vaccine, 165
Blepharochalasis, 176
Blepharophimosis, 191
Blepharoplasty, 798
Dieffenbach's method, 798
Everbusch's method, 798
Knapp's method, 798
Landolt's method, 798
Blepharospasm, 192
fibrillary, 193
hysterical clonic, 568
senile, 193
Blind spot, Mariotte's, 141
enlargement of, 144
Blindness caused by aneurism pressing on optic nerve, 520
due to anemia caused by hemorrhage, 433
of one or both eyes, condition of pupil in, 347
without intra-ocular inflammatory manifestations, 527
Blood serum, Löffler's, 909
Blood-staining of cornea, 306
Blood-vessel formation in vitreous, 605
Blood-vessels, atrophy of retinal, 442
in optic-nerve atrophy, 521
preretinal, 439
Blue vision, 537
Bone beneath conjunctiva, 211
ethmoid, 31
formation in chorioid, 375
frontal, 30
lachrymal, 31
malar, 30
palate, 31
sphenoid, 31
Botryomyces, 176
Botryomycosis of eyelids, 175
Bowman's lachrymal probes, 207
Brain disease, diagnostic value of choked disk in, 508
reaction in, 123
Bright's disease, cause of papillitis, 501
Bulbar paralysis, eye-symptoms accompanying, 760
Buller's eye shield, 232
Buphthalmos, 304, 419
Burns of conjunctiva, 255
of cornea, 307
eyelids, 184

C

Cachexia amblyopia, 560
strumipriva, 772
Calcareous deposits on papilla, 524
Calcification of sclera, 316
Canal of Cloquet, 70
persistent, 597
lachrymal, 28, 50, 53, 195
Canal, Schlemm's, 34, 58
Canaliculæ, 28, 52
Canaliculi, anomalies of, 195
atresia of, 201
stenosis of, 201
Cancer of eyelids, 182
Röntgen rays in treatment of, 183
Cannulæ, lachrymal, 209
Canthoplasty, 792
Canthotomy, 792
Canthus, external, 43
internal, 43
Capsular cataract, 577, 579, 590
Capsule forceps, 837
lens, 21, 67, 843
anatomy of, 34, 67
development of, 21
Tenon's, 34, 46
Capsulotomy, 843
Carcinoma of chorioid, metastatic, 381
of ciliary body, 356
of eyelids, 182
of optic nerve, metastatic, 522
of orbit, 638
Cardinal directions of gaze, 720
Caries of orbit, 621
Cartilage in chorioid, 374
Caruncle, 260
affections of, 261
Cataract, 575
accompanying retinitis pigmentosa, 584
skin disease, 587
acquired, 580
albuminuric, 586
axial lenticular, 580
black, 583
capsular, 590
anterior, 577
polar, 577
posterior polar, 579
secondary, 590
chorioidal, 580
complicated, 580
or secondary, 584
congenital, 577
consecutive, 584
cortical, 580
diabetic, 585
diffuse, 577
discission in, 855
extraction of, 846
after-treatment in, 850
iridectomy preliminary to, 851
of lens and its capsule in, 851
linear, 850
Major Smith's method of, 852
operation on lens capsule after, 860
by suction, 853
with iridectomy, 841
hypermature, 581
immature, 580
incipient, 580, 591
inflammatory, 589

Cataract knives, 836
lamellar, 575
mature, 580
Morgagnian, 590
naphthaline, 588
nuclear, 580
occupation, 588
operations for, accidents occurring after, 857
in, 847
antisepsis in, 833
combined, 841
incision in, 839
partial, 591
primary, 580
progressive, treatment of, 593
punctate, 577
pyramidal, 577
raphanic, 587
reclination in, 854
result of ergot-poisoning, 587
of sea-sickness, 587
of systemic poisoning, 587
ripening of, artificial, 859
secondary, 584
after cataract extraction, 590
treatment of, 593
senile, 580
simple, 580
senile, course of, 583
etiology of, 580
pathology of, 581
symptoms of, 582
stellate, 589
symptomatic, 585
toxic, 587
traumatic, 588
zonular, 575
Cataracta fluida, 590
lactea, 590
nigra, 583
Catarrh of conjunctiva, Saemisch, 214
Catophoria, 711
Catotropia, 712
Cellulitis of orbit, 622
Centrad, 91
Centres, primary subcortical optical, 86
Cerebrospinal meningitis, eye-symptoms accompanying, 762
Cervical sympathetic nerve, resection of, 418, 831
Chalamydozoan, 220
Chalazion, 170
forceps, 170
operation for removal of, 780
Chancroid of eyelids, 174
Channels, lymph, 34
Chart for plotting the location of foreign bodies in eye and orbit, 878
Chiasm, optic, 411
anatomy of, 84
diseases of, 526
Chicken-pox, eye symptoms accompanying, 762
Chloroma of orbit, 634
Chlorosis, cause of papillitis, 501
Chlorosis, eye affections due to, 766
Choked disk, 503
diagnostic importance of, 508
pathology of, 506
symptoms of, 503
Cholera, eye symptoms accompanying, 762
Chorea, eye symptoms accompanying, 759
Choriocapillaris, 27, 64
Chorioid, 359
anatomy of, 63
angiocavernoma of, 360, 376
angioma of, 376
anomalies of, 359
atrophy of, 372, 464
bone formation in, 375
calcareous deposits in, 375
cartilage in, 374
coloboma of, 359
crescentic defects of, 373
detachment of, 373, 858
diseases of, 360
effects of uveitis on, 386
examination of, 133
excrescences of, 375
in glaucoma, 410
hyperemia of, 360
leprosy of, 371
leukosarcoma of, 377
melanosarcoma of, 377
metastatic carcinoma of, 381
multiple pedunculated polypoid granulation tumors of, 376
myoma of, 376
in myopia, 656
plexiform neuroma of, 376
retina and, gyrate atrophy of, 464
retinitis proliferans accompanying atrophy of, 374
rupture of, 374
sarcoma of, 376
diagnosis of, 380
metastatic, 381
treatment of, 381
tumors of, 376
wounds of, 374
Chorioidal cataract, 580
ring or crescent, 134
Chorioiditis, 360
areolaris, 366
centralis, 366
diffuse, 362
disseminate, 363
embolic, 367
guttate, 366
hemorrhagic, 371
metastatic embolic, 367
plastic embolic, 367
posterior staphyloma accompanying, 372
senile, superficial, 373
serofibrinous, 360
suppurative, 368
tubercular, 370
Chorioretinitis, circumscribed, 467

Chorioretinitis, diffuse, 466
macular, 466
pigmentosa, 374
syphilitic, 361, 466
Chromatometers, 152
Chromatophotometer, Chibert's, 152
Chromatopsia produced by certain drugs, 560
Chromidrosis, 173
Cicatrix, cystoid, 415
Cilia, 44
Ciliary body, 349
anatomy of, 61
anomalies of, 349
carcinoma of, 356
cysts of, 355
detachment of, 358
development of, 26
diseases of, 349
effect of uveitis on, 385
endothelioma of, 357
epithelial hyperplasia of, 356
in glaucoma, 410
glioma of, 356
gumma of, 355
inflammation of, 349
myoma of, 356
perithelioma of, 357
sarcoma of, 356
senile degeneration of, 354
syphilis of, 354
tubercular syphilide of, 355
tuberculosis of, 355
tumors of, 355
wounds of, 357
ganglion, 42
zone, 58, 61
wounds of, 357
Cilioretinal artery, 81
Circle of Haller, 65
of Zinn, 36
Cleft lid, 155
Clinoscope, 732
Cloquet, canal of, 70
persistent, 597
Cocaine, 125
as a local anesthetic, 778
conjunctivitis, 253
Colloid excrescences on papilla, 524
Collyria, 897
Coloboma of chorioid, 359
of crystalline lens, 573
iridis, 321
lentis, 571
of optic nerve, 491
palpebræ, 155
of vitreous, 596
Color-amblyopia, 527
Color blends, Jennings', 528
blindness, 528
acquired, 532
complete, 151
congenital, 528
etiology of, 528, 531
incomplete, 151
partial, 528
Color-blindness, special tests for, 153
Thompson's lantern for testing, 153
total, 528
field in glaucoma, 411
hysterical inversion of, 569
reversal of, 569
perception, 529
theories of, 528
sensations, primary, 528
sense, Donders' lantern for testing, 153
hysterical absence of, 569
perversion of, 569
measurement of, 151
Oliver's apparatus for testing, 154
quantitative determination of, 154
tests, 151
Pflüger's, 152
Colored shadows, 152
Colors, complementary, 530
contrary, 530
of spectrum, 88
Coma, eye symptoms in, 759
Commissure, external, 43
optic, 84
Commotio retinæ, 474
Compressor lentis, 62
Conical cornea, 303
Coniin, 125
Conjugate deviation, 754
foci, 93
paralysis, 754
spasm, 754
Conjunctiva, 211
abscess of, 254
acne of, 260
adenoma of, 259
amyloid disease of, 250
anatomy of, 49
anesthesia of, hysterical, 568
angiocavernoma of, 211
angioma of, 211
argyrosis of, 256
atrophy of, 251
bone beneath, 211
burns of, 255
congestion of, 112
cysts of, 259
emphysema of, 254
entozoa cysts of, 259
entrance of bacillus of glanders through, 250
epithelial plaques of, 259
epithelioma of, 260
fibroma of, 259
fibrous growths of, 212
gout of, 224
granuloma of, 259
hyperemia of, 212
injuries of, 255
leprosy of, 248
lipoma of, 211, 259
moles of, 212

Conjunctiva, myxoma of, 259
osteoma of, 259
palpebral, 49
pigmented patches of, 212
polypi of, 258
pseudoleukemic disease of, 251
pseudotuberculosis of, 253
Saemisch catarrh of, 214
siderosis of, 255
syphilis of, 248
telangiectatic growths of, 211
tuberculosis of, 246
tumors of, 259
cystic, 259
dermoid, 211
malignant, 260
vascular growths of, 258
wounds of, 255
xanthelasma of, 259
Conjunctival flaps, transplantation of, 861
sac, operation for restoration of, 802
temperature of, 112
secretion, collection of, for microscopic examination, 907
Conjunctivitis, 212
acute contagious, 225
associated, 213
bacillus subtilis, 250
bacterium coli, 250
catarrhal, 213
chronic, 251
cocaine, 253
diphtheritic, 238
diplococcus, 228
eczematous, 244
follicular, 216
gonorrheal, 221
in infants, 235
metastatic, 235
granular, 217
hemorrhagic, 225
herpetic, 214
hop picker's 253
Klebs-Loeffler, 238
Koch-Weeks bacillus, 225
lachrymal, 213
larval, 253
lithiasis, 214
membranous, 241
meningococcus, 237
micrococcus catarrhalis, 237
Parinaud's, 224
Petit's diplococcus, 229
petrificans, 214
Pfeiffer's influenza-bacillus, 227
phlyctenular, 244
pneumobacillus, 250
pneumococcus, 227
purulent, 229
simple, 213
spring catarrh, 214
staphylococcic, 245
streptococcus pyogenes, 228
subacute, 228
symptomatic, 213
Conjunctivitis, tea-leaf, 253
toxic, 252
vernal, 214
Conus, myopic, 650
Convergence, 666
amlpitude of, 667
anomalies, nature of, 743
excess, 744
combined with divergence insufficiency, 745
hysterical spasm of, 568
insufficiency, 748
and divergence excess, combined, 749
meter angle of, 667
movements of, 722
near-point, 730
negative, 667
positive, 667
prism, 730
range of, 667
reaction of iris to, 123
tests of, 730
Convergent squint, 711, 745, 751, 753
esophoria and, 74
Corectopia, 321
Cornea, abrasion of, 305
abscess of, 280
acne rosacea of, 300
anatomy of, 53
aniline staining of, 311
bacillus pyocyaneus ulcer of, 275
blood-staining of, 306
burns of, 307
cauterization of, 817
conical, 303
contusion of, 304
curvature of, 53
cyst of, 310
deposits of lime on, 299
of salts on, 298
diseases of, 262
endothelioma of, 309
epithelioma of, 309
examination of, 115
in exophthalmic goitre, 771
family degeneration of, 297
fibroma of, 309
foreign bodies in, 305
in glaucoma, involvement of, 408
gumma of, 297
herpes of, 285
hyaline degeneration of, 297
infiltration of, 295
irregularities of surface of, 115
lead incrustations on, 299
leukomata of, 311
lymph stasis in, 300
in myopia, 656
myxoma of, 309
opacities of, 116
striated, 296
papilloma of, 309
perithelioma of, 309
polypoid growths of, 309
relapsing erosion of, 288

Cornea, Saemisch's operation on, 817
sarcoma of, 311
scabies of, 300
sensibility of, 118
silver deposits on, 299
staphyloma of, 301
tattooing of, 211, 817
tuberculosis of, 289
tumors of, 308
dermoid, 308
teratoid, 308
ulcer of, 263
crescentic, 266
diplobacillary, 268
due to bacillus ulceris corneæ, 267
infected, 266
marasmic, 283
microscopic examination in, 908
Mooren's, 277
pneumobacillus, 275
pneumococcal, 269
simple, 266
streptococcus, 274
wounds of, 304
Corneæ, arcus senilis, 300
Corneal margin, sclerosis and atrophy of, 300
tissue, death of, 295
regeneration of, 262
transplantation of, 862
Cornu of eyelids, 180
Corona ciliaris, 62
Corrugator supercilii, 45
Cortex reflex, 125
Cortical cataract, 580
pupillary reflex, 124
visual area, 87
Couching needle, 854
Coverglass preparations, 910
Crescent, myopic, 650
Cretinism, eye affections due to, 771
Cryptophthalmos, 155, 608
Crystalline lens, 571
absence of, 572, 680
anatomy of, 65
in aniridia, defects of, 322
and its capsule, extraction of, 851
coloboma of, 573
development of, 20
diseases of, 571
dislocation of, congenital, 571
spontaneous, 594
traumatic, 594
effect of iritis on, 340
of uveitis on, 385
examination of, 126
extraction of, 844, 846
foreign bodies in, 595
in glaucoma, 410
in high myopia, removal of, 659
injuries of, 594
mobility of, 571
opacification of, 575
Crystalline lens, ossification of, 595
parasites in, 595
position of, 571
regeneration of, 595
Cul-de-sac, operation for restoration of, 802
Cupping of optic disk in glaucoma, 398
physiological, 400
Curvature myopia, 657
Cyanopsia, 537
Cyanosis, eye affections due to, 767
Cyclitic membrane, 351
Cyclitis, serous, 349
Cyclodialysis, 830
in treatment of glaucoma, 418
Cycloplegia, 681
in skiascopy, 688
Cycloplegics and mydriatics, table of, 682
use of, in determining errors of refraction, 681
Cyclophoria, 711, 750
Cyclotropia, 711, 712
Cylindrical lens, 94, 103
Cylindroma of eyelids, 184
of lachrymal gland, 200
of orbit, 637
Cystic degeneration of Meibomian glands, 171
Cysticercus of conjunctiva, 259
of orbit, 639
subretinal, 486
Cystitomes, 837
Cysts of ciliary body, 355
of cornea, 310
of eyeball, 608
of eyelid, 158, 172, 181
of iris, 341
of optic nerve, 522
of orbit, 638

D

Dacryo-adenitis, 196
acute, 196
metastatic, 196
subacute, 197
Dacryocystitis, 203
acute, 203
chronic suppurative, 102
congenital, 196
treatment of, 205
Dacryoliths, 198, 201
Dacryops, 198
Dalrymple sign in exophthalmic goitre, 769
Daltonism, 528
Daturia sulphate, 682
Daturine, 125
Day-blindness, 538
Declination, 731
negative, 712
positive, 712
Degeneration of ciliary body, senile, 354
of cornea, 297
glaucomatous, 402
Demodex folliculorum, 170

Dendrites, 73
Deposits in chorioid, calcareous, 375
on Descemet's membrane, 385
on papilla, calcareous, 524
of salts on cornea, 298
of silver on cornea, 299
Dermoid cysts of eyelids, 181
of orbit, 638
tumors of conjunctiva, 211
of cornea, 308
of eyelids, 158
Descemet's membrane, 26, 54, 297
deposits on, 385
Desiccation keratitis, 283
Desquamative eczema of eyelids, 163
Detachment of chorioid, 371
of ciliary body, 358
of iris, 344
of retina, 362, 482, 652
of vitreous, 605
Development of eye, 17
Deviation, comitant, 712
conjugate, 754
constant, 712
continuous, 712
diplopia due to, 716
intermittent, 712
latent, 710
lateral, 711
manifest, 710
nature of, 735
non-comitant, 712
periodic, 712
superable, 710
vertical, 711, 722, 731
Dextrotorsion, 712
Diabetes mellitus, eye symptoms accompanying, 761
Diabetic cataract, 585
iritis, 336
retinitis, 451
Diathetic disease, eye symptoms accompanying, 761
Dilatation of retinal veins, 429
Dilatator pupillæ, 59
tract, sympathetic, 123
Dionin, 895
in glaucoma, 413
Dioptre, 97
prism, 91
Diphtheria antitoxin, 901
eye symptoms accompanying, 762
faucial, relation of, to eye, 641
of lachrymal sac, 209
papillitis after, 502
Diplobacillus of Morax-Axenfeld, 268
Petit's, 268
Diplopia, 715
anomalous, 717
binocular, 715
due to deviation of eyes, 716
exceptions to law of, 717
monocular, 719
hysterical, 568
in paralyses of individual muscles, 735
Diplopia, physiological, 714, 715
produced by a prism, 716
tests for imbalance, 727
Dischromatopsia, hysterical, 569
Disciform keratitis, 279
Discission after cataract extraction, 860
Disk, choked, 503
Mason's, 150
Maxwell's, 153
optic, 81, 133, 135, 398
in optic-nerve atrophy, excavation of, 521
of Placido, 116
vascular anomalies of, 426
Dislocation of eyeball, 629
of globe, 613
of iris, 344
of lachrymal gland, 199
of lens, congenital, 571
spontaneous, 594
traumatic, 594
Disseminate chorioiditis, 363
Disseminated sclerosis, affection of optic nerve in, 518
Distichiasis, 158
operation for, 786
Divergence anomalies, nature of, 743
excess, 748
and convergence insufficiency, combined, 749
insufficiency, 745
combined with convergence excess, 745
movements of, 722
tests of, 730
vertical, movements of, 722
tests of, 731
Divergent squint, 711, 747
development of, 749
treatment of, 751
Dots, Gun's, 136, 464
Dressings, bandages, and protective appliances after operations, 775
Duboisine sulphate, 682
Duct, lachrymal, stenosis of, 202
operation for, 808
nasal, 52

E

Eccentric fixation, 709
hyaloid artery, 597
vision, 149
Ecchymosis of eyelids, 185
Echinococcus cysts of conjunctiva, 260
of eyelids, 182
of orbit, 639
in vitreous chamber, 604
Ectasiæ, corneal, 301
scleral, 317
Ectopia lentis, 571
Ectropion, 189
cicatricial, 185, 190
operations for, 793, 794, 796, 797
paralytic, 190
senile, 190

Ectropion, spasmodic, 189
tarsorrhaphy in, 793
of uvea, congenital, 323
Eczema of eyebrows, 186
of eyelids, 162
Eczematous conjunctivitis, 244
keratitis, 263
Edema of eyelids, 186
of retina, 471
traumatic, 474
Egyptian ophthalmia, 251
Electric light on retina, effect of, 476
Electricity in treatment of cataract, 593
of telangiectatic growths of orbit, 632
Electrolysis for removal of hair bulbs, 787
in treatment of lachrymal stenosis, 208
of tumors of eyelids, 178, 181
Elephantiasis of eyelids, 176
Emmetropia, 100
Emphysema of conjunctiva, 254
of eyelids, 185
of orbit, 185
Enchondroma of eyelids, 180
Endarteritis deformans, 440
Endocarditis, eye affections due to, 766
Endothelioma of ciliary body, 357
of cornea, 309
of optic nerve, 522
of orbit, 637
Enophthalmos, 114, 612
Entozoa cysts of conjunctiva, 259
intra-ocular, 617
in vitreous, 603
Entropion, 188
canthoplasty in, 792
cicatricial, 189
operations for, 786
resection of tarsus in, 788
knife, Wilder's, 791
spastic, 188
operation for, 786
Enucleation of globe, 866
Ephedrine, 125
Ephidrosis, 173
tincti, 173
Epibulbar growths, 617
Epicanthus, 156
Epilepsy, eye symptoms accompanying, 759
Epiphora, 200
in exophthalmic goiter, 770
Episcleritis, 312
partialis fugax, 312
persistent, 313
Epithelioma of conjunctiva, 260
of cornea, 309
of eyelids, 182
of lachrymal gland, polymorphous, 200
sac, 210
Erb's disease, eye symptoms accompanying, 760
Ergot poisoning, cataract as a result of, 587
Erysipelas, cause of papillitis, 500
eye affections due to, 763
of eyelids, 159
Erythema of eyelids, 158
Erythropsia, 536
Eserine, 125
in glaucoma, 412
Esophoria, 711
convergent squint and, 744
operative treatment of, 753
prisms for correction of, 703
Esotropia, 711
Essential ophthalmomalacia, 422
Ethmoid cells, relation of disease of, to eye, 642
Eucaine as a local anesthetic, 778
Eversion of eyelid, 111
Evisceration, 870
Exanthematous fevers, affections of eyelids accompanying, 162
Excavation of disk in glaucoma, 398
in optic-nerve atrophy, 521
Excursion test, 728
Exenteration of orbit, 863
Exercise of eye muscles, 751
Exercises, orthoptic, 751
Exophoria, 711
divergent squint and, 747
non-comitant, 747
prisms for the correction of, 703
Exophthalmic goiter, 768
eye affections due to, 768
Rosenbach's sign in, 770
Stellwag's sign in, 770
treatment of, 771
Exophthalmos, 113, 609
in goiter, 768
pulsating, 610
Exposure to cold, amblyopia due to, 537
optic neuritis, 501
Expression due to eye strain, facial, 567
Extorsion, 712, 731
Exudation, subretinal, 482
Eye, anatomy of, 29
artificial, methods for improving movements of, 868
wearing of, 872
fluorescin in examination of, 116
foreign bodies in, localization of, 873
microörganisms of, 914
muscles, exercise of, 751
governing movements of each, singly, 719
pathogenic microörganisms of, 914
position of lenses in relation to eye, 675
of opacities in interior of, 145
relation of diseases of throat, nose, and accessory sinuses to, 641
screen, Fuchs' wire, 777
shield, Andrews' aluminum, 777
Buller's, 232
McCoy's aseptic, 777
speculum, Weeks', 835, 883

Eye, sympathetic inflammation of, 389
irritation of, 388
tuberculosis of, 900
vesicle, primary, 18
secondary, 19
Eyeball, 607
amputation of, partial, 870
anatomy of, 31
anomalies of, 607
avulsion of, 630
burns of, 255, 307
cysts of, 608
development of, 31
dislocation of, 613, 629
disorders of associated parallel movements of, 754
endogenous infection of, 613
entozoa in, 617
enucleation of, 866
accidents during, 867
insertion of body into Tenon's capsule after, 869
removal of, 873
exogenous infection of, 613
field of action of muscles of, 720
foreign bodies in, 614
growths on exterior of, 617
injuries of, 612
luxation of, 629
movements of, 709
binocular, 721
parallel, 721
tests for, 722
operations on, 866
paralysis of ocular muscles following contused wounds of, 613
penetrating injuries of, with retention of foreign bodies, 614
primary position of, 720
prominence of, 113
rotation of, 719
sinking of, 114
subenucleation of, 871
tension of, 34, 114
tests of parallel movements of, 728
toleration of, for foreign bodies, 616
wounds of, 612
Eyebrows, diseases of, 186
and eyelashes, atrophy of, 187
disappearance of, in exophthalmic goiter, 771
favus of, 187
pediculosis of, 187
tinea tonsurans of, 187
Eyelashes, 44
and eyebrows, atrophy of, 187
premature grayness of, 186
Eyelids, 155
abscess of, 160
adenocarcinoma of, 183
adenoma of, 177
affections of, accompanying exanthematous fevers, 162
alopecia of, 186
anatomy of, 42
Eyelids, anesthesia of, hysterical, 568
aneurism of, 177
angio-caverno-endothelioma of, 177
angioma of, 177
cavernosum of, 177
venosum of, 177
angioneurotic edema of, 186
anthrax of, 159
blastomycosis of, 175
botryomycosis of, 175
burns of, 184
gunpowder, 185
carcinoma of, 182
chancroid of, 174
cornu of, 180
cylindroma of, 184
cysticercus of, 182
cysts of, 158, 172, 181, 182
development of, 28
ecchymosis of, 185
eczema of, desquamative, 163
hypertrophic, 163
moist, 162
edema of, 186
elephantiasis of, 176
lymphangiectodes of, 176
emphysema of, 185
enchondroma of, 180
epithelioma of, 182
erysipelas of, 159
erythema of, 158
eversion of, 111
favus of margin of, 169
fibroma of, 178
furunculosis of, 159
hyperemia of, 158
hysterical anesthesia of, 568
impetigo of, 159
infarcts of, 172
inflammation of border of, 166
injuries of, 185
leprosy of, 174
lichen simplex affecting, 162
lipoma of, 158, 179
lupus erythematosus of, 175
vulgaris of, 174
malignant pustule of, 159
milium of, 172
molluscum contagiosum of, 181
fibrosum of, 178
morphœa of, 176
noma of, 160
operations on, 780
osteoma of, 180
papilloma of, 179
plexiform neurofibroma of, 178
Röntgen rays in treatment of cancer of, 183
sarcoma of, 184
seborrhea of, 166
syphilis of, 173
tetanus following wounds of, 185
tophi of, 172
tuberculosis of, 174
tumors of, 176
dermoid, 158

Eyelids, tumors of, fibroid, 171
malignant, 182
ulcer of, 159
gangrenous, 160
rodent, 182
urticaria of, 158
vaccinia of, 165
with globe, failure of contact of, 158
xanthelasma of, 180
Eye strain, facial expression due to, 567
headache caused by, 760
head-tilting due to, 567
migraine caused by, 539
Eyes, deviation of, nature of, 735

F

Facial expression due to eye strain, 567
Fädchen keratitis, 280
Far point, 100
Fascia tarsoörbitalis, 47
Fatigue field of vision in neurasthenic asthenopia, 564
Favus of eyebrow, 187
of margin of eyelids, 169
Fever, rheumatic and relapsing, eye affections due to, 764
scarlet, eye affections due to, 765
typhoid, eye affections due to, 765
yellow, eye affections due to, 765
Fibrochondroma of orbit, 633
Fibroma of conjunctiva, 259
of cornea, 309
of eyelids, 178
of lachrymal gland, 199
of optic nerve, 522
lymphangiectatic, 522
of orbit, 632
Fibrous growths of conjunctiva, 212
tumors of eyelids, 171
Field of action of muscles of eyeball, 720
of fixation, 720
of light sense, measurement of, 150
of vision, combined, 142
for color, 142
for light perception, 140
in glaucoma, 411
limits of normal, 140
measurement of, 136
pathological defects of, 143
Filariæ in vitreous, 604
loa in orbit, 640
Filix-mas, amblyopia due to, 557
Fissure, palpebral, 42
Fistula of lachrymal gland, 198
sac, 205
Fixation, binocular, 666, 709
anomalies of, 709
field of, 728
tests of, 724
eccentric, 709
field of, 720, 723
line of, 664
monocular, 709
point of, 664
Fluoroscopy in examination of eye, 115
Foci, 93
conjugate, 93
of lenses, 95
Forceps, advancement, Prince's, 888
Reese's, 891
Weeks', 888
capsule, Smith's, 837
chalazion, 780
fine-tooth, Stevens', 883
fixation, Graefe's, 835
iris, 819, 836
Liebreich's, 821
trachoma, 800
Foreign bodies in cornea, 305
in globe, 614
and orbit, removal of, 873
in iris, 345
in lens, 595
in orbit, 628
in sclera, 319
in vitreous, 614
Form sense, 147
Fornix conjunctivæ, 49
Fovea centralis, 71, 78, 136
externa, 78
interna, 78
Fracture of walls of orbit, 626
Frame, trial, 695
adjustable, for facial measurements, etc., 705
Frontal sinuses, relation of disease of, to eye, 643
Fuchsin stain, 910
Function of iris, 320
of optic nerve, 491
of retina, 423
Fundus oculi in exophthalmic goiter, 771
normal appearance of, 133
sacci lachrymalis, 52
Fungus growths of vitreous, 606
Furunculosis of eyelids, 159
Fuscin, 74
Fusion, 712
centres, 713
faculty, 713
training, 751

G

Ganglion cells of retina, 24
ciliary, 42
Gasserian, 41
lenticular, 42
ophthalmic, 42
Gangrenous ulcerations of eyelids, 160
Gasserian ganglion, 41
Gelsemine, 125
Gerlier's disease, 742
Gerontoxon, 300
Giant magnets, 615
Giemsa's stain, 912
Gland, lachrymal, 28, 50
diseases of, 198
extirpation of, 807

Gland, Meibomian, 28, 44, 46
of Moll, 44
retention cysts of, 172
sebaceous, 28
sweat, 28
Zeiss, 44
Glasses, application of, for the correction of muscular anomalies, 676
for correction of ametropia, presbyopia, and errors of extra-ocular muscles, 704
mounting of, 704
Glaucoma, 397
absolute, 402
anterior chamber in, 397
aqueous humor in, 410
arterial pulsation in, 397
chorioid in, 410
ciliary body in, 410
color fields in, 411
complicated, 422
conditions influencing development of, 407
crystalline lens in, 410
cupping of optic disk in, 398
absolute, 400
cyclodialysis in, 418
diminution of vision in, 398
dionin in, 413
eserine in, 412
etiology of, 405
evolutum, 401
exciting causes of, 408
field of vision in, 404
fulminans, 403
halos in, 401
hemorrhagic, 421
heredity as a cause of, 407
increase in tension in, 405
infantile, 419
inflammatory, 400
chronic, 403
involvement of cornea in, 408
of iris in, 408
of lachrymal gland in, 408
iridectomy in, 414, 825
laceration of infratrochlear nerve in, 418
Lagrange operation in, 826
miotics in, 412
neurotomy in, 418
ophthalmosc opicappearance of disk in, 399
optic nerve in, 410
pathology of, 408
pilocarpine in, 412
predisposing causes of, 407
primary, 400
diagnosis of, 412
reduction of intra-ocular tension in, 416
sympathectomy in, 418
treatment of, 412
prognosis in, 416
relapses in, 415
retina in, 410
Glaucoma, secondary, 420
etiology of, 420
hypotony in, 422
reduction of intra-ocular tension in, 422
retinal hemorrhage as a cause of, 421
sympathectomy in, 422
simple chronic, 403
size of globe in, 407
stretching of supratrochlear nerve in, 418
subacute, 403
systemic conditions as a cause of, 407
time of operation in, 415
treatment of, medicinal, 412
operative, 414, 825
vitreous in, 410
Glaucomatous crisis, 401
degeneration, 402
ring, 403, 411
Glioma of ciliary body, 356
of optic nerve, 522
of retina, 477
development of, 478
diagnosis of, 480
pathology of, 480
treatment of, 481
Gliosarcoma of orbit, 637
Globe. *See* Eyeball.
Goiter, exophthalmic, 678
cornea in, 771
Dalrymple sign in, 769
disappearance of eyebrows and eyelashes in, 771
epiphora in, 770
etiology of, 768
fundus oculi in, 771
Gifford's sign in, 770
Graefe's sign in, 769
iris in, 771
ocular muscles in, 771
pigmentation of eyelid in, 770
Rosenbach's sign in, 770
Stellwag's sign in, 770
symptoms of, 768
tâche cérébrale in, 770
treatment of, 771
Gonorrhea, eye affections due to, 763
Gonorrheal conjunctivitis, 229
iritis, 334
Gout of conjunctiva, 224
eye symptoms accompanying, 761
Gouty iritis, 334
retinitis, 471
Grafts, Thiersch, 796
Gram stain, 911
Granular conjunctivitis, 217
Granuloma of conjunctiva, 259
of iris, 344
Graves' disease, 768
eye affections due to, 768
Green vision produced by certain drugs, 561
Gumma of ciliary body, 353

Gumma of cornea, 297
of iris, 331, 342
of optic nerve, 522
Gunpowder burns of eyelids, 185
Gun's dots, 136, 464
Gunshot wounds of orbit, 628

H

Habitus glaucomatosus, 402
Hair bulbs, electrolysis for removal of, 787
operation for removal of, 787
Headache caused by eye strain, 760
Head-tilting due to eye strain, 567
Hemangioma of orbit, 632
Hemeralopia, 144, 537
Hemiachromatopsia, 532
homonymous, 542
Hemianopsia, 540
absolute, 542
altitudinal, 541
binasal, 540
bitemporal, 540
development of, 543
dividing line in, 542
etiology of, 541
homonymous, 540
horizontal, 540
hysterical, 569
pupil in, 543
relative, 542
significance of various forms of, 543
treatment of, 543
vertical, 540
without intra-ocular inflammatory manifestations, 527
Hemiopia, 340
Hemoglobin media, 909
Hemorrhage, anemia due to, followed by blindness, 433
cause of optic-nerve atrophy, 521
from retinal vessels, 475
into optic nerve, 496
sheath, 496
into orbit, 626
into vitreous, 600
macular, 473
subretinal, 482
Hemostasis, local, 779
Heredity, cause of papillitis, 499
factor in production of color-blindness, 531
in optic-nerve affections, 518
Hernia of orbital fat, 640
Herpes of cornea, 285
corneæ febrilis, 286
neuralgicus, 286
zoster corneæ, 286
frontalis, 164
ophthalmicus, 164
orbitales, 164
Heterophoria, 710
comitant, strabismus and, 743
Heterophoria, prisms for correction of, 703
squint and, classification of, 710
symptoms of, 750
treatment of, 750
Heteroplasty, orbital, 869
Heterotropia, 710
Hippus, 320
hysterical, 568
Holocaine as a local anesthetic, 778
Homatropine hydrobromate, 682
Hooks, Tyrell's, 821
Hop picker's conjunctivitis, 253
Hordeolum, 161
Meibomianum, 161
Hutchinson teeth, 292
Hyaline bodies in papilla, 525
degeneration of cornea, 297
Hyalitis, 598
asteroid, 602
punctata, 598
purulent, 598
Hyaloid artery, eccentric, 597
persistent, 596
pseudo-, 597
Hydatid buzzing, 639
cyst of optic nerve, 522
of orbit, 639
in vitreous chamber, 604
Hydrophthalmos, 304, 419
Hyoscine, 125
Hyoscyamine, 125, 682
Hyperemia of chorioid, 360
of ciliary body, 349
of conjunctiva, 212
of eyelids, 158
of iris, 324
of optic nerve, 494
of retina, 426
Hyperidrosis, 173
Hyperopia, 100, 647
absolute, 668
correction of, 100
facultative, 668
latent, 668
manifest, 668
symptoms of, 669
total, 668
varieties of, 668
Hyperostosis of orbit, 622
Hyperphoria, 711, 750
prisms for correction of, 703
Hyperplasia of ciliary body, epithelial, 356
Hypertrophy of lachrymal gland, 199
Hypertropia, 711, 750
Hypopyon, 262
keratitis, atypical, 274
Hypotony in treatment of secondary glaucoma, 422
Hypotropia, 711
Hysteria, asthenopia and, 562
Hysterical amaurosis, 568
amblyopia, 568
Hystero-epilepsy, conjugate deviation of eyes in, 568

I

Idiocy, amaurotic family, 488
Idiopathic iritis, 336
Illiterates, test letters for, 148
Illumination, oblique, 116
Image, false, 715
real, 715
Images, incongruous, 718
in lens refraction, 96
by refraction, formation of, 94
suppression of, 534, 718
tipping of, 731
Imbalance, 710
diplopia test for, 727
parallax test for, 727
Impetigo of eyelids, 159
Implantation cysts of iris, 341
of orbit, 639
Incidence, angle of, 89
Incipient cataract, 591
Index myopia, 657
lenticular, 657
refractive, 89
Indirect method of ophthalmoscopy, 105
reflex, 121
Infarcts of eyelids, 172
Infectious diseases, affections of eye due to, 762
eye symptoms accompanying, 762
Infiltration anesthesia, 779
solutions for, 779, 780
Influenza, cause of papillitis, 500
eye affections due to, 763
Influenza-bacillus conjunctivitis, 227
Injections, intra-orbital, 899
pericorneal, 325
subconjunctival, 898
Inoculation of eyes of animals, 909
Instruments for operation, preparation of, 775
Insufficiency, convergence, 748
divergence, 745
of ocular muscles, 710
Intermittent exophthalmos, 610
International tests, Buchardt's, 148
Intestinal parasites, eye affections due to, 773
Intorsion, 712, 731
Intra-ocular entozoa, 617
Intra-orbital injections, 899
Inunctions, mercurial, 902
Iodoform, amblyopia due to, 550
Ioduret and thiuret, amblyopia due to, 550
Iridectomy, 818
forms of, 820
in glaucoma, 414, 825
accidents that may follow, 414
complications that may follow, 414
Iridencleisis, 824
Iridocyclitis, 349
plastic, 350
purulent, 350
Iridocyclitis, serofibrinous, 349
treatment of, 354
Iridocystectomy, 824
Iridodesis, 824
Iridodialysis, 344, 824
Iridoplegia, unilateral reflex, 347
Iridotomy, 821
extra-ocular, 824
Iris, 320
anatomy of, 58
angle, incision of, 829
anomalies of, 321
coloboma of, 321
cysts of, 341
implantation, 341
detachment of, 344
diseases of, 324
dislocation of, 344
effect of uveitis on, 385
examination of, 119
in exophthalmic goiter, 771
forceps, 819, 821, 836
Liebreich's, 821
foreign bodies of, 345
function of, 320
functional disturbances of, 345
in glaucoma, involvement of, 408
granuloma of, 344
gumma of, 342
hyperemia of, 324
inflammation of, 325
injuries of, 344
leprosy of, 343
lipoma of, 344
lymphomata of, 343
melanoma of, 324, 343
nevi of, 324
operations on, 818
papillomata of, 343
pigmentation of, 61
prolapse of, 345, 857
in cataract operations, 847
reaction of, 123
retroversion of, 244
sarcoma of, 342
scissors, 819
de Wecker's, 823
tumors of, 342
vascular growths of, 343
voluntary, 125
wounds of, 344
Iritis, 325
catamenialis, 335
croupous, 327
diabetic, 336
due to disorders of teeth and nose, 335
to infectious diseases, 335
gonorrheal, 334
gouty, 334
gummatous, 331
hemorrhagic, 330
herpetic, 337
idiopathic, 336
nodosa, 335
papillary, 331

Iritis, parenchymatous, 330
plastic, 328
purulent, 329
results of, 337
rheumatic, 333
secondary, 337
serofibrinous, 326
serous, 326
spongy, 327
sympathetic, 336
syphilitic, 330
tuberculous, 336
Irritation, sympathetic, 388
Ischemia of retina, 429

K

Keratectasiæ, 303
Keratitis arborescens, 282
aspergillus, 276
of Bombay, superficial punctate, 295
bullous, 287
deep vascular, 294
dendritic, 282
desiccation, 283
disciform, 279
eczematous, 263
e lagophthalmos, 283
Fädchen, 280
fascicular, 265
filamentous, 280
frenular, 265
furrow, 282
hypopyon, atypical, 274
lymphatic, 263
marginal, 266
superficial, 279
mycotic, 276
neuroparalytica, 165, 284
neuropathic, 284
parenchymatous, 290
phlyctenular, 263
relapsing traumatic, 288
ribbon, 298
sclerosing, 296
scrofulous, 263
sequestrating cicatricial, 298
snail's track, 265
striped, 858
suppurative, 263
syphilitic, 291
toxic, 301
tubercular, 289
Keratocele, 302
Keratoconus, 303
Keratoglobus, 304
Keratomalacia, 243, 283
Keratome, Agnew's angular, 818
Jaeger's angular, 819
straight, 819
Keratometry, principles of, 104, 108
Keratoplasty, 862
Keratosis nigricans, 169
pilaris, alopecia due to, 186
Kidneys, disease of, eye affections due to, 443
Knife, entropion, Wilder's, 791
Graefe's, 836
needle, 821
Knapp's, 856
Knives, canaliculus, 809
cataract, 836
Koch-Weeks bacillus, 225

L

Laceration of infratrochlear nerve in treatment of glaucoma, 418
of optic nerve, 514
of retina, 475
Lachrymal apparatus, 195
anatomy of, 50
anomalies of, 195
diseases of, 196
examination of, 111
operations on, 807
artery, 47
canal, 28, 50, 53
anomalies of, 195
canaliculi, 28, 52, 195, 201
cannulæ, 209
duct, stenosis of, 202
operation for, 808
treatment of, 206
gland, accessory, extirpation of, 808
atrophy of, 199
development of, 28
dislocation of, 199
extirpation of, 807
fistula of, 198
in glaucoma, involvement of, 408
hypertrophy of, 199
nerve supply of, 51
syphilis of, 200
trachoma of, 199
tuberculosis of, 199
tumors of, 199
nerve, 42
papilla, 52
probes, Noyes', 208
puncta, 28, 43
affections of, 200
sac, abscess of, 203
actinomycosis of, 209
anatomy of, 52
anomalies of, 195
blennorrhea of, 205
diphtheria of, 209
epithelioma of, 210
excision of, 810
fistula of, 205
follicular inflammation of mucous membrane of, 210
phlegmon of, 203
polypus of, 209
sarcoma of, 210
tuberculosis of, 209
secretion, 51
styles, 208

Lachrymal syringe, Anel's, 206
Lactation, eye affections due to, 767
Lacunæ, 54
Lagophthalmos, 155, 191
La grippe, eye affections due to, 763
Lamella, posterior limiting, 60
Lamina cribrosa in optic-nerve atrophy, 521
of Sattler, elastic, 64
vitrea, 60, 64
Landolt's ophthalmodynamometer, 730
Lanterns for testing the color sense, 153 154
Law of binocular single vision, 715
of diplopia, exceptions to, 717
of projection, 713
of refraction, 89
Lead, incrustations on cornea, 299
Leber's disease, 511
Lens axis of a, 103
capsule, 21, 67, 843
removal of portion of, 843
centre of, 98
crystalline, 20, 65, 571
extraction of, 844, 846
cylindrical, 103
determination of axis of cylindrical, 103
of power and centre of, 98
focal length of, 95
power of, 98
principal focus of, anterior, 93, 95
posterior, 95
primary optic axis of, 95
refraction, images in, 96
spoon, Bowman's, 838
star, 67
stenopeic, Stevens', 727
toric, 103
Lenses, 94
application of, for correction of ametropia, 676
asymmetrical, 94
biconcave, 94
biconvex, 94
bifocal, 706
achromatic, 707
Franklin, 706
Morck's, 707
paster, 706
prisms in, 708
cardinal points of, 95
classification of, 94
collective, 95
concavo-convex, 94
construction of, 705
convexo-concave, 94
cylindrical, 94
dispersive, 95
foci of, 95
mounting of, 704
numeration of, 97
obliquity of, 704
periscopic, 94, 705
plano-concave, 94
plano-convex, 94
Lenses, position of, 704
in relation to eye, 675
for skiascopy, Gruening's set of hand, 688
spherical, 94
toric, 94, 103, 705
trial, 696
method of employing, in determination of errors of refraction, 696
twisted, 705
Lenticonus, 573
Leontiasis osseous, 621
Leprosy of chorioid, 371
of conjunctiva, 248
of eyelids, 174
of iris, 343
of sclera, 316
Leptothrix buccalis, 201
Leukomains, amblyopia due to, 560
Leukomata of cornea, 311
Leukemia, eye affections due to, 766
Leukopsin, 423
Levaditi's silver stain, 912
Levator palpebræ superioris muscle, 47
paralysis of, 194
Levotorsion, 712
Lichen simplex affecting the eyelids, 162
Lid clamp, Knapp's modification of Desmarres', 786
Lid, cleft, 155
forceps, Weeks', 800
holder, Jaeger's, 787
reaction, 124
retractor, Desmarres', 838
Ligament, annular, 62
external palpebral, 44
suspensory, 23, 67, 69
Ligamentum pectinatum, 26, 55
Light perception, field of vision for, 140
reflexes, 120
sense, 149
transmitted, 118
Limbus, 49
conjunctivæ, 50
Lipoma of conjunctiva, 211, 259
of eyelids, 158, 179
of iris, 344
of orbit, 633
Liquor Morgagni, 581
Lithemic diathesis, eye symptoms accompanying, 761
Lithiasis conjunctivæ, 172, 214
Lupus erythematosus of eyelids, 175
vulgaris of eyelids, 174
Lymph channels, 34
stasis in cornea, 300
system, canalicular, 54
Lymphangiectasis of conjunctiva, 258
Lymphangioma of orbit, 632
Lymphoma of iris, 343
of lachrymal gland, 199
of orbit, 633

M

McHardy's perimeter, 138
MacNab's ointment, 273
Macropsia, 125
Macula lutea, 71, 78, 136, 475
in myopia, 652
senile circular defects at, 477
traumatic perforation at, 475
Madarosis, 168
Maddox double prism, 108, 731
rod, 698, 727, 731
Magnet, giant, Haab's, 879
Hirschberg's, 878
Innenpol, Mellinger's, 880
Magnets, 615
Magnifier, Jackson's binocular, 116
Malaria, cause of papillitis, 501
eye affections due to, 764
Malformations of skull as a cause of optic-nerve affections, 520
Malingering, Schmidt-Rimpler's test for, 536
tests for, 535
Wilbrand's test for, 535
Mania, postoperative, 858
Mask, Ring's ocular, 777
Massage, 896
in treatment of cataract, 593
Maxilla, superior, 30
Measles, eye affections due to, 763
Megalocornea, 304
Megalophthalmos, 304
Meibomian glands, 28, 44, 46
cystic degeneration of, 171
pyorrhea of, 172
stye, 161
Melanoma of iris, 324, 343
of retina, 477
Membrane, Bowman's, 26, 54
Bruch's, 60
cyclitis, 351
Descemet's, 26, 54
limiting, of retina, 72, 76
vascular, 22
Meningococcus conjunctivitis, 237
Menstruation, eye affections due to, 194, 767
Mercury, administration of, 902
injections of, intramuscular, 902
intravenous, 904
Meridians, 674
horizontal, 674
oblique, 674
principal, 102
vertical, 674
Meter angle, 91
of convergence, 667
Methylene blue stain, Loeffler's, 910
Micrococcus catarrhalis conjunctivitis, 237
Microörganisms, cultivation of, 908
of eye, 914
Microphakia, 571
Microphthalmos, 608
development of cysts in, 608
Microscope of Czapski, 116
Microscopic examination, preparation of specimens for, 907
Migraine caused by eye strain, 539
ophthalmoplegic, 741
Milium of eyelids, 172
Miner's nystagmus, 755
Miosis, amblyopia due to agents producing, 560
irritation, 347
paralytic, 346
Miotics, 125
in glaucoma, 412
Moles of conjunctiva, 212
Moll, glands of, 44
Molluscum contagiosum of eyelids, 181
fibrosum of eyelids, 178
Moon-blindness, 536
Morgagnian cataract, 590
Morphine, 125
Morphœa alba plassa, 176
of eyelids, 176
Motor oculi, 38
Movements of convergence, 722
of divergence, 722
vertical, 722
of each eyeball singly, 719
of eyeball and their anomalies, 709
binocular, 721
disorders of associated, 754
parallel, 721
refraction, of congenital origin, 756
tests for, 722
parallel, 728
Mucaine, 125
Mucocele, 202
Mumps, eye affections due to, 764
Muscæ volitantes, 598
Muscles, advancement of, 886
Brücke's, 62
ciliary, 62
of ciliary body, 62
compressor lentis, 62
corrugator supercilii, 62
displacement of insertion of, to correct torsion, 893
eye, exercise of, 751
extrinsic, 35
of eyeball, 35
of eyelids, 44
field of action of, 720
governing movements of each eyeball singly, 719
insufficiency of, 710
of iris, 59, 344
levator palpebræ superioris, 47
Müller's, 47, 62
affections of, 194
oblique, 37, 719
operations on, 882
overaction of, 743
paralysis of, 735
diagnosis of, 738
etiology of, 736
following wounds of globe, 613

Muscles, paralysis of, individual, 735
diplopia in, 735
innervational, 737
insertional, 737
prognosis of, 741
special types of, 741
structural, 736
symptoms of, 738
treatment of, 742
varieties of, 736
orbicularis palpebrarum, 44
recti, 35, 719
resection of, 891
of Riolani, 45
spasm of, 743
static condition of, Maddox rod for testing, 698
tensor chorioidea, 62
tarsi, 45
Muscular anomalies, application of glasses for correction of, 676
asthenopia, 563
Myasthenia gravis, eye symptoms accompanying, 760
Mycobacterium tuberculosis, 246
Mydriasis, 681
amblyopia due to agents producing, 560
in determining errors of refraction, 683
etiology of, 345
Mydriatics, 125
cycloplegics and, table of, 682
use of, in determining errors of refraction, 681
increased tension of eyeball as a contra-indication to use of, 681
Myodesopsia, 598
Myoma of chorioid, 376
of ciliary body, 356
Myopia, 100, 646
anatomical changes in, 650
axial, 649
chorioid in, 656
ciliary muscle in, 656
cornea in, 656
correction of, 101
curvature, 657
etiology of, 653
Fuchs' pigment spots in, 653
index, 657
lenticular, 657
influence of near work on, 654
of occupation on, 653
of posture on, 655
macula in, 652
malignant, 649
optic disk in, 651
nerve in, 651
physiological, 649
posterior staphyloma in, 650
progressive, 649
removal of lens in high, 659
retina in, 651
retinal supertraction in, 651
in school children, 654
Myopia, sclera in, 656
staphyloma verum in, 651
tension in, 657
treatment of, 658
lenses in, 670
operative, 658
vitreous in, 656
Myopic conus, 650
crescent, 650
in sclerochorioiditis posterior, 372
Myxedema, eye affections due to, 771
Myxoma of conjunctiva, 259
of cornea, 309
of optic nerve, 522

N

Nasal cavities, relation of disease of, to eye, 641
duct, 52
Near-point, convergence, 730
Necrosis of orbit, 621
syphilitic, 621
Needle-holder, Stevens', 883
Nerve, cervical sympathetic, resection of, 831
ciliary, 42
fifth, 41
fourth, 40
laceration of infratrochlear, 830
lachrymal, 42
optic, 491
atrophy of, 516
sixth, 41
supply of chorioid, 65
of ciliary body, 63
of conjunctiva, 50
of cornea, 55
of eyelid, 49
of iris, 61
of lachrymal gland, 51
of ocular muscles, 38
of retina, 81
third, 38
trigeminal, 41
Nervous system, diseases of, in relation to ocular conditions, 759
Neurasthenic asthenopia, 563
Neuritis, optic, 497
retrobulbar, 511
bilateral hereditary, 511
Neuro-epithelioma of retina, 477
Neurofibroma of eyelids, plexiform, 178
Neuroma of chorioid, plexiform, 376
of orbit, 634
Neuroretinitis, sympathetic, 390
Neurotomy, opticociliary, 831
in treatment of primary glaucoma, 418
Nevi of iris, 324
Nevus of eyelids, 179
vinosus, 179
Nicolle's thionin stain, 911
Nicotine, 125

Nictitation, 192
Night-blindness, 537
Nigricans, acanthosis, 169
keratosis, 169
seborrhea, 173
Nitrate of amyl, amblyopia due to, 599
Nitrobenzol and dinitrobenzol, amblyopia due to, 551
Nodal point, 94
Noma of eyelids, 160
Nose, optic-nerve atrophy accompanying, 519
relation of disease of, to eye, 641
Nyctalopia, 538
Nystagmus, 755
miner's, 756

O

Oblique illumination, 116
Obliquity of lenses, 704
Occlusio pupillæ, 339
Occlusion of lachrymal puncta, 200
Ocular conditions connected with general disease, 759
disturbances, hysterical, 568
manifestations, sympathetic, 388
muscles, 35
extrinsic, 35
insufficiency of, 710
operations on, 882
paralysis of, 735
vesicles, rudimentary, 609
Oculomotor nerve, 39
Ointment, MacNab's, 273
mercurial, 903
Opacification of lens or of its capsule, 575
Opacities of cornea, 116, 296
in interior of eye, position of, 145
of vitreous, 599
Operations, 774
bacterial examination before, 774
preparation of instruments for, 775
of patient for, 774
of skin in region of, 774
of surgeon and assistants for, 774
Ophthalmia, 212
chronic, 251
Egyptian, 251
migrating, 389
military, 214
neonatorum, 229, 235
nodosa, 253
sympathetic, 389
vaccine, 165
Ophthalmic artery, 38
Ophthalmodynamometer, 730
Ophthalmomalacia, essential, 422
Ophthalmometer, 109
Helmholtz's, 109
Javal-Schiötz, 109, 681
Ophthalmometry, 108, 684
Ophthalmophakometer, 686
Ophthalmoplegia, bilateral transient, 742
Ophthalmoplegia, chronic progressive, 741
exterior, 736
interior, 736
recurrent, 741
Ophthalmoscope, 126, 691
Loring's, 126
luminous, 129, 133
Morton's, 126
Ophthalmoscopic examination, direct method, 131
indirect method, 129
interpretation of, 129
Ophthalmoscopy, 105, 691
principles of, 104
Optic chiasm, 491
anatomy of, 84
disease of, 526
ciliary neurotomy in treatment of primary glaucoma, 418
disk, 81, 133
cupping of, in glaucoma, 398
physiological, 135
in myopia, 651
pigmentation of, 493
nerve, 491
affections of, in disseminated sclerosis, 518
due to heredity, 518
to malformations of skull, 520
in lateral sclerosis, 518
anatomy of, 81
anemia of, 495
angiosarcoma of, 522
anomalies of, 491
aplasia of, 493
arterial pulsation of, 494
atrophy of, 516
accompanying a serous discharge from nose, 519
after excessive sexual intercourse, 520
bloodvessels in, 521
caused by electricity, 519
due to internal hydrocephalus, 520
fields of vision in, 522
in general paralysis of insane, 519
lamina cribrosa in, 521
in lateral sclerosis, 518
ophthalmoscopic appearances in, 521
result of arteriosclerosis, 520
of hemorrhage, 521
secondary, 522
symptoms of, 521
in tabes dorsalis, 516
blindness caused by aneurism pressing on, 520
carcinoma of, metastatic, 522
circulatory disturbances of, 494
coloboma of, 491
compression of, 514

Optic nerve, cyst of, 596
hydatid, 522
development of, 25
diseases of, 494
endothelioma of, 522
fibroma of, 522
fibrosarcoma of, 522
function of, 491
in glaucoma, 410
glioma of, 522
gliosarcoma of, 522
gumma of, 522
hemorrhage into, 496
hyperemia of, 494
inflammation of sheath of, 513
injury to, 514
intra-ocular end of, gumma of, 524
tumors of, 524
laceration of, 514
in myopia, 651
myxofibroma of, 522
myxoglioma of, 522
myxoma of, 522
myxosarcoma of, 522
psammoma of, 522
pulsation of, 494
rupture of, 514
sarcoma of, 522
alveolar, 522
endothelial, 522
metastatic, 522
symptoms of, 523
treatment of, 524
sheaths, 82
hemorrhage into, 496
tumors of, 522
lymphangiectatic, 522
tubercular, 522
venous pulsation of, 494
neuritis, 497
exposure, 501
localizing value of, 509
rheumatic, 501
in sympathetic ophthalmia, 390
papilla, connective-tissue masses on, 493
tracts, 86
Optical centres, primary subcortical, 86
Optics, general principles of, 88
Ora serrata retinæ, 23, 71, 79
Orbicularis palpebrarum muscle, 44
diseases of, 192
examination of, 113
paralysis of, 193
reaction, 124
Orbit, 618
abscess of, 624
actinomycosis of, 640
anatomy of, 29
angioma of, 632
anomalies of, 618
auscultation in examination of, 115
carcinoma of, 638
caries of, 621
cellulitis of, 622
Orbit, chloroma of, 634
contents of, 31
cylindroma of, 637
cysts of, 638
cysticercus, 639
dermoid, 638
echinococcus, 639
hydatid, 639
implantation, 639
inclusion, 638
parasitic, 639
serous, 639
teratoid, 636
development of, 29
diseases of, 619
electricity in treatment of telangiectatic growths of, 632
emphysema of, 185
endothelioma of, 637
examination of, 115
exenteration of, 863
fibrochondroma of, 633
fibroma of, 632
filariæ in, 640
fluoroscopy in examination of, 115
foreign bodies in, 628
removal of, 873
treatment of, 628
fracture of walls of, 626
symptoms of, 627
treatment of, 628
gliosarcoma of, 637
hemangioma of, 632
hemorrhage into, 626
hyperostosis of, 622
influence of shape of, in refraction, 647
injuries of, 626
lipoma of, 633
lymphangioma of, 632
lymphoma of, 633
necrosis of, 621
neuroma of, 634
operations on, 863
osteoma of, 635
palpation in examination of, 115
periostitis of, 619
treatment of, 621
phlegmon of, 622
radiography in examination of, 115
rhabdomyoma of, 634
sarcoma of, 636
symptoms of, 637
treatment of, 637
telangiectatic growths of, 632
tumors of, 630
removal of, 864
wounds of, 628
Orbital fat, hernia of, 640
septum, 46
Orthophoria, 710
Orthoptic exercises, 751
Ossification of lens, 595
of sclera, 316
of viterous, 606
Osteochondroma of lachrymal gland, 199

Osteoma of conjunctiva, 259
of eyelids, 180
of orbit, 635
Ox eye, 419
Ozena bacillus, 250

P

Pain reaction of pupil, 123
Pannus, 288
Panophthalmitis, 368
treatment of, 369
Papilla, 49, 52, 81
calcareous deposits on, 524
colloid excrescences on, 524
connective-tissue masses on, 493
hyaline bodies in, 525
Papillæ, lachrymal, 52
Papillitis, 497
causes of, 499
color of disk in, 498
elevation of disk in, 499
excessive, 503
prognosis of, 510
treatment of, 510
Papilloma of conjunctiva, 259
of cornea, 309
of eyelids, 179
of iris, 343
Paracentesis, 816
needle, 816
of posterior chamber, 828
Paraffin injections, amblyopia following, 534
Parallax test for imbalance, 727
Paralysis of accommodation, 679
asthenic, eye symptoms of, 760
bulbar, eye symptoms accompanying, 760
conjugate, 754
of individual muscles, 735
of levator palpebræ superioris, 194
of muscles, diagnosis of, 738
etiology of, 736
following contused wounds of globe, 613
innervational, 737
insertional, 737
prognosis of, 741
special types of, 741
structural, 736
symptoms of, 738
treatment of, 742
varieties of, 736
oculomotor, 736
of orbicularis palpebrarum, 193
of sphincter pupillæ, 346
trochlear, 736
Parasites in crystalline lens, 595
intestinal, eye affections due to, 773
Parasitic cysts of orbit, 639
Paresis of abducens, hysterical, 568
Pars ciliaris retinæ, 24, 62
iridis retinæ, 24
non-plicata, 61
Pars plicata, 62
uvealis corneæ, 26
Parturition, eye affections due to, 767
Pediculosis of eyebrows, 187
Pemphigus, 223
Penicillium, 201
Perimeter, 723
Förster's, 139
McHardy's, 138
Meyrowitz's registering, 137
Priestley Smith's, 138
Purkinje's, 140
Schweiger's hand, 138
Perimeters, 137
Perimetry, 137
Perineuritis, 513
Periostitis of orbit, 619
due to pyogenic bacteria, 619
syphilitic, 620
tubercular, 620
papillitis as result of, 502
retrobulbar neuritis as result of, 502
Periscopic lenses, 94, 705
Perithelioma of ciliary body, 357
of cornea, 309
of retina, 477
Perivasculitis retinæ, 439
Pernicious anemia, retinitis of, 437
Perversion of color sense, hysterical, 569
Phlegmon of eyelids, 160
of lachrymal sac, 203
of orbit, 622
Phlyctena pallida, 214
Phorometer, Stevens', 728
Phosphorus, amblyopia due to, 559
Photometer, Förster's, 149
Phthiriasis, 169
Pigment of retina, 425
absence of, 424
changes marked by a disturbance of, 473
spots, Fuchs', 653
Pigmentation of chorioid, 359
of eyelid in exophthalmic goitre, 770
of optic disk, 493
of sclera, congenital, 312
Pigmented patches of conjunctiva, 212
Pilocarpine, 125
in glaucoma, 412
Pinguecula, 256
Pink eye, 225
Placido, disk of, 116
Plague, eye affections due to, 766
Plano-concave lenses, 94
Plano-convex lenses, 94
Plexus annularis, 56
marginal, 49
Plica semilunaris, 49
Plugging of central artery of retina, 430
Pneumobacillus conjunctivitis, 250
Pneumococcus conjunctivitis, 227
lanceolatus, 269
ulcer of cornea, 269
Pneumonia, eye affections due to, 766
Point of fixation, 664
of reversal, 107

Point of reversal, skiascopy in determining, 687
Points, corresponding, 713, 715
Poisons producing amaurosis and amblyopia, 544
Polariscope, 153
Polycoria, 321
Polyopia due to errors of refraction, 660
Polypi of conjunctiva, 258
Polypoid growths of cornea, 309
Polypus of lachrymal sac, 209
Posterior chamber, 33
Pregnancy, albuminuric retinitis in, 450
    eye affections due to, 767
Preiss' stain, 912
Presbyopia, 101, 678
    correction of, 101
Prisms, 89
    application of, 702
    batteries, 731
    in bifocal lenses, 708
    convergence, 730
    for constant use in squint, 753
    for correction of esophoria, 703
        of exophoria, 703
        of heterophoria, 703
        of hyperphoria, 703
    dioptre, 91
    diplopia produced by a, 716
    divergence, 730
    double, 731
    numeration of, 99
    optical, 89
Probes, lachrymal, 207
Processes, ciliary, 62
Projection, law of, 713
Prolapse of iris, 345
Prominence of eyeball, 113
Protective appliances after operation, 777
Psammoma of optic nerve, 522
Pseudoglioma of retina, 481
Pseudo-hyaloid artery, 597
Pseudoisochromatic powders, Mauthner's, 152
    tests, 152
Pseudoleukemia of conjunctiva, 251
Pseudotuberculosis of conjunctiva, 253
Pterygium, 257
    operation for, 806
    strangulation of, 807
    transplantation of, 806
Ptomaine-poisoning, amblyopia due to, 560
Ptosis, acquired, 187
    congenital, 157
    hysterical, 568
    in neurasthenic asthenopia, 563
    operations for, 781
Puerperium, eye affections due to, 767
Puncta lachrymalia, 52
        anomalies of, 195
        obliteration of, 808
Pupil, 33
    Argyll-Robertson, 122, 348
    condition of, in blindness, 347
    examination of, 120
Pupil in hemianopsia, 543
    irregularity in size of, 345
    measurement of, 120
    multiple, 321
    pain reaction of, 123
    reaction of, to remedies, 125
    in tabes dorsalis, Argyll-Robertson, 348
        condition of, 348
    traumatic paralysis of, 346
Pupillary membrane, persistent, 322
        remnants of, 323
    reaction, 122, 348
    reflex arc, 86
    zone, 58
Pupillometer, 120
Purpura hæmorrhagica, 439
        eye affections due to, 767
Pustule, malignant, of eyelid, 159
Pyemia, eye affections due to, 765
Pyorrhea of Meibomian glands, 172

Q

Quinine amblyopia, 555

R

Radiography in examination of eye, 115
Radium, 905
    effect of, on retina, 477
Reaction, pupillary, 122, 348
Recti muscles, 36, 37
    insufficiency of, 710
Reflex arc, pupillary, 86
    attention, 124
    consensual, 121
    cortex, 125
    direct, 121
    foveal, 136
    indirect, 121
    red, 106
    sensory, 123
Reflexes, light, 120
Refraction, 646
    aberration in, 699
    angle of, 89
    asymmetrical, 102
    axial peculiarities in, 646
    congenital influences in, 647
    correction of, in heterophoria and squint, 750
    errors of, 100, 646
        chart for recording, 683
        method of determining, 681
        subjective examination in determining, 691
    external conditions in, 646
    formation of images by, 94
    images in lens, 96
    influence of heredity on, 646
        of shape of orbit on, 647
    law of, 89

Refraction, methods of determining, 701
movements of eyeball, anatomical conditions present in, 757
of congenital origin, 756
polyopia due to errors of, 660
Scheiner's experiment to determine, 701
Regeneration of corneal tissue, 262
of lens, 595
Resection of cervical sympathetic in treatment of glaucoma, 418
Retina, 423
absence of pigment in, 424
anatomy of, 71
anemia of, 429
anesthesia of, traumatic, 474
aneurism of central artery of, 522
angeioid streaks in, 454
angioma of, 477
anomalies of, 424
atrophy of, gyrate, 464
changes marked by a disturbance of the pigment of, 473
of nature of an arteriocapillary fibrosis in, 474
detachment of, 482
in myopia, 652
symptoms of, 483
in syphilitic chorioretinitis, 362
treatment of, 486
development of, 24
dilatation of veins of, 429
diseases of, 426
edema of, 471, 474
effect of colored lights on, 424
of electric light on, 476
of radium on, 477
of Röntgen rays on, 476
of sunlight on, 475
of ultra-violet or chemical rays on, 477
of uveitis on, 386
examination of, 133
foreign body in, 881
function of, 423
in glaucoma, 410
glioma of, 477
treatment of, 481
hyperemia of, 426
immediate determining causes of detachment of, 483
injuries of, 474
ischemia of, 429
laceration of, 475
melanoma of, 477
in myopia, 651
neuro-epithelioma of, 477
opaque nerve fibers in, 425
overdistention of, 483
perithelioma of, 477
physicochemical changes in, 423
plastic exudation of, 472
plugging of central artery of, 430
pseudoglioma of, 481
rupture of, 475
serous exudation of, 471
Retina, tuberculosis of, 477
tumors of, 477
vascular anomalies of, 425
venous stasis of, 527
Retinal apoplexy, 442
asthenopia, 566
bloodvessels, aneurism of, 439
arteriosclerosis of, 440
atrophy of, 442
hemorrhage from, 475
hemorrhage, cause of secondary glaucoma, 421
perivasculitis, 439
pigmentation, 426
supertraction in myopia, 651
Retinitis, albuminuric, 443
complications of, 451
diagnosis of, 449
in pregnancy, 450
atypical forms of, 460
centralis punctata diabetica, 452
circinata, 455
circumscribed, 467
diabetic, 451
hemorrhagic, 452
punctate, 452
embolic metastatic, 470
gouty, 471
hemorrhagic, 442
hyperplastic, 458
leukocythemic, 435
macular, 471
of pernicious anemia, 437
pigmentosa, 460
cataract as an accompaniment of, 584
centralis, 460
symptoms of, 462
treatment of, 463
proliferans, 458
accompanying atrophy of chorioid, 374
punctata albescens, 463
purulent, 469
metastatic, 470
secondary, 470
traumatic, 470
septic, 471
solar, 475
striata, 455
syphilitic, 464, 465
diffuse, 465
etiology of, 468
macular, 465
without visible affection of chorioid, 465
Retinoscopy, 106, 686
Retrobulbar neuritis, 511
acute, 511
bilateral hereditary, 511
symptoms of, 512
treatment of, 512
chronic, 511
agents producing, 544
produced by arteriosclerosis, 502

Retrobulbar neuritis, result of periostitis, 502
toxic, 511
Retroversion of iris, 344
Reversal of color fields, hysterical, 569
point of, 107, 687
Rhabdomyoma of orbit, 634
Rheumatism, eye affections due to, 764
Rhinorrhapy, 156
Rhodopsin, 423
Ring, glaucomatous, 403, 411
Rod, Maddox, 698, 727, 731
Röntgen rays, 905
effect of, on retina, 476
for localizing foreign bodies in globe, 615
transparency of various substances for, 615
in treatment of cancer of eyelids, 188
Rotation, centres of, 666
of eyeball, 719
Rupture of chorioid, 374
of optic nerve, 514
of retina, 475
of sclera, 318

S

Sac, conjunctival, 49, 112, 802
lachrymal, 52, 195, 203, 205, 209, 210
excision of, 810
Saemisch catarrh of conjunctiva, 214
Salicylate of soda, 904
Salicylic acid, amblyopia due to, 558
Salmon patch, 294
Santonin, colored vision produced by, 561
Sarcoma of chorioid, 376
of ciliary body, 356
of cornea, 311
of eyelids, 184
of iris, 342
of lachrymal gland, 199
sac, 210
of optic nerve, 522
of orbit, 636
Scabies of cornea, 300
Scammonium and colocynth, amblyopia due to, 560
Scarificator, Weeks', 800
Scarlet fever, affections of eye due to, 765
Schleich's solutions for infiltration anesthesia, 779
Schlemm's canal, 34, 58
Scintillating scotoma, 539
Scissors, enucleation, 866
iris, 819
movement in skiascopy, 690
Stevens', 838
tenotomy, Stevens', 883
Sclera, 312
anatomy of, 56
calcification of, 316
congenital pigmentation of, 312
development of, 27, 32
Sclera, diseases of, 312
effect of uveitis on, 385
foreign bodies in, 319
in glaucoma, involvement of, 408
trephining of, 418
inflammation of, 312
injuries of, 317
leprosy of, 316
malignant growths of, 317
in myopia, 656
operations on, 827
ossification of, 316
removal of contents of, 870
rupture of, 318
staphyloma of, 317
syphilis of, 315
tuberculosis of, 316
wounds of, 318
Scleral ectasiæ, 317
ring or crescent, 134
Scleritis, 312
deep, 313
fugacious, 312
posterior, 316
scrofulous, 314
suppurative, 315
Sclerochorioiditis posterior, 372
Sclerociliotomy, 829
Sclerokerato-iritis, 314
Sclerosis and atrophy of corneal margin, 300
of optic nerve in lateral and disseminated, 518
multiple, eye-symptoms accompanying, 760
Sclerotomy, 827
posterior, 417
Scopolamine, 125
hydrochlorate, 682
Scotoma, 539
absolute, 143
fortification, 539
indistinct, 143
relative, 143
ring, 144
scintillating, 539
spectrum, 539
treatment of, 540
Screen test, 724
Scurvy, eye symptoms accompanying, 761
Sea-sickness, cataract as a result of, 587
Seborrhea of eyelids, 166
nigricans, 173
Seclusio pupillæ, 339
Secretion, lachrymal, 51
Selection test, 151
Sense of contrast, 149
measurement of, 150
form, 147
light, 149
Septicemia, eye affections due to, 765
Septum orbitale, 46
Sera, 900
Sexual organs, eye affections due to condition of, 767

Shadow test, 106
Shadows, colored, 152
Sideroscope, 615
Siderosis conjunctivæ, 255
Silver, amblyopia due to, 559
deposits on cornea, 299
Simulation amblyopia, 535
Sinuses, relation of disease of accessory, to eye, 641
Skiascopes, 686
Skiascopy, 106, 686
cycloplegia in, 688
Gruening's set of hand lenses for, 688
scissors movement in, 690
Skin disease, cataract accompanying, 587
Skull, affections of optic nerve due to malformations of, 520
Smallpox, eye affections due to, 765
Snow-blindness, 536
Spasm, conjugate, 754
of ocular muscles, 743
Spatula, 838
Spectroscope, 152
Ramsay's, 152
Spectrum, colors of, 88
scotoma, 539
Speculum, tear-sac, Meller's, 812
Weeks', 835, 883
Sphenoidal sinus, 644
Sphincter of eyelids, 44
pupillæ, 59
traumatic paralysis of, 346
Spirochæta pallida, 292
staining of, 912
Sporotrichosis, 169
Sporotrichum Burmanni, 169
Spring catarrh conjunctivitis, 214
Squint, 710
alternating, 712
amblyopia in, 718
convergent, 711
esophoria and, 744
treatment of, 751
divergent, 711, 747
exophoria and, 747
treatment of, 751
heterophoria and, 710
treatment of, 750
lateral, 711
monocular, 712
prisms for correction of, 753
spastic, 743
uniocular. 712
vertical, 711
vision in, 717
Staphylococcus conjunctivitis, 245
Staphyloma accompanying chorioiditis, 372
corneal, 301
pellucida, 303
posterior, 372
in myopia, 650
racemose, 301
Staphyloma of sclera, 317
verum in myopia, 651
Static astigmia, 648
Statometer of Snellen, 113
Stauungspapille, 503
Stellate cataract, 589
Stenopeic lens, Stevens', 727
Stenosis of canaliculi, 201
of lachrymal duct, 202
Stereoscope test of binocular vision, 732
Stereoscopic vision, 715
Stop needle, Bowman's, 856
Strabismus, 710
Stramonium, amblyopia due to, 553
Streptococcus pyogenes conjunctivitis, 228
Streptothrix Foesteri, 201
Stretching of supratrochlear nerve in absolute glaucoma, 418
Stye, 161
Styles, lachrymal, 208
Substantia propia, 54
Suction curette, 853
Sulcus scleræ, 53
Sunburst, astigmic, 693
Sunlight on retina, effect of, 475
Supertraction in myopia, 651
Suprarenal extract, 895
Suspensory ligament, 32, 67, 69
Sycosis parasitica, 169
Symblepharon, 157, 256
operation for, 801
Sympathectomy in treatment of primary glaucoma, 418
Sympathetic inflammation of eye, 389
iritis, 336
irritation, 388
neuroretinitis, 390
ocular manifestations, 388
ophthalmia, 389
Synchysis, 602
scintillans, 602
Synechiæ, 337
Syphilis, cause of papillitis, 500
of ciliary body, 354
tubercular, 355
of conjunctiva, 248
of eyelids, 173
of lachrymal gland, 200
of sclera, 315
Syringe, Anel's lachrymal, 206

T

Tabes dorsalis, Argyll-Robertson pupil in, 348
atrophy of optic nerve due to, 516
condition of pupil in, 348
Tâche cérébrale in exophthalmic goitre, 770
Tarsal plates, 45
Tarsitis, 173
Tarsorrhaphy, 793
Tarsus, resection of, in cicatricial entropion, 788
Tattooing of cornea, 311, 817
Tea-leaf conjunctivitis, 253

Teeth, Hutchinson, 292
Tendon folding or tucking, 892
hook, Stevens', 883
resection of, 891
Tenometer, 114
of Schiötz, 114
Tenon's capsule, 34, 47
Tenotomy, 882
Tension of eyeball, 34, 114
effect of iritis on, 340
in myopia, 657
in primary glaucoma, 416
in secondary glaucoma, 422
Tensor chorioidea muscle, 62
tarsi muscle, 45
Test for binocular vision, red glass, 732
card, 148, 692
for children, Wolfberg's, 148
chromatic aberration, 702
contrast, Holmgren's, 151
excursion, 728
for imbalance, 727
parallax, 727
letters, 147
for illiterates, 148
for malingering, Schmidt-Rimpler's, 556
screen, 724
selection, 151
shadow, 106
type, 147
Snellen's, 147
Testing central vision, 148
diminished vision, 148
functional, 110
vision for reading, 148
Tests of binocular fixation, 734
vision, 727, 732
Buchardt's international, 148
for color-blindness, 151
of convergence, 730
of divergence, 730
for malingering, 535
for movements of each eyeball singly, 722
of parallel movements of eyeball, 728
pseudo-isochromatic, 152
for squint, method of making, 734
for torsion, 731
of vision, method of making, 733
Tetanus following wounds of eyelids, 185
Thiersch graft, 796
Thiosinamin, 311
Throat, relation of diseases of, to eye, 641
Thrombophlebitis, orbital, 624
Tilting of head due to eye strain, 567
Tinea tonsurans of eyebrows, 187
Tipping of images, 731
Tobacco amblyopia, 546
Tonsurans, tinea, 169, 187
Tophi of eyelids, 172
Torsion, displacement of insertion of muscle to correct, 893
pathological, 731
tests for, 731
Toxemia, cause of papillitis, 502
Toxin theory of sympathetic ophthalmia, 393
Trachoma, 217
body, 220
stain, 813
forceps, Knapp's, 800
Noyes', 800
Prince's, 800
Rust's, 800
of lachrymal gland, 199
operations for, 799
Tracts, optic, 86
Transillumination, 118
Sachs', 118
Würdemann's, 119
Trephine, corneal, Von Hippel's, 862
Trephining of sclera in treatment of glaucoma, 418
Trial frame, adjustable, for facial measurements, etc., 705
for determining errors of refraction, 695
lenses, 696
Trichiasis, 187
operation for, 786
Trigeminal nerve, 41
Trochlearis, 37, 40
Tropococaine as a local anesthetic, 779
Tropometer, 723
Tubercle of iris, 336, 342
Tuberculins, 899
sera, and vaccines, 899
Tuberculosis of ciliary body, 355
of conjunctiva, 246
of cornea, 289
of eye, 900
of eyelids, 174
of iris, 336
of lachrymal gland, 199
sac, 209
of retina, 477
of sclera, 316
Tumors of chorioid, 376
of ciliary body, 355
of conjunctiva, 211, 259, 260
of cornea, 308
of eyelids, 176, 177, 182
of iris, 342
of lachrymal gland, 199
of optic nerve, 522
of orbit, 630
of retina, 477
of vitreous, 606
Tunic, inflammation of vascular, 384
Tunica vaginalis bulbi, 34
vasculosa lentis, 22
Typhoid fever, cause of papillitis, 502
eye affections due to, 765

U

Ulcers of cornea, classification of, 263
of eyelids, 159, 182
Ulcus atheromatosum corneæ, 298

Ultra-violet or chemical rays, effect on retina of, 477
Urticaria of eyelids, 158
Uvea, congenital ectropion of, 323
of iris, 60
Uveal layer, cysts of, 341
tract, 33
Uveitis, 384
anterior, 314
in sympathetic inflammation of eye, 389

V

Vaccine blepharitis, 165
Vaccines, 901
Vascular growths of conjunctiva, 258
tunic, inflammation of, 384
Vasomotor nerves of retina, 81
Vectis, 838, 852
Veins, ophthalmic, 38
retinal, dilatation of, 429
Vertical deviation, 711, 722, 731
Vertige paralysant, 742
Vesicles, rudimentary ocular, 609
Violet vision produced by certain drugs, 561
Vision, binocular single, 666, 713
field of, 729
tests for, 732
blue, 537
color, field of, 142
colored, 536
combined field of, 142
defects of, due to disease of retina and chorioid, 144
of periphery of field of, 144
eccentric, 149
field of, hysterical telescopic, 569
limits of, 140
measurement of, 136
pathological defects of, 143
functional disturbances of, 143
in glaucoma, field of, 404
line of, 664
red, 536, 561
in squint, 717
stereoscopic, 715
tests for binocular, 727, 732
for central, 148
for diminished, 148
yellow, 537
Visual acuity, 147
area, cortical, 87
defects, atheroma as a cause of, 520
Vitreous, 596
artificial, insertion of, 871
bloodvessel formation in, 605
chamber, 33
echinococcus in, 604
coloboma of, 596
detachment of, 605
Vitreous, effect of uveitis on, 386
entozoa in, 603
examination of, 126
filariæ in, 604
fluidity of, 602
foreign bodies in, 614
fungus growths of, 606
in glaucoma, 410
hemorrhage into, 600
hydatid cyst of, 604
inflammation of, 598
in myopia, 656
opacities of, 599
ossification of, 606
spheres, Mules', 871
tumors of, 606

W

Wheel, Green's astigmic, 692
Whooping cough, eye affections due to, 766
Word-blindness, congenital, 533
Wounds of chorioid, 374
of ciliary body, 357
of conjunctiva, 255
of cornea, 304
of eyeball, 612
of eyelids, tetanus following, 185
of globe, 612
of iris, 344
of orbit, 628
of sclera, 318

X

Xanthelasma of conjunctiva, 259
of eyelids, 180
Xanthoma of eyelids, 180
Xanthopsia, 537
produced by certain drugs, 561
Xanthopsin, 423
Xerophthalmia, 251
Xerosis epitheliatis, 242
infantilis, 242
triangularis, 242

Y

Yellow fever, eye affections due to, 765
vision, 537
produced by certain drugs, 561

Z

Zone, ciliary, 58, 61
pupillary, 58
Zygomatic process, 31

28.D.288
A treatise on diseases of the e1910
Countway Library BET6895
3 2044 046 010 807

28.D.288
A treatise on diseases of the e1910
Countway Library BET6895
3 2044 046 010 807